This is a digital copy of a book that was preserved for generations on library shelves before it was carefully scanned by Google as part of a project to make the world's books discoverable online.

It has survived long enough for the copyright to expire and the book to enter the public domain. A public domain book is one that was never subject to copyright or whose legal copyright term has expired. Whether a book is in the public domain may vary country to country. Public domain books are our gateways to the past, representing a wealth of history, culture and knowledge that's often difficult to discover.

Marks, notations and other marginalia present in the original volume will appear in this file - a reminder of this book's long journey from the publisher to a library and finally to you.

Usage guidelines

Google is proud to partner with libraries to digitize public domain materials and make them widely accessible. Public domain books belong to the public and we are merely their custodians. Nevertheless, this work is expensive, so in order to keep providing this resource, we have taken steps to prevent abuse by commercial parties, including placing technical restrictions on automated querying.

We also ask that you:

+ *Make non-commercial use of the files* We designed Google Book Search for use by individuals, and we request that you use these files for personal, non-commercial purposes.
+ *Refrain from automated querying* Do not send automated queries of any sort to Google's system: If you are conducting research on machine translation, optical character recognition or other areas where access to a large amount of text is helpful, please contact us. We encourage the use of public domain materials for these purposes and may be able to help.
+ *Maintain attribution* The Google "watermark" you see on each file is essential for informing people about this project and helping them find additional materials through Google Book Search. Please do not remove it.
+ *Keep it legal* Whatever your use, remember that you are responsible for ensuring that what you are doing is legal. Do not assume that just because we believe a book is in the public domain for users in the United States, that the work is also in the public domain for users in other countries. Whether a book is still in copyright varies from country to country, and we can't offer guidance on whether any specific use of any specific book is allowed. Please do not assume that a book's appearance in Google Book Search means it can be used in any manner anywhere in the world. Copyright infringement liability can be quite severe.

About Google Book Search

Google's mission is to organize the world's information and to make it universally accessible and useful. Google Book Search helps readers discover the world's books while helping authors and publishers reach new audiences. You can search through the full text of this book on the web at `http://books.google.com/`

Lu - 4

PRESENTED TO
LIBRARY OF
COOPER MEDICAL COLLEGE,
by Dr Henry Gibbons Jr

LIBRARY
OF
Cooper Medical College
DATE
NO. 483 SHELF E 5 24
GIFT OF
Prof. Henry Gibbons, Jr. M.D.

LANE
MEDICAL LIBRARY
LEVI COOPER LANE FUND

DISEASES OF THE EYE

INCLUDING THE

ANATOMY OF THE ORGAN.

TREATISE

ON THE

DISEASES OF THE EYE,

Including the Anatomy of the Organ.

BY

DR. CARL STELLWAG (VON CARION),

PROFESSOR OF OPHTHALMOLOGY IN THE IMPERIAL ROYAL UNIVERSITY OF VIENNA.

TRANSLATED FROM THE FOURTH GERMAN EDITION AND EDITED BY

D. B. ST. JOHN ROOSA, M.D.,
CLINICAL PROFESSOR OF THE DISEASES OF THE EYE AND EAR IN THE UNIVERSITY OF THE CITY OF NEW YORK, SURGEON TO THE MANHATTAN EYE AND EAR HOSPITAL.

CHARLES S. BULL, M.D.,
FORMERLY ASSISTANT SURGEON TO THE MANHATTAN EYE AND EAR HOSPITAL, CLINICAL ASSISTANT IN THE NEW YORK EYE AND EAR INFIRMARY, ETC.

AND

CHARLES E. HACKLEY, M.D.,
CLINICAL PROFESSOR OF THE DISEASES OF THE EYE AND EAR IN THE WOMAN'S MEDICAL COLLEGE OF THE NEW YORK INFIRMARY, SURGEON TO THE NEW YORK EYE AND EAR INFIRMARY.

LANE LIBRARY

FOURTH REVISED AND ENLARGED EDITION,

ILL[illegible]D BY WOOD ENGRAVINGS AND CHROMO-LITHOGRAPHS.

LANE MEDICAL LIBRARY
483
SAN FRANCISCO

NEW YORK:
WILLIAM WOOD & CO., 27 GREAT JONES STREET.
1873.

Entered according to Act of Congress, in the year 1873, by
D. B. St. JOHN ROOSA, M.D.,
In the Office of the Librarian of Congress at Washington.

LANE LIBRARY

Poole & Maclauchlan,
PRINTERS AND BOOKBINDERS,
205–213 *East 12th St.*,
NEW YORK.

410
S82h
1873

PREFACE

TO THE

FOURTH AMERICAN EDITION.

THE cordial appreciation by the English speaking profession of the translation of Professor Stellwag's work, has encouraged the undersigned to undertake and complete the task of preparing a new Edition from the last German one. It will be found that about one hundred and fifty pages are entirely new, while changes have been made in nearly every page of the work. The index of subjects has also been made more complete, while one of authors, which is not found in the German Edition, has been added.

Although the industry and erudition of the distinguished author have allowed the translators a very small field for the introduction of new material, the views of American and English writers have been amplified on some few points. The article on cataract has been enlarged by the description of two new methods of removing the crystalline lens. The subject of the use of the direct method of examining the fundus of the eye, has been fully discussed in the Appendix, and a description, with illustrations, of Dr. Loring's adaptation of the ophthalmoscope to this method has been added.

In presenting this volume, which is almost a new one, to the profession, the Translators venture to repeat the conviction expressed in

the Preface to the First Edition, that those who give it a careful study will thereby lay the foundations for a thorough and exact knowledge of the diseases of the eye, and they hope that its intrinsic merits of completeness and thoroughness, will atone for the difference which must exist between a translation and a work originally written in the English language.

D. B. St. John Roosa.
Charles S. Bull, of St. Louis, Mo.

New York, *March*, 1873.

TRANSLATORS' PREFACE.

The time has certainly come when a complete and acceptable treatise on the diseases of the eye, including its minute anatomy, will be cordially received by the American medical profession. We hope that the translation of Professor Stellwag's book, herewith presented, may prove to be such a work.

Doubtless a compilation adapted more especially to the professional habit of thought in England and the United States, would have some advantages over a work originally prepared for medical men speaking another tongue. But we have believed that the present work presented sufficient advantages to outweigh any such objections to it.

Moreover, without disregarding the great assistance rendered by English and French surgeons, we must consider the present advanced position of ophthalmology as due, in a great measure, to the labors of the Germans. Under these circumstances, it seems just to recognize this fact by presenting a text-book which is regarded as one of the best in the German language.

We had nearly finished a translation of the second edition, when the author informed us that a third was in preparation. The changes and additions were so many, that we found it necessary to begin our work anew, and we accordingly translated this third edition from advance sheets sent by the author. Thus our labors as translators were greatly increased, but on the other hand we found very little to do as editors.

Our work has been conscientiously performed, and yet, undoubtedly, many imperfections will be found, for which we ask the indulgence of the profession. We offer this book to our professional brethren with the firm conviction that those who give it a careful study will

thereby lay the foundation for a thorough and practical knowledge of the diseases of the eye.

In revising the translation and preparing it for the press, we have received the encouragement and assistance of our friends, Drs. George H. Humphreys and George M. Beard, to each of whom we desire to present our cordial acknowledgments.

The publishers also deserve our thanks for the hearty manner in which they have endeavored to render the mechanical execution of the work such as should be creditable to its subject.

The additions made by the Translators will be found inclosed in brackets, and in the Appendix.

CHAS. E. HACKLEY.
D. B. ST. JOHN ROOSA.

NEW YORK, *December*, 1867.

AUTHOR'S PREFACE

TO THE AMERICAN EDITION.

Ophthalmology has undergone many changes in the last fifteen years. We are no longer content with a methodical arrangement of the symptoms of disease, and with set empirical formulas for their cure; but we strive with all our might toward the proper understanding of pathological conditions and processes. The genius of the present age urges us on in this latter course, with great power, and the conviction is constantly becoming more firmly rooted, that it is only a clearer insight into the nature of morbid deviations, which can furnish a firm basis for treatment. Mere observations on patients are never sufficient for our present aims in the practice of ophthalmology. Every kind of scientific assistances must be brought in and made use of. Thanks to the united efforts of many able men, and to the division of labor among them, this requirement has been amply fulfilled, and we have fully realized the influence which an exact knowledge of the minute structure of the eye, its pathological anatomy, physiology, and optics, exert upon ophthalmology. In all the various departments of our knowledge of the diseases of the eye, this influence has been demonstrated by the most important advances. The greater portion of this subject has been newly worked up from the very foundations, while a number of portions, already fruitful, have been made to produce more abundantly. There has also been extraordinary progress in the resources of treatment.

Under such circumstances, the older text-books, excellent as they were in other respects, could no longer answer for the purpose of education in the science and art of ophthalmology. There was an imperative necessity for a treatise which should blend the acquisitions of an earlier period, with those of modern time, into an harmo-

nious whole. This is the task which I have undertaken, in offering the present work.

I have labored particularly to give a faithful and comprehensive representation of the present position of the science. I have, therefore, gone over the great mass of material on this subject, so far as it was accessible to me, with all possible care, and have taken from it what appeared to me to be valuable, or even that which, in spite of its inexactness, seemed to have acquired a certain importance, and, therefore, demanded elucidation.

The pathological descriptions depend, for the greater part, on my own labors. So far as microscopic conditions come into consideration, they rest on Professor Wedl's "Atlas der Pathologischen Histologie." This latter is a rich mine of unadorned facts, which has been often used by others, but which is apt to be seldom cited. In the preparation of the section on tumors, the excellent work of VIRCHOW has been used as the basis.

The part which treats of the anomalies of refraction and accommodation, rests in general on the principles which I first announced more than twelve years ago, in the Vienna Imperial Academy of Sciences, and which, since that time, have everywhere served as the basis of investigation. The nucleus of this subject lies in the strict separation of refraction and accommodation, and in the reference of the individual errors to deviations in the absolute visual distance; that is, to the difference between the distance of the far and near point of vision.

The section on impairments of the functions of the ocular muscles, appears as the first attempt to make a practical use of Listing's laws governing the movements of the eyes, and those educed by Hering as regulating binocular vision.

In order to remove any subjective coloring, as far as possible, I have avoided any allusion to my own writings in the text. On the contrary, where the labors of others of a recent date have been woven into the literature of the subject, and where it became necessary either to support the views advanced by an accumulation of authorities, or to leave the presentation of them to their originators, I have never neglected to give the names of the authors.

Those who are familiar with the literature of ophthalmology, will find many deviations when the citations of this work are compared with those of some other modern writings. The reason of this is, that I have kept myself strictly within the bounds of historical truth, and that I have disdained to injure or advance the interests of any persons or schools, by any misplacement of authorities.

When not otherwise indicated, the anatomical preparations from which the wood-engravings are made, were all taken from my collection.

The chromo-lithographic plates were made from originals and painted entirely from life, and the appearances of one eye were combined with those of another to a very small extent only, on account of want of room.

In the authorities, I have not given the titles of works in full, but this omission scarcely requires explanation.

STELLWAG.

VIENNA, *September*, 1867.

ADVERTISEMENT

TO THE

SECOND AMERICAN EDITION

Owing to the favorable reception and very rapid sale of the first edition of this work, there has been but little time for any advances to occur in our knowledge of ophthalmology, nor has there been much opportunity for a thorough revision of this book. The changes in the present issue consist chiefly in the correction of some typographical errors.

CONTENTS.

PART FIRST.

INFLAMMATION AND ITS CONSEQUENCES.

PAGE

INTRODUCTORY SECTION 1

FIRST SECTION.

KERATITIS 48
1. Vascular Keratitis 57
2. Herpes of the Cornea 60
3. Keratitis Punctata and Hydromeningitis 68
4. Diffuse Keratitis 70
5. Suppurative Keratitis 73

CONSEQUENCES OF KERATITIS.

1. Pannus 95
2. Opacities and Cicatrices of the Cornea 101
3. Staphyloma, or Ectasia 115
a. Corneal Staphyloma 115
b. Cicatricial Corneal Staphyloma 122
c. Cicatricial Staphyloma 123

SECOND SECTION.

INFLAMMATION OF THE VITREOUS—HYALITIS 133

THIRD SECTION.

INFLAMMATION OF THE OPTIC NERVE—OPTIC NEURITIS 144

FOURTH SECTION.

INFLAMMATION OF THE RETINA—RETINITIS 154
1. Diffuse Neuro-retinitis 172
2. Exudative Neuro-retinitis 183

PAGE
3. Nephritic Neuro-retinitis ..... 1[illegible]
a. Detachment of the Retina ..... 1[illegible]
b. Atrophy of the Retina and of the Optic Nerve, Amaurosis, Amblyopia ..... 2[illegible]
c. Pigment Degeneration of the Retina ..... 2[illegible]

FIFTH SECTION.

INFLAMMATION OF THE IRIS.—IRITIS 240

SIXTH SECTION.

INFLAMMATION OF THE CHOROID AND CILIARY BODY—CHOROIDITIS—CYCLITIS 273
1. Irido-cyclitis, Irido-choroiditis 291
2. Glaucoma 304
3. Suppurative Choroiditis 325

SEVENTH SECTION.

INFLAMMATION OF THE SCLERA.—SCLERITIS 334
Scleral Staphyloma 338
1. Sclero-choroidal Staphyloma 338
a. Complete Sclero-choroidal Staphyloma 338
b. Partial Sclero-choroidal Staphyloma 340
2. Posterior Staphyloma 348

EIGHTH SECTION.

INFLAMMATION OF THE CONJUNCTIVA, CONJUNCTIVITIS 357
1. Catarrhal Conjunctivitis 369
2. Membranous Conjunctivitis 376
3. Blennorrhœa and Pyorrhœa 379
4. Ophthalmia Neonatorum 390
5. Diphtheritic Conjunctivitis 395
6. Trachoma or Granular Ophthalmia 401
7. Herpes of the Conjunctiva 416

CONSEQUENCES OF CONJUNCTIVITIS.

1. Pterygium 419
2. Xerosis 425

NINTH SECTION.

INFLAMMATION OF THE LIDS.—BLEPHARITIS 427
1. Abscess of the Lid 437
2. Acne Ciliaris 439

PAGE
3. Blepharitis Ciliaris 441
4. Hordeolum 448

CONSEQUENCES OF BLEPHARITIS.

1. Ankyloblepharon and Blepharophymosis 454
2. Symblepharon 457
3. Distichiasis and Trichiasis 462
4. Entropion 470
5. Ectropion 477

TENTH SECTION.

INFLAMMATION OF THE LACHRYMAL APPARATUS 488
1. Phlegmonous Lachrymal Inflammation 496
2. Blennorrhœa of the Lachrymal Duct 500

ELEVENTH SECTION.

INFLAMMATION OF THE ORBIT 513
1. Basedow's, or Graves' Disease 520
1. Abscess of the Orbit 526
3. Caries and Necrosis 531

PART SECOND.

TUMORS.

1. Extraocular Tumors 569
2. Intraocular Tumors 575
Enucleation of the Globe 580
Adaptation of Artificial Eyes 583

PART THIRD.

CATARACT.

1. Discission 655
2. Linear Extraction 657
3. Flap Extraction 660
4. Peripheric Linear Extraction (Graefe) 665
5. Small Corneal Flap (Liebreich) 672
6. Streatfield's Operation 671

PART FOURTH.

FUNCTIONAL DISEASES.

FIRST SECTION.

PAGE
Errors of Refraction and Accommodation 677
1. Myopia 700
2. Hypermetropia 718
3. Astigmatism 730
4. Accommodative Asthenopia 740
5. Paralysis of Accommodation 742
6. Mydriasis 750
7. Spasm of Accommodation 753
8. Myosis 755

SECOND SECTION.

Entoptic Appearances, Scotoma 757

THIRD SECTION.

Hemeralopia 771

FOURTH SECTION.

Diseases of the Muscles 775
1. Convergent Strabismus 799
2. Divergent Strabismus 828
3. Nystagmus 839
4. Paralysis 842

Description of Chromo-lithographs 855

TRANSLATOR'S APPENDIX.

The Ophthalmoscope 864
Indirect Method 866
Direct Method 867
Loring's Ophthalmoscope 870
Jaeger's Test-types 873
Snellen's Test-types 891

LIST OF WOOD-CUTS

FIG.		PAGE
1.	Mode of making applications to the palpebral conjunctiva	44
2.	Anatomy of the cornea	48
3.	Onyx and hypopyon	75
4.	Ulcer of the cornea	81
5.	Perforation of the cornea	83
6.	" "	83
7.	" "	84
8.	" "	85
9.	Partial iris staphyloma	85
10.	Prolapse of the iris	86
11.	Staphyloma iridis or racemosum	87
12.	Paracentesis cornea	94
13.	Stop-knife for paracentesis	94
14.	Perforation of the cornea	104
15.	Cicatricial corneal staphyloma	122
16.	Cicatricial staphyloma	123
17.	" "	124
18.	" "	125
19.	" "	125
20.	" "	125
21.	" "	126
22.	Incision of staphyloma	128
23.	Excision "	129
24.	Critchett's operation for staphyloma	130
25.	Knapp's " "	131
26.	Remains of hyaloid artery	134
27.	Results of inflammation of the vitreous	141
28.	Results of suppuration of the cornea	141
29.	Anatomy of the optic nerve	145
30.	Congenital excavation of the optic papilla	1[illegible]3
31.	Macula lutea	158
32.	Halo around the macula	159
33.	Diffuse neuro-retinitis	173
34.	Register of field of vision	210
35.	Field of vision	212
36.	" "	212
37.	Iridectomy	263
38.	Iridodesis	269
39.	Iridenkleisis	270
40.	Glaucomatous excavation of the optic papilla	280
41.	Rupture of choroid	288
42.	" "	288
43.	Hydrops subretinalis	298
44.	Results of irido-choroiditis	299
45.	Limitations of the visual field in glaucoma	3[illegible]8
46.	Section of atrophied eyeball	330

FIG. PAGE
47. Sclero-choroidal staphyloma 339
48. " " " 339
49. Partial " " 341
50. Anterior scleral staphyloma 343
51. Posterior staphyloma 348
52. " " 349
53. " " 349
54. " " 349
55. " " 351
56. " " 351
57. Ligation of pterygium 422
58. Excision " 423
59. Structure of the eye-lids 427
60. Extirpation of tumors of the lids 453
61. Canthoplasty 455
62. Operation for symblepharon 459
63. " " 460
64. Operation for trichiasis 464
65. " " 466
66. " " 467
67. " " 467
68. " " 467
69. " " 468
70. " " 473
71. " " 475
72. Operation for ectropion 481
73. " " 482
74. " " 483
75. " " 484
76. " " 484
77. " " 485
78. " " 486
79. " " 486
80. Lachrymal apparatus 490
83. Introduction of the lachrymal probe 505
84. Horizontal median section of left orbit 513
85. Vertical section of right orbit 516
86. Intraocular tumor 545
87. " " 546
88. " " 553
89. " " 554
90. " " 556
91. Enucleation of the eyeball 581
92. Artificial eyes 584
93. Loring's cataract glasses 651
94. Scleroticonyxis 655
95. Keratonyxis 656
96. Linear extraction 657
97. Extraction of secondary cataract 658
98. Flap extraction 661
99. Peripherical linear extraction 665
100. Liebreich's corneal extraction 672
101. " " " 672
102. " " " 673
103. Schematic eye 684
104. Relative range of accommodation and convergence 689
105. Different states of refraction 692

FIG. PAGE
106. Determination of far-point by the ophthalmoscope 700
107. " " " 701
108. Determination of hypermetropia by the ophthalmoscope 719
109. " " " 719
110. Visual line 785
111. Deviations of visual line 787
112. " " 787
113. Instrument for measuring deviation 789
114. Fixation-point 791
115. Crossed and homonymous images 816
116. Operation for strabismus 819
117. Lateral or oblique illumination 863
118. Method of using ophthalmoscope 866
119. Arteries and veins of optic papilla 867
120. Loring's ophthalmoscope 870

PART I.

INFLAMMATION OF THE EYE AND ITS RESULTS

INTRODUCTORY SECTION.

GENERAL OBSERVATIONS ON THE INTRA-OCULAR CIRCULATION AND THE TREATMENT OF DISEASES OF THE EYE.

THE object of all treatment is to give as favorable a direction as is possible to the nutrition. By thus doing, resolution of any impairment of its functions is induced.

In order to properly fulfill this indication, it is necessary in the first place to thoroughly understand the circulation and innervation of the eyeball. The circulation in the interior of the eye is subject to different conditions from those which obtain in the scleral and orbital vessels and their branches.

In the interior of the eye, besides the common hindrances to the circulation, the fact must be taken into consideration, that the parts supplying the eye with blood—that is, the choroid and retina—are interleaved, as it were, between the dioptric media and the sclerotica, or capsule of the globe. The dioptric media are to be considered as substantially incompressible, on account of the very slight amount of dense material of which they are composed. The sclerotica, or capsule of the globe, however, is to a certain extent elastic and compressible. This property, according to the experiments of Mayrhofer, is chiefly to be ascribed to the *lamina cribrosa.*

In accordance with these anatomical conditions, the pressure of the blood in the interior of the eye, upon the walls of the vessels, so far as it is not neutralized by the contractile walls themselves, is transferred to the sclerotica, and distends this until its elastic counter-pressure is able to maintain an equilibrium with the powerful pressure of the blood.

The actual lateral pressure, or pressure of the blood upon the vessels, or its distending power, is called the intra-ocular or internal pressure.

This may be objectively appreciated by a hardness of the globe; but the external pressure and internal tension do not always exactly counterbalance each other, nor do they stand in a constant proportion to each other. The perceptible hardness of the globe is an expression of the resistance which the sclerotica in a state of tension offers to further distention. This resistance evidently depends not alone on the degree of the already existing tension—that is, not alone on the distending power, but on the amount of the elastic distensibility; in other words, on two entirely different factors, either of which may deviate from the normal.

Thus it sometimes occurs, for example, that the elastic tension of the sclerotica sinks very low, becoming almost nothing, while the resistance increases very much, the eyeball feels as hard as wood or bone, although the actual pressure of the blood in the walls of the internal vessels must be absolutely less.

We see from this, that the so-called tonometers or ophthalmotonometers are en-

tirely useless as measurers of the intra-ocular pressure. They can only measure the resistance which the surface of the globe offers to a substance pressing upon it (*Dor*, *Monnik*), that is to say, they measure a power which depends upon the intra-ocular pressure and the elastic distensibility of the sclerotic, or capsule of the globe, but which may be modified very much by the contraction of the external muscles of the eye, the circulation in the orbit, and so on. Besides all this, on account of the difficulty of applying the instruments twice in exactly the same manner, a proper comparison of the condition of the two eyes in the same individual is not always to be obtained.

If the equilibrium between the intra-ocular pressure and the elastic counter-pressure of the capsule of the globe be destroyed by an increase of the pressure of the arterial blood, the tension of the sclerotic, and with it its elastic counter-pressure, must evidently be increased. Since this elastic counter-pressure affects equally the whole intravascular region, which rests upon an incompressible basis, the arterial current will also meet with increased resistance upon its entrance into the interior of the eye, and will be weakened, while the venous blood is forced out from the interior of the globe at a somewhat accelerated rate. If, on the contrary, a disturbance of the equilibrium results from a lessening of the arterial blood-pressure, the tension, and with it the elastic counter-pressure of the capsule, must be lowered. The arterial current will then meet with less resistance upon its entrance into the intra-ocular space, and there press upon the walls of the vessels with a greater amount of force from the heart, while on the other hand the venous current is rendered somewhat slower on account of the weakening of a factor with considerable impelling force, that is, the pressure of the heart transmitted from the arteries through the capillaries.

The intra-ocular pressure, according to what has been said, may not increase or decrease proportionately with the pressure of the arterial blood, but to a much less proportionate degree. The effective power of the heart is, on the whole, a limited one, and the general pressure of the blood throughout the system appears to be capable of increase only within narrow limits. This is especially true of the periphery of the vascular system, when the blood has overcome so many resistances. We must therefore believe that the intra-ocular pressure can only be increased slightly, if at all, by a mere increase of the general pressure of the blood. Experience sustains this view, and at the same time justifies the correlative supposition, that mere diminution of the arterial blood-pressure will produce scarcely a noticeable diminution of the intra-ocular pressure.

Indeed, no difference can be detected in the average tension of the globe, when we compare the eyes of persons with decided plethora, who have a strong and full radial pulse with violent action of the heart, with those of very anæmic persons, or with persons suffering from Asiatic cholera (*Graefe*), or even when we compare them with the eyes of patients with a very weakened heart-action, and who are near their last moment, where the radial pulse is scarcely perceptible, thread-like, and very compressible. The tension of the eyeball is not decreased to any marked extent until the moment of death, when the visible internal vessels empty themselves, and the fundus of the eye becomes pale (*Bouchut*, *Hippel*, *Grünhagen*).

The slight variation of the intra-ocular pulse, and a certain constancy of the amount of blood-circulation in the interior of the eye, are intimately connected with the steadiness of the intra-ocular pressure, and regulate its effects. This constancy in amount does not prevent irregular distribution, however, but only

hypothecates the actually existing ability to equalize local overloading by equal depletions of other parts of the intra-ocular space (*Memorski*).

The variations in the pulse are indeed much less than would correspond to the caliber of the intra-ocular trunks. They are only perceived on the larger retinal veins, and by enlarging the ophthalmoscopic image (*Donders*). In the arteries, under normal circumstances, they cannot be objectively perceived, and subjectively, the arterial current in the entoptic, projected, choroidal image has either been found equable (*Vierordt, Laiblin*), or a slight isynchronous acceleration of the systolic sound has been with some difficulty recognized (*Berthold, Pope, Hippel, Grünhagen*).

The results of a number of physiological experiments on animals indicate that the amount of blood within the eye is unchangeable in quantity. In these experiments the current of blood to and from the head was partially or entirely interrupted by ligations of the principal blood-vessels of the neck (*Kussmaul, Memorski, Trautvetter, Weber*). To this may be added the fact, that even a very considerable active or passive hyperæmia of the adjacent orbital tissues does not necessarily produce a marked influence upon the amount in the intra-ocular vessels, and upon the color of the fundus. The official surgeons at executions by hanging, have observed an overloading of the scleral and orbital, but never of the intra-ocular vessels (*Memorski*).

The power of maintaining the equilibrium in the intra-ocular vessels is most plainly seen in the retina, because here abnormal dilatations of the veins are usually connected with marked contraction of the arteries. It exists in the uvea also, as we should suppose from the change in size of the ciliary processes necessary to the play of the pupil (*O. Becker*). If we remember, also, that in ischæmic conditions of the retina there is never any paleness of the fundus, and that in so-called embolism of the central artery of the retina, the nearly complete emptiness of the retinal vessels is accompanied by a dark redness in the region of the yellow spot, and sometimes with choroidal hemorrhage (*Mauthner*), the supposition is justified, that under the regulatory influence of the capsule of the globe, anomalies in the filling-up of the retinal vessels may be compensated for by an opposite condition of the uveal vessels. If we consider the fact, also, that the iris and choroid consist chiefly of vessels, and that the sum of their caliber is far greater than that of the retinal vessels, such a maintenance of the equilibrium in the quantity of the blood will appear to be very easy, and to be possible without any marked change in the caliber of the uveal vessels, and perhaps we may believe that the peculiar structure of the choroid is for the very purpose of rendering this maintenance of the equilibrium in the quantity of blood an easy task.

The regulatory influence of the elastic capsule of the globe is inefficacious if the venous flow from the interior of the eye be rendered difficult, or even if it be hindered. The intra-ocular pressure as well as the amount of blood circulating in the eye then increases, while greater variations appear in the pulsation of the larger vessels. Yet, according to physiological experiments (*Memorski*) and practical experience, congestions in the orbital veins and their branches are not sufficient to cause marked changes in the intra-ocular vessels. The causes of congestion must act upon the vessels as they emerge from the sclerotic in order to produce this effect.

The fact comes into consideration at this point, that the extra-ocular venous trunks have very thin walls, and that they run in a very loose yielding tissue—that is to say, they are exposed to a very slight external pressure, and besides this, the sum of their caliber far exceeds that of the intra-ocular veins. They can, then, offer very little resistance to the proportion-

ately very small current of the ocular and venous blood, as the current is forced outwards under the powerful elastic counter-pressure of the capsule of the globe. But if the causes of congestion act directly upon the emergent vessels of the sclerotica, the former equilibrium between the pressure of the blood upon the walls of the vessels and the elastic counter-pressure of the capsule can only be maintained if a corresponding acceleration of the blood-current takes place in the venous trunks still remaining free.

If this do not occur, there must be a disproportion between the flowing in and out of the blood: the amount of blood and the intra-ocular pressure must increase. This disproportion will become prominent the greater the arterial blood-pressure, and the greater the resistance of the veins. The equilibrium is thus disturbed, the tension of the capsule and its counter-pressure increased, and, in consequence, the venous trunks still remaining free, especially those near the emergent vessels, empty themselves at every pressure of the arterial blood-current more quickly and completely than otherwise, and then show variations in their pulsations. But when the partial retardation of the return of venous blood is insufficient to equalize the rhythmical increase in the arterial lateral pressure which causes it, that is to say, when the resistance of the arterial flow increases, the pulse must appear more and more distinct in the trunks of the arteries.

The regulative influence of the capsule of the globe is also diminished by the lessening of the elastic distensibility that is often connected with advanced senile changes in the eye, but which may also be observed as an habitual condition in some persons and even in whole families. On the one hand a rigid capsule offers great resistance to the dilatation of the venous emergent vessels, and thus renders the restoration of the equilibrium difficult, if an increase of the arterial flow of blood, however caused, demands an accelerated and increased exit of venous blood. On the other hand, we must consider that the regulative influence of the capsule of the globe can only be felt so far as a certain amount of elastic distensibility remains at our disposal as a reserve force. But this amount, with an equal amount of tension and elastic distensibility, will rise and fall in an inverse proportion with the rigidity of the capsule and the degree of the existing tension. If the elastic distensibility of the capsule be nothing from the very start, or if it be completely exhausted by tension, the regulative influence will, of course, be completely removed and the capsule be like a rigid wall.

It is all the same under these circumstances, whether the existing degree of tension be produced by the intra-ocular pressure or by a pressure acting from without on the globe, since this latter will be carried through the incompressible media upon the inner wall of the capsule. In consonance with this, pressure upon the eyeball with the finger will actually excite very great variations in the pulsation of the retinal vessels (*Graefe, Donders*). This will occur so much the more easily and certainly the more rigid is the capsule, and the greater the degree of tension already existing.

The regulative influence of the capsule of the globe is, besides, to a great degree dependent upon endosmosis and exosmosis as well as on the filtration of the eye.

This regulative influence must be considerably increased if the abnormal increase of the pressure in the globe, as in other parts of the body, lead to an increased carrying off of the nutrient material. An abnormal diminution of the pressure, on the contrary, leads to an increased deposition of material. In such a case, the intra-ocular pressure can never rise and fall to a degree correspondent to the increase or decrease of the lateral pressure in the intra-ocular vessels, and correspondent to the sum of the resistance of the venous current. The variations in the intra-ocular pressure must

always remain below this, and under favorable circumstances be completely neutralized. We may estimate the control of such compensatory currents as well as their power on the normal eye by a simple experiment. If a somewhat powerful pressure be exercised upon the globe, even for a short time, the dioptric media quickly lessen to a certain extent, but the loss is restored as soon as the pressure is removed (*Donders*). Now, whatever may be effected by an external pressure, may certainly also be accomplished by the counter-pressure of a capsule rendered very tense from within out, although the resultant of the changed conditions must show variation in certain respects. In fact, when an abnormal increase of the intra-ocular pressure induced by venous congestion exists, there is, as a rule, a marked decrease of the aqueous humor at a very early period, together with an equivalent increase of the vitreous humor. In this case the increased pressure of the capsule of the globe upon the dioptric media, and the increased pressure of the blood upon the wall of the vessels caused by the venous congestion, are to some extent opposed to each other. If we may draw conclusions from analogous conditions, we may say that the increased pressure of the capsule of the globe leads to an increase of resorption, and especially to an increase of the transfusion through the cornea, that is, to a lessening of the aqueous humor. The increased pressure of the blood upon the walls of the vessels must assist the filtration, especially in the choroid, and thus cause an increase in the vitreous humor.

In view of this, we need not, in order to explain these symptoms, accept the view that there is a peculiar anomaly of secretion or a peculiar disease, influencing the nerves of secretion (*Donders*, *Wegner*, *Hippel*, *Grünhagen*). Such an hypothesis is the less justifiable, from the fact that it must presuppose an opposite condition of innervation in the anterior and posterior half of the globe, respectively, and thus be inconsistent with the anatomical conditions of the ciliary nerves. So long, therefore, as the results of physiological experiments are so confused, and to some extent contradictory (*Wegner*, *Bernard*, *Donders*, *Adamük*, *Horper*, *Grünhagen*), it is better to hold to the simpler explanation that the increase of the vitreous as well as the lessening of the anterior chamber depend upon entirely analogous processes—that is, upon increased filtration from the vessels and greater transfusion through the cornea, and that these are both to be referred to the prevailing pressure.

Finally, the regulative influence of the capsule of the globe may be limited or completely removed by abnormal conditions of filtration and osmosis. Practically, only those deviations are to be considered which cause a diminution in the dioptric media, and which may thus completely destroy the resistance of the globe, so that it feels very soft and atrophied, and the cornea even becomes flaccid and wrinkled.

This condition of things, with apparent complete integrity of the individual parts of the eye, has been sometimes observed as a periodical affection, appearing in paroxysms and united with neuralgia of the fifth pair (*Graefe*). It has also been observed as an exacerbating and remitting affection (*Nagel*), and considered to be a kind of neurosis of secretion. As a rule, however, it accompanies manifest disease involving the nutrition (*Raleigh*), and is one of the most prominent evidences of beginning and advancing atrophy of the globe.

It is believed by many that an increase of the intra-ocular pressure, and consequently abnormal tension and limitation of the regulative influence of the capsule of the eye, may be caused solely by an increase of the dioptric media. Apart from the results of physiological experiments (*Grünhagen*, *Memorski*, *Adamük*, *Hippel*), we may urge against this view the fact that in a normal condition of the circulation the source of the secretion must soon become

More recent observations render it probable that in the so-called intermittent ophthalmia the effect of blood infected with malarial poison may exhibit symptoms in the sympathetic centers, and that thus this affection of the eye is a kind of a disguised intermittent fever. Intermittent ophthalmia is quite often described by the older authors (*Himly*, *T. Benedikt*, *Ruete*, *Mackenzie*), and very recently it has again attracted attention (*Eulenberg*, *Landois*). The affection is characterized by symptoms of vascular paralysis, which appear in distinct quotidian or tertiary forms, and, in the beginning at least, there is a complete intermission. These symptoms are usually confined to the conjunctiva and lids. These parts are more or less reddened, œdematous, while the mucous secretion is increased, and at times there is considerable ciliary irritation (*Staub*, *Mannhardt*) [*Roosa*]. In rarer cases the ciliary system is affected to a greater extent, and at times the affection presents the form of an intermittent iritis, with or without hypopyon (*Staub*). When the affection continues for a long time it is said to result in a permanent chronic ophthalmia, opacity of the cornea, atrophy of the eye (*Griesinger*). Some authors speak of intermittent amaurosis (*Teslelin*), but the proximate cause of such affections, and whether they could be directly referred to malarial infection, has not been made clear.

In the same way disturbances of circulation and nutrition may occur if the ganglia, the trunks, or branches of the sympathetic nerve are in any way affected. The type of the affection varies according to the location of the injurious impression, the anatomical conditions, and the physiological significance of the affected portion of the sympathetic nerve. We must therefore consider these facts a little more closely.

The center of the sympathetic system is generally considered to be in the medulla oblongata (*Schiff*, *Salkowski*), or still higher up, in the *crura cerebri* (*Budge*). A part of the fibers arising here originated from both the brain and the medulla, and lie on the trunks of some of the cerebral nerves, from there passing on to vessels, or, having united with the former, pass on to the periphery. Such fibers accompany the seventh nerve (*Schiff*, *Samuel*), and the fifth to their outermost limits.

Sympathetic twigs are united to the trunks of the latter, even in the brain, which are then pressed into a bundle on the united first and second branch of the fifth. They then extend to the Gasserian ganglion, where they are lost.

The greater portion, however, of the fibers arising in the brain pass downwards into the spinal cord and are here *probably* strengthened by fibers which spring from the spinal cord itself. The sympathetic fibers going to the eye and its appendages extend downwards into the anterior fibers of the medulla without crossing, and are here united to other fibrillæ, which probably proceed from the anterior and middle fibers (*Budge*). They appear to be nearly united with the anterior roots of the spinal nerves in question (*Budge*, *Salkowski*), beneath the sixth cervical ganglion and above the second (*Bernard*) or third (*Budge*, *Salkowski*) thoracic plexus. Only a small bundle, designed for the conjunctiva, the lids, and the lachrymal glands, passes up as high as the third cervical ganglion (*Landois*, *Eulenberg*). The bundles extending into the first and second cervical nerves appear in the two corresponding superior thoracic ganglia, and pass through the united portion of the marginal fibers into the cervical portion of the latter. This unites in itself all the sympathetic fibers proceeding from the eight cervical nerves, and has three large ganglia. The direction of the fibers in this portion is ascending, and is continued by the fibers from the upper cervical ganglion. These inclose the carotid, and extend with their branches, forming twigs over all the organs of the neck and head. A number of the fibers thus pass with the carotid into the cavity of the skull, and follow in part the ramifications of the vessels, but in part pass over from the cavernous sinus into the Gasserian ganglion; here they unite with the sympathetic fibers coming directly from the

the orbital tissue, and so on, all act together, and it is not possible to measure the individual action of these factors. We are, therefore, not justified in using the results of manometric experiments as premises for conclusions as to the intra-ocular pressure in the unopened eye. They are, however, of inestimable value, but only so far as they relate to the general laws of circulation.

We must not, however, consider the regulative influence of the intact capsule, and the constancy of the intra-ocular pressure, and the quantity of intra-ocular blood as absolute; in other words, we should not consider the autonomy of the intra-ocular circulation as being the same with entire independence. On the contrary, each change in the general blood-pressure must momentarily affect the intra-ocular circulation. The regulative effect of the capsule of the globe is nothing but the elastic reaction of the cornea and sclerotica to real disturbances of equilibrium, and requires a very small space of time. This is shown by the very slight variations which are observed on the central portions of the retinal veins, and in the entopic choroidal image in a normal condition synchronously with the heart's pulsation, and even with the varying respiratory pressure (*Donders*).

It is also a fact of importance that an elongation of the vascular current on the entoptic choroidal image may be observed on a slight pressure upon the eyeball (*Berthold*). We may also regard in the same light the retinal hemorrhages which are sometimes observed as a result of morbid muscular contraction; for example, after a severe fit of sneezing, coughing, or vomiting, and which are evidently to be referred to blood congestion.

Furthermore, we should not overlook the fact that the regulative effect of the elastic capsule of the globe does not exclude an uneven distribution of the amount of intra-ocular blood, and that strictly *localized* disturbances of circulation, as well as general ones, are destructive to the nutrition of the affected parts. They favor the development of circumscribed inflammatory masses, and may considerably modify their course. Finally, we should remember that the oculistic field extends beyond the interior of the eyeball into a vascular region, which is under the complete sway of the laws of the general circulation.

We must, therefore, in sketching out a plan of local treatment, be most careful of the influences which may impair the general circulation or nutrition. In this respect, besides some deviations in the quantity and quality of the blood, which will be better considered in the chapters on special diseases, there are certain disturbances of innervation to be considered. The sympathetic nerve alone can exert a direct influence, this being the nerve that supplies the muscles, and which probably directly influences the nutrition.

This influence is very markedly seen in paralysis or irritation of the sympathetic centers, apart from the consequences which result from the disturbance of the nutritive innervation itself. Marked hyperæmia or ischæmia may occur, which will unfavorably influence the nutritive processes, and which may be directly or indirectly caused. The latter may result from the fact that the narrowing or widening of large numbers of vessels must necessarily place the blood-pressure and the distention in the other portions of the current in opposition to each other.

Such central affections of the sympathetic are induced, according to physiological experiments on animals, by the action of blood poisoned with carbonic acid, through an interruption of the respiration (*Bezold*, *Ludwig*, *Théry*). Another source of these affections may be found in certain poisons, for example, curare, atropine, and calabar bean, when injected into the vessels (*Bezold*, *Götz*, *Bloebaum*), and thus brought in contact with the brain.

ately very small current of the ocular and venous blood, as the current is forced outwards under the powerful elastic counter-pressure of the capsule of the globe. But if the causes of congestion act directly upon the emergent vessels of the sclerotica, the former equilibrium between the pressure of the blood upon the walls of the vessels and the elastic counter-pressure of the capsule can only be maintained if a corresponding acceleration of the blood-current takes place in the venous trunks still remaining free.

If this do not occur, there must be a disproportion between the flowing in and out of the blood: the amount of blood and the intra-ocular pressure must increase. This disproportion will become prominent the greater the arterial blood-pressure, and the greater the resistance of the veins. The equilibrium is thus disturbed, the tension of the capsule and its counter-pressure increased, and, in consequence, the venous trunks still remaining free, especially those near the emergent vessels, empty themselves at every pressure of the arterial blood-current more quickly and completely than otherwise, and then show variations in their pulsations. But when the partial retardation of the return of venous blood is insufficient to equalize the rhythmical increase in the arterial lateral pressure which causes it, that is to say, when the resistance of the arterial flow increases, the pulse must appear more and more distinct in the trunks of the arteries.

The regulative influence of the capsule of the globe is also diminished by the lessening of the elastic distensibility that is often connected with advanced senile changes in the eye, but which may also be observed as an habitual condition in some persons and even in whole families. On the one hand a rigid capsule offers great resistance to the dilatation of the venous emergent vessels, and thus renders the restoration of the equilibrium difficult, if an increase of the arterial flow of blood, however caused, demands an accelerated and increased exit of venous blood. On the other hand, we must consider that the regulative influence of the capsule of the globe can only be felt so far as a certain amount of elastic distensibility remains at our disposal as a reserve force. But this amount, with an equal amount of tension and elastic distensibility, will rise and fall in an inverse proportion with the rigidity of the capsule and the degree of the existing tension. If the elastic distensibility of the capsule be nothing from the very start, or if it be completely exhausted by tension, the regulative influence will, of course, be completely removed and the capsule be like a rigid wall.

It is all the same under these circumstances, whether the existing degree of tension be produced by the intra-ocular pressure or by a pressure acting from without on the globe, since this latter will be carried through the incompressible media upon the inner wall of the capsule. In consonance with this, pressure upon the eyeball with the finger will actually excite very great variations in the pulsation of the retinal vessels (*Graefe, Donders*). This will occur so much the more easily and certainly the more rigid is the capsule, and the greater the degree of tension already existing.

The regulative influence of the capsule of the globe is, besides, to a great degree dependent upon endosmosis and exosmosis as well as on the filtration of the eye.

This regulative influence must be considerably increased if the abnormal increase of the pressure in the globe, as in other parts of the body, lead to an increased carrying off of the nutrient material. An abnormal diminution of the pressure, on the contrary, leads to an increased deposition of material. In such a case, the intra-ocular pressure can never rise and fall to a degree correspondent to the increase or decrease of the lateral pressure in the intra-ocular vessels, and correspondent to the sum of the resistance of the venous current. The variations in the intra-ocular pressure must

brain, and radiate in the fifth pair, in its peripheral course. With the first branch of the fifth, which, however, takes some twigs direct from the carotid plexus, the sympathetic fibers pass to the eye and its appendages, where they meet with other fibers, which belong to the vessels and the facial nerve.

The first branch of the fifth, whose roots, in common with those of the second branch, lie in the medulla oblongata, and are connected to the *corpus restiforme* (*Deiters*), passes, with the sympathetic fibers that are mingled with it, through the superior orbital foramen, and here, or somewhat earlier, divides into three branches. The lachrymal nerve passes to the lachrymal glands and to the outer portion of the upper lid. The frontal nerve supplies the integument of the forehead, and with a neighboring branch, the supra-trochlear nerve, the inner part of the upper lid and the root of the nose. The third branch, the naso-ciliaris, first gives off the ciliary nerves. It then divides into the infra-trochlear nerve, which radiates into the upper lid and the integument of the root of the nose, and into the ethmoidal nerve. This latter nerve runs through the ethmoid foramen into the cranial cavity, and from here through the cribriform plate into the nasal cavities, where it supplies the anterior portion of the Schneiderian membrane, and, being continued, perforates the nose between the lower border of the nasal bone and the cartilage, thus reaching the integument of the end of the nose, and is lost in terminal branches.

The nerve-fibers, intended to supply the globe of the eye itself, run in part directly from the naso-ciliary nerve, as long ciliary nerves, to the globe; but some of them run first into the ciliary ganglion as long roots, where they meet with fibers which, as short roots, have branched off from the third pair of cerebral nerves, and with others which the ganglion takes as nutrient branches from the surrounding sympathetic vascular tissue.

All these different kinds of fibers are thoroughly mingled in the short ciliary nerves passing out from here. They run through a number of small ganglion-like nodules (*C. Krause, H. Müller, Schweigger, and Sämisch*) embedded in the choroid, and finally, after very many plexus-like turnings (*Donders*), branch out in the different parts of the eyeball. A small portion of the sympathetic fibers in the cervical limiting cord act as motory nerves. They supply the dilator of the pupil as well as the organic muscles of the lid and the orbit. By regulating the tension of these muscles they have a reflex influence upon the circulation of the eye and its surroundings. The principal part of these fibers, however, are of the vaso-motory kind; with the systolic movements of the vessels they also gently influence certain other contractions and expansions, that are independent of the pulse, and which determine the blood-contents of every vessel, as well as the resistance to the current (*Schiff, C. Bernard*).

Interferences with the conducting power of the cervical or of its roots, according to practical experience (*Eulenberg, Guthman, Ogle*), exactly as division of the above-named parts in animals, result in a marked contraction of the pupil (*Petit, Biffi, Trautretter, Arlt, Jr.*) as well as of the palpebral fissure (*Cl. Bernard, R. Wagner, Remak*), a recession of the globe within the orbit (*Petit, Schiff, Prevost, Jolyet, Budge*), enlargement of the vessels of the iris, and a marked congestion of the affected side of the head, with increase of temperature. Irritation of the cervical and experimental excitations produce the opposite symptoms (*Cl. Bernard, Budge, Wegner, Salkowski, Donders*), provided the irritation does not extend beyond a certain degree, in which case the symptoms of paralysis rapidly appear.

The other bundle of sympathetic fibers, which springs directly from the brain,

obstructed of itself, to such an extent that the resistance of the arterial and venous flow increases with the increase of the media. Of course, however, we do not deny the possibility of considerable increase in the dioptric media. This occurs whenever the cavity of the globe is enlarged by staphylomata or ecstasiæ of any kind. It is then, however, not so much the cause as the result of the distention of the capsule, and the means by which the lateral pressure of the blood, flowing in the vessels which are but little capable of dilatation, is equalized with the elastic counter-pressure of the capsule.

If any part of the dioptric media have been evacuated through rupture of the walls of the globe, the intra-ocular vessels are under the same physical conditions as when a portion of the media have become softened on account of a wound of the sclerotica or cornea. The intra-ocular pressure and, with this, the elastic tension of the capsule fall to zero, while at the same time the substructure against which the capsule compresses the intra-ocular vessels is destroyed. The resistance which the capsule offers to the entrance of the arterial blood is thus removed, while at the same time one of the important factors in impelling the venous current is also removed. The intra-ocular vessels become distended as far as the local blood-pressure requires it, and as is allowed by the elastic contractility of its walls. Pulsations of the same kind as in other arteries of the same diameter are observed in the arteries, while the venous blood flows off in a more even current. In short, the intra-ocular circulation has lost its independent action, and it takes part in all the disturbances of circulation of the efferent and afferent vessels, and is therefore influenced by the condition of the tissue on the orbit, and the tension of the muscles surrounding the globe.

Proofs of this are furnished by a number of direct (*Memorski*) and especially manometric experiments (*Grünhagen*, *Wegner*, *Adamük*, *Hippel*, *Weber*). The latter are to a certain extent convincing, since the circulation of the eye is affected about in the same manner when a portion of the dioptric media is evacuated externally, as when it escapes into a well-fitting tube.

The fluid inclosed in the manometer must, of course, increase the resistance to the exit of the blood; but with the greatest care and improvement in the instruments (*Hippel*, *Grünhagen*, *Adamük*), they can never replace the elastic counter-pressure which constantly changes with the internal pressure. Hence the regulative influence which a completely closed, normal capsule of the globe exercises upon the intra-ocular current, and by means of which it strives to equalize each increase of the arterial flow by a corresponding increase in the venous current, is not completely compensated for in these experiments. Proofs of this are found in the rhythmical variations in the manometer column of fluid, isynchronous with the heart, and in the varying respiration, as well as in the great contraction of the pupil (*Hippel*, *Grünhagen*, *Adamük*) which occurs even in eyes fully under the influence of atropine, at the instant the canula is forced through the capsule. The contraction of the pupil continues as long as the tube allows any distention of the media. This myosis, as we may suppose from analogy, indicates with great probability that the tension is greatly reduced, or that it is at zero.

The very great differences which are shown by modification of the experiment in a medium elevation of the manometer column do not contradict this view by any means; for these are the expression of the control of a sum of very different forces, which allow the distention of the media, but which cannot be transferred to the opened capsule in such a way as to bring out its elastic counter-pressure. In this case the lateral pressure in the intra-ocular and orbital vessels, the state of tension of the inorganic and organic muscles which surround the globe, the resistance of

the orbital tissue, and so on, all act together, and it is not possible to measure the individual action of these factors. We are, therefore, not justified in using the results of manometric experiments as premises for conclusions as to the intra-ocular pressure in the unopened eye. They are, however, of inestimable value, but only so far as they relate to the general laws of circulation.

We must not, however, consider the regulative influence of the intact capsule, and the constancy of the intra-ocular pressure, and the quantity of intra-ocular blood as absolute; in other words, we should not consider the autonomy of the intra-ocular circulation as being the same with entire independence. On the contrary, each change in the general blood-pressure must momentarily affect the intra-ocular circulation. The regulative effect of the capsule of the globe is nothing but the elastic reaction of the cornea and sclerotica to real disturbances of equilibrium, and requires a very small space of time. This is shown by the very slight variations which are observed on the central portions of the retinal veins, and in the entopic choroidal image in a normal condition synchronously with the heart's pulsation, and even with the varying respiratory pressure (*Donders*).

It is also a fact of importance that an elongation of the vascular current on the entoptic choroidal image may be observed on a slight pressure upon the eyeball (*Berthold*). We may also regard in the same light the retinal hemorrhages which are sometimes observed as a result of morbid muscular contraction; for example, after a severe fit of sneezing, coughing, or vomiting, and which are evidently to be referred to blood congestion.

Furthermore, we should not overlook the fact that the regulative effect of the elastic capsule of the globe does not exclude an uneven distribution of the amount of intra-ocular blood, and that strictly *localized* disturbances of circulation, as well as general ones, are destructive to the nutrition of the affected parts. They favor the development of circumscribed inflammatory masses, and may considerably modify their course. Finally, we should remember that the oculistic field extends beyond the interior of the eyeball into a vascular region, which is under the complete sway of the laws of the general circulation.

We must, therefore, in sketching out a plan of local treatment, be most careful of the influences which may impair the general circulation or nutrition. In this respect, besides some deviations in the quantity and quality of the blood, which will be better considered in the chapters on special diseases, there are certain disturbances of innervation to be considered. The sympathetic nerve alone can exert a direct influence, this being the nerve that supplies the muscles, and which probably directly influences the nutrition.

This influence is very markedly seen in paralysis or irritation of the sympathetic centers, apart from the consequences which result from the disturbance of the nutritive innervation itself. Marked hyperæmia or ischæmia may occur, which will unfavorably influence the nutritive processes, and which may be directly or indirectly caused. The latter may result from the fact that the narrowing or widening of large numbers of vessels must necessarily place the blood-pressure and the distention in the other portions of the current in opposition to each other.

Such central affections of the sympathetic are induced, according to physiological experiments on animals, by the action of blood poisoned with carbonic acid, through an interruption of the respiration (*Bezold*, *Ludwig*, *Théry*). Another source of these affections may be found in certain poisons, for example, curare, atropine, and calabar bean, when injected into the vessels (*Bezold*, *Götz*, *Bloebaum*), and thus brought in contact with the brain.

More recent observations render it probable that in the so-called intermittent ophthalmia the effect of blood infected with malarial poison may exhibit symptoms in the sympathetic centers, and that thus this affection of the eye is a kind of a disguised intermittent fever. Intermittent ophthalmia is quite often described by the older authors (*Himly*, *T. Benedikt*, *Ructe*, *Mackenzie*), and very recently it has again attracted attention (*Eulenberg*, *Landois*). The affection is characterized by symptoms of vascular paralysis, which appear in distinct quotidian or tertiary forms, and, in the beginning at least, there is a complete intermission. These symptoms are usually confined to the conjunctiva and lids. These parts are more or less reddened, œdematous, while the mucous secretion is increased, and at times there is considerable ciliary irritation (*Staub*, *Mannhardt*) [*Roosa*]. In rarer cases the ciliary system is affected to a greater extent, and at times the affection presents the form of an intermittent iritis, with or without hypopyon (*Staub*). When the affection continues for a long time it is said to result in a permanent chronic ophthalmia, opacity of the cornea, atrophy of the eye (*Griesinger*). Some authors speak of intermittent amaurosis (*Teslelin*), but the proximate cause of such affections, and whether they could be directly referred to malarial infection, has not been made clear.

In the same way disturbances of circulation and nutrition may occur if the ganglia, the trunks, or branches of the sympathetic nerve are in any way affected. The type of the affection varies according to the location of the injurious impression, the anatomical conditions, and the physiological significance of the affected portion of the sympathetic nerve. We must therefore consider these facts a little more closely.

The center of the sympathetic system is generally considered to be in the medulla oblongata (*Schiff*, *Salkowski*), or still higher up, in the *crura cerebri* (*Budge*). A part of the fibers arising here originated from both the brain and the medulla, and lie on the trunks of some of the cerebral nerves, from there passing on to vessels, or, having united with the former, pass on to the periphery. Such fibers accompany the seventh nerve (*Schiff*, *Samuel*), and the fifth to their outermost limits.

Sympathetic twigs are united to the trunks of the latter, even in the brain, which are then pressed into a bundle on the united first and second branch of the fifth. They then extend to the Gasserian ganglion, where they are lost.

The greater portion, however, of the fibers arising in the brain pass downwards into the spinal cord and are here *probably* strengthened by fibers which spring from the spinal cord itself. The sympathetic fibers going to the eye and its appendages extend downwards into the anterior fibers of the medulla without crossing, and are here united to other fibrillæ, which probably proceed from the anterior and middle fibers (*Budge*). They appear to be nearly united with the anterior roots of the spinal nerves in question (*Budge*, *Salkowski*), beneath the sixth cervical ganglion and above the second (*Bernard*) or third (*Budge*, *Salkowski*) thoracic plexus. Only a small bundle, designed for the conjunctiva, the lids, and the lachrymal glands, passes up as high as the third cervical ganglion (*Landois*, *Eulenberg*). The bundles extending into the first and second cervical nerves appear in the two corresponding superior thoracic ganglia, and pass through the united portion of the marginal fibers into the cervical portion of the latter. This unites in itself all the sympathetic fibers proceeding from the eight cervical nerves, and has three large ganglia. The direction of the fibers in this portion is ascending, and is continued by the fibers from the upper cervical ganglion. These inclose the carotid, and extend with their branches, forming twigs over all the organs of the neck and head. A number of the fibers thus pass with the carotid into the cavity of the skull, and follow in part the ramifications of the vessels, but in part pass over from the cavernous sinus into the Gasserian ganglion; here they unite with the sympathetic fibers coming directly from the

brain, and radiate in the fifth pair, in its peripheral course. With the first branch of the fifth, which, however, takes some twigs direct from the carotid plexus, the sympathetic fibers pass to the eye and its appendages, where they meet with other fibers, which belong to the vessels and the facial nerve.

The first branch of the fifth, whose roots, in common with those of the second branch, lie in the medulla oblongata, and are connected to the *corpus restiforme* (*Deiters*), passes, with the sympathetic fibers that are mingled with it, through the superior orbital foramen, and here, or somewhat earlier, divides into three branches. The lachrymal nerve passes to the lachrymal glands and to the outer portion of the upper lid. The frontal nerve supplies the integument of the forehead, and with a neighboring branch, the supra-trochlear nerve, the inner part of the upper lid and the root of the nose. The third branch, the naso-ciliaris, first gives off the ciliary nerves. It then divides into the infra-trochlear nerve, which radiates into the upper lid and the integument of the root of the nose, and into the ethmoidal nerve. This latter nerve runs through the ethmoid foramen into the cranial cavity, and from here through the cribriform plate into the nasal cavities, where it supplies the anterior portion of the Schneiderian membrane, and, being continued, perforates the nose between the lower border of the nasal bone and the cartilage, thus reaching the integument of the end of the nose, and is lost in terminal branches.

The nerve-fibers, intended to supply the globe of the eye itself, run in part directly from the naso-ciliary nerve, as long ciliary nerves, to the globe; but some of them run first into the ciliary ganglion as long roots, where they meet with fibers which, as short roots, have branched off from the third pair of cerebral nerves, and with others which the ganglion takes as nutrient branches from the surrounding sympathetic vascular tissue.

All these different kinds of fibers are thoroughly mingled in the short ciliary nerves passing out from here. They run through a number of small ganglion-like nodules (*C. Krause, H. Müller, Schweigger, and Sämisch*) embedded in the choroid, and finally, after very many plexus-like turnings (*Donders*), branch out in the different parts of the eyeball. A small portion of the sympathetic fibers in the cervical limiting cord act as motory nerves. They supply the dilator of the pupil as well as the organic muscles of the lid and the orbit. By regulating the tension of these muscles they have a reflex influence upon the circulation of the eye and its surroundings. The principal part of these fibers, however, are of the vaso-motory kind; with the systolic movements of the vessels they also gently influence certain other contractions and expansions, that are independent of the pulse, and which determine the blood-contents of every vessel, as well as the resistance to the current (*Schiff, C. Bernard*).

Interferences with the conducting power of the cervical or of its roots, according to practical experience (*Eulenberg, Guthman, Ogle*), exactly as division of the above-named parts in animals, result in a marked contraction of the pupil (*Petit, Biffi, Trautretter, Arlt, Jr.*) as well as of the palpebral fissure (*Cl. Bernard, R. Wagner, Remak*), a recession of the globe within the orbit (*Petit, Schiff, Prevost, Jolyet, Budge*), enlargement of the vessels of the iris, and a marked congestion of the affected side of the head, with increase of temperature. Irritation of the cervical and experimental excitations produce the opposite symptoms (*Cl. Bernard, Budge, Wagner, Salkowski, Donders*), provided the irritation does not extend beyond a certain degree, in which case the symptoms of paralysis rapidly appear.

The other bundle of sympathetic fibers, which springs directly from the brain,

and which runs along the border of the trunk of the fifth pair to the Gasserian ganglion, does not give off any motor filaments to the dilator of the pupil, for galvanic irritation of this ganglion or of the first branch of the fifth pair, after extirpation of the first cervical ganglion, does not produce dilatation of the pupil (*Budge*). On the other hand, in connection with the vaso-motory tubes, it contains a great number of peculiar fibers which are wanting in the cervical, and which are closely connected with the nutrition of the eye, and are therefore called nutritive fibers.

In accordance with this anatomical fact, division of this bundle behind the ganglion or inside of the *pons varolii* (*Büttner, G. Meissner, Schiff*) often leads to very marked disturbances, which, in conjunction with the paralysis of nutrition of the vessels, gives the idea of a neuro-paralytic ophthalmia. This never occurs in division of the cervical limiting cord (*Schiff*).

Paralysis of the vessels is marked by a more or less decided hyperæmia and œdematous swelling of the conjunctiva, attended by the secretion of a muco-purulent material, and sometimes by hemorrhage into the subconjunctival tissue (*Hippel*). The disturbances of nutrition are seen in infiltration and ulceration of the cornea, diminution in the lachrymal secretion, and decrease in the intra-ocular media, that is to say, in a general softening of the globe.

Irido-choroiditis (*Graefe, Heymann*), or hypopyon, which may finally produce atrophy of the globe, is sometimes secondarily developed. In some cases affections in the nerve and retina have also been observed, which are apt to vary in duration and degree, and which may increase to complete but temporary amaurosis (*Graefe, Hippel*).

In accordance with the conditions which have just been described, morbid processes which are located in the *pons varolii*, or in the trunk of the fifth pair (*Stanley, Alison, Power*), just as division of the latter in animals (*Schiff*) produce neuro-paralytic ophthalmia, which are then usually accompanied by extensive disturbances of sensation in the region supplied by the trifacial. Similar results not unfrequently occur, however, if the Gasserian ganglion, or the first branch of the fifth pair up to the point where the ciliary nerves are given off, is involved in a morbid process (*Schiff, Graefe, Junge, Budge, Rothmund, Geissler, Steffan*). Even if the ciliary branches are themselves incapable of conducting (*Graefe*), if there be an affection of the semilunar ganglion, or the first branch of the fifth pair, or if it has been divided (*Magendie, Schiff, Graefe, Winther*), the paralysis of the vessels occurs more frequently as well as sooner, and is more extensive. This is probably explained by the fact of the great number of sympathetic fibers which pass from the cervical limiting fibers (Grenzstränge) and unite with the trifacial in the Gasserian ganglion. At least, in the observations just quoted, great stress is laid upon a contraction of the pupil which appears gradually, is permanent, and independent of any impairment of the third pair (*Budge, Cl. Bernard, Graefe*), as well as upon the appearance of numerous greatly distended vessels in the iris (*Budge, Wegner, Graefe*).

It is very strange that we do not always find, under such circumstances, paralysis of the vessels and disturbances of nutrition. We cannot yet say, whether a sufficient explanation is found in the fact that a great number of sympathetic fibers reach the eye and the adjacent parts *with* the vessels. We can scarcely, therefore, reject the idea that there are some accessory processes at work. Anæsthesia is to be undoubtedly considered as one, since it prevents the warding off of numerous external injurious influences, which by their irritation produce and increase paralysis of the

vessels, and which may even induce inflammatory processes. Besides, when the sensibility of the eye and its covering disappears, the real motive power of the rhythmical and involuntary closure of the lid is also gone; the eye remains open and allows the exposed conjunctival surface to become dry. This is more apt to occur, because in any interruption of the conducting power in the first branch of the fifth pair, the lachrymal glands must be deprived of the nervous power which regulates the secretion, and thus the secretion of tears be diminished, even reduced to the slightest quantity (*Graefe*, *Hippel*). Acute xerosis is very apt to occur, the epithelium of the cornea and conjunctiva, especially in the parts exposed by the palpebral fissure, flakes off, becomes rough, and covered with delicate mucus, which hardens into crusts. And thus another factor is produced which acts upon the nutrition of the part, and greatly favors inflammation and ulceration. Indeed, numerous experiments leave no doubt that closure of the palpebral fissure, that is to say, protection from injurious external influences and from drying of the secretions, may, in the majority of cases, prevent the appearance of neuro-paralytic ophthalmia, and in case it has occurred, cause it to recede. Some even consider that neuro-paralytic ophthalmia is caused by injuries unavoidably produced in the absence of protection to the eyes (*Snellen*, *Rosow*, *Knapp*), or by the anæsthesia of the parts and the accompanying stoppage of the lachrymal secretion (*Graefe*). Others again believe, that on account of the impairment of the conducting power of the sympathetic nerve, there is a lessening of the resisting power of the tissue (*Büttner*, *Samuel*). Against this view it may be said, however, that covering the eye does not furnish an absolute immunity from the disease (*Schiff*, *Hippel*), and that neuro-paralytic ophthalmia is not at all connected with anæsthesia, but that it has been observed when the parts were perfectly sensitive (*Schiff*, *Geissler*, *Steffan*, *Mooren*).

The influence of the portion of the sympathetic connected with the trifacial, upon the circulation and nutrition, is seen not only in the complex symptoms of the neuro-paralytic ophthalmia, but also in the so-called *secretion neroses* connected with neuralgia of the fifth pair, and in the atrophy of the connective tissue, of the muscles, and even of the bones, which is sometimes found as a consequence of long existing neuralgia and anæsthesia of branches of the fifth pair (*Benedikt*, *Graefe*).

But this influence is most clearly seen in herpetic or the so-called phlyctenular disease of the parts supplied by the trifacial. There is scarcely any doubt, according to the few anatomical investigations that have been made, that herpes has a close causal connection with inflammatory processes which have localized themselves in the track of bundles of sympathetic fibers (*Danielssen*, *Esmarck*, *Bärensprung*, *Charcot*, *Cotard*).

It is also certain that the seat of the morbid collection will determine the location and extent of the characteristic eruption.

Morbid processes, which have become developed in the region supplied by the frontal or lachrymal branches, or in the course of the naso-ciliaris, beyond the branching off of the ciliary nerves, in accordance with the anatomical conditions, can only directly affect the circulation and nutrition in the accessory portions of the eye. But the influence which they may exert upon the circulation and nutrition of the globe is, therefore, greater. The reflex relations between the sympathetic and the sensory fibers, not only of the fifth pair, but also of all the sensory nerves, here come into consideration. These relations are very important in pathology and therapeutics.

We may sum up the results of the experiments as yet made upon these points in a few words, as follows:—

Irritations of the skin cause, primarily, contraction of the smaller vessels of the body, with a decrease in the temperature as well as increase of the number and force of the heart-beats.

This contraction of the vessels remains for a time after a removal of the cause, and finally yields to a slight dilatation, if the irritation of the skin be relatively feeble. (*Haumann*, *Loven*). On the contrary, in the parts supplied by the branches of the sensory nerves (*Cl. Bernard*) and their vicinity, the contraction of the vessels passes very quickly, almost at once, into great dilatation, while in distant organs it continues (*Zülzer*), if the irritation of the skin be moderate. The degree of the irritation does not depend solely on the absolute severity of the attack, but on the irritability of the body at the time, so that the same irritation in different persons, and in the same persons under different circumstances, will cause entirely opposite reactions (*Naumann*)—that is to say, at one time contraction of the vessels, with decrease in temperature; at another time, enlargement of the vessels, with increase in temperature, but subsequently retardation of the blood-current, passive hyperæmia with the lessening in temperature dependent upon it, and thus may excite œdema, inflammatory exudations, with all their consequences.

These reflex effects, as is well known, are very markedly seen in hyperæmia and œdematous swelling of the conjunctiva and lids, which are apt to accompany neuralgic attacks in the trifacial, and also in the great sensitiveness developed in the cervical. There are also certain cases belonging to this category in which injuries or disease of certain branches of the fifth pair—for example, diseases of the teeth—have caused severe inflammation of the eye (*Schiff*), or impairment of vision (*amaurosis trifacialis*). From all that has been said, we see that it is not necessary to believe that there are any fibers peculiar to the fifth pair, which have the power of enlarging the vessels of the eye, and also of influencing the secretion in its interior (*Hippel*, *Grünhagen*). We may the more readily take this view, since the experiments made on this point lose much of their value, from the fact that it is impossible to limit the direct impression upon the sensory fibers (*Adamük*, *Wegner*).

On the other hand, it may be believed that variations in the amount of blood, dependent upon disturbances in the innervation of the sympathetic nerves of the affected portion, may become a source of irritation to the parts supplied. The symptoms in hemicrania point to this view (*Eulenberg*, *Gutman*). Certain it is, that inflammation for which the way is broken by paralysis of the vessels may irritate the sensory nerves at the point of disease, and thus be reflected upon the sympathetic fibers.

The irritation continued from the sensory nerves upon the sympathetic fibers usually shows itself in the interior of the eye by a more or less decided movement of the pupil (*Budge*, *Trautvetter*, *Donders*, *Cl. Bernard*). The brain, the ciliary ganglion, or even the intra-ocular ganglion, may be the means of transmitting this reflex irritation. The movements themselves are the effect of different actions. Some of them are very slow, and probably cause a change of tension in the muscles of the vessels, or rather a change in the filling up of the vessels of the iris. The other movements are rapid, and are undoubtedly chiefly caused by the action of the real motory muscles of the iris. In either case a change occurs in the blood distribution in the uveal vascular tract. It is proven that at every enlargement of the pupil the size of the iris decreases, a part of the blood in the vessel of the iris flowing into

the *vasa vorticosæ* of the choroid, while on the contraction of the pupil the blood returns in part to the iris (*O. Becker*), and thus increases its size. It is clear, that when there is a morbid process going on in the interior of the eye these variations must have some effect upon the circulation and nutrition which are already affected; since each muscular contraction brings with it an increase in the assimilation (Stoffwechsel), and, when there are pathological conditions existing, may produce severe irritations in the sensory nerves. Muscular rest is universally recognized as an important aid in treating inflammation.

To the extent that has been indicated, the reflex action which acts from the retina upon the pupillary branches of the third pair of cerebral nerves, by means of the center in the inner half of the anterior pair of the *corpora quadrigemina*, should also be considered (*Flourens, Budge*).

The reflex actions from the retina and the sensory nerves of the region of the eye upon the motory nerves of the seventh pair, which supply the *orbicularis palpebrarum*, also deserve mention. Finally, the voluntary action of the external muscles of the eye, the muscles of the lid, and especially of the muscle of accommodation, require careful consideration.

By many (*Graefe, Weber*) it is asserted that increased tension of the ciliary muscle will increase the intra-ocular pressure, or, at least, that pressure under which all the posterior parts of the interior of the eye are placed, and thus alter the circulation and nutrition. These views rest upon the results of various experiments (*Völckers, Hensen, Coccius, Förster, Cramer*) and of the results of iridectomy (*Graefe, Wegner*).

These views are, however, contradicted by other experiments equally important, so that many doubts arise on the subject (*Völckers, Hensen, Hippel, Grünhagen, Adamük*).

We may especially take into consideration the fact that the dioptric media are incompressible, and that the arterial blood-pressure in the intra-ocular currents is so great that a proportionately great external pressure must act upon the globe in order to markedly diminish the caliber of the vessels seen with the ophthalmoscope. The filling up of the cavity of the eye is, therefore, without doubt, quite enough to enable the relatively weak traction of the ciliary muscle to balance the outer form of the globe. Besides, if this were not so, the contraction of the ciliary muscle would necessarily make itself known by an increase in the convexity of the cornea, while there is incontestable proof that the different conditions of accommodation in the eye have no effect whatever upon the curvature of the cornea. We can only, then, believe in an increase of pressure in the posterior part of the eye; but if the contraction of the muscles of the iris and of the ciliary muscle will lessen the space inclosed by the uveal tract, the pressing forwards of the aqueous humor in the posterior chamber would be sufficient to render it impossible that there should be any effect from an increase in pressure. Besides, the space between the choroid and sclera would immediately be filled up by an increase of blood in the *venæ vorticosæ*.

Moreover, such a pressure would be seen in the entoptic appearances of the choroid, while experiments to ascertain this point show just the opposite, and have proven that paresis and spasm of the muscle of accommodation caused by atropine or calabar bean produce no change in the quickness of the movement of the blood and in the strength of the pulsation, which is, however, the case on external pressure (*Hippel, Grünhagen*).

After this detailed description of the conditions of innervation and circulation, we may pass on to the treatment of inflammations of the eye.

There are two general indications in treatment. They are the indications springing from the cause, and from the disease itself.

1. *The indication from the cause of the disease.*—This aims to remove all internal or external injurious influences, and not only those which have excited the inflammatory process, but also those which may act on the inflamed part in the progress of the disease, thus keeping up the inflammation.

2. *The indication from the disease.*—This aims to limit the process itself, to break its force, and increase the chances of resolution.

The indications springing from the cause are divided into innumerable special requirements. These are the removal of any physical, mechanical, chemical, or organic injurious influences, as well as of any predisposition to diseased action; the circulation and aeration of the blood should be regulated as well as the nutrition. Some of the causes of inflammation only act in individual cases, and under peculiar circumstances. Many of them show an affinity to certain parts of the eye, and to certain forms of disease. We shall, therefore, defer any reference to them until we reach the sections devoted to these parts and their affections.

A smaller portion of these injurious influences, however, have a more general importance, since all people, amid very different circumstances of life, are more or less liable to their effects.

The indications of, and the appropriate remedies for, these injurious influences, are the subject of the present part of this work.

A. The following may be especially named as among the mechanical injurious influences which most frequently aggravate irritations and inflammations of the eye:—

1. Rubbing, pressing, or even touching the eyelids to alleviate unpleasant feelings of itching, biting, burning, or actual pain; pressing the eyes with the hands or arms in order to relieve annoying photophobia. Although this is particularly to be seen in children, we not unfrequently meet with similar improper management in adults. In the case of the latter, simple instruction is sufficient; but with children we may be compelled to use compulsory measures. Formerly a handkerchief folded like a bandage was applied as a protective covering. This is not only too warm, but it is oppressive, on account of its weight, and it may exert very uneven pressure. All the requirements are better answered by the method of bandaging now in general use. This consists in filling the orbital region with fine charpie [picked lint] or soft cotton, and in the use of a soft and light elastic bandage. The charpie is placed either in a single cushion, properly formed, or in numerous small layers over the closed lids, and so distributed that all the depressions between the convexity of the globe and the bony orbital borders are filled. The bandage placed on this exerts a perfectly uniform pressure upon the parts lying beneath. We use as a bandage a seamless strip of the finest flannel, which, for the sake of greater elasticity, is cut obliquely with the course of the fibers. This should be six inches long and one to two inches wide, and to each end, which is pointed, a small strip of tape is attached, in order to have a small knot in fastening, and to limit, as far as possible the annoying wrapping of the part.

One of the chief requirements is, that the bandage, while not very tightly applied, shall not slip off. The binocular bandage, which is placed obliquely over the eyes, usually maintains its position, but not so with the monocular. It is necessary, in order to secure the latter in its

oblique position, that one end of the bandage should be placed close under the lobe of the ear, the other over the forehead and exactly over the boss of the parietal bone, and then the ends cross over the center of the optical region, and are brought forward and tied in front. We should here take care that the knot does not lie on the eye, and thus cause a very unpleasant pressure.

This bandage has an important therapeutic advantage if properly applied, in entirely preventing the opening and shutting of the lids. It allows, also, the free escape of a certain amount of secretion from the palpebral fissure. If both eyes are closed, and vision rendered impossible, the movements of the globe as well as the accommodation are reduced to a minimum. This muscular rest is an advantage in the treatment of irritated parts, which cannot be too much esteemed. Besides, immobility of the parts is often imperatively required, when we wish for a proper apposition, and the speediest possible adhesion of the edges of wounds; as, for instance, after accidental or operative injuries to the eye and its surroundings.

Plaster is never sufficient for this purpose. When it covers only a small portion of the closed lids, it does not prevent their movement, and if the surface of the lid, particularly the edges, are entirely covered with plaster, the exit of the redundant secretion into the conjunctival sac is retarded. This becomes a source of unpleasant irritation, amounting sometimes to unbearable pain. If the plaster is of a material which is irritating in its nature, erythema of the extremely delicate integument may occur, and lead to a great irritation of the conjunctiva and of the globe. Added to this, plaster presses very unequally, according to the degree of its tension. This unpleasant peculiarity is especially true of the isinglass plaster, which shrinks soon after its application, and thus the edges are turned in some places directly upon the surface of the lid. Then, too, the adhesive material readily dissolves in the tears, diffuses itself, and, again becoming dry, completely closes a great part of the palpebral fissure.

Whether it is possible to prevent the movements of the eyes by purely mechanical means may be fairly doubted. The nearly spherical form of the globe, and the position of its axis, do not allow us to suppose that all motion can be prevented, even by the most accurate application of large masses of padding, without inflicting a degree of pressure which could not be endured. Still some believe that they can accomplish this without excessive annoyance to the patient. For this purpose the use of a roller bandage about four feet long, with a knit middle portion and flannel ends, is recommended. This is first carried circularly around the forehead, then above the ear of the unaffected side, to the back of the head, under the other ear over the affected eye. If both eyes are to be closed, then two bandages should be used. In order to exert a still more powerful pressure upon the well-padded orbital region, a so-called *laced bandage* is highly spoken of. This renders necessary a bandage ten feet long, of the kind just described, and requires three ascending monocular turns, in the manner indicated in the use of the pressure bandage (*Graefe*).

It will require further experience to decide whether such a severe pressure, as is necessary in the use of this bandage, furnishes real therapeutic advantages, and whether the result, which in individual cases may be thereby attained, balances the disadvantages, which in very many instances are absolutely intolerable. It seems as if the ordinary protective bandage, with a somewhat greater tension of the elastic part of it, were able to accomplish all that is to be generally expected from a pressure bandage, without excessive annoyance and without danger of unpleasant consequences.

[It is more than probable that the true function of the bandage would be better expressed by using the name retentive bandage, thus indicating the most important agency which the dressing fulfills, namely, to keep the eyelids closed, the air excluded; and, in the case of a wound of the front of the eyeball, to give a splint-like support.]

2. *The effects of dust upon the conjunctiva and cornea.*—Working with dusty substances, or frequenting dusty localities during the existence of conjunctival or corneal disease, should be strictly forbidden, since the mechanical contrivances used for excluding dust fail to accomplish that purpose.

[This rule must not be construed into a prohibition of out-door life as a means of keeping active the nutritive forces, especially in obstinate forms of sub-acute conjunctival and corneal disease.]

a. Dust-Spectacles, Goggles.—Wire-work, in spectacle frames, was at one time used as such, and called by this name.

These dust-spectacles have the disadvantage of keeping the eye behind them continually enveloped in the vapor of its own moisture, which cannot fully escape. Thus the irritated condition is rather increased than diminished. The principal reason for their disuse lies, however, in the impairment of distinct vision, which compels the patient to strain his eyes severely in order to see surrounding objects distinctly.

By the wire-work considerable objective light is kept away from the eye, and the frame of the dust-spectacles places the translucent gauze in an unfavorable angle to the outer world, thus limiting the visual field. Moreover, the manifold diffraction which the transmitted light undergoes on the wire gauze comes into consideration. Besides, when these spectacles are worn in an atmosphere loaded with dust, the meshes of the gauze become filled, and then their defects are increased.

Ordinary glass spectacles, of circular shape, about an inch in diameter, are to be preferred to the dust-spectacles above described. Of course they protect the eye less; but where the dust is so abundant that sufficient protection is not afforded by the ordinary glass spectacles, or where a small amount of dust upon the eye proves injurious, the surgeon does well to prohibit the patient from being thus exposed.

3. A very common source of injury, among certain kinds of laborers, is the chipping off of bits of metal, stone, and the like (*Stavenhagen*), which come with great force upon the eye, and sometimes even enter it. These must often be removed by the aid of instruments, which usually cause considerable irritation and loss of substance. According to the detailed statistics of *H. Cohn*, almost half of the workers in metal suffer from such injuries. Wearing ordinary glass spectacles would diminish the danger somewhat, but they are too easily broken and too expensive to be commonly used. Mica spectacles have therefore been introduced, but as yet they are unfortunately not generally employed. They are thin, almost perfectly transparent disks of mica in metallic frames, fitting well on the orbital ridge, and which are fastened on the head by a bandage, or, better still, by means of an ordinary spectacle-frame (*H. Cohn*). They do not break, and are cheap. Besides, mica is a poor conductor of heat, and in working over fire it does excellent service, especially if colored blue or gray, in neutralizing the bright reflection.

B. Among chemical causes of injury, our attention is especially called to

1. *Uncleanliness of the edges of the lids or of the conjunctival sac.*

Among children we cannot give the matter too much attention, particularly where the case does not permit the use of the protective bandage. Children in playing are apt to soil their face and hands every moment, and rub the dirt into their eyes in order to alleviate itching. The rules for avoiding this are evident. It is only necessary to remark in passing, that those who have the care of children with eye-disease should be impressed with the necessity of keeping them away from all dirty places or dirty substances.

2. *The action of remedial agents.*—Eye-washes, ointments, etc., which are employed at an improper time, or in too strong a solution, or too often, immediately upon the conjunctival sac or the globe, may be harmful by increasing the irritation or inflammation. Besides this we may mention salves, tinctures, and the like, which are used only for their irritative, absorbent, or narcotic effect, and which are applied to the lids or their vicinity; meal poultices, vegetable decoctions, baths which have been made more active by the addition of salts, etc. Among

careless persons, especially children, the occasional getting the preparations used into the eyes is scarcely to be avoided. Such a soiling is the more dangerous the severer the irritation. *Vesicants* also, although generally applied some distance from the eye, not unfrequently make the irritated condition much worse. The patients are inclined to scratch, rub, and feel about the excoriated portion in order to alleviate the unpleasant sensation which the blister causes, or in order to remove the sensation of the part which is robbed of its epidermis, and thus they soil the hands, and with them the sensitive surface of the eye.

3. *Snuff-taking.*—This irritates the eyes, especially when the person is unaccustomed to its use. In the case of amateurs, therefore, a slight injection of the conjunctiva with severe sneezing generally follows taking a pinch. In view of this, snuff-taking can only be allowed in those cases where the patient is in the habit of it, and a slight increase of the irritation involves no danger. In inflammations which may readily have bad consequences, even the ordinary snuff-taker may be only exceptionally allowed the moderate use of snuff, and then with the greatest care.

4. *The abode in a damp room, or one filled with excrementitious exhalations, or with irritating vapors of any kind whatever.*—Pure air is, indeed, one of the most important requisites for the successful treatment of eye-diseases. We cannot too strenuously recommend that the patients be placed in rooms which can be easily and thoroughly aired, and we should keep away from them all the above-named sources of injury.

Our special attention should be directed to the habit of cooking, washing, carrying on of many odorous employments in the ordinary living-rooms of the poor; also keeping in the room the remains of food, of half-filled chamber utensils, or the stowing away of soiled linen in the apartment.

The condition of the patient, however, does not always permit that he should remain indoors. In many cases it may even be desirable that he take exercise in the open air. Where walking is recommended, the surgeon should never forget the tendency of patients to exceed what is recommended. A proper precaution demands that the patient should be entirely forbidden to visit taverns, restaurants, theaters, balls, concerts, and, in general, places where many people are gathered together.

In such localities many sources of injury concentrate, and operate in conjunction with other injurious influences; for example, dazzling and irregular illumination, which is so powerful a morbid agent, that by it even a very slight irritation can be increased to one of the severest and most destructive inflammatory processes. In hospitals and similar institutions it is of importance to look well to the condition of the water-closets. Very often these have become infernal pits, whose pestilential vapors even force tears from healthy eyes, and are very naturally more destructive to diseased ones.

5. *Tobacco-Smoke.*—This is a bitter enemy to diseased eyes, and it must be laid down as a fixed rule, that eye-patients should always, and under all circumstances, avoid closed places where there is any smoking. The patient with a diseased eye must not smoke in his own room, nor allow others to do so, even if the ventilation be very good.

In very mild irritations, however, which allow the patient to go out in the open air, *but only in these*, an absolute denial of tobacco-smoking is not always justified. Patients who smoke daily, and are passionately fond of it, bear such a denial with difficulty, and a persistence in its enforcement will probably lead to its secret use. In cases where a slight increase of the irritation can produce no especial harm it seems better, therefore, to allow the patient to smoke moderately, taking certain precautions. *The first rule is, to smoke only in the open*

air, and where there is a gentle breeze; since here there is less danger of a great quantity of smoke reaching the eye. For greater protection, the patient can wear spectacles, or shut his eyes. Long pipes are generally advised, and with good reason.

C. Among the physical causes of injury are the following:

1. *Wind.*—In the existence of an irritated condition of the eye the access of wind is to be avoided, even when it is not very severe, and is free from dust. Even very slight irritations are made very much worse by the effects of the wind. The patient should, then, be kept in his room in windy weather, and this rule is the more imperative, since spectacles are such an insufficient protection, and the use of a veil is not always practicable.

2. *Excessive Heat.*—Those who work before a fire—cooks, bakers, etc.—are especially liable to this influence, and should therefore be warned as to its injurious effect. Sitting too near the stove, an evil habit of many, should also be guarded against; since experience has shown that thereby irritations are caused and increased, especially in hospitals, and in the dwellings of the poor. It may be remembered, in general, that an equable cool temperature of the room in which eye-patients are kept should be maintained; about 62° to 66° Fahrenheit is the best for therapeutic purposes.

3. *Severe Cold.*—This is generally, at least for a while, better borne than great heat. Patients suffering from conjunctivitis feel very well in the quiet air of a cool winter's day; but when there is iritis, choroiditis, etc., the patient cannot remain in the open air in cold weather without danger, on account of the impossibility of bearing the cold without active exercise, which again produces injurious changes in the temperature of the body.

4. *Severe and sudden Changes of Temperature.*—Rapid cooling of a warm portion of the body, or sudden and irregular heating of a part deprived of its natural warmth, has been always, and with good reason, regarded as one of the more frequent causes of inflammations or irritations. The sudden change in the local conditions of the circulation certainly plays an important part. The most frequent source of such a sudden change in temperature lies in a draught of air. The avoidance of this furnishes, therefore, a very important therapeutic requirement.

For this purpose it is, however, by no means necessary to envelop the patient with wrappings, or to place him in bed surrounded with screens or curtains, or to cover the head of the bed. By such means the patient is confined, annoyed, and disquieted, and generally a heavy perspiration is induced. Even congestions of the head are excited, and not rarely the hindrance of the necessary circulation of air leads to constitutional disease. The patient should be able to breathe freely. Therefore it seems advisable not to lessen the small space of his room, but only to see to it that the patient, whether he is in bed or goes freely about, is never in a draught. The injuriousness of sudden changes in temperature makes it also advisable, in cases in which an equable temperature is particularly desirable, to avoid washing with cold water or putting on cold linen.

D. It is of great importance, in the treatment of irritated and inflamed eyes, to properly regulate the intensity of the light thrown upon the organ; for improper illumination is one of the most effective causes of injury. In certain cases it is necessary to keep the light entirely away from the eyes, and this can be done, either by darkening the windows as much as possible, or by the use of a protective bandage. But in the great majority of cases such an entire exclusion of light is not only unnecessary, but even injurious, since, during convalescence, it is with great difficulty that the patient becomes so accustomed again to the increase of light as to avoid the relapses which may be readily induced by a greater intensity of illu-

mination. Convalescence is retarded by too great darkness, on account of the evil influences which a long seclusion in a darkened room exercises on the general condition. A moderate degree of illumination, about such as we have at twilight, is the best adapted for the treatment of eye-disease. Gradations in the degree of light will, of course, be made for different patients, according to their individual sensitiveness.

It is, however, not to be forgotten that some patients are excessively sensitive, beyond all proper limits. In order not to induce photophobia, it is advisable to look more to the objective condition than the subjective sensations, in determining the amount of light to be borne. It is especially important to carefully avoid all contrasts of light, since even a diseased eye may accustom itself to a considerable degree of intensity of light. But even a healthy eye bears contrasts with difficulty, and an irritated eye will always be markedly affected thereby.

According to recent investigations, prolonged rest in a dark room increases the sensitiveness of the retina (*Aubert*) thirty-five times, and a stay of two minutes increases it ten to fifteen fold. The irritation of light in the beginning of its impression excites the maximum of sensation; but this, with the continuance of the irritation, decreases so much that, after a time, a somewhat weaker impression will not be noticed.

The color of the light reaching the eye is also of importance. In general we may say that orange, yellow, and green excite the sense of color more powerfully, and with the same intensity, irritate more severely than the other colors.

This is shown not only by means of the subjective sensation which becomes manifest by looking through different colored glasses, but also by a measurement of the reaction of the pupil.

This contracts most when exclusively yellow or orange rays are conducted into the eye, by means of a solar spectrum and a prism. It becomes wider and wider when the outermost red or only *calorific rays* (warme Strahlen) enter the eye. Just so, the diameter of the pupil increases when the eye is directed out of the yellow of the spectrum into the green or blue. Yet the *ultra* chemical violet, and even the outermost violet rays seem again to irritate the eyes more. Electric light, which contains many chemical rays, is very unpleasant to the eye, and demands a diminution of its intensity by means of glasses which are colored with oxide of uranium (*Jansen and Follin*). The means to meet these requirements are:

1. *Window-curtains.*—These can seldom be dispensed with in the treatment of irritated conditions of the eye, and are to be preferred to shutters, where we do not wish a complete darkening of the room.

All the windows in the room should be covered; and when the door leads into a very light room, it is of great advantage to weaken the illumination there also. The curtains should fully cover the window, so that no chink remains at the side, through which the light can come to produce strong contrasts. For the same reason the materials of which the curtain consists should be sufficiently thick, especially when the window is illuminated by the sun. On windows which never receive the direct rays of the sun, thin crape-like material will be thick enough. The color of the curtain should always be rather of a dusty brown. The best are gray, blue, or violet. The much-recommended green curtains are not so good, since in transmitted light they show a very light coloring, and cause pain in the eye.

Light-green is by no means a mild color. It is next to the yellow of the sun, and this, as is well known, is the most irritating color. Only reflected dark-green, such as that of the fields and foliage, is pleasant to the eye. It is very evident, then, that the modern curtains, painted in the brightest colors, will not do at all.

2. *Lamp-shades.*—These cannot be dispensed with where it is necessary that the patient should stay in a room artificially lighted, since inclosing the bed with a curtain renders the circulation of air in the room difficult, and will annoy the patient.

When he remains in bed the formerly fashionable flat night-shades, which are placed before

the flame, may be used, or even a sheet of rough paper fastened in front of the flame, as occasion may require. In case a lamp is used, it will be best to make a round opening in a sheet of paper, cut oval at one end so that it hangs over the shade, and then place it over the glass chimney. Gray paper, especially blotting-paper, is the best material for such shades. Light-colored shades, especially the favorite light green or blue, do not answer the purpose, on account of the intensity of their color in transmitted light. It will be understood that brightly painted or perforated shades are still less desirable. Opaque shades, as, for example, tin ones, are even less useful on account of the contrast which they produce between shaded and illuminated places.

3. *Eye-shades.*—These can only be of use when we wish to keep the direct rays of the sun, or of any other intense light from the eye. They avail little or nothing against diffused light.

In order to ward this off they must be placed at a very acute angle with the face. Even then the patient looks out of a very dark space, and the contrast produces the same effect as if he looked out of a dark cellar upon the bright sky. The material of which eye-shades are made is not of very great importance. It may be said, however, that shades of coarse gray paper, such as the wrappings of loaf-sugar, fastened on the head by means of a little band, are most to be recommended on account of their flexibility, simplicity, and cheapness. Green taffeta shades, fastened by wire, do not answer as well, since in direct sunlight they let in a great deal of green light; and the wire presses on the temple, and thus becomes unbearable. The thick pasteboard shades are very unpleasant on account of their stiffness.

Eye-shades are evidently unnecessary in artificial illumination, lamp-shades being sufficient. In direct sunlight, broad-brimmed hats or caps, with large front-pieces, are more easily worn.

4. *Veils.*—These may be especially used by females and children, whose cases demand that they should be allowed to go out in the fresh air, even when they have irritated eyes. The best are the plain gray or black. Those of a yellow color are not advisable.

5. *Protective Spectacles.*—These are best made of smoke-gray glasses.

Green glasses are not advisable, since in a bright light they transmit a very intense and very dark green approaching a yellow, which increases rather than diminishes the irritated condition. Blue glasses are to be preferred to green, as the blue color exerts a less severe impression upon the retina. Even these do not fully answer the purpose. Deep-blue glasses, as experience teaches us, pain the eye in bright light. Pale-blue glasses, on the other hand, furnish no effective protection. They weaken the light too little. They are only sufficient when we are dealing with a very evanescent condition of irritation, and here protective spectacles are nearly superfluous.

Smoke-gray glasses, London smoke, weaken the transmitted light very considerably, and this naturally in proportion to the depth of their shading. They envelop all the objects in the visual field, as it were, in the twilight of evening, or of a very dark day; they allow the objects looked upon to be seen in their natural color, but with very much subdued intensity, and on the whole answer fully the purpose which may be reasonably expected from wearing them. Such smoke-gray glasses may be obtained in all possible shades. Those of a light color only are useful.

Those glasses whose color in reflected light approaches a black, darken the visual field too much. They disaccustom the eyes to the light, and thus render difficult the return to a normal illumination. They also hinder the distinct view even of near objects, and thus often cause the patient to strain his eyes and increase the irritated condition. Every one may convince himself by his own experience of the annoyance of very deep shades of gray glasses. It is evident, also, that eyes which require a considerable darkening of the visual field are better

kept in a dark room, because protective spectacles certainly do not sufficiently alleviate the contrasts of illumination, which are so common in the open air; and on the other hand, such darkly-shaded glasses themselves excite these strong contrasts of light, for they scarcely ever fit exactly on the orbital borders, thus allowing light from all sides to strike the periphery of the retina. This latter objection may be also urged against light-gray smoke-glasses, but to a much less degree. To lessen some of the objections, it is advisable that round glasses be used, somewhat more than an inch in diameter. In case of necessity, side glasses may also be employed, but in general these are not to be recommended, since four glasses with the necessary fastenings make the spectacles heavy and troublesome, and also accustom the eye to too little light, and prevent the free circulation of air about it. Small oval glasses are entirely useless, since they only cover the center of the visual field. It is very important to see to it that the bridge of the spectacles is not too long, and that the inner part of the eye is perfectly covered; and in choosing these spectacles we should be careful to see that the glass is good, and furthermore that its color be a clear gray, and not, as is often the case, a yellowish or brownish gray. For this purpose, the spectacles, after careful testing of their surfaces, may be laid on a sheet of white paper, or any such substance, where the faults described may be easily detected.

These protective spectacles should be always ground plane, since the depths of their coloring depend to a great extent on their thickness. Concave glasses, therefore, shade the periphery more, convex the center, and this in the greater mispropportion the darker the glass and the greater the curvature of its two surfaces.

Protective spectacles are not intended for exact vision, and this defect appears the more disturbing the more the refraction of the eye deviates from the normal—that is, the greater the curvature that is necessary. In very myopic or hypermetropic patients, who go about with difficulty unless aided by concave or convex lenses, a remedy may be obtained, since we can cause plano-concave or plano-convex spectacles to be ground of the necessary focal distance, and on its plane surface, by means of the Canada balsam, affix a plane smoke-gray glass. Lately the so-called muscle spectacles, that is, spectacles formed like watch-glasses, are much in fashion. Their convexity allows of a very considerable approach of the edges to the orbital border, and hence furnishes a more efficient diminution of the lateral illumination than plane spectacles do. Since, however, the radius of the posterior concave surface is always smaller than the anterior convex one, these spectacles become weak concave lenses, and are, as a rule, therefore, very annoying to far-sighted and hypermetropic eyes.

In the use of protective spectacles it is very necessary to see that we do not harm the eyes instead of benefiting them; we should inform the patient they are to be used only to protect the eyes from high degrees of light. When they are used to guard against light of a low grade of intensity, they darken the visual field too much, accustom the eye to this darkness, and are therefore not sufficient to alleviate the irritating effect of bright light, and besides this they prolong the convalescence. They are only to be worn when we wish to soften the light of a sunshiny day, or the reflection from snow, sand, or from the surface of a sheet of water, it being all the same whether the brilliant light illuminates the whole or a part of the visual field. They should be immediately taken off when the patient is under the shadow of a house, when he enters a wood, etc., as well as in the evening, and on dark days. It is especially important that he should put on the protective spectacles when he passes out of the regular illumination of his room into a room too brilliantly lighted for the irritated condition of his eyes. Should the patient use the protective spectacles for a considerable time in his room, and pass with them into the bright sunlight, the contrast in the intensity of the light in the two rooms is scarcely at all alleviated. Besides, it is well to notice that protective spectacles are only of use in diffused light, but they avail nothing against the direct rays of the sun, of a lamp, etc., since contrasts in the illumination of the visual field are not removed by them.

In the open air they do not render broad-brimmed hats, or in a room lamp or eye-shades, superfluous. If smoke-gray glasses have been used for some time by the patient, they should not be suddenly laid off, since the eye, unaccustomed to bright light, is more sensitive than normal. Where dark shades have been used, we may prevent the transition from being dangerous by passing gradually to lighter shades, in order that the eye may very gradually accustom itself to a bright light.

E. Among the organic causes of injury to the eye should be mentioned every kind of straining for the purpose of obtaining clear and exact vision.

When there is much irritation of the eyes, accompanied by photophobia and pain, straining efforts are prevented by the increase which they occasion in the subjective and objective symptoms. Where, however, the irritated condition is a slighter one, the patient is not troubled in his work, and does not find himself compelled to give it up, because the unpleasant consequences do not show themselves for some time, and even then may be very slight, because the disease advances very slowly.

Here it becomes the duty of the surgeon to look carefully into the causes of injury, and to oppose their further action. In general, it appears most advisable to forbid patients to read, write, or to occupy themselves in any way by which the retina or accommodative apparatus are called into action during the disease, and only to allow a very gradual return to the ordinary avocations. Greater liberties generally lead to misuse, and the effects of remedies are thus weakened or made nugatory.

F. Further indications for treatment result from the dependence of the extra-ocular trunks, and with certain limitations of the intra-ocular vessels to the general blood-pressure, and the circulatory requirements in the vessels of the head and neck. These indications are chiefly those springing from the disease.

It is, perhaps, superfluous to go into details at this point: still, a special condition deserves notice on account of its importance: this is the *absence of valves* in the veins, carrying the blood to the superior venous sinuses. Congestion in the veins of the neck and head is on this account very apt to occur, and hence diseases of the heart, impediments in the portal circulation, etc., are very apt to be reflected in disturbances in the circulation of the visual organ. Irregularities in respiration also may become a source of extremely pernicious congestions in the region of the eye. Hence, in congestive conditions of the eye and its vicinity, we should look carefully to the respiration. Patients should especially avoid all loud speaking, crying, singing, sneezing, and, as far as possible, coughing, on account of the increased difficulty in the entrance of blood into the heart, caused by expiration. This is the more imperative the greater the degree to which the existing morbid process has been developed in the visual organ, and the more important the part in which it is located. During such occasions as above indicated, the increased turgidity and marked redness of the face plainly indicate how much a severe and prolonged expiration may influence the course of circulation. Besides, the expiration does not here act alone, but in the visual organ another circumstance assists considerably. Many of the facial veins are supplied in part from the orbital veins, and run between the muscles and bones of the face. In loud speaking, and the like, these muscles take an active part, and in their contraction they press the veins against the bones, and thus diminish their caliber. Furthermore, everything which may in the least interfere with the respiration by narrowing the trachea and con-

tracting the thoracic cavity, or by compressing the lungs, should be removed and avoided. In this is comprehended, among other things, tight cravats, tight clothing pressing upon the chest, collections of fecal masses in the intestines, overloading the stomach with food and drink. Finally it is an important rule that patients with congested or inflamed eyes should eat nothing which renders necessary a great expenditure of power by the muscles of mastication, on account of the above-described blood-congesting effect of the facial muscles. The increase of a congestion of the eyes after a full meal is a matter of daily experience.

II. *The indications furnished by the disease itself.* These may be divided into the following: *a. The limitation of the local depositions; b. The lessening of the blood-supply; c. The removal or lessening of febrile action.*

The means of fulfilling these indications will now be enumerated:

1. *Direct removal of heat.* This limits the local change or nutrition by lessening the temperature of the inflamed tissue, and rendering chemical combinations difficult. Moreover, cold applied for this purpose acts as a powerful irritant upon the contracted portion of the tissue and especially upon the muscles of the vessels, forcing them to contraction, and therewith causing a narrowing of their caliber, and in this way decreasing the amount of blood carried to the inflamed part. It also diminishes the sensibility of the parts, and with it their functional power. Sensitive organs lose their sensation, muscles become rigid, secretions are lessened, etc. The application of cold affects not only the surface, but also the tissues, to a greater or less depth, according to the degree of cold employed, and the duration of the application. The means by which we obtain the effect of cold in the region of the eye are naturally exceedingly various, but cold compresses are the best.

Douches were formerly the fashion, but their preparation is generally too expensive for the private patient, and their use has generally been given up in hospitals, a certain evidence that they have only partially, or not at all, answered their intended purpose. This is not at all surprising when the effect of douches is more exactly understood. Besides the abstraction of heat, there occurs on the use of the douche, whether it be used in a full stream or in the form of spray by means of a nebulizer, a mechanical power or force with which the water strikes upon the parts. By means of this mechanical force, the douche acts, first, as an irritant upon the sensory nerves, and increases the afflux of the blood, and the part which is acted on becomes painful and red. The next effect of this gradual abstraction of heat is that the part becomes pale, without sensation and cool. Any longer action of the douche, however, will not be easily borne. If cold exerts only a momentary effect upon a part, the reaction appears more evident: the inflammation is rather increased than diminished.

Cold applications act primarily as irritants upon the sensory nerves, and may therefore induce a dilatation of the vessels. This effect, however, is evanescent and scarcely comes into consideration, it being understood that by means of the cold compresses the warmth is *continuously* removed, and not merely a high grade of temperature interchanged with a lower one, as is the case when the compresses are so seldom changed that they have time to become warm again before they are replaced by fresh ones. If such contrasts of temperature have an effect upon a part, the result, as a rule, will not be favorable. An important rule therefore is, to quickly change the applications, and the quicker the warmer the part is. If this requirement is fulfilled, the principal danger in the use of cold is avoided. A second danger springs from an immoderate use of the application. Water of a low temperature readily leads to freezing, and this the more easily, the less the warmth is developed in the affected part. The consequences of such a freezing, in the wider

sense of the word, are characterized by all the symptoms of inflammation in relaxed parts, and this inflammation is the severer the quicker the parts are again warmed. By improper use of cold applications, inflammations may be produced as an after-effect, and this not only at the point of application, but also at some distance. In ophthalmia the seat of inflammation is circumscribed, and it is rarely possible to limit the effect of the cold in the inflamed parts, since the compresses used for the application, if they really remove much heat, must always have a relatively large circumference. Even if ischæmia is not to be much feared in the inflamed part, the neighboring parts may suffer, and it not unfrequently occurs that, after a long-continued effect of the cold, collateral hyperæmia and sometimes true inflammations are developed, especially in the periosteum of the orbit and of the bones beneath, rheumatic toothache, etc. These inflammations are, as a rule, very obstinate, and trouble the patient more than the original disease. Sometimes the cold affects even more remote parts. A chill occurs, and affections of inner organs arise, such as we may see after "catching cold," bringing with it new dangers. We may easily overcome these evil results, if we do not allow the effect of the application of cold to go so far that the temperature of the parts sinks much below the physiological standard, that is, making use of the cold application only so long as the warmth of the inflamed part is greater than that of the surrounding healthy parts. On the whole, the abstraction of heat is indicated to a very limited extent in the treatment of inflammations of the eye. Where it can be used with benefit, we must generally employ it carefully at intervals. Only in very special cases, in certain severe inflammations of the external portions of the visual organs, are continuous applications essential.

Linen compresses are the most appropriate means for the application of cold to the eye. Compresses dipped in cold water and wrung out, or still better, made cold by placing them on a block of ice, are to be recommended. These compresses should not be of much larger size than is sufficient to cover the borders of the orbit, in order not to abstract heat from the parts which are in a normal condition. They should not be heavy, except in cases where pressure upon the eye is desired. A piece of fine linen of three to four thicknesses will be sufficient. The compresses should always be well wrung out. If the water drips from the cloths, it becomes a source of unpleasant chilliness. Besides this, very wet cloths are apt to loosen the epidermis; this is thrown off, the corium exposed, and thus not rarely a severe erythema or an erysipelas excited. Excoriations and their evil consequences occur much more readily when the water or ice employed is salty. Mineral spring waters for this reason have of old been decided to be unfit for applications to inflamed parts. When soft water, or ice formed from it, cannot be obtained, we may use distilled water. These precautions are especially necessary in the case of persons with a very soft and sensitive, or relaxed and wrinkled skin. Such patients do not bear cold applications well, and they should therefore not be used, except in case of urgent necessity, and then as sparingly as possible, even running the risk of somewhat delaying the healing process. We may somewhat alleviate this evil effect of the cold compresses by smearing the parts with a little clean fresh fat, before applying them, or by placing upon them a piece of linen, which has been smeared with the fat. If excoriations have already occurred, an erythema, etc., it will be best to stop the application where it is possible, and to favor the healing of the inflammation of the skin by smearing the part with fat or glycerine.

2. *Direct abstraction of Blood.*—Until recently, venesection was very much esteemed.

The efficacy of venesection is doubtful, and the benefit is very little compared with the destructive influence which it may have upon the nutrition of the whole body; therefore nowadays in ophthalmic practice we are nearly restricted to local abstraction of blood. The purpose of this is to favor the exit of blood from con-

gested or inflamed parts through the vessels, to remove the hindrances to circulation, and in a revulsatory way to regulate the development and increase of a stasis, to diminish the rapidity of the circulation and of the increased molecular attraction. The means of local blood-letting are the natural and artificial leeches, wet cups, incisions and scarifications of the conjunctiva.

Natural leeches as well as the artificial ones are, as a rule, most properly applied on the temporal region. In order to attain any effect in the case of very small children, one to two leeches should be applied; in those who are older, three to four; in adults, six to eight of medium size. Care should be taken that the leeches bite as nearly as possible at the same time, and that after they drop off the flow of blood is not interrupted.

[In this country, as a rule, the use of leeches in the treatment of eye-disease in children is not justifiable. Wet cups should never be applied to young children.] Since the effect of natural leeches is evanescent, and the changes in the current of blood are quickly over, it seems advisable, for the sake of an expansion as far as possible of the temporary effect, to apply the leeches in the beginning of an exacerbation of the inflammation. It is at this time that the process receives an impetus, its products are more abundant, and the pain also increases.

The fossa angularis, as well as the integument of the lid, are improper positions for the application of leeches, because the marks of the bites remain for a long time, and disfigure the patient. But this position is chiefly to be avoided because the leeches very often bite through the skin, which is exceedingly thin in this place, even to the veins, and thus considerable bleeding is caused, as well as extravasations in the loose subcutaneous connective tissue. These extravasations may exist for weeks and months before they completely disappear. Sometimes even worse results are seen. Inflammations and abscesses are occasionally caused.

The mastoid process may be a point for the application of leeches when any congestion or inflammation of the eye is connected with hyperæmia of the base of the brain.

On the whole, the therapeutic results of the application of natural leeches are of importance only in the external ophthalmia, that is, in inflammation of the lids and of the conjunctiva. In inflammation and hyperæmia of the globe, especially of the interior of it, the results are scarcely satisfactory, and may be with good reason considered doubtful. This is chiefly explained by the fact that the anatomical connection between the vessels of the temporal region and of the ciliary vascular system is not very intimate, but is relatively distant. The therapeutic effect of natural leeches may be increased by the so-called *bdellatomy*, which has been recently recommended. By this not only the quantity of the evacuated blood, but also the rapidity with which it is taken from the vessels, is considerably increased.

Bdellatomy is best performed by means of a spring lancet. It may, however, in case of necessity, be done with an ordinary lancet. The best moment is when the leech has filled himself quite well. The end of the animal is then carefully lifted up and the blade is thrust vigorously in the side of the leech, better the left. The incision is not so well done in the back, badly in the belly. After the incision the wound should be kept free from coagulations, by means of a moist sponge, or by the injection of lukewarm water, in order that the blood may flow freely from the abdominal cavity of the leech. A leech thus treated sucks much longer than one which is uninjured, and draws a much greater quantity of blood, sometimes taking one and even two ounces. If, in consequence of the restlessness of the patient, or of rough handling of the leech, it falls off too quickly, if reapplied it again acts freely. If carefully kept in clean water the same leech may be repeatedly applied, and incised at intervals of days or weeks (*Fischer*).

The speedy local removal of greater quantities of blood is attained most certainly by the artificial leech.

Heuteloupe's is to be preferred to *Harder's*, the former making a circular wound, the latter cutting with three little spring-knives. The severe and extensive change in the blood-current, caused by the application of this instrument, arises chiefly from the powerful impression which the sudden evacuation of a vascular region exerts on the vaso-motory nerves of the vicinity and even on distant parts. The revulsive effect declares itself after the operation in a very striking nervous and vascular excitement. This reaction cannot, unfortunately, always be estimated beforehand, and under some circumstances may become very dangerous. Thus we observe, as an immediate effect of the operation, almost always a considerable increase in the hyperæmia of the neighboring parts, which, however, soon declines, and, in favorable cases, gives place to the intended vascular contraction. In very excitable patients even actual hyperæmia may occur, and not unfrequently the reaction shows itself by all kinds of disturbances of sensation in photopsia; and in the existence of amblyopia, a decrease in acuteness of vision has been observed which often does not disappear for several days. This is true, although to a less extent, according to past experience of *bdellatomy*. This is also said to excite the patient very considerably. It seems, therefore, advisable to undertake local blood-letting of this kind before retiring, in order that the night's rest may moderate the reaction. When the patient is very excitable it may even be advisable to keep him as quiet as possible in a darkened room during the whole of the following day (*Graefe*).

These are only palliative means, which may, perhaps, diminish the danger of the reaction, but which cannot entirely remove it. On the whole, we conclude that in inflammations having a sthenic character, local blood-letting by means of bdellatomy and the artificial leech is better avoided, and their use is limited exclusively to conditions of passive hyperæmia and chronic inflammation. Even here the recent immoderate praise of the artificial leech is not wholly deserved.

There is no good place for the application of wet cups in the vicinity of the eye; and when applied at some distance they scarcely have influence enough upon the circulation of the visual organ and appendages. Dry cups applied on the temples have no effect. Incisions and scarification are only useful in severe conjunctivitis. The great pain caused by these latter procedures prevents their being carried out in the greater number of cases.

The practical oculist should be the more guarded in their employment, since the result does not always answer the expectation, or it is not appreciated by the patient.

It not unfrequently occurs, that they increase the inflammation in the loose conjunctival tissue. Besides all this, the desired effect may be generally attained by the application of a sufficient number of natural leeches.

3. *Antiphlogistic regimen.*—We understand by this the lessening of the supply of the peculiar nutritive material of the blood, as well as the keeping away of all which may act as an excitant upon the nervous system or circulation. This should be strictly carried out when the inflammation is dangerous either from its severity or extent, whether the whole organism, as manifested by febrile action, is taking part in it or not. If this be not the case, it is generally sufficient to observe moderation in every respect, and besides to avoid the use of hard and tough food, which demands the vigorous action of the muscles of mastication. A severe antiphlogistic regimen is not indicated in mild cases, since the lowering of the nutrition, especially in chronic inflammation, by continued dieting, may easily lay the foundations for dangers which far exceed those of the local condition. Where the nutrition is already somewhat impaired, or perhaps atonic conditions, having their origin in this

impairment, have been increased by the occurrence of the inflammation, it will be often found necessary to favor resolution by means of generous, slightly stimulating diet.

Bodily and mental rest belong to severe antiphlogistic regimen, as well as the maintenance of an equable and pure temperature; the avoidance of all aromatic and stimulating drinks; coffee, tea, wine, beer; lessening of the amount of food, and the choice of easily-digested substances. Food easily oxidized, such as Liebig's respiration material, the vegetable acids, farinaceous and saccharine substances, soups, vegetables, salads, steamed and stewed fruits, should be the main portion of the diet.

Highly seasoned food should be forbidden, as well as fat, the latter not being easily digested in the inactive condition required of the patient. It is also advisable to have the food cool when eaten, and only a little should be taken at a time, but often during the day.

4. *Antiphlogistic medicines.*—Their number is large, but we cannot rely much upon them in the struggle with the inflammatory process. We should therefore restrain ourselves as much as possible from their use in cases of pure ophthalmia, where we desire solely an antiphlogistic effect. Where circumstances permit, we should use the milder antiphlogistics, *e. g.*, nitrate of potash, the carbonates, phosphates, vegetable acids, avoiding the heroic remedies, or only using them when the functions of the eye are in real danger from the inflammatory process, and it reaches the point where, in case the result should be bad, we wish to be able to say to ourselves that all has been done that could be done to prevent it.

The use of the *Infus. rad. Senegæ*, oil of turpentine, and similar specifics, has been long since abandoned. It is therefore superfluous to speak of them further. Tartarized antimony, formerly a very much esteemed remedy, is in ophthalmic practice entirely useless, even harmful, and is strictly to be avoided. Iodide of potassium, on the other hand, used in moderate doses, is scarcely dangerous, but as a pure antiphlogistic is of no particular value. The greatest misuse has certainly been made of mercury; for every irritation, however moderate, in the region of the eye, was formerly treated by this agent. In mercury a remedy was seen which had a decidedly specific effect on the eye, and which was able to bring its inflammatory action to resolution. The origin of this erroneous idea lies in a want of observation. The view was inculcated that syphilitic iritis was characterized by certain decidedly peculiar symptoms, and that when these symptoms were wanting there could be no idea of a syphilitic origin in a given case of iritis.

Now then, practically, an iritis was often found which concealed every positive evidence of syphilis, which was, however, of syphilitic origin, and which only yielded to anti-syphilitic treatment by means of mercury; the opinion was necessarily reached that mercury acted more efficaciously on an inflamed organ of vision than any other agent, and thus it happened that it acquired the fame of a real panacea. Strange to say, calomel is the preparation most frequently used—a preparation which, as is well known, easily excites fluid, greenish stools, and also easily induces injurious and obstinate salivation, and by no means rarely becomes destructive. A few doses of a grain each are often sufficient to excite this unpleasant symptom, and compel the surgeon to give up the use of the remedy before the wished-for effect can be developed. Where we wish really to mercurialize the patient, calomel is not well adapted to the purpose.

The same may be said of Hahnemann's soluble mercury and the proto-iodide. The sublimate of mercury or corrosive chloride is to be preferred. This is generally well borne, and may be taken for a long time without especial harm. Sometimes, however, it excites severe pain in the stomach, which forbids the further use of it. It is best given in the form of a pill. *Mer. sub. corrosi.*, gr. ij.; *solve in q. s. Aq. dist.* Adde, *mica panis alb. q. s. ut f. pil. gr. i. n. 32*; *consp. pulv. Liquiritiæ.* One pill is to be taken night and morning on an empty stomach; and every two to three days increase the dose, until half a grain a day has been reached, and again the dose is to be diminished at intervals of two days. Again, the external use of *Ung. Hydrarg. Cinereum*, in the frontal region, is very much esteemed. It is

believed that by this the effect of the internally administered antiphlogistics is increased, and at the same time absorption in the orbital cavity is frequently excited. The value of this remedy is, however, more than doubtful. In the case of children and dirty, careless patients, the inunction of this ointment, as in fact of all salves, in the vicinity of the eye is even dangerous, since this class of persons often smear the salve everywhere, bringing it into the conjunctival sac, and thus favor unpleasant irritations in the eye.

When we wish a speedy and sufficient effect of mercury, in order as quickly as possible to make a powerful impression, especially where the ophthalmia is founded on a syphilitic affection, the inunction treatment is without doubt the most certain. In recent times it is employed in connection with the internal use of the iodide of potassium, or the cheaper chlorate of potash, a combination which much experience has shown to be very advantageous. The number of the inunctions, and the number of days of treatment with it, depends upon the result of the use of the remedy. In general the treatment should be continued up to the disappearance of the ophthalmia, and of the accompanying syphilitic manifestations. In order to remove recent local affection ten to sixteen inunctions are often sufficient. Sometimes for this purpose twenty to thirty are necessary. To exceed this latter number is not advisable, for when twenty to thirty inunctions have no result, the further use of mercury does no good, but may rather be harmful.

The imperativeness of the circumstances does not allow, in diseases of the eye, the otherwise customary but time-consuming preparations for the inunction treatment. Warm baths, even in the existence of severer inflammations of the eye, are contra-indicated, and, in such cases, should be replaced by washing the parts of the body which are to be anointed, with lukewarm soap and water. For an inunction, about one to two scruples of the gray ointment—best a mixture of three parts *Ung. Hydrarg. Cin. comm.*, with one part *Ung. Hydrarg. Cin. fort.*, is used. This, in small quantity, is gradually rubbed into the parts with a rotary motion of the hand, and best by the patient himself. On the first day, it should be rubbed in the calf and the popliteal space; on the second day, on the inner surface of the thigh; the third, on the surface of the chest and abdomen; on the fourth, on the inner side of the forearm and arm, including the elbow, and then the same course is gone over again. The nipples, navel, very hairy parts, or those covered with moist eruptions or ulcers, are to be avoided in the application. After the inunction, the parts should be wrapped in a linen or woolen cloth. The best time for the inunction is an hour before going to bed, because during the night perspiration is the least interfered with. In the morning the perspiration should be increased by an additional covering, but care should be taken at that time, as well as during the night, that the mouth is not covered, and the patient thus breathe the mercurial vapor developed in the bed.

After this perspiration, the body should be washed in lukewarm water and dried. Then the patient should get up and remain in his room completely dressed. The bed should always be placed in a part of the room free from draughts and changes in light, but it should not be surrounded by shades or curtains, because interference with the free circulation of air favors ptyalism, and the seclusion of the patient in a narrow space annoys him unnecessarily, and may be positively harmful. Daily and careful ventilation of the room is not to be neglected. It is better, where practicable, that the patient should have two rooms, and the temperature should be uniform, and should never fall below 63 degrees F.

The imperative necessity of securing good ventilation (while administering mercury) has

been very clearly shown, by recent experiments on men and animals, and from observations on workers in quicksilver, miners, manufacturers, etc. These observations prove that mercury does most harm in the form of vapor, and that the stomatitis appearing during the inunction treatment, together with its consequence, salivation, is generally if not exclusively caused by inhaled mercurial vapor. The tendency of the mucous membrane of the mouth to inflammatory affections from this vapor is explained by the severe rubbing and pressure to which the membrane is subject from the teeth. In old persons without teeth, and children, this tendency is said to be absent.

The fact also comes into consideration in the pathogenesis of mercurial stomatitis, that the mercury taken into the body is chiefly removed through the saliva. It thus comes in immediate contact with the mucous membrane of the mouth, and may cause inflammations by the mechanical irritation, just as occur on the sensitive skin of delicate persons. It is of the highest importance to take the greatest care of the mouth and teeth. The mouth should be cleansed every hour by gargling and rinsing, and the teeth with a soft brush. In the existence of abrasions or ulcerations in the mouth or pharnyx, solutions of the bichloride of mercury one to two grains to the ounce, of the chlorinated soda, one to four drachms, or chlorate of potash, one drachm to the pint of water, may be used as gargles. If there be no ulceration, a solution of alum, one to two drachms to the pint of water, tincture of galls, two to four drachms, or borax, from one to two drachms in the same quantity of water, may be used. If the gums are already affected, loosened, spongy, or bleeding, they should be painted several times daily with the tincture of galls or opium.

During the whole time of treatment, the patient should take five grains of iodide of potassium or chlorate of potash three times a day. The diet should be restricted, but not so much so as to exhaust the patient by hunger. Where the patient's condition is already very much deteriorated, it may appear even advisable to aid the system by rich, easily-digested, and nourishing food. We should see that the bowels are evacuated daily or oftener. Baths are not advisable during the treatment of eye-diseases, however useful they may be in other cases; but as a substitute, the linen may be frequently changed, having it first thoroughly warmed. On the day after the last inunction, the patient should take a warm bath, and change his linen. He should return very gradually to his former way of living. It is advisable to continue the iodide of potassium for several days after the inunctions have been stopped.

The inunction treatment is still deemed by many an extremely destructive attack upon the system. Its employment should be well considered in persons with weak lungs and tuberculosis. In such cases, where it is possible it should be avoided, since experience shows that such persons are affected very seriously by the vapor of mercury. But in other cases we scarcely find any injurious effect upon the whole system, in a carefully and properly conducted inunction treatment. The great fear of it does not seem to be justified, when we remember that only a short time ago, and even to some extent at the present time, mercury was used in large doses in the most trifling affections, and for a long time, without producing any decided or permanent injury. But mercury always requires the greatest care in its use, and it is only to be justified in really urgent cases, when other means are not sufficient. In syphilitic affections of the interior of the globe it is indispensable, and should be employed, even if there be danger that the constitutional disease be not cured, and that it may become worse by relapses in consequence of the mercurial treatment (*Boeck*). It is even admitted by the severest opponents of mercury, that recent local affections are easily removed by this remedy, and often with surprising rapidity. Here is just the point in syphilitic ophthalmia, since a short delay in the case often does permanent harm, and may even destroy the functions of the organ, while relapses exist only in anticipation, and do not always return in this very important part of the body.

5. *Drastic Purgatives.*—The sulphates of soda, of magnesia and potash, as well as the other purgatives, jalap, senna, castor-oil, etc., are only indicated in a few

cases, in the treatment of eye-disease. They accomplish nothing as revulsants, but rather do harm, since the rest of the patient, which is so imperatively demanded, is disturbed by the frequent stools and the intestinal pains. As simple evacuants, however, they should not be wholly rejected. It is not unfrequently necessary to excite speedy and abundant evacuations from the bowels, in order to remove fæcal collections, and thus to attack the congestion in the upper part of the body depending upon them.

Indeed obstinate constipation is decidedly inimical to the favorable course of a disease of the eye, and is therefore to be carefully treated. The drastic purgatives, however, may often be dispensed with. Where we simply wish to prevent the collection of fæces, the remedies known as eccoprotics may be used, since they excite the somewhat inert intestinal canal very little. We only wish one or more gentle evacuations daily, and not a real purgation. Laxative mineral waters are very useful.

6. *Counter-Irritation.*—In setting up a severe irritation in the vicinity of the eye, we aim to withdraw the blood from the original seat of inflammation, and to lessen the lateral pressure. It is clear, however, that this collateral deviation of the stream of blood can only last a short time, and scarcely long enough for the vessels to dilate. The effect then is evanescent.

The advocates of this method of treatment may perhaps have observed this, and support their views on the possibility of a resolution in an antagonistic way. Unprejudiced observers have not been able to discover any such effect in eye-diseases, but the profession has been compelled to call these remedies instruments of martyrdom, which do no good in any case, but often do more harm than the original disease.

All this is true of moxas, setons, and issues. Exhaustive suppuration and even erysipelas, terminating fatally, are the possible consequences of the use of these agents. The pustules from the use of tartar-emetic ointment cannot be much better spoken of. Even euphorbia plaster is dangerous, especially in persons with a soft skin, and in children. Extensive impetigo and eczema not unfrequently arise, in consequence of counter-irritants applied behind the ear, or in the temporal region. We also very often see the cervical glands swollen and even suppurating, as a result of the same treatment. The ulcerated part may also be scratched by the patient, and the matter brought in contact with the eye.

7. *Narcotics.*—These are often of undoubted benefit; they are not only indicated for the purpose of lessening or removing pain, but also to exert a favorable effect on the course of the inflammation, by removing the bodily and mental disquiet produced by the pain. They also quiet the sensory nerves, and thus remove one of the causes of impairment of circulation and nutrition. We should never forget, however, that narcotics, administered in effective doses, are dangerous remedies, and that they often develop unpleasant effects as well as those which are desired. We should not, then, use narcotics without due consideration, and only when really required, always being on our guard to avoid their injurious effects.

Morphine stands at the head of the list of narcotics, on account of the certainty and great regularity of its medicinal effect. It should have the preference before all other agents, where we desire a quick, powerful, and decided result. These are peculiarities which are often of great value, yet morphine readily causes vomiting, which, under some circumstances, may be dangerous in eye-disease, or after an operation on the eye, and therefore limits its employment. The sulphate or the muriate being very soluble, are the preparations usually employed.

Morphine is particularly to be recommended as an excellent anæsthetic, adapted for internal and external use, mixing chloroform with it. ℞. *Morphii pur.*, gr. iij.; solve ope *Acidi acet. concentrat.* gutt. vi.; leniter ebulliendo in *spirit. vini rectificatissimi*, ʒ i.; solutioni refringeratæ admisce *Chloroformi*, ʒ ss. D. in vitro bene clauso. The solution is best made in an *eprouvette* over a spirit-lamp, the alcohol being added gradually. For internal use in adults, doses of from twenty to forty drops; in children, ten to fifteen, given on sugar, may be ordered. It may subdue the severe local pain when rubbed into the frontal region, as well as when applied on a bit of cotton in the external auditory meatus (*Bernatzik*).

The endermic use of opium and morphine in the form of ointments or powders, the latter being placed on a part of the forehead deprived of its epidermis by vesicants, is entirely untrustworthy. It is not applicable when a local toning down of the morbidly excited sensory nerves is really and imperatively required. Dilute hydrocyanic acid, cherry and bitter almond water, digitalis, aconite, lupuline, hyoscyamus, belladonna, and stramonium are entirely useless as pure anodynes, since in efficacious doses the unpleasant concomitant effects are too prominent. Yet aconite and digitalis, on account of their brilliant effect on the action of the heart and kidneys, under certain circumstances favor the resolution of local inflammation. They are thus appropriate as antiphlogistics. Aconite is also esteemed by some as a remedy for rheumatic and gouty affections.

Hypodermic injections are very much used, and indeed this method has much to recommend it above the others. We are more certain that the remedy has been taken up, and its effects appear quicker and are more permanent and complete than when it is used internally. The effects are often seen within half a minute. This method is particularly to be recommended in accidents which threaten loss of life, poisoning, etc., the constitutional effect appearing in the shortest time. But undoubtedly local effects are also secured by the hypodermic injection of narcotics, and with this an especial curative action, as observations in reflex spasms prove, where we can most accurately determine as to the seat of pressure. These injections are best made by means of Luer's improved syringe, or Prava's. The most appropriate point for the injection, when we wish a constitutional effect, or when we desire to subdue pain in the orbital region, is the center of the temple. In other forms of neuralgia, and in reflex spasm, the seat of pain or the predominant seat of pressure should be chosen for the injection. We should pinch up a fold of integument, lifting it up well, but releasing it after the entrance of the point of the needle. If this be not done, the fluid will run out. For an anæsthetic effect, a solution of one of the salts of morphia is used, four grains to the drachm. The syringe is filled with this, and the fluid injected until the mark 7—9 on the handle is reached, when about 1-6 or 1-5 of the alkaloid has been injected. The solution should be perfectly clear and neutral. The primary excitement after the hypodermic injection of morphia is apt to be much more severe than on the internal use. Nausea and vomiting also occur more readily, which is a point to be considered; still this reaction quickly passes away. This treatment is particularly to be recommended after injuries and operations, when we wish to alleviate severe pain in neuralgia also, without eye-disease and in reflex convulsions (*Graefe*).

The local reaction caused by the wound itself is almost always extremely slight, if the point of the instrument be sharp enough, and it be used with care. In no case is there any danger to be apprehended from the wound, and from the entrance of the fluid into the sub-cutaneous cellular tissue. Sometimes, however, fortunately in very rare cases, the point of the instrument enters a sub-cutaneous vein, and thus the solution is injected directly into the blood. The symptoms are then very alarming, and they appear with the rapidity of lightning. They are severe burning and cutting sensation over the entire skin, a strong acid taste on the tongue, a dark reddening of the face, tinnitus aurium, flashes of light, and a very severe pain in the scalp. Added to these symptoms, there is an extremely powerful and rapid movement of the heart, and

in some patients loss of consciousness and convulsions. These symptoms last for some minutes; but in all cases which have as yet been observed, they pass away without harm.

This accident indicates an important rule, which is, to inject very slowly, and on the appearance of the symptoms in question to stop immediately, and draw the fluid back into the syringe. The reaction appearing with such lightening-like rapidity, this may be easily done. When there is any danger of apoplexy, from a morbid condition of the vessels, venesection should be performed as quickly as possible (*Nussbaum*).

8. *Mydriatics.*—Agents which enlarge the pupil. These are of inestimable value in the treatment of diseases of the eye. They take their name from the most striking of their effects, that is, the dilatation of the pupil. In the strict sense of the word, belladonna, hyoscyamus, and stramonium, with their alkaloids, are to be considered as the mydriatics.

Besides these may be mentioned solanine (*Fraas*), delphinine (*L. V. Praag*), aconite (*Lombe Athill*), which all act in large internal doses; and strychnine (*H. Braun*), which produce the same result on external use. These substances should not be employed for their mydriatic effect, since it can only be obtained at the expense of disturbances in the entire organism, so very serious and dangerous as to be considered symptoms of true poisoning.

The enlargement of the pupil, which is caused by the true mydriatics, reaches its maximum, that is, the iris is retracted to a narrower border, only when the agents are applied in sufficient quantity. The iris is completely immovable when this effect is attained; it does not react to alternations of light, or to changes in the convergence of the optic axes. The power of accommodation is also greatly limited. With a more powerful effect, the latter is even completely removed, and the refraction becomes a little less than corresponds to a normal relaxation of the accommodation. These effects last one or two days, according to circumstances, when the size of the pupil gradually becomes less, and its action is restored. The paralysis of accommodation yields last of all. It remains for days, decreasing steadily, after the pupil is restored to its normal size, and has regained its mobility.

This impairment of the accommodation is evidence that the ciliary muscle as well as the muscles of the iris are influenced by mydriatics. As an insurmountable proof of this the fact may be adduced, that in isolated cases, after complete loss of the iris, very similar changes in the accommodation and refraction may be induced by the mydriatics (*Graefe*).

These effects are, generally speaking, either the expression of a weakening or paralysis of the intra-ocular muscles, supplied by the third pair of nerves, or, very probably, the evidence of a direct excitement of those inner muscles of the eye which receive their nerve-supplies from the cervical portion of the sympathetic. Indeed, the mydriatics enlarge the pupil to the maximum, where conduction is completely interrupted in the third and fourth nerves, in fact, in all the cerebral nerves passing to the orbit (*Graefe*). These contractions are also more powerful than those which can be excited, in the normal state, by external irritation, which state of things may be with some certainty referred to the radiate fibers of the iris.

Mydriatics are useful, then, when we wish to secure a dilated pupil only, or a vigorous contraction of the muscles which accomplish this. Under some circumstances, the reduction of the refraction of the dioptric apparatus is also useful.

Besides, their paralyzing effect on spasm of the internal muscles supplied by the third pair is of value. Such spasms have been certainly observed, especially as a consequence of traumatic inflammations, and they have been relieved by mydriatics.

The remarkable observation was at the same time made, that the function of accommodation, which was impaired during the spasm, became free again, even before the pupil was dilated (*Graefe*).

It seems, besides, as if these spasms appeared much more frequently than has been believed, or than could be proven. It is not improbable that they frequently accompany the severe forms of irritation of the sensitive ciliary nerves, which are very often observed in the various forms of keratitis, iritis, etc. The favorable effects of the mydriatics in those diseases is to be probably sought for in their antispasmodic effect.

Mydriatics should be applied directly to the eye, if we wish their peculiar action to be certainly and thoroughly developed. They can then be absorbed by the conjunctiva and cornea. If this is not done, mydriasis either does not occur at all, or slowly and insufficiently, and very quickly disappears.

In accordance with this, the direct application of a mydriatic on one eye does not cause the pupil to enlarge in both. Where mydriasis appears in the other, experience shows that it is to be attributed to an accidental application of the agent to that eye; a contraction of the pupil of the eye in which the mydriatic was not used has even been observed. This is probably to be ascribed to the increased impression of the light upon the eye acted on by the mydriatic. In using mydriatics internally, grave symptoms of poisoning often occur before the pupil becomes dilated. Hypodermic injections, and the use of a powder upon the surface of the skin, deprived of the epidermis, have also proved insufficient for the purpose of producing mydriasis. They are only proper when a constitutional effect is desired.

If a mydriatic be placed in the conjunctival sac, a small portion immediately reaches the intra-ocular space by absorption (*Ruiter*, *Graefe*), and thus may act upon the intra-ocular ganglionic system. The enlargement of the pupil and paralysis of accommodation are only evidences of a loss of conducting power of these ganglia, produced by the poison. The ganglia become incapable of conducting an impulse of the will or the nerve-currents from the brain, which are carried there from the ciliary twigs of the third pair, or *oculo-motorius*. They remain sensitive, however, to irritations acting directly upon them, or those which are transmitted by the sensory branches of the fifth pair, and they reflect these with undiminished power upon the motory terminal twigs of the third nerve, which pass from them toward the periphery.

Indeed we cannot produce any contraction of a pupil which has been dilated by a mydriatic, even by irritation of the intra-cranial part of the third nerve (*Grünhagen*, *Bernstein*). But the pupil contracts rapidly and vigorously if the aqueous humor or a part of the vitreous humor be evacuated, if a current of electricity be conducted upon the sphincter of the pupil (*Bernstein*), or if strong chemical agents—nicotine, creasote, and the like—act upon the surface of the globe (*Rogow*). Besides, daily experience teaches us that even the greatest amount of dilatation of the pupil quickly recedes if morbid processes with severe irritation of the ciliary branches of the fifth pair are developed, and that the mydriatics do not act well, when used locally in such diseases of the eye. In fact, the magnitude and rapidity of the effect of mydriatics practically become a very valuable measure of the severity of any given ciliary irritation.

We can scarcely seek for the origin of the reaction in the sphincter pupillæ and in the ciliary muscle, from mydriatics and myotics placed in the conjunctival sac. in any other situation than in the ciliary ganglionic system; because these reactions are strictly confined to this system, and also occur when the third pair has become incapable of conduction by disease or from an operation (*Ruete*,

Donders), if the cervical sympathetic alone (*Biffi*, *Cramer*, *Donders*) or with the trunk of the trifacial has been divided, even if the optic nerve and all the ciliary nerves have been cut through (*Budge*, *Donders*), or if the brain and spinal cord have been removed from animals recently killed, or the eye completely isolated (*Ruiter*, *Rogow*, *Grünhagen*). But it cannot be the intra-ocular muscles themselves (*Budge*, *Grünhagen*), or the ends of the fibers of the third pair (*Bernstein*, *Dogiel*, *Rogow*), that are directly and alone affected by the poison; because the paralysis of the sphincter produced by the mydriatic is only relative; its muscular fibers and the ends of the nerves preserve their full sensitiveness to irritation.

This relative paralysis of the sphincter of the pupil is, however, not sufficient to completely explain the mydriasis. The marked lessening in size which the iris undergoes, shows that there must be some power in action which causes the blood to pass from the vessels of the iris into the posterior part of the vessels of the uveal tract. Besides, the stretching and frequent breaking up of posterior synechiæ, as well as the distention of portions of the iris between the points of adhesion, so often seen, are evidences that great traction is exerted upon the pupillary border. We must, therefore, believe that in connection with the relative paralysis of the motory nerves of the sphincter and the ciliary muscle there is an irritation of the motory nerves, belonging to the sympathetic, which supply the dilator of the pupil and the muscles of the vessels.

This view is in accordance with the accepted fact, that complete interruption of the conducting power of the trunk of the third pair only causes a partial dilatation of the pupil, and only slightly affects its shape if posterior synechiæ exist. The second factor, the spasmodic innervation of the dilator of the pupil and of the muscles of the vessels of the iris, is wanting in such cases. But if this be excited by mydriatics, or by irritation of the cervical portion of the sympathetic, the mydriasis becomes as complete as when the third pair is intact, and the stretching of the posterior synechiæ becomes marked.

There is a difference of opinion as to whether in artificial mydriasis the excitation of the oculo-pupillary sympathetic twigs has its origin in the intra-ocular ganglia, or if the sympathetic nerve is itself directly influenced by the poison. Some experiments on animals favor the latter view (*Meuriot*, *Fraser*). But if the former view be correct, it would show a considerable difference, as far as the ciliary twigs of the third pair are concerned; because the functional connection of the sympathetic filaments with their cerebral origin does not appear to be a loose one; so that division of the cervical cord weakens the mydriasis (*Biffi*, *Cramer*, *Donders*), while its irritation increases the dilatation (*Donders*). It must be, then, that these conditions are to be referred to numerous sympathetic tubes which run with the vessels into the interior of the eye, and which probably do not pass beyond these ganglia. At any rate, these nerve-nodules cause a reflex action from the sensitive fibers of the fifth pair upon the motory nerves of the dilator of the pupil and the muscles of the vessels of the iris. Weak irritations of this kind may somewhat increase the reaction of these muscles, severe irritations remove it. They completely paralyze the twigs of the sympathetic, so that neither galvanization of the cervical sympathetic, nor irritation of the cerebral origin by carbonic acid gas will cause a dilatation of the pupil (*Rogow*).

From all this, we judge that mydriatics are especially indicated, where we wish a dilatation of the pupil, or a vigorous contraction of the dilator of the pupil. Under some circumstances the diminution of the refraction is also useful. Besides,

the production of paralysis of the accommodative apparatus is also of value in spasm of the internal muscles supplied by the third pair. These spasms are undoubtedly a very common accompaniment of severe irritations of the sensory ciliary nerves, such as are often observed in various forms of keratitis, iritis, and so on. It is probable that we may ascribe at least a part of the good effect attained by the use of mydriatics in such cases to the relief of these spasms, for the spasms certainly act upon the sensory ciliary nerves, and thus upon the vaso-motory nerves, by increasing the irritation. Whether there is a direct anodyne effect (*Meuriot*, *Bezold*, *Bloebaum*) is uncertain. Certain it is, that the power of producing paralysis is only one factor; the other, and perhaps the chief factor, is the vigorous contraction of the vessels, in the anterior portion of the ciliary region, which is undoubtedly accomplished by the mydriatics. Thus these remedies, with some restrictions, become entitled to a place among the true antiphlogistics.

These restrictions are first in regard to locality. The invariability in the amount of intra-ocular blood necessarily unites with a contraction of the anterior portion of the ciliary vessels an equal dilatation of the choroidal vascular net-work, as proven by actual observations (*Schneller*). But it is clear that it is impossible, that an increased flow of blood should favor the resolution of congestive or inflammatory conditions. Indeed, within a short time some authorities (*Mooren*) protest against the use of mydriatics in cases in which the posterior uveal tract is the site of the diseases in question, or when its development is feared in this situation.

The indications, also, that the use of atropine favors the outbreak of acute glaucoma in an eye already affected (*Graefe*, *Hasket Derby*), have increased of late. Retinal detachment, and other affections connected with disturbances in the choroid, may possibly be induced by the same cause.

Under such circumstances we can the more readily dispense with the remedies in question, since we know that the view so readily adopted, that we could influence the hight of the intra-ocular pressure by mydriatics, is scarcely justified, but is rather opposed to the facts that the vigor of the pulsations increase with the quickness of the blood-current, shown in the entoptic choroidal appearances of an eye under the influence of atropine (*Hippel*, *Grünhagen*).

Secondly, the limitations in the action of mydriatics of which we have spoken, are in regard to the dose of the agent employed. The sympathetic fibers maintain their usual character under the action of mydriatics, and by a weak irritation are placed in a state of continuous excitement, while they become paralyzed under a greater irritation. In consonance with the fact, it has been known for a long time, that very strong applications of atropine, or very frequent ones within a short time, finally lead to a marked increase of the morbid vascular symptoms. As often as the agent is used, does the conjunctiva and episcleral tissue become reddened. Severe pain occurs and the inflammatory process takes a step forward.

In some cases, even the independent development of severe irritations of the lids and conjuntiva, attended by lachrymation, œdema, and eczematous eruptions, which lasted for months, have been observed (*Graefe*). In other cases the globe is said to have finally lost much of its normal resisting power (*Coccius*). This has been ascribed to great interferences with the circulation and the nutrition in the posterior cavity of the globe.

Under such circumstances we are apt to speak of an overdosing of the eye, but we cannot overlook the fact that such attacks sometimes occur very early and after a few and weak applications (*Lawson*). The individual variety in the sensitiveness

of the sympathetic nerve-fibers, which varies very much according to circumstances, and the time, are also to be taken into account. If we are not deceived by all that has been observed in such cases, passive dilatations of the intra-ocular vessels, such as accompany degenerative inflammatory processes of the whole uveal tract, but which are especially found in accidental or operative evacuations of the intra-ocular media, will occur and continue until the cicatrix is firm. They thus prevent the reaction, and it is certainly well under such circumstances, especially after cataract extraction, to be careful in the use of mydriatics. The earnest warnings which we have lately received (*Sichel*) against the misuse of atropine are to this extent justifiable.

Atropine, and by this we mean the neutral sulphate, answers all the requirements that can be made of a mydriatic. It is very soluble in water and does not require the addition of alcohol as does the pure alkaloid. It is also cheap and retains its virtues well.

Daturine is almost as effectual. Hyoscyamine is a much more powerful mydriatic (*Schroff*), and may be used where we desire a rapid and vigorous contraction of the iris; for example, where there are posterior synechiæ, or where the atropine is not well borne. It is not fitted, however, for use in inflammation on account of its powerful effect upon the oculo-pupillary branches of the sympathetic, since it is apt to increase the paralysis of the vessels, and thus make the condition worse. It is besides very dear, and does not keep well as a neutral sulphate, since it has been used, up to this time, in the form of an extract, and in this form is very hygroscopic, and readily becomes moldy.

The extracts of belladonna, hyoscyamus, and stramonium are not now used in ophthalmic practice, on account of their insufficient effect as mydriatics, besides other objections.

We may use a solution of sulphate of atropia, one grain to two drachms of distilled water, of which a few drops are dropped into, or pencilled upon, the conjunctival sac.

One such application, where there is no severe ciliary irritation, is usually sufficient to attain a full effect. In old persons a somewhat longer time is required for this effect than in young; where we desire the atropine to act as an antiphlogistic, once or twice, at the highest three times a day, are sufficient for the applications.

A stronger solution and more frequent application do not accomplish any more, and place the eye in some danger of sympathetic over-irritation, while they may act as constitutional poisons.

Solutions of atropine sometimes suffer from the formation of fungi or mold; become flocculent, and thus in some cases cannot be used without danger; sometimes the flocculi appear in two or three days. The solution should then be filtered, in order to avoid unpleasant irritation. Solutions are therefore by no means for preservation for any length of time. Atropine paper is sold for this purpose in most of the apothecaries' shops (*Streatfield*). This is cut in quadrants, and if one be placed in the conjunctival sac for a few minutes it is sufficient to cause a great dilatation of the pupil. Atropine gelatine, which for some time was to be had in similar quadrants, and which was so soluble that it did not require removal after its employment, does not appear to have found friends enough to keep it in market.

It is not advisable to use atropine in substance, in order to secure the most powerful effect possible (*Homberger*, *Dobrowolsky*), on account of the difficulty in telling what amount is being used, and on account of the irritating effect which the salt produces on the sensory nerves, in severe inflammations (*Rogow*). But an ointment of one grain of the agent to two drachms of pure lard, a piece about the size of a pea, being placed in the conjunctival sac may be used. But this ointment when rubbed into the forehead is entirely untrustworthy as a mydriatic, since, unless some be accidentally transferred to the conjunctiva, it can only act by absorption, that is, from the blood. It often happens, therefore, that when such an ointment has been used for a long time, suddenly and contrary to all expectation, symptoms of poisoning occur which last for several days.

Mydriatics are very active poisons, which may be carried into the blood, even when employed in very small doses of one-hundredth of a grain or even less, and excite exceedingly unpleasant, and under some circumstances dangerous, symptoms. The symptoms of such a poisoning are, a scratching sensation in the throat, a heavy pain in the head, the greatest excitement, sleeplessness, excited dreams, frequency of pulse, ischuria, and so on.

Some few patients are exceedingly sensitive, and react to even the most careful instillation of mydriatic solutions with exceedingly unpleasant symptoms.

Of course these unpleasant effects occur more readily if strong solutions are frequently used and continued for a long time. Very slight amounts of the agent are always absorbed through the mucous membrane of the lachrymal apparatus, and may thus get into the blood. When the lachrymal passages are very permeable it may happen that the greater part of the solution dropped into the conjunctival sac will pass in a few minutes into the nasal cavities and from there into the alimentary canal, where it is completely taken up by the blood, and acts exactly as if taken up by the mouth.

In order to guard against this carrying of atropine into the alimentary canal, it is well to evert the lower lid somewhat during the instillation, in order to bring the lower punctum out of the way. Besides this we may close the two canaliculi by pressing the finger upon them (*Donders*). Of course this procedure only prevents the direct overflow into the puncta and canaliculi, and does not guard against the subsequent overflow of that lying on the surface of the conjunctival sac. In order to be perfectly safe, the conjunctival sac may be washed out with pure water after the atropine has had sufficient effect.

If poisoning by atropine does occur, we should immediately make an hypodermic injection of sulphate of morphine, from one-sixth to one-third of a grain, into the temporal region. Morphine is a very efficacious and trustworthy antidote to atropine (*Benjamin Bell*, *Graefe*, *Buttles*), at least as far as its mydriatic and narcotic effect is concerned.

Myotics.—Agents which contract the pupil are of very inferior importance in the treatment of diseases of the eye. They are the antagonists of mydriatics as far as regards their local, and in some respects as to their constitutional effects. The only useful myotic, when we desire a great contraction of the pupil without any unpleasant concomitants, is calabar bean. This agent has but lately been brought into notice (*Christison*, *G. Harley*, *Th. Fraser*, *A. Robertson*, *Bowman*). Its active principle is physostigmine.

Opium and morphine also act as myotics when taken internally or when used in hypodermic injections. Opium, morphine, coniine, and digitaline are exceed-

ingly powerful myotics when applied to the eye (*Rogow, Grünhagen*). This myotic effect is probably not due to their specific properties, but to the severe irritation which they produce upon the sensory nerves of the conjunctiva and surface of the globe, and which acts from here through the ciliary ganglionic system upon the motory nerves of the sphincter of the pupil, and upon the muscles of the iris.

Myosis, which is produced by the local use of large quantities of the preparations of calabar bean, lasts about eight days, although a slight retrogression is observed within six to twelve hours after the application. If a small dose be used the effect is apt to pass away in from one and a half to two days. The changes in accommodation remain a much shorter time, disappearing generally within a few hours. The far point begins to recede in the first twenty minutes, and in three-quarters of an hour to two hours reaches its former position, and the near point also assumes its normal distance (*Graefe*).

The calabar bean acts primarily and preferably upon the muscles of the iris, exciting contraction of the sphincter, and relaxation in the radiate fibers. If used to a large amount it causes a spastic contraction of the ciliary muscle. This is shown by the increase in the refractive power, even in eyes without an iris. These effects are confined to the eye to which the application was made. The pupil of the other is even apt to enlarge on account of the diminution of the total impression of the light acting on the two retinas.

According to what has been said there is a complete contrast between the true mydriatics and the calabar bean. This is also more clearly shown by parallel experiments with atropine and the myotic in question. Indeed, on carefully mixing the two in exact proportions, their effect is completely neutralized. Calabar bean preparations are, however, much weaker than atropine, for mydriasis recently produced by a full application of the latter, cannot be permanently removed by a strong preparation of the calabar bean. Mydriasis which has been produced by a weak solution of atropine, or which has become lessened by the lapse of several days, is only removed for a short time by strong preparations of calabar bean, but on the repeated application of the latter, its disappearance is somewhat accelerated (*Graefe*).

The alcoholic extract of the calabar bean is the most useful and durable preparation. It is diluted with glycerine, in the proportion of one to thirty or fifty parts, and applied to the lower portion of the conjunctival sac with a camel's-hair brush.

Very recently filtering-paper saturated with the alcoholic tincture—calabar paper—has been used. One or more quadrants are placed between the lower lid and the globe, in order to get a myotic effect. This paper does not act as certainly as the glycerine solution.

Physostigmine and its salts are exceedingly changeable and less useful in practice. This is to be regretted, since they do not irritate the conjunctiva. Physostigmine is described by *Jobst* and *Hesse* as an amorphous, yellowish-brown substance, not easily dissolving in cold water, but readily soluble in alcohol, benzine, etc. It readily forms salts with acids. These are of a dark-red color, rarely of a dark blue. Its effect passes off very quickly, although it is three times as great as that of the extract (*Vée*).

The extract is apt to cause a very marked, although very transitory irritation of the conjunctiva. Besides this the myosis and changes in accommodation are always accompanied by a painful sense of tension, partly along the equator of the globe, partly in the ciliary region; or there is a nervous pain in the whole globe, radiating along the supra-orbital nerves, like a kind of ciliary neurosis. The pain also extends itself, like hemicrania, over half the head, and is increased by any exercise of the accommodation (*Graefe*).

These irritating effects render the use of the calabar bean extract a very grave

matter, when there is any irritation on or in the eye. Calabar bean extract may also be recommended as a myotic, when there are peripheral corneal ulcers, which threaten to become perforating; in case of eccentric opacities of the cornea and of the capsule, as well as when the lens is luxated, for the purpose of improving the vision, by creating a stenopaic apparatus for the eye; in the operation of iridectomy, for the purpose of enlarging the surface of the iris, especially in glaucoma, when the iris is not yet degenerated; and also to favor the disappearance of mydriasis induced by atropine.

Calabar bean has not proved of use in insufficiency and paresis of the muscles of accommodation from internal causes, and in similar conditions of the external muscles it accomplishes nothing.

In order to fulfill the above-mentioned indications, the local application of weak solutions of the extract should be repeated daily. Caution should be observed, for the agent is a powerful poison. Indeed, when instillations have been made, very frequently symptoms of constitutional poisoning may occur, among which an extraordinary reflex excitability and paralysis of motion of the extremities are prominent (*Schelske*).

Large internal doses generally produce vomiting, a small weak pulse, cool skin, cold perspiration, extreme prostration, and death by paralysis of the expiratory muscles. The proper antidote is the speedy employment of hypodermic injections of a solution of atropine about 1-40 to 1-30 of a grain.

10. *Irritants.*—These have a very extended use in the treatment of external inflammation of the eye and its results. In order to accomplish their object, they must act directly upon the affected organ. The irritation which they set up in the sensory nerves being carried over to the vaso-motory nerves, may cause a contraction of the caliber of the vessels when they are in a condition of relaxation. This is done by the excitation and invigoration of the atonic muscular fiber.

Thus, resolution of the inflammation is favored by the lessening or removal of the congestion, which is one of the causes of an unfavorable course. Added to this the agent acts upon the proliferating tissue itself. This effect may change the character and lessen the degree of the inflammation, when the conditions are appropriate. It may serve also to alter morbid secretions, and to excite the prostrate curative action, and to hasten the tardy reparation of losses of substance. Frequently such an artificial irritation becomes useful by bringing with it an active flow of blood and favoring assimilation. It thus has a favorable influence on the retrocession and absorption of old inflammatory products. The speedier change in the epithelial layers which is connected with the irritation is not unimportant. This consists in the more abundant throwing off of the morbid layers, and their replacement by new ones, which are formed under more favorable conditions, and possibly in a manner more corresponding to the normal process. In certain cases of exceedingly luxuriant production [of these layers], it is not only an advantage to increase the separation of the superficial strata in this way, but also to act somewhat on them by a chemical destruction—that is by the caustic effect.

Finally, some of the irritants do service by chemically acting on certain morbid secretions, and depriving them of the harmful influence which they may exercise upon the nutrition of the inflamed parts in contact with them. The use of irritating agents, of course, has no good object, but is rather harmful and contra-indicated, when there is an inflammation existing, having a sthenic character. Such an inflammation is indicated by a lively red injection, tense swelling and heat of the part, together with symptoms of nervous irritation. The same is true where there is severe

ciliary irritation, the increase of which causes us to fear an affection of the inner parts of the eyeball.

Inasmuch as the irritative conditions in inflammations frequently vary in degree, and may be temporarily excited or increased, by many fortuitous internal and external irritations, it is necessary to take the precaution of testing exactly the condition of the part before each application of an irritant. It should be ventured upon only when the condition shows that an increase of irritation will be salutary. In properly estimating the amount of irritation, it is necessary to exclude everything which may influence the effect of the agent used. The reaction caused by irritants applied to the eye is apt to be far greater after the night's rest, after meals, and after exciting bodily and mental exertion, than at other times. Generally speaking, the morning, from one to three hours after rising, is the best time for the application, when it is made once a day. The number of irritants which may be used is very large. We may divide them, according to the method of application and the kind of effect which they produce, into:—

Irritating powders,
Irritating ointments,
Astringent eye-washes, and
Astringent caustics.

Calomel stands first among the powders; it is a very mild irritant when properly used. It appears to act mechanically, as well as chemically, when in contact with the chloride of sodium of the tears. It is dusted into the conjunctival sac by snapping it from a camel's-hair brush.

In using calomel with young children that struggle very much, it is advisable to be in a sitting position. The head of the child is held between the knees of the surgeon, and while the eye is held open with the fingers of one hand, the calomel is dusted in with the other. We should take special care that none but the finest powder, and no lumps, enter the conjunctival sac. The latter act exactly as foreign bodies, and in case they remain, are changed by the chloride of sodium of the tears into the corrosive chloride of mercury; they are then extremely irritating, and occasionally actually cauterize the conjunctiva. As a further precaution, it is well not to evert the lower lid, and thus expose the palpebral fold during the dusting in of the calomel. Quite a large quantity may lie in the palpebral fold and cause no unpleasant sensation at first, but remain unnoticed until a severe irritation or actual cauterization has occurred. Where considerable irritation is seen some time after the application, the conjunctival sac should be carefully examined, and be cleaned of any remains of the powder by wiping it out. The introduction of large quantities cannot be sufficiently guarded against; it is sufficient when a frosty-looking coating appears on the conjunctiva and cornea. The brush should therefore be freed from the rough particles before it is used. There are some other powders much less reliable but more irritating, which have been blown into the conjunctival sac through a quill. Their use has been given up to some extent, and is not advisable. They are, dehydrated clay, silicious earth, besides sugar, alum, borax, common salt, flowers of zinc, cream of tartar, crab's eye, cuttlefish bone, glass, pumice stone, tin-filings, aloes, etc. These were used in the finest powder, either pure or in mixtures of various kinds.

Irritating ointments also act very powerfully and are very useful; they are introduced into the lower palpebral fold with a camel's-hair brush, and then, the lids being closed, the ointment is distributed over the conjunctiva, by gently rubbing them with the finger. A great variety of agents are used as the efficacious part of these ointments. The *amorphous yellow oxide of mercury* stands high in respect to the certainty and regularity of its effect. One to three grains are mixed with a drachm of lard, simple cerate, fresh butter, or cocoa butter. The commercial *hydrarg. præcipitatus ruber*, one to two grains, *hydrarg. præcipitatus albus*, one to four

grains, *oxide of zinc*, three grains, *iodide of potassium*, two to four grains, and pure *iodine*, one-eighth of a grain to the drachm of the vehicle, respectively, are also used, but do not answer as well.

The amorphous yellow oxide of mercury, called *bioxyde de mercur hydraté* by the French, is obtained by precipitation from a solution of the bichloride made by means of caustic potash. It is essentially nothing more than the officinal red precipitate, but it has the advantage over this, that it is much more finely divided, it mixes more intimately, thoroughly, and evenly with the vehicle, and thus allows a more exact measurement of its effect. If the ordinary red precipitate be carefully triturated as the pharmacopœia directs, it is not inferior to the amorphous yellow oxide, and does not have a red color, but is a bright orange-yellow. The extremely irregular effects which the formerly so much esteemed red precipitate produced in ophthalmic practice, are to be entirely ascribed to the careless preparation of the agent.

Ointments of one part of the yellow amorphous oxide of mercury to eight parts of fat, as they have recently been recommended (*Pagenstecher*), act too severely, and require subsequent cleansing of the conjunctival sac. The amorphous yellow oxide has one unpleasant property, and that is, it readily decomposes when exposed to the light; therefore it should be carefully protected and frequently renewed. The ointment should be thoroughly rubbed up, so that one part does not act more powerfully than the other. Recently, instead of the fat, a mixture of one part of starch with five parts of glycerine has been used. By soaking the former in glycerine heated up to 70° R. [about 190° F.], the mixture attains the consistency of fat. It does not become rancid like fat, however, which then does harm and decomposes the preparation. Most of the agents used in eye-salves are readily soluble in glycerine. Besides, the glycerine itself deliquesces in the tears, and the medicaments enveloped in it are more easily distributed throughout the whole conjunctival sac, and thus are more certainly taken up, than when applied in the ointments made with fat, which the moist conjunctiva, as it were, throws off. Therefore, glycerine ointments containing the same amount of the active substance have almost double the effect of the others. The glycerine used should be chemically pure, perfectly colorless, and as clear as water (*Graefe*).

Closely allied to the ointments are the fats, popularly known as eye-salves—eel's oil, serpent's fat, bear's fat, etc. These cannot be had fresh every day, are therefore generally rancid, and act as irritants through the free fat acids.

A great number of substances are used as astringent eye-lotions. The most useful are: sulphate of zinc, sulphate of copper, sulphate of cadmium, alum, nitrate of silver, corrosive chloride of mercury, acetate of lead, tincture of opium, and tannin. To this list may be added the *lapis divinus*, which, as is well known, consists of *sulph. cup., nitri puri, alum crud.*, *āā* ℥ j.; *camphoræ*, ʒ ss. Besides, common salt (*Ruv*), and sesquichloride of iron (*Follin*), are used. It is usual to write for a grain of sulphate of zinc, sulphate of copper, sulphate of cadmium, crude alum, lap. divin., to the ounce of water, and half a grain of nitrate of silver, a quarter of a grain of the corrosive chloride of mercury, four grains of acetate of lead, two to four grains of salt, or the sesquichloride of iron, ten grains of tannin to the same quantity, and of tincture opium, half a drachm to the ounce.

The solutions in this list are equally efficacious, and it is all the same, in this respect, whether we use one or the other. Recent experiments on rabbits (*Prosoroff*) confirm this opinion. These show that the agents used in the form of collyria, all act irritatingly on the conjunctiva, and cause, according to the strength of the solution, either a hyperæmia, or an abundant nuclear formation, or, finally, the development of pus-corpuscles; furthermore, that the time during which the formation of pus lasts before giving place to the nuclear formation, and passing over through a simple hyperæmia to a normal condition, also depends on the strength of the solution; and that, when the most different of these agents are used, in the same strength, the same effect is produced.

The acetate of lead and corrosive chloride of mercury are least to be recommended, on

account of their great liability to decomposition. Sugar of lead is, besides, dangerous, when there are ulcers on the cornea or conjunctiva, since it readily forms a deposit on their floor. This becomes encapsulated, and causes various evil results. Nitrate of silver and sesquichloride of iron cause stains in clothing which are not easily removed. Tincture of opium readily forms a sediment, and, therefore, acts unequally. The sulphates, especially the sulphate of zinc, should therefore have the preference in catarrhal inflammation, especially if the results of some recent experiments should be confirmed, according to which, sulphate of zinc contracts the vessels more powerfully than any other agent except cold.

Pure distilled water is generally used as a menstruum. We may also use slightly aromatic vehicles, such as *Aq. Rosarum*, *Tiliæ*, *Sambuci*, *Euphrasiæ*, etc. Very odorous, ethereal fluids should always be avoided, since their irritative effect is too prominent. They will not be generally borne. If we wish to give a strong odor to our eye-wash, a mixture of *aqua laurocerasi* (cherry-laurel water) f. ʒ ss. to f. ℥ ij. of the collyrium is most to be recommended. We should never prescribe more than two ounces of a collyrium, and with proper use one ounce is generally enough.

Chlorine water, *Aq. chlori*, which is produced by the conduction of chlorine gas through distilled water to saturation, is used. It is said of it, though having an equally powerful effect as an alterative and astringent, that it is far behind the metallic astringents in its irritative power, and is therefore a substitute for the others, to be recommended in very irritable eyes. Besides, it may be used with good effect as a disinfectant against the harmful influence of certain secretions upon the conjunctiva and cornea (*Graefe*). Its results in these cases, however, hardly answer the expectations excited.

If a powerful effect of the collyria is wished for, they should act upon the affected part for a quarter or half a minute.

It is, also, not sufficient that the agent come in contact with one half of the conjunctival sac, or with the portion about the palpebral fissure; therefore the patient, for the purpose of allowing the instillation, should lie down and turn the face a little toward the opposite side from the one in which the eye-wash is to be dropped. In this position a sufficient quantity of the eye-wash can lie in the *fossa angularis* without running off. If the lids are then drawn a little away from the globe, while the patient looks up and then down, the collyrium enters not only the upper, but also in the lower palpebral fold, and the complete effect is secured. At the same time it depends upon the inclination of the surgeon whether the collyrium act for a longer or shorter time, and thus he may regulate the effect according to the requirements. Applications of little pledgets of linen, which have been dipped in the eye-lotion, are very unreliable in their effects, and are only practicable in insignificant affections, and in children, who react excessively to the instillations, which are always painful, and thus completely neutralize any benefit there may be in their use.

Still, under some circumstances, a method of application formerly much esteemed, but again abandoned, has proved itself useful in the case of small children. In this method, a bunch of charpie saturated with an astringent solution is placed immediately upon the closed lids; this is covered by a little cushion of fine cotton, and the whole fastened by an elastic bandage of the finest flannel.

Covering the saturated bunch of charpie with a small cushion of cotton has the effect of giving more elasticity to the bandage, and of making a more even pressure upon the part beneath. For the same reason, the bandage should be made of a very elastic material.

If we wish the bandage to accomplish its purpose, it should adhere firmly and immovably, without causing annoyance.

This requires great care in the application, and frequent examination, in order, if it has moved at all, to make the necessary change. Besides, the bandage should be changed often, in order to remove the pus collected under it, and to clean the eye, otherwise the secretion may become partially dry and change the bunch of charpie to a hard lump with an irregular surface, and thus cause an uneven pressure. The secretion may also become decomposed, and

affect the lids and neighboring parts chemically, increasing the inflammation. In abundant secretion, the renewal of the charpie four to five times a day will be sufficient; with less secretion a change of the bandage two or three times a day is quite enough. If, on taking off the bandage, the bunch of charpie is found dry, it should be softened by dropping on warm water. In order to delay the drying as much as possible, the charpie should be applied wringing wet; we should see to it that none of the medicament runs in the mouth, which may readily occur during the application of the bandage. For if poisoning is not to be feared as the result of this, it is still to be remembered that nitrate of silver has a very disagreeable taste, which is exceedingly hard to remove, and readily causes children to cry for a long time. We may most easily avoid this unpleasant accident by applying the bandage when the patient is in a recumbent position. With children, to this end, it is earnestly to be recommended that the surgeon manipulate in a sitting position, holding the head and back of the child between his knees.

Astringent Caustics.—Nitrate of silver and the sulphate of copper are almost exclusively used for this purpose. The *lapis infernalis* is sometimes employed in solutions of five to thirty grains to the ounce of water, sometimes in substance melted with nitrate of potash, as *nitras argenti mitigatus.* The blue vitriol is used in the form of crystals as large as possible, and with broad surfaces, which are smoothed off with a knife and file, and then rubbed with a damp cloth. Solutions of these agents in water and glycerine are less useful; one part of the agent to six to eight parts of the vehicle, as well as ointments of one scruple of the vitriol to an ounce of fat, are used (*Roser*, *Warlomont*).

The *lapis infernalis mitigatus* is prepared by melting together crystallized nitrate of silver and nitrate of potash, in equal quantities by weight, or in the proportion of one to two, and running it into sticks. Some oculists use mixtures of equal parts of nitrate of silver and gum arabic, as the mitigated lapis. In order to prevent deliquescence by the light, and the decomposition of the mixture, as well as to give more firmness to the sticks, it is well to give them a thin coating of some substance, for example of flour, and then to cover this with collodion.

Where the chief requirement is to cause an astringent effect, and to chemically act upon any existing morbid conjunctival secretion, but a severe cauterant effect is not desired, or a great increase in irritation appears to be a serious matter, solutions of nitrate of silver, five grains to an ounce of water, are indicated. The sulphate of copper has also slight caustic power, but it is a powerful astringent and irritant. It is therefore especially appropriate in a torpid character of the affection, unaccompanied by irritation, with great relaxation of the parts. Where, however, there is a prominent indication for the destruction of superficial exuberant proliferating layers, solutions of nitrate of silver, from ten to thirty grains to the ounce of water, according to the effect desired, are to be advised, or the mitigated nitrate of silver, which far exceeds the former as a caustic. Where, however, the regular application of the nitrate of silver by the surgeon is impossible, from some reason or other, and it must be left to the patient or the nurse, the ointment of the sulphate of copper, or the glycerine solution is a convenient substitute. Pure nitrate of silver can only be used without danger in certain diseases of the integument of the lids, and of the lachrymal passages. In conjunctival affections and those of the globe, its use is to be strictly avoided under all circumstances. It dissolves too readily in the tears, and is thus easily diffused. It is difficult, therefore, to estimate the depth and extent of its effect. Very bad cicatrices may occur from its use, even when no great amount of carelessness attended it.

Besides this, the mitigated nitrate of silver renders the pure unnecessary. It is equally as

powerful a caustic, and as great an effect as is desired may be attained. It has still an advantage, that its effect may be very accurately estimated, it being less soluble in the lachrymal solution. It is somewhat similar with crystallized sulphate of copper. It is its slighter solubility which gives it the preference over the crystalline masses or uncrystallized powder. If these latter preparations of sulphate of copper come in contact with the conjunctiva, they dissolve almost immediately in the tears, and the concentrated solution thus made is distributed everywhere. The result is generally a severe irritation over a large space, with all its consequences. Crystalline masses also become rough, even during the cauterization, on account of their great solubility, and thus cause parenchymatous hemorrhage. Therefore, crystals of sulphate of copper in which crumbling spots are to be found should not be used.

The very powerful action of the means in question renders the greatest care necessary in their employment, in order that the effect be not too severe, and especially that the caustic be not applied to parts which do not need cauterization. Especially in affections of the conjunctiva, we frequently wish to preserve the corneal and scleral portion of the conjunctiva from contact. For this purpose, the palpebral conjunctiva and the palpebral fold should be exposed by an eversion of both lids. It is then to be painted either with a camel's-hair brush dipped in the solution, or touched with the caustic in substance, more or less, according to the indications.

There is no difficulty in everting the lower lid. When this has been done, the lower palpebral fold may be easily brought into view by causing the patient to look upward. In order to be able to easily evert the upper lid, we tell the patient to open his eyes, and we seize the lashes, draw down the lid in an oblique direction away from the globe, and then we press down the convex tarsal border, which lies 4''' over the edge of the lid, with a thin stick, a delicate key, or the little finger, while at the same time the edge of the lid is lifted up. One who is practiced in this will readily hold both lids everted, when the patient is told to press them together by contraction of the orbicularis muscle. The palpebral fissure is closed by pressing forward the two puffed-out folds, so that the anterior half of the conjunctival sac is, as it were, cut off from the posterior.

Fig. 1.

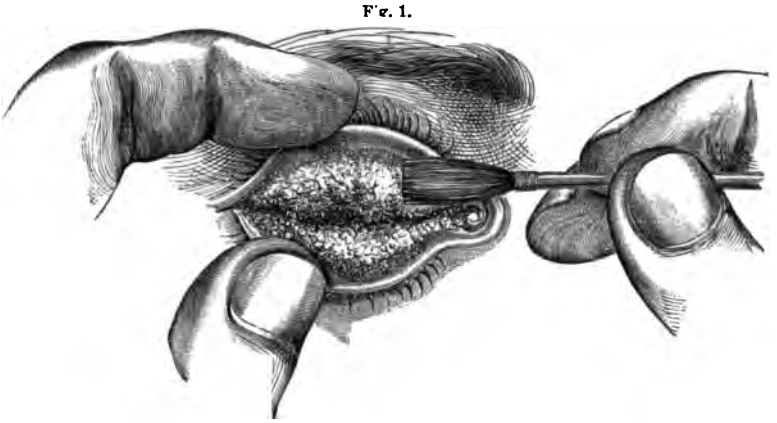

Those less practiced in this manipulation must be satisfied with everting one lid after the other, causing the patient to look in the opposite direction, and to close the eye.

In order, after replacement of the lids, to prevent undissolved portions from touching and cauterizing the scleral conjunctiva and the cornea, it is necessary to first wash away the excess of it with a camel's-hair brush dipped in water. This is

especially necessary when stronger solutions of *argent. nit.*, or the mitigated stick, are used; still, even in weaker solutions the neglect of this precaution is not entirely without danger.

A neutralization of the excess by penciling the cauterized portion with a solution of common salt is superfluous, but was formerly generally recommended. Cauterizations with crystals of sulphate of copper only require a wiping off of the excess, when there is some disposition to severe irritation. The fluid running off in making an application to the eyes injures the clothing and furniture very much. In order to prevent this, a piece of oiled muslin bound about the neck of the patient, and reaching to the knees, becomes very useful. The surgeon protects himself best by an apron.

Dusting irritating powders in the eye should only be done once or twice during the day: the irritative ointments should never be used but once a day. On the contrary, the weak astringent collyria may be used twice or three times a day, and even oftener, according to the desired effect, and the sensitiveness of the part. The astringent caustics are never to be applied but once a day, and even in those cases where a very powerful cauterization is not desired, or when the reaction following is very considerable, they should only be repeated after the lapse of two or more days. A slight irritation always follows the use, even of the weaker of these agents. This is even *necessary* in order that their effects may be developed. If it remains within the bounds of moderation, and if it passes rapidly over, it is not to be resisted. If, on the contrary, it becomes annoying by severe nervous symptoms, or the reaction is serious from the degree and duration of the vascular symptoms, the use of cold applications until they are overcome is indicated.

After cauterization, it is, under all circumstances, advisable to use cold applications, since we then wish to favor the throwing off of the slough. If the part has been severely cauterized, or if the patient is very sensitive and subject to inflammations, the throwing off of the slough, which generally follows within one to two hours, should be carefully observed. It not unfrequently occurs that portions of the slough only partly detach themselves, roll up in the act of winking, and then, as foreign bodies, irritate excessively. We may readily guard against this, by separating the loosely hanging eschar by a camel's-hair brush, or a piece of fine linen.

Special attention should also be paid, after a cauterization, to the adhesion of some parts of the palpebral fold, which not unfrequently occurs. If the parts be severely cauterized, excoriated surfaces come in contact after the throwing off of the slough, and finally completely adhere, so that the conjunctiva is considerably shortened. If such an adhesion is discovered, it should be immediately separated by the finger-nail, or by something similar. We should afterwards frequently examine it, to see that the adhesion has not again occurred. In this way it is easy to prevent the adhesion. If the reaction after appropriate and careful use of the irritant be excessive, and if, in the course of some hours after the use of antiphlogistic means, it does not yield, the agent is too severe. We should then not repeat the application, but after the reaction has been subdued, we should begin with a weaker preparation, and in case of necessity, pass on gradually to the stronger.

In America a mixture of tannin with glycerine is very much thought of by some, as an application to the lids in trachoma. [The tannic acid is mixed with glycerine in the proportions of from ten to sixty grains to the drachm of glycerine.]

Very recently astringent pastes are also used (*Heymann*). From one-half to one drachm of the salts that have been named is rubbed up with the cooked white of an egg and mixed

with two scruples of glycerine. The paste thus made is spread on linen and laid upon the closed lids. Solutions, especially tannin, are used on the conjunctiva by means of a nebulizer (*Heymann*, *Cyr*).

Authorities.—*Hemodynamic Conditions: Mayrhofer*, Zeitschrift der Wien. Aerzte. 1860. S. 737, 739.—*Dor*, kl. Monatbl. 1865. S. 351; A. f. O. XIV. 1. S. 13.—*Monnik*, according to Snellen, kl. Monatbl. 1868. S. 363.—*Stellwag*, der intraoc. Druck. Wien. 1868. S. 10, 17, 20–34, 63, 75 et seq. 86 et seq.; Ophthalmologie. I. S. 313, No. 40; S. 314–318.—*Graefe*, A. f. O. I. 1. S. 306–313, 382–390; III. 2. S. 426, 432–437, 456; XII. 2. S. 207–211, 256–259; VII. 2. S. 29; kl. Monatbl. 1868. S. 212, 401.—*Bouchut*, Gaz. med. de Paris, 1868. P. 695.—*Hippel*, *Grünhagen*, A. f. O. XIV. 3. S. 219, 221–258; XV. 1. S. 265, 273, 282, 284; kl. Monatbl. 1868. S. 384.—*Memorsky*, A. f. O. XII. 2. S. 79, 112.—*Donders*, A. f. O. 1. 2. S. 75–103; kl. Monatbl. 1864. S. 434; Anomalien d. Acc. u. Refr. Wien, 1866. S. 486, 489, 490.—*Vierordt*, *Laiblin*, Diss. Die Wahrnehmung der chorioid. Gefässe. Tübingen, 1856. S. 14.—*Berthold*, Ref. Wien. med. Presse 1867. S. 467.—*Pope*, A. f. O. I. 1. S. 77.—*Kussmaul*, Diss. Untersuchungen etc. Würzburg. 1855. S. 12, 18, 25, 27, 40.—*Trautvetter*, A. f. O. XII. 1. S. 95, 119, 131, 132.—*Weber*, kl. Monatbl. 1868. S. 395–399.—*O. Becker*, Wien. med. Jahrb. 1863. S. 159, 170; 1864. S. 3.—*Mauthner*, Lehrb. d. Ophthscop. Wien. 1868. S. 339, 340.—*Wegner*, A. f. O. XII. 2. S. 10–21.—*Cl. Bernard*, A. f. O. XII. 2. S. 18; according to Landois, Eulenburg, Wien. med. Wochensch. 1867. S. 1010, 1025, 1073; Compt. rend. LV. S. 382; according to Donders, Anomalien, S. 491; according to Salkowski, Zeitschr. f. rat. Med. XXIX. S. 169.—*Adamük*, kl. Monatbl. 1868. S. 386, 390, 392; Sitzungsber. d. Wien. Akad. d. Wissensch. LIX. S. 1–16; Centralbl. 1866. S. 562; 1867. S. 434; Annal. d'oculi. LVIII. S. 8.—*Eulenburg*, *Landois*, Wien. med. Wochenschr. 1867. S. 1074, 1140.—*Staub*, ibid. S. 1140.—*Griesinger*, ibid.—*Mannhardt*, kl. Monatbl. 1866. S. 18.—*Testelin*, Canstatt's Jahresber. 1866. II. 2. S. 447.—*Schiff*, Untersuchungen zur Phys. d. Nervensyst. Frankfurt, 1855. S. 20–198; Zeitschr. f. rat. Med. XXIX. S. 217; according to Eulenburg, Landois, l. c. S. 1075.—*Salkowski*, Zeitschr. f. rat. Med. XXIX. S. 167–190; Centralbl. 1867. S. 487.—*Budge*, according to Eulenburg, Landois, Wien. med. Wochenschrift 1867. S. 1009; Die Bewegung der Iris. Braunschweig, 1855. S. 90–178.—*C. Krause*, Handb. d. Anat. 2. Aufl. 1. S. 526.—*H. Müller*, Würzburger Verhandl. X. S. 179.—*Schweigger*, A. f. O. V. 2. S. 216.—*Saemisch*, Beitr. z. phys. und path. Anat. d. Auges. Leipzig, 1862. S. 26.—*Eulenburg*, *Guttmann*, Arch. f. Psychiatrie u. Nervenkrankheiten, I. S. 420, 425 et seq.—*Oyle*, Lancet, 1869. I. S. 461.—*Petit*, *Biffi*, according to Budge, Bewegung der Iris. Braunschweig, 1855. S. 105, 107.—*Arlt*, *jun.*, A. f. O. XV. 1. S. 305, 313.—*R. Wagner*, Würzburg. Verhandl. X. S. XI–XIII.—*Deiters*, according to Rüdiger, Anat. d. menschl. Gehirnnerven. München, 1868. S. 19.—*Remak*, Deutsche Klinik, 1864. S. 159.—*Prevost*, *Jolyet*, Zeitschr. f. rat. Med. XXXII. S. 605.—*Büttner*, ibid. XV. S. 254, 268, 271.—*G. Meissner*, ibid. XXIX. S. 96, 101.—*Heymann*, kl. Monatbl. 1863. S. 204.—*Stanley*, *Alison*, etc., according to Schiff, Untersuchungen, etc. S. 97 et seq.—*Power*, Virchow's Jahresber. 1868. II. S. 478.—*Junge*, A. f. O. V. 2. S. 191.—*Rothmund*, Deutsche Klinik. 1867. No. 24.—*Geissler*, Schmidt's Jahrb. 136. Bd. S. 74.—*Steffan*, kl. Erfahrungen u. Stud. Erlangen, 1869. S. 37, 38, 41, 44.—*Magendie*, u. A. according to Budge, d. Beweg. d. Iris. S. 93, 97.—*Winther*, Experimentaluntersuchungen über d. Path. d. Flügelfelles. Erlangen, 1866. S. 33–48.—*Samuel*, according to Winther, l. c. S. 42; according to Eulenburg, Landois, l. c. S. 1075.—*Mooren*. ophth. Beobachtungen. Berlin, 1867. S. 101.—*Snellen*, Arch. f. path. Anat. XIII. S. 107; Jarl. Verslag. IV. S. 191. kl. Monatbl. 1864. S. 242.—*Snellen*, *Rosow*, Centralbl. 1867. S. 774.—*Knapp*, Canstatt's Jahresber. 1863. III. S. 107.—*Danielssen*, *Esmarch*, *Baerensprung*, according to Steffan, kl. Erfahrungen, S. 37, 38.—*Charcot*, *Cotard*, Centralblatt. 1866. S. 360.—*Naumann*, Prag. Vierteljahrschrift, 77. Bd. S. 1, 13; 93. Bd. S. 133, 143, 151.—*Lowen*, Centralbl. 1867. S. 56.—*Zülzer*, Deutsche Klinik, 1865. S. 127.—*Voelckers*, *Hensen*, Experimentaluntersuchung, etc. Kiel. 1868. S. 24; Centralbl. 1866. S. 722.—*Coccius*, d. Mechanismus d. Accomod. Leipzig, 1868. S. 74.—*Förster*, kl. Monatbl. 1864. S. 368, 373.—*Cramer*, Het accomodatievermogen. Harlem, 1853. S. 87.—*Bezold*, *Ludwig*, *Théry*, according to Hippel, Grünhagen, A. f. O. XV. 1. S. 266.—*Bezold*, *Goetz*, *Bloebaum*, according to Hippel, Grünhagen, l. c.; Centralbl. 1866. S. 599; 1867. S. 241, 564.—*Klebs*, Virchow's Archiv, XX. S. 346.—*Leber*, Denkschriften d. Wien. k. Akad. d. Wiss. 24 Bd. S. 310.—*Roosa*, Peculiar form of Conjunctival Disease, Transactions American Ophth. Soc., 7th year.

Causal Indication: Graefe, A. f. O. IX. 2. S. 111.—*Stavenhagen*, klin. Beobachtgn. Riga, 1868. S. 75.—*H. Cohn*, Berlin. kl. Wochenschr. 1868. Nr. 8.; kl. Monatbl. 1868. S. 293.—*Aubert*, A. f. O. III. 2. S. 38—*Heymann*, *Sussdorf*, Sitzungsber. d. Gesell. f. Natur- u. Heilkd. z. Dresden. 1867. S. 42, 45.—*Jansen*, *Follin*, Arch. gén. de méd. 1861. II. S. 26.—*Virchow*, Handbuch, I. Bd. 1854.—*Helmholtz*, phys. Optik, IX. S. 191.

Indicatio Morbi: Nussbaum, Aerztl. Intelligenzblatt 1865. Nr. 36.—*Feith*, Centralbl. 1867. S. 496.—*Achscharumow*, Archiv. f. Anat. u. Phys. 1866. S. 255, 281.—*Blodig*, Zeitschr. d. Wien. Aerzte. 1860. S. 673.

Mydriatics: Graefe, A. f. O. II. 2. S. 209; VII. 2. S. 29; IX. 2. S. 70; IX. 3. S. 117; X. 2. S. 200; XIV. 2. S. 117; Deutsche Klinik, 1861, Nr. 29.—*Grünhagen*, Archiv. f. path. Anat. XXX. S. 514; Zeitschr. f. rat. Med XXIX. S. 4, 21, 275, 284.—*Ruiter*, A. f. O. IX. 3. S. 117.—*Bernstein*, Zeitschr. f. rat. Med. XXIX. S. 36.—Rogow, ibid. S. 15, 18-19, 31.—*Ruete*, klin. Beiträge. Braunschweig, 1843, S. 250.—*Donders*, Anomalien der Ref. u. Acc. Wien. 1866. S. 493, 497, 498, 520, 521; klin. Monatbl. 1891. S. 414.—*Biffi*, *Cramer*, Het accomodatievermogen. S. 127.—*Budge*, Bewegung d. Iris. S. 182.—*Bernstein*, *Dogiel*, Centralbl. 1866, S. 453.—*Fraas*, Arch. f. path. Anat. VI. S. 231.—*L. v. Praag*, ibid. S. 438.—*Lombe Atthil*, Gaz. méd. de Paris. 1862. Nr. 37.—*Braun*, A. f. O. V. 2. S. 112.—*Schur*, Zeitschr. f. rat. Med. XXXI. S. 373, 396.—*Stellwag*, der intraoc. Druck. S. 56. et seq. 71.—*Meuriot*, Centralbl. 1868. S. 378.—*Fraser*, On the phys. action of the Calabar Bean. Edinburgh, 1867. S. 67.—*Bezold*, *Bloebaum*, Centralbl. 1867, S. 564.—*Schneller*, A. f. O. III. 2. S. 154, 156.—Mooren. Ueber sympath. Gesichtstörungen, Berlin, 1869. S. 21, 42.—*Hasket Derby*, Transact. of the Amer. Ophth. Soc. 1869, S. 35.—*Hippel*, *Grünhagen*, A. f. O. XIV. 3. S. 235.—*Coccius*, Mechanismus d. Accomod. Leipzig, 1868, S. 109, 110.—*Lawson*, Schmidt's Jahrb. 136. Bd. S. 317.—*Sichel*, Klin. Monatbl. 1868, S. 211.—*Schroff*, Lehrb. d. Pharmacologie. Wien. 1869, S. 515.—*Streatfield*, kl. Monatbl. 1863, S. 83.—*Homberger*, ibid. 1864, S. 215.—*Dobrowolsky*, ibid. 1868. Beilage, S. 119.—*Benjamin Bell*, according to Graefe, A. f. O. IX. 2. S. 70.—*Buttles*, The Med. Record, 1868, III. S. 267.—*Erlenmeyer*, Berliner kl. Wochenschr. 1866, Nr. 2.—*A. Weber*, A. f. O. VII. 1. S. 51.—*Schmid*, kl. Monatbl. 1864, S. 158.—*Liebreich*, *Graefe*, *Donders*, kl. Monatbl. 1864, S. 411.—*Leach Harry*, Med. Times, 1865, vol. II. S. 784—*Lopez* and *Lee*, Pharmaceut. Centralhalle f. Deutschl. 1862, Nr. 61.—*Camus*, Gaz. hebd. 1865, Nr. 32.

FIRST SECTION.

INFLAMMATION OF THE CORNEA.—KERATITIS.

Anatomy.—The cornea is essentially composed of modified connective tissue. Like this, it consists of a fibrous fundamental material, with numerous cells lying in it. On boiling no gelatine is produced, but a gelatinous substance resembling chondrin (*Burns*).

The fundamental substance (Fig. 2, *a*) is composed of the finest fibrillæ, which are distinguished from the ordinary connective-tissue fibers by their more tortuous course and great refractive power; at the edge of the cornea these connective-tissue fibrillæ run immediately into the fibrous elements of the conjunctiva and sclerotica, becoming transformed, as it were, into these tissues.

Fig. 2.

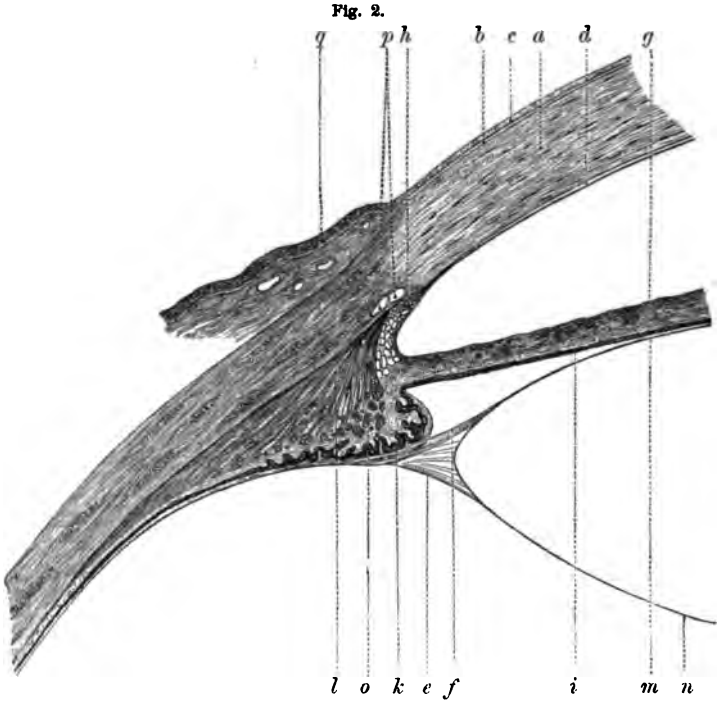

The corneal fibrillæ, by lying closely together, become very transparent, smooth, and broad fibers, and these again are formed into lamellæ, which may be traced through the greater parts of the cornea, and which, on a vertical section, give it a laminated appearance. These layers, or laminæ, usually lie parallel to the surface and to each other, but here and there they unite at an acute angle. The fibers of two layers usually cross at a right angle. The union of the fibrillæ into fibers and lamellæ, as well as of the latter to form the whole structure, is effected by means of a cement-like material, which penetrates the whole structure. This mate-

rial is not very consistent, however, is almost fluid, and refracts the light as strongly as the fibrillæ (*Henle, Engelmann, C. F. Müller, Classen*).

The corneal corpuscles lie regularly distributed at an even distance from each other, between the lamellæ. These corpuscles are cells lying vertically to the corneal surface. Sometimes they are flat, again fusiform, and again of the shape of a pea, with sharp angles, having a vesicular nucleus and a homogeneous protoplasm, granularless in structure.

A number of processes pass off from these cells, especially from the angles. These processes branch off like those of a tree. They penetrate the fundamental substance in all directions. Some of them remain in the same inter-lamellar space, others perforate the layer above or beneath them, and end in a free extremity, or they are united with similar processes of the adjacent cells, or of the space between the layers, and thus become a net-work extending through the whole cornea. The stellate cells may be separated from the base substance by certain chemical processes; but it is denied by almost all authorities that they have any peculiar membrane.

Besides these fixed corneal corpuscles, a varying number of small cells, identical with lymph-corpuscles, are found scattered through the tissue (*Recklinghausen, Engelmann*). These constantly change their shape, and move with the greatest rapidity in various directions, and push the lamellæ and fibrillæ apart.

This movement in the cells led to the belief that they were peculiar canals for the transmission of nutrient fluid (*Recklinghausen, Cohnheim*). But such canals do not exist. The cells are enabled to change their position by means of the cement-like material, which permeates the whole corneal structure, which fills up the spaces left by the pushing forward of the cells, while the fibrillæ, which have been pressed apart, again close behind the cells (*Engelmann*). This capability of dividing up in this way, explains the peculiar lattice-work appearance seen on injecting the corneal substance (*Harpeck, Hartmann*).

In the most anterior layers of the cornea, which have the greater number of stellate corpuscles, the lamellæ become wider and intertwine more with each other. Therefore a vertical section through the striation thus caused takes a course more inclined to the surface; at the same time the density of the tissue increases anteriorly, the fibrillæ, which ascend in abrupt loops, become twisted and more and more tufted, and finally, with the aid of the cement-like material, change to a firm membranous structure, *b* (*Iwanoff, Engelmann*). This is more or less distinctly separated from the less dense tissue lying beneath, and is called Bowman's membrane, anterior boundary layer, sub-epithelial layer, and external basement membrane.

It varies very much in thickness, and is not unfrequently almost wanting; while in other cases it forms quite a thick layer of great transparency, and with considerable power of resisting chemical and pathological processes. It was therefore formerly considered by many to be a hyaline membrane. It is permeable to the wandering cells of the cornea (*Iwanoff*) and is perforated by numerous nerve trunks.

In front of Bowman's membrane lies the delicate, exceedingly transparent epithelium. *c*. Its deepest layer consists of cylinder-shaped, somewhat irregular cells, which are placed vertically to the surface. The most anterior layer bears the character of pavement epithelium. In the intermediate layers the elements show transition forms and become smoother the more anteriorly they lie (*Schalygen*). Between the peculiar superficial epithelial cells we find, especially in the cylindric layers, more rarely in the middle layers, and extremely seldom in the most anterior layers, small wandering cells which are in constant motion and change of shape (*Engelmann, Iwanoff*).

The posterior surface of the cornea is covered by the membrane of Descemet, *d*. It is also called Demour's membrane, inner basement membrane, or capsule of the aqueous humor. It has a layer of beautiful polygonal cells on the side adjacent to the anterior chamber. It is a hyaloid membrane, appearing perfectly structureless, transparent, quite firm, and so elastic that as soon as it is partially separated from the cornea it curls up anteriorly. On transverse section it exhibits a parallel striation, which indicates a lamellar formation.

Recently this lamellar formation is claimed to be proven, and the individual layers, like those of the corneal substance, are said to be composed of the finest fibrillæ. The fibrillæ are united by a cement (*Kitt*) which comes from the corneal substance. The fibrillæ diverge from each other at the edge of the membrane, pass in part into the sclerotica and partly into the suspensory ligament of the iris (*Tamanschef*).

Blood-vessels.—They are found, in great numbers, in the fœtal cornea. In Bowman's membrane they form quite a thick net-work, which, however, does not seem to extend to the center of the cornea; toward the end of fœtal life and after birth these vessels contract and disappear. Only on the margin some remain, which lie under Bowman's membrane, and form one or more arches; besides these there are some capillaries from the sclera; they usually accompany nerves and form loops, but they are not constant. Lymphatics (*Teichmann*) are only found at the margin of the outer surface of the cornea, and probably belong to the conjunctiva (*Teichmann, Henle, Engelmann, C. F. Müller*).

Nerves.—The nerves of the cornea (*Cohnheim, Kölliker, Engelmann, Hoyer*) come in part from the conjunctival nerves (*Petermöller*), but they are chiefly terminal branches of the ciliary nerves. The conjunctival nerves pass directly from the limbus conjunctivalis into the cornea. The ciliary nerves pass, however, through the anterior portion of the sclerotica. The nerves, as soon as they have entered the corneal tissue, are without medulla, perfectly clear and transparent, and ramify extensively, especially in the most anterior layers, when they form a thick net-work immediately under Bowman's membrane. A part of the twigs pass backward, however, and are lost near the membrane of Descemet in a net-work formed of right-angled meshes (*Kölliker*). A portion of the twigs pass abruptly out from the anterior net-work, perforate Bowman's layer, and divide into fibers which radiate in all directions, interlacing with each other, and thus form a kind of structure in the epithelial layer. From this plexus numerous very fine filaments pass off anteriorly into the most anterior epithelial layers, where they disappear between the cells without any especial ending (*Kölliker, Engelmann*).

We can scarcely accept the view that they appear on the free surface of the corneal epithelium, or that their very fine extremities wave about in the fluid layer covering the cornea (*Cohnheim*).

Each of the fibers having a dark border is surrounded by a delicate nuclear sheath, closely attached to it. This becoming thinner and thinner, is continued upon the colorless fibers. The nuclei, which at first are very numerous, become less numerous as they pass from the corneal border. Finally we only find them in the angles of the mesh-work (*Engelmann*).

Senile changes.—As one of the symptoms of old age, analogous to the whitening of the hair, falling of the teeth, etc., may be noticed the arcus senilis, or *gerontoxon* of the cornea; which usually accompanies fatty degeneration of the muscles and blood-vessels of the eye, far-sightedness, and other signs of change in people over

fifty years old, but does occur even sooner in persons who have suffered from diseases deeply affecting the nutrition. In low grades it presents a superficial grayish or even tendinous opacity, which borders the upper and lower edges of the cornea, like two crescents. The process continuing, this opacity increases in density, extends deeper, even to Descemet's membrane; the crescents become broader and the horns extend till they meet. The senile arch forms a cloudy ring more distinct above and below; and the transparent part of the cornea is transversely oval. The inner border of the arcus senilis is always indistinct, but the peripheral is usually opaque and sharply defined. It does not touch the conjunctiva at its outer margin, but leaves outside of it a ring of clear cornea about half a line broad. The limbus conjunctivalis also appears cloudy, and as it is broader above and below than laterally, increases the impression that the cornea has a transversely elliptical form. The opacity is the outward expression of a previous fatty degeneration of the corneal vessels, and of a marked breaking up of the filamentary intercellular substance dependent on it.

In low degrees of development, *i. e.*, at the commencement, the corneal corpuscles particularly suffer. Subsequently the lamellæ, as well as the corneal bodies and their branches, seem to be strewn with numerous dusty-looking, fat-molecules, and the corneal substance itself appears remarkably dry and easily split into layers, so that a sort of filamentary formation becomes evident. These metamorphoses are most advanced in the superficial layers. The deeper we go, the less is seen of them. The epithelium and Bowman's membrane generally change but little. In great senescence, however, a very similar layer-like disposition of molecular fat has been seen in the bordering zone of the conjunctiva and sclera, and even in the ciliary muscle and processes, with atheromatous degeneration of the corresponding vessels.

In very marasmatic persons, the involution shows itself in other ways. The cornea often becomes decidedly smaller and thinner, and loses much of its tonicity, so that if, as a result of ulcerative perforation or operation, the aqueous escapes, the cornea sinks in, and numerous wrinkles appear on its surface, unless the lens and vitreous are driven forward by contraction of the muscles, and thus render it tense. This condition has a very serious influence on the healing process.

Dull, translucent, yellowish, or brownish groups of molecules, very indifferent to chemical action, exceptionally appear in senile corneæ. They lie both in the deep and superficial strata, and resemble the choloid deposits in the hyaloid membranes (*Wedl*).

Descemet's membrane, like the other hyaloid membranes of the eye, also changes in advanced age. It becomes somewhat thickened, and at the same time more friable, hence it forms folds with greater difficulty, and tears easily occur, sometimes superficially, sometimes running deeply, which would indicate a layer-like deposition of the hyaloid substance. Besides this, at the margin, we find warty deposits much increased, some of them even being pushed out to near the center of the free surface.

Nosology.—The inflammatory products of keratitis are chiefly produced by the great exudation of white blood-corpuscles (*Cohnheim*), but subsequently by their endogenetic multiplication (*Recklinghausen*, *Hofmann*), and by the proliferation of fixed cells (*Hofmann*, *Stricker*).

The exudation comes in part from the vessels of the swelled *limbus conjunctivalis*, in part from the dilated terminal loops of the scleral vessels. The formative cells which have passed in by the first-named way chiefly remain in the epithelial layer, while the others are collected in the true corneal tissue, but they occasionally permeate Bowman's layer, and run into that.

The cells proceeding from the *limbus conjunctivalis* at first collect chiefly in the most posterior epithelial layer. The cylindrical elements of this layer are pushed apart from each other, and finally are almost destroyed by proliferation (*Schalygen*) and fatty degeneration, so that for some distance between Bowman's layer and the epithelium, which is as yet little changed on the surface, we find a layer of formative cells. This layer varies very much in thickness, in some spots it is quite dense, subsequently a part of these cells gradually press forward into the superficial epithelial layers, involve this in the inflammatory process, and deprive it of its epithelial character by proliferation or fatty degeneration. We can then only distinguish a single layer of formative cells, whose uneven surface is covered by a thin layer of smooth cells which has many gaps in consequence of the loss of those cells which have been thrown off. A small portion of the formative cells may then, under certain circumstances, pass over into Bowman's layer and destroy its peculiar structure (*Iwanoff*).

The cells which pass off from the peripheral loops of the scleral vessels find a convenient way for their wandering in the soft cement which perforates all portions of the corneal substance. We meet them advancing from the corneal border to the inflammatory foci, collected in a constantly increasing quantity in and between the individual layers. At times they lie in fissures which have been made by the separation of the fibrillæ from each other. They appear arranged in parallel rows in this layer, but in the one above and below they unite almost at a right angle, and thus the whole appearance is that of lattice-work. In other places they are collected in more or less dense filaments, which having branches and anastomosing freely with each other, form a very irregular mesh which permeates the fundamental substance in every direction, and reminds one of the processes of the fixed corneal cells. There are, besides these, individual and irregularly grouped formative cells, which from their arrangement and stellar shape can only result from the proliferation of the fixed corneal corpuscles (*His*, *Classen*, *Wedl*). The closer we approach the center of the inflammatory mass, however, the more indistinct become the forms which have just been described. The greater number of the formative cells have no distinguishing marks. There is only a conglomeration of neo-plastic cells, in which we can no longer distinguish the fundamental substance, if it has not already been destroyed by fatty degeneration. If this inflammatory center lie near the surface, the formative cells collect in great numbers in front of as well as behind Bowman's membrane, and thus for some time form a sharp boundary-line between the two layers. But this membrane is soon destroyed also; the formative cells perforate it, destroy it in some parts, and thus the two neoplastic layers are brought in contact.

In exceptional cases the whole of the cornea may be changed by inflammation into a mass of proliferating cells, in which we can scarcely distinguish the normal elements. Generally, however, we have to deal with a more or less extensive mass with very indistinct borders, which is sometimes superficial and again deeply situated, while the remainder of the cornea either appears normal or is only slightly involved in the inflammation. The herpetic form of corneal disease is the only one that furnishes distinctly bounded inflammatory masses of a typical form.

The efflorescences of herpes are primarily spherical collections of formative cells, whose nuclei lie chiefly in the epithelial layers. The roundish base is presented anteriorly, while the apex perforates Bowman's membrane, and is continued into a swollen nerve-trunk, thickly surrounded by formative cells (*Iwanoff*).

Gradually a quantity of fluid intercellular substance is collected, which causes the scarcely altered epithelial layer to be pushed forward into a vesicle, or, what is more common, tears through it, and thus forms an almost circular excoriation with an infiltrated base. Later on, a number of cells wander into the surrounding tissue, involve this in the inflammatory process, the inflammatory mass becomes larger, loses its typical shape, at the same time numerous formative cells collect along the course of the affected nerves, above as well as beneath Bowman's membrane, and thus the herpetic efflorescences are combined with a true keratitis.

The further changes of the inflammatory process are exceedingly various.

1. The greater number or all of the wandering cells, or those newly formed by proliferation, often undergo fatty degeneration, together with the inter-cellular substance separated from them, which contains more or less fibrin; pus is formed in the true tissue of the cornea, which being soon involved, becomes opaque, soft, and is finally also destroyed, becoming a mass of fatty detritus. From the surface of the cornea such products soon fall, as the sub-epithelial layer is rapidly destroyed. The result is a more or less extensive ulcer. But within the cornea pus is retained for some time, where, so long as it is inclosed by corneal substance, it is called an abscess. The laminated structure of the cornea, then, not unfrequently allows a portion of the fluid-pus to pass between the lamellæ and collect in quite large quantities in the inter-lamellar spaces, near the corneal border, and thus an *onyx* is formed.

2. Just as often the inflammatory products go on to a higher degree of development.

The collection of formative cells which lie superficially are especially inclined to this. These are quickly divided into two layers, which are connected to each other by variously shaped processes, and are usually sharply defined from each other. The elements of the anterior layer become epithelial cells, while those of the posterior layer grow, and by a change into the fusiform shape as well as by a gradual formation of an intercellular substance which soon becomes striated, reminds us of connective tissue or true corneal substance. In this granulation layer vessels soon become evident, which proceed from those in the limbus conjunctivalis, and permeate the layer of neoplastic cells, always running towards the center, and finally form a net-work of large trunks. These are then continued in greatly dilated conjunctival veins.

It seems as if the blood at first ran in sharply bounded fissures between the elements of the granulation layer, for actual walls are not seen at an early period (*Iwanoff*). They then appear as branched tubes, which are closely covered by fusiform cells (*His*, *Niemetschek*) which under some circumstances may become a very dense adventitious membrane. The greater number and often even all of the neoplastic vessels run above Bowman's membrane, where this still exists. This membrane is frequently destroyed at an early period, however, at least some parts of it. Thus there ceases to be any boundary membrane for the vessels that run through the whole granular layer. The blood, which runs in vessels visible to the naked eye, must be considered as venous, in consonance with the nature of the emergent conjunctival trunks, although its color is a light red. This color is explained by the superficial situation of the vessels, which allows the oxidizing influence of the atmospheric air.

This appearance of blood-vessels is so marked, that for a long time it has been considered the indication of a peculiar form of corneal inflammation, *vascular keratitis*. The changes in the granulation layer which have been described are apt to increase with the duration of the disease. They are found most advanced, and are therefore most distinctly seen when a chronic inflammation has existed for a long time; especially when the irritation has been slight, and the condition has thus the character of *pannus*. Then the granulation layer is developed into true connective tissue, in which are found quite large vessels with dense adventitious tissue. Newly formed elements shut up in the true corneal tissue show, generally speaking, a much less tendency to higher development and the formation of blood-vessels, except when the layers affected have approached the surface by ulceration or traumatic loss of substance of the layers over them. Then true corneal substance usually develops from these newly-formed elements, which more or less completely fills the existing

void, and causes the ulcer to heal. The well-known and, in fact, wonderful power of regeneration of the cornea depends chiefly on this process. Under such circumstances, the above-described process repeats itself. The healing ulcer is covered, beginning from the periphery, with a mass of formative cells, which immediately changes into a stratum of epithelium, and a granulation layer (*Iwanoff*, *Schiess-Gemuseus.*)

Frequently the newly-formed epithelium as well as this replacing membrane are and remain transparent. Its similarity to the surrounding normal corneal layers is so great, that a distinction between the new and old is absolutely impossible, and the boundaries of the replacing tissue cannot be absolutely determined. More frequently, however, only the deeper layers attain the dignity of normal tissue; approaching the surface, the new formation becomes more and more opaque, and even resembles fibrous tissue.

The cause of this lies partly in the molecular turbidity of the neoplastic intercellular substance, but still more in the superficial accumulation of spindle-shaped cells, which appear thrown together in the most irregular forms, and in the outer layers so closely, that the intercellular substance almost disappears.

Very frequently in such a replacing tissue, permanent vessels are developed, and perhaps also nerves (*Gouvea*). The former are the few remains of the net-work previously existing in the granulation layer, and are almost always covered with an adventitious membrane.

In case the healing ulcer comes in immediate contact with true connective tissue, whether bordering on the *limbus conjunctivalis* or surrounding a prolapse of the iris, it not unfrequently occurs, that the superficial layers of the new formation take on the character of spongy granulations in a wound, and finally degenerate into true connective tissue, which is loose and quite vascular, and covered by a more or less thick layer of epithelial cells.

In some cases, inserted between the epithelium and the anterior membrana limitans, or lying wholly in the epithelium and dividing it into two layers (*Althof*), we find an extensive stratum of striated tissue which contains elongated nuclei, a large number of vessels, and choloid bodies grouped together. This neoplastic layer is not everywhere equally thick, but at some places swells out, at others shows depressions, into which the epithelium enters, or where it may be interrupted. These neoplasia have been particularly observed as a result of very tedious inflammation which has greatly affected the nutrition of the entire eye, as in very chronic irido-choroiditis progressing to atrophy, or where atrophy has already occurred, in chronic glaucoma of old persons, etc. But it is also said to occur in old pannus (*Donders*), and sometimes to cover corneal cicatrices (*Klebs*). Opinions vary as to the mode of occurrence of this deposit. Some believe that it proceeds from the limbus conjunctivalis, and depends on its superficial proliferation (*H. Müller*); others regard it as a product of Bowman's layer (*Klebs*), but its occurrence on the surface of cicatrices is against this view, for the formation of cicatrices presupposes ulceration, in the course of which the anterior membrana limitans is always destroyed.

3. The advance of the new elements to higher or even permanent formations is not absolute, even when the course of the keratitis is very slow; in many cases, after advancing even to a high point of organization, they retrograde when there is an arrest of the disturbance of nutrition. When the process has not advanced far and the production remains moderate, the new formations simply retrograde; but in other cases they become wholly or partially a soluble substance, such as fat, which is then removed by resorption. Frequently they wear away or shrivel up. In this state they may be found, after years, with fatty detritus collected in nests between the filaments. It appears as if they had not by shrivelling lost the power of blooming up and advancing again under favoring circumstances and a new impulse, or of unfolding any properties that recent cells and nuclei possess. These nests of retro-

graded cells and nuclei are the anatomical characteristics of certain corneal opacities (*Wedl*).

4. As regards the membrane of Descemet, there is no longer any doubt that it, like other hyaloid membranes, is capable of inflammation in a certain sense. In the cell layer belonging to it, at least the inflammatory process has certainly been shown to exist. This sometimes appears extended over the whole epithelial layer of the membrane of Descemet, and then causes a general opacity of the posterior surface of the cornea. Sometimes it is developed in small scattered masses in great luxuriance, and leads to the formation of groups of punctate or nodulated roundish deposits.

Sufficient investigations have not as yet been made as to the character of these neoplasia. Yet we may believe that they assume this or that elementary form in accordance with the character of the inflammation. Under some circumstances they may even deliquesce into pus, and become the same with the proliferation products of other cell layers. It is also probable that the products collected on the membrane of *Descemet* are not all of them, but that more or less of the exudation is thrown off by progressive proliferation, which clouds the aqueous humor and may contribute considerably to the formation of hypopyon. At any rate these nodules are not very adherent, for when the anterior chamber is opened they often pass out with the aqueous humor (*Hasner*).

Inflammation of the membrane of the aqueous humor, hydromeningitis, keratitis postica (*Hasner*), never occurs pure and independently, but is always combined with keratitis, which may appear in any form, but usually shows itself either by diffuse opacity of the cornea or deposits of its products in small, scattered points (keratitis punctata), and this again only occurs in company with chronic inflammation of the inner parts of the eye, which are very dangerous to the existence of the eye itself.

It has not yet been determined how far the substance of Descemet's membrane and the other hyaloid membranes actively participate in the inflammation. But it is certain that under the influence of neighboring foci of inflammation, they are gradually thinned, and the more delicate of them may be totally disintegrated. Still this process can hardly be referred to an inflammatory change of tissue. But, on the other hand, we not unfrequently find the thickenings and hyaline deposits, which occur particularly in the eyes of aged persons, along with the results or during the course of severe inflammations of neighboring parts (*Donders*, *Coccius*). Then by their decided softness they often prove that they are quite recent, and hence it is probable they originate from the inflammation. They have also been observed along with similar changes in the choroidal vessels in the course of Morbus Brightii (*H. Müller*). It however remains uncertain if the alterations do not depend on different processes in different cases, and whether they constantly possess the same morphological character.

5. The hemorrhages which occur in the degenerative processes in the eye, especially in severe irido-choroiditis, still deserve a special mention. They appear as red tufted masses, always, however, pressed from before backwards like a leaf. They seem attached to the border of the sclerotica by a short and usually thick peduncle, and lie in the true corneal substance. They usually last for a very short time, their sharply defined borders soon run together, and the blood is diffused and absorbed in the surrounding parts. A portion, however, is apt to sink downwards and then remain on the lower corneal border as an onyx-like ridge. It is sharply bounded above, and of a crescent shape. There are cases in which hemorrhagic onyx reaches the horizontal meridian of the cornea, or even passes beyond it and repeatedly increases and decreases in size. It seems that this condition has been usually confounded with hemorrhage into the anterior chamber.

Authorities: *Kölliker*, mikr. Anat. II. Leipzig, 1856, S. 608.—*Brücke*, Beschreibung des menschl. Augapfels, Berlin, 1847, S. 8.—*Henle*, Handbuch der Anat. Braunschweig, II. 1866, S. 590.—*His*, Beiträge zur Histol. d. Cornea, Basel, 1856; kl. Monatbl. 1863, S. 173.—*Classen*, Untersuchungen über die Histologie der Hornhaut, Rostock, 1858.—*J. Arnold*, die Bindehaut der Hornhaut, Heidelberg, 1860.—*Teichmann*, das Saugadersystem, Leipzig, 1861, S. 65.—*Recklinghausen*, Virchow's Archives, 27 Bd. S. 419.—*Reeken*, Ontleedkundig Onderzoek, v. d. Toestel v. acc. Utrecht, 1855, S. 29.—*Harpek*, Arch. für Anat. u. Phys., 1864, S. 222.—*Hartman*, ibid. S. 235.—*Leber*, Denkschriften der Wiener k. Akad. der Wiss. 24 Bd. S. 322; kl. Monatbl. 1866, S. 17.—*Kühne*, Canstatt's Jahresbericht, 1864, I. S. 74.—*Hoyer*, Arch. für Anat. u. Phys. 1866, S. 180.—*C. Ritter*, A. f. O. X. I. S. 63.—*Sämisch*, Beiträge zur norm. und path. Anat. des Auges, Leipzig, 1862, S. 1.—*Winther*, Experimentalstudien, etc., Erlangen, 1866, S. 5, 8-13.—Naturwiss. Zeitschr. Würzburg VI. 30. Juni, 1866.—*Classen*, A. f. O. XIII. 2. S. 453.—*Recklinghausen*, Virchow's Arch. 38. Bd. S. 157, 173, 180; according to Engelmann, über die Hornhaut des Auges, S. 2, 10.—*Burns*, Centralbl. 1867, S. 717.—*Engelmann*, Ueber die Hornhaut des Auges, Leipzig, 1867, S. 1-28 et seq.—*C. F. Müller*, Virchow's Archiv, 41. Bd. S. 110, 145.—*Cohnheim*, Virchow's Archiv, 38. Bd. S. 343; 39. Bd. S. 24; Centralbl. 1860, S. 353.—*Petermöller*, Zeitschr. f. rat. Med. 34. Bd. S. 88 et seq.

Senile Changes, Nosology: *J. Arnold*, l. c. S. 40, 43.—*Wedl*, Atlas Cornea, Sclera.—*His*, l. c. S. 73, 137.—*H. Müller*, A. f. O. II. 2 S. 48, 51, 64; Würzburger Verhandl. der phys.-med. Ges. 1856, 27 Dec.—*C. O. Weber*, Virchow's Archiv, XV. S. 475.—*Coccius*, Ueber die Neubildung von Glashäuten im m. Auge, Festrede, Leipzig, 1858; Ueber Glaucom. Entzündung, etc., Leipzig, 1859, S. 36.—*Schiess-Gemuseus*, Virchow's Arch. 27. Bd. S. 137.—*Althof*, A. f. O. VIII. 1 S. 126.—*Klebs*, ibid. XI. 2 S. 238.—*C. Ritter*, ibid. IV. 1 S. 355, VIII. 1 S. 85.—*Hasner*, kl. Vorträge, etc., Prag, 1860, S. 168.—*Stellwag*, Zeitsch. der Wiener Aerzte, 1852, II. S. 385; Ophth. I. S. 374.—*Donders*, A. f. O. III. 1 S. 150, 161.—*Graefe*, ibid. III. 2 S. 387.—*Junge*, Med. Centralzeitg. 27. Jahrg. S. 301.—*Cohnheim*, Virchow's Archiv, 39. Bd. S. 1 et seq.—*Recklinghausen*, *Hofmann*, Centralblatt, 1867, S. 481; 1868, S. 343.—*Schalygen*, l. c. S. 88.—*Iwanoff*, l. c. S. 127, 131; unveröffentlichte Zeichnungen.—*Classen*, A. f. O. XIII. 2 S. 467, Tafel II., III.—*Niemetschek*, Prag. Vierteljahrschr. 94. Bd., S. 28.—*Gouvea*, Archiv für Aug. und Ohrenheilk. I. S. 118.—*Stricker*, Studien aus dem Institute f. exp. Path. Wien, 1870, S. 1-17.

1. Vascular Keratitis.

Symptoms.—*This disease is marked by more or less irritation in the ciliary portion of the globe, a gray opacity of, and development of vessels on the roughened surface of the cornea.*

1. The corneal surface becomes grayish in one or more points, loses its polish, appears dull, like ground glass, and not unfrequently strippled, as if it had been punctured by needles. This cloudiness generally proceeds from the margin towards the center, more rarely the reverse.

2. Vessels soon appear advancing towards the centre, following the opacity as it were. These unite with each other to form a more or less fine net-work, and at last disappear in small ultimate branches; when the opacity begins at the center, the vessels are not generally seen till it approaches the margin.

Occasionally the vessels rupture and extravasations of blood occur, which are seen as irregular red spots, between the meshes of the individual vessels.

In the deeper layers the changes of tissue are more rarely marked, and vessels are only exceptionally seen by the naked eye.

3. Symptoms of ciliary irritation almost always precede and accompany the alteration of tissue of the cornea. The ocular conjunctiva appears streaked with a net-work of vessels, which increases in fineness towards the cornea, and presents a nearly scarlet border, which covers a greater or less arc of the corneal periphery. Under this superficial net-work appears a deeper one, belonging to the episcleral tissue, which towards the corneal border is thickened to a bright-red ring, and not unfrequently (from serous expansion of the vessels) extended as a ring-like swelling over the surrounding parts. The parts about the eye then feel warmer than natural, even when the lids are not red or swollen, which, moreover, is not rare in the intense grades of keratitis. The tears show an increase of temperature.

The amount of pain varies greatly; it may be wholly absent or very severe. It occurs particularly where removal of epithelium or traumatic loss of substance has left the nerves exposed. It often extends along the frontal nerve, less frequently along the infra-orbital. It is usually accompanied by marked spasmodic contraction of the pupil, which is with difficulty overcome by mydriatics. Photophobia and consequent lachrymation and spasm of the lids usually attend it, and sometimes from their intensity and obstinacy these are the chief symptoms. In vascular keratitis, moreover, photophobia may occur without much pain, and the latter without the former.

4. If the cloudiness of the cornea is in front of the pupil, it of course causes dimness of vision, which is greater in proportion to the amount of the alteration and the extent of the pupil covered.

Causes.—Vascular keratitis is frequently merely an accompaniment of herpes corneæ. It often occurs also with trachoma, and is then a trachomatous development of the tissue of the cornea, more rarely it is a sequence of different forms of

conjunctivitis. It is primarily developed as a result of the most varied external injuries, especially those affecting the surface of the cornea, such as mechanical irritation caused by the presence of foreign bodies, specks of dust, inverted cilia, etc. Chemical irritants, smoke, hot steam, caustic fluids, high temperature, etc., frequently induce it. We must particularly notice among the causes the untimely use of strong eye-waters, irritating salves, etc., used in the treatment of other eye-diseases. Also the continued action of air on an eyeball which has been exposed by shortening of the lids, ectropion, exophthalmia, etc. Besides these, we may mention as possible causes of vascular keratitis, sudden change of temperature, draughts, and various other physical and functional causes of injury.

Course.—This is very variable. Where the cause acted but a short time, the disease may terminate in a week, or it may, even with careful treatment, run on for months. Where the cause is not removable, the termination of the disease is of course delayed. Keratitis usually begins with some ciliary irritation, which precedes for some days the cloudiness of the cornea; then the latter gradually spreads, vessels appear, and in a few days or weeks the disease reaches its maximum. Here it sometimes remains for weeks, while the symptoms of irritation vary. Finally the latter recedes, and the keratitis goes on to recovery or becomes chronic, and sometimes lasts for months.

Results.—The most usual termination is in recovery. A vascular keratitis, produced by a temporary cause which does not recur, gives hope of a speedy cure under proper treatment. Long existence of the inflammation, great extent and a commencing grayish-white cloudiness of the part, and finally difficulty or impossibility of removing the cause, render the prognosis grave, for then the epithelial cloudiness, opacities, or pannus often remain. The arrest of the process is generally first shown by the decrease of pain and photophobia, the exacerbations become milder or do not occur, the tears are less warm and abundant, the vessels around the cornea more isolated, the cloudiness clears up from the edges towards the center of the portion affected, and the vessels correspondingly recede. The eye always remains quite sensitive for some time, and the greatest care of surgeon and patient is required to prevent relapses.

Sometimes at one part or other of the inflamed portions, the epithelium, perhaps also Bowman's membrane and the subjacent layer, are destroyed, and an excoriation of varied form and depth remains. The irritation of the tears, air, etc., appears very great at such points, then the injection of the deeper vessels, the pain and especially the photophobia reach and maintain a high grade, till a layer of epithelium has covered the excoriation. Not unfrequently the inflammation increases and spreads to the substance of the cornea (parenchymatous keratitis). Such a combination of the only artificially separable forms of keratitis is not rare, for where unfavorable circumstances of the patient, or improper remedies, unite to act disadvantageously, the decease of the cornea increases, and frequently advances to abscess or ulceration. The development of herpetic eruption also is not rare, and occasionally the disease extends to the uvea, causing iritis.

Treatment.—The first indication is to look carefully for foreign bodies, inverted cilia, and so on, and by removing the cause to arrest the progress of the disease. The remaining indications are directed especially to checking the intensity of the inflammation and accompanying symptoms in the vascular and nervous systems.

1. When in the acute course of vascular keratitis the inflammatory symptoms

are moderate, as well as in cases where the nervous character of the process is evident from the disproportionate severity of photophobia or pain, and relatively slight vascular symptoms, careful and antiphlogistic regimen and instillations of solution of atropine, repeated two or three times daily, together with a protective bandage, are most serviceable. Where the inflammation is more intense, particularly when the vascular symptoms are prominent, leeches may be used; and if the local temperature is much increased, cold compresses may be carefully applied for short periods. If unbearable pain or excessive photophobia, with great spasm of the lids, render a treatment of symptoms absolutely necessary to counteract general or local danger, hypodermic injections of morphia are better than the internal use of opium. In cases where the nervous symptoms have a particular type, the use of quinine and morphia in suitable doses is recommended.

In such cases the nervous symptoms are often intense, and readily tempt the inexperienced practitioner to use antiphlogistics, especially leeches. This should be carefully avoided. This treatment is particularly injurious in debilitated persons, women, and delicate children. On account of its effect on the constitution, it not unfrequently increases the nervous symptoms. Sometimes the result of treatment does not appear at once. The disease often resists all remedies. Then nothing is so injurious as the popular "feeling around in the medicine chest" for specifics. It increases the sufferings of the patient and lessens his confidence in the surgeon. We should make a careful prognosis, then carefully and patiently carry out the treatment once recognized as indicated.

2. If, in spite of the cessation of the symptoms of irritation, the clearing up of the cornea is delayed, or if the keratitis becomes chronic, finely-powdered calomel should be dusted on the eye with a camel's-hair brush. If this be followed by great irritation, its use must be delayed for a time; but if well borne it may be used once or twice daily, and after a time changed for the more active yellow oxide of mercury salve.

3. In trachomatous keratitis special treatment is not required. After subduing the more prominent symptoms of irritation, direct treatment of the trachoma by caustics is the most serviceable. If nothing else interferes, the corneal cloudiness disappears under their use much sooner than the trachoma itself.

In the treatment of the various forms of keratitis, more especially, however, of trachomatous inflammation of the cornea and herpes, or phlyctenular keratitis, as well as of pannus, there is often great value in the operation of dividing the external canthus, the so-called *canthoplasty*. Its effects in pannus and phlyctenular keratitis and conjunctivitis, where there is great photophobia, are usually very marked. The operation consists in the free division of the conjunctiva and integument of the external canthus with a pair of strong scissors or a scalpel, and the union of the divided membrane to the skin by two or three fine sutures. A free dissection of the conjunctiva from the integument, or of the orbital connective tissue, is unnecessary and not without danger, while the simple division of the external commissure may be considered a perfectly safe procedure. It is an operation which, when performed in the above-named class of cases, has been found to be a powerful adjuvant in their treatment, by at once lessening the prominent symptoms of irritation.]

2. Herpes of the Cornea [Phlyctenular Keratitis].

Symptoms.—*The chief characteristics of corneal herpes are the development of circumscribed, rounded points of inflammation about the size of a poppy-seed, in the superficial layers of the cornea, and vascular injection of the ciliary region of the eyeball.*

1. The herpetic eruption appears first as a rounded cloudy nodule, which is imbedded more or less in the substance of the cornea, and generally protrudes somewhat above the surface. Sometimes a vesicle containing a watery fluid comes on the summit of this nodule. Occasionally this vesicle bursts before being perceived, and then in its place is found an excoriation or a loss of substance, which appears as an ulcer, with sharp edges and a fatty or purulent covering. Sometimes no vesicles are formed. The nodule quickly becomes cloudy-white, or it throws off the epithelial covering and is replaced by an ulcer, covered with fat or pus, of the size and shape of the original nodule. Sometimes the inflammation proceeds, and the nodule or ulcer is surrounded by a cloudy border. The cloudy mass forming this border is often destroyed and the ulcer extends, changing its original form. Not unfrequently the cloudiness departs, and the efflorescence appears as a round loss of substance of variable depth, with perfectly smooth transparent walls, which give no other evidence of inflammatory alteration than a so-called "resorption ulcer."

The vesicles may develop on any part of the cornea. Often only one is found, in other cases numbers. Occasionally they form groups. At the limbus conjunctivalis they often collect, and so cover a greater or less arc of the corneal periphery. They often occur with herpes conjunctivæ, and form connected groups with its eruptions. As the vesicles do not all develop at once, but one after the other, they may be found on the cornea and conjunctiva at various stages of development.

2. Congestion of the conjunctiva and episclera precedes and accompanies the eruption; this is generally universal when the number of vesicles is large, or if they are scattered. A coarse net-work of vessels runs through the conjunctiva, while under it, around the margin of the cornea, may be seen the fine rosy net-work of the episclera. Where the eruption is slight or limited, the hyperæmia is confined to the immediate neighborhood supplied by the ciliary nerves that are irritated; so that a greater or less section of the ocular conjunctiva and episclera is injected. Then we find in the ocular conjunctiva a more or less broad bundle of intensely injected, variously-branched vessels, which, proceeding from the reflection of conjunctiva, advance towards the edge of the cornea, forming an irregular triangle, one of whose sides is in a meridional direction, and whose base is toward the reflection of the conjunctiva. If the efflorescence is on the margin of the cornea, it forms the apex of the triangle; if it is removed from it, the apex appears to be cut off at the limbus conjunctivalis; if the sides of the triangle are imagined as prolonged they meet in the efflorescence.

This vascular injection is the objective expression for the state of irritation

produced in the parts surrounding the herpetically affected nerve-twig. In the non-vascular cornea, this irritation cannot be visibly expressed; hence in efflorescences which are seated on the cornea at a distance from the limbus conjunctivalis, the bundle of vessels appears broken off. The irritation increases occasionally, however, to inflammation and to change of tissue in the conjunctiva, episclera, and cornea. Then the symptoms of vascular keratitis appear. That part of the cornea which separates the efflorescence from the cut-off end of the bundle of vessels becomes cloudy, and vessels soon develop on it. These unite with those of the hyperæmic conjunctiva. The vessels of the latter thus reach the efflorescence, which now forms the apex of the completed triangle. The corneal part of the latter is called the "*herpetic bridge*" (*die herpetische Brücke*).

Where several efflorescences are developed close together, the bundles of vessels intermingle as well in the conjunctiva as in the cornea, and so destroy the typical form. Still it does occur that several efflorescences are scattered around, and yet each is connected with an independent bundle of vessels.

Not unfrequently vascular keratitis is developed first, it extends more or less, and subsequently the efflorescences appear within or outside of the inflamed part. Then, naturally, the bundle of vessels is completely lost in the universal hyperæmia. The same thing, of course, happens when herpes of the conjunctiva occurs during a conjunctivitis, and the diagnosis is made entirely from the existence of the peculiar efflorescence.

3. As a rule, the disease begins with burning pain in the eye, and photophobia with its accompaniments, lachrymation and spasm of the lids. During the course of the disease the degree of pain and photophobia varies greatly, being sometimes insignificant, and again almost unbearable, and predominating over the other symptoms.

4. Vision is impaired by the lachrymation, and subsequently by catarrhal secretion, but it is especially affected when part of the pupil is covered by the efflorescence.

Causes.—Herpes of the cornea is not unfrequently seen as one of the symptoms of an eruption occurring in the region of the distribution of the trifacial (fifth) nerve. Such a zoster may extend over the integument supplied by all three chief branches (*Singer*), or over that supplied by two (*De Haen*). It may be even confined to one branch. According to experience and the course of the oculo-papillary branches of the sympathetic fibers, the eye is only involved when the belt of eruption occurs in the region supplied by the naso-ciliary nerves, and thus extends to the tip of the nose (*Hutchinson*). But even in the latter case the eye may not be affected (*Hutchinson, Steffan*), and on the other hand it may be involved in herpes zoster, affecting the frontal and lachrymal nerves (*Bowman, Hebra, Horner*). Cases even occur where the ciliary region is severely attacked, and where there are only isolated groups of the characteristic efflorescences on the lids and the adjacent parts of the facial integument.

Some refer trifacial zoster to certain diseases of the Gasserian ganglion, founding this view on certain cases in which the eruption is connected with inflammatory swelling of the sympathetic spinal ganglion (*Bärensprung, Charcot, Cotard*), while others consider the starting-point of the disease to be in the sympathetic nerve-centers (*Steffan*). Pathological investigations show that the proximate cause may be affections of individual nerve-twigs (*Danielsen, Esmarch*), and even of peripheral terminal twigs (*Ivanoff*), provided they have sympathetic tubes; then it is possible, of course, that the inflammatory changes may be secondary. At

any rate it is a very important fact that individual herpetic groups have been observed at the same time in nerve tracts widely separated from each other (*Niemetschek*). These can only with difficulty be explained, unless we suppose that they were scattered collections of the fundamental disease.

The affection of the eye is usually seen some days after the beginning of the eruption. In some of the cases it manifests itself by lachrymation, great chemosis of the lids and conjunctiva, photophobia, and severe pain. Subsequently a slight opacity of the cornea and iritis not unfrequently occur. The latter may go on to irido-choroiditis and lead to loss of the eye (*Hutchinson*). In such cases the eye behaves in a manner quite analogous to the inflamed and infiltrated integuments which connect the efflorescences of a zoster on the back and chest. Isolated phlyctenulæ (*Johnen*) have been seen on the cornea, but rarely in their primary form, they having usually cast off their epithelium and resemble minute ulcerations, or they even run together and form large ulcers. Some authors compare these "small deliquescing spots or ulcers" to those which occur after measles (*Bowman*). In one case a small nodule of exudation formed on the pupillary margin of the inflamed iris (*Hutchinson*).

Although the nosological connection between herpes of the cornea and of the various forms of zoster has been known for a long time, the observation of several cases of trifacial zoster has contributed to the proper appreciation of that common disease, and yet so variously named, —herpes of the cornea and conjunctiva.

More attention has been given trifacial zoster, and the ophthalmia connected with it, since the publication of Hutchinson's cases. This author gives the name of "herpes ophthalmicus" to the disease.

Since then there have been a number of cases published (*Hutchinson*, *Bowman*, *Steffan*, *Jeffries*, *Johnen*). It is seen from these cases that severe pain in the region of the affected twig of the trifacial usually precedes the attack of herpes ophthalmicus. These last, with slight intermissions, during the whole course of the disease. For weeks after the eruption on the skin has healed, this pain may remain with a loss of sensibility of the parts. This pain is so severe that surgeons have felt obliged to divide the affected nerve, but thus far with only a temporary benefit (*Bowman*). Sometimes there is no pain, and merely itching sensations and loss of sensation. The eruption occurs some days after the outbreak of the affection. The skin and the connective tissue beneath are infiltrated, with great hyperæmia and elevation of temperature. The condition thus resembles erysipelas, and could be mistaken for this, if it were not for the slightness or absence of the constitutional symptoms, the sharp boundary-line of the eruption on the middle of the face and the usual limitation of the swelling to the part supplied by one of the trunks of the fifth pair, as well as the peculiar appearance of the efflorescence.

These cases are not as numerous, however, as those in which herpes of the cornea appears independently. The latter disease is one of the most common of affections of the eye.

Injurious influences from without, whether mechanical, chemical, or physical, which irritate the ciliary nerves, may cause herpetic disease. It frequently occurs secondarily. Occasionally irritation of other branches of the fifth pair affects the ciliary nerves, and causes herpes of the conjunctiva and cornea. In this way may be explained its frequent occurrence in eczema, impetigo, etc., of the cheeks and nasal mucous membrane, a combination called by old authors ophthalmia *psoriaca*, *impetiginosa*, *serpiginosa*. Thus also may be partly explained the frequent appearance of herpes in the course of different forms of conjunctivitis, such as catarrhal and trachomatous inflammations of the conjunctiva.

As it is not easy to escape the varied causes of herpes, it is not strange that every age and all stations of life in every climate are liable to it. Still, it is more frequent in certain classes where the exciting causes are more numerous.

A predisposition to herpes cannot be denied. Generally persons of very irritable, nervous temperaments suffer most from it. It appears most frequently among children of so-called scrofulous constitution. During youth and adult age it is found among weak and ill-nourished persons, or those reduced by disease. It is found so often in the desquamative stage of measles, small-pox, and scarlet fever, that it has been named ophthalmia morbillosa, variolosa, scarlatinosa.

Course.—The herpetic process is typical. It begins with burning, piercing pain and photophobia; soon the characteristic vascular injection of the conjunctiva appears, and after a day or two the herpetic nodules may be seen, and during the succeeding few days they increase in size. Meantime the symptoms of vascular and nervous irritation recede; but the changes that the cornea has undergone during the inflammation do not generally disappear for weeks or months. But this course is rarely seen; it happens only in those cases where the disease was produced by some external cause, and when the patient is living under circumstances favorable to the cure.

The inclination to renewed attacks which is peculiar to herpes manifests itself here also. As one efflorescence finishes the typical course, another comes on, and one crop of vesicles following another, the pain and photophobia continue, and the disease runs on for weeks. Of course the long continuance of the disease influences the general health, especially when the surgeon helps to undermine the constitution by antiphlogistics, low diet, narcotics, etc. Remarkable paleness, flabbiness, softness of the muscles, increased irritability of the nervous system—in fine, a state corresponding to the so-called "scrofulous" is the result. Swelling of the cervical glands also often occurs to complete the picture of scrofula.

Such appearances have led the ophthalmic surgeon to impute to herpes a scrofulous basis, and where it occurred in apparently healthy persons, to assert that there was a latent scrofula. In accordance with the above, scrofula is not unfrequently the result of a precedent herpes, instead of the latter being the localization of a blood-disease. As regards the swelling of the glands, it may be stated that they are most frequently caused by herpes, but not by a scrofulous affection of the blood; for they appear in the strongest and most robust individuals during the course of the herpes, especially when it is accompanied by marked nervous or vascular irritation. They have the same relation to disease of the eye that swelling of the axillary glands has to paronychia.

In children of so-called scrofulous habit, herpes corneæ takes on a peculiar course; commencing with excessive photophobia, which, with slight intermissions, continues days, weeks, or months, and the accompanying spasm renders examination of the eye very difficult. If the lids are forcibly opened, a very disproportionately slight injection of the vessels is found. Only a delicate rosy ring shows itself around the cornea in the episcleral tissue. Frequently the efflorescences cannot be discovered on account of the opposition made by the patient. Then photophobia is the only perceptible disease, and this was described by older writers as "scrofulous photophobia." On more careful examination, however, efflorescences will almost always be found.

Sometimes cases occur in which the photophobia exists a long time without the efflorescences appearing, and in which they only reappear at long intervals, so that even at repeated

examinations the characteristic alterations of the cornea are absent. They are, however, rarely permanently absent. They appear sooner or later, and then the hyperæmia and swelling of the conjunctiva and episclera usually reach a high grade temporarily, even the lids and surrounding parts often participating. In extreme cases the symptoms are similar to those of blennorrhœa.

The secretions flowing from the eyes and nose often excoriate the parts with which they come in contact, and cause pustular eruptions. The ophthalmia tarsi, impetigo and eczema of the lids and cheeks, and of the nares and lips, are often developed during a herpes of the cornea, especially when this is accompanied by severe photophobia and lachrymation.

In eczema of the nares, the intimate connection between the ciliary nerves and those of the Schneiderian mucous membrane is of etiological importance, and shows itself by the itching in the nose, and consequent sneezing, which accompanies irritation of the ciliary nerves. Indeed, in dirty patients, who constantly rub their eyes with soiled hands or rags, such a change of symptoms is often observed.

Finally we must mention the so-called "scrofulous vascular band" as a rather peculiar variety, which greatly reminds us of the serpiginous course of some of the exanthemata. A nodule comes on some point of the corneal border, and before it has run its course, another comes at its edge; then while the preceding one goes on in its changes, a third, fourth, etc., occur, and this process continues for months, and results in a grayish or yellowish-white cicatrix, stretching out on the surface of the cornea, and showing a fresh efflorescence at its extremity. The hyperæmia and swelling of the conjunctiva and episclera, as well as the pain and photophobia, meanwhile continue unchanged.

Results.—1. The disease often terminates in perfect recovery. This generally occurs in very superficial efflorescences of slight extent. They often simply recede either quickly, before all the symptoms of irritation are gone, or slowly—that is, in the course of weeks or months. In other cases the superficial nodule softens and disintegrates. The excoriations or ulcerations then formed fill up with transparent cornea, are covered by pellucid epithelium, and all traces of the efflorescences are obliterated; but sometimes the newly-formed tissue is cloudy, and only subsequently becomes transparent.

2. Deeper and more extensive nodules have a less favorable course; they rarely disappear entirely. They usually result in ulcers, which fill up with transparent corneal tissue, but are covered by cloudy epithelium, which remains opaque for a long time, perhaps always, forming an epithelial opacity. In other cases the regeneration is slow, the filling up of the cavity requires weeks or even months, during which the eye remains very sensitive and inclined to irritation; the exfoliation becomes a simple facette, a plane surface, and finally either a herpetic epithelial opacity, which subsequently does not always completely disappear, or else on the site of the facette a thick cloudiness occurs, presenting a tendinous appearance. But not unfrequently such opacities form quickly by the ulcer filling up with a cloudy mass, which becomes permanent. These spots correspond in form and size to the previously existing nodules, but are thinner, as some transparent corneal tissue always forms on the floor of the ulcer. They are usually surrounded by a dim, cloudy border.

3. The breaking down of herpetic nodules is occasionally the cause of perforation of the cornea. Sometimes this occurs very quickly, a few hours sufficing for the formation and destruction of the nodules. But usually the course is slower, the nodule existing for several days before perforation occurs.

4. More frequently the perforation is only a secondary effect of herpes. The

cornea becomes inflamed around the disintegrating nodule, and an ulcer forms on the base of the herpetic eruption; this runs exactly the same course as a primary ulcer, and has the same results, among them perforation, which will be a subject of future remark.

5. The elements forming the herpetic nodule can have progressive as well as retrogressive action; they sometimes form cartilaginous or chalky masses, that last through life.

6. In the same way the products of the accompanying vascular keratitis are sometimes permanent. After disappearance of the symptoms of irritation, the herpetic bridge leaves after it an epithelial or panniform opacity, or even a tendinous neoplasia corresponding to it in form and extent. If the congested part of the conjunctiva becomes hypertrophied, pterygium is started, and consequently this is one of the results of herpes corneæ.

7. After frequent relapses, herpetic pannus occasionally appears. This will be spoken of under conjunctival herpes.

8. Finally, it must be observed that the herpetic process does not always exist pure and unmixed. It sometimes occurs *secondarily* in the course of a vascular keratitis, but on the other hand it often spreads and becomes complicated with the latter, which modifies its course. The combination of corneal herpes and iritis is particularly important; it occurs particularly as a result of inappropriate treatment or bad circumstances of the patient. In obstinate herpes, however, a catarrh or true trachoma of the conjunctiva is more generally developed. The hyperæmic and œdematous conjunctiva become relaxed and spongy, and that covering the tarsal cartilages becomes rough and velvety. Great lachrymation and secretion of catarrhal mucus occurs, and subsequently characteristic granulations appear. Once so far advanced, the disease recedes with difficulty. Its disappearance is gradual, and is marked by more or less decided exacerbations, in which at one time the vascular, at another the nervous symptoms predominate, according as the conjunctivitis or herpes has the upper hand in the relapse. Thus we see that the trachomatous complication causes the continuance of herpes, and hence in prolonged herpes corneæ we should always carefully examine the conjunctiva by everting the lids.

9. Amblyopia from non-use of the eye, and strabismus, are to be feared as secondary results of herpes corneæ, especially in children.

Treatment.—The treatment of corneal herpes is almost exactly the same as that applicable to vascular keratitis. The application of a protective bandage and the once or twice daily dusting in of calomel, or the penciling on the conjunctiva of the ointment of the yellow oxide of mercury, is recommended as a kind of specific in herpes of the cornea. The good effects of this treatment can not be denied, yet the use of these irritants is only applicable when the vascular and nervous irritation have subsided, and the inflammation has reached its maximum, and when atropine is able to fully dilate the pupil. These irritants are particularly useful in removing superficial opacities of the cornea, left behind after the herpes has run its course; on the other hand they are injurious as long as the process is acute, and has a sthenic character. They certainly then often increase the irritation. These remedies are injurious as long as the presence of inflammatory irritation is evinced by arterial hyperæmia and local elevation of temperature.

2. In the treatment of the herpes of the cornea, it is of great importance to guard against eczematous and impetiginous eruptions of the eyelids, cheeks, nos-

trils and lips (they usually occur on children and thin-skinned persons), for they favor relapses, thus rendering the disease very tedious.

Perfect cleanliness is necessary for this purpose, and the best way of insuring this is the "protective bandage," which keeps off injurious influences, and prevents rubbing, etc., while the charpie absorbs the tears, etc. It should be changed twice daily, and before reapplication the parts should be bathed with water. If any excoriations exist, lard, simple cerate, cod-liver oil, or glycerine-cream may be applied to them. When the interior nares and lips are affected, they are to be smeared with the salve, as they cannot always be protected by the bandage. If the irritation of the Schneiderian membrane extends far into the nose, it may be advisable to pass in wads of charpie smeared with fat, and to change them frequently during the day.

Quite recently Labarraque's or Javalle's solution, or a solution of soda saturated with chlorine, have been strongly recommended for this purpose (*Liebreich*).

If the eruption has already occurred, these means do not suffice to remove it quickly. In such cases, after proper cleansing, the affected part must be carefully examined; if there are any crusts present, they must be removed by fomentations with warm water or milk; if the surface under them is much inflamed, it is well to make cold applications, provided they can be easily used. When the symptoms of irritation have somewhat receded, direct remedies may be used. These are solutions of nitrate of silver gr. v. to x., sulphate of zinc, gr. v., corrosive sublimate, gr. j., to the ounce of distilled water; salve of flowers of zinc, half a drachm, or iodine of sulphur, one drachm to the ounce of simple cerate, cod-liver oil, etc. After previously cleansing the eye, the solutions may be applied either on a camel's-hair brush, or on charpie moistened with them and placed over the eye, a flannel bandage being applied over it. The salves may be simply smeared in, starch or lycopodium dusted on, and the bandage then applied. The cod-liver oil is best applied on a piece of flannel soaked in it, laid over the affected part, and there retained by an ordinary bandage. In any case, these remedies must be applied frequently during the day, and the parts must be cleansed well before each application. Internal remedies are of no service against these eruptions.

3. The frequent complications of herpes with catarrh and trachoma of the conjunctiva are just as important in regard to treatment; for great catarrhal secretion, and particularly trachoma, very decidedly contraindicate the use of the protective bandage, and its application may even cause an increase of the disease. Hence it must be confined to those cases and stages where the nervous symptoms require it. Otherwise it is better in the more sthenic cases to content ourselves with antiphlogistic regimen and dropping in of atropine solutions, until the subsidence of the severe vascular irritation permits the use of the yellow mercurial salve. When the herpetic process is arrested, or there is reason to suppose that catarrh or trachoma cause relapses, we should pencil the conjunctiva with a solution of nitrate of silver.

4. Further therapeutic indications arise from the changes which occur in the course of the disease. These indications aim at aborting the unfortunate results of the changes, or at least reducing their amount as much as possible.

As above mentioned, the alterations in question do not depend directly on the herpes proper, but on the quantity and quality of the new elements, their more or less rapid development, etc., and are analogous to the varied metamorphoses of the products of other forms of keratitis, Hence there is no necessity of particularly mentioning the practice to be followed, as it is the same as in the other forms.

5. After the inflammatory process has terminated, it is most important, especially

in children, to find how far each eye has preserved its functional power, and how it acts with the other eye in binocular vision. If the eyes are not perfect, means should be immediately used to ward off amblyopia and strabismus; as will be explained under these diseases.

6. In cases showing the action of a predisposition, especially in children of the so-called scrofulous habit, besides the local treatment, we are generally obliged to use constitutional remedies to prevent relapses.

The object of the constitutional treatment is to increase the nutrition of the whole body. At the same time particular attention must be paid to the nervous symptoms, and attempts made to diminish them by invigorating the patient. For this purpose cold baths, or still better, sea-baths, may be recommended; when these cannot be used, on account of the condition of the patient, or the time of year, they may be replaced by shower-baths, or by rubbing the body with a sponge wet with cold water. In bathing great attention must be paid to the weather. If the patient cannot stand cold baths, it will be well to begin with warm water, and use cold by degrees. Morning is the best time for bathing, and sometimes it is well for the patient to lie down for a few minutes after the bath.

Those wishing to use therapeutic remedies may add decoctions of oak or willow-bark, or walnut leaves to the baths; where there is great paleness, tartrate of iron may also be used in them.

Authorities.—*Stellwag*, Ammons Zeitschrift f. Ophth. IX. S. 510; Ophth. I. S. 94.—*Hiltermann*, Zeitschrift f. wissenschaft. Therapie IV. 1. S. 50.—*Blödig*, Zeitschrift der Wiener Aertzte, 1860, S. 728.—*Hasner*, Entwurf ein anat. Begründg., Prag, 1847, S. 88; klin. Vorträge, Prag, 1860, S. 147.—*Liebreich*, klin. Monatbl. 1864, S. 393.—*Graefe*, A. f. O. VI. 2. S. 130; X. 2, 202.—*Singer*, according to Jeffries, Transact. of the Amer. Ophth. Soc. 1869, S. 86, 75, 90.—*De Haen* u. A. according to Steffan, klin. Erfahrungen, S. 25.—*Hutchinson*, Ophth. Hosp. Rep. V. S. 191; VI. S. 181, 182, 263; Steffan, klin. Monatbl. 1868, S. 30, 369.—*Steffan*, kl. Monatbl. 1868, S. 366; klin. Erfahrungen, S. 26, 29, 43.—*Bowman*, Ophth. Hosp. Rep. VI. S. 1. Fall. 8; V. P. 1; from Jeffries, l. c. S. 85, 87.—*Hebra*, according to Steffan, kl. Erfahrungen, S. 38, 40.—*Charcot*, *Cotard*, Centralbl. 1866, S. 360.—*Danielsen*, *Esmarch*, according to Steffan, kl. Erfahrungen, S. 37, 38.—*Iwanoff*, unpublished drawings.—*Niemtschek*, Prag. Vierteljahrschr. 101. Bd. S. 78. *Johnen*, Deutsche Klinik, 1868, S. 288.—*Pagenstecher*, kl. Monatbl. 1868, S. 371.

3. Keratitis Punctata—Hydromeningitis.

Symptoms.—*This affection is characterized by the occurrence of groups of small round gray spots in the different layers of the regularly-clouded gelatinous-looking corneal substance and on the free surface of Descemet's membrane.*

The cornea appears partly or totally dull-grayish, with a tendency to a yellowish or greenish hue. The surface loses its natural polish; when the light falls on it in certain directions, it has an opalescent hue, like the play of color in an old window-pane. When closely examined, the epithelium looks rough, full of small holes, as if it had been stuck with needles; small, round dull-gray spots, bordering on yellow, or even brown, about the size of a hemp-seed, also appear, which seem sometimes to be near each other in the same layer, sometimes at different depths; in the latter case they appear to overlap each other, and hence, to the naked eye, they seem to run together. They are more commonly found in the posterior laminæ of the cornea, and on the free wall of the aqueous capsule, where they readily change to extensive cloudy opacities; though sometimes they appear just under Bowman's membrane. They are usually in the lower half of the cornea.

It is doubtful whether the points observed on the posterior wall of *Descemet's* membrane, and occasionally projecting into the anterior chamber, and which belong to the picture of hydromeningitis or keratitis postica, are the same as those groups of nodules which develop in the various layers of the cornea itself, and are characteristic of keratitis punctata, and if they are to be considered as different localizations of the same process. Both forms are separately observed; still the frequency of their occurrence together, as well as the great similarity of the two in all points, renders a distinction between them difficult and practically useless, before we have a more perfect insight into the processes causing them.

The symptoms of congestion are usually slight, and are generally limited to a small circle of injected vessels in the anterior zone of the episcleral tissue. Pain and photophobia are often absent; but there is almost always marked disturbance of vision. This depends partly on the cloudiness of the cornea, but partly also on the accompanying intra-ocular trouble.

Keratitis punctata is rarely an independent disease; it usually appears as one symptom of an inflammatory process affecting the deeper parts of the eyeball. Irido-choroiditis is its chief companion, especially the form that is chronic, and often leads to atrophy. Hence, cloudiness in the aqueous and vitreous, deposits on the anterior capsule, and posterior synechia are such frequent occurrences that they are often considered as symptomatic of keratitis punctata and hydromeningitis.

Causes.—Inasmuch as the disease in question is usually only a secondary or accompanying affection, its etiology corresponds for the most part with that of the original complaint. Still, disposing causes for the punctate exudation have been sought in certain dyscrasia, especially in constitutional, developed, or hereditary syphilis (*Hutchinson*), in chlorosis, and anæmia as well as in scrofula. It is also said that women are more disposed to keratitis punctata and hydromeningitis than men are, and that children are the least liable to the disease (*Hasner*).

Course and Results.—The course is almost always very chronic; occasionally

weeks and months pass without decided changes being observed in the cornea. Sometimes at irregular intervals an increase or a partial resorption of the exudation occurs. The disease has also been known to disappear entirely. The deposits on the posterior surface of Descemet's membrane are said to absorb with particular rapidity, when the original disease has been overcome. On the contrary, the spot-like deposits in the deeper layers of the cornea propria are apt to be permanent. Lastly, the prognosis is greatly affected by the amount of disease of the deeper structures of the eye, and this usually renders it very grave.

The Treatment is to be mostly directed to the general disease of the eye, and any existing dyscrasia. Special treatment is hardly suited for keratitis punctata and hydromeningitis. But atropine is said to be useful, and, where there is at the same time turbidity of the aqueous, paracentesis corneæ is highly spoken of, as it favors the throwing off of the exudation from the posterior wall of Descemet's membrane (*Hasner.*)

Authorities.—*Hutchinson*, Clin. Memoir, p. 154.—*Hasner*, klin. Vorträge, 5, 170, 171.

4. Parenchymatous or Diffuse Keratitis.

Symptoms.—*The chief characteristic of this disease is a moderate infiltration of the cornea with an opaque grayish or yellowish-white product, occurring with inflammatory symptoms. This infiltration shows little inclination to disintegrate, and usually collects in extensive, cloudy, distinctly-bounded points.*

The inflammatory proliferation of tissue evinces itself first by a slight gelatinous or misty cloudiness, which usually begins at the periphery, but day by day extends more toward the center, and finally spreads over the entire cornea. Subsequently a delicate gray cloudiness, of variable extent, commences in the inflamed cornea, which has hitherto remained transparent; this opacity is evidently in different layers; it soon thickens in some places, while it clears up more or less in others. Thus nearly or quite opaque, milk-white or yellowish spots of various shapes and sizes, with indistinct borders, are formed. In this way there is often formed a disc-shaped point of inflammation as much as three lines in diameter, or even a complete or interrupted ring, which surrounds the center of the cornea at a variable distance, and has quite a sharp border externally, but is indistinct internally. If the whole cornea be inflamed it may become entirely opaque, grayish-white, and even decidedly swelled.

The disease rarely runs its course without the formation of vessels in the deeper layers of the cornea. Usually, soon after the development of the peculiar points, delicate branches are developed, which run to the point of exudation from the part of the scleral border lying nearest to it. These often cross each other, thus showing that they are located in different layers of the cornea, and occasionally they are so close together as to appear to the naked eye like a red band or an extravasation of blood. At the margin of the exudation they resolve into a more or less fine net-work, which partly or entirely borders its periphery.

At the same time the surface of the cornea not unfrequently retains its reflecting brilliancy, but more often it appears dull, stippled, and even as if spun over with a newly-formed vascular net-work; the diffuse keratitis is combined with vascular keratitis. The subjective symptoms, such as pain and photophobia, as well as hyperæmia of the conjunctiva, are variable, and are often out of proportion to the disease, or they may be entirely absent.

If the cloudiness is in front of the pupil, of course there will be disturbance of vision. If the ciliary irritation is slight or nearly absent, this is usually the symptom that excites the patient's attention, and causes him to visit the surgeon.

Causes.—The most varied external injuries may serve as the immediate cause. More frequently, however, diffuse keratitis occurs without any discoverable reason; this even appears to be the rule. Many think that the disease in question must be regarded as the localization of a dyscrasia, or they consider scrofula and tuberculosis (*Mackenzie, Arlt*), hereditary (*Hutchinson, Secondi*), or constitutional syphilis, as greatly favoring the development of diffuse keratitis. This is still a disputed point. It is certain that the disease is met with at all ages, in both sexes, and the

most varied constitutions; that, however, it occurs more rarely in small children and in adults beyond forty years, while those between twelve and fifteen years are most frequently affected. Girls are said to be more disposed to it than boys, and that delicate, weakly, anæmic, backward, dysmenorrhœic individuals are particularly apt to be affected.

Course.—Usually the symptoms of ciliary irritation, vascular injection, pain and photophobia, with their attributes, precede for several days the visible formation of exudation. These symptoms are usually very decided at first. With the progress of the product formation they gradually moderate, and may even totally disappear; although cases occur where they continue throughout the disease, with exacerbations and remissions, maintaining a decided intensity, and appearing irremovable. Independent of these variations, the proliferation is sometimes excessive; again, there is only a slight amount of product, and the process reaches its height in the course of days or weeks. Having attained this point, the disease usually continues for weeks or months, with varying intensity of the ciliary irritation, before commencing to retrograde. The removal of the infiltration is, as a rule, very slow, and may even require months. Cases with strongly marked vascular symptoms usually run their course more rapidly than those where these are less prominent. The duration of the disease is usually shorter in children than in persons at or beyond puberty (*Hasner*).

The affection is rarely limited to one eye; the two eyes are usually attacked soon after one another. Relapses readily occur. Sometimes it is combined with iritis, irido-choroiditis, or with other forms of keratitis. In cases thus complicated a very marked softening of the globe has been repeatedly observed (*Tetzer*). This was the case when the symptoms did not justify the assumption that there was a degeneration of the deeper parts of the organ, and when the eye within a short time was completely restored to a normal condition. The affection has therefore been referred to a disease of the nutrient nerves, and the softening of the globe has been explained to be a kind of neurosis of secretion (*Graefe*).

Results.—Under favorable circumstances and with proper treatment, diffuse keratitis is often cured, for the symptoms of ciliary irritation diminish and disappear, then the points of exudation clear, disintegrate in small spots, and are finally all absorbed without leaving a trace. Of course, slight gray cloudinesses clear up more certainly and quickly than perfectly opaque spots, and fresh productions more readily than those that have existed for months. Still, with proper treatment, even the apparently unfavorable cases not unfrequently result in perfect cure, especially when they are accompanied by great ciliary irritation. The prognosis is most favorable in children. In them opacities often disappear, which, from their intensity and long duration, would in adults leave little hope of a cure. Perfect health of the other parts of the eyeball has an important influence on recovery. Where these have been greatly affected by the inflammation, the prognosis in regard to the cornea is less favorable.

The Treatment aims at limiting the inflammatory process, removing excessive nervous irritation, and opening a way for the retrogressive changes of the newly-formed elements. If there is any constitutional disease that can possibly influence the local affection, of course it must be appropriately treated. The means for accomplishing the first two indications are the same as those that succeed in vascular keratitis, but they are less efficacious in diffuse keratitis.

Quite lately, especially in recent cases, the favorable effect of paracentesis corneæ has been seen; for the process, which usually runs such a tedious course, has been arrested in eight to fourteen days. But in vascular diffuse keratitis with marked ciliary irritation, and when complicated with iritis, this treatment appears of little value (*Hasner*). In some cases of keratitis diffusa running a very chronic course, and without much vascular injection, warm applications have proved serviceable. If the entire conjunctival sac participated moderately in the inflammation, perfect cure sometimes followed very soon (*Graefe*, *Secondi*).

When the inflammation approaches or has reached its termination the indication often exists to assist the tardy clearing up of the cornea. Dusting in calomel or introducing salve of yellow oxide of mercury are then very advisable. More irritating remedies, such as laudanum, solutions of sulphate of copper in glycerine (*Roosbroeck*), etc., should not be applied until the symptoms of irritation and the diseased sensitiveness of the eye have entirely disappeared. Even then they should be used with great care and had better be let alone.

Authorities.—*Mackenzie*, Prakt. Abhandlung über die Krankheiten des Auges, Weimar, 1832, S. 407.—*Arlt*, Krankheiten des Auges, Prag, 1851, I. S. 183. *Hasner*, Klin. Vorles. Prag, 1860, S. 160, and Prag. Med. Wochenschrift, 1864, Nro. 1.—*Hutchinson*, A Clinical Memoir, etc., London, 1863, P. 26. *Secondi*, Clinica ocul. di Genova, Torino, 1865, P. 13.—*Graefe*, A. f. O. VI. 2, S. 133.—*Sämisch* and *Pagenstecher*, kl. Beobacht. Wiesbaden, 1862, II. S. 109.—*Roosbroeck*, kl. Monatbl. 1863, S. 493.—*Tetzer*, Wien. Med. Jahrb. 1866. 4. S. 6.

5. Suppurative Keratitis.

Symptoms.—*Purulent collections in the cornea are recognized by their great cloudiness, and by the disintegration and breaking up of the cornea into fatty granular detritus.*

The symptoms of ciliary irritation which precede and accompany the formation of pus in the cornea, vary exceedingly. Sometimes the vascular, at others the nervous symptoms are the more prominent; sometimes they are equal, and both are very intense; again they are almost absent. These differences to some extent depend on the causes, and will be more fully mentioned when speaking of the course.

Sometimes the collection of pus is an abscess, at others an ulcer; as it occurs at one time in the parenchyma, at another on the outer surface of the cornea. Besides these, we have the pus sinking in the form of onyx and hypopyon. In regard to the latter, it is constantly becoming more evident that the purulent collections in the anterior chamber, apart from the rupture posteriorly of corneal abscesses, may come not only from proliferation of iris tissue, but are extensively derived from inflammatory proliferations of the epithelium of Descemet's membrane. This suppurative hydromeningitis certainly often accompanies suppurative keratitis; still, iritis is not a necessary antecedent of hypopyon. Such inflammations of the membrane of Descemet are usually found along with broad, extensive ulcers, with white-yellow infiltrated borders, and especially in all extensive and deep purulent collections in the cornea, accompanied by great ciliary irritation. Hypopyum-Keratitis (*Roser*).

The contents of the purulent collection are not always homogeneous, which indicates that the process is capable of various modifications. Often the contents look like pure pus, they are creamy, contain firm lumps, and appear to exercise but little influence on the surrounding tissue, as the collection of pus often exists for a long while without destroying the lamellæ of the cornea in contact with it. In such cases the inclination to higher formation of the new elements, that is to regeneration of the cornea, shows itself in the vicinity of, or even in, the purulent collection. In other cases the pus appears very fluid, and the fatty detritus excessive, the inclination to higher development is absent; on the contrary, the lamellar substance of the cornea rapidly melts away as far as the outer border of the collection, so that we might imagine there was a corrosive action of the pus. Another series of cases seems to act in the same way. In these the contents appear at first stiff and yellow; they quickly become a thickish pus, which seems to melt away everything with which it comes in contact. This product is much like disintegrating tubercle. Finally cases occur in which the affected portions of cornea break up into a light gray or gelatinous translucent, almost colorless mass. These cases have been referred at least partially to softening, a process differing from inflammation. But the disintegration certainly depends on a process of development in the corneal corpuscles, similar to that forming the basis of suppuration.

A. The abscess appears as a layer of yellowish substance (sometimes red, from a mixture of blood), in the cornea. Partial abscesses, if near the center of the cornea, are generally roundish; if near the periphery, kidney-shaped. The edge of such an abscess is often sharply defined, but often, also, has a white-grayish border, which gradually shades off into a gelatinous opacity. If this cloudiness extends to the

periphery of the cornea, newly-formed vessels are found in it. The layers of cornea covering the abscess anteriorly are often but little changed, and their surface appears very polished. In other cases, however, they are clouded to a variable extent. Occasionally, also, they are vascular, and covered with rough epithelium.

The purulent collection is thickest at its center, and at that point sometimes extends almost through the cornea. But toward the border it flattens out, and if sharply defined has a chisel-like edge. It is frequently in the middle layers of the cornea, so that anteriorly and posteriorly it appears covered by a thick layer of clear cornea. Sometimes it is in the posterior layers or even between the cornea and Descemet's membrane. Finally cases not unfrequently occur, in which the anterior layers contain the pus.

In total abscess of the cornea, the so-called *vortex purulentus*, the cornea appears changed to a yellowish-white *plug*, whose edge approaches the sclera, and whose surface evidently projects above the normal level, showing a thickening of the cornea.

At first the contents of an abscess are not generally fluid; if it be punctured, nothing flows out. The transformation of its contents to pus usually begins after a few days, generally in the center of the mass—often, however, in several points at the same time. In other cases the first stage is short; very soon the entire mass becomes a more or less fluid pus, which is easily evacuated by a puncture, and occasionally even ruptures spontaneously. There is no certain sign by which we may always recognize the firmness or fluidity of the contents before the opening of the abscess.

By a perpendicular section it is at once seen that the purulent matter of the abscess does not form a compact mass, as in abscesses in the subcutaneous tissue, muscles, etc., but appears to lie in more or less thick discs between the laminæ of the cornea; the purulent collection consists of alternate layers of inflammatory product and fibrous lamellæ.

The layers of pus are not all of equal extent, and their centers do not all lie in the same radius of the cornea; hence the abscess often has an irregular, lamellar appearance. This is especially true of the center of the purulent collection, for here a great number of layers lie over each other. Toward the border this number decreases, and frequently only one layer is found, which has opened an interlamellar space far out.

The corneal lamellæ traversing the abscess appear at first, especially in certain cases, to take little part in the process, as they show scarcely any change. But sooner or later they begin to cloud up, and are finally destroyed, by progressive decomposition of the inflammatory product, into fatty granular masses, then permitting communication between the different compartments of the purulent collection. The lamellæ, however, are not destroyed at points immediately behind each other, but at any part that is in contact with the pus. The abscess proper consists, then, in layers of pus placed over each other, which are connected together by irregularly situated openings of variable size in the separating corneal lamellæ. It is only after some time that these projecting lamellæ deliquesce and the cavity of the abscess becomes single.

The pus in abscesses is under a certain pressure, and naturally presses against its boundaries. The bulging forward of the anterior or posterior wall is only a result of these mechanical conditions. It can, moreover, scarcely be doubted, that in large and quickly-forming abscesses, gangrenous destruction of some portions of the inflamed part is not unfrequently intimately connected with this state.

The lateral extension of the abscess is partially dependent on the progressing disease, but is also partly mechanical. The pus collecting in the interlamellar spaces separates the layers

more and more to give itself room, and, on account of the equality of the pressure exercised by the fluid, the individual layers of pus acquire a nearly circular shape. Particularly in the loose middle layers of the cornea does it find a favorable chance to spread out laterally. Hence the periphery of the abscess is usually in the middle layers, and as it extends beyond the actually inflamed part it often appears sharply bounded.

B. Besides the pressure, the weight of the pus also acts; hence it sometimes sinks down between the lamellæ of the cornea, pressing them apart. This condition, from its resemblance to the lunula of the nail, is called onyx, or unguis. Onyx (Fig. 3, *a*) generally lies in the middle interlamellar space, at its lowest part, moving inward or outward, according to the motion of the head. Its lower edge, *b*, does not reach quite to the corneal margin; the upper, *c*, is straight or concave, rarely convex—often, however, not sharply defined, but always forming an acute angle. Corresponding to the anatomical condition, onyx is almost always a flat layer, which is pushed in between the layers of the cornea, and which, when examined from the side, is seen to be separated from the iris by the entire anterior chamber.

Fig. 3.

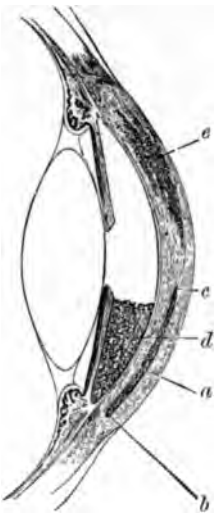

This evident distance of the anteriorly convex layer of pus from the iris, and its sharp upper border, above which may be seen parts of the iris lying below its level, form the diagnostic points between onyx and hypopion, *d;* for the latter lies in contact with the iris, and when viewed from above, presents a thickness equal to the depth of the anterior chamber. A further diagnostic symptom is the universally greater mobility of hypopyon on lateral motion of the head. This, however, is less significant, as onyces also occur which readily change their position, while hypopya sometimes do not move, on account of their firmness. The diagnosis is most difficult when they occur together and attain a high grade. Then the presence of the onyx can sometimes only be determined by the thinness of the cornea lying in front of it, and from the existence of an abscess or ulcer.

In some rare cases the discovery of the canal uniting the ulcer or abscess, *e*, and the onyx aid the diagnosis. This appears as a small pus-colored line, which runs from the under border of the abscess to the upper one of the onyx; it always exists, whether discoverable or not; sometimes, by pressure on the lower part of the cornea, this otherwise invisible canal may be filled with pus and thus brought to view.

The size of the onyx is very variable. Sometimes it is a small yellow streak around the margin of the cornea, and it requires a practiced eye to detect it; sometimes the vertical diameter is half a line; again, the upper border of the onyx unites with the lower border of the abscess; cases even occur where the abscess, being situated at the upper part, the entire cornea appears divided into an anterior and a posterior half by the onyx.

C. Corneal ulcers are very frequent. They usually occur primarily, that is, without precedent abscess or onyx. A circumscribed part of the anterior layer of the cornea clouds over, its surface becomes dull, assumes a peculiar rough appearance, and falls off, leaving a loss of substance, which spreads with the progress of the disease.

Any part of the cornea may become the seat of an ulcer, whose size varies greatly. Sometimes it is no longer than a hemp-seed; again it extends over nearly the whole cornea. Often the ulceration does not extend beyond the anterior layer, while in other cases, even with slight extent of the ulceration, its base seems to rest on Descemet's membrane, or it even perforates the cornea, so that the anterior chamber communicates externally.

The shape of the ulcer also varies. When central, it is generally round or oval; when peripheral, kidney-shaped or semilunar. The edges are usually smooth; the ulcer resembles a trough whose floor joins the surface of the cornea at an obtuse angle, so that the borders of the ulcer are almost imperceptible. But in other cases the edges are quite steep, or even perpendicular to the surface of the cornea and the floor of the ulcer. The surface of the side and floor are often smooth without perceptible prominences. But just as often in trough-shaped ulcers they appear *stair-like* (*treppenartig*) or in layers. In ulcers with perpendicular walls they often appear ragged, as if eaten away, or even overhanging. The floor of the ulcer as a whole is mostly concave and smooth, or uneven, with small elevations. Where the ulcer is extensive and deep, its floor is not unfrequently bulged forward by the intra-ocular pressure and projects above its edges as a vesicle. It is often covered by a fatty, purulent, or gelatinous product of varied amount. The ulcer and parts around it appear pus or brown-colored, since the prolifications in the neighborhood of the ulcer continue or even increase.

Vessels are often seen on the cloudy floor of the ulcer, especially when a vascular keratitis has been developed in its neighborhood. In fact the development of vessels about the periphery of the ulcer is not unfrequently very extensive; one fine net-work of vessels mingling with another surrounds the suppurating spot, but only a small number of the twigs go over the edge of the ulcer, to be lost on its floor. If the ulcer is on the edge of the cornea, so that part of it is in contact with the limbus conjunctivalis, or if perforation has occurred and a part of the iris prolapsed, granulations not unfrequently form on the floor. With continued development these project, and by their flesh-color and inclination to bleed, exhibit great vascularity. Cases, however, appear, where from the rapid casting off of the pus, all cloudiness in the ulcer is absent, and this then appears as a loss of substance with transparent walls.

When the ulcer is not in the lower edge of the cornea, onyx very often accompanies it; the pus from the ulcer having sunk down between the layers of the cornea and collected at the lowest point.

Causes.—1. These are in part the same irritating circumstances that excite other forms of keratitis. Doubtless great intensity, long duration, or frequent repetition of an injury may very much favor the proliferation, and thus cause a transformation of the process to suppuration. But this explanation does not answer for all cases. Sometimes very extensive ulcerations result from limited injuries of slight intensity and short duration, without sufficient cause for them being found in the constitution of the individual. In this regard chemical and mechanical injuries of all kinds, but especially wounds of the cornea, must be considered as very important. Suppurative keratitis is one of the worst enemies to all eye-operations in which the cornea is wounded. Concussions of the cornea *often*, torn, bruised, and unclean wounds *usually*, cause suppuration; and it is by this means that foreign particles in it are often removed.

2. A peculiar kind of corneal inflammation is the neuro-paralytic. It is devel-

oped with more or less hyperæmia and œdematous swelling of the conjunctiva, as a result of disturbance of conduction of the fifth pair of nerves. In incomplete paralysis of this nerve it is rare, usually remains partial, and does not generally go on to purulent destruction, but remains as simple infiltration, and frequently recedes. But in total paralysis of the branches of the fifth pair going to the eye, purulent destruction of the cornea often occurs. The entire cornea is then generally affected; it first becomes brawny, then gray, milk-white, and finally pus-colored; swells, and is destroyed to a greater or less extent, forming ulcers.

Anything that can limit or prevent conduction in the fifth pair of nerves may be considered as secondary causes of the disease, diseases of its central parts, wounds, tumors at the base of the brain, etc. But especially to be mentioned is meningitis basilaris in its various forms, including the epidemic cerebro-spinal meningitis (*Canstatt*, *Schirmer*).

A peculiar form of infantile encephalitis deserves especial mention at this point. It is marked by extensive fatty degeneration and hyperæmia of the white cerebral substance, especially of the hemispheres, and readily leads to shrinkage and induration (*Virchow*, *Klebs*). It is a rare disease and usually appears in an epidemic form. It then has a chronic course without fever or marked cerebral symptoms, but soon leads to progressive marasmus, with more or less impairment of the digestion and nutrition, and finally the patient usually dies from exhaustion with the symptoms of broncho-pneumonia. It is very rarely that children a few weeks old are attacked, but usually those from two to six months old. Such patients, who have been previously healthy begin to be ailing, and fail gradually, without the detection of any decided constitutional disease or affection of any organ. In the course of a few weeks a little photophobia appears in one or the other eye, slight lachrymation, and injection of the episcleral vessels, while a circumscribed portion of the cornea has a yellowish-gray opacity and suppurates. The ulcer then constantly extends in depth and extent, with little or any cessation, while the conjunctiva, as far as exposed by the palpebral fissure, becomes dry and flaky. In a short time the iris and all the internal parts are involved, the eye is destroyed by panophthalmitis, if death has not before this put an end to the process (*Frank*, *Fischer*, *Graefe*, *Hirschberg*).

During the course of severe constitutional diseases—typhus fever, scarlatina—corneal ulcerations occasionally occur, to which a neuro-paralytic basis may be ascribed (*Arlt*, *Graefe*), yet such ulcerations are very different from those just described, as regards their acute course and the accompanying symptoms, and perhaps it is better to classify them with the metastatic forms of disease.

The corneal ulcerations, on the contrary, which often appear in the later stages of epidemic cholera, are very decidedly of the neuro-paralytic character. They are always united with acute erosis of the conjunctiva.

This dryness is to be ascribed to the loss of lachrymal sensation and the want of power in the lid, but more remotely to the loss of sensation in the trifacial and the weakness of the reflex action thus caused (*Graefe*).

In the anæsthetic form of lupus (Spedalsked) the paralysis of the trifacial is also seen in neuro-paralytic ophthalmia (*Riegler*, *B ck*, *Danielson*, *Chisholm*).

In diabetes also, in very rare cases, such a local affection may appear (*Simrock*). At least in the later stages of the disease, paralysis of the different nerves are by no means unfrequently observed (*Seegen*) which are explained as diseases of the kind now under discussion.

Local anæsthesia of the ciliary nerves is also to be mentioned as a possible cause. Indeed, the ulcerations of the cornea found in glaucoma, extensive sclero-choroidal staphylomata, in exophthalmos occurring suddenly in Basedow's (Grave's) disease especially, are by many numbered among the neuro-paralytic ophthalmia, and referred to interferences in the conduction of the stretched or entirely interrupted ciliary twigs (*Graefe*).

3. Keratitis is often developed with, or as a result of, purulent panophthalmitis (see section on this) as well as whenever there is a deposit of pus or blood in the anterior chamber; then it causes perforation and the evacuation of the morbid pro-

duct; such a panophthalmitis may be either primary or secondary, and in the latter case are dependent on certain blood diseases, such as pyæmia, tuberculosis, typhus, puerperal fever, glanders, anomalous exanthemata, etc. They either begin in the meninges of the brain, and the inflammation thence extends along the sheath of the optic nerve into the eye, or the general disease affects the interior of the eye originally.

4. Not unfrequently suppurative keratitis proceeds from other forms of corneal inflammation, by increase of the process of proliferation. This occurs rarely in diffuse keratitis, more frequently in the vascular form, and most frequently in herpes, whose efflorescences, by extension of the inflammatory foci, readily change to ulcers, which no longer bear the herpetic character but perfectly correspond with those occurring primarily. Moreover, gangrenous or mortified parts of the cornea are demarcated by purulent foci, just as foreign bodies are, and so the parts which have become incapable of living are more rapidly cast off and the cure is hastened.

5. Finally, suppuration of the cornea often occurs in the course of blenorrhœa, diphtheritic conjunctivitis, etc., in fact in any conjunctivitis commencing with great intensity and proceeding with marked hyperæmia, swelling, and increase of temperature. For under such circumstances the inflammation is readily propagated from the conjunctiva to the cornea, and leads to extensive ulceration in the latter.

The Course of keratitis suppurativa is very variable and much influenced by the causes.

1. Where it arises from constitutional causes the whole cornea may become a mass of pus in a few hours or a couple of days; this quickly deliquesces or becomes gangrenous. Strangely enough, in these cases the symptoms of irritation are not always very decided; they vary in all degrees, and are often scarcely noticeable.

Under such circumstances, however, the suppurative keratitis is not always total, sometimes with or without symptoms of irritation, an abscess or ulcer of limited extent is developed in it. It is true this may extend and soon lead to phthisis corneæ, but it not unfrequently remains limited, and after a while is absorbed or cicatrizes like suppurative keratitis from other causes. It is, then, difficult to believe that the constitutional disease is limited to a part of the cornea. Probably external injuries, propagation of inflammation from the conjunctiva, etc., may be blamed as the immediate causes of these states.

2. The abscesses caused by gonorrhœal, purulent, or diphtheritic disease are not less rapid in their course.

3. The neuroparalytic is generally more chronic; cases, however, do occur which run their course in one or two weeks. But more frequently the paralysis exists a long time without the cornea showing any change; the corneal disease is not a necessary result. If it finally does occur, the points of inflammation sometimes remain unchanged for weeks or months, temporarily improve, again grow worse, and so on, or in their places come ulcers of very chronic course and slight inclination to extend; they even show a tendency to heal and again break out, and so it goes on till the process on the cornea ends.

4. The course of spontaneous or traumatic suppurative keratitis varies most.

a. Its development is often so rapid that the stage of gray cloudiness is so short as to be overlooked; within a few hours, or a day or two, a more or less extensive abscess is formed, or even the whole cornea changed to pus.

At the same time the symptoms of irritation in the ciliary vessels and nerves are sometimes very slight. Cases occur in which, in spite of the extensive formation of pus in the cornea, the conjunctiva and episcleral tissue are scarcely injected, the local temperature is normal, and pain absent; other cases begin with symptoms of irritation,

which may be excessive, but these soon subside and the process becomes torpid. These are usually cases where the immediate cause is obscure. Like cold abscesses in other parts of the body, these painless collections of pus are usually sharply bounded and quickly extend in depth and breadth, and even destroy the whole cornea. They are often complicated with iritis, and then extensive hypopyon frequently occurs. The occurrence of symptoms of irritation is generally a good sign; it shows the commencement of a limiting reaction, and this is usually first evinced by a gray cloudiness around the collection of pus.

These, however, are rare exceptions; where the keratitis is acute, the accompanying vascular and nervous irritation is generally decided. Especially where it has been produced by an external cause, hyperæmia of the episcleral and conjunctival vessels, heat, pain, and photophobia are apt to be excessive, although cases occur where the cornea suppurates with slight symptoms of irritation, as after cataract operations. This occurs not unfrequently in old, decrepit individuals.

b. In opposition to these cases with acute development of purulent collections, inflammatory corneal infiltrations occur, which, with more or less decided symptoms of irritation, exist for weeks, increasing and diminishing till suppuration finally shows itself.

5. When the abscess is once formed it generally runs its course quickly, in rare cases it remains closed for weeks. The same is true of onyx; small onyces often come and go within a few days, and vary greatly in regard to their depth. Large collections of pus, on the contrary, often exist for weeks before they disappear or change their conditions. The ulcer frequently advances and destroys large portions of the cornea, before limiting itself; in other cases it clears up almost immediately. Again it becomes chronic, the formation of pus continues for weeks, with less symptoms of irritation, the floor and sides of the ulcer remain cloudy, and constantly secrete pus, without the size of the ulcer varying much. When the ulcer cleans off, it frequently heals rapidly, but sometimes it remains without symptoms of irritation for weeks or months before completely filling up.

Results.—*A.* Abscess of the cornea is capable of resorption. The entire disappearance of small abscesses, especially in children, is not uncommon. But the larger the amount of pus and the older the individual the more rarely does this favorable result occur. If the pus does not break through and resorption gradually cease, extensive and thick leucomata are left; these depend partly on metamorphosed remains of pus, partly on new tissue, which has replaced that destroyed. If the abscess was extensive the whole cornea usually shrinks and changes to an opaque, tendinous plug, which closes the contracted and irregular sclerotic opening of the atrophying globe. Sometimes, in such cases, part of the pus changes to a fatty, chalky mass, which subsequently appears pressed into the cloudy part of the cornea, as a sort of concrement. On the whole, these are rare results in cases arising from blennorrhœa, etc., and are scarcely ever seen where the disease of the cornea occurs as a symptom of constitutional affection. Frequently, especially in the latter class of cases, the cornea is rapidly destroyed to the whole depth and extent of the purulent collection, and an open (and often perforating) ulcer is caused, which again cleans up and cicatrizes or spreads in all directions, and finally destroys a large part or the whole of the cornea.

Then the process sometimes seems to correspond more with necrosis, the cornea breaks up into a gray pultaceous mass, which lies on the iris for a time before falling, and but slightly resembles pus. In other cases the cornea mortifies completely and changes to a discolored,

badly-swelling pulp, or dry-wrinkled scurf, which subsequently falls off. Phthisis of the cornea results.

In by far the greater number of cases the deliquescence into pus occurs more slowly; collections of pus form in one or more points of the abscess, which gradually augment, unite, and break through. Sometimes the abscess perforates posteriorly, the pus is partly evacuated into the anterior chamber, and the anterior wall is not destroyed till later in the disease. As a rule, however, the anterior wall of the abscess is destroyed first, the collection of pus changes to an excavated ulcer, which, from progressive destruction of its walls, becomes an open ulcer, frequently perforates, and not rarely causes phthisis of the cornea or atrophy.

According to recent observation, which, however, requires confirmation, deep abscesses, with marked symptoms of iritation, accompanied by iritis, frequently perforate posteriorly and cause hypopyon. Then by oblique light it is said that we may see a second layer of pus behind the abscess, in contact with the membrane of Descemet, which connects with the abscess by an inverted, funnel-shaped plug of pus, and either directly perforates to the anterior chamber, or breaks through indirectly by the formation of an onyx on the floor of the chamber. Then the pus passes from the abscess to the anterior chamber. Sometimes, when the opening is directly into the anterior chamber, the aqueous enters the cavity of the abscess and bulges out the anterior wall. If the perforation occurs through an onyx this does not happen, for then the communicating canal is closed by intra-ocular pressure. In such cases the abscess often fills and empties itself posteriorly. (Gangrenous corneal abscesses. *A. Weber.*)

B. The onyx itself is of slight importance. When the collection of pus is not large, the onyx often disappears very quickly, and the cornea is generally left transparent.

This disappearance is not altogether dependent on resorption, the pus often escapes outwardly. For the onyx is connected with the abscess by a canal in the corneal tissue, and if the latter opens outwardly, or is from the first an ulcer, there is nothing to prevent the escape outward of the pus from the onyx.

In large onyces the prognosis is less favorable, leucomata usually remaining after them, for the layers inclosing the dependent pus are generally also much affected; besides, a part of the pus is transformed into an insoluble chalky mass and encysted in the cloudy layers. As a result of this participation of the lamellæ, a large onyx is apt to burst open and form an ulcer, which joins with the original collection of pus. In large onyces the extensive separation of the corneal layers has a bad influence on the nutrition, and may produce atrophy, necrosis, etc., the way for which was already paved by keratitis.

C. 1. The open ulcer may heal without opacity. In children especially, under favorable circumstances, even extensive and deep excavated ulcers fill up with transparent corneal tissue, and disappear without leaving a trace; or they leave a slight cloud, which, with time and the growth of the cornea, is lost sight of. In adults this result can only be hoped for when the ulcer is very superficial, and even then a superficial opacity is often left, which after partially clearing up, remains stationary. The cloudiness is generally more extended and thicker the more rapid the filling up of the ulcer.

2. In ulcers with abrupt edges, as in extended or deep excavated ulcers in adults, as a rule, only a portion of the loss of substance is replaced by transparent corneal tissue; the rest is filled up by a gray-white tissue, which, except as regards the opacity, corresponds with normal cornea in its histological character. Thus there occurs a more or less thick opacity or tendinous cicatrix, corresponding in form to the loss of substance.

3. The vascular, spongy new formations on granulating ulcers subsequently change to so-called epithelial or connective-tissue cicatrices, which latter, in peripheral ulcers, form a continuation of the conjunctiva, and by atrophying greatly, may cause false pterygium.

4. In ulcers which are of slight extent but deep, extending almost to the membrane of Descemet, the thin floor of the ulcer is often pushed forward (Fig. 4, *a*) into a vesicle, which from its thinness is generally transparent, at least at the summit.

Fig. 4.

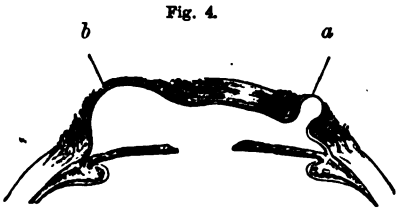

It was thought that this vesicle consisted entirely of membrane of Descemet, but on more careful examination it has been found that some of the posterior layers of the cornea proper are also engaged, and that even if at the summit of the vesicle, Descemet's membrane is exposed, the lateral walls at least have a covering of corneal layers, which layers increase in thickness at the border, for the floor of the ulcer descends stair-like toward the center.

This state has been called keratocele and *hernia of the cornea.* It leads almost always to perforation with its results. The aqueous escapes, the perforation closes, the vesicle forms again, etc. Sometimes, however, by the growth of corneal tissue, the walls are strengthened, and a cicatrix is formed which contracts, then the vesicle is flattened out, and the rupture of the cornea heals, leaving a flat cicatrix.

5. Large ulcers do not acquire so great a depth before bulging out; under favoring circumstances the protrusion reaches a high grade without the ulcer being deep. Frequently the base appears only slightly pressed forward (Fig. 4, *b*); in other cases the projection is vesicular, and the closure of the lids becomes difficult or impossible. This condition is called ulcerative corneal staphyloma.

The shape of the vesicle is spherical or conical, according as the coverings are of the same thickness throughout, or are thinner at one part. The zenith of the vesicle is not always at the center, but corresponds to the thinnest part of the floor of the ulcer.

In very rare cases the superficial layers of the cornea ulcerate throughout their extent, and the posterior laminæ forming the floor of the ulcer are pressed forward *en masse*, forming a total ulcerative protrusion.

The walls of the vesicle are at first mostly grayish or yellowish, and the surface is covered with a purulent deposit. The ulceration extends, the walls of the staphyloma become thinner, and finally a rupture occurs. Under favorable circumstances, however, the ectatic ulcer clears up, the development of tissue goes on more slowly, and the new elements assume a higher development. Hence the anterior wall of the vesicle is covered with a thick layer of neoplastic corneal substance, and a layer of cloudy epithelium; the result is a cicatricial corneal staphyloma. Sometimes, however, by atrophy and thickening of the new tissue, the staphyloma flattens or even disappears.

This condition is called keratectasia. Under such circumstances perforation soon occurs. Under more favorable circumstances, however, the base of the ulcer clears up, the proliferation of tissue becomes less intense, and the newly formed elements begin to pass into a stage of higher formation. The anterior wall of the vesicle is in consequence covered by a layer of neoplastic opaque corneal substance

and an opaque layer of epithelium, and the ectasia itself becomes permanent as a cicatricial staphyloma. Occasionally, however, a flattening if not an obliteration of the staphyloma is rendered possible by the shrinkage and thickening of the newly-formed superficial layer.

6. Large, and especially deep, ulcers often cause unevenness of the entire cornea, and, consequently, disturbance of vision. If there is a protrusion of the layers under the ulcer, surrounding parts of the cornea that are not ulcerated are also protruded. In other cases, however, the whole cornea flattens out, as the cicatrix shrinks and retracts with it the surrounding parts.

7. A frequent result of corneal ulcers is perforation. This occurs the more readily the larger and deeper the ulcer; being almost universal in those reaching to the membrane of Descemet. In this case the perforation may result from normal intra-ocular pressure; where the ulcer is shallow, the pressure must be abnormally increased. This is particularly necessary, where the floor of the ulcer has not become extensible by inflammatory change.

The abnormal increase of intra-ocular pressure may result from local increase of blood-pressure, or an increase of the contents of the globe. But it is much more frequently caused by a simultaneous contraction of the muscles of the eyeball. For these surround the globe in greater or less arcs, and, as it is fixed, compress it by their simultaneous action; since a curved muscle, when its ends can not be approximated by contraction, seeks to shorten itself from an arc to the chord of the arc.

These strong simultaneous contractions of the recti muscles are often, or even as a rule, associated. Intense or spasmodic contraction of the muscles of the body, lifting heavy weights, sneezing, coughing, vomiting, straining at stool, etc., may thus cause perforation of the cornea.

At the moment of perforation, if the opening is small, the aqueous humor alone escapes; as the vitreous is pressed on by the muscles, it drives the iris and lens forward against the posterior wall of the cornea. When the perforation is small, a prolapse of the iris is only possible at this time, if the opening is at the periphery of the cornea, or when the lens is absent, or a rupture of the zonula occurs, as occasionally happens at the moment of rupture in peripheral corneal perforations.

For where the perforation is peripheral, the direction in which the aqueous escapes is nearly parallel to the surface of the iris; and, while escaping, it readily removes the margin of the pupil, corresponding to the perforation, from the lens, and pushes the iris into the opening. If the perforation be somewhat further from the margin of the cornea, the aqueous can not cause a prolapse at the moment of perforation, as there is only a minimum of aqueous behind the iris, while that in front of it escapes perpendicularly, or at least at a great angle to it; so that it is rather pushed away from the opening. If, however, the lens be absent, or the zonula ruptured, the case is different. For then the vitreous has a chance to press into the perforation, and also push in the portion of iris in front of it.

The intra-ocular pressure is diminished or removed by the escape of the aqueous, and in the intra-ocular vessels the mechanical resistance and muscular contractility of their walls alone oppose lateral pressure; if these have suffered, ruptures easily occur, a choroidal or retinal hemorrhage takes place, and may prove serious. In a normal state of the vessels, this is not to be feared; here, at most, a dilatation of the vessels and subsequent passive hyperæmia of the choroid and retina occur.

a. If the floor of the ulcer simply breaks through, while still thick, and the deeper layers have not been affected by the ulceration, the edges will sometimes come together and heal by the first intention. Then the aqueous collects again, the iris

and lens resume their former positions. This may be repeated several times, and healing take place as if there had been no perforation.

b. If the perforation be small and ulcerated, or a rupture be only partly healed by first intention, it often happens that the part of the anterior capsule or iris in contact with the opening adheres to it, and thus stops up the wound without entering it; whereupon the aqueous again collects, and the anterior chamber is re-established.

If the perforation is central, a part of the anterior capsule is generally glued to the edges of the opening, while the iris remains free; when the aqueous collects, the lens is pressed back. Often the capsule breaks loose from the plug that has formed in the perforation, or draws a small portion back with it, and the perforation remains closed, although the crystalline resumes its natural position. In other cases the entire plug accompanies the lens, the opening is renewed, the aqueous again escapes, and this may be repeated several times, until finally the plug has greatly increased in size, and remains attached to the edges of the wound, so that it can only partially follow the retreating lens. The corneal ulcer may heal with, or more rarely without, a cicatrix or superficial opacity; while the remains of the plug on the anterior capsule are absorbed, or cause a chalky deposit, forming a so-called central capsular cataract. If the corneal perforation is at some distance from the center, with a small posterior opening, a portion of the pupillary margin, or of the breadth of the iris, becomes glued to it (Fig. 5); but this often becomes free again, with the reformation of the anterior chamber, the muscles and elasticity of the iris commence to act, and they draw back the part glued to the cornea. In adhesions of slight extent, detachment follows as a rule the more readily, when the displaced long fibers and sphincter pupillæ so act on the point of adhesion *c* of the iris, that their forces, *a* and *b*, nearly combine, and the resultant *d* is almost a radius of the curvature of the perforated cornea. Frequently no trace of the attachment remains on the cornea, occasionally only a speck of iris pigment. Sometimes, under the traction of the iris, the attaching plug is drawn out to a few filaments, which subsequently rupture and disappear, or are left attached to the corneal cicatrix, and extend thence to the iris. In some cases the attachment of the iris remains; this is called partial, anterior synechia.

Fig. 5.

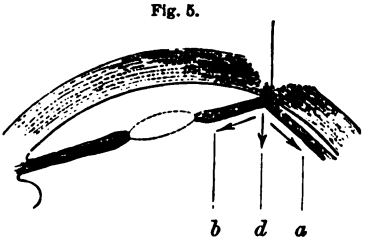

c. In perforations, whose posterior opening exceeds a millet-seed in size, the results are generally different.

If the cornea be perforated in the center, the results may, it is true, be the same as, or similar to, those above mentioned. But generally as the pupil is contracted by the decrease of intra-ocular pressure, consequent on escape of the aqueous, its edges come in contact with and adhere to the neoplastic formation plugging the perforation (Fig. 6). The capsule, whose middle part *a* is glued to the edges of the perforation, may be broken loose by the renewal of the aqueous, and, by resorption of the part of the plug remaining attached to it, may again become transparent. But the visual power remains limited, even when the pupillary margin is freed, by the traction of the dilator muscles, for the pupil remains wholly or partly behind the opacity left by the corneal ulcer

Fig. 6.

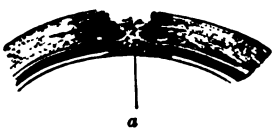

when healing. But the adhesions are often strong enough to maintain the connection between the lens and cornea, notwithstanding the pressure of the collecting aqueous, so that the anterior chamber is not re-formed.

If the cornea rupture at a greater distance from the center, as the pupil contracts after the escape of the aqueous, its border falls beyond the point of perforation, and part of the breadth of the iris enters the opening, and is kept there by the pressure of the lens and vitreous. Hence the iris covers the opening without fully closing it, the aqueous has free exit; so long as this is possible the condition remains the same unless the ulceration progresses. Inflammatory proliferation begins sooner or later in the exposed portion of iris which thus becomes glued to the edges of the perforation. The aqueous again collects, the lens resumes its position, the iris muscles may again act, and if the adhesions are not too firm, the iris may partially break loose and the aqueous again escape, and this may be repeated for weeks. Finally the adhesions become so firm that the muscular power of the iris cannot break them up. The aqueous collecting, now presses against the posterior wall of the cornea, and the iris is stretched through the opening as through a frame, and extruded in the shape of a vesicle, forming a prolapse of the iris (Fig. 7). This varies from the size of a millet-seed to that of a pea. The walls of the vesicle are thin, hence the slightly illuminated fundus of the eye appears black.

Fig. 7.

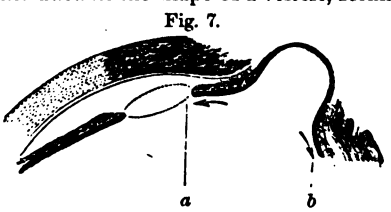

The gradual increase of the vesicle depends chiefly on the stretching of the originally exposed portion of iris, which is adherent around the edges. An addition to the portion of iris involved only occurs if the neoplastic tissue is torn (by the pressure on the vesicle from behind) and gives way somewhat. But this giving way is, as a rule, very slight, the resistance of the adhesions being increased by the action of the muscles of the iris, which keep this membrane tense, and strive to draw it away from the opening.

Not unfrequently the vesicle ruptures, especially when it is large, since with the extent of the prolapse the amount of the intra-ocular pressure acting on it increases. After this second rupture the edges unite, the vesicle forms again, etc. Finally after a perforation, the walls of the vesicle folded together are united by inflammatory product to a plug which thickens more and more, and after closure of the opening offers sufficient opposition to the pressure of the aqueous, and becomes a flat corneal cicatrix, into which the prolapsed portion of iris is transformed, leaving only a little mass of black pigment. The iris is then adherent around the posterior border of the cicatrix. Under such circumstances the pupil is free, at most a little elongated, but quite movable, and as the opacity is to one side, vision is good or only limited. This limitation is mostly dependent on the loss of function caused by the attachment of the iris, and not on the covering of the pupil.

But the case is less favorable when a portion of the pupillary margin of the iris is attached to the perforation. This may occur at the time of the perforation; or when a part of the breadth of the iris was originally exposed, it may happen from an extension of the ulceration. At other times its immediate cause is the partial deliquescence of the product that glues the exposed portion of iris to the edges of the ulcer; for, in the latter case, the parts of the iris attached to the borders of the opening are easily torn loose by the pressure of the aqueous, and the pupillary margin of the part engaged is driven into the perforation by the escaping aqueous.

If the ulceration does not proceed further, the prolapsed pupillary portion re-

mains glued to the edges of the perforation, and the opening is closed by the formation of a plug (Fig. 8) which posteriorly is in contact with the lens and vitreous. Subsequently, while the lens, under the pressure of the collecting aqueous humor, again becomes free, the newly-formed mass gradually thickens to a cicatrix, to which, naturally, the engaged part of the pupillary zone of iris remains attached. Thus, in proportion to the amount of the border engaged, the pupil is lessened, and falls partly or entirely behind the corneal opacity, so that vision is more or less impaired.

Fig. 8.

This state is made still worse by the fact that when the aqueous escapes the pupil contracts, so that even with a small perforation a relatively large proportion of the pupillary margin is brought in contact with its edge and there retained. Besides, after the closure of the perforation, the iris muscles begin to act, but the circular muscle has gained a fixed point at the plug, toward which it contracts. Thus it successively brings new portions of pupil near the plug and renders their attachment possible, especially when the iris tissue is extensively inflamed. In fact where the pupillary margin is thus exposed and subsequently attached to the cornea, we often see (especially in peripheral perforations) the opposite half of the iris distorted toward the corneal perforation, and the center of the pupil is displaced in the same direction. The pupil then becomes elongated, even slit-shaped, and the margin furthest from the perforation gradually approaches it; in some cases it even reaches the perforation and becomes adherent to it, so that the pupil is entirely closed.

If the exposed portion of the pupillary zone is somewhat extensive, that is, if the diameter of the perforation is considerable and the pupillary margin falls near the central border of the opening, after it has become adherent, the exposed portion of iris may be expanded to a vesicle, while its margin remains attached to the central border of the perforation. Sometimes it also happens that not only the part of the iris in question, but a part of the plug to which the pupillary margin is attached is protruded, and hence arises a prolapse whose central portion consists of newly-formed substance.

d. In perforations where the posterior opening exceeds the size of a pea, even where it is peripheral, a portion of the pupillary margin almost always becomes engaged. The lens pushing it forward, the exposed portion of iris is retained in contact with the posterior wall of the cornea, where it inflames, begins to proliferate and becomes attached to the edges of the perforation. The contracted pupil is at the same time closed by a plug of exudation substance, which is attached on the one side to the anterior capsule, on the other to the opening in the cornea. If the process continues, granulations soon form on the exposed portion of iris, which gradually thicken and close the opening with a cicatrix. Frequently after its attachment to the margin of the perforation, the aqueous, pressing from behind, bulges the iris out into the form of a vesicle, as large as a pea or bean, causing a prolapse of the iris, which is usually called a partial iris staphyloma (Fig. 9). This vesicle may burst, and the collapsed wall form the foundation for a flat cicatrix. But the vesicle often continues, the walls develop and change to a thick cicatricial tissue, and a partial cicatricial staphyloma is the result.

Fig. 9.

In these large perforations, the lens and part

of the vitreous not unfrequently escape at the moment of rupture or subsequently. The globe collapses, and, as a consequence of the entire removal of intra-ocular pressure, marked hyperæmia of the uvea and retina result. The perforation generally closes in a few days, since, by collapse of the globe, the edges of the corneal opening approach each other, and the perforation is also partly covered by the prolapsed portion of iris, and the pupil is obliterated. Subsequently the prolapsed iris becomes adherent to the edges of the perforation, and forms the foundation for a more or less extensive and thick corneal cicatrix, which may remain as such or become a partial cicatricial staphyloma. But usually the cicatrix remains flat and even, the non-ulcerated portion of cornea shrinks up, the anterior half of the eye flattens and atrophies. In many cases, after partial evacuation of the globe, intense inflammation of its remaining contents occurs. On account of the hyperæmia resulting from absence of intra-ocular pressure, there may be hemorrhage, and the cornea, iris, and even a great part of the choroid and retina may suffer from purulent inflammation; the pus is evacuated and the collapsed globe finally shrinks to the size of a pea or hazel-nut.

In rare cases, at the moment of perforation, the vitreous advances so suddenly, that part of the retina adherent to its outer wall is torn loose from the ora serrata, prolapses and becomes attached to the cicatrix. Where there was previous disease of the choroid, vessels also burst and a mass of blood is poured out between choroid and sclera, sometimes to such an extent as to loosen the former from the latter entirely; or even the ciliary muscle is ruptured, and the blood flows outward. What remains coagulates and organizes, while the eye gradually atrophies.

c. If the cornea is destroyed by purulent inflammation or necrosis, of course the lens and vitreous escape more easily, and in such cases phthisis of the globe frequently results. Cases, however, occur where the lens retains its normal relation to the ciliary body and preserves its integrity, or where only the anterior capsule is torn and the nucleus of the lens evacuated. Then the iris appears stretched behind the abnormal opening, the pupil is contracted and is soon closed by a neoplastic plug, which posteriorly unites intimately with the anterior capsule. The iris proliferates, swells, becomes more vascular, and fleshy warts arise on its surface. By these its exterior zone is united with the ulcerated edges of the perforation. Subsequently this new formation thickens to a cicatrix, which gradually contracts to a round or oval plate as large as a pea. The anterior zone of the sclera is thus deviated toward the optic axis, and is not unfrequently much flattened; while the globe, as a whole, atrophies.

Moreover, it not unfrequently happens that, after closure of the pupil and attachment of its margin to the anterior capsule, the exposed iris is partly or entirely bulged out by the collecting aqueous into a vesicular protrusion, beyond the scleral opening. This is called total iris-staphyloma.

Fig. 10.

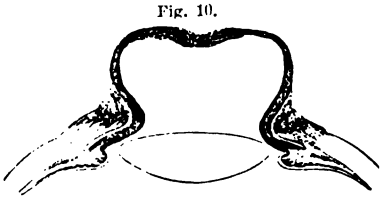

If the entire iris is prolapsed, the zenith of the vesicle usually appears umbilicated (Fig. 10), as the plug closing the pupil does not stretch so much as the iris itself. This result supposes, of course, that the plug has loosened from the anterior capsule, or that the zonula has ruptured and the lens has followed the plug into the concavity of the staphyloma. Where the anterior capsule maintains its normal position, and the pupillary margin of the iris has not broken loose from it, the bulging can only occur at one or more parts, while the remainder

of the iris and its pupillary zone maintain their normal position, and gradually change to a flat cicatrix. The staphyloma then usually appears puffed up in places.

The protrusion is not always equal at all points. Not unfrequently adhesions form between the posterior surface of the iris and the anterior capsule, which present obstacles to the protruding action of the aqueous; they are often stretched out to threads before they rupture, and they retract certain points on the surface of the iris. In other cases the tissue of the iris itself thickens, and at certain points of the vesicle, tendinous opacities form which are less extensible. In both cases the surface of the staphyloma appears uneven (Fig. 11), with furrows running in different directions. It acquires a distant resemblance to a bunch of grapes, hence the name staphyloma iridis racemosum.

Fig. 11.



Staphyloma of the iris may burst and again fill up, or after repeated ruptures may remain folded up, and give rise to a flat cicatrix, or the walls may thicken and form a complete corneal staphyloma. Then the eyeball is generally enlarged, though its deeper structures may atrophy.

Treatment.—The indications are to limit and suppress the suppuration, to present the best circumstances for a cure, to shun the secondary accidents, and lessen, as far as possible, bad results.

1. The same means may be used to hinder suppuration, and thus arrest the progressing destruction of the cornea, as in other forms of keratitis. Of course the cause must first be removed. Occasionally this suffices to induce the process to recede. In the neuroparalytic form especially the application of a protective bandage, which keeps off injurious influences and may prevent abnormal dryness, usually suffices to cause resorption of existing infiltration or cicatrization of ulcers. The indications for treatment depend greatly on the intensity of the existing symptoms of irritation.

a. When the process begins with decided symptoms of vascular and nervous irritation, and so long as it progresses with great hyperæmia, chemotic swelling of the neighboring vascular parts, as well as with great local elevation of temperature; strict antiphlogistic regimen, cold applications, and, if required, local blood-letting, are indicated. Besides these, instillations of atropine repeated several times daily, and, when the affection is very painful, hypodermic injections of morphia are required.

b. Where the vascular as well as the nervous symptoms are only moderate; besides suitable regimen, we will only need to use the protective bandage, and one or two instillations of atropine daily. The mydriatic is dangerous, however, if the abscess is so situated that a prolapse of the pupillary portion of the iris is to be feared should perforation of the cornea occur while the pupil is dilated; under such circumstances it had better be avoided if possible.

c. If the abscess is developed with relatively slight vascular irritation but intense ciliary neurosis, hypodermic injections of morphia should be combined with the energetic use of atropine and the protective bandage. If this does not lessen the severe nervous symptoms, we may have a trusty nurse apply temporarily (and alternately with the protective bandage) compresses wet with warm water or chamomile tea of about 100° F.

At the same time the atropine is to be continued; occasionally the sufferings of the patient

are very much eased by this procedure, without our having to fear much extension of the abscess. Perhaps this result is due to a diminution of tension in the cornea.

But so soon as the ciliary neurosis recedes, that is, when the pain is lessened or removed, the warm applications should be given up. Their too long continuance usually causes severe conjunctival hyperæmia, or even inflammation, and may lead to annoying increase of suppuration of the cornea (*Graefe*, *Classen*, *Stavenhagen*).

In the greater number of cases this method of treatment will be found sufficient. But it may occur that the remedies named have no effect, or that the irritation, especially the exceedingly painful ciliary neurosis lessens, while the suppuration continues; the inflammatory product extends further in the adjacent cornea and thus causes it to be destroyed, that is, the inflammatory point extends and is finally connected with iritis, and often with hypopyon, and thus the eye is completely lost by phthisis of the cornea or suppurative panophthalmitis.

This resistance of the disease to remedies which are at other times effectual, may be thus explained. Resorption is difficult when there is a great amount of purulent infiltration, and is not quite enough to prevent a perforation. But this perforation does not always occur by the shortest way, but very frequently not until the pus has become widely distributed and a large portion of the cornea is destroyed. Besides, the advancing destruction of the cornea is not always to be ascribed to the inflammation and the deliquescing properties of the infiltration, but in part to the decided pressure under which the infiltrated and the tissue adjacent to it are placed. It has been sufficiently shown how destructive is pressure to the nutrition of infiltrated tissue.

From what has been said, we see that the direct indication is to evacuate masses of pus in which these evils are threatened, or at least by relaxation of the tension of the cornea to place it in less danger. Indeed it is a recognized fact shown by experience, that suppuration in the cornea heals rapidly after perforation and prolapse of the iris have occurred. It does not then advance, but the material that can not be healed is thrown off, the floor of the ulcer clears up, and it soon heals. We were thus led to imitate this natural process, but at the same time to avoid any further loss of substance and prolapse of iris. Paracentesis of the cornea thus became a means of treatment.

This operation appears to be especially indicated—

1. In large abscesses and onyces.

2. In abscesses which have opened posteriorly, but which fill up rapidly and show a great disposition to extension.

3. In suppurations of any kind accompanied by intense vascular and nervous irritation, and when the tissue is exposed to great pressure on account of the amount of the infiltration.

4. The evacuation of pus into the anterior chamber, or even into the deeper parts of the eye, renders the indication more decided, even renders it absolutely necessary.

According to the above, the object of the operation is not by any means simply the evacuation of the infiltration. If it were so, it would be fruitless in most cases. For pus that is fluid and capable of being evacuated, is rarely found at a time when paracentesis could serve as a preventive against progressing destruction of the cornea. In spite of this, even in these cases the result of paracentesis is often beneficial. The pain is usually lessened or altogether removed, and frequently the progress of the abscess, as well as the destruction of the corneal elements, in it are arrested. It is, moreover, certain that the same results are attained when the puncture is made outside of the abscess in the sound cornea.

This rather disproves the recently urged necessity of evacuating the abscess at all hazards; for this purpose it was recommended to enter the abscess at its lower extremity, and pass from it to the anterior chamber at its upper border. Thus the aqueous humor would flow through and thoroughly wash it out; any pus remaining is to be picked away with toothed forceps. It is said that in this manner a cure will be assisted, since the aqueous will not evert the edges of the inner wound by pushing them into the track of the wound, and thus prevent union (*A. Weber*).

If an abscess has been partly or entirely emptied by paracentesis or spontaneous rupture, and its anterior wall then appears thin, and there is little prospect of its continuing intact, it is best to remove it with the sharp edge of a Daviel's spoon, so as to change the cavity of the abscess to an open ulcer. When undertaking the operation we must always remember that the diseases demanding paracentesis are in themselves serious, and that the operation does not by any means offer a certainly favorable result, but rather that in spite of it the process continues, and may result badly.

Undoubtedly much of this want of success is due to the fact that the opening readily closes again, the unfavorable conditions return before the resolution of the disease is assured. We should therefore make the opening as broad as possible, and in urgent cases often reopen it by means of Daviel's spoon, or a delicate spatula.

The frequent insufficiency of one paracentesis led to the trial of iridectomy at a time when the iris was considered to be drawn into the process (*Graefe*, *Mooren*, *Classen*). The results on the whole were satisfactory. This may be explained by the large opening, and the more difficult consolidation of the line of union, without supposing that the cutting off of the iris had anything to do with it. The peripheric linear section with the small knife is now preferred to the lance-shaped knife (*Graefe*). Yet even iridectomy has not answered all the expectations (*Saemisch*).

Very recently it is believed that the proper treatment has been found in a free transverse section of the purulent collection. This operation is performed on ulcers which are very much inclined to extend superficially, especially toward one side, and which are apt to be complicated with iritis. The eyeball is fixed, the lids held apart, while a Graefe's cataract knife is entered on the outer border of the cornea within the still healthy corneal substance, carried rapidly through the anterior chamber, and brought out on sound tissue, so that the floor of the ulcer shall, as it were, be halved, doing this last by a sort of sawing motion. The eye is then covered by a simple compress, and treated with atropine. But since the wound will close within an hour, or even earlier, in order to be certain of an effect it should be opened with a delicate spatula, at first twice a day, but subsequently at longer intervals (*Saemisch*). The results of this treatment are very highly spoken of. Yet we should not decide as to the relative value of this operation over a simple paracentesis until further comparisons have been made. It is certainly a much more severe procedure.

After paracentesis of the cornea the protective bandage should be applied, the patient should be kept in bed, while a general antiphlogistic regimen is maintained. In all cases an atropine solution should be repeatedly dropped in the eye. But if the extension of the purulent infiltration and the severity of the inflammation forbid the hope that enough of the cornea will be preserved for an artificial pupil, it is advisable to favor suppuration by means of compresses dipped in warm water, or by the application of poultices, and thus prevent the suppuration from lasting for

This book is the property of
COOPER MEDICAL COLLEGE
SAN FRANCISCO, CAL.
and is not to be removed from the
Library Room by any person or
under any pretext whatever.

weeks, and finally even endangering the general condition of the patient. In total abscesses of the cornea, especially when it is an accompaniment of suppurative panophthalmitis, such a treatment after paracentesis and partial evacuation of the pus from the globe is especially to be recommended.

d. In the case of ulcerations which are not irritable, but which steadily advance, especially superficially, very carefully applied warm compresses, alternating with the bandage, and the instillation of an atropine solution, are apt to do good. A little reaction is usually seen after this treatment: the conjunctiva and episcleral tissue become injected and swell somewhat, the eye becomes more sensitive, and an opaque line of demarcation forms around the ulcer, over which the pus with difficulty advances.

Generally speaking, the rule is to make the applications the warmer, the less the irritation. Yet the temperature should never exceed 106° F. As fast as the reaction sets in, the heat of the applications should be lessened, and finally only the bandage and atropine employed. In case the reaction is very great, we may perhaps be obliged to employ cold applications, leeches, and so on. The existence of iritis and hypopyon where there is no irritation, does not contraindicate the hot applications.

The cause has also no influence on the indications for this treatment (*Graefe*). With careless patients and attendants warm compresses are apt to be harmful, and the bandage may as well be substituted for them.

e. & *f.* Irritating agents are to be used in chronic ulcers which exist for weeks continually secreting a small amount of pus, and which resist all treatment, but steadily advance in depth and surface; also in ulcerative losses of substance, which, after having cleared up, do not show the slightest tendency to fill up, and which remain for weeks with an entire absence of all symptoms of irritation. They are to be used with care. Their object is the excitation of the nutritive process in the cornea, and thus favor the formation of new corneal tissue. The applications most to be recommended are the ointment of the yellow oxyd of mercury, and pencilings with pure or dilute tincture of opium. Warm compresses do very little good in such cases.

The use of solutions containing lead as well as the instillation of collyria of acetate of lead, nitrate of silver, sulphate of zinc and copper, in which there is laudanum, should be avoided. These solutions readily form precipitates on the floor of the ulcer, which adhere very firmly, and when used for a long time become incrusted, and since they become covered over by granulations, become actually incapsulated and leave dense opacities.

More dangerous still the use of the real caustics, especially the much-vaunted nitrate of silver. Even the most careful and delicate touching of the base of the ulcer with nitrate of silver in substance, is apt, on account of the ready solubility of the pure agent, to cause great destruction of tissue, and thus considerably enlarge the ulcer. Besides, the reaction after such a procedure is usually very severe, and in consequence the suppuration is increased instead of lessened, and the loss of substance grows larger.

2. When the inflammation has passed its hight, and the diminution of the accompanying irritation shows that it is on a decline, when the ulcer has ceased to enlarge, we will find any very active treatment to be useless, and it may even prevent healing. The treatment should then be confined to the removal of all harmful influences, to which end the eyes should be carefully protected, especially by the wearing of a bandage. When the sensitiveness of the eye is completely removed, and

the loss of substance of the cornea is completely filled up, the patient may gradually, and with the greatest care, return to his ordinary employment.

If, after the ulcer has filled up, an opacity remains, we may try the insufflation of calomel, and subsequently the ointment of the yellow oxyd of mercury for the purpose of clearing it up. But these agents should be used with the greatest care and at first only experimentally.

3. Besides these general indications the peculiar circumstances of each case of suppuration will furnish a number of special ones, whose exact carrying out is not less necessary, if we desire that the treatment shall in some degree answer the above detailed requirements.

In open ulcers we should pay especial attention to any projection forward or bulging of the base of the ulcer.

Since we have no means of increasing the resisting power of the thinned cornea, we should avoid with the greatest care the momentary increase of the intra-ocular pressure. The use of the protective bandage is the best means of accomplishing this. Of course it increases the intra-ocular pressure, but, since it acts directly upon the anterior wall of the globe, it neutralizes the intra-ocular pressure in part, exactly in the position in which this can do harm. It is also of the greatest importance to avoid powerful contraction of the recti muscles. For this purpose we may advise rest, best in the recumbent posture, and especially should the patient avoid sneezing, coughing, vomiting, straining at stool, crying, stooping the head quickly, and so on.

When the extent of the purulent collection and the intensity of the inflammatory symptoms forbid all hope of saving a sufficient portion of the cornea for an artificial pupil, it is advisable to hasten the formation of pus by warm applications, and thus prevent the suppuration from going on for weeks, and injuring the general health of the patient. In total abscess of the cornea, where it is one of the symptoms of purulent panophthalmitis, the above proceeding is especially to be recommended after paracentesis. In desperate cases the enucleation of the globe is then sometimes justifiable.

In open ulcers, besides assisting the formation of pus, we must attend to any bulging out of the floor of the ulcer. The cornea should be supported by a "protective bandage," in spite of the fact that the total intra-ocular pressure is thus increased. If cold be indicated at the same time, ice compresses may be used to act by their weight and temperature. They diminish intra-ocular pressure by lessening the amount of blood in the eye. Spasm of the recti muscles should be prevented as much as possible, by having the patient remain in bed, and avoid sneezing, coughing, straining, &c.

In extensive deep ulcers, this does not always suffice to prevent perforation. Hence, if this is imminent, it is advisable to perform paracentesis at the thinnest part of the floor of the ulcer, after a previous dilatation of the pupil. Or, in case there is a large central ulcer which renders it probable that there will be a thick cicatrix, which will require an artificial pupil, we may try an iridectomy. This often prevents an extensive rupture and an enlargement of the opening by progressive destruction of the floor of the ulcer.

In restive and struggling patients, it is advisable to undertake the operation under anæsthetics, in order to prevent strong contractions of the muscles. The eye should be covered by a protective bandage while the anæsthetic is being given. There will always be some difficulty in performing the operation, and the ulcer often ruptures in consequence of the great muscular contraction before the incision is made, or, at least, before it is completed.

After artificial or spontaneous perforation, antiphlogistic regimen, but especially rest and the application of a pressure bandage, are strongly indicated. In this case the pressure bandage also has the object of increasing to some extent the much diminished intra-ocular pressure, and lessening the tendency to passive congestion, hemorrhage, and inflammations of the deeper parts of the eye.

A second very important and never-to-be-neglected rule is the removal of the pupillary margin from the vicinity of the thin part of the ulcer. Where the perforation appears probable, or even possible, as well as when it is to be artificially produced, it must be remembered that the attachment of the *pupillary margin* to the edges of the perforation injures the eye as an optical instrument more than the attachment of a part from the *breadth* of the iris or the anterior capsule.

In small ulcers, and particularly in cases where the floor of the ulcer is deeply excavated at a very circumscribed spot, and perforation threatens, these requirements are easily fulfilled. If such an ulcer or the thinnest part of an extensive ulcer be near the center of the cornea, the pupil must be dilated as much as possible. In peripheral ulcers it must be *contracted*. If the perforation is to be expected at about the middle point of one of the meridians of the cornea, the pupil may be either much contracted or much dilated. But inasmuch as the means for continued dilatation of the pupil are more trustworthy than those for its contraction, the former is preferable. It is well known that the mydriatics serve to dilate the pupil, and keep it dilated; for the opposite purpose we use the preparations of calabar-bean. If the perforation has already occurred, and a part of the iris distant from the pupil lies over or in the opening, the activity of the sphincter must not be weakened by the use of mydriatics; but, on the contrary, if a slight irritant would not be dangerous, calabar preparations should be used. But in all other cases atropine should be used to keep the pupillary margin away from the opening, and prevent the adhesion of large portions of it with the exudation plug.

In peripheral and very small perforations, the perfect action of the contractor of the pupil is of great use, because, after restoration of the anterior chamber, it facilitates the separation of the portion of iris attached to the edges of the wound. But in more extensive perforations, where the formation of an anterior synechia is not to be avoided, it seconds the opposition of the adhesions to the traction of the part of the iris which is exposed and bulged forward by the aqueous, and may thus impede the repeated opening of the anterior chamber, and especially may prevent any of the pupillary margin from being subsequently pressed into the opening.

If the prolapse bulges forward, and the vesicle increases more and more, on account of the relative increase of the pressure on its posterior wall, it is possible that, in spite of the contraction of the sphincter, the adherent new formations may give way, and the pupillary margin may be pressed into the opening. To prevent this, the projecting piece of iris should be snipped off with a pair of scissors curved on the flat, and a protective bandage worn till the perforation has completely healed.

Cauterization of the prolapsed portion of iris is very dangerous. The subsequent reaction is very severe, and injurious iritis not unfrequently occurs. Instillation of laudanum is also harmful, as, on account of the severe pain that this remedy causes, strong contractions of the muscles of the eye are usually produced, and these may cause enlargement of the prolapse, new perforations, and even prolapse of the pupillary margin. Attempts to reduce prolapse of the iris by means of sounds or other instruments are fruitless, and, on account of the mechanical irritation they cause, are dangerous.

If the ulceration be extensive, and a large perforation is to be feared, mydriatics are always to be used. Of course we can rarely remove the pupillary margin from the vicinity of the future perforation. Mydriatics are useful from the fact that if the pupil is widely dilated when a prolapse occurs, a relatively smaller part of its extent becomes engaged in the opening than when the pupil is contracted; and the resulting corneal cicatrix is less apt to impair vision.

We should here remark that, under such circumstances, instillation of atropine may readily prove dangerous in anxious and restive patients; for they usually contract the muscles of the eye with all their power, at the moment the lids are opened and the solution dropped in. Thus, not only perforation of the cornea, but evacuation of the lens and vitreous, may be caused. In such cases it is advisable simply to depress the lower lid with the finger, and paint its inner surface with a strong (three to four grains to ℥j.) solution of sulphate of atropia.

If the cornea is already largely perforated, and a considerable portion of the iris with its pupillary margin exposed, the indications are to oppose the protrusion or staphyloma of the iris and malcurvature of the now ulcerated portions of cornea. A pressure bandage is here absolutely necessary, and it must be carefully worn till complete cicatrization of the cornea has occurred.

If staphyloma of the iris be already developed, it is best to split it from end to end with a cataract knife, or to remove part of it by passing a cataract knife through its base and cutting off the flap thus formed with scissors curved on the flat. After either operation a pressure bandage must be worn till complete cicatrization. (See treatment of cicatricial staphyloma.) Simple paracentesis of the staphyloma is less certain in its results and must often be repeated.

If the lens and part of the vitreous be already gone, we must try to prevent further injuries, and limit as much as possible the formation of pus by the application of the pressure bandage, and regulating the diet, &c., of the patient. If, however, phthisis of the globe fairly begins, it is best to hasten suppuration by warm applications, and thus terminates the process.

Opening the Anterior Chamber—Paracentesis of the Cornea.

Indications.—The operation appears to be indicated—

a. In extensive abscesses in the cornea, when it is desired to evacuate fluid products or to remove a pressure injurious to the tissue, or to prevent the protrusion and rupture of the floor of an ulcer.

b. For the purpose of removing large quantities of pus, blood, swelled portions of cataract, &c.

c. Perhaps in diffuse keratitis, for the sake of relaxation.

Quite recently it is said that a kind of magic remedy has been found in systematic and unlimited repetitions of paracentesis, that its influence on the nutrition benefits almost all possible diseases, removes commencing congestion and atrophy, cures cataract, glaucoma, &c. (*Sperino*). Unprejudiced observations, however, have destroyed these unbounded hopes and shown the operation to be ineffective.

Operation.—The patient should lie down. The lids should be opened as wide as possible, and held so, while a lance-shaped knife is passed obliquely through the abscess into the anterior chamber (Fig. 12), making a wound one and a half to two lines long. The incision should always be made at some distance from the margin of the cornea, and obliquely to its surfaces, because prolapse of

Fig. 13.

the iris is thus best avoided. It is hardly necessary to remark that, after traversing Descemet's membrane, the point of the knife should be turned, to avoid wounding the anterior capsule.

Immediately after the operation, a secure and well-fitting pressure bandage should be applied, the patient kept quietly in bed, and otherwise treated as after the formation of an artificial pupil. After two days the wound is usually healed and the danger caused by the operation is over.

[A stop knife is safer for the performance of paracentesis than the ordinary lance-shaped knife.]

Fig. 12.

Authorities.—*Roser*, A. f. O. II. 2. S. 151.—*A. Weber*, ibid. VIII. 1. S. 322. —*Graefe*, ibid. II. 2. S. 241, VI. 2. S. 133, IX. 2. S. 147, X. 2. S. 204.—*Sämisch* u. *Pagenstecher*, kl. Beobacht. Wiesbaden, 1862. II. S. 99.—*Hasner*, Entwurf einer anat. Begründ. der Augenkr. Prag, 1847, S. 109; kl. Vorträge, Prag, 1860, S. 165 and 171.—*Junge*, A. f. O. V. 2. S. 200.—*Sperino*, Etudes clin. sur l'evacuation de l'humeur aq. Turin, 1862 and kl. Monatbl. 1863, S. 87.—*Stellwag*, Ammon's Zeitschr. f. ophth. IX. S. 490, Zeitschr. der Wiener Aerzte. 1856. S. 181.

Graefe, A. f. O. III. 2. S. 437; XII. 2. S. 118, 203, 250; XIV. 3. S. 140.—*Stellwag*, Ophthal. I. S. 314, Nota 50 u. f.—*Gouvea*, Archiv. f. Aug. u. Ohrenheilkd. I. S. 106, 120.—*Virchow*, *Klebs*, A. f. O. XII. 2. S. 254, 255.—*Frank*, Casper's Wochenschr. 1846. Nr. 45.—*Fischer*, Lehrbuch, S. 275.—*Hirschberg*, kl. Monatbl. 1868, S. 282.—*Arlt*, Lehrbuch. I. S. 211.—*Crisholm*, Virchow's Jahresbericht, 1868, II. S. 401.—*Simrock*, Canstatt's Jahresber. 1863, III. S. 107.—*Stavenhagen*, kl. Beobachtgn. S. 59.—*Classen*, A. f. O. XIII. 2. S. 506, 508.—*Mooren*, Ophth. Beiträge. S. 99, 100, 181.—*Sämisch*, das Ulcus Corneæ, Bonn, 1870.—*Canstatt*, Anal. d'ocul. 14. S. 157.—*Schirmer*, klin. Monatbl. 1868, S. 282.—*Riegler*, die Türkei und ihre Bewohner, Wien II. S. 110.—*B ck*, *Danielsen*, Traité de la spedalsked, Paris, 1848, S. 271.—*Seegen*, Wien. Med. Wochenschrift, 1866, Nos. 23–25.—*Stavenhagen*, kl. Beobachtungen, S. 59.

Results of Keratitis.

1. PANNUS.

Pathology.—By pannus, a vascular, superficial cloudiness of the cornea is generally understood. Chronic keratitis, therefore, often comes under the head of pannus. But in the strict sense, pannus is the product of a precedent inflammation, in which the change of tissue, as shown by the formation of new elements, has ceased, and the nutritive process is confined to the maintenance or advance of the neoplasia already formed by the inflammation. Where the inflammatory proliferation is very prominent, we should speak not simply of *pannus*, but of inflamed pannus or keratitis pannosa.

In the lower grades of pannus, *pannus tenuis*, we find the same pathological changes as in vascular keratitis. The elements are only further advanced in development.

In the higher grades, *pannus crassus*, under the thickened epithelium is found a layer of the character of connective tissue, which is filled with vessels.

The stratum of closely-grouped neoplastic cells lying under Bowman's membrane has also changed to connective tissue, or at least shows the inclination so to do, by prolongation of the growing cells and development of striated intercellular substance. It produces also newly-formed vessels, some of which pass obliquely into the cornea and disappear. Moreover Bowman's membrane appears thus to be destroyed, so that the subjacent connective-tissue layer apparently unites with that developed under the epithelium (*Wedl*, *Iwanoff*).

Symptoms.—Pannus tenuis is, as a rule, confined to limited portions of the cornea, and in relatively recent cases has the symptoms of vascular keratitis. In the former as in the latter we find a cloudy, rough appearance, and anastomotic vessels running toward the edges. But in old cases the surface of the cornea appears less rough, although dull, and has a more grayish and vascular cloudiness.

Pannus crassus, carnosus or sarcomatosus, generally spreads over the whole cornea. In recent cases, it appears as a superficial, dull, and rough translucent gray-yellowish or reddish layer, with a net-work of coarse vessels, which spreads over the cornea, and is immediately connected with the limbus conjunctivalis. In highly developed cases, warty-looking bodies project from the cornea, which then sometimes resembles a granulating wound. In more advanced cases these dry up, and the pannus layer changes gradually to a thick, hard, tendinous layer. This again is in many cases covered by a layer of loose connective tissue, which is immediately connected with the limbus conjunctivalis, and is, as it were, a continuation of the conjunctiva.

The pannous vessels of the cornea, which in all their properties most resemble veins (*Coccius*), unite at its margin into thick trunks, which lie mostly in the conjunctiva proper, and run toward its reflection, where they enter the orbital vessels. They may be moved with the ocular conjunctiva. In the episcleral tissue, such coarse, enlarged vessels are more rarely found near the corneal margin.

In pure pannus the episcleral tissue is, as a rule, but slightly injected, and great pain and photophobia are also absent. The patient is mostly troubled by disturbance of vision. In this and in the stability of the symptoms lie the diagnostic signs between pannus and superficial vascular keratitis.

Where the episcleral tissue appears strongly injected with a net-work of vessels around the cornea, and local elevation of temperature, excessive flow of hot tears, pain, and photophobia are present, there is either a keratitis, or a new inflammation is developed in a case of pannus. A variety of symptoms occur, also, from the difference of the pathogenetic causes of the disease.

Causes.—1. In most cases the pannus is a corneal trachoma, and occurs with granular lids; the trachomatous development has passed from the granular conjunctiva to the superficial layer of the cornea, and there caused those changes that are designated as pannus. Pannus, as above described, comes especially under this form. The typical pannus crassus occurs almost solely in high degrees of trachoma.

The keratitis, from which the pannus is developed, often comes on simultaneously with the conjunctival trachoma, or at least in the early stages, but just as often the pannus comes on late, or even first occurs in old cases of trachoma.

Besides the anatomical connection between the conjunctiva and the surface of the cornea, other clearly external causes take part in the production of pannus; such as the use of too irritating remedies in the treatment of keratitis; or extensive conjunctival cicatrices, which may act as foreign bodies, from the roughness of their surfaces.

In the same way, tough, hard, conjunctival granulations may cause pannus. Such cases form a link between pannus trachomatosus and pannus traumaticus.

2. Pure traumatic pannus is caused by the continued action of mechanical or chemical injuries to the cornea. The most common causes are cilia brought against the cornea, foreign bodies in the conjunctival sac, the untimely use of irritating ointments, collyria, &c., and the action of the atmosphere in ectropion, lagophthalmos or exophthalmos.

Mechanical injuries acting only on one part of the cornea are often followed by partial pannus; at least the change occurs most markedly at the point of irritation. As a peculiarity of this form of pannus it is to be mentioned that near the superficial vascular pannous layer, leucomata of the deeper layers may very frequently be observed.

3. A third species is herpetic pannus, the result of continued herpetic eruption. It usually appears under the form of pannus tenuis, and is confined to the cornea. If it attains the grade of pannus crassus it is generally combined with herpetic conjunctival pannus. The characteristics of this special form are peculiar herpetic nodules, cicatrices, exfoliations, and fresh efflorescences scattered in the pannous layer. It is often combined with trachomatous pannus.

Course.—If left to itself, pannus runs on for months or years without much change. The renewals of inflammation are important in a prognostic and therapeutic point of view, for they sometimes recur in spite of all treatment, are painful to the patient, and lead to incurable difficulties.

Results.—Pannus, up to a certain grade, may possibly be cured without leaving an opacity, provided it has not become chronic. Pannus tenuis alone is cured spontaneously, and this occurs only while it is recent, when the causes are entirely removed and under very favorable circumstances. Where the circumstances are less favorable, the pannus is changed to a non-vascular, superficial, or to a more or less thick tendinous opacity, or even to a fibrous membrane, which covers the corneal surface, and is, as it were, a continuation of the conjunctiva. Sometimes

in the above cases the conjunctiva is thickened and the tendinous covering of the cornea becomes peculiarly dry, with a silky gloss—a condition which is called pannus siccus, and shows a complication with xerophthalmos. Sometimes, after frequent relapses of inflammation, the pannous cornea is finally bulged forward, forming a vesicular protrusion, called staphyloma from pannus.

As a general rule, the prognosis is the more favorable, the thinner and more recent the pannus. Even a thin pannus that has existed a long while is apt to leave an opacity. In the same way, pannus crassus does not readily clear up entirely; a superficial, epithelial, or tendinous opacity often remains, even when the pannous layer has existed but a short time, when the treatment has been perfectly proper, and when the patient has been under the most favorable circumstances.

Of the different forms of pannus, other things being equal, the trachomatous presents the best prospect of a cure under suitable treatment, the pannus disappears more rapidly than the trachoma, and if it be not too thick or too chronic, the cornea is left clear or with only a slight cloudiness. But this only happens where the conjunctiva is not already cicatrized or extensively shrunken. In these latter cases even pannus tenuis can only be brought to a non-vascular corneal opacity, and it returns sooner or later.

In the prognosis of traumatic pannus, the leucomata of the deeper corneal tissues must be considered. These generally withstand treatment, or are at most only diminished and not entirely removed, and henceforth disturb vision very much. The cure of pannus depends on the case with which the causes may be removed, and normal conditions be resumed by the neighboring parts. Not until this is attained do the above-mentioned circumstances acquire an independent prognostic signification.

The same is true of pannus herpeticus. Besides the possibility of preventing future eruptions, we must consider the number, position, and form of the existing efflorescences and their results. The pannus may disappear without much gain to the patient, on account of the opacities of the cornea caused by the efflorescences, which remain.

Treatment.—1. The chief point is to remove the cause. In traumatic pannus operative interference of some kind will often be the first thing required. In herpetic pannus we have to oppose the predisposition to fresh eruptions. In trachomatous pannus the disease of the conjunctiva must be treated as hereafter described.

2. For the pannus itself, after removing the cause, local irritants have served best, and a number of these have been used from time immemorial. It appears as if their irritation of the pannous layer favored the resolution of the material into that which is easily absorbed, and also partly caused its removal. Among these remedies are particularly to be mentioned, dusting in of calomel, the use of an ointment of yellow oxide of mercury, or of white precipitate, painting in of pure or dilute laudanum, etc. In a word, all remedies that can excite a suitable degree of irritation in the eye are useful.

3. These irritants are useful in pannus tenuis in its various grades and transformations to opacities of the cornea. But in pannus crassus of high grade, even when of recent date, they may with advantage be replaced by actual caustics, which besides the irritant have a destructive effect, and when carefully used attain their object much sooner. These may be used with the less fear the thicker the pannus, for then there is less danger of injuring the deeper and perhaps normal tissues.

Of the means hitherto proposed, nitrate of silver is the best, as it irritates less in proportion to its chemical power, and its action is most readily limited. According

to the grade of the pannus, it may be used in solutions of ten grains to thirty grains to the ounce of distilled water. For fleshy granulations on the surface of the cornea, the "mitigated stick" of nitrate of silver is the best form to use. The former should be painted on with a brush; the stick may be applied directly, and any excess washed off with tepid water. If conjunctival trachoma exists simultaneously, of course the cauterization of the conjunctiva is combined with that of the cornea. Where there is excessive torpor, especially with a decided sensibility of the part, as often happens after a severe trachoma has run its course, direct cauterization of the pannous cornea and conjunctiva with crystal of sulphate of copper is preferable to the use of nitrate of silver.

Painting the cornea with acetate of lead, which has been frequently lauded, deserves as little recommendation here as in conjunctival trachoma. The use of acid nitrate of mercury with an equal quantity of water may be dangerous. It is recommended to apply this remedy to the cornea by means of a glass rod. The reaction after its use is said not to be greater than after the application of nitrate of silver (*Warlomont*). Aqua chlori, which is recommended in old cases of trachomatous pannus, where the washes made from metallic salts are not borne (*Graefe*), is less dangerous, but is not very serviceable.

Not long since, cauterization of the limbus conjunctivalis with nitrate of silver was in high repute (*Sanson*). Apparently, simply the irritating action of this proceeding is the medium of the favorable results. The excision or scarification of the conjunctival vessels leading to the pannus has been frequently recommended, and as often given up. Lately the excision of the entire anterior zone of the ocular conjunctiva has been recommended, particularly on account of its speedy results and safety (*Scarpa*, *Kuchler*). But it is generally used in cases where the above-mentioned bloodless means would suffice; simple excision has been generally abandoned in old and obstinate cases. It is recommended by some to cauterize the episcleral tissue exposed by the excision of the conjunctiva, but this must be regarded as dangerous, in spite of all claims for its safety made by its proposer (*Bertrandi*, *Fernari*).

4. While using irritant and caustic remedies, it must be remembered that by their untimely employment existing irritation may be aggravated, and the pannus may be thickened and extended by new formations. Hence, when injection of the conjunctival vessels, local elevation of temperature, sensitiveness of the eye, pain, photophobia, and lachrymation follow their use, they are dangerous applications, and antiphlogistics should be used instead, as in vascular keratitis. It is immaterial if the keratitis preceding the pannus has run its course, or if one of the inflammatory attacks, which so often appear in the course of pannus, be present, or if an external cause (as too active treatment, etc.), has temporarily increased irritation.

But even if such symptoms are absent, in view of the varied excitability of different individuals, it is best to begin with weak remedies in small quantities, and little by little go to the stronger ones; and in the commencement to apply them at long intervals, subsequently repeating them more frequently, but to stop them and commence antiphlogistic treatment so soon as a continued reaction follows their use.

5. Not unfrequently we meet cases, especially of old trachomatous pannus, in which the degeneration of the neoplastic elements ceases at a certain point. The cornea does not clear up in spite of continued and proper treatment, as the parts have become accustomed to a certain amount of therapeutic irritation, and the recourse to stronger means endangers the integrity of the cornea and conjunctiva directly or by exciting greater and more destructive inflammation. In such cases, by long discontinuance of treatment we may increase the susceptibility for remedies formerly well borne, and make these again useful. Sometimes the end is attained more quickly and safely by the use of warm applications (of 95° to 105° F.) applied

over the closed lids until the conjunctiva is brought to a condition of inflammatory swelling. The pannus inclines to resorption, and often clears up greatly under this treatment. At any rate, after it we may expect a more decided action of other remedies (*Graefe*, *Stavenhagen*).

6. If the latter remedy is ineffectual, there remains but one other for increasing the power of resorption, viz., the inoculation of the conjunctiva with blennorrhœal matter. The observation that even long-existing pannus which resisted other remedies, could be removed by a judiciously caused purulent conjunctivitis, led to this proceeding as much as fifty years ago (*Fried. Jaeger*, *Piringer*, *H. Walker*, *Mooren*). A long series of successful and sometimes surprising results have since then assured it a position in the treatment of pannus.

In regard to the indications for inoculation, we must bear in mind that it does not lie in the power of the surgeon, by the choice of matter, or certain manipulations, to measure beforehand the amount of inflammation to be excited. It must be further stated that inoculation sometimes results in a pernicious diphtheritic conjunctivitis, and that even simple blennorrhœa, although, as we know from experience, it endangers highly pannous corneæ less than it does normal ones, still leads in no small percentage of cases to partial ulceration, and even phthisis corneæ, let the treatment be what it may. It is also worth while noting the fact that pannous corneæ, under the influence of great inflammation, easily becomes staphylomatous, and that an inflammation of the conjunctiva can easily lapse into trachoma. Hence, inoculation of blennorrhœal matter is and will remain a heroic treatment, whose use is only justified by the previously proved inefficiency of other methods.

Judged in this manner, inoculation is almost solely indicated in the highest grades of pannus crassus; that is, where the whole surface of the cornea appears covered with a thick, vascular, neoplastic layer, which at no point permits the deeper layers of the cornea or the iris to be seen. In fact, the effects of this proceeding are the more brilliant the thicker the pannus.

The presence of corneal ulcers is a contra-indication, for the process of ulceration advances readily during blennorrhœa, and may end in phthisis of the cornea. The remedy is without result in tendinous induration of the conjunctiva, because here the contagion does not take.

If only one eye is pannous and the other sound, or at least serviceable, there is danger that in clumsy or careless patients the inoculated blennorrhœa may be transferred from the diseased to the healthy eye, and thus cause irreparable injury. In such cases it is wiser to avoid inoculation. In patients known to be trustworthy, however, a protective bandage carefully kept in place, will almost certainly prevent the matter from reaching the other eye, and partially remove the above objection to inoculation.

In cases where both corneæ were pannous, it was proposed to inoculate one eye first, and later, to carry the contagion to the second eye from this, because in the eye last affected the blennorrhœa would take on a milder character and less endanger the cornea. But this statement is not to be trusted. Besides, against this proceeding stands the fact that the patient has much longer to suffer, and cases occur in which the first affected eye, after blennorrhœa has run its course, becomes again affected.

It is wise, when possible, to use matter from blennorrhœa of a relatively mild character, best that from ophthalmia neonatorum. Excessive anxiety in the choice of matter is not, however, necessary. The best results have repeatedly been obtained from inoculating with the matter from purulent conjunctivitis, or even gonorrhœa, without regard to the age or degree of the disease furnishing it. It is even proposed to excite an intense blennorrhœa or purulent conjunctivitis. If the secretion from too mild a blennorrhœa be used, there is danger that the contagion will not take, or at least that it will not be of sufficient intensity,

so that the process must be repeated, and finally we are not safe against inflammation of the worst kind; for the intensity and whole character of the affection caused by inoculation is not entirely dependent on the quality of the matter.

Inoculation is best done with a small brush or piece of sponge, by means of which the matter is placed on the conjunctiva of the lower lid, while the latter is everted. A very minute quantity of matter suffices. This takes more certainly when it is brought immediately from the secreting surface to the conjunctiva of the pannous eye (*Piringer*).

Where this is impossible, the matter may be preserved between two pieces of glass, and used before it dries. The pus will stand considerable dilution with water, but its power of contagion is thereby evidently lessened. In the same way it loses in power by being kept and drying. If the contagion does not take, it must be repeated. Sometimes it is necessary to insert the matter with a lancet (*Piringer*).

In case the inoculation takes, blennorrhœa is usually developed in a few hours, and at most in one to three days. It must be allowed to advance to a high grade, but then all the remedies customary to such cases must be used.

Frequently only part of the pannous layer disappears during the *course* of the inoculated blennorrhœa, while the rest clears off during the *after-treatment* above described. Where this does not happen, some recommend the repetition of the inoculation, as cases are known in which the second, third, or even the fifth inoculation produced the effect, where the first had failed.

7. Constitutional treatment is of no benefit in pannus; remedies acting through the blood have no marked influence on it. For successful treatment a proper regimen is necessary to improve the nutritive process if it is weakened, or to retain it in a normal state if it is healthy. If the acute disease which generally precedes the pannus, or still more the mental influences which accompany the disturbance of vision, or a lengthy treatment, by its privations and frequently painful applications, are sufficient to undermine the constitution, it is no wonder if injurious cachexia are developed. In such cases residence in healthy fresh air, out of doors in the shade, nourishing and easily digested diet, sometimes water-cures, etc., are the best adjuvants to the local treatment.

Authorities.—*His*, Beiträge zur Histologie der Hornhaut, Basel, 1856, S. 107 and 109.—*Wedl*, Atlas cornea sclera.—*C. Ritter*, A. f. O. IV. 1 S. 355.—*Hasner*, kl. Vorträge, Prag, 1860, S. 157.—*Coccius*, über glaucom. Entzünd. u. s. w., Leipzig, 1859, S. 30.—*Arlt*, kl. Monatbl., 1864, S. 426.—*Warlomont* et *Testelin*, Mackenzie Traité prat. des mals d. yeux, Paris, 1857, II. P. 164.—*Graefe*, A. f. O. VI. 2 S. 146; X 2 S. 199.—*Roosbroeck*, kl. Monatbl., 1863, S. 492.—*Critchett*, ibid. 1864, S. 393.—*Bader*, *Lawson*, Ophth. Hosp. Reports IV. 1, VI. 1, and Canstatt's Jahresbericht, 1863, III. S. 122 and 123.—*Secondi*, clinica ocul. di Genova, Torino, 1865, P. 12.—*Williams*, Compte rendu du congress d'ophth., Paris, 1863, P. 137.—*Hairion*, ibid. P. 179.—*Fournari*, ibid. P. 193.—*Sanson*, *Scarpa*, *Küchler*, *Bertrandi*, ibid. P. 181, and Desmarres Traité d. mals d. yeux, Paris, 1847, P. 231.—*H. Walker*, according to Hairion, l. c. S. 187.—*Piringer*, Vienna med. Jahrb. neueste Folge, XV. S. 183. Die Blennorrhœ am Menschenauge, Graz, 1841, S. 42 et seq.—*Iwanoff*, Pagenstecher's klin. Beobachtgn. III. S. 130 u. f.—*Stavenhagen*, kl. Erfahrungen S. 54.—*Mooren*, Ophth. Beiträge, S. 87.

3. Opacities of the Cornea.

Pathology.—Opacities of the cornea are new formations, the result of an inflammatory change of tissue. They may be divided into:

1. Parenchymatous opacities. These are very varied in appearance.

a. In some cases the cloudiness of the cornea is universal; throughout its breadth and thickness it appears more or less regularly bluish or whitish, and is translucent. like milk-glass, while the surface has retained its normal luster, "complete leucoma."

b. In other cases, in the corneal layers are seen flaky, smoky, or bluish translucent opacities; or thick, figured white clouds; or cloudy, yellowish-white, or even chalky-white spots, lines, crescents, etc. These "partial leucomata," like the complete, result from diffused keratitis.

These opacities, especially the thicker, are caused by meniscoid nets of opaque grumous substance, which is pressed into the layers of the cornea. This grumous substance is found to be formed from shriveled nuclei, lying in a mass of fat-cells, frequently of a dirty yellow color. Besides these nests in such cases, the corneal cells are also much swelled from a like grumous substance. There is also a fatty degeneration of the intercellular substance in streaks; the lamellæ appear as if dusted over and sowed with a mass of fatty granules.

c. Round, sharp-bordered, or badly defined cartilaginous or chalky nodules of the size of a poppy or millet-seed, which lie with their long diameter in the superficial layer, but sink into the deeper ones. These are old, and sometimes calcified, herpetic points. They exist singly, sometimes strewn around or brought into groups on the cornea. Sometimes they are connected together by tendinous bands, or a new formation of connective tissue.

d. Circular, flat, sharply-bordered, grayish-white or yellowish opacities, from the size of a poppy to a millet seed, which seem pressed into the various layers of the cornea, but are apt to be in the posterior layer or on the free surface of the membrane of the aqueous humor. These are the products resulting from keratitis punctata.

2. Epithelial opacities. These are quite superficial, smoky, misty, or cloudy, half-transparent bluish or grayish opacities, within distinct borders. They are often so fine that even skilled oculists frequently have difficulty in detecting them. They generally appear by oblique light thrown through a convex lens. But in most cases this means is not necessary; the opacity may be seen even at a distance. In the denser part of the opacity there is generally a decrease of brilliancy in the cornea, the reflection appears dull, with indistinct or irregular outlines. Sometimes at these points, where the light comes from a certain direction, a silky luster, or even a sparkling appearance of various colors, is seen. By examination with a lens, in such cases, an apparent roughness of the surface is always seen.

3. Tendinous-looking opacities. These appear to the naked eye as tendon-like membranes, of greater or less thickness, covering to various extents the anterior surface of the cornea, and sometimes projecting beyond its level. Varying degrees of opacity, milk to chalky white color, tendinous, silky, and sometimes pearly opalescent hue, and hardness of the layers, are the remaining physical peculiarities.

The edges are usually indistinct, as a cloudy epithelium generally surrounds the new tendinous formation. In case the opacity itself or its cloudy border touches on the conjunctiva, one or more vessels usually come out over its anterior surface and divide up. Hence the possibility of hemorrhage occurring from the opacity in case of injury.

Epithelial as well as tendon-like opacities are in many cases the results of superficial vascular keratitis or pannus. But at other times they come from an ulcerative loss of tissue, where the cavity has been filled by substance which is transparent, or only externally cloudy.

Epithelial and tendon-like opacities do not differ in quality, but only in the thickness of the neoplastic layer. To the extent of this, and even beyond, the epithelium appears thickened unequally, and in irregular layers; its elements are clouded with fatty, molecular masses, often so pressed together that their contours are with difficulty recognized. If the opacity has formed on the floor of a healing ulcer, Bowman's membrane is absent, and the epithelium lies immediately on the new formation. This fills, as it were, a cavity in the superficial strata of the cornea, and is the result of a development of corneal cells. For it consists mostly of much elongated, even partially filiform nuclei, which, pressed together, hide each other and appear wavy. These nuclei lie in a cloudy intercellular substance of fat molecules. Sometimes in the new formation we may recognize neoplastic vessels, or their remains, in the form of thick bands. The borders of the new formation are often sharp; sometimes cloudy streaks proceed from it into the surrounding clear cornea. Usually with epithelial and tendinous, we find parenchymatous opacities, marked with the above-described characters (*Wedl*).

4. Simple corneal cicatrices. Their distinction from opacities is in reality artificial; the difference lies simply in the thickness, that is, in the solidity of the neoplastic tissue. The size and form of the cicatrix depends, for the most part, on the shape and extent of the cavity on whose floor the replacing tissue is developed. The cicatrix, however, rarely forms a cast of the cavity; for, under favorable circumstances, pellucid corneal tissue is formed at the bottom, and only the superficial portion of the opening is filled with the cloudy neoplastic tissue.

Generally the cicatrices in the substance of the cornea are surrounded by parenchymatous opacity, which is to be traced partially to the regenerated, but not entirely transparent, corneal tissue, partially to the disposition in nests of the cells, and to fatty molecular disturbance of the intercellular substance. But on the surface, the cicatrix spreads out generally as a tendinous opacity, which again is inclosed by an epithelial cloudiness, and thus shades off to the normal surroundings. According to the difference of texture are distinguished:

a. Tendon-like cicatrices. Apart from their thickness, by which they reach to a greater or less depth into the proper corneal tissue, even sometimes to the membrane of Descemet, their appearance approaches nearly that of the tendinous opacity. The exterior appearance of the cicatrix varies with the form of the loss of substance; it is different in punctured, incised, or flap wounds, or those with loss of substance, or after partial ulceration of the corneal layers.

The microscope shows the epithelium unequally thickened and cloudy, as in tendinous opacities. Bowman's layer is absent. In its place is a slightly transparent substance, composed of elongated nuclei closely packed, and less often a cloudy intercellular substance, lying more or less deep in the cornea. Posteriorly and laterally, the new formation becomes lighter, the intercellular substance acquires the preponderance, but appears in irregular layers. The layers appear confused, and interspersed in all directions with corneal cells, swollen with nuclei and fatty, grumous masses. Here and there are seen vessels, or their remains, in the shape of thick threads, with numerous nuclei and masses of pigment. Further off, the swollen corneal bodies resume their normal, parallel direction; the still cloudy, neoplastic corneal substance approaches

nearer to the normal. Sometimes, in very old cicatrices, choloid granules have been collected in groups (*Wedl*).

b. Connective-tissue cicatrices consist of layers which may be lifted in folds, and which are traversed by more or less thick net-works of vessels, and which, consequently, bleed on injury. These new formations agree in external appearance with loose connective-tissue, especially with the conjunctiva; often, however, these cicatrices seem traversed by thick, hard, tendinous strings and laminæ.

The loose connective-tissue neoplasia thickens towards its deeper part to a tendinous, hard layer, which covers the floor of the corneal loss of substance. Deeper in, this thicker portion of the cicatrix becomes cloudy, then transparent corneal substance, and by this latter the neoplasia is immediately connected with the normal elements of the cornea. Hence, in the thickness of the cornea, the cicatrix appears surrounded by a more or less extensive cloudiness. On the surface, its borders run into a tendinous opacity, bordered by epithelial opacity.

The simple connective-tissue cicatrix is always marginal, and immediately connected with the conjunctiva; it presents, as it were, a continuation of the latter over the periphery of the cornea, to fill up the loss of substance. The connective-tissue cicatrix is always preceded by a granulating ulcer of the cornea; but fleshy warts only form on the floor of a non-perforating corneal ulcer, when this is on the edge of the limbus conjunctivalis.

Not unfrequently simple connective-tissue cicatrices present themselves as the corneal part of a false pterygium.

c. The epithelial cicatrix presents a completely opaque formation of whitish gray, white, and yellow, mixed or wholly rusty-yellow or brown hue, which may easily be peeled off in the form of a fatty, greasy-feeling, granular, scaly or leafy, mottled, easily-broken mass from the floor of the cavity filled by it.

This mass consists mostly of epithelial plates, in different stages of disintegration, and a basis of molecular, organic substance, in which free fat, cholesterine crystals, chalky masses, and blood-corpuscles undergoing pigment degeneration are mingled in various proportions. This mass reposes on a loose connective tissue, or hard, tendinous stratum, which covers the floor of the loss of substance, and is connected with the surrounding corneal tissue by a layer of neoplastic corneal substance. Hence the epithelial cicatrix also appears to be bordered by a parenchymatous cloudiness, and superficially by a tendinous opacity, the latter being again lost in an epithelial opacity.

Like the connective-tissue cicatrix, the epithelial, also, proceeds from small, fleshy warts, implying also a granulating ulcer, and, hence, is situated on the margin of the cornea, when the ulcer was not a perforating one, complicated with prolapsus of the iris.

5. Cicatrices complicated with anterior synechia. These, like simple cicatrices, are, in a great majority of cases, of tendinous appearance; they are more rarely seen as loose connective-tissue, or epithelial cicatrices.

The chief characteristic is, that the cicatrix involves the whole thickness of the cornea, and has attached to it a greater or less portion of iris. This may be known from the change of position of the iris, by its approach to the posterior wall of the cornea, and the accompanying contraction or closure of the pupil, and finally, by the dark color of the cicatrix from the pigment contained in it. The extent and shape of the cicatricial mass depend naturally on the size and form of the original loss of substance, and vary greatly, as in simple corneal cicatrices.

The anatomical condition of the cicatrix varies, moreover, with the size and form of the posterior opening of the perforation. If this is narrow, the prolapsed portion of iris has the form of a pedunculated vesicle or strawberry, since its posterior part is brought together by the edges

of the opening. But under increased shrinking of the cicatrix, the anterior portion of the prolapse is compressed and soon atrophies. Henceforth it appears as if the iris were glued to the posterior end of the perforation. On more careful examination, however, the remains of the prolapsed portion of iris are found in the form of a greater or less amount of brown or black pigment inclosed in cells. According as the form of the perforating canal is round or linear, the pigment forms a leafy or stringy figure, which the cicatricial mass traverses, reaching often to the epithelial layer, where it shows itself as a brown spot at the middle of the anterior surface. In deep extensive ulcers, the iris prolapses sometimes in many places, and a corresponding number of colored spots are found.

This state was formerly called clavus or myocephalon. If the posterior opening of the perforation was wider, and a piece of the iris covered it, the cicatrix is subsequently often found hollowed out (fig. 13), while the anterior edge extends on a level with the rest of the cornea. Hence the new formation developed on the prolapsed iris shows the vesicular form of the prolapse. At the edge of the posterior concave surface of the cicatrix, the iris is attached and connected with a delicate structureless, highly-pigmented membrane, *a*, which covers the concavity, and is to be regarded as a remainder of the coloring matter of the prolapsed iris. At the edges of the cicatrix we even find parts of the membrane of Descemet folded up; for the parts of this membrane exposed by the ulcer are torn at the moment of perforation, subsequently are surrounded in the portion of iris pressed forward, and are then enveloped in the cicatrix. If the iris vesicle has burst before arriving at cicatrization, or if the cicatrix occurs at the pupillary border, the concavity at the posterior surface of the cicatrix is not seen; on the contrary, the new tissue usually projects into the anterior chamber, and is continued on the iris in the shape of tendinous bands. Then the anterior capsule is often connected with the cicatrix; the latter covers part of the former, and by the disturbance of nutrition often causes cataract.

Fig. 14.

In extensive perforations, where a large portion of iris with its pupillary margin has been exposed, the pupil appears nearly always closed, and the center of the capsule glued to the cicatrix, while the rest of the posterior surface of the cicatrix is covered with pigment membrane, and hence distinguishable from the lens. In cicatrices developed from extensive prolapse of the iris, the cicatricial tissue is almost always throughout its extent richly permeated by dark pigment, which lies partly free in masses, partly inclosed in cells, showing signs of former prolification. The posterior layers of the cicatrix especially assume the form of connective tissue; the intercellular substance is more or less wavy, and traversed by elongated cells, which are bound together by anastomosis, and, along with prolific nuclei, contain pigment of various amounts and hues. Dentate (Stachel) cells have been found, in the often very much thickened epithelial layer (*Czerny*).

6. *Bony degeneration.* Osteoid masses are rarely seen in the cornea. When they do occur, they are always in the shape of thin, delicate plates or scales, in thick tendinous cicatrices, with whose layers their rough surfaces are closely united. Hence they are only found in the cadaver. During life they are hidden by the cicatricial mass. They are characterized by a homogeneous or parallel striated organic base, and more or less bony corpuscles and chalky granules.

7. *Chalky deposits* appear under two forms: one, a stony, hard, rough solid, consisting of earthy and alkaline salts with an organic base, which is distinguished from the osteoid growth only by the absence of bone-corpuscles; the other as a fatty, sandy pulp, in which are mingled free salts, fat cells, cholesterine crystals, and broken down grumous organic substance, in different proportions.

Both forms appear like the osteoid in tendinous cicatrices. Sometimes they occur as round nodules surrounded by parenchymatous cloudiness, lying in the anterior layers of the cornea. In the latter case they represent degenerated herpetic vesicles. Again they occur as results of corneal abscesses, which, without perforating and evacuating, have become calcified. The new formation appears then as an opaque, chalky-white, or brown spotted, lens-shaped body, in the walls of the cornea, covered anteriorly and posteriorly by cloudy corneal layers.

8. *Metallic incrustations.* When sugar of lead and other metallic salts in solution with preparations of opium are used as collyria, during the presence of corneal ulcers, the floor of the

ulcer is incrusted, and finally granulations arise from the edges and cover over the deposit. Then on the site of the former ulcer, an elevated, thick, opaque, chalky-white or yellowish spot appears, often superficially opalescent, with edges sharp or indistinct, and traversed by vessels, which is generally taken for a cicatrix or tendinous opacity, till the anatomical examination shows the incorrectness of this opinion. (*Cunier*). This examination shows, just under the epithelial covering, a layer of yellowish or dark-brown brittle substance, without a trace of organization. This mass rests on a cloudy layer, which covers a bowl-shaped depression in the layers of the cornea, and is often traversed by vessels.

Accompanying Symptoms.—Impairment of vision is a constant accompaniment of all opacities which fall in the slightest degree over the pupil.

This visual disturbance is caused by the dispersion, reflection, and absorption undergone by the light falling on the opacity.

Hence, on the one hand the intensity of the direct light proceeding from the object and falling on the retina is weakened, and with it the retinal images. On the other hand, a part of the light dispersed by the corneal cloudiness falling on the retina is perceived by it and projected outward as a white or gray mist, cloud, etc. But as the elements sensitive to light are not in condition to separate different simultaneous impressions, and still more always to unite a confused impression, it appears to the patient as if the cloud were placed between his eye and the object, or as if the object were enveloped in it.

The amount of disturbance of vision depends chiefly on the proportion in which the two simultaneous impressions stand to each other. It is the more decided, the less the impression of the object exceeds that produced on the retina by the light dispersed by the corneal disturbance.

If only direct light fell on the cornea, the proportion between the two would be almost always constant. But besides the direct light from the object, diffuse light also always strikes the cornea, and in proportion to its intensity, strengthens the brightness of the spectrum proceeding from the opacity, and hence lessens proportionately the impressions of the real image.

In thin opacities this spectrum is usually the chief cause of visual disturbance. In dense ones, however, which let through little or no light, the spectrum only comes in question when marginal portions of it fall through the pupil. For thick opacities are seldom sharply defined, their borders fade off gradually and form a more or less wide zone, which disperses light falling on it, and then lets it through. Apart from this, the visual disturbance, under such circumstances, is mostly caused by the lessening of the brightness of the retinal images, and hence is in proportion to the density and size of the part of the opacity lying in front of the pupil. So it reaches the maximum when such a thick opacity covers the whole pupil, and from the middle of the visual field no image is thrown on the retina.

Visual disturbances also arise from roughness of the epithelial layer, abnormal curvatures of the cornea, and extensive anterior synechia, and not rarely from obliquity of the lens. Moreover, in synechia anterior, the lessening of the accommodation comes in question. So in many cases the visual disturbance is greater than is accounted for by the opacity alone. With unevenness of the epithelial layer, and especially in abnormal curvature of the cornea, vision is often so affected that without proper examination we might suppose there was amblyopia.

Unevenness and roughness of the superficial stratum are found in all kinds of opacities, even in the most delicate epithelial cloudiness, and often extend beyond the bounds of the macula, as seen with the naked eye. They are easily recognized by oblique illumination, but also by irregularity and distortion of the images, and in high grades, by their multiplication. This irregularity of the reflection allows us to judge in the best and most direct way of the highly disturbing effect that is exercised on the refraction of rays and the quality of the retinal images. For the anterior surface of the cornea is the surface of the dioptric apparatus, where the incident rays are most deviated.

On this latter account, deviations in convexity of the cornea are very injurious to vision. Such abnormal curvatures, however, appear not only as a result of extensive ulceration, where they are sometimes caused by pressure on the floor of the ulcer, sometimes by contraction of the resulting cicatrix; but they are often found with very delicate cloudiness, and then date from the inflammation, and are the results of the diminished resistance of certain portions of cornea to the intra-ocular pressure. By more careful examination, *i. e.*, with the ophthalmometer, it is found that the individual meridians of the cornea have different and generally irregular curvatures; even parts of the same meridian have different curves, and hence different focal lines and surfaces. The influence that this has on the retinal images, and hence on the clearness of perceptions, depends on the fact that, where even slight malcurvatures exist, instead of exact retinal images we have a blur of circles of dispersion, of which scarcely the chief outlines reach the retina, and these arrive there with deviated shady borders. The optical effect manifests itself markedly in cases not recognizable by the naked eye. By examination of the eye in the reversed image, it is at once seen that the pupil, etc., are distorted in the most varied directions.

But the rays proceeding from external objects to the retina undergo the same deviation as those from the retina outward (see astigmatism).

Changes of position of the lens are, as a rule, not so marked as to be of much importance, and moreover, they may be partially corrected by corresponding deviation of the visual axes.

To do away, at least partially, with these disturbances of vision, individuals with macular are accustomed, when they wish to see clearly with the affected eye, to increase as much as possible the impression of the image or the object, and to lessen the intensity of the diffused light.

They hold the object as near the eye as their accommodation permits, for thus, without annoyance, they increase the apparent brightness of the retinal images, and the number of excited nerve elements; they turn their back to the light, while they place the object itself in the best light; they half close the lids, hold the hands before the eyes, or look through the partially closed fist, to cut off the diffuse light as much as possible from the eye. But this means is best attained by holding up a diaphragm with a small hole in it.

In binocular vision, the impressions made on corresponding portions of the two retinæ are united in the brain to one of increased intensity. Hence, if one eye is undisturbed in its function, while the other is affected by an opacity before its pupil, in binocular vision, the light diffused over the retina of the affected eye will be evinced in the combined impression of the two eyes, and the object will appear enveloped in a mist.

Just as in monocular vision, the disturbance is especially evident when fixing objects of which it is desired to gain sharp and clear perceptions. The patients say the diseased eye dazzles the sound one, and they are often obliged in writing, reading, etc., to close the affected eye. But in ordinary vision the affected eye materially assists the other, since it strengthens the intensity of the latter, and, moreover, increases the visual field; provided, of course, that the corneal opacity does not render impossible the passage of a sufficient number of direct rays or cover the outer half of the pupil.

Where the pupil is entirely covered by a thick opacity, the positive disturbance of vision, on account of the less intensity of the light let through, is absent, and it seems as if the sound eye alone acted. But where the outer half of the pupil is covered by such an opacity, objects on that side of the visual field are slightly or not at all perceived, and vision is limited as in a monocular individual; so that persons thus affected run against objects.

In case both eyes are affected with opacities, which, however, are not thick enough to annul the perceptions of objects, of course the disturbance of vision is greater. The patient then uses the better eye, that is, the one which gives sharper

and clearer images, and in fixing objects seeks to exclude the weaker one from the act of vision.

Results.—Corneal opacities are capable of certain changes, and in so far we may speak of results:

1. The most changeable are the epithelial and the various forms of parenchymatous opacities. Both of these kinds of opacities may be removed spontaneously or by the use of remedies.

In epithelial opacities such a proceeding implies either the absorption of the neoplastic cells under the elastic lamina, or the casting off of the existing opaque epithelium, and its replacement by clear cells. But in parenchymatous opacities, the cure is, according to the anatomical conditions, sometimes caused by the absorption of the interlamellar cells, sometimes by a higher formation of the regenerated corneal layers.

As a rule, it may be said, the prospect of cure in these cases is the greater the more recent the case. Shortly after the termination of the inflammation causing them is the best time for treatment; at this stage even extensive and thick opacities sometimes disappear spontaneously. Old opacities, that have existed for months or years, on the contrary, are obstinate; it is immaterial whether they are thick or thin, large or small—even those that are scarcely perceptible almost always resist treatment.

There is reason to believe that opacities resulting from ulcers are less inclined to clear up than those from parenchymatous or vascular keratitis.

In children the prognosis is much more favorable than in adults; in them extensive opacities from deep and even perforating ulcers often clear up. And much more will epithelial clouds, and those parenchymatous maculæ dependent on interlamellar nests of cells do so.

It is not improbable that the growth of the cornea has some influence on them. On the one hand the opacity will hence be portioned over a greater surface and become thinner, and so less perceptible; on the other, with the spreading of the neoplasia, the number of its points of connection with healthy corneal tissue is increased, and hence the effect of any commencing process of resorption is greater.

2. Opacities and cicatrices in the strict sense, whatever their histological character, have not the power of changing to transparent corneal tissue, although they sometimes become diaphanous. They are, however, generally surrounded by parenchymatous and epithelial opacities, which often clear up spontaneously or by treatment. In this way such opacities are often apparently diminished and their influence on vision lessened.

Tendinous opacities, and especially tendinous cicatrices, increase occasionally, by continued change of tissue, to button-shaped masses, which look much like staphylomata, but differ from these by their solidity. These are tendinous or long outgrowths, which occasionally very perceptibly rise above the level of the cornea.

Opacities and tendon-like cicatrices may also suppurate. This cicatricial keratitis (*Hasner*) is developed and usually runs its course with the symptoms of severe ciliary, vascular, and nervous irritation; the cicatrix and the parts surrounding it usually swell somewhat, while the proliferating epithelium becomes rough and cloudy. Then, sometimes, the color of the cicatrix is gray or yellowish, and superficial layers begin to fall off, leaving a more or less deep and extensive ulcer with irregular borders and base, which in favorable cases always fills up again with cloudy cicatricial tissue.

Recent and peripheral cicatrices are more inclined to suppurate than old central ones. The most varied external injurious influences may cause the ulceration. Wounds of the cicatrix, either accidental or operative, may be mentioned as very frequent causes. It is said (*Hasner*) there is an especial predisposition to ulceration in sickly, weak, or irritable persons.

Herpetic eruptions, also, are sometimes developed in the tendinous neoplasia on the cornea. They also ulcerate readily, and occasionally cause extensive loss of substance, by extending the original point of inflammation.

3. Chalky and osteoid neoplasia, as well as metallic incrustations, are permanent in the strict sense of the term. Still the latter, like the tendinous opacities and non-perforating cicatrices, offer a possibility of a cure or improvement. For experience has shown that, in some few cases, after this tissue has been cut out, the opening left fills with neoplastic corneal substance, and this clears up.

4. A series of very injurious results depends on the disturbance of vision caused by these opacities. Thus, very decided myopia not unfrequently occurs, if the patient is obliged to use one or both eyes affected with corneal opacities for acute vision, especially of small objects. For he is then obliged to approach them much nearer to the eye than is necessary with a normal cornea; but if there is only a slight predisposition to it, continued strain of accommodation will readily produce the change in the formation of the eye or lens that causes myopia.

The great strain of accommodation, and the increased action of the internal recti associated with it, not unfrequently cause strabismus of the weaker eye, and in children with thick opacities on both eyes, even nystagmus often occurs. The necessity of excluding from binocular vision the eye which is clouded, or weaker in its functional activity, in order to maintain the most distinct impressions, when fixing an object, assists in causing strabismus, and where the opacities are on one side only, are often the sole cause of the deviation. But where this does not occur, it is often the immediate cause of amblyopia from non-use, for the patient gradually learns to see with the healthy or better eye, and to neglect the other, when fixing sharply; hence the power of accommodation is gradually lost, and the energy of the retina diminished.

Strabismus or *amblyopia ex-anopsia* may be caused by corneal opacities that are not permanent; these may disappear without the disease that they have produced receding. Indeed plenty of cases occur, where the strabismus or amblyopia from disuse may be directly traced to a keratitis that has run its course during youth without leaving a trace.

Treatment.—The indications are:

a. By assisting the powers of absorption and the throwing off of the epithelium, to excite or hasten the clearing up of the opacities; and where a complete removal of these is impossible, at least to diminish the extent of the disturbance.

b. In permanent, unimprovable opacities, to limit as much as possible the visual disturbance, that is, to diminish the intensity of the diffused light admitted, but to increase the apparent brightness of the retinal images, and when necessary, to open new ways for the entrance of direct rays.

c. Finally, to prevent the immediate results of visual disturbance.

1. To answer the first indications, there are a number of time-honored empirical remedies. They have in common the property of directly causing a greater or less irritation of the eye. That the removal of the epithelium may thus be effected is a known fact. But how resorption is effected is not clear. It is possible, that by the hyperæmia of the part, and the consequent increase of change of tissue, a sort of softening of the neoplastic elements is caused, and the removal and absorption favored.

It is true that the production of such a condition of irritation is indispensable

to a true therapeutic result, and that the most powerful known absorbents, quicksilver, iodine, etc., refuse to act when not applied directly to the cornea and conjunctiva. The remedies most frequently used are, dusting in calomel, applications of salve of yellow and red oxide of mercury, iodine salve and laudanum, instillations of astringent collyria, slight cauterization of the conjunctiva with sulphate of copper or solution of nitrate of silver.

Formerly, for the same purpose, steam was conducted to the eye by means of a funnel; warm mucilage of quince-seeds or mallows dropped into the conjunctival sac, or applied with a brush, fine oil or fat, ox or fish-gall, eel's-liver oil, viper-fat, bear-fat, etc., and solutions of various extracts. The above-mentioned substances were especially popular as preparatory remedies, as it was claimed that the parts were softened, and the efficacy of the resorbents increased thereby (*Beer*). Empyreumatic and ethereal oils, such as juniper-berry, paper-oil, sal-volatile, etc., were formerly much used.

Electricity was once quite fashionable for these affections. A current was passed through the upper lid or the cornea itself, and some other part of the body, the copper pole being placed over the eye, the zinc-pole to the tongue or hand (*Crusell*). But the remedy acts no better than the above-mentioned, and may be dispensed with. Acupuncture, where the needle is placed directly in the cornea, is dangerous. In deep opacities, that are not vascular, subconjunctival injections of solutions of common salt are also recommended (*Rothmund*).

All these, and many other remedies, when properly used, are very serviceable in certain cases. If some of them are more in use than others, it is perhaps not because of any peculiarity of their action, but on account of their more easy application, and especially the possibility of measuring and controlling their action. Hence, dusting in of calomel, on account of its slight irritation, is especially suitable in fresh maculæ, and where the eye is sensitive and inflammations are to be feared. The salve of yellow oxide of mercury is preferable where we require a powerful effect, and the irritability of the eye is moderate. Astringent collyria are best where there is catarrhal relaxation of the conjunctiva. Cauterization with crystals of sulphate of copper, or solutions of nitrate of silver, are indicated in complication of the corneal opacities with hypertrophy of the conjunctiva.

It is generally well to begin the treatment with weak remedies, and in case of need, to increase the strength or pass to more active applications.

If the eye reacts not at all, or only slightly, after the use of the remedy, the strength must be increased, or a more active application resorted to. Frequently, after the continued use of a sufficiently strong remedy, it ceases to irritate the eye. It is then well to discontinue it for a time, so as to let the susceptibility return, when it will again act well. In some cases, also, we may increase the susceptibility by warm applications and cataplasms.

In deep, non-vascular corneal opacities, remaining after diffuse keratitis, it has been recommended to inject a solution of chloride of sodium (one-third of one drachm to one oz. water), under the conjunctiva every three or four weeks. This may be done with a hypodermic syringe, and is said to act well and without danger (*Rothmund*).

[In a recent memoir to the French Academy, M. de Luca recommends the application of finely-powdered sulphate of soda directly to the cornea. He claims that it has the power of removing corneal spots in an almost incredibly short space of time. Croton oil, one part to six or eight of olive oil, is also advised as a local treatment for corneal opacities (*Thomas Windsor*).]

It is very important to restrain the irritation excited by the remedy within certain bounds. If the irritation is not great, it is sufficient to keep the patient, during its continuance, in a moderately illuminated chamber, and carefully to keep off all possible cause for its increase, as straining of the eyes, smoking, etc. In intense irritation, also, use cold compresses. When these symptoms have disappeared,

there is no necessity of confining the patient too closely. Fresh air and exercise out of doors, in shady, quiet places, free from dust, aid the cure. The diet should be regulated, spirituous liquors in moderation, as well as snuffing and smoking in the open air, need scarcely be forbidden. Internal remedies are useless in opacities of the cornea.

In opacities where the clearing up will evidently take a long time, it is advisable to forewarn the patient that the visual disturbance will not always be lessened in proportion to the lessening and thinning of the opacity. It is also well at the commencement of the treatment to determine the amount of monocular vision, by noting the size of and distance at which certain objects can be seen by the eye in question; and in the progress of the cure, by the choice of smaller objects at greater distance, to satisfy the patient of the improvement, and encourage him to persevere in the treatment (*Arlt*).

Where complete cure does not result, the above-mentioned remedies, even in increased dose and varied changes, finally refuse to act. Some oculists then expect favorable results from other and sometimes heroic remedies.

Direct attempts to cure corneal opacities by the inoculation of blennorrhœa have not been successful (*Piringer*); still it cannot be denied that, as a result of accidentally excited suppuration, very obstinate superficial maculæ have sometimes been cured.

Scarification and excision of the conjunctival vessels going to the corneal neoplasia is generally fruitless. On the contrary, scarification of the opaque part alone (*Weller*, *Desmours*), or combined with the above pharmaceutical proceedings, often acts energetically. It is, however, a question if, in cases where irritating salves, powders, washes, etc., were insufficient, scarifications can accomplish enough to outweigh the dangers of the inflammation accompanying them.

Much more important is the abrasion of the cornea, which is done in two ways,—by shaving off the superficial opaque part and by removing it in large pieces. Both plans originate from the observation that loss of substance occurring in this way, is in some cases replaced by new layers, which, from their transparency, resemble corneal tissue.

a. The shaving or scraping is done with the edge of a cataract or lance-shaped knife, or a cataract needle, used as is customary in erasing from paper. This operation is often painful, and hence is best done under anæsthetics. It is rarely possible to remove completely, or even mostly, in a short time the opaque part, while long-continued scratching is dangerous, as it may easily excite severe and injurious inflammation. Hence it is more prudent to repeat the operation at numerous short sittings, separated by long intervals, and the rather so because after each abrasion a part of opaque tissue always again results, while the floor of the loss of substance little by little rises up. This method is most serviceable in metallic incrustations, epithelial cicatrices, and superficial chalky deposits.

b. The removal requires a thin cataract or lance-shaped knife, which is placed under the opaque superficial stratum of the cornea, so that it may be separated in the shape of a thin flap, which latter is held with the forceps and further loosened by successive strokes of the knife. This method must also be repeated in many cases, on account of the formation of opaque layers. This operation is most serviceable in thick superficial tendinous opacities, particularly where these project beyond the surface without entering the substance (*Mead*, *Larrey*, *Wardrop*, *Weller*, *Gulz*).

Neither method is free from danger. With delicate and skillful manipulation, indeed, decided reaction may not occur. Still, on the other hand, as a result of the operation, we often have keratitis suppurativa, iritis, and even panophthalmitis. Hence we may say that abrasion is only to be used in cases of the above-mentioned opacities, where vision is limited to perception of light, and where it can only be improved by a clearing up of the cornea.

2. If the means for lessening or removing the opacity are exhausted, or if a hopeless case of opacity of the cornea exists, we must lessen its disturbing influence on vision, or open a new way for the light from the object to enter the eye.

In delicate cloudy opacities, such a curative measure will be especially useful, when the eye in question is the only useful one, or is the best, and the conditions

of the patient require sharp vision. The object aimed at is, that the spectrum traversing the opacity undisturbed may unite with sufficient brightness into a retinal image.

In thick opacities, whose nucleus permits the passage of little, if any light, and which therefore influence greatly the brightness of retinal images, therapeutic aid is much desired and even absolutely demanded. The chief aim is the extension of the existing, or the opening of a new way for the entrance of light; and at the same time covering up the dispersing borders of the opacity.

Further and not less important indications exist in cases of one or other variety of superficial roughness and curvature of the cornea, and sometimes in oblique position of the lens. It is generally desirable to turn off, as much as possible, irregularly refracted rays, and to form a way for direct light which comes as near as possible to the normal in regard to refractive conditions.

a. When a sufficiently large part of the pupil lies behind a transparent or only hazy portion of the cornea, also when this is abnormally curved, a plane diaphragm with a small central opening held close before the eye is very serviceable (*Travers*).

These shades do not answer well, because, while cutting off the laterally diffused light, which markedly increases the intensity of illumination, they also cut off a great part of the direct and regularly refracted light, and thus injure materially the brightness of the retinal images. Moreover, they limit the visual field most injuriously; they only render possible a more perfect perception of objects lying in the middle of the field, but cannot be used while the patient is going about, and much less when the objects move and change position rapidly. Hence they only temporarily increase the clearness of vision, and of course can only be used for monocular vision. When using stenopäic spectacles, *i. e.*, cups with openings in the center (*Ritterich*, *Donders*), which are fastened before the eye, the greater distance of the hole from the center of the cornea causes the limitation of the visual field to be more marked; hence they are less serviceable than flat monocular perforated shades.

b. But the above indications are better fulfilled by an operative displacement of the pupil. For thus the pupil will be drawn out to act as a stenopäic fissure and distorted toward the prolapse. If the opacity and superficial roughness of the cornea is not too extensive, it will not be difficult in the choice of a point for operation to place the entire pupil, or its greater part, behind transparent and regular cornea, and thus turn the rays from the disturbing opacity and irregularly refracting rough cornea, and so increase directly the clearness and sharpness of the retinal images. In certain cases there will be a question of giving the slit-shaped pupil a position and direction, by which the optical effects of irregular curvature of the cornea may be diminished if not destroyed, since only the more direct rays pass, and these have gone through a meridian but little deviating from the normal curvature, and with or without glasses unite on the retina to sharp images (see Astigmatism). The circumstance that the play of the pupil and the power of accommodation are retained to a certain extent, has considerable influence in regard to the gain to be obtained. Unfortunately, the conditions necessary to the success of this operation are not always present.

In extensive thick opacities it is rarely possible to place most of the pupil behind transparent and superficially smooth parts of the cornea, or entirely to do away with the spectrum from the indistinct edges of the opacity, without excessively stretching the iris and narrowing too much the passage for direct rays, and detracting greatly from the brightness of the images. In anomalies of curvature of the cornea, moreover, it is not always possible to place the long axis of the pupil opposite the

least curved portion of the cornea, as this is not always in a transparent and regular part. Anterior synechia of the iris, especially of the pupillary zone, does not permit a true displacement of the pupil, and a sufficient covering of the edges of the opacity; the pupil can only be drawn out to a slit, and in favorable cases, by a suitable position and direction, somewhat diminish the optical effect of a given abnormal curvature of the cornea.

c. From these considerations the indications for displacement of the pupil for opacities of the cornea are limited.

In most cases it is well to renounce its uncertain results, and, by effecting a wider opening for direct lights at the most favorable part, to increase as much as possible the brightness of the retinal images; that is, to choose iridectomy. Where the circumstances are not too unfavorable, this is generally a very satisfactory operation. It is not uncommon by it to give rather good vision, so that the eye, at least with the aid of suitable glasses or stenopäic spectacles, is fitted for near and distant vision, reading, writing, etc., and even for the recognition of small objects. Slight abnormal curvatures of the cornea do not at all prevent such a result, but, on the contrary, experience has proved that such deviations in the convexity frequently so diminish after iridectomy that their optical effects are easily neutralized or brought to a small amount by cylindrical glasses. Where, on the contrary, the circumstances are very unfavorable, the cornea very irregular, or only a small peripheral portion passable for direct rays, brilliant results can not be expected, and this must be considered in the prognosis before the operation. However, such unfavorable conditions do not render the operation entirely superfluous or worthless.

The fact of the other eye being normal does not contraindicate an operation, be it displacement of the pupil or iridectomy, even if the result desired is only improved vision.

Strengthening the impressions of light and extending the visual field are indications enough to recommend the operation. If a decided improvement of the amount of vision may be hoped for, there is a direct indication not to delay operation, as the affected eye may meanwhile deteriorate and lose its functional power from want of use. Careful observation has proved that the operated eye does not necessarily act injuriously on the sound one, and so cause its impressions to be repressed (*Graefe*).

Where the other eye is entirely useless for vision, the operation seems indicated even under most unfavorable circumstances, as even a slight improvement of sight, rendering possible the recognition of shadows of objects, or even strengthening the perception of light, is a gain for the patient.

It may be considered a rule, to make the pupil as near as possible to the center of the cornea. In peripheral synechia, where the pupillary margin of the iris is drawn toward the cicatrix, there is often an opportunity to carry out this rule. In central opacities of the cornea, the artificial pupil should be peripheral. Then, where there is a choice, the inner lower quadrant of the cornea is the point of election for the new pupil.

It is important to remember here, first, that the visual axis meets the corneal axis at an angle, and passes through the cornea at a point a little inside of and below its center; and, secondly, that in *fixing*, the visual axis must be turned to the object regarded, in order that its image may fall on the yellow spot. Hence, if the artificial pupil be formed elsewhere than at the inner and lower quadrant of the cornea, all the rays of light entering the eye through it must be regarded as marginal rays, which fall the more obliquely on the refractive surfaces, the more removed the artificial pupil is from the inner lower quadrant of the cornea. Under

such circumstances, even in normal curvature of the cornea, the spherical and chromatic aberrations are very perceptible; but when there is abnormal curvature, the deviation of the light is very annoying. To this is to be added the fact, that of the rays of light falling on the portion of cornea in front of the pupil, on account of the size of the angle of incidence, a large portion are reflected, some are absorbed, some scattered; hence the retinal images are less bright, and even a slight opacity will impair their distinctness.

We must attend to the above, not only in cases where we wish simply to give as good monocular vision as possible, but where functional activity of the other eye induces us to attempt to restore binocular vision. In old, extensive, central opacities, especially those originating in youth, this hope is, however, slight; hence it seems better to attempt increasing the field of vision, and to make the artificial pupil externally.

Generally, we may have greater expectations of restoring binocular vision by operation, the more favorable are the conditions for attaining sharp, retinal images, and the more certainly we may count on the muscles of the eye being in a condition to correct slight differences in the position of the images on the two retinæ. Eccentric pupils at the outer or upper part of the cornea, and particularly when very peripheral, rarely or never permit binocular vision.

Those made upward are often covered by the upper lid, and hence their beneficial effect is limited. And it is necessary to combat this by laying back the superior rectus; for by the tenotomy the action of the muscle is limited, and the visual line directed below the horizon. Hence, when fixing an object, a stronger exertion of the will on the superior rectus is necessary than usual, to bring the optic axis in the right direction. But this impulse always affects simultaneously the levator muscle of the upper lid from the community of function; hence, this is always elevated in fixing an object, which is the point desired.

d. In cases where the entire cornea is cloudy, it has been proposed to make a way through the sclerotic (*Autenreith*). In the exterior zone of the sclerotic a round opening is to be made, and the part of the choroid and retina thus exposed, to be cut out. Then the vitreous body fills the opening, and for a time it certainly permits a shadowy perception of large and near objects. But this opening always contracts, and finally is closed with cloudy, cicatricial tissue. Hence this method is of no practical benefit.

The attempts to transplant the corneæ of beasts, by uniting them by stitches to the edges of an opening in the cornea (*Himly*, *Wutzer*), have failed. The transplantations clouded over or contracted, if they did not die outright. Not less unsuccessful have been the attempts to form an artificial window, by introducing a stud-shaped piece of glass into an opening in the cornea, and healing this up around it (*Nussbaum*). However, one case is recorded, where the glass remained and permitted vision, for three months after its introduction (*Heusser*).

e. To break up an anterior synechia, a proceeding analogous to iridectomy is serviceable. Thus, after dilating the pupil as much as possible by atropine, a lance-shaped knife is so introduced through the cornea, in the meridian of the adhesion, that by advancing it the adherent layer of the iris comes under the blade just at the cicatrix. If any part remains, it may be removed by the hook used in iridectomy. Repeated instillations of strong solutions of atropine must keep the pupil and edges of the wounded iris as widely dilated as possible. This proceeding is, however, never certain in its effect, and is rarely worth the trouble and danger. In central cicatrices, with synechiæ of the pupillary borders, it will rarely remove the necessity for iridectomy. While in eccentric or peripheral synechiæ, which influence but little the diameter of the pupil, and where only a small portion of the pupil seems covered with the cicatrix, the detachment seems to have little effect.

3. The third indication aims at preventing the consequences of keratitis, that is, the development of short-sightedness, amblyopia, strabismus, etc. (The proper means for this will be discussed in the chapters on these subjects.)

Authorities.—*Wedl*, Atlas cornea sclera.—*Klebs*, A. f. O. XI. 2. S. 237.—*Stellwag*, ophth. I. S. 42, 218, 226, 263, 303 and 322.—*Cunier*, Ann. d'ocul. X. P. 264, XIII. P. 255.—*Knapp*, kl. Monatbl. 1864, S. 304.—*Piringer*, die Blenn. am Menschenauge, Graz, 1841, S. 261.—*Beer*,

Lehre von den Augenkhten. Wien, 1817, II. S. 95.—*Arlt*, Krankheiten des Auges, Prag, I. S. 269.—*Rothmund*, kl. Monatsbl. 1866, S. 161.—*Crusell*, Ueber den Galvanismus, etc., Petersburg, 1841.—*Mackenzie*, Traité d. mal. des yeux, Traduit par Warlomont et Testelin, Paris, 1857, II. P. 156.—*Weller*, *Desmours*, according to Desmarres, Traité des mal. d. yeux, Paris, 1847, P. 332.—*Ruete*, Lehrbuch der Ophth. Braunschweig, 1853, II. S. 262.—*Mead*, according to Ruete ibid.—*Gulz*, Oesterr. Wochenschrift, 1842, Nr. 24.—*Malgaigne*, Ann. d'ocul. XIII. P. 212.—*Desmarres*, ibid. IX. P. 96, X. P. 1.—*Hasner*, Entwurf einer anat. Begründ. etc., Prag, 1847, S. 123, and kl. Vorträge, S. 152, 205.—*Travers*, *Mackenzie*, Abhandlung über die Kkhtn. des Auges, Weimar, 1832, S. 513.—*Ritterich*, according to Th. Ruete, Lehrbuch, II. S. 265. —*Schauenburg*, Die künstliche Pupille vor und in dem Auge, Berlin, 1854, u. deutsche Klinik, 1854.—*Donders* und *Wijngaarden*, A. f. O. I. 1. S. 257.—*Graefe*, ibid. II. 2. S. 177.—*B. Ruete*, kl. Monatbl. 1865, S. 239.—*Autenrieth*, Tübinger Blätter für Naturwissenschaft, 1. S. 88.—*C. Himly*, Kkhtn. und Missbildgn. des. m. Auges, Berlin, 1843, II. S. 58, 60.—*Wutzer*, Zeitschrift f. Ophth. I. S. 486, and V. S. 323.—*Nussbaum*, Ueber die Behdlg. der Hornhaut-Trübungen, etc., München, 1856, und deutsche Klinik, 1853, Nr. 34.—*Heusser*, ärztl. Intelligenzblatt, etc., 1860, Nr. 24.—*Schalygen*, A. f. O. XII. 1. S. 93.—*Czerny*, Wien. Augen-Klinik Ber. S. 190.—*Gouvea*, Archiv für Aug.- und Ohrenheilkunde, I. 1. S. 120.—*De Luca*, Gaz. Méd. de Paris, 1867, S. 360.

3. Staphyloma.

Ætiology.—In order that a staphyloma may be developed within the anterior opening of the sclerotic, there must first be a decrease of the normal resistance of the corneal tissue, or it must be replaced by an extensible tissue. A second condition is a certain pressure from the contents of the globe, by which the part of the walls in question is subjected to a power too great for its resistance. The last condition requires the absence of even the slightest opening in any part of the tunics of the eye, and that the parts which secrete the humors have their function unimpaired. The pressure of the recti muscles also favors, but is not necessary to, the production of staphyloma. The diminished resistance of the cornea is occasionally the result of a simple relaxation of its layers. If this reaches so high a grade that the intra-ocular pressure acquires even a temporary ascendency, a protrusion of the cornea results; more frequently the decrease of the resistance is grounded in local or total destruction of the anterior corneal lamellæ. The exposed posterior layers, under the influence of the intra-ocular pressure, are then stretched and pressed forward, and an ulcerative keratectasia results, which, by successive additions of a neoplastic, more or less cloudy, even cicatricial tissue deposit, may become a cicatricial corneal staphyloma. Finally, in most cases an extensive perforation or destruction of the cornea is the origin of the staphyloma. The uncovered iris advances to the opening, glues itself to the edges of the perforation, forming a staphyloma of the iris, which, by development of cicatricial tissue in and around its walls, is transformed to a true cicatricial staphyloma.

A perfect division into these three forms of staphyloma is only theoretically possible. In point of fact the boundaries are lost in various intermediate forms.

a. Corneal Staphyloma.

Pathology.—The state of staphyloma of the cornea is best described by the synonym ectasia or protrusion of the cornea, since it represents the proper corneal tissue as the part which has suffered extension and increase of surface.

There are distentions of the eyeball, in which the inflammatory basis is evident as well in the history as in the accompanying symptoms. When of a low degree they are described as corneal staphylomata in the strict sense of the word; when highly developed they are always united with protrusions of the anterior scleral zone or of the whole sclerotica, and are therefore a symptom of the so-called *hydrophthalmus anterior*, or total staphyloma of the globe (see sclero-choroidal staphyloma).

There are also ectasiæ or protrusions of the eyeball, whose proximate cause lies in certain want of development, or in certain inflammatory processes, but for which no remote cause can be found in a previously existing inflammation. Such cases are the so-called keratoconus, conical cornea, or conical corneal staphyloma and keratoglobus, cornea globosa or spherical corneal staphyloma, also called buphthalmus.

The protrusion always occurs at the expense of the thickness of the cornea. In keratoglobus the cornea is evenly thinned, it is scarcely as thick as letter-paper, and

posteriorly is lined by the membrane of Descemet, which is also distended and thinned.

In conical cornea the periphery was found sometimes thickened, sometimes normal. In the middle, however, corresponding to the most prominent part of the staphyloma, the cornea appeared much thinned, about as thick as letter-paper. At the anterior surface the transition of the two different great zones of the cornea was unmarked, but on the posterior it was sudden, so that the central thinned part seemed surrounded by a pad, as it were (*M. Jaeger, Walker, Middlemore, Cappelletti*).

Symptoms.—These vary with the degree of protrusion, and are also frequently modified by various affections which are closely connected with staphylomatous formations.

1. Low grades of protrusion escape even the practiced eye, unless the finer means of diagnosis are resorted to, since they do not cause any marked deviations in the size or shape of the cornea.

But the irregular astigmatism connected with the protrusion is exceedingly evident to the patient, especially when the eye was formerly normal. Distant vision is always indistinct, and we are not able to improve it by spherical or cylindrical glasses. Distant objects of a smaller size which are distinctly marked, appear reduplicated, subsequently even near vision becomes more and more difficult, the patient is obliged to hold the objects near the eye, without then getting a distinct view. This polyopia is often very disturbing—we may then easily mistake the difficulty in vision for amblyopia, yet the ability of distinguishing color tints even, of objects very near at hand, and especially the marked improvement in vision, when the patient looks through a round opening in a shade, as well as when he nearly closes his eyelids, will prevent an error in diagnosis.

The irregularity of the corneal curvature is also seen in the ophthalmoscopic image. We only see a small portion of the fundus. The vessels and the border of the optic papilla appear distorted in various directions, dilated and contracted, while their contour is seen with varying distinctness. We not unfrequently see a vessel very much attenuated running into one side of the visual field out of the indistinct border, and gradually becoming more distinct and at the same time thicker, and finally leaving the visual field on the other side when it has become considerably enlarged. The slightest displacement of the axis of the mirror or of the affected eye causes great distortions of the image, so that the vessels and the border of the optic disc seem actually to twist into each other.

There are also changes in the reflex from the anterior surface of the cornea. These are not marked, however, in consequence of the smallness of the image. But if the curvature be conical, as is the case in keratoconus, the appearance of the reflex is a very good means of diagnosis.

If such a reflex be thrown upon the vertex of the cone, it appears very small without any marked distortion. But it is lengthened in an instant, if we change the position of the eye to the source of illumination.

These dioptric and catoptric symptoms only appear distinctly, when the protruding cornea has preserved at least the greater part of its transparency. Such cases are, however, the lesser number. In keratectasia, in the strict sense of the word, the cornea is, as a rule, opaque and cicatricial. In keratoconus a transparent apex is also exceptional, and in keratoglobus the cornea very often appears permeated by slight cloudy opacities, and in some cases evenly and densely opaque. Besides, the consequences of intra-ocular inflammatory processes and other causes for the impairment

of vision come into consideration, so that the diagnosis of slight degrees of this affection becomes quite difficult.

2. In the higher degrees of development all these symptoms are more prominent. The cornea, especially when the eye is viewed laterally, appears distinctly curved forward, and the anterior chamber seems considerably enlarged.

a. In true keratectasia the distention of the cornea is sometimes quite even and regular, when the curvature is like a miniature dome; again it is irregular, often limited to one part of the cornea, in which case the cornea approaches the shape of a blunt cone, and slopes off regularly or irregularly on all sides, according as the vertex of the curvature corresponds to a central or lateral portion of the cornea.

b. In keratoconus the curvature is conical, or, strictly speaking, that of a *hyperboloid*, since the lateral walls are not straight in the direction of the meridian, but more or less convex. But the curves are not regular, for in the different meridians, and in the individual parts of the same meridian, the curvatures vary exceedingly (*Brewster*).

The characteristic conical protrusion of the cornea in keratoconus, and the extensive widening of the anterior chamber united with it, are such marked symptoms that they can scarcely be mistaken. In fact, the staphyloma occasionally protrudes so as to be seen when the lids are closed, or it even renders the closure of the lids irregular. The blunt point of the cone often corresponds with the center of the cornea, which then arises with an equal angle from all points of the periphery to the zenith, and appears bell-shaped. But just as often the position of the zenith is eccentric, when at some points the walls of the staphyloma are unequally abrupt. The apex of the cone is often transparent, but more frequently cloudy, hazy, or opaque, like an epithelial or tendinous spot, or it is even cicatricial. The lateral walls of the staphyloma are, as a rule, completely transparent, smooth, and reflecting. The contrary is to be ascribed to accidental complications, which do not stand in immediate relation to keratoconus.

The reflex and ophthalmoscopic images show the above-described changes in the size, form, and position in more marked manner when the position of the axis of the cone to the source of illumination is varied. If the axis of the cone be turned exactly to the source of illumination, all the light will be reflected. The result is the appearance of a bright ring (*Ammon*, *Knapp*). Sometimes the reflection is so great that the conical cornea glitters like a crystal.

Vision is always very much impaired in greatly developed keratoconus, and can only be a little improved by the use of minute openings in a shade, blinking of the lids, and a lateral position of the object (*Mackenzie*).

In highly-developed cases the sight is not sufficient for the patient to walk alone. For objects in the axis of the cone escape observation, and those to the side are only recognized in their rough outlines; hence, in attempting to fix an object, the patient turns the side of the eye to it. Frequently, however, vision is limited to distinguishing light from darkness or different colors, and often all sensibility to light is gone, and the keratoconus is combined with amaurosis.

c. In keratoglobus the cornea curves forward like a cupola. At first the line of demarcation between the cornea and sclerotica is still very distinct; but gradually the anterior zone of the sclera becomes distended; it appears bluish and translucent, while the line between the two tissues becomes less and less distinct. The cornea becomes very much larger. In pure cases not unfrequently the brilliant reflection of its surface and the transparency of its tissues are preserved. Occasionally there is a greenish or smoky opacity of the cornea, especially on the periphery, so that it can scarcely be distinguished from the sclerotica. Often these

extensive leucomata, or the whole corneal tissue, may become completely opaque. The anterior chamber is enormously enlarged, the iris is widened generally, somewhat discolored, the pupil is of medium size, very sluggish, or even immovable. The lens and the aqueous humor are usually transparent, more rarely cataractous. At times the lens is dislocated and floating, from the distention or partial rupture of the zonula. The fundus is slightly changed; at the greatest it shows slight atrophy of the tapetum. In the optic nerve entrance, far advanced complete excavation has been repeatedly demonstrated. This has been referred to an increase in the intra-ocular pressure, which, in the greater number of cases, is said to be manifest by a marked hardness of the globe.

The vision of such a globe is always much reduced, but by no means annihilated. In some cases limitations of the visual field have been observed. The refraction of the eye is not always myopic to a high degree, as we should expect from the elongation of the corneal radius, and not always even myopic to any degree (*Muralt*).

In consequence of the fact that the posterior part of the globe is not affected, the mobility of the eye is not impaired. Yet without doubt, when there is a large staphyloma, and the palpebral fissure is thus put on the stretch and the lids rendered very tense, the free motion of the eyeball is somewhat limited.

Causes.—Keratectasia, in the strict sense, is actually in most cases the result of an extensive vascular keratitis. It is developed, especially, often during the course of a high grade of trachomatous pannus, and thus bears the name *keratectasia resulting from pannus.*

Frequent and severe inflammations dispose particularly to these protrusions: more rarely a diffuse keratitis or a partial ulceration is the immediate cause.

Inflammation also plays an important part in keratoconus (*Ruete, Graefe, Mackenzie, Sichel*). Independent of direct observations, the frequent occurrence of opacity, especially at the apex of the cone, is proof that it originates in inflammatory relaxation of tissue, particularly as such observations often exist at the commencement of staphyloma. Still, inflammation cannot be the sole source, as conical staphyloma is often developed without inflammatory symptoms appearing at any stage of the disease.

In such cases we may perhaps look for the cause in the thinning of the center of the cornea which has been demonstrated to exist, and this may be referred to an original malformation.

In support of the view that an error of development is the disposing cause, we find that conical cornea is often congenital and even hereditary, and not unfrequently appears combined with other anomalies of development of the eye and head (*Ammon*). We also find that the disease rarely remains monocular, but usually affects one eye after the other, or both together, which is not the case in keratoglobus.

In keratoglobus the changes within the eye indicate a precedent deep inflammation, and if this be congenital or hereditary (*Ammon, Jüngken*) the disease may have run its course during fœtal life.

Yet there are cases when all the indications of such inflammation are wanting. The frequent occurrence of a glaucomatous excavation in connection with increased resistance of the globe have led to the view that an increase of the intra-ocular pressure may be one of the proximate causes (*Muralt*). But, since in glaucoma itself the most marked increase of the intra-ocular pressure is not able to cause a distention of the cornea and of the outer scleral layers, it must be evident that in keratoglobus another factor—that is, lessening of the resisting power of the sclerotica—must also act, and this we must explain by an inflam-

mation which relaxes the tissue, or an original predisposition, that is, a kind of malformation (*Muralt*).

Course and Results.—Corneal staphyloma, as a rule, developes very slowly. On account of its slightness, its commencement is often overlooked, and the disturbances of vision caused by it are ascribed to some other disease. Hence a slight protrusion often continues months or years undiscovered and gradually increases; or it advances rapidly after an intercurrent keratitis, heavy coughing, vomiting, crying, etc., giving rise to the supposition that it is developed as a result of this circumstance. Even in those cases in which a marked inflammation, by a change of tissue, has prepared the way for the protrusion, it often happens that when developed it escapes observation, and is only discovered after long-continued growth.

Still, cases are seen where, even during the course of the inflammation, the protrusion has reached a high grade. This especially happens in keratectasia ex panno and keratoglobus. The development of the latter is sometimes very rapid, terminating in a few weeks. It is then generally preceded by attacks of intense pain, on account of the pressure on the ciliary nerves.

Not unfrequently the development of a corneal staphyloma is much interrupted; the ectasia reaches a certain point, then rests for months or years, and again proceeds with or without an apparent cause.

The development to the highest grade is, however, not absolutely necessary. The protrusion may halt at any stage and become stationary. Thus cases occur which have remained unaltered for years, and give no reason to expect a further formation of keratoconus or keratoglobus.

In high grades of keratoconus, if the apex be not cloudy at first, it generally becomes so very soon. The cause of this may be that when the lids close, the tears are not conducted over the apex, which, being less covered than a normal cornea, must suffer more from dryness, on account of its exposure to the atmosphere. A keratoconus or conical cornea never bursts except from application of force (*Wardrop*). The existence of a corneal staphyloma of this kind does not prevent the development of an intense, even ulcerative inflammation, and under such circumstances a perforation is possible. In keratoglobus of the highest development rupture is not uncommon (*Muralt*) (*see Sclero-choroidal Staphyloma*).

No certain observation of a spontaneous cure of the various forms of corneal staphyloma is recorded.

Treatment.—We should first attempt to prevent the protrusion. In case the development is progressing, the indication is to restore the normal conditions, or at least prevent further advance. If this is impossible, nothing remains but to reduce the accompanying disturbance of vision to a minimum.

1. The first indication requires, on the one hand, the correct treatment of the faulty action causing the diminished resistance, and hence in the majority of cases is to be antiphlogistic, but on the other hand demands the reduction or neutralization of the pressure acting on the posterior wall of the cornea. In this view, the greatest possible relaxation of the muscles of the eye, and especially the avoidance of anything that can excite the latter to simultaneous contraction, is advisable. Hence a suitably applied pressure bandage may be serviceable. If there is reason to fear danger from expansion on account of the rapid change of tissue, or if abnormal hardness of the eyeball shows increased tension, we should perform iridectomy immediately (*Graefe*).

Very recently it is said that good results have been thus obtained in keratoglobus. Yet the operation is very dangerous in these cases, because the wound does not readily close; vitreous humor is apt to flow through the interstices of the zonula, hemorrhages into the vitreous often occur, and thus hyalitis is sometimes developed. Several eyes have been destroyed by suppuration after iridectomy (*Muralt*).

2. The second and chief indication is to restore the normal curvature, and it has been attempted to fulfill this by producing a shrinking cicatrix on the apex of the cone. The vertex of the cone, at an interval of several days, is cauterized with a fine point of nitrate of silver, and where this does not suffice, the cornea is occasionally punctured (*Sichel*). Lately this method has been combined with keratectomy. An incision is made with a small and thin knife through the thickness of the membrane without perforating it; the flap thus formed is cut out with the scissors, and the cut surface cauterized at several points with the mitigated nitrate of silver (nitrate of silver and nitrate of potash). If four to five cauterizations do not produce sufficient irritation and exudation, a paracentesis should be made several times at the apex of the cone, afterwards atropine and the protective bandage are used; in case, however, the inflammation becomes very great and threatens to end in ulceration, lukewarm aromatic compresses are used (*Graefe*). The results of this method of treatment are very much praised by many (*Horner*, *Carter*, *Ed. Meyer*, *Secondi*), since by the shrinkage of the cicatrix a better and more regular curvature of the cornea is obtained, and the vision is said to be markedly increased. Yet these results have sometimes been attained by very dangerous inflammations of the deeper parts of the eye—iritis with hypopyon, irido-choroiditis, and so on. This mode of treatment is therefore by no means without danger, and besides is somewhat difficult to perform, since it is not easy to cut off the outermost layers of the apex of the cornea without perforating it. It is evident, moreover, that a simple shaving off of the epithelium would accomplish the same.

Others have obtained the same result by repeated paracenteses of the cornea (*Wardrop*), and by the intra-ocular myotomy division of the ciliary muscle (*Hancock*, *Coursserant*). The dangerous operation of removing the transparent lens has also been performed as a method of treatment (*Adams*). The proposition to cut out a piece of the base of the staphyloma, and to favor the formation of a flat cicatrix, deserves further observation (*Fari*). A spontaneous recession of the keratoconus, in consequence of an extensive perforating ulcer of the cornea, with prolapse of the iris, has been observed. It would be a better plan, however, to excise a lance-shaped flap, having its long axis meridionally, out of the apex, than from the base of the staphyloma. A wound of this shape offers the best chances of healing, as its edges can more easily come together when the cornea collapses. A prolapse of the iris, with accompanying contraction or closure of the pupil, can hardly be prevented. It is, however, of little consequence. A subsequent iridectomy easily makes a way for the rays of light. To prevent a return of the protrusion after excision, a pressure bandage is necessary till the consolidation of the neoplastic tissue is completed.

3. The second indication is to make the retinal images as clear and distinct as possible—that is, to neutralize the optical effects of the existing and incurable curvature of the cornea. It presupposes the power in the functional part of the apparatus to bring objective light to perception, and hence is of no value, where the staphyloma is accompanied by amblyopia or amaurosis.

All these requirements are best fulfilled by a displacement of the pupil in the direction of a corneal meridian, which in curvature, etc., is nearest normal (*Tyrrel*, *Donders*). Iridectomy is far less serviceable for this purpose (*Graefe*). If, however, an artificial pupil has been already made to limit the progress of the dis-

ease, or because the attempt at displacement has failed, we may at least diminish the existing errors of refraction by cylindrical glasses or stenopäic spectacles.

A displacement of the pupil to both sides, so that a stenopäic slit reaches over the whole diameter of the cornea (*Bowman*), is less advisable, as an entire meridian of the cornea offers too great a difference of curvature in its various parts, and its middle is always too convex to permit moderately sharp vision. Besides, the great traction on the pupillary part of the iris is dangerous.

Authorities.—*M. Jaeger*, Zeitschrift f. Ophth. I. S. 544.—*Walker*, Principles of Ophth. Surgery, London, 1834, P. 80.—*Middlemore*, Treatise on the Diseases of the Human Eye, London, 1835, I. P. 532.—*Cappelletti*, Wiener med. Wochenschrift, 1842, Nro. 14.—*Stellwag*, Ophth. I. S. 260, II. S. 984.—*Pickford*, Dublin Journ. 1844, Jan.—*C. Himly*, Krakh. u. Missbild. d. m. Auges, Berlin, 1843, II. S. 74 u. S. 192.—*Jüngken*, nach Himly, ibid.—*Adams*, Journ. of Science and Arts, 1817, II. P. 403.—*Ammon*, Zeitschrift f. Ophth. I. S. 122, u. klin. Darstellungen etc. I. Taf. 3.—*Mackenzie*, Abhandl. über die Krankh. des Auges, Weimar, 1832, S. 511.—*Wardrop*, Essays on the Morb. Anat. etc., London, 1819, P. 131.—*Brewster* after Wardrop, ibid. P. 132.—*Tyrrell*, Pract. Works on the Diseases of the Eye, London, 1840, I. P. 277.—*Fari* according to Ruete, Lehrbuch, II. S. 270.—*Chelius*, Handbuch der Augenheilk. Stuttgart, 1839, II. S. 378.—*Knapp*, kl. Monatbl. 1864, S. 313.—*Bowman*, ibid. 1863, S. 85.—*Graefe*, A. f. O. I. 1. S. 297, IV. 2 S. 271.—*Donders*, ibid. VII. 1. S. 194.—*Hasner*, kl. Vorträge, Prag, 1860, S. 135.—*Hancock*, Lancet, 1860.—*Oph. Hospital Reports*, 1859, IX. S. 154.—*Mauthner*, Lehrb. d. ophthalmoscop. S. 158.—*Muralt*, über Hydrophthalmus congenitus, Zurich, 1869, S. 36-59.—*Sichel*, Mackenzie's Treatise, II. S. 237.—*Horner*, kl. Monatbl. 1869, S. 139.—*Carter*, Lancet, 1869, I. S. 189.—*Ed. Meyer*, Virchow's Jahresbericht, 1868, II. S. 490.—*Secondi* della, cura del cheratocono, Genova, 1869, S. 20.—*Hancock*, *Coursserant*, Annal. d'ocul. XLIV. S. 243.—*Heyman*, Ophthalmologisches, Leipzig, 1868. S. 20.

b. Cicatricial Corneal Staphyloma.

Pathology.—This may be defined as the protrusion of a portion of cornea that is covered with cicatricial tissue; for it is nothing but the bulging out of a cicatricial ulcer, an ulcerative keratectasia that has become permanent. It presupposes an extensive trough-shaped ulcer, whose floor, either originally or in the course of cicatrization, has become protruded. The thinnest part of the floor is most pressed out, and subsequently forms the zenith of the staphyloma (Fig. 15). This zenith has often scarcely the thickness of writing-paper. But from it outwards the thickness increases, till at the foot of the vesicle it becomes normal.

Fig. 15.

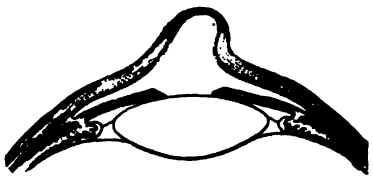

The zenith is, as a rule, formed almost entirely of cicatricial tissue; at least the substratum of proper corneal substance is so thin as to escape notice. On the sides of the staphyloma, however, a more or less thick layer of transparent cornea may be recognised, lying under the cicatrix. The posterior wall of the sound cornea and of the staphyloma is covered with the capsule of the aqueous humor. Towards the zenith this membrane becomes thin. Sometimes it even seems to be absent, so that the cicatrized part appears uncovered. But, under such circumstances, the covering of atrophied iris is wanting, and hence this form of staphyloma may be distinguished from true cicatricial staphyloma. Anterior synechia may indeed exist; still the attached portion of iris does not form the base on which the cicatricial tissue rests, as it were. The part of the cornea around the protrusion is frequently remarkably curved in various directions, and not rarely affected with superficial and parenchymatous opacities.

Course and Results.—The development is sometimes rapid, and may even occur during the inflammatory process; sometimes it is slow, beginning after the inflammation has ceased, and being frequently interrupted during its progress.

We cannot expect a spontaneous cure; on the contrary, when the apex of the staphyloma is thin, it not unfrequently ruptures. The repeated attacks of inflammation and ciliary trouble, occurring at variable intervals, are important practically. They are most frequent when there is anterior synechia, and probably depend on tension of the iris.

These inflammations, which sometimes appear as keratitis, kerato-iritis, or irido-cyclitis, often cause an increase of the staphyloma, occasionally further ulceration of the cornea or cicatrix, adhesions of the pupil, etc., and finally even attack the deeper parts of the eyeball, or even the other eye, causing a sympathetic ophthalmia.

Treatment.—In small circumscribed staphyloma, if the rest of the cornea is not too much distorted, displacement of the pupil, or an iridectomy, suffices to give a satisfactory amount of vision.

In some cases the partial staphyloma and malcurvature of surrounding portions of cornea are much diminished by an iridectomy combined with the methodical use of a pressure bandage.

In very prominent or extensive staphyloma of this variety, iridectomy must be

combined with splitting or removal of the ectatic portion (see treatment of cicatricial staphyloma).

Frequent attacks of inflammation or ciliary neurosis call for the immediate performance of the operation, so that the cornea may not be clouded to a great extent and rendered unfit for an artificial pupil, and that the iris may not suffer, etc. If the attacks recur in spite of the operation, and the deeper parts of the eye are much affected sympathetically, or the other eye threatened, enucleation of the eyeball may be required. But if under such circumstances a sympathetic affection of the other eye is not to be feared, and it is desirable to insert an artificial eye for the improvement of the looks, instead of enucleating, we may cause suppuration of the eyeball (see *Sclero-choroidal Staphyloma*).

c. Cicatricial Staphyloma.

Pathology.—The cicatricial staphyloma is a vesicular cicatrix protruding beyond the level of the cornea—in other words, a staphyloma whose walls are composed, for the most part and throughout their whole thickness, of cicatricial tissue. In a genetic point of view it may be considered as a cicatrization of a vesicular prolapsus iridis or a cicatrized iris staphyloma. It presupposes an extensive penetrating loss of substance of the cornea, and its closure by prolapsed iris and neoplastic tissue. According as this cicatrix replaces a part or the whole of the cornea, the condition is called partial or total staphyloma.

Ectasia proceeds in cicatricial staphyloma, as in others, at the expense of the thickness. Hence the walls of the staphyloma frequently appear very thin (Fig. 16), especially at the summit, which often has scarcely the thickness of paper. However, the protrusion does not prevent further development of tissue, so it not unfrequently happens that the staphyloma has a thickness equal to that of the normal cornea, but sometimes greater and even double or more (Fig. 17). For such a state is not uncommon in very large cicatricial staphyloma, which can only with difficulty be covered by the lids. Some parts of the wall, most frequently the summit, occasionally reach a remarkable thickness, even so as to much impede an operation. Doubtless the steady action of various external irritants, and the excitement produced by them, is a decided cause of this increase of substance.

Fig. 16.

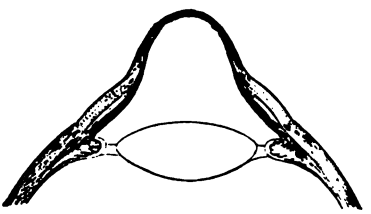

The surface of the cicatricial staphyloma is covered with cloudy epithelial cells, which, from their physical peculiarities, may be divided into a corneal layer and a mucous substratum. In very large staphylomata which project beyond the lids, the corneal tissue bears more the character of epidermis, as it appears formed of dry epidermis plates without nuclei. These cellular elements are sometimes piled up to a considerable thickness (Fig. 17, *a*). Cases occur in which the epidermis may be peeled off as a membrane 1-4 to 1 line in thickness. In these layers chalky deposits are not unfrequently found; but generally the superficial layers are mingled with numerous granular masses of fat from the Meibomian glands. Lately, the occurrence of *stachel* and *riff* cells in the mucous layer has been observed, which in a thick layer cover the surface of the staphyloma (*Czerny*, *Schiess-Gemuseus*). [Stachel cells are cells with linear projections from their circumference; riff cells have dentated borders.]

Beneath the epithelial layer is found exceptionally a thin layer of loose vascular connective

Fig. 17.

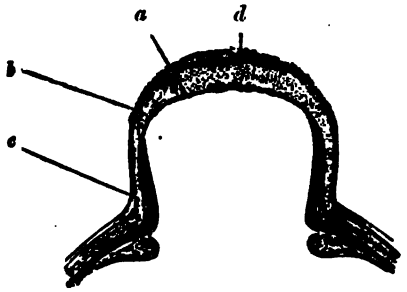

tissue, *b*, which appears to be a continuation of the conjunctiva. As a rule, however, the epithelium lies immediately on the cicatrix, whose tissue in the anterior layers, especially in the peripheral zone, mostly corresponds with neoplastic corneal substance, and in so far, doubtless, results from outgrowth of the external corneal border, which usually resists ulceration.

Further back, however, the new formation acquires more and more the character of connective tissue, and is distinctly striated, and the developing connective-tissue cells show an increasing amount of dark pigment the further back we go. This connective tissue is formed by the proliferation of the iris exposed by the ulceration. It also contains vessels which form loops and bleed freely in case of injury. Bony scales are also found.

At the base of the staphyloma, the prolapsed neoplasia is united with the remaining non-indurated part of the cornea, and rarely with the edge of the sclerotic itself. The kind of union between the cicatrix and healthy cornea varies, as in simple penetrating corneal cicatrices, according as the ulcer had steep or sloping edges. In the former case, the change from the neoplastic mass to the more or less cloudy cornea is sudden, but in the latter the cicatricial tissue, gradually thinning, advances over the former seat of the ulcer. The foot of the staphyloma shows anteriorly a cicatricial, posteriorly a layer, originally of corneal substance, and from this point gradually becomes a tendinous, then an epithelial opacity, if there is room on the cornea for these changes.

The posterior wall of the staphyloma is sometimes smooth, sometimes full of depressions. It generally appears covered with a delicate, structureless brown membrane, *d*, which is so intimately connected with the cicatrix that it can only be loosened in patches. This is the remains of the iris which was exposed by the corneal loss of substance, and on which the staphyloma has developed. In total and in partial central cicatricial staphyloma, the pupil is indicated by an increased amount of pigment on this membrane.

On the posterior surface of the base of the staphyloma remains of Descemet's membrane are always found. These are sometimes massed together in a ball, and simply hang to the cicatrix, or are glued to it. But ordinarily the base of the staphyloma is regularly covered by this membrane, as it falls forward from the portion of cornea surrounding the protruded cicatrix, and so reaches the sides of the staphyloma, where its ragged edges immediately sink into the cicatricial layers. Only in cicatricial staphylomata which have developed on a trough-shaped perforation does this hyaloid coating extend further—that is, so far as the posterior layers of the cornea have done.

So far as the membrane of Descemet extends, the iris lies on the staphyloma wall without growing fast to it; adhesion begins where the Descemet ends or disappears in the cicatrix. The free portions of iris, changed by previous inflammation, often appear covered with a tendinous extension from the cicatrix, traversed by a tendinous framework and atrophied. But just as frequently these remains of iris retain their integrity. The cicatricial staphyloma is generally filled with aqueous, and presents an enormously enlarged posterior chamber as it were. Rare cases, however, are met with in which a more or less thick tendinous net-work is contained, which is intimately connected with the cicatrix, and whose meshes appear filled with a yellowish or brown cheesy mass. Careful examination has discovered in this mass a formless organic molecular base, nuclei, and cells in different stages of development; also blood-corpuscles, fat-globules, cholesterine and chalky masses. This mass shines through the cornea and gives it from without a peculiar yellowish-red and brown-spotted look. It is always the result of an excessive proliferation of the iris.

Frequently, especially inpartial staphyloma, the crystalline preserves its integrity. It often, however, appears as a primary or secondary cataracta siliquata, which, when the zonula remains, sometimes appears bulged out by the vitreous (Figs. 18 and 19). The wrinkling of the crystalline is at one time the result of cataractous metamorphosis, but at another depends on the

evacuation of the lens (on the perforation of the cornea), while the ruptured capsule retains its connections, and its edges finally close by exudation, or chalky degeneration of the cataractous remains. Still the entire lens is sometimes absent, as in extensive perforations it easily escapes with a portion of vitreous. Cases also occur in which the cataractous lens, frequently shrunken to a solid mass, is found in the concavity at the summit of the staphyloma, for the lens is often firmly united to the plug closing the pupil; later, when the cicatrix protrudes, it bursts the zonula and drags the lens forward with it. In the two latter cases, the inside of the staphyloma and the back part of the eye form one cavity, which is filled with a fluid resembling aqueous humor. Wounds of the globe cause this fluid to be evacuated and the eyeball to sink together.

Symptoms. 1. As regards partial cicatricial staphyloma, its appearance varies according as it has developed on a perpendicularly-edged rupture of the cornea or on a trough-shaped perforating ulcer. In the first case it usually presents itself as a roundish cloudy vesicle, about as large as a pea, which is raised perpendicularly above the surrounding, more or less malcurved, parts of the cornea, and is often pedunculated. (Fig. 18). In the second class this pedicle is absent, the protrusion slopes down into the remainder of the cornea, which is also abnormally curved. According as the staphyloma is central or peripheral, the cornea about its base is regularly (Fig. 22) or irregularly (Fig. 22) curved.

Fig. 18.

Fig. 19.

Fig. 20.

A small staphyloma of this kind is easily covered by the lids, and hence with each motion of winking it is moistened, and its surface appears smooth and reflecting; the walls are of tendinous whiteness and opaque, but when thin are sometimes translucent. Staphylomata of great size, which project beyond the lids and prevent their closure, and so can not be regularly moistened, have always a dull, often rough, surface covered with yellow or brownish crusts of dry mucus. The cornea surrounding the staphyloma is more or less cloudy. Frequently the cicatrix sends off a shoot like a tendinous opacity, which ends in a cloudy epithelial ridge. At the base of the staphyloma the iris always lies close to the posterior wall of the cornea.

In peripheral staphylomata, which have developed over exposed parts of the breadth of the iris, the pupil may be free; so that only the malcurvature of the cornea in front of it causes disturbance of vision. In a central staphyloma of this class, and especially where part of the pupillary margin of the iris is united with it, the pupil appears closed, and vision is limited to the perception of light.

A peculiar form of partial cicatricial staphyloma results sometimes from perforating crescentic ulcers or flap-wounds, such as are formed in the operation for extraction of cataract. A

pad-shaped prolapsus iridis is developed, which by degrees cicatrizes and loses its convexity and changes to a wall perpendicular to the sclerotic (Fig. 21, *a*), and unites at a sharp angle with the flattened and protruded flap of the cornea. Such a staphyloma has no apex but an edge.

Fig. 21.

2. Total cicatricial staphyloma often reaches a very large size, even to that of a hazel-nut or a chestnut. In shape it is sometimes a cone, sometimes half oval; sometimes it is quite irregular, as one part of the wall is more protruded than another, and advances beyond the rest. Very frequently it is contracted at the base, as the sclerotic generally takes no part in the protrusion. The base of the staphyloma is not always elevated in its whole extent, directly from the anterior opening of the sclerotic, but only at a small part of its periphery. The remainder of the latter is bordered with a more or less wide crescentic cicatrix, which lies on the level of the anterior scleral opening. Since the summit of the staphyloma is always placed in the opening of the lids, it is clear that the intra-orbital portion of the globe must undergo a strain, that the optic axis, which does not correspond with the staphyloma axis, is prolonged outwardly, will cut one or the other lid.

Causes.—The development of a cicatricial staphyloma presupposes a loss of substance of the cornea, from a distention of the layers. As a rule, it is the result of an ulceration; rarely of a necrosis. It is often developed over the opening made by taking away a like or different form of staphyloma, and then constitutes a relapse. Flap-wounds, also, such as are formed in cataract extractions, sometimes lead to staphylomata.

Course and Results.—Cicatricial staphyloma is, as a rule, only an advanced stage of staphyloma iridis. The change from the latter to the former is often rapid, occurring even in a few weeks; but it is also frequently slow. That is, the proliferation of tissue in the exposed iris is sometimes very rapid, so that in a few days this appears changed to a spongy, fleshy formation of decided thickness; but sometimes it is so slow that after weeks and months the walls of the iris staphyloma preserve their former delicacy and transparency, and show only here and there some spots or net-work of tendinous tissue.

However, there are cases in which the prolapsed iris, for a time, undergoes a luxuriant proliferation, sometimes granulates, and in places assumes the character of tendinous tissue before it bulges out, either because up to this time an opening permitted the escape of the aqueous, or because the latter was secreted in less quantities and transuded through the prolapsus.

The cicatricial staphyloma, once developed, generally grows slowly and with many interruptions. The walls, however, increase in thickness, especially when the staphyloma protrudes beyond the lids, and there is consequent irritation of the globe. When the walls have reached a certain thickness, a further protrusion is improbable; but an increase of extent outward by growth of the cicatricial tissues, or, as is more common, by addition of epithelial layers, may occur. Apart from this, such thick-walled staphylomata are strictly stationary, since they can neither heal spontaneously nor rupture. Only exceptionally does it happen that the walls ulcerate, collapse,

after partial or total evacuation of the contents of the globe, and change to a flat cicatrix, or that the eye is destroyed by suppuration.

Thin-walled, and especially recent staphylomata, on the contrary, frequently burst. An external, mechanical injury, a powerful contraction of the recti muscles, often suffices to cause this. After the rupture, follows simply a loss of aqueous, or of a great part of the contents of the globe. In the former case the staphyloma, in the latter the eyeball, collapses. The edges of the rupture may unite, and the former condition recur. Sometimes, especially if after the rupture a pressure bandage is used, it happens that the walls of the staphyloma, which are folded together, inflame, and adhere, forming a ball, and consolidate to a flat cicatrix. This is the only way to a relatively spontaneous cure. Not rarely, however, extensive hemorrhages occur, generally after evacuation of the contents of the globe, which, without inflammation, cause atrophy or phthisis of the eyeball.

We must not omit to say that, in cicatricial staphyloma, the internal parts of the eye easily become sympathetically inflamed, either originally or during the subsequent development. The long removal of intra-ocular pressure, caused by ulceration of the cornea, tension of the iris united to the cicatrix, the swelling of a cataractous lens, external injuries that affect the eye while uncovered by the lids, are frequent sources of these affections. These are, then, the causes of frequently relapsing inflammation, unbearable ciliary neurosis, and where there is great excitability of the ciliary region, and decided increase of intra-ocular pressure, not unfrequently lead to glaucomatous conditions or staphylomatous protrusion of the sclerotic and choroid, and may even sympathetically affect and endanger the other eye.

Treatment.—We should aim, first, at converting the protruded into a flat cicatrix, and, if possible, restoring a certain amount of vision; secondly, at meeting attacks of inflammation, and ciliary neurosis, and guarding against the dangers attending them.

The flattening of the staphyloma is to be accomplished, according to the case, by splitting, cutting off the protruding portion, or by cutting out an elliptical piece of the cicatrix, and uniting the edges left by sutures.

In somewhat extensive cicatricial staphylomata, the first two modes of operating should be combined with the evacuation of the lens; that is, immediately after splitting or cutting off the protrusion, the capsule should be divided in various directions, and any part of the lens which is not then evacuated spontaneously should be scooped out with Daviel's spoon (*Küchler*). This is necessary in order to diminish as much as possible the intra-ocular pressure, and to prevent the occurrence of another protrusion of the neoplastic tissue, after the edges of the wound have united, or the loss of substance caused has been covered. On the other hand, we must remember that, in large cicatricial staphylomata, splitting or excision can hardly be performed without wounding the crystalline, or causing rupture of the zonula, which are already stretched by the tension of the muscles of the eyeball; that hence the operation almost always leads to the formation of cataract, and that the swelling of a cataractous lens, especially after wounding the capsule, is a very fruitful source of severe irritation and inflammation, which often causes suppuration of the eyeball, thus aborting the aim of the operation, or even proving dangerous. Moreover, in such cases, the restoration of even a moderately satisfactory amount of vision can scarcely be hoped for in any event; hence the removal of the lens does no harm.

In small, circumscribed cicatricial staphylomata, when the integrity of a large portion of the cornea permits the restoration of a certain amount of functional

activity to the eye, the lens is to be preserved, if possible, and instead of removing it, a large iridectomy should be made. This should be done just before the splitting or excision of the protruded cicatrix, and, of course, the point chosen must be that which will be followed by the best optical results. The object of the operation is not, however, solely the making of a direct passage for the light, but also the diminution of pressure, and the removal of the irritation caused by the tension of the iris, dependent on a protruded or again protruding cicatrix, which has already been operated on.

If the lens has been wounded during the operation, or has been found to be cataractous, its evacuation is necessary.

Fig. 22.

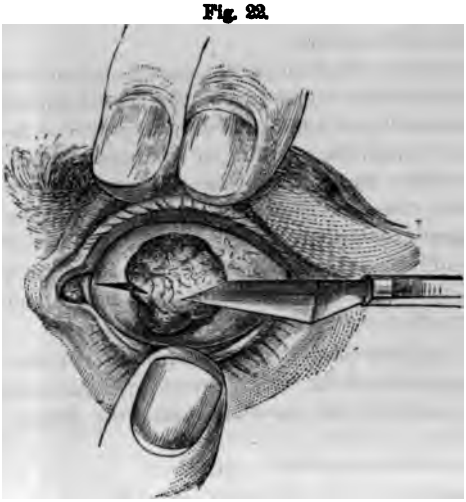

When attacks of inflammation or ciliary neurosis often occur, the indications for the operation are increased, and some circumstances even justify the causing of suppuration or enucleation of the eyeball.

1. Splitting, also called incision, is a division of the cicatrix in the direction of its meridian. This serves first to make the walls fall together by the evacuation of the aqueous, or a part of the entire contents of the eyeball, and gives the two halves an opportunity to unite while lying together; secondly, it presents a foundation upon which a continued growth of tissue may form a flat cicatrix. The operation is best done with the patient lying down, while an assistant steadies the head and widely separates the lids of the eye to be operated on. According to the extent of the staphyloma, a cataract or staphyloma knife should be used. With the edge toward the apex (Fig. 22), the knife should be made to pierce the cornea at the edge of the staphyloma, and transfix it in the direction of its greatest diameter, dividing it in one or two cuts through the zenith, so that the swelling shall be divided into two halves.

Immediately after the operation the lids should be brought together by two strips of adhesive plaster, and a pressure bandage applied, while care is taken, that it is not displaced. The patient must stay in bed, on antiphlogistic diet, for two or three days, during which time the bandage may be renewed, if necessary. After this the patient may be allowed more liberty, he can go about the chamber; but the bandage should be worn till the cicatrix acquires the desired strength.

Besides preventing the subsequent evacuation of the g.obe, the pressure-bandage has other objects. First, it lessens the dangers which the complete removal of intra-ocular pressure causes. Secondly, it retains the two halves of the staphyloma in apposition, and thus favors their undisturbed and rapid cicatrization.

The simultaneous closure of the lids by adhesive plaster is advisable, especially in unreliable patients, as a monocular pressure-bandage is easily displaced, and is ineffectual, while a binocular one would be unbearable, if worn for a length of time.

Incision is indicated only in thin-walled staphylomata. It answers best in partial, especially staphyloma of the iris. Here it equals, if it does not surpass, excision in efficiency, as it does not require a complete new formation of a tendinous cicatrix, but a simple adhesion of the half folded over the other, and a relatively slight strengthening of this by neoplastic tissue is sufficient.

Thick-walled staphylomata do not completely sink together after division, and the two halves are not easily retained in apposition by a pressure bandage. Hence the production of a flat cicatrix is difficult, especially as the thick epidermis layer of this staphyloma is unfavorable to the adhesion of the two halves. The evacuation of the lens and vitreous, with consequent collapse of the globe, and, if necessary, keeping open the wound by frequently breaking up adhesions, may, it is true, remove this difficulty, by causing the staphyloma walls to shrink and unite to a flat cicatrix. But the results of this method seem not to come up to expectations, and such cases are almost always treated by excision.

Fig. 23.

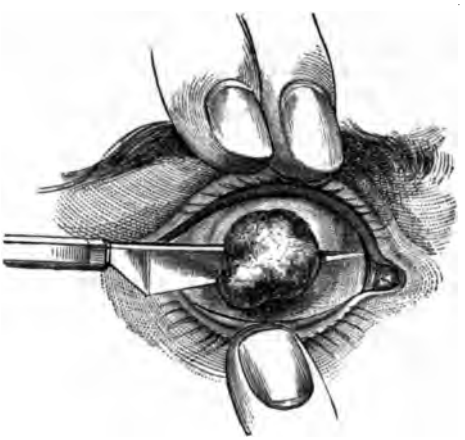

2. The ablation or excision of a staphyloma aims at the partial or entire removal of the protruded portion of the eye, and secondly at the closure of the opening thus formed by a flat cicatrix. The patient lying down, the operation is to be done in two stages: in the first, the staphyloma is to be divided from the base, in about two-thirds of its extent; in the second, the remainder is to be divided, or, still better, a flap formed to cover the opening at the base of the staphyloma, or to serve as the foundation of a flat cicatrix.

With this aim (Fig. 23), the lids being held widely apart by an assistant, a cataract knife (or, if the staphyloma is very extensive, a staphyloma knife), with the blade in the plane of the base of the staphyloma, is made to transfix, and in one or two strokes cut out along the edge a little above its great diameter; then the wall, which sinks in, is held by forceps and divided by scissors curved on the flat, in the plane of the base of the staphyloma; or else a flap is cut from this to correspond in form and size to the opening. Then the lids are to be closed with adhesive plaster, and a pressure bandage applied. The after-treatment is the same as after incision.

In ablation of small staphylomata, the lens advances to the opening and covers it without being torn loose from the zonula; but when extensive, the lens is generally evacuated if it is still present, and it is generally broken up, as it is apt to fall on the knife when the section is made. Then a portion of vitreous, resembling a transparent vesicle, fills the opening; but more frequently this or the fluid in its place is evacuated with the lens. Where the lens has been evacuated by the ulcerative rupture of the cornea, this latter is an almost constant event.

Where only the aqueous, with or without the lens, escapes, the globe does not collapse, but by the action of the recti muscles preserves a certain degree of extension. If a flap is formed it finds a support in the lens or exposed portion of vitreous, lying on which and in apposition with the edges of the wound, it may readily adhere and form a hard cicatrix. But in case the staphyloma is entirely removed, under favorable circumstances, as a result of the proliferation of the elements, the edges of the wound are glued to the lens or vitreous, and the opening

between them fills up with a white formation, which projects as a more or less broad border from the edges of the wound, like the frame of a watch-glass.

Then, for a time, the zenith of this vesicle remains transparent, and permits the perception of large objects, exciting hopes in the patient which are soon to be blasted. For, on the one hand, the opening diminishes by the approximation of the edges; on the other, the neoplastic border extends, and the lens or vitreous is finally covered by the new formation. Only a continued proliferation is necessary to finally replace the opening by a hard, sufficiently thick, and resisting flat cicatrix, which is generally smaller than the former opening. The consolidation of such a cicatrix requires, as may be imagined, several weeks or months.

Frequently a small, scarcely perceptible depression remains in the midst of the already flattened and much shrunken replacing tissue, which is covered only by a very thin membrane. In careless patients, particularly when the bandage is displaced or mechanical force acts on the eye-ball, this easily bursts, and so in the later periods of convalescence causes escape of the vitreous, with all its attendant dangers.

The tediousness of the cure and the necessity of wearing a bandage for so long a time are good reasons for preferring the formation of a flap to excision of the entire staphyloma.

If the greater part of the vitreous, or the fluid replacing it, is evacuated, the globe collapses, and after the closure of the opening, it not unfrequently shrinks to the half of its normal size, as a result of the extended inflammation and the consequent atrophy of the organ. Thus the disease is confirmed, and all possibility of saving any sight is lost. Suppuration then often occurs, which, sooner or later, sometimes after weeks of suffering for the patient, terminates when the globe is reduced to a small body, and, moreover, the other eye is disposed to dangerous and even fatal disease by pyæmia.

The cause of this severe inflammation lies mostly in extensive intra-ocular hemorrhage, which is produced by the sudden removal of intra-ocular pressure. It is most often witnessed where the inflammatory process is continued to the choroid, or the staphyloma is accompanied by sclero-choroidal staphyloma.

3. The object of cutting out an elliptical portion of the cicatrix, and uniting the edges of the wound by stitches, is to avoid the danger of evacuating the lens and vitreous that accompanies excision of the staphyloma, to render possible the union of the wound in the shortest time, and to form a firm, elastic movable stump, which will permit the insertion of an artificial eye, for the improvement of the personal appearance (*Critchett*).

Fig. 24.

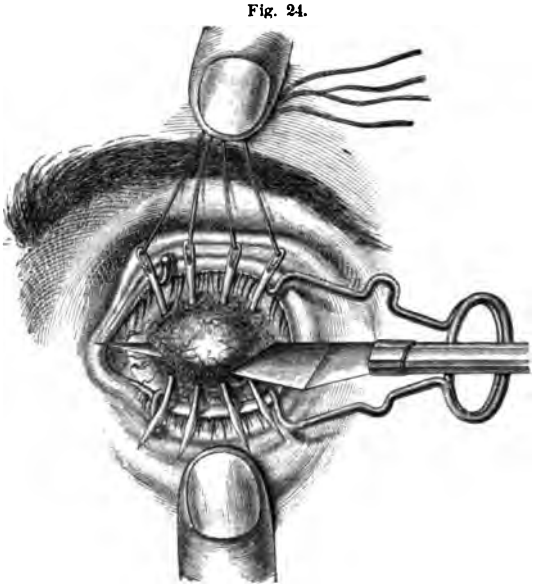

The operation should always be done during anæsthesia. When the patient has been properly placed, and the lids fixed by an assistant, or a spring-speculum, four or five small curved needles should be passed through the cicatrix in a row along the upper and lower border of the staphyloma and left there. When this has been done, a meridional wound, about two lines long, is to be made with a knife, just in front of the line of insertion of the internal rectus muscle. Starting from the inner angle of this wound, we

cut out with the scissors a small elliptical portion of the staphyloma wall. It is simpler to make the lower flap at once with the knife, by introducing it at the anterior scleral border, obliquely to the horizontal meridian, and passing it directly through the staphyloma, so that it may come out in the sclera at the base of the opposite side; then complete the section by long cuts. The flap is then to be seized with the forceps and cut off with the scissors; its size must vary with the extent of the staphyloma. It is not at all necessary to cut out the whole of the ectatic cicatrix, so as to have the edges of the wound in the sclera; for the freshened edges of the cicatrix unite without suppuration. For perfect union to occur, the long axis of the flap must be perpendicular to the direction of the needles, and the sides be within their points of entrance and exit. When the flap has been removed and the lens evacuated, the needles (which have been previously armed with surgeons' silk) are to be passed entirely through and the silk tied, taking care to adjust the edges of the wound correctly. The stitches should remain for some weeks, and, if they do not fall out spontaneously, are to be removed after adhesion of the wound.

It is claimed as a great advantage of this operation that the size of the stump can be regulated, a point that is very important when an artificial eye is to be used. It is also said that suppuration more rarely results from it than from excision of the entire staphyloma. The greatest advantage, however, is, that the patient is spared from wearing the pressure bandage so long. Attempting to save the lens is dangerous (*Critchett*), even if it is possible.

Added to this the insertion of the needles through the ciliary body, and the long continuance of the threads in the ball, are not without danger. In consequence of this, severe inflammation of the deeper parts, and even sympathetic of the other eye, have been observed. It has been recently recommended to place the stitches through the conjunctiva.

For this purpose a fine needle is entered two to three lines beyond the base of the staphyloma and a little to the inside of the vertical meridian, and carried somewhat obliquely under the conjunctiva towards the nose, and brought out vertically above the inner border of the base of the staphyloma; then the same needle and thread are so carried under the staphyloma through the conjunctiva that the entrance of the needle is directly under the inner border of the staphyloma and its point of emergence is nearly in the vertical meridian. A second needle is then carried in a similar manner outward from the vertical meridian through the conjunctiva above and below the staphyloma. The effort is made to include as much as is possible of the conjunctiva and the episcleral tissue, at the same time to push the conjunctiva as little as possible over the sclera, and to draw this well toward the center of the palpebral fissure. The threads are then laid back, the staphyloma cut off, and the ends of the threads are tied. Fig. 25 (*Knapp*).

Fig. 25.

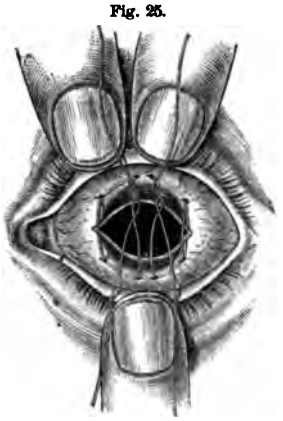

Of course these methods are only suitable in nearly total cicatricial staphylomata, especially those with thick walls or even button-like thickened vertex where a restitution of vision is impossible, and it is only a question of forming a stump for an artificial eye. It also answers the purpose in a combination of cicatricial with sclero-choroidal staphyloma. If in such cases suppuration occurs there is not much lost.

Authorities.—*Beer*, Lehre von der Augenkrankheiten, Wien, 1817. II. S. 216—*Scarpa*, Trattato delle pr. malattie d. occhi, Pavia, 1816. II. P. 156—*Küchler*, Eine neue operat. Heilme-

thode der sämmtl. wahren Hornhautstaph. Braunschweig. 1845.—*Chelius*, Zur Le
Staphylomen des Auges, Heidelberg, 1858.—*Critchett*, ophth. Hosp. Reports IV. 1
Monatbl. 1864. S. 32.—*Secondi*, Clinica oc. di Genova. Torino, 1865, P. 22.—*Z*
Med. Jahrb. 1866. 4. S. 15.—*O. Becker*, ibid. S. 16. 20.—*Czerny*, Wien. Augenkli
S. 190.—*Schiess Gemuseus*, kl. *Monatbl.* 1868. S. 98.—*Arcoleo*, Nuovo Processo
tomia, Palermo, 1869.—*Knapp*, A. f. O. XIV. 1. S. 273.—*M. Schultze*, Centralbla
Wissensch. 1864. Nro. 12. 17.—*Virchow*, ibid. Nro. 15. 19.

SECOND SECTION.

INFLAMMATION OF THE VITREOUS: HYALITIS.

Anatomy.—The vitreous humor, *corpus vitreum*, is enumerated among the mucous tissues (*Virchow*), or the gelatinous connective tissues (*Kölliker*). It is perfectly structureless, without vessels or nerves. It has, however, a number of nuclei and cells, which are intimately connected with its nutrition. They lie mostly in the peripheral layers, while some are situated on the inner surface of the surrounding hyaline, and hence are sometimes regarded as epithelium (*C. Ritter*). Occasionally we meet single filaments, or whole bundles of them, of the character of connective tissue: they are regarded as the remains of fœtal vessels (*Henle*). Nutrition is carried on through the vessels of the retina and uvea.

There appears to be some trace of organization in the vitreous. In preparations properly made there is found quite a firm cortex and a nucleus. In the former, concentric layers of varying thickness are found, which, beginning at the *ora serrata*, surround the nucleus like a kind of open cup. In the latter, there runs from before backwards a fissure having branches, which represents the rudiment of the canal of *Cloquet* (*Stilling*). Where the vitreous has been hardened by certain reagents, the onion-like layers of the cortex are very distinct (*Hannover*), and instead of the fissure we find a radiate striation similar to that of an orange (*Brücke*). This only shows that the vitreous may be split, for there are certainly no actual membranes as separating walls (*H. Müller*, *Doneau*, *Kölliker*, *Iwanoff*).

In fœtal life the cells are very richly strewn through the vitreous. They then appear at quite regular distances through the entire *corpus vitreum* (*Virchow*). After birth they diminish greatly, and with advancing age become very rare in the interior of the body. They are sometimes oval, flat nuclei, sometimes round or oval, finely-granular, nucleated cells of the character of mucous globules (cytoid), sometimes of larger multinucleated cells with more distinct envelopes (*Henle*). They are mostly found near the *ora serrata*, behind the lens, and in front of the optic nerve entrance (*Klebs*). The existence of spindle-shaped and stellated cells, with offshoots, and occasionally arranged in groups (*Virchow*, *C. O. Weber*), is still doubted by many. The same is true of the physaliphores, *i. e.*, round cells with or without offshoots, which have in their interior, or on their outer walls, small, round, translucent vesicles, and which are said to participate in the formation of mucus (*Iwanoff*).

About the existence of a filamentary framework in the fœtal vitreous (*Bowman*, *Iwanoff*), also, there is no certainty. But the existence of numerous branches of the hyaloid artery renders its existence, at least in the earlier periods of fœtal life, very probable. Cases of incomplete development in the eye also favor this supposition. Thus, in coloboma of the sclera there was found a tendinous process starting from the vicinity of the ciliary processes, and attached to the dislocated lens (*Arnold*). In another case of the kind, the fissure of the vitreous was filled with an extensive tendinous, vascular comb, which started with a broad base from the lower border of the optic papilla, gradually dwindled away, was attached to the anterior border of the scleral staphyloma, but from here spread out like a fan and surrounded the posterior surface of the crystalline like a cup. In a third, in the living subject, and afterwards on the cadaver, was observed a round string, one line long, which, from the entrance of the vessels of the optic disc, projected into the vitreous, and in it divided up brush-like into a thick cloudy opacity.

The central trunk of the vessels of the vitreous does not disappear till the end of the fœtal life. In the calf and horse, however, its string-like tendinous remains continue visible long after birth (*H. Müller*). In the human being, also, the rudiments have been seen ophthalmo-

scopically, and on the cadaver, either simply as a short tendinous offshoot (*Meissner*), or as a tendinous band stretching from the papilla to the posterior wall of the lens, and here expanding to a flat opacity (*Toussaint*, *Liebreich*, *Sämisch*, *Mooren*, *Stör*).

Occasionally near such remains of the hyaloid artery we find very peculiar, half-transparent, dark-green shaded, grayish prominences in the fundus, the nature of which is not as yet sufficiently explained. Perhaps they are the remains of the fœtal connective tissue structure. They lie chiefly around the optic nerve (*O. Becker*), or in the direction of the embryonal palpebral fissure. They seem to be covered by the retina, at least some retinal vessels run over these bodies, which seem bent and distorted in the folds of the surface. The hyaloid artery has once been observed on the living subject filled with blood (*Zehender*). This case recalls another, in which there was a thin, vessel-like, sharply-demarcated column of blood, which ran from the optic papilla toward the center of the posterior capsule, and here expanded into a small disk-like extravasation. There were no walls to be found, however, in this blood column, and hence it was explained as an injection of Cloquet's canal, such as often really occurs in post-mortem injections made for anatomical purposes. Very recently actual grounds for a belief in the patency of the canal have been adduced (*Stilling*), and in one case it was recognized ophthalmoscopically on both sides, with the light entering in in a certain way as a transparent cord, but with other illuminations, as a dark one. (*Wecker.*)

Fig. 26.

The gelatinous substance, the so-called *vitrina*, is surrounded posteriorly by the limiting membrane of the retina, anteriorly by the posterior layer of the zonula and capsule of the lens. There is no real hyaloid membrane. Where such a membrane has been supposed to be found it was actually the separated internal boundary membrane of the retina (*Henle*, *Iwanoff*).

The vitreous humor is closely connected to this latter. Therefore when the eye examined is not very fresh, the limiting membrane is very apt to be removed with the vitreous. The scales which have been observed on the outer surface of the supposed hyaloid membrane, which by many have been thought to be epithelium (*Hannover*, *Finkbeiner*), are probably nothing more than remains of the torn-off ends of the radiate fibers (*Henle*, *Iwanoff.*)

The zonula begins just beyond the ora serrata, somewhat in front of the equator, as a layer of very fine filaments running in a meridional direction, some of which may be followed into the vitreous (*Henle*), and throughout their course are united into a plate by a homogeneous cement. This plate is intimately united to the ciliary region of the retina and the tapetum, as well as to the hyaloid of the ciliary processes. At the ciliary body it divides into two folds, of which the posterior goes to the posterior, and the anterior chiefly to the anterior half of the capsule and unites with it. Thus, between the two folds of the zonula and the margin of the capsule is formed the canal of Petit, which, however, like the serous cavities, is closed during life, inasmuch as the two folds of zonula appear to rest on each other (*Henle*).

The zonula filaments are at first wavy or looped, and have the characteristics of connective or elastic tissue. In the anterior fold, however, they soon change their appearance. For here

stiff, smooth, transparent, sharp-edged, very elastic filaments appear, replacing them to a great extent; this gives to the zonula a very peculiar histological character. These filaments are arranged in tufts which, as the filaments separate brush-like, spread out toward the wall of the capsule and adhere to it by their flat surfaces. The greater part of these filaments meet on the margin of the anterior capsule, a smaller part on the periphery of the posterior. Hence a section made vertically and in a meridional direction through the zonula always gives a fan-shaped figure, whose concave central border is formed of the anterior and posterior capsule. Hence the zigzag line, which is described as a boundary of the ciliary processes, and which winds about from the anterior to the posterior capsule, is only the anterior border of the fan-like zonula attachment (*Henle*, *Heiberg*, *Ed. Jaeger*). The existence of obliquely-striated muscular filaments (*Finkbeiner*, *Heiberg*) in the zonula is at least doubtful.

Senile Changes.—Senile involution shows itself in the vitreous by a slight milky cloudiness which is particularly seen in the anterior external parts, and is caused by a delicate precipitate of an albuminous, finely molecular, dirty-yellowish mass containing fat globules. The occurrence of the latter is accounted for by the fatty degeneration of the cells of the vitreous (*Wedl*).

This senile process of fatty degeneration not unfrequently leads to complete liquefaction of the vitreous humor (synchysis). This always begins from the posterior portion, but gradually spreads out on all sides, without leaving any distinct boundary between the vitreous that has become fluid and that which, although normal in consistence, still contains cells undergoing fatty degeneration (*Iwanoff*).

It is said that senile involution occasionally manifests itself in the zonula by loss of the filamentary appearance, and the elasticity is so much diminished that spontaneous rupture and consecutive loosening of the lens from its attachments is favored (*H. Müller*). Deposits of coloid, and sometimes chalky, masses also occur, but appear to be rather changes of the tissues on which they are situated.

Nosology.—The fundamental or anatomical character of hyalitis may be said to be the profuse exit of white blood corpuscles from the vessels of the surrounding parts (*C. Ritter*, *Iwanoff*, *Blix*), their proliferation, and probably also of the cells of the vitreous humor itself.

Altogether, proliferation of the vitreous cells seems to be a frequent occurrence; at least there is every reason to refer the very frequent movable and many fixed scotomata (see this) to development and increase of the elements in question. Usually, however, the processes causing scotomata are not included under hyalitis, as they do not result in any decided objective changes of the vitreous, and also escape positive observation; for diagnosis of inflammation of the vitreous, as well as of keratitis, there must be some perceptible product, such as a new formation.

Hyalitis is frequently partial, and then, if not caused by injury, is confined to a peripheral part of the vitreous. Just as often, however, the whole vitreous is inflamed. The parts bordering on the ciliary processes and retina, as well as those organically united with the optic nerve entrance, usually show their predisposition by rich products of inflammation. Where the anterior part of the vitreous is affected, the zonula usually sympathizes most; it appears covered and infiltrated with the same neoplastic elements, from the vascular parts covering the ciliary processes. These proliferate into the vitreous.

The character of the hyalitis varies much, according to circumstances. Frequently the inflammation is suppurative; exceptionally it appears to be excretion of tubercle. Most frequently, however, the tendency is to hypertrophy; the new elements are not only proliferations, but higher formations, or have, under the influence of neighboring parts, changed to connective tissue.

In the purulent and rare tuberculous forms of hyalitis the entire vitreous is engaged, and the new formation is very extensive. But circumscribed abscesses, especially around foreign

bodies, do occur. (*Graefe, Donders, Ruete.*) The products are pus cells mixed with fatty detritus and a variable quantity of fatty or necrosed cells. At the same time appear groups of cells of higher formation, and bundles of neoplastic connective tissue. These products press so close together in some places that the vitreous between them totally disappears, and the whole assumes a caseous appearance. Frequently, at the periphery of the vitreous, they form large plates, which partially or entirely cover the posterior surface of the ciliary processes and the lens, as well as the inner wall of the retina, but toward the center lose themselves in a mixture of knobs and furrows, which project into the pus-infiltrated cells of the vitreous, or rather are surrounded by the fluid remains of the latter and loose flakes of pus.

The hypertrophic form of hyalitis is often partial, and as a rule less productive. As an immediate product of this, are often found at the commencement only sparsely-scattered groups of round or polygonal cells, enveloped in a fine molecular detritus and fatty granular masses, which give the vitreous a fine granular or indistinctly striated appearance, and cause it to seem opaque to the naked eye. But more frequently in the vitreous, which is clouded by inflammation, besides incubation foci of new cells, we meet products in which may be observed the most varied transformation of small nucleolar bodies of simple or multinucleated, round, polygonal, granular cells into other cells, which have already gone on to higher development. Thus, groups of cells appear in which individual elements have grown to stellated figures by addition of numerous processes. But these cells then generally have the character of true connective-tissue corpuscles, and surround with their net-like offshoots bundles of wavy fibers.

The connective tissue thus formed sometimes serves only as a scaffolding or envelope for cells of the most varied shape, and forms, in conjunction with the latter, papillary outgrowths of oval or elongated nodulated forms, which branch with one another, and when magnified appear as projecting points or network in the cloudy vitreous. (*C. O. Weber, Wedl.*) At other points the neoplastic connective tissue presents itself as irregular rays of wavy bundles of fibers. Most frequently, however, the elements approach more nearly, and so form knotty or membranous laminæ, which occasionally project into the vitreous, sometimes mingle and form network, again sharply bound the vitreous on one side or the other, and finally sometimes envelop foreign bodies as in a capsule.

In most cases the newly-formed connective tissue is traversed by more or less numerous vessels, whose branches anastomose with those of the surrounding vascular parts, as the ciliary processes, retina, or optic papilla. Sometimes the starting-point of these may be recognized as a knotty or bud-like outgrowth, which, proceeding from the vessels of the organ in question, grows into the vitreous, and here projects further and further by the addition of neoplastic cells. (*C. O. Weber, Wedl, Czerny.*)

The entire development of the connective tissue is intimately related to that of the surrounding organs. One part of it has usually the appearance of being connected with the stroma of the neighboring tissue, just as if the connective tissue was growing from without into the vitreous. The neoplasia in the anterior part of the vitreous often show this origin by the pigmentation of their cells.

The products of the inflammation do not always, however, attain a higher grade of development. Frequently, after advancing to a certain point, they retrograde, decompose into soluble substances and are absorbed, or by regressive metamorphosis become stationary.

Thus not unfrequently we find cells, or groups of cells, which evince the commencement of their decay by containing fat granules. Often these groups have decomposed and present only irregular masses, in which fatty detritus with more or less pigment forms the chief constituent. Elsewhere we meet single cells or groups, which by the addition of a thick mass, not liable to chemical action, have been transformed to a fatty-looking, clearly-layered and radiated solid body, which in polarized light shows a bright cross in a dark field. At the same time nests of cholesterine crystals, groups of pigment granules, and formations of carbonate of lime often appear; the latter are arranged like a wreath, and form loops which intertwine to make network figures. The products of regressive metamorphosis lie mostly in a finely-molecular cloudy vitreous, which often contains fat granules.

In some cases lines of cells crossing each other at acute angles point to the loss of a filament-

ary structure. As a rule, however, perfect connective-tissue elements long retain their original shape, even to the last stages of the retrogression of cells. They then usually become denser by shrinking. Sometimes they even become chalky or bony.

A mixture of variable amounts of extravasated blood, either fresh or affected by pigment metamorphosis, often occurs. To this is frequently due a great part of the accumulations of pigment found among the results of hyalitis.

Causes.—Hyalitis almost always depends on inflammation of the vascular parts surrounding the vitreous. This is true, with certain limitations, even of the developments causing scotomata, but still more so of hyalitis in the strict sense. But the vitreous participates more especially in the suddenly commencing and actively progressing affections, that is, in the suppurative forms of choroiditis, irido-cyclitis, retinitis, where it produces more or less pus, according to the character of the affection. Still, less intense and even slow chronic inflammations of the above-named organs often cause sympathetic affection of the vitreous; certain forms of these, as glaucoma, chronic irido-choroiditis, and neuro-retinitis rarely run their course without affections of the vitreous; hence cloudiness of the latter is mentioned among their symptoms. The results of hyalitis in cases of the latter kind are generally connective-tissue, fatty, or calcareous new formations.

Traumatic causes have little effect on the vitreous, and when hyalitis develops as a result of injury, it is not generally as a direct effect, the immediate cause being inflammation of the surrounding vascular organs; the vitreous participates only after there is inflammation in the latter, and the hyalitis is influenced by them in the most decided manner.

However, the dependence of hyalitis on inflammation of the neighboring organs is not absolute. Prolapse of the vitreous, as it occurs after some operations, *e. g.*, extraction of cataract, readily causes diffuse and membranous opacities without symptoms of inflammation necessarily occurring in the retina and uvea. But the possibility of an independent primary occurrence of hyalitis is most clearly shown when foreign bodies, entozoa, pieces of lens, extravasations of blood, etc., are driven deep into the vitreous. For not unfrequently these are rapidly enveloped in pus or in membranous new formations, which are not united to the surrounding organs in any perceptible manner; in some cases these foreign bodies are even incapsulated, without perceptible injury to the functional power of the vascular envelopes of the vitreous (*Kittle, Soelberg Wells*). In depression of cataractous lenses, it is just this incapsulation, without participation of the retina and choroid, that secures the success of the operation.

Foreign bodies, especially bits of steel, and pieces of gun-caps, which enter the cavity of the globe, exceptionally pass through the posterior wall of the globe, and then adhere to the orbital tissue, become buried in a muscle, and so on (*Berlin, Stavenhagen*). Sometimes they remain for some time in the posterior wall, and are then recognized by the ophthalmoscope (*Jacobi*). In by far the greater number of cases, however, they do not go beyond the choroid and retina, and are thrown back, leaving a fissure about as broad as a hair, and then fall down to the bottom of the eye. Foreign bodies are therefore usually found at the lowest part of the fundus oculi, and generally a little in front of the equator of the globe, since the plane of vision is usually directed a little downward, and when the eye is in this position the deepest portion is most apt to be entered by the foreign body. Under such circumstances extravasations of blood soon occur, running from the wound of the retina and choroid into the vitreous in all directions, but especially along the wound.

Suppurative choroiditis with dense opacity of the vitreous usually follows in a short time. In other cases the reaction is less severe, the retina and choroid undergo comparatively little change, except in the vicinity of the wound, and cloudy opacities are quickly formed around

the foreign body, which soon become dense, and which assume a laminated fibrous appearance at their edges. Sometimes even the course of the body may be recognized by an opaque line. A foreign body thus enveloped can, of course, be no longer seen; but its presence may frequently be detected by an interruption in the upper portion of the visual field, which, subsequently, when the choroiditis has made considerable advance, passes more and more into a general cloudiness of vision (*Berlin*).

Extravasations of blood in the vitreous are comparatively rarely seen. They sometimes originate from neoplastic vessels in the vitreous, and are then usually associated with extensive degeneration of the interior of the eye. In other cases they originate from the retinal, or even the choroidal, vessels. The cause is then usually traumatic, as a direct blow on the eye or a concussion propagated through the skull. Still spontaneous ruptures occasionally occur, and in some cases even a periodical recurrence of them has been observed. There is no doubt that disease of the vessels has something to do with this; occasionally simultaneous apoplectic attacks (*Rothmund*), or the precedence of frequent epistaxis (*Graefe*), seem directly to indicate this fact.

The hemorrhages announce themselves by total or partial darkening of the visual field, which either occurs suddenly or develops gradually, extends and even changes its locality, according as the blood from the first runs into the pupillary region of the vitreous, or only gradually presses into it, and, with progressive resorption of the vitreous, occupies more space. The splitting or breaking up of the vitreous caused by the hemorrhage, or perhaps even by the precedent injury, favors the movement of its parts. Hence it happens that the red glimmering shadows depending on the extravasation are often caused to vibrate irregularly by rapid movements of the eye, and, as it were, to roll around in the visual field. If the blood has sunk down, the shadows only appear on such motions, and disappear again when the eye becomes quiet, or they are only seen when the eye is in certain positions. With the ophthalmoscope, or by oblique light, the extravasations are easily seen.

They often disappear entirely in the course of a few weeks, after first breaking up into small heaps and points. More frequently, however, they leave behind more or less strongly pigmented, variously-shaped connective-tissue opacities in the vitreous; not unfrequently the inflammation produced by the injury, or the hemorrhagic breaking up of the vitreous, leads to its tendinous degeneration and to retinal detachment, or it becomes suppurative and destroys the eyeball, as a purulent panophthalmitis. Independent of severe and extensive injuries of the eye, such results are particularly to be feared in repeated effusions (*Förster*), as well as where choroidal vessels are the source, and the retina was originally torn by the injury, or by the blood collecting behind it. Still, even in such cases, at least a relative cure is not impossible (*Graefe*, *Becker*).

Symptoms.—In order to see the changes caused by hyalitis, the dioptric media must be transparent. But their transparency is frequently lost early in the disease. For where hyalitis begins with extensive products, the view of the interior of the eye is usually hindered, as in suppurative forms, by purulent infiltration of the cornea, hypopion, posterior synechiæ, and the results of capsulitis; but in the chronic form, by deposits on the capsule, closure of the pupil, or by cloudiness of the lens. As a whole, the type of hyalitis is rarely perfect; symptoms almost always co-exist which belong to the accompanying or developing choroiditis, cyclitis, or neuro-retinitis.

Apart from this, hyalitis shows itself objectively, by diffuse opacities within the vitreous, which, for their extent and thickness, depend much on the character of the process.

1. The commencement and lowest grade of hyalitis are mostly only to be recognized by aid of the ophthalmoscope, especially where the pupil is contracted, and the new formations reflect too little light to change the normal blackness of the pupil. Viewed through the ophthalmoscope, the inflamed parts of the vitreous appear as a diffuse, slight mist, which spreads out behind the pupil. Then the vessels of the retina, optic nerve entrance, etc., seem to be quite blurred. When the light reflected

from the mirror falls at certain angles, the mist appears distinctly, and here and there concentrates to thick points, blurred spots, striæ, etc.

2. If the process is further advanced, the opacity is, of course, more marked, and even with the naked eye, figured connective-tissue formations, with their mixture of pigment and cholesterine, may often be seen. These frequently only glisten indistinctly out of the diffused opacity; in other cases, their detail is especially with the ophthalmoscope, easily to be recognized, as they project beyond the cloudy parts of the vitreous. Thus we find, especially in the peripheral part of the vitreous, at its anterior zone, yellowish or whitish points, irregular spots, variously intertwined filaments and networks, in a delicate, cloudy opacity. In other cases, with or without these appearances, lines crossing each other are often seen through the ophthalmoscope to traverse the vitreous in all directions and form trelliswork. In some cases even vessels are seen, which divide up in the most varied directions (*Coccius*, *O. Becker*). All of these entoptic bodies are usually very movable, swinging freely on rapid motion of the eye, or even entwined through each other, and this occurs without fluidity of the vitreous.

These opacities are best seen, if, while examining by the reversed image, the lens is held so far from the eye that the cornea and iris are distinctly seen (*Schweigger*), or if the binocular ophthalmoscope be used (*Knapp*).

If a foreign body, as a fragment of the lens, etc., is driven into the vitreous, the whole track of the wound is often seen enveloped in a thick capsular envelope, from which numerous cloudy or striated crossing lines proceed, hiding the foreign body.

3. Where the anterior dioptric media have maintained their transparency, and nothing prevents the perception of objective light, the hyalitis becomes subjectively apparent through a more or less thick mist, which covers the visual field, and also through the shadows, which correspond to the new formations in size, form, and position, and are only distinguished from scotoma proper (see scotoma) by the absence of the characteristic details.

Results.—The products of hyalitis are, in general, the less changeable the more highly organized they are.

Polar cataract is not always of inflammatory origin; it does not always depend on hyalitis. Although it chiefly occurs in company with other changes in the eye, that indicate extensive proliferation, still it occurs quite often in eyes in which neither the state of the parts nor the history indicates an inflammatory origin. It may then be congenital. This is the more probable, as it is apt to occur with various anomalies of development in the eyeball: with great elongation or spherical shape of the globe, pigmentation of the retina, coloboma oculi, mikrophthalmos, etc., and is usually binocular. Moreover, in favor of this view is the fact that it is often accompanied by nystagmus, which almost exclusively proceeds from disturbance of vision in very early life. It is possible that its immediate cause may be an incomplete disappearance of the arteria hyaloidea and its branches to the posterior wall of the crystalline (*Ammon*). Sometimes there is marked pigmentation in its tissue; exceptionally, vessels still filled with blood are found in it (*Hasner*). In one case in a goat, the arteria hyaloidea could even be traced from the papilla to the polar cataract (*H. Müller*).

Late in life polar cataract easily causes total cataract. Its removal by operation is difficult, and is dangerous so long as the lens is transparent.

1. Diffuse opacities of the vitreous are, at the commencement at least, very changeable. They develop rapidly, and in a short time extend over the entire vitreous; disappear just as quickly, again to reappear, and so on. If the inflammation of the vascular envelope (which serves as the developing membrane

of the vitreous) ceases, and the nutritive condition of the internal parts of the eye takes a permanently favorable turn, the corpus vitreum frequently returns to its normal state. But if these attacks of inflammation occur frequently, and particularly if the developing membrane (Mutterorgane) is decidedly changed, the vitreous also suffers.

a. In some cases the corpus vitreum becomes partly or entirely fluid; *synchysis* of the vitreous occurs. Relatively this occurs most frequently in the ectatic forms of sclero-choroiditis, in highly-developed posterior staphyloma, in the disseminated variety of retino-choroiditis, and after extensive loss of vitreous, and it also results from breaking up of the vitreous in discision or depression of cataract.

Then the synchysis is sometimes simple, the vitreous dissolves into a pellucid fluid without any firm constituents; sometimes it is flaky, the fluid contains more or less degenerated remains of inflammatory neoplasia, groups of cells, clumps of pigment, cholesterine crystals, single or in groups, fat globules, etc. Simple synchysis, which usually occurs independently without precedent inflammation, does not show itself by any outward sign, or at most only by waviness of the iris and lens. In the flaky form of synchysis, on the contrary, the symptoms are very prominent. For with perfect quiet of the eye, the above-mentioned opaque bodies sink to the deepest part of the fundus, and hence disappear from the visual field of patient and observer. But on rapid motion they start up, shoot off in various directions, then sink slowly back.

Where there is much cholesterine in the fluid, the brightly-glittering bodies present a beautiful appearance, which, in some cases, may be compared to the twinkling of sparks or shooting stars. If the retina is healthy the phenomena appear to the patient also like stars suddenly lighting up, or a shower of sparks. At the same time cholesterine groups are often found in the anterior chamber. This state is called *synchysis scintillans* (*Desmarres*).

Synchysis greatly endangers the eye, as it usually leads to cataract and often causes partial or total detachment of the lens. It renders cataract operation very dangerous, especially extraction and depression.

b. In other cases the vitreous humor thickens and shrivels up. Since it then is drawn away from the posterior wall of the eyeball, it is detached from the limiting membrane of the retina, where it is not too closely united with the membranes lying beneath. The vacant space thus occurring is filled up by a serous product containing fibrin, but only rarely mixed with young cells. Thus detachments of the vitreous most frequently occur and are of the greatest extent where large quantities of inflammatory exudation, going on to a higher development, have been deposited in the vitreous humor, as a result of primary or secondary irido-choroiditis, however caused, but especially where foreign bodies or a depressed cataractous lens are seeking to become encapsulated (*Iwanoff*).

When the shrinkage continues in such cases, the vitreous recedes more and more from the membrana limitans, the space filled with serum becomes larger and larger, until finally the thickened fibrinous tissue of the vitreous is connected to the optic papilla by means of the cicatrix of the retina and choroid, or the fibrous envelope of a foreign body. In some cases the connection with the optic nerve entrance is broken up under the powerful traction of the shrinking neoplasia. The degenerated vitreous humor then becomes a brawny mass of tissue lying upon the zonula and lens and traversed by a tendon-like framework.

If, however, the vitreous humor, in consequence of the precedent inflammation, is partially or entirely adherent to the retina, and if the vitreous increases in size, the

retina must at last yield to its traction, and a detachment of both vitreous and retina result, or a detachment of the entire retina alone, which constantly increases, so that finally the retina is only connected to the walls of the globe at the ora serrata and at the entrance of the optic nerve.

We then find the vitreous more or less enveloped by the retina thickened by inflammation and changed into a truly tendon-like mass. (*Fig.* 27 *a.*) Besides containing variously-shaped cells and nuclei, there is frequently much pigment, while the vitreous is adherent to the ciliary body by means of flocculent connective tissue. This tendinous mass acquires a cup shape, and thus forms as it were a basis upon which the ciliary processes and lens lie. From the center of the cup there runs backward a pedunculated solid or striated process, *b*, which adheres to the center of the optic papilla. The cup and process are always surrounded by the retina, which is drawn together in such a way as to resemble a funnel, *c*. Occasionally this cup-like portion ossifies, and its edges come in immediate contact with a bony capsule, *d*, whose outer surface lies directly upon the choroid, and whose cavity is filled with a fluid, which washes around the funnel-shaped retina. This fluid is apt to be rich in protein materials and their derivatives.

Fig. 27.

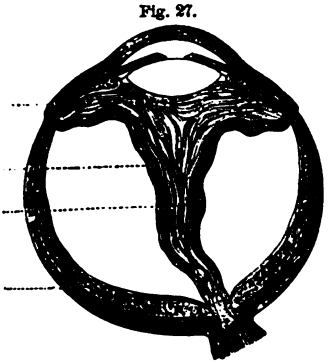

Ulcerations of the cornea and loss of the lens not unfrequently cause such processes in the interior of the eye. We then find (see Fig. 28) the vitreous humor surrounded by the funnel-shaped retina degenerated into connective tissue, *a*, and anteriorly lying upon a tendon like membrane, *b*, which covers the remains of the iris, *c*, and the ciliary processes, and at its center is united to a smooth cicatrix which takes the place of the true corneal tissue, *d*.

In one case, the optic papilla was dragged forward like a plug into the posterior chamber, while the inner layers of the retina were detached from the outer about the entrance of the optic nerve (*Iwanoff*).

Fig. 28.

Such detachments of the vitreous, caused by the shrinkage of the vitreous which has undergone tendinous degeneration, and which may be classed as *secondary*, are to be distinguished from the *primary*. In the latter form the vitreous humor is simply pushed away and separated from the limiting membrane of the retina by an inflammatory product or serous transudation from the membranes beneath. Such detachments, at least in the beginning, are usually confined to very narrow limits, and the tissue of the vitreous undergoes very little change. At the most it contains a somewhat greater quantity of young cells.

This condition, at times connected with small detachments of the retinal limiting membrane, is found as a result of suppurative panophthalmitis and nephritic retinitis (*Knapp*, *Berlin*, *Iwanoff*).

The exudation which causes the detachment is then apt to contain a great quantity of elements undergoing disintegration. As a rule, however, primary detachments of this kind are caused by increased filtration, in consequence of abnormally diminished intra-ocular pressure. This decrease in tension may occur from distention of the sclera, or from lessening of its contents. Thus a space is created which must be filled by fluid, in order that the equilibrium of pressure may be restored or approx-

imated. Indeed these primary detachments of the vitreous are usually found where there are large posterior staphylomata, and in all the varieties of sclero-choroidal staphylomata. They occur very readily from great and sudden lessening of the contents of the globe—for example, at the extraction of cataract (*Gouvea*), and in ulcerative or traumatic perforations of the cornea (*Iwanoff*).

Such detachments of the vitreous, when no inflammation occurs, especially in posterior staphyloma, may exist for a long time without in any way making themselves known. But when inflammation arises, whether caused by the fundamental disease or from some subsequent influence, adhesions of the vitreous to the surrounding membranes not unfrequently occur, as well as connective-tissue degeneration.

These changes by means of the shrinkage not only greatly increase the detachment of the vitreous, but are also combined with impairment of the functions of the retina, and thus produce a condition which can not be distinguished from the above-described secondary detachments (*Iwanoff*).

2. But every connective tissue or new formation in the vitreous humor does not necessarily lead to synchysis or detachment. On the contrary, the most different kinds of opacities of the vitreous may exist for years without producing any marked changes.

Moderately-sized new formations of connective tissue are most frequently found as regularly or irregularly limited tendinous-looking spots lying superficially in the center of the posterior capsule. They have been improperly called polar cataract, or posterior polar cataract, and in case they inclose the whole posterior surface of the lens, vitreous or hyaloid cataract. Cases occur where the anterior portion of the vitreous has completely degenerated into a connective-tissue neoplasia, and the lens seems to lie in the concavity of a membranous partition which completely shuts off the posterior portion of the eye from the anterior.

Polar cataract seems to have been confounded by many with posterior capsular cataract. This has occurred in consequence of the fact that at times the two forms are combined; yet the conditions are quite different. Posterior capsular cataract is situated within the cavity of the capsule itself, and arises from proliferation or disintegration of elements which are in the lens. Consequently, on oblique illumination a rough, often granular surface seems to protrude into the lens, while polar cataract has a brilliant smooth surface, which exactly fits on the posterior part of the lens.

Treatment.—This is about the same as that of the original disease, the retinitis or choroiditis. We need only say that in recent inflammatory diffuse opacities of the vitreous, which are not accompaniments of glaucoma (which has its peculiar indications), the inunction treatment appears particularly efficacious.

Organized membranous or band-like new formations of connective tissue, such as often occur after intense vitreous inflammation, hemorrhage, &c., and which may prove injurious as well by their effect on vision as by their reflex action on the retina, induce the attempt to cut or tear them with a sickle-shaped needle introduced through the sclera, and thus to permit the retraction of the individual portions.

Experience thus far (*Graefe*) seems to prove the practicability and good results of such a proceeding in appropriate cases.

Authorities.—*Anatomy: Brücke*, Anat. Beschreib. des m. Auges. Berlin. 1847, S. 31, 33.—*Hannover*, das Auge. Leipzig, 1852, S. 28, 94.—*Virchow*, dessen Archiv IV. S. 468, V. S. 278.—*C. O. Weber*, ibid. 16. Bd. S. 410, 19. Bd. S. 367.—*Klebs*, ibid. 19. Bd. S. 334, 21. Bd. S. 185.—

Kölliker, mikr. Anatomie. Leipzig, 1854. II S. 713, 716.—*Henle*, Handbuch der Anat. Braunschweig, II. 3. S. 670, 674.—*Doncan*, Diss. de struct. corp. vitr. Strassburg, 1854, und Henle, l. c.—*Bowman*, Lectures on the parts, &c., London, 1849 und Kölliker, l. c.—*Finkbeiner*, Zeitschrift f. wiss. Zoologie, VI. S. 330.—*Coccius*, Ueber das Gewebe und die Entzündung des Glaskörpers. Leipzig, 1860, u. kl. Monatbl. 1864. S. 319.—*H. Müller*, Würzb. naturwiss. Zeitschrift II. 3, A. f. O. II. 2. S. 43, 65, III. 1. S. 20, IV. 7, 392, 371.—*C. Ritter*, A. f. O. VIII. 1. S. 12. X. 1, S. 74, XI. 1. S. 99.—*Iwanoff*, ibid. XI. 1. S. 155 u. klin. Monatbl. 1864, S. 319.—*H. Heiberg*, ibid. XI. 3. S. 168.—*Ed. Jaeger*, Einstellungen des dioptr. Apparates. Wien, 1861. Taf. IV. Fig. 1.—*Dousmani*, Comp. rend. 61. Vol. i. P. 286.—*M. Langenbeck*, Die Insolation des m. Auges, etc., Hannover, 1859. S. 1.—*Ammon*, Archiv f. Anat. u. Phys. 1859. S. 1, kl. Darstellungen III. S. 67 u. Taf. 15.—*Arnold*, Untersuchungen im Gebiete der Anat. u. Phys. 1838. I. S. 215.—*Stellwag*, Ophth. I. S. 678 u. 714.—*Sämisch*, kl. Monatbl. 1863. S. 258.—*Zehender*, *Liebreich*, ibid. S. 259.—*Toussaint*, ibid. S. 350.—*Stör*, ibid. 1865. S. 24.—*Meissner*, Zeitschrift f. rat. Heilkunde. 3. Reihe. I. S. 562.

Pathology.—*Wedl*, Atlas. Lens Corp. vitr., Retina-Opticus.—*H. Müller*, A. f. O. II. 2. S. 47, IV. 1. S. 371, 375. Verhandlungen der Würzb. phys. med. Gesellschaft. 1858. S. 159.—*C. O. Weber*, Virchow's Archiv. 19. Bd. S. 394, 409, 15. Bd. S. 476.—*Coccius*, Ueber, Glaucom, etc. Leipzig, 1859. S. 47, Ueber das Gewebe, etc. 1860. S. 11, 24, and kl. Monatbl. 1864. S. 319.—*Meckel*, Ann. des Charité-Krankenhauses, V. Jahrg. S. 276 and *Coccius*, l. c.—*Stellwag*, Ophth. I. S. 698, 714, 732 Nota 310, S. 717, 793 Nota 385—398.—*Esmarth*, A. f. O. IV. 1. S. 350.—*Arlt*, *Förster*, kl. Monatbl. 1864. S. 364.—*Donders*, *Ruete*, *Arlt*, ibid. S. 323.—*Graefe*, A. f. O. I. 1. S. 351, 357, II. 2. S. 277, III. 2. S. 337, et seq. IX. 2. S. 79, 101, XI. 3. S. 38.—*Iwanoff*, ibid. XI. 1. S. 143—155, 195, 198.—*Schweigger*, ibid. V. 2. S. 221, 227, VI. 2. S. 259, et seq. IX. 1. S. 199, Vorlesungen über den Gebrauch des Augenspiegels. Berlin, 1864. S. 51, kl. Monatbl. 1864, S. 326.—*Pagenstecher*, A. f. O. VII. I. S. 92, 114.—*C. Ritter*, ibid. VIII. 1. S. 12, 52.—*Schiess-Gemuseus*, ibid. IX. 1. S. 39, XI. 1. S. 143, 154, 168.—*Jacobson*, ibid. XI. 2. S. 152.—*Kittel*, Allg. Wiener med. Zeitg. 1864. Nro. 43—45.—*Soelberg Wells*, kl. Monatbl. 1863. S. 449.—*Ed. Jaeger*, Oesterr. med. Zeitschrift, 1857. Nro. 2.—*Zander* und *Geissler*, Verletzungen des Auges. Leipzig. 1864. S. 202, 392.—*Tetzer*, Allg. Wiener med. Zeitg. 1862. S. 64.—*Rothmund*, Jahresbericht, etc. 1861-2. München, 1863. S. 19.—*Hasner*, kl. Vorträge. Prag. 1860. S. 248.—*Galezowsky*, Ann. d'oc. 51. Bd. P. 125.—*Desmarres*, ibid. 14. Bd. S. 220, and Traité des mal. d. yeux. Paris, 1847. S. 665.—*Knapp*, kl. Monatbl. 1863. S. 320.—*Schauenburg*, Ueber Cholesterinbildung im m. Auge. Erlangen, 1852.—*Seidel*, Wiener med. Wochenschrift, 1852. Nro. 34, 35.—*Rydel*, *Tetzer*, *O. Becker*, Wien. med. Jahrb. 1866. 4. S. 60, 63, 65. *Henle*, Zeitsch. f. rat. Med. 35. Bd. S. 121.—*Stilling*, A. f. O. XIV. 3. S. 260, 262, XV. 3. S. 299, 305.—*Iwanoff*, ibid. XV. 2. S. 33, 51.—*Sämisch*, kl. Monatbl. 1869. S. 303, 304.—*Wecker*, ibid. 1869. S. 210.—*D. Smith*, Lancet, 1869. Nr. 68, II. S. 275 u. f.—*Mooren*, Ophthalm. Beiträge. Berlin. 1867. S. 33.—*Mauthner*, Lehrb. der Ophthalmoscopie S. 250.—*O. Becker*, kl. Monatbl. 1868. S. 354.—*Blitz*, Centralbl. 1869. S. 200.—*Graefe*, A. f. O. XII. 2. S. 185.; kl. Monatbl. 1868. S. 301.—*Iwanoff*, A. f. O. XV. 2. S. 1. 21. 55. u. f.; Centralbl. 1868. Nr. 9; Congrès ophth. Paris, 1868. S. 121; kl. Monatbl. 1868. S. 297.—*Pagenstecher*, Centralbl. 1869. S. 676.—*Knapp*, kl. Monatbl. 1863. S. 320; Congrès ophth. Paris, 1868, S. 122; A. f. O. XIII. 1. S. 138, 162.—*Czerny*, Wien. Med. Jahrb. 1867. 1. S. 33, 41.—*Berlin*, A. f. O. XIII. 2. S. 283, 287, 298; XIV. 2. S. 275; Arch. f. Aug. und Ohrhlkde. I. S. 150.—*Jacobi*, A. f. O. XIV. 1. S. 138.—*Stavenhagen*, kl. Beob. Riga. 1868. S. 79.—*Mooren*, Ophthalm. Beiträge S. 199.—*Saemisch*, kl. Monatbl. 1867. S. 31.—*Dohmen*, ibid. S. 160.—*Alf. Graefe*, ibidem, 1869. S. 178.—*Mauthner*, Lehrb. der Ophthalm. S. 151.—*Gouvea*, A. f. O. XV. 1. S. 245.

THIRD SECTION.

INFLAMMATION OF THE OPTIC NERVE: NEURITIS OPTICA.

Anatomy.—The optic nerve originates by an anterior root from the *thalamus opticus*, and a posterior from the *corpora quadrigemina*, and also receives filaments from the *corpora geniculata*, *substantia perforata antica*, *tuber cinereum*, and the *lamina terminalis*. A few bundles of filaments connect it directly with the posterior columns of the spinal cord and the gray cortical substance of the brain. Its trunk advances from the brain, as *tractus opticus* or *stria optica*, along the posterior inferior surface of the optic thalamus; and, crossing the *crura cerebri* (without neurilemma, covered only by the delicate meninges), it runs forward at the side of the *tuber cinereum*, and in front of the *infundibulum* unites with the optic tract of the opposite side to form a chiasma.

This, with the two anterior parts of the striæ, bounds the floor of the third cerebral ventricle anteriorly and exteriorly. The optic nerves themselves proceed from its lateral portions; these, covered with neurilemma, run over the two segments of the *arteria corporis callosi*, somewhat divergently, to the two optic foramina; after passing these they become enveloped in a fibrous sheath, whose exterior is a continuation of the periorbita. They then run somewhat tortuously, and enter the eyeball within and below the center of the posterior half of the sclera.

In the chiasma a partial crossing of nerve filaments occurs; for, from the inner side of each tract, a bundle of filaments passes to the optic nerve of the opposite side, and goes with this to the inner half of the retina. But the greater part of the filaments of each tract remain on the same side, and run through the outer part of the chiasma to the optic nerve, to spread out in the outer half of the retina.

Nerve filaments of very different course are also found in the chiasma. A number of these, springing from the lamina terminalis cinerea, wind over the anterior border of the chiasma to its under surface, and, passing the posterior edge, return upward, to be lost in the gray hippocampus and infundibulum (*commissura ansata*). Another portion of the nerve filaments goes from the inner edge of the tract to the posterior edge of the chiasma, and runs back again on the inner edge of the other tract. In the same way a bundle of nerve filaments goes from the one optic nerve on the anterior side of the chiasma to the other (*commissura arcuata posterior et anterior*). (*Hannover*, *Bowman.*)

The fibrous sheath of the orbital portion of the optic nerve may be divided into two firm connective-tissue layers slightly mixed with elastic elements, an external thick, *a* (Fig. 29, after a preparation by *Czerny*), and an inner thin one, *b*. Between the two is formed a thin layer, *c*, of loose connective tissue, containing a few fat cells, which continues anteriorly into the substance of the sclera, *d*.

The outer stratum of the fibrous sheath, however, goes uninterruptedly, and at an oblique angle, into the posterior and middle layers of the posterior half of the sclera. The inner layer of the sheath, however, which represents the neurilemma, presses forward to the intra-ocular surface of the sclera, and there inclines under a more acute angle to the anterior layer of the sclera. So, at the optic foramen of the

sclera, a more or less projecting border, the connective-tissue ring (*Ed. Jaeger*), is formed, to which the edge of the posterior opening of the choroid, *e*, is attached by filamentary tissue. Posteriorly the scleral opening widens somewhat. It is entirely filled by the anterior part of the optic nerve.

Fig. 29.

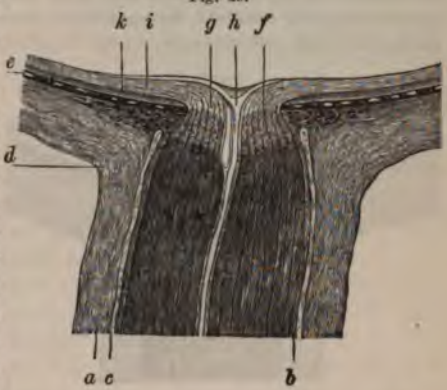

From the inner surface of the neurilemma, in the whole course of the optic nerve, proceed a large number of firm tendon-like processes, which envelop the individual bundles of the medulla, and in which the nutrient vessels and the nerves of the medulla branch out. Anteriorly and near the sclera these processes or internal nerve-sheaths become more abundant, and in the plane of the anterior scleral layer are strengthened by a thick network of elastic elements, which come from the thick tendinous sheath of the central artery of the retina, and unite with analogous fibers from the sclera, and form the so-called *lamina cribrosa*, *f*. This incloses the optic foramen of the sclera with a convexity directed somewhat backward, but affords the optic nerve-fibers and their sheath a passage. It often contains pigment cells.

Beyond the lamina cribrosa the bundles of optic nerve filaments separate more from each other (*Cauda-equina-nervi optici*, *g*), but remain enveloped in connective-tissue sheaths, which here are transparent even into the retina, *i*, whose bacillar layer is here indicated by *k*. In the interspaces are found large numbers of free nuclei or small cells, which in their entire bearing present some similarity to the cell formations found in the vitreous, and may be nearly related to the vitreous itself. For at the point in question the hyaloid, as well as the limitans, is entirely wanting; the vitreous lies immediately on the nests of cells traversed by soft connective tissue. The hyaloid is first developed at some distance from the center, apparently by the union of connective-tissue filaments (*Klebs*). The nervous tubes lose their medulla, become, like the sheaths, transparent, yellowish or grayish, and take on altogether the character of the finest tubes in the brain. The head of the optic nerve then becomes to a certain extent transparent, so that in ophthalmoscopic examination the lamina cribrosa is seen.

This boundary between pellucid and cloudy tissue is not always, however, very distinct. Sometimes the optic nerve tubes are accompanied even into the retina by their sheaths, especially those on the periphery of the nerve-trunk. Sometimes, also, the inner nervous sheaths partially preserve their opacity, especially at the *peripheral* zone of the papilla. On the other hand, we find cases where the *central* parts of the papilla are absolutely *more* transparent than normally, or where the tubes even before their passage through the lamina cribrosa have lost their sheath. Ophthalmoscopically these anatomical variations present themselves as excavations of the optic papilla. They are, therefore, described as "apparent *congenital* excavations" (*Ed. Jaeger*).

The optic-nerve fibers with their envelopes are elevated perceptibly above the level of the inner scleral surface before they enter the retina, and so form a slight prominence, the optic papilla. On the cadaver this often appears dish-shaped;

sometimes it is umbilicated, or even has a funnel or pot shaped excavation, a "true congenital excavation" (*Ed. Jaeger, H. Müller*). This is not always at the center of the disk, but often to the nasal side.

Such true congenital excavations are not generally deep. They rarely reach back beyond the plane of the choroid; therein they differ decidedly from the *apparent* excavations. Still *both* forms appear *combined*, for sometimes a true congenital extensive excavation is observed, partly filled with *pellucid* tissue, *a* (*Fig. 27, after Ed. Jaeger*).

Fig. 30.

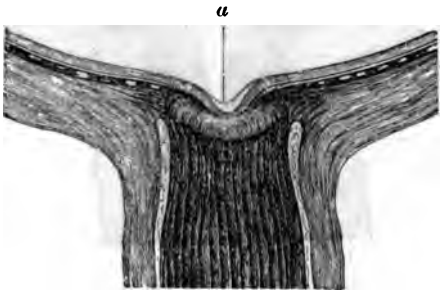

Blood-vessels.—The central artery sometimes originates directly from the ophthalmic artery, sometimes is a twig of the ciliary or muscular branch. A few lines behind the sclera it pierces the sheath and medulla of the optic nerves obliquely, and then, enveloped in a thick adventitious membrane, from which filaments everywhere project into the neurilemma, it usually runs anteriorly into the papilla without branching. In the latter it divides into two chief branches, of which one runs up, the other downward; these again usually divide either on the papilla or near its border, so that four large branches enter the retina divergently.

The retinal veins, like the arteries, unite to two superior and two inferior chief branches, which run in a convergent direction to the middle of the optic nerve entrance. These four branches usually form two near or on the papilla; these again unite at a point near the artery, or run apart as far as the lamina cribrosa, there to unite.

Occasionally, also, it happens that four chief veins enter the papilla at a distance from the arterial trunk, to unite farther back in the head of the optic nerve, or possibly to escape from the sheath of the nerve without uniting, and to empty into the orbital trunks.

The central vein and artery are never inclosed in the same sheath, and, as a rule, the former leaves the optic nerve quite near the posterior wall of the sclera.

It usually passes directly into the cavernous sinus, but is connected by numerous branches to the two ophthalmic veins, and thus communicates with the anterior facial vein (*Seseman*).

Besides the chief branches of the central vessels, a variable number of small arterial and venous twigs are always found on the papilla. These branch, and anastomose variously with the vessels of the retina and choroid, and thus form a vascular connection between the ciliary and retinal blood-vessels (*Leber*).

They lie sometimes superficially, sometimes deep in the substance of the papilla. Their twigs pass the lamina cribrosa sometimes at a distance from, again quite near to, the chief trunks; finally, they occasionally leave the central and posterior scleral vessels just at the papilla (*Leber*). With the exception of the latter branches they are usually offshoots from the arteries and veins supplying nutriment to the optic nerve. Most of the latter originate from the ciliary and muscular arteries, penetrate the sheath with the nerve-twigs, and finally, with the filamentary processes from the interior of the sheath, they enter the medulla of the optic nerve.

Lymphatics.—Lymphatics are said to be very numerous in the trunk, and particu-

larly in the inner sheath of the optic nerve. They run somewhat independently of the blood-vessels. They are considered as canals for the carrying off of the retinal lymphatics (*His*). In the *lamina cribrosa* the lymphatics are said to form a thick network, which is connected to the space between the sheaths (*H. Schmidt*). This latter, however, has been considered as a lymph cavity lined by endothelium, which is connected with the arachnoid space in the cranium (*Schwalbe*).

Ophthalmoscopic Appearances.—1. On examination with the ophthalmoscope, the optic nerve entrance is seen as a clear round disk projecting from the surrounding surface, on which we see the central parts of the retinal vessels running up and down.

The disk is rarely perfectly circular, often slightly oval, with the long axis perpendicular, occasionally somewhat flattened or bulged out on one side or the other. Its angle to the visual line has an evident influence on the form in which it presents itself to the examining eye, and may easily give rise to deceptions.

The disk is usually sharply bounded, since its borders (the edge of the posterior choroidal opening) are only covered by the pellucid expansion of the optic nerve. This choroidal edge is often partly or entirely bounded by a dark pigment; hence, especially in dark-haired individuals, we often find at the border of the optic nerve entrance a black or brown granular stripe, which surrounds an arc or even the entire periphery of the disk. Besides this, we often find the optic nerve disk surrounded by a clear whitish-yellow ring, the connective tissue or sheath ring (chrom. lith., A, N), which in different persons is of different width; moreover in the same case it varies in width in different places, and is often even reduced to a small crescentic figure which incloses the outer border of the disk.

This ring or crescent is evidently elevated above the surrounding parts, so that we may distinguish a choroidal boundary and a scleral or inner border. The latter under normal circumstances is not usually very sharp, but in material changes of the papilla appears more distinct. The choroidal border, on the contrary, is always strongly marked, and often strewn with pigment.

Under normal circumstances the disk is always of the same size on both sides. But the size of the image perceived always varies much, according to the position of the examining and examined eye, and the refraction of the rays in the dioptric apparatus of the ophthalmoscope used. The prominent color is usually yellowish-white, often, however, grayish-yellow, clear brownish-gray, or slightly bluish. In dark-haired individuals, with strongly pigmented choroid, the color is mostly much brighter than in blondes, on account of the contrast.

Moreover, the color of the artificial light used, the more or less oblique illumination, etc., have a decided influence on the color of the papilla. The reddish color appears especially often on the peripheral parts, particularly between the larger vessels. It is here occasionally so intense, that in absence of the connective-tissue ring the optic nerve projects but slightly from the surrounding parts of the fundus.

We often, also, find the optic papilla unevenly colored, covered with more or less distinct gray or grayish-blue, but oftener dirty-brownish clouds, between which lies a net-work of clear striæ, which is united to the connective-tissue ring. These bright striæ are caused by the lamina cribrosa and the inner nerve sheath, the cloudy gray appearance by nerve tubes (*Ed. Jæger*). In very rare cases a quantity of pigment appears in the tissue of the papilla. This is generally pathological, and may usually be traced to extravasations of blood. Still, it does sometimes occur as an original product, and depends on great pigmentation of the uvea (*Liebreich*, *Knapp*, *Hirschberg*, *Pagenstecher*).

2. The vascular trunks advance in a radiated direction from the center of the disk or somewhat inward from it, proceed in an arc convex anteriorly to the periphery of the optic nerve entrance, and then sink into the retinal tissue. On account of the great pellucidity of the nerve tubes, in the whole territory of the papilla, they may usually be distinctly perceived; but when the disk is more cloudy, its central part, from the lamina cribrosa to the surface, appears veiled, dull, and less sharply bounded; it is distinctly seen that the vascular trunk only gradually presses its way from the cloudy mass to the surface, and becomes more sharply defined the farther it is from the lamina cribrosa.

The arteries are brighter-colored and smaller, run straighter, and, on account of their cylinder-shaped border, often show on one side a bright line, a sort of catacaustic. The veins are darker, broader, more tortuous, and from their flat shape do not have this light border.

The trunk of the artery often advances undivided near to the limitans, then splits into two chief branches, which form a T with the first. In other cases the division occurs even in the porus opticus, in the lamina cribrosa. From this point the two chief branches advance up and downward; and in case the substance covering the papilla is very cloudy, it may even appear as if they came from different openings in the lamina cribrosa. Occasionally one chief branch appears to be a twig of the other with which the trunk is continuous. Usually these primary branches divide up, even within the optic nerve entrance, into two smaller branches.

The trunk of the vein lies near that of the artery. Often, however, the four veins first unite near the porus opticus to two trunks, or all four enter the opening separately, and at some distance from each other.

Small offshoots often spring from the chief branches of the veins and arteries, even within the papilla, which go in the most varied directions to the retina. But besides this, at various points are seen small vessels which come from deeper layers, and occasionally form a thick net or sort of convolution, which partially covers the optic-nerve entrance and envelops the chief branches.

3. Congenital excavations of the optic-nerve entrance are of great practical importance. They occur very often, are met as well in the eyes of infants as of adults, and as a rule exist for life without material change. In most cases they are shallow and small, and hence are difficult to recognize. Very often, however, their apparent or true dimensions are considerable; they then appear very marked when seen by aid of the ophthalmoscope.

This excavation is seen as a whitish, or whitish-yellow, spot in the *porus opticus*, more translucent and brighter than the surrounding part, and which stands out prominently from the peripheral zone of the optic disk. The other parts of the papilla, being much darker, are usually decidedly red, and of the same color with the remainder of the fundus. (Fig. A, N.)

The excavation appears as a more transparent and clear whitish or whitish-yellow spot, situated in the territory of the porus opticus, which is strongly distinguished from the decidedly darker, usually more reddened bordering zone of the nerve disk, which is often of the same color as the rest of the fundus. (*Chrom. lith.*, A, N.) This spot is sometimes round, sometimes oval or elongated, with its long axis directed horizontally or obliquely outward and downward, rarely slit-shaped, and exceptionally scalloped. The diameter of the true or apparent entrance is often only a small part of the diameter of the papilla; but in other cases it is so great that the darker border of the optic disk presents only a *small* ring. The *boundary* of the excavation in the ophthalmoscopic image is not always very sharp. In superficial excavations, with sloping edges, the darker line of the border of the

margin shades off gradually into the brighter hue of the center of the disk. In funnel-shaped excavations, with steep walls, however, the transition is *rapid*, the boundary-line very sharp. Sometimes, behind the boundary-line, we notice a dark shadowy border, the excavation acquires an ampullar appearance, with a neck-like contracted opening and widened excavation. The fundus of the excavation itself appears smooth, sometimes like the normal papilla, uneven from depressions and elevations.

The position of the central vessels is also very characteristic, since the excavation has great influence on their course. In trough-shaped or small funnel-shaped excavations the middle portions of the vessels appear arched; with a more or less pronounced curve they sink backward into the porus opticus, and there, on account of their oblique position, appear much darker. In large excavations with abrupt sides, however, the vessels bend suddenly at the entrance; they there show quite a marked inclination and much darker color (*chrom. lith.*, N), since the portion of vessels running backward presents the inclosed column of blood in the long axis. In ampullar-shaped excavations, with contracted openings, we find the vessels behind the bend frequently displaced or even interrupted by the dark shadowy ring, so that it is difficult to find out the parts belonging to each other, especially as the parts of vessels running on the walls of the excavation are usually joined together, plexus-like, by oblique and short lateral branches.

Moreover, in the territory of the excavation the vessels can not always be clearly followed. Often they are apparently altogether wanting; the retinal vessels curve beak-like on the edge of the excavation, and disappear suddenly, as they sink into the cloudy tissue of the optic papilla bordering the excavation. In other cases, the vessels in the excavation appear covered with a cloudy veil; they present themselves as delicate, rose-colored, indistinctly-bounded, band-like striæ, which run from the porus opticus to the entrance of the excavation.

4. One peculiar ophthalmoscopic phenomenon is the pulsation of the chief branch of the central vessels. It is only perceptible in the papilla, and only very exceptionally extends behind its border.

The venous pulsation (*Trigt, Coccius*) is a constant physiological appearance (*Donders*); but in the normal state it is not easily recognized. Where it is apparently absent, it may often be rendered visible by a continued moderate pressure on the side of the eyeball. It shows itself by a stronger or weaker filling of all the parts affected. The contraction begins at the porus opticus, somewhat before the diastole of the central arteries, and advances toward the periphery of the optic-nerve entrance. The diastole of the veins, on the contrary, begins at the periphery, immediately after the radial pulse, and progresses centripetally. If the pressure with the finger be increased, the distinctness of the venous pulse also increases, and shows itself in an alternate complete emptying and refilling of the vessels affected.

With the venous systole a part of the contained blood recoils outward through the porus opticus, but the other part, under centrifugal, progressive flattening of the veins, is drawn back toward the capillaries. But with the venous diastole their filling and consequent expansion follows from the periphery, and advances toward the porus opticus. Where the venous pulse is very strong in the papillary part of the chief branches, we distinctly see the stream of blood move to and fro; its central end is sharply bounded, cut off perpendicularly or conically, according to circumstances, and hence elevates itself clearly from the contours of the compressed bloodless parts of the vessels.

Under normal circumstances, the arterial pulsation (*Ed. Jaeger*) is not percep-

tible, although it certainly exists. But the wave of blood advancing with e systole of the heart moves too rapidly, and with too little lateral motion through entire length of the part of the vessel in sight, for the variation in caliber of latter to be perceived. To excite the arterial pulsation artificially, we must strong pressure from without, except where the arteries are very rigid; then slight pressure suffices (*Graefe*). Its perceptible occurrence is always accompa by a darkening of the visual field (*Donders*). It sometimes appears in one, times in all the branches of the central retinal artery, and manifests itself by ryhthmical filling and emptying of the parts of the arterial branches lying on optic papilla. The arterial diastole begins with the radial pulse, and somewhat af the carotid pulse. It appears as an impulsive, rapid entrance of a column of blo into the previously contracted or empty portion of the artery. The subsequ systole requires more time, and shows itself as a slow centrifugal, partial or e emptying of the visible portion of the vessel.

If, with the advancing arterial wave, a greater portion of blood entered the eye, the int ocular pressure would be correspondingly increased. But this is not the case. For the pressure of each advancing arterial wave is propagated more rapidly through the vitreous than through the capillaries to the veins; indeed the transfer of pressure through the vitreous is almost instantaneous. Hence, before the positive wave enters the veins, it has caused the evacuation a proportionate amount of venous blood, a venous systole begins simultaneously with the arterial diastole, both reach their maximum at the same moment, and again sink to a minimum. Hence, the intra-ocular amount of blood and the intra-ocular pressure are not changed by the arterial diastole. The possibility of a pulsation of the entire eyeball, that has been asserted by some (*Graefe*, *Coccius*), if the observations are correct, presupposes very peculiar pathological conditions. It is only supposable in excessive arterial diastole, where the ocular capsule is excessively distensible, and the escape of venous blood obstructed.

The pressure transferred from the arterial wave to the contents and capsule of the eye, acts on the veins in proportion to their surface. Hence it is evident that the effect must be felt first and most strongly on the flat ends of the chief venous branches, and this is the more certain to occur as the blood flows more easily, and can follow external impulses the more readily, the larger the caliber of the vessel. Hence the perceptible mechanical effect of the wave, divided up through the whole intra-ocular arterial system, is concentrated, as it were, on the central venous branches; these are compressed, and the parts lying near the porus opticus are rapidly emptied, while the distant parts are congested. Meanwhile, the impulse of the arterial wave continues through the capillaries into the veins, and drives the stagnated blood forward, the central part of the veins are again filled, and are dilated during the diastole, while the central artery simultaneously passes through its systole, thus furnishing room for the venous diastole.

Hence the venous pulse depends on the arterial; it is the apparent effect of the usually invisible arterial pulsation, and brings to light objectively the action regulating the stability of intra-ocular circulation, and the conditions of pressure governing the interior of the eye (*Memorski*).

But if the venous pulse is the mechanical effect of the arterial pulse, it is evident that it must become more perceptible, and that the column of blood in the central venous trunks must vary more, the greater the difference in the lateral pressure caused by the arterial wave on the contents and capsule of the globe during the diastole and systole of the intra-ocular arteries. Hence the more irregularly the blood flows into the arteries, the more limited is the regulating influence of the elastic arterial walls within and without the globe.

In fact an extensive spontaneous venous pulsation is never absent when there is any perceptible arterial pulsation, or where this can be produced by slight pressure and conversely a decided spontaneous venous pulsation is usually associated with spontaneous or easily-produced arterial pulsation.

Clinical observation also shows that rigidity of the trunk and branches of the ophthalmic artery and of the capsule of the globe are active factors among the pathogenetic causes of the symptoms in question.

There is scarcely a doubt that the elasticity of the ocular capsule, even if slight, seconds the contractility of the walls of the vessels in regulating the arterial current; for the intravascular lateral pressure transferred through the contents of the globe to the ocular capsule must react through the same medium on the outer walls of the vessels. But this implies that the loss or diminution of elasticity of the ocular capsule increases the rhythmical vibrations of the column of arterial blood, and consequently the perceptibility of the intra-ocular pulsation.

The same circumstance also explains the great effect that experimental increase of intra-ocular pressure has on the occurrence and extent of the pulsation. The elasticity of the ocular capsule is very light; it diminishes in proportion to the pressure, and the eye-ball acquires rigid walls in proportion as the elasticity is affected, and the tension approaches its maximum.

This state of the ocular capsule, then, is one cause why strong external pressure on the eye increases the appearance of pulsation. Another cause is, that external pressure on the capsule and contents of the globe is transferred to the outer walls of the vessels, and thus the resistance to the entrance of blood into the intra-ocular circulation is increased. If the external pressure attains a certain grade, it easily happens that the systole of the extra-ocular arteries no longer suffices to throw the blood in a continuous stream through the porus opticus in the lamina cribrosa, but that the filling of the central artery must be accomplished by the immediate pressure of the systole of the heart, and hence is impulsive. But if the pressure is further increased the arterial blood can not flow in during the entire period of the arterial diastole, the intra-ocular arteries fill themselves incompletely only for a moment during the maximum of the positive wave. Their diastole becomes constantly shorter and more incomplete, the systole longer, and these phases also correspond with similar phases of the venous pulse. Diastole and systole become isochronic in the arteries and veins, since at the maximum of the positive wave the walls of the vessels are pressed from within and without, and being held, as it were, between incompressible fluids, play the part of rigid tubes, so that the impulse of the arterial blood passes directly through the capillaries to the blood in the veins, driving the latter before it. On the strongest external pressure, the arterial blood-wave will not be able to enter at all. The entrance and exit of the blood ceases, the central parts of the arteries and veins appear empty, contracted, and only in the latter do we still occasionally see a slight, excursive to-and-fro motion of the column of blood.

Nosology.—The inflammatory change of tissue probably always commences in the neurilemmatous envelope of the nervous bundle. At least it is always found first and most remarkably changed, traversed by more or less thicker vascular nets, or regularly reddened, often also spotted with blood extravasations, and pervaded with inflammatory products, spongy and relaxed. When the process does not advance too rapidly and cause an actual breaking up of the tissue, the primitive nervous tubes for a long time do not show any decided participation, by either losing their medulla or by becoming transparent and varicose or fatty.

The *inner* sheath, and especially the stratum of loose connective tissue, which lies between the two sheaths of the orbital portion of the optic nerve, also usually appears more or less involved in the change of tissue. This occurs, also, in the *meningeal envelope* of the cerebral portion, but less often, however, in the entire sheath of the optic nerve.

The quality and quantity of the product vary in some degree, according to the intensity of the inflammation. In many cases it develops itself only in a slight quantity, with a few nuclei and cells, and remains rather transparent.

The neurilemmatous envelope participates in this peculiarity, and thereby acquires a peculiar gelatinous appearance. Consequently, to the naked eye, the tissue is but slightly changed; it only appears somewhat swelled and more succulent. In the papilla especially the change is so slight, on account of the natural transparency of the elements, that it may easily be overlooked, if the accompanying hyperæmia or any existing extravasation does not call attention to the disease. Later, however, the nervous tubes evidently participate; their medulla becomes transparent, they elevate themselves but slightly from the semi-opaque envelope, and finally are actually destroyed; the affected portion of the nervous trunk is apparently or actually gelatinously degenerated, and becomes diaphanous.

More frequently, however, the cell and nuclear development is more extensive, a part of the newly-formed elements undergoes fatty degeneration, and in variable proportion becomes changed to granular cells and groups of granules; while simultaneously colloid masses develop in variable degree. Then the product appears from the first more cloudy, wheyey, or even pus-like.

The nervous bundles, inclosed by the infiltrated neurilemma, under such circumstances usually very soon betray their participation by fatty degeneration, by breaking up into fat granules, laid on each other in series, and finally by complete destruction. It is, of course, understood that by such a product the normally transparent papilla is decidedly clouded. In the medullary portions of the optic nerve, however, very evident changes are not necessarily caused; to the naked eye the affected portion appears at most somewhat hyperæmic, sprinkled with blood, relaxed, and to some extent destroyed.

In some cases the alteration of tissue is *active* and very great; the nervous tubes and their connective tissue envelopes are entirely destroyed; at the affected part the optic nerve is found changed to a more or less consistent mass of pus, in which only shreds of nerve tubes and of the necrosed neurilemma can be found.

In rare cases the interstitial tissue swells greatly, as a result of extensive infiltration by a product which is transparent or clouded with molecules and fat globules, turbid, or very fluid and serous. In the cranial portion this serous product occasionally collects to such an extent as to cause it to swell to the size of the little finger (*Hydrops nervi optici*). Then proliferations of the nuclei and their consequences, especially granular cells, subsequently varicose expansion and fatty degeneration of the nerve tubes, hypertrophy, and partial fatty disintegration of the connective tissue occur. So far this condition has always been found with extensive and usually inflammatory œdema of the basal meninges, which again is usually, but not always (*Manz*), associated with Bright's disease of the kidneys or tuberculosis, and occurs along with collections of serum in other parts. The hydrops nervi optici in question should not be confounded with the frequently-occurring inflammatory œdema of the papilla (*Heymann*), and with serous infiltrations of the orbital interlamellar layer (*Ammon*).

Only very exceptionally does the process appear limited at a certain part of the nerve to a few bundles; almost always the nerve shows itself affected throughout its entire thickness; still it frequently happens that in the same section the grade of the alteration at different points is varied, so that some bundles are already destroyed, while others are slightly affected, and may be functionally active up to a certain point.

Often we find both optic nerves affected throughout their length by inflammatory change of tissue, and, following the peculiar product, can trace the course of the two tracts into the brain as far as the corpora geniculata, where the characteristic alterations usually cease with a sharp border. The grade of the diseased alteration of tissue is then usually different in the two nerves and at different parts of the same nerve. Exceptionally the process is confined to one stria, or to the chiasma and the two tracts. Most frequently, however, only the one or the other individual optic nerve is affected, and often remains so through life, since the process limits itself in the ante-

rior half of the corresponding lateral portion of the chiasma, in a sharp arc directed backward or in an ill-defined line. When the orbital portion of the optic nerve is inflamed, whether the process commenced there or was propagated from the cranium (*neuritis descendens*), the optic papilla almost always shows its participation. It swells around the entrance of the vessels to a circular pad, over which the central portion of the retinal vessels run in an arc usually very distinctly convex anteriorly, the papilla, at the same time, usually appearing very cloudy from the infiltration, reddened by the injected fine vessels, and often spotted by hemorrhagic extravasations. In by far the greater number of cases the inflammation does not remain limited to the papilla, but attacks the retina; the process appears as neuro-retinitis (see *Neuro-retinitis*). But if the cranial portion be affected, and, as often happens, the proliferation of tissue does not extend down along the optic nerve to the eye-ball, the orbital portion and papilla and the filamentary and ganglion layer of the retina usually atrophy, and the process appears objectively as a pure atrophy of the optic nerve and retina, but subjectively as cerebral amaurosis (see *Amaurosis*).

In very rare cases large extravasations of blood have been observed in the orbital portion of the optic nerve. In some cases the blood was exuded into the space between the sheath, and distended the outer sheaths, in a fusiform shape (*Ig. Meyer*, *Knapp*).

Again it was found in the nerve trunk itself, and had actually disintegrated its tissue to a certain extent (*His*, *Leber*, *Hirschberg*). It is believed that such hemorrhages, by means of the diffusion of the coloring matter of the blood and its further disintegration, may cause the rich pigmentation of the optic papilla that has been sometimes observed (*Knapp*). The fact that considerable extravasations in the optic nerve entrance are very commonly entirely absorbed without leaving a trace behind, is an argument against this view (*Wecker*).

Authorities.—*Kölliker*, Mikr. Anatomie, Leipzig, 1852. II. 1. S. 480; II. 2. S. 670.—*Bowman*, Lectures on the parts, etc. London, 1849, und Kölliker, l. c.—*J. Wagner*, Ueber den Ursprung der Sehnervenfasern. Dorpat. 1862. S. 21.—*Hannover*, Das Auge. Leipzig, 1852, S. 1.—*Henle*, Handbuch der Anat. Braunschweig, 1866. II. 3. S. 582.—*Sappey*, Centralbl. 1868. S. 421.—*Ammon*, Prager Vierteljahrschrift, 1860. I. S. 132; A. f. O. VI. 1. S. 15, 17, 33.—*Klebs*, Virchow's Archiv. 19 Bd. S. 321, 335.—*Donders*, A. f. O. I. 2. S. 75, 83, 90.—*Graefe*, ibid. I. 1. S. 375, 382; I. 2. S. 299, 302.—*Förster*, ibid. III. 2. S. 86.—*H. Müller*, ibid. IV. 2. S. 3, 10.—*Liebreich*, ibid. IV. 2. S. 295; Atlas. Tafel 12. Fig. 3; kl. Monatbl. 1864. S. 229; 1868. S. 426.—*Leber*, Denkschrift. d. k. Akad. 24. Bd. S. 318; A. f. O. XIV. 2. S. 169, 333, 343, 357; kl. Monatbl. 1868. S. 302, 309.—*His*, Beiträge z. norm. u. path. Histolog. der Cornea. Basel. 1856. S. 132; kl. Monatbl. 1867. S. 133, 135.—*Ed. Jaeger*, Wiener med. Wochenschrift, 1854. Nro. 3–5; Staar und Staaroperationen. Wien. 1854. S. 105; Beiträge zur Pathol. des Auges. Wien. 1855, Taf. I; Einstellungen des dioptr. Apparates. Wien. 1861. S. 30, 48, 52.—*Knapp*, Canstatt's Jahresbericht 1864. III. S. 158; A. f. O. XIV. 1. S. 252.—*Mauthner*, Lehrb. d. Ophthalmoscopie, S. 252.—*Sesemann*, Arch. f. Anat. u. Phys. 1869. S. 170.—*Pagenstecher*, A. f. O. XV. 1. S. 243.—*Trigt*, Nederl. Lancet 3 Ser. 2. Jahrg. S. 456; Der Augenspiegel, übersetzt von Schauenburg. Lahr. 1854. S. 49.—*Coccius*, Ueber die Anwendung des Augenspiegels. Leipzig, 1853. S. 3; Ueber Glaucom. Entzündung etc. Leipzig, 1859, S. 13.—*Schweigger*, Vorlesungen über den Gebrauch des Augenspiegels. Berlin. 1864. S. 70, 142.—*Zander*, Der Augenspiegel. Leipzig, 1862. S. 86.—*Mayrhofer*, Zeitschrift der Wiener Aerzte. 1860. Nro. 47.—*Memorski*, A. f. O. XI. 2. S. 84, 104, 112.—*Türck*, Sitzungsberichte der Wiener kais. Akad. IX. S. 231; Zeitschrift der Wiener Aerzte. 1852. II. S. 301.—*Stellwag*, Ophth. II. S. 567, 617, 619.—*Wedl*, Atlas, Retina-Opticus.—*Heymann*, kl. Monatbl. 1864. S. 273.—*Manz*, ibid. 1865. S. 280.—*Hirschberg*, ibid. 1868. S. 426; 1869. S. 74.—*Wecker*, ibid. 1868. S. 304.—*Ig. Meyr*. Beiträge z. Augenheilkunde. Wien. 1850. S. 24.—*Schwalbe*, Arch. für mik. Anat. VI. S. 47.—*H. Schmidt*, A. f. O. XV. 2. S. 142.

FOURTH SECTION.

INFLAMMATION OF THE RETINA; DICTYITIS; RETINITIS.

Anatomy.—The retina lies smoothly between the pigment layer of the choroid and the vitreous, to whose hyaline membrane it is closely adherent during life. Posteriorly it is bounded by the optic nerve entrance, anteriorly by the ora serrata, where it becomes adherent to the choroid.

A *pars ciliaris retinæ* is also described. This is really a process of the retina, although it no longer bears a nervous character, but consists of a layer of elongated cells which lie on the zonula, and have been recently recognized as shortened radial or supporting filaments (*H. Müller*, *Klebs*).

The retina is not perfectly transparent. At the posterior end of the optic axis, in the horizontal meridian, about one and a half lines from the outer edge of the optic-nerve entrance, is the yellow spot, the *macula lutea*, the most sensitive part of the retina. This spot is horizontally oval and somewhat variable in size. Its center is excavated in the form of a fossa, *fovea centralis*, and the retina around it appears pressed forward like a wall.

The retina consists partly of nervous elements, partly of modified connective tissue, which envelops and holds together the former, retaining them in their relative positions. At the center the nervous tissue predominates, but at the periphery the connective-tissue framework is in excess.

Strictly speaking, and especially in a genetic point of view, the choroidal tapetum also belongs to the retina. For it either originates alone (*Babuchin*, *M. Schultze*, *Barkan*, *Haase*), or in connection with the layer of rods (*Kölliker*) from the outer stratum of the secondary ocular vesicle, while all the other layers proceed from the inner lamellæ of this fœtal formation.

1. The nervous elements appear quite different in the different layers of the retina. They are divided into *mosaic* layers (which are intimately connected with the specific irritation of the sense of vision), and proper *nervous* layers, whose elements correspond with those occurring in all parts of the brain (*Henle*). Hence the strata in question may be compared to a flat expansion of a cerebral ganglion (*Kölliker*), and the rather so, as they originally represent a portion of the cerebral substance, and are only subsequently separated from it by parts being pushed in between, and later exist independently.

Passing from without inward, we usually distinguish eight layers in the retina, as follows: The layer of rods and cones (Fig. 30 *a*), the external limiting membrane or limitans externa *b*, the external granule layer *c*, the intergranule layer *d*, which is also called the external fibrous layer or membrana fenestrata; the internal granule layer *e*, also called the granule-cell layer or external ganglion layer; farther the granulated layer *f* or internal fibrous layer, the ganglion cell layer *g* or internal ganglion layer; the layer of nerve-fibers *h*, and finally the internal limiting membrane *i*, or limitans interna.

The layer of rods and cones, the two granule layers, the layer of ganglion cells and the layer of nerve-fibers are regarded as the actual nerve elements. The rods and cones may be divided into an external and an internal segment, which are structures of a totally

different nature, and of a different chemical composition (*Braun*, *M. Schultze*, *Hasse*), and are connected with each other by a thin layer of cement of a very low refractive power. The same slightly refracting basement substance is found in both, with a denser external membrane, and containing molecules of a more highly refractive power. The molecular substance is massed together in the outer segments in a number of layers, lying parallel to one another and of a measurable thickness, which are separated from each other by exceedingly thin layers of the less highly refracting basement substance (*M. Schultze*). The so-called Ritter's fibre, which is said to lie in the axis of the outer segment (*C. Ritter*, *Hensen*), does not exist (*M. Schultze*). In the inner segments of the cones (*W. Krause*) and rods (*M. Schultze*), the more highly refracting molecular substance is arranged in the form of plano-convex bodies, either semi-globular or like truncated cones, and of a homogeneous nature. They are situated at the external end of the inner segments, with their flat surface turned towards the external segments. A fine delicate fiber runs in the axis from the convex surface inwards (*C. Ritter*, *Hasse*, *Manz*), and is connected either directly or indirectly with the external granules. Extremely delicate longitudinal lines may be observed upon the surface of the inner segments, and are prolonged for some distance upon the external segments. This appearance depends upon the presence of very fine fibers, which proceed from the rod and cone fibers, and, perforating the external limiting membrane, surround the inner segments like a cup, and, running in a very loose spiral, pass over upon the outer segments and inclose their inner part like a tube. These may possibly be of the same nervous nature, and may arise from the division of the fibers of the rods and cones (*M. Schultze*). The external granules are ellipsoid in shape, arranged with the long axis perpendicular to the plane of the retina, and lying several in a row behind one another. When fresh they appear transversely striated (*Henle*) and lead us to suspect the stratified arrangement of disk-shaped masses of substance of a different chemical constitution. A number of these granules lie in the dilatations of the inner segments of the rods and cones, which then perforate the external limiting membrane. These rod-and-cone granules are somewhat larger than the other granules, and sometimes form a distinct layer upon the external limiting membrane (*Henle*). Most of the rods however terminate at the inner end in a delicate, pale fiber, similar to an axis-cylinder and often varicose, which perforates the limitans externa and enters the external granule layer. Here it spreads out repeatedly in order to inclose a granule, and runs as far as the inter-granule layer. At the margin of the latter the end of the rod-fiber swells up and then again passes on as a delicate fiber, which perforates the inter-granule layer (*Hasse*) and is probably connected with the internal granule (*Steinlin*). The same is the case with the cone-fibers, which at the margin of the inter-granule layer swell up into conoid molecular bodies with a broad base, out of which three or more fibers pass into the inter-granule layer, and afterward reach the inner granules. The latter are small, round cells with large nuclei, and resemble bipolar ganglion-cells. Their internal processes pass through the granulated layer, where they form networks (*M. Schultze*) and then probably unite with the multipolar elements of the ganglion-cell layer (*Hulke*, *Manz*). The ganglion cells have a cloudy contents and a beautifully developed nucleus. A large process runs from every ganglion cell inward and is continued into the nerve-fiber. The nerve-fibers of the retina are entirely analogous to the pale fibers of the brain, transparent and homogeneous. They are regarded by many as mere axis-cylinders (*M. Schultze*), which have lost their medullary sheath in their passage through the cribriform fascia. Among other circumstances, the fact that the fibers exceptionally retain their medullary sheath even in the retina, or, having passed through the lamina cribrosa, regain it for a distance (*H. Müller*, *Virchow*, *v. Recklinghausen*), and occasion dense, superficial opacities of the retina with corresponding functional disturbances, tends to corroborate this view. These nerve-fibers, in the neighborhood of the papilla, lie in bundles close upon one another, but soon separate more and more as they radiate into the retina, and near the periphery considerable interspaces may be distinguished.

The connective-tissue portion, the connecting substance of the retina, permeates all the layers as far as the layer of rods and cones, whose elements are held together by a very clear, firm, flexible, delicate and elastic mass (*Henle*).

The internal limitans *i* has generally the character of a hyaline membrane (*Kölliker*). It is formed by the firm cementing of the nucleated fiber-cells peculiar to the retinal connective

tissue (*C. Ritter*). Each of these fiber-cells is said to lie only partly in the limiting membrane, generally only the smaller half, but the other part bends at an angle toward the interior of the retina, and by the union with other fiber-cells concur in the formation of Müller's supporting fibers. The inner ends of these supporting fibers appear conoid, the individual fiber-cells here come together, unite into thinner cords which anastomose abundantly with each other, and so form a frame-work in which the nerve-fibers and ganglion-cells lie embedded. The supporting fibers are continued into the granulated layer, and may here be distinctly recognized as fibers, which are everywhere provided with large and small irregular spines, in which molecular granules may be seen. The interspaces are filled by a homogeneous granular basement substance, which is connected with the radial fibers. In the inner granule layer the radial fibers appear as narrow or broad fibers which inclose granules and nerve-fibers with their jagged processes like capsules, and fill all the intervening spaces. They appear slightly granular, and contain round or fusiform nucleated cells without processes (*Hasse*). In the intergranule layer the intervening spaces of the radial fibers are filled by large, flat, multipolar cells of a connective-tissue character, which, especially in young animals, contain nuclei. They are intimately connected with each other as well as with the radial fibers, and show many spaces between them in which the nervous elements lie. The presence of these spaces in this tissue has gained for it the name of membrana fenestrata (*W. Krause*). In the external granule layer the structure is the same as in the inner granule layer. The radial fibers run through the layer with ramifying branches, but contain no nucleated cells. They surround all the granules and nerve-fibers with a sheath, fill all the spaces, and finally end at the outer margin of the granule layer in a plane, by blending here again into a denser membrane, the limitans externa (*M. Schultze*). This however only forms a closed layer at the periphery of the retina, but is elsewhere perforated like a sieve, and by means of the perforations admits of the connection of the elements of the layer of rods and cones with the granules.

About the macula lutea, where the retina is more intimately connected with the choroid, or, more properly, with the tapetum, its formation appears different.

The nerve-fiber layer is here very much reduced in thickness. Its bundles surround the yellow spot in curves, and appear to send merely a single layer of fibers over its surface (*Henle*). In compensation for this reduction in thickness, the layer of ganglion-cells is here thicker than elsewhere: its elements are smaller, and are arranged in several layers, sometimes as many as eight (*H. Müller*). The granulated layer is wanting, and the internal granule layer is very much thinned. The intergranule layer is, on the contrary, highly developed, and consists in great part of connecting nerve-fibers, which all appear to radiate from a point in the center of the yellow spot, and form its external layers, and by a slight curve to pass in the horizontal direction (*Henle*). The external granule layer is thick. The rods are replaced by lengthened cones, closely crowded together, and they only appear again outside the fovea, increasing in number toward the periphery.

The blood-vessels of the retina are twigs of the central artery and vein, whose trunks lie in the optic nerve. There are two superior and two inferior, arterial and venous, that is, eight main branches altogether, besides several smaller twigs, which radiate toward the periphery of the retina, branch out in various directions, and finally curve into loops, forming a close network, with round openings. These vessels never pass the ora serrata. They are connected with the nutrient vessels of the optic nerve by many fine twigs, and by these indirectly with the posterior scleral and choroidal vessels. The latter connection, however, is mostly in the arterial circulation (*Leber*).

The main branches pass together over the nerve filament layer proper, and at most enter it without going behind it. Their finer subdivisions traverse the connective-tissue framework to the inner filament layer, at most to the internal granular layer, *e*. The mosaic layers are absolutely without vessels. In the yellow spot, also, some capillaries occur. It is only the fovea centralis which contains no vessels. The large venous trunks of the retina are said to be

everywhere surrounded like a net with lymphatic vessels, but the arteries only partially so. These lymphatics pass through the cribriform fascia, and are connected with the lymphatics of the optic nerve (*His*).

Ophthalmoscopic Appearances.—The retina is not perfectly pellucid, it is true, but still it is sufficiently transparent to escape the observation of inexperienced observers. They recognize only the branched vessels traversing the retina and rising sharply above the yellowish-red fundus of the eye, and some showing themselves to be arteries by their brighter color, small size, and direct course, some veins by their darker color, greater size, and tortuous course; with strong illumination of the fundus, however, and particularly with oblique light, it is not difficult to recognize the retina itself as a very delicate bluish-white mist, covering the fundus.

Eyes rich in pigment are especially suited for this; those of blondes are less so. This cloudiness is most marked in the immediate vicinity of the optic nerve, and there it is often so decided that the papilla appears blurred and enlarged in its diameter on account of its indistinct boundaries, and the vessels appear veiled. Then it is often possible to perceive even the individual bundles of the optic nerve as fine, radiating striæ (*Liebreich*).

Exceptionally, around the papilla the retina appears cloudy and entirely opaque, even large elevated spots with cloudy or flamelike borders appearing and hiding the choroid as far as they extend, but leaving the papilla free or only partially covering it. As a very uncommon occurrence, such a spot entirely surrounds the entrance of the optic nerve; it is generally limited to a portion of the circumference, but is then sometimes double or multiple (Fig. 31). It never takes the direction toward the macula lutea. The vessels sometimes run freely over its surface, and sometimes they dip down more or less into it, and hence appear partially veiled or entirely interrupted. The cause of this anomaly is that the nerve filaments, which usually lose their medullary sheath on entering the membrana cribrosa, sometimes reacquire it after passing from the papilla to the retina, or at least do not become transparent till they enter the latter. Unless very extensive, these conditions do not cause amaurotic weakness of vision; they usually produce an enlargement of the blind spot (*O. Becker*, *Dönitz*), and they do this because the cloudy nerve filaments cover the sensitive elements of the bacillar layer, and hence, as far as they reach, render impossible the reception of images of objects on this stratum. Beyond the cloudy spots the retina functions normally. The condition is always congenital. It has been repeatedly observed in children, in one case in two sisters, but never as yet in new-born children (*Mauthner*).

In rare cases a peculiar reflex is seen in the retina, which can not as yet be satisfactorily explained. It is sometimes serpentine streaks of light which run along the side of the vessels, and by a movement of the mirror spring from one side to the other, and even entirely conceal a vessel for some distance (*Schirmer*); sometimes it is silvery glistening spots with dark shadows, which change in extent and form according to the position of the mirror (they have been compared to ice-flowers?) (*Schirmer*), and have exactly the appearance of having come from an irregularly folded reflecting surface. They are found solely in the region of the macula lutea, and especially in deeply-pigmented eyes.

As a rule, the macula lutea is seen only with great difficulty or even not at all. Still the slight vascularity of its immediate surroundings, as well as its known position, somewhat under the horizontal diameter of the fundus oculi, and about two diameters of the papilla outwards from the latter, are sufficient data to enable us to bring it within the visual field. Frequently, however, especially in myopes, it appears very distinctly as a small, bright-colored depression, which reflects the light in a peculiar manner (*Coccius*), and is usually surrounded by a brownish spot (Fig. A. P), which appears dark-red in a very light-colored fundus. This spot is sometimes round, sometimes irregularly formed, large or small in diameter, and, when its color is blood-red, may easily be mistaken for an extravasation. Its outline is usually indistinct. In some cases, however, as a transversely or obliquely directed

ellipse, whose border is surrounded by a bright glistening line, either partially upon one side or the other, according to the position of the mirror (Figs. 31, 32), or entirely (*Schelske, Schweigger, Coccius, Ed. Jaeger*).

The explanations of the glittering ring seen round the region of the yellow spot with the ophthalmoscope, as given by Liebreich, Schweigger, Schirmer, and others, have never been accepted by physiologists as conclusive; and Mauthner, in his recent work on the ophthalmoscope, brings an exhaustive review of the many attempts to solve the problem to a close, with the assertion that the phenomenon can not be accounted for on anatomical grounds with the knowledge of the part now in our possession.

Fig. 31.

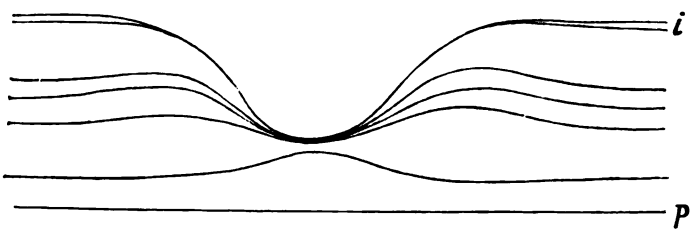

On looking at some drawings of the region of the macula, by Max Schultze, one of which I now reproduce in a diagrammatic form* (Taf. vi., Fig. 1), it occurred to me that the effect in question might be produced by the same causes within the eye that often produce it in other places in nature, or, in other words, that it might be the products of reflexion and refraction, from the combination of curved surfaces which enter into the construction of this portion of the retina.

As you will see, this region, as figured in the diagram (Fig. 1), bears in its formation a strong resemblance to a shallow cup, of which the rim is represented by a convex and the bowl by a concave surface. If we look upon these curved surfaces as mirrors, they would each have their foci, one lying behind the other in front, according to their respective degrees of curvature. And if light should be thrown perpendicularly against such a combination of curves, the apex of the outside rim or convex surface would, from well-known optical laws, appear illuminated, while the inside or concave surface would appear more or less in shadow. Thus we should have the effect of a darker center, surrounded by an illuminated edge.

In order to demonstrate this in its application to the retina, two eye-phantoms or cameras were made, precisely alike in every respect. At the bottom of one a concave metal mirror, belonging to an ophthalmoscope, was placed, to represent the retinal surface. Another mirror, precisely like the first, was then taken, and a

* The outlines and curvature of the different layers are fac-similes of Schultze's original drawing. The scale is here, however, reduced one-half; *p* represents the pigment epithelium and *i* the nerve-fiber layer.

very slight depression made in it by carefully pounding down the region immediately about the hole in the center with a rounded chisel-handle. As the implement was made of wood, a shallow indentation was made without cutting into the substance of the mirror. This was placed at the bottom of the second camera, and represented, in a rough but sufficiently exact way, the cup-like cavity shown in the drawing, as belonging to the yellow spot. The two cameras were then examined with the ophthalmoscope.

The first gave a perfectly distinct image of the mirror at its bottom, exactly as we should expect to see it, with the hole in the center, with clearly-defined edges; but in the second camera the hole was surrounded by a brilliant circle, corresponding exactly to the limits of the depression, while the central portion seemed to be somewhat in shadow. An idea, although a very rough one, of the effect can be formed from the following diagram, in which *A* represents the camera in which the mirror had been left in its natural condition, and *B* the one in which the slight central depression had been made.

[Fig. 32.

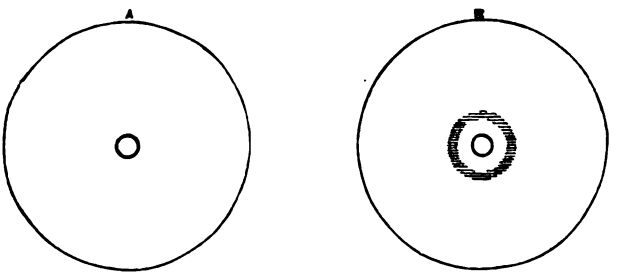

In showing this experiment to a *confrère*, I was told that, striking as it was, it could not embody the right explanation of the affair, inasmuch as there was, in fact, no such depression of the entire region of the macula as I had been led to suppose from Schultze's diagram; that the only depression in the whole surface of the retina was confined to the fovea itself; and that this, as was self-evident, was entirely too small to give so extensive a reflex; and finally, that Schultze's figure was merely a diagrammatic representation of the fovea, very much enlarged.

If this is true, then of course the experiment, and with it the explanation, falls to the ground; and it cannot be denied but that Henle distinctly states that the only depression in the whole surface of the retina is just at the fovea centralis itself. But it is by no means so certain that the excavation pictured by Schultze is meant to represent only that of the fovea, or that it is an exaggerated and diagrammatic representation for the mere purposes of explanation. On the contrary, he states distinctly that "all the layers, excepting the rods and cones, are copied exactly from a section through a normal human retina; the drawing, as here represented, shows the macula lutea without plica, *consequently as it actually is in life*" (*loc. cit.*, p. 109).

Schultze has given, too, the scale on which the drawing was made, namely, an enlargement of one hundred and ten times. If we now measure in his diagram the extent of surface on the retina which is stained yellow, and which it is to be supposed

was meant to represent the extent of the region of the macula lutea, we find it is 158 millimetres. This, reduced to the normal size, would give for the measurement of this region 1.4 millimetre, which corresponds to the average dimension, as determined by the majority of observers. Again, if we suppose that Schultze meant the depression to be confined solely to the fovea, and under this supposition we measure the distance across the actual mouth of the cavity as figured in the diagram, we find it is equal to 110 millimetres, which, reduced, gives an actual size of 1.0 millimetre, which is five or six times as large as it is in the normal eye, so that it is not possible that the cup-shaped depression is meant to represent nothing but the fovea. There can, indeed, be no doubt but that Schultze meant to give in his picture an exact counterpart of this region of the retina as it really is in nature, and if so, there is no reason why the conditions represented in the experiment should not be a sufficiently exact imitation of those in the actual eye.

It must be conceded, however, that Schultze's views and Henle's are diametrically opposed. Can it be that this cup-like depression varies in different eyes, both as to extent and depth, so that in some it shall be limited to the fovea alone, and in others extend, getting shallower as it goes, even up to or near the boundary-line of the entire macula? This would account for the presence of the ring in some eyes, and its absence in others, and its frequent and not inconsiderable variation when present in size and shape.

Bearing in mind that at the macula lutea the nerve-fiber layer ceases to exist as such, and that the nerve-fibers make a peculiar bend here, it occurred to me that a difference in level might be occasioned, which, varying in different cases, might still be sufficiently marked in many eyes to give the effect in question.

In order to show how slight an inequality in surface would produce the phenomenon, and to determine whether it could be possibly produced by the above condition, the following experiment was made:—

A piece of thin and perfectly pure tin-foil, such as dentists use, was selected, and its thickness carefully measured under the microscope; this was found to be only $\frac{1}{700}$ of an English line. A flat circular disk of plain glass was then prepared. A small circular hole was next cut in the center of a piece of the foil, which was left somewhat larger than the disk of glass. This latter was then covered with the foil by carefully folding the surplus quantity over the edges of the glass till the surface of the foil was gradually worked perfectly tight and smooth, so as to give finally much the appearance of a flat, thin button, covered with silver, and having in its center a circular hole, through which the glass was visible. As the thickness of the foil was $\frac{1}{700}$ of a line, the depth of the hole in the center must be the same.

A second piece of foil, having, however, no hole in its center, was now stretched as above over the first covering, and the surface was then gently rubbed till the upper covering had molded itself under the pressure into the hole in the covering beneath.

The effect of this was to give a perfectly smooth surface, with a very slight depression in the center. The depth of this depression, even if it was equal to that of the hole itself before the second covering was put on, could not be more than $\frac{1}{700}$ of a line, but it must be in fact much less, as it is evident that the depth must decrease with each covering. The disk was then fitted to a camera and observed with the ophthalmoscope, just as in the former experiment, and with precisely the same result. The glittering ring, marking the boundary of the depressed region,

was present in a marked degree, and showed a very striking resemblance, both in size and appearance, to that seen in the actual eye.

We have taken, it must be borne in mind, the depth of the depression as $\frac{1}{100}$ of a line, a difference in level which seems almost inappreciable, and which is, in fact, three times less than the thickness of the single layer of epithelial cells between the retina and choroid. Now, as the nerve-fiber layer is, at the distance from the optic disk corresponding to that of the macula, $\frac{1}{30}$ of a line thick,* we should, even if we took the lowest estimate, have tissue enough in the thickness of the nerve-layer alone to make a depression fourteen times as deep as that which produced the effect in the phantom.

And if for any reason whatever, such as the bending or overlapping of some of the fibers as they inclosed the macula, and the ending of others concentrically around it, a difference of level of even the slightest degree was formed, then the effect might be produced through the nerve-fiber layer alone, without taking into consideration the thinning of the other layers of the retina at this place.

But it may be said that if this difference of level did exist, it ought, however slight it might be, to be seen with the microscope. This we readily admit ought to be the case if we could get sections of the part as it really exists in nature, but it must be borne in mind that it is almost hopeless to do this, on account of the distortion of the part by the formation of the so-called plica at almost the very moment the eye is opened, and this too, letting alone the disturbance of the tissue which would necessarily follow by even the most delicate manipulation, and letting alone, too, the minor difficulty of even getting a section directly through this region.

It must, too, be admitted that, with all the labor and talent which have been expended on the anatomy of the retina, we still know little about that of the nerve-fiber layer in the region of the macula. Under these circumstances may not the ophthalmoscope have a voice in explaining a phenomenon which is in strict accordance with physical laws, and which, outside of the eye, can only be so explained?

How far the peculiar arrangement of the anatomical elements of the different layers which enter into the construction of the part, and which go to make this inequality of level, contributes to the effect, we will not attempt to determine; it is the difference of level itself which we would insist upon as the essential factor in the production of the phenomenon.

There are one or two additional points which go to prove that the effect is due to difference of level, one of which is the fact that we often get a reflex of precisely the same character along the vessels; and we know from the microscope that these often project, though still covered with the nerve-fibers, above the level of the retina.

A second argument in its favor is the peculiar reflex seen at the fovea centralis, with the *upright image*, first pointed out by Coccius, and the usual shape of which, as you are aware, is that of a horse-shoe, which changes from side to side according to the movements of the eye.

Now, we know that the fovea is described by most anatomists as a narrow fossa with pretty sharply-descending walls, and the shape of the reflex is just such as would come from a narrow-mouthed pit; for, while one side was turned so as to catch the light and reflect it, the other edge would be turned so that no reflex

* Ritter. Wecker's Études, t. ii., premier fascicule, p. 51.

would come back from it, consequently we should have a crescent or half-moon-shaped reflex, changing its position as it really does with every movement of the eye.

The reflex of the fovea, even when present, is not, however, always of a crescentic shape, for it sometimes has the appearance as if it were only the segment of a small circle which was illuminated, or as if the fossa were a triangular one and light were reflected from only one side of it, in which case the reflection stream out something like the tail of a very minute comet; again, it has the appearance of a delicate phantom-like veil stretched, in part or entirely, across the fovea; and then again there is no reflex at all, and the fovea looks like a small yellow disc varying in size and shape, and has the appearance as if it had been flecked directly on to the surface of the retina with a brush.

May not these differences in effect of the reflection, when present, be due to variations in anatomical construction of the part, and principally to differences in shape and depth of the excavation; and, when the reflex is absent, may not its absence be due to the want of any difference in level?

These are questions which the anatomists must answer, but one thing is certain: where there are such marked variations in effect, there must be also marked variations in cause.

In regard to the fact which Mauthner emphasizes as so curious and unaccountable, that we only get the halo round the macula with the inverted image, and never, under any circumstances, with the upright, I have only to offer in explanation that we should bear in mind that the apparent diameter of the region of the yellow spot, under the enlargement of the upright image, would be, on the average, about one inch, which is much too large for the entire circuit to be in view at once, and furthermore that, do what we will, the illumination with the upright image is never so strong, or so concentrated on a small surface, as with the inverted.

But I would add, while admitting Mauthner's statement as almost a law, that occasionally I have got a distinct but very faint segment of reflection which I could make play about in that portion of the retina where I imagined the boundary circle of the yellow spot should be (*Loring*).]

Senile Changes.—These affect, principally, the connective-tissue envelope and framework. The radial fibers become cloudy from molecular detritus, and then give to the retina, when viewed from without, a marbled appearance, which is especially evident in the eyes of the cadaver.

In old persons we almost always find transparent, highly refractive coloid and amyloid spherical masses, and sometimes these are laid on in such numbers and size that, to the naked eye, as well as with the ophthalmoscope, the retina appears stippled white. They are situated principally in the nervous-filament layer, but appear also in the connective-tissue framework of the optic nerve, and are sclerosed connective tissue, and partly, perhaps, sclerosed nerve elements. The limitans retinæ also usually becomes cloudy by a deposition of organic matter, which frequently aggregates into the most various figures. We also meet atheromatous vessels (*Wedl*).

Small vessels and capillaries which have undergone fatty degeneration, and thickly strewn in part with chalk-granules, are by no means an uncommon occurrence, particularly in the neighborhood and at the periphery of the retina, and appear to be connected pathogenetically with œdema retinæ, very commonly occurring in old people and with senile cataract (*Iwanoff*).

It is probable that these changes are connected with the decrease of sharpness o

vision which is occasionally noticed in old persons. But here undoubtedly the atrophy of the pigment layer, the coloid degeneration of the uveal-bounding membrane, and the thus-caused stronger reflection of light of the fundus, also assist.

Histology—The inflammatory process always starts from the connective-tissue framework of the retina. It furnishes variable amounts of a product which usually appears as an infiltration between and in the layers of the membrane, but often also collects as an exudation on one or both surfaces of the retina. This is composed of a gelatinous, coagulable basis, and of cell developments, which vary greatly in quality and quantity with the character of the inflammation. The elements of the retina itself are thus changed in various ways. The connective-tissue framework and walls of the vessels are often partly hypertrophied, but more frequently, especially with great intensity of the process, the connective tissue is affected with fatty degeneration, and may even be entirely dissolved. Those of the connective-tissue nuclei that are not destroyed in the inflammatory proliferation are changed partly to fat granules and partly sclerose, and are transformed into coloid and amyloid bodies. The nervous elements long retain their integrity, and usually show their participation in the inflammation less by marked proliferation than by sclerosis, and especially by fatty degeneration (*H. Müller*, *Schweigger*, *Wedl*).

The brawny basement substance of the inflammatory product is at first almost homogeneous, or at most merely finely molecular, but becomes gradually opaque by the secretion of small fat globules. Sometimes it may coagulate during life; at any rate it can be made to coagulate by using hardening fluids, and then appears in the form of an opaque whitish-gray fibrous mass, which insinuates itself between the elements of the retina, separating them from one another. It is usually found in all the layers of the retina, though most of it is collected together in the granular layers. The serpentine course of the vessels in an ascending and descending meridional direction, so frequently observed in inflammation of the retina, certainly indicates that these infiltrations of the tissue are not always uniform, but lift up the surface of the retina like a hump.

The fatty disintegration of the filamentary framework is particularly observed in the connective tissue of the granular layer, while the framework of the inner retinal layer often, and especially in long-existing chronic inflammation, is found hypertrophied. The hypertrophic supporting fibers evidently increase in size, each individual filament becomes thicker and more refractive, and hence the whole framework becomes cloudy, so that the vascular trunks, coursing in the inner retinal layers, are enveloped as by a veil. The cloudiness is, moreover, decidedly increased by the simultaneous changes of connective-tissue nuclei. These swell, their contents become cloudy by precipitation of molecular fatty masses, and they commence to proliferate. Subsequently a large part of these elements change to fatty granules, while another part harden and metamorphose into resisting, strongly opalescent, nucleated, and often slightly granular coloid and amyloid bodies. The fat granules, as well as the coloid bodies, are sometimes isolated, sometimes grouped in masses between the framework; when they are pressed together in nests they often cause the above-mentioned stippled appearance on the retina. The fatty granules and the coloid bodies usually appear most plentifully in the granular layer, and then in the nerve-filament layer. Here they often occur to such an extent that they cannot have resulted from preëxisting elements, but render necessary the supposition of a precedent cell increase, and a subsequent metamorphosis of the newly-formed cells. Finally, the anatomical evidences often point to luxurious cell development in an unmistakable manner—often large neoplastic cells, sometimes undergoing proliferation, appear in the framework, while the fatty granules and coloid bodies decidedly diminish in number. In some cases, heaps of already developed spindle-shaped or nodulated nucleated cells, and the commencement of neoplastic connective-tissue intercellular substance, have been found in the framework of the retina. Sometimes the new formation has gone further; whole bundles of completely developed nucleated tissue grow, especially from the intergranular layer, into the choroidal tapetum (*Pope*), or, as more frequently happens, into the vitreous. Such collections

of neoplastic nuclei or cells appear mostly to be the cause of the above-mentioned *martial* appearance of inflamed retina.

The nervous elements, as was said before, often resist for a long time, or become cloudy simply by fatty deposition, without losing the possibility of again returning to normal functional activity. Finally, however, by fatty degeneration or sclerosis, they lose their nervous character. Nervous tubes undergoing fatty degeneration often swell decidedly, and when numerous, not unfrequently cause a very distinct striated appearance in the parts of the retina affected. In ganglion cells undergoing fatty atrophy, instead of nuclei we find one or two distinct shining fat globules, or even the *entire* cell contents are changed to a fine granular mass, and the *processes* from it also appear expanded by a similar friable mass. The granules and the elements of the bacillar layer usually hold out the longest, but they also may finally become fatty. Sclerosis is more especially seen in the nervous tubes; of the other nervous parts nothing is yet certainly known, only it is very probable that they sclerose and may change into coloid bodies (*Iwanoff*, *Klebs*). Sclerosing nervous tubes appear elongated, varicose, finely molecular, and more strongly refractive. Some of the varicose swellings develop quickly to considerable size, and gradually acquire the appearance of coloid bodies, especially when the nervous-tube framework uniting them degenerates, or is even entirely destroyed, and the sclerosed nodules appear isolated.

In one case the development of these coloid masses had progressed very far though only seventeen hours had elapsed since the occurrence of the wound which was the exciting cause of the inflammation (*Berlin*). There is, therefore, good reason for distinguishing the coloid degeneration under such conditions from that which is observed in progressive atrophy, and for regarding the former rather as a kind of hypertrophy.

The vessels undergo changes in their *walls* similar to those in the fibrous framework of the retina. Especially do the finer twigs become fatty here and there. They also partake of sclerose, their walls appear thickened by a hard, strongly-refracting substance, which also spreads into the caliber and narrows it, and also here and there collects into nodules or plates which correspond in all their peculiarities to the coloid bodies of the connective tissue (*Virchow*). The adventitious layer of the vessels usually hypertrophies, and in the larger trunks often does so very extensively, so that they not only appear remarkably thickened, but also provided with neoplastic connective-tissue appendices, which sometimes resemble papillary outgrowths, at others the wing-shaped border of some plant pedicles (*Wedl*). Their nuclei often appear greatly developed, and not unfrequently contain whole chains of neoplastic cells. The epithelium on the lining of the vessels participates in the proliferation (*Iwanoff*).

In some cases the proliferation of the walls of the vessels exceeds that of the connective-tissue framework to a remarkable extent, so that the larger branches of the trunks of the central veins are distinctly seen to project as white cords from the inflammatory cloudiness of the retinal tissue (*Perivasculitis retinæ*, *Iwanoff*, *Nagel*).

The participation of the walls of the vessels in the process is a chief cause of the very frequent occurrence of hemorrhagic extravasations in inflamed retinæ. These extravasations are usually of slight extent, as the conditions of the intra-ocular circulation are unfavorable to the escape of blood from individual ruptures of vessels. But, on the other hand, they are often very numerous. They are usually situated in the inner layers of the retina, but under the pressure of the blood not unfrequently press into the meshes of the connective-tissue framework, and their shape is modeled by it. Among the supporting filaments they appear columnar, about the papilla striated, etc. (*Heymann*, *Schneller*). Rarely they break up the tissue and extend to the outer filamentary layer, or between the retina and choroid or on the other side enter the vitreous. When not very extensive they are usually absorbed. But occasionally they become permanent, change to a purple

or rusty-brown color, and are transformed to a granular mass, in which necrosed blood corpuscles, and sometimes hematin crystals, may be recognized for a long time.

But the frequent occurrence of extravasations in retinal inflammations has another cause, namely, the swelling of the optic papilla, and the venous congestion dependent on it. A process of proliferation going on in the retina is rarely confined to it; it usually extends to the trunk, or at least to the head of the optic nerve. On the other hand, a neuritis is rarely confined to the papilla, but extends to the retina. Hence there is usually not a retinitis in the strict sense, but a neuro-retinitis.

The anatomical picture of the process is not by any means always the same, but changes its characteristics very decidedly. From these differences many varieties of neuro-retinitis are described, which, however, are connected by many intermediate forms.

In the great majority of cases the retina and papilla in the dead subject appear quite regularly swelled throughout, with a gelatinous translucency or veil-like cloudiness, in parts perhaps stippled, striated, or marbled. Careful examination shows the inflammatory process in all layers of the retina. But the infiltration, the increase in the connective-tissue framework, fatty degeneration and sclerosis of the nerve elements, are not spread equally through the entire thickness of the retina. But we are apt to find the characteristic changes more prominent sometimes in the nervous, sometimes in the pavement strata.

If the inner layers are chiefly affected, a decided hyalitis usually occurs; on the contrary the choroid and tapetum usually retain their integrity in pure cases, or only participate late in the disease. These cases are described as neuro-retinitis diffusa.

But where the inflammatory process most affects the outer strata of the retina, the tapetum always sympathizes very decidedly. It is often found undeveloped, yellow, irregularly distributed, and is even absent in some places. Some groups of cells, however, are usually in a state of proliferation, increase by new formation, collect in clumps, in some places grow into the retina relaxed by inflammation, and here excite other neoplastic cells to the formation of pigment. The causes of this intimate connection between retina and tapetum are partly connective-tissue outgrowths from the pavement strata, which grow in between the pigment cells (*Junge*, *Pape*, *Iwanoff*, *Rudnew*), but chiefly an exudation layer of gelatinous coagulable product on the outer surface of the retina, which unites the retina and choroid, and represents an exuded portion of inflammatory infiltration.

This layer appears sometimes homogeneous, or at most finely granular, sometimes striated or indistinctly filamentary. It usually contains but a slight amount of cellular elements. Occasionally some newly-formed vessels occur in it (*Sämisch*), which appear to be connected with those of the retina, and probably are pressed inward with the connective-tissue outgrowths.

The exudation layer is often spread quite regularly over the whole surface of the retina, and its attachment to the choroid and the changes in the tapetum extend to all parts of these bodies. Although these cases represent an exudative form of neuro-retinitis, they are almost always classed among the diffuse retinal inflammations, as their characteristic changes are almost always obscured during life by the cloudiness of the retina and vitreous, caused by the inflammation. The appearance of the two diseases is, therefore, very similar during life, and the difference does not become apparent till later in the course, when the cloudy portions begin to clear up, and progressive atrophy takes the place of proliferation.

In other cases the exudation collects particularly at certain parts of the posterior surface of the retina, or it only takes place in streaks, while elsewhere the diffusely inflamed retina does not unite with the choroid. Indeed not unfrequently the whole process occurs only in spots, and the remainder of the retina and tapetum continue nearly normal, or only sympathize to a slight extent. These exuded products usually form rather thick, and often even extensive, patches with more or less sharp borders. Their opacity and brighter color cause them to show distinctly in the surrounding cloudiness, and when they are more extensive they give the retina about them the appearance of being pressed forward. Later, when part of the exudation has been absorbed and the rest is shrinking away, they present very characteristic, frequently figured spots, whose intensely bright basis, and often moderate deposit of very dark pigment masses, render most perceptible the above-mentioned tapetal changes. They are most generally in the vicinity of the macula lutea, where normally the union between retina and choroid is very intimate. The term neuro-retinitis exudativa is especially suited to this form.

When the inner layers of the retina very decidedly participate in the affection the vitreous is usually clouded by the inflammation. The choroid may participate in the proliferation, but does not necessarily do so (*Sämisch*), and when it does it generally in a manner less marked. But later atrophy of the choriocapillaris and vasculosa occur in the vicinity of the point of exudation. Still, here and there we meet cases where, according to recent observations, the product is originally deposited in the choroidal parenchyma proper, in nodular masses, or in flat, extensive round patches with sharp elevated edges. It is said that these points subsequently break through the limitans of the choroid, come in contact with the outer surface of the retina, and, while they cause the latter to participate in the process, press into its tissue (*Förster*, *Iwanoff*). These conditions of the choroid justify to some extent the names formerly given to the whole disease, retino-choroiditis, or choroiditis exudativa.

The nodular deposits in the choroidal tissue manifested themselves as groups of proliferating spindle-shaped cells, or as branching, anastomosing and strongly pigmented cords, which were partly degenerated blood-vessels of the vasculosa, partly newly-formed nucleated masses. These formations were deposited in a slightly striated tissue, which was strewn with numerous coloid bodies and non-pigmented nuclei. Here and there, however, the pigmented masses collected so that the basis altogether disappeared, and extensive, almost solid masses of pigment appeared, projecting somewhat above the surface of the choroid. In one case this deposit was found to consist of a transparent, finely-filamented, wide-meshed, colorless tissue, which was sharply bounded from the surrounding slightly-changed choroidal tissue. This tissue had cavities in it which were filled with a formless mass of scanty nucleolar tissue and true nucleated cells. The elements of the choroid about these points were entirely destroyed. On the surface of the non-pigmented nodules could be clearly seen a stratum of proliferating, darkly pigmented, nucleated cells. The retina appeared connected with the new formation by filamentary processes, and as the cases examined were old, it appeared greatly atrophied (*Förster*).

The number of recorded observations is too small for us to be able to say with certainty whether the above-mentioned differences are only varieties of the same disease, or characterize essentially different processes. Latterly the inclination has been to favor the latter view; some even distinguish cases of the first kind as "retinitis circumscripta," those of the second as "choroiditis areolaris," saying that in the former the retinal, in the latter the choroidal affection predominates (*Sämisch*). But it is only a question of proportion, and the occurrence of numerous transition forms permits the consideration of the two varieties together.

3. In another form of retinal inflammation, which is associated with Bright's (or

similar) disease of the kidney, and is hence described as nephritic retinitis, large quantities of an inflammatory product, which quickly becomes fatty, collect in the posterior half of the retina and in the papilla, and often cause them to swell decidedly. At the same time there is great congestion, at least in the veins. Striated or spotted extravasations in the region of exudation constantly occur.

The microscopical appearance is not very different from that of the preceding form of retinitis. It is only characterized by the enormous ganglion-cell-like hypertrophy of the nerve-fibres (sclerosis) in the coloid degeneration of the walls of the retinal vessels, by the moderate collections of exudation which usually appear as infiltrations, but not unfrequently as exudations between retina and choroid, gluing together these two membranes at intervals, and causing changes of tapetum characteristic of the exudative form of retinitis. At the same time fibrinous coagula and proliferating cells are often seen in the vitreous. The choroid appears infiltrated with serum, and its tissue spongy; the connective-tissue cells of its stroma appear swelled, clouded, and some of them changed to coloid bodies. The delicate vessels, especially the network of the choriocapillaris, had their walls thickened by a highly refracting substance, but their caliber contracted or quite obliterated (*sclerosed*), that is, they participated in a degeneration which, according to recent investigations, is said to extend to all the smaller vessels of the body, and is regarded by many as the actual starting-point of Bright's disease (*Kussmaul, R. Meyer*). The limitans of the choroid appeared normal or strewn with coloid masses (*Virchow, H. Müller, Zenker, Schweigger*).

4. In a fourth form of retinitis, which may be called purulent, suppurative, occasionally also tuberculous, the greater part or the whole of the retina and papilla appears remarkably clouded and hyperæmic at first, but later becomes opaque, pus-colored, containing similar extravasations to those in the former class, swells, increases in thickness, becomes looser, and in places breaks up into a purulent mass, while simultaneously purulent products collect on one or both surfaces; or the product collects to a tubercular swelling, which subsequently liquefies. The vessels are mostly covered by the inflammatory product, and partially also even compressed. In many cases some trunks or branches appear filled, sausage-like, with purulent product, and much bulged out (*Wedl, C. Ritter, Nagel*).

In the purulent form of retinal inflammation also, this coagulable substance is found as the basis of the product. It is always very cloudy from fatty detritus. The characteristic essential parts of the product are pus corpuscles. In some cases they have been found only in the nervous-filament layer, where they pressed close on each other, while the remaining strata presented the signs of a diffuse non-purulent inflammation, and then also appeared saturated with coagulated fatty product. As a rule, however, the pus corpuscles show themselves *everywhere* within the swelled gelatinous tissue and in the exudation on the free surface, and *preponderate* usually even to such an extent that they cover up everything else. With them often appear fat granules, rarely large masses of coloid bodies. The nervous elements and fibrous framework suffer always very early from fatty degeneration, and are usually quickly destroyed. Of the nervous elements, the nervous tubes and ganglion cells are especially easily destroyed, while the granules and elements of the rod and cone layer continue for some time, or at most become cloudy and swell.

In very intense suppurative retinitis, particularly in the tubercular form, true pus corpuscles are not developed; but the retina rather appears entirely changed at intervals to a more or less purulent or cheesy-looking mass, whose chief constituents are fatty detritus and a number of irregularly-formed nuclei, which divide up and quickly undergo fatty degeneration.

Suppurative retinitis occurs almost always with extensive depositions of pus in the choroid and vitreous, and as a rule it is only a partial symptom of choroiditis, or still more of panophthalmitis suppurativa. Suppurative retinitis only very exceptionally appears primarily and pure, and then is usually a result of purulent embolia

of ind re nal vessels (*Virchow*, *Nagel*). It is always characterized by very acute c ich products. Even in a few days the already mostly or entirely blinded ret ears to a great degree or throughout its extent much pressed forward and cove by purulent products. Then the other organs of the globe soon participate, and the eyeball is destroyed by atrophy or phthisis, with the symptoms of panophthalmitis (see *Choroiditis Suppurativa*).

5. The retina suffers very peculiar changes in many cases of leucæmia from the enormous amount of white and red blood-corpuscles exuded from the congested vessels (*Liebreich*, *O. Becker*, *Simon*, *Sämisch*, *Leber*). These blood-corpuscles are usually collected in some few spots, particularly in the periphery of the retina and in the region of the macula lutea, in the form of small or large, round, elevated masses of a whitish-yellow color, which are as a rule, though not always, surrounded by a ring of pale violet hemorrhagic dots. The smaller masses are found especially in the inner layers of a, particularly in the nerve-fiber layer; the larger ones, on the contrary, are strew ough the thickness of the retina. The blood-corpuscles thus crowded together pu the normal elements more or less completely. The retina moreover appears œdem ightly cloudy, its connective tissue somewhat hypertrophied, and in the inner gran s and in the papilla slightly bulged out sometimes by masses of nuclei, and st th pale violet hemorrhagic extravasations. The vessels are very much dilated, pa in region of the papilla, and are filled with bright, brick-red blood, and their ad v much thickened by the large number of exuded white blood-corpuscles. An hypertrophy of the nerve elements has hitherto been observed but once (*Recklinghausen*); in the other cases it was wanting, as well as every trace of fatty degeneration, while the latter usually appear rery early in inflammatory conditions of the retina; hence then the doubt, whether the c ition is to be defined as inflammation in the narrow sense of the word, and whether, when latter occurs, it is not to be regarded as secondary and additional, is justified (*Leber*). In dition, flaky opacities of the vitreous are met with, and in one case, partial fatty degeneration of the trunk of the optic nerve has been observed. The development of leucæmic tumors has, moreover, been observed in the choroid. The symptoms were those of an apoplectic iridochoroiditis with colossal dilatation of the vessels and enormous exudation of red and white blood-corpuscles into the tissue of choroid, retina, and vitreous humor. This finally led to luxuriant growth and partial atrophy of the tapetum and retina, as well as to closure of the pupil (*Sämisch*). The course of the affection, according to observations that have been made, has been chronic and variable, inasmuch as the leucæmic masses repeatedly disappeared and reappeared. Retinitis leucæmica may be distinguished ophthalmoscopically by a very marked orange-yellow color, and a slight veil-like opacity of the fundus oculi, by indistinctness of the border of the papilla, and by diminution in the size of the arteries, which appear of a pale-yellow color, without any mixture of red. There is a very marked bluish-red color, running into pink, of the widely dilated and tortuous veins, which are indistinctly defined and surrounded on both sides by a narrow, band-like white line. The leucæmic masses appear as bright whitish-yellow spots, generally round and somewhat elevated, which are usually surrounded by a ring of pale violet, round dots (*O. Becker*). As long as the affection is limited to the retina, its subjective manifestation is a relatively trifling diminution in the acuity of vision, which is easily overlooked. In one case a central mass of exudation had given rise to metamorphopsia without much diminution in the perceptive power of the yellow spot; hence it is believed that the leucæmic mass was situated in the choroid (*O. Becker*). The view, that these masses in the interior of the eye are a constant occurrence in leucæmia, has been refuted by more recent investigations (*Knapp*, *O. Becker*, *Simon*).

6. The nature of certain processes which are met with in the region of the macula lutea and here cause very marked objective changes, generally accompanied by grave disturbance of the central acuity of vision, and even complete defect of the visual field, is as yet very obscure.

To this category belongs the so-called central recurrent retinitis (*Graefe*). It is characterized by dark pigmentation of the excavated macula lutea, and by the development of a lar number of white, punctate round dots which surround the fovea centralis in concentric circl and are on the whole very variable, sometimes increasing in number, sometimes diminishi and occasionally even entirely disappearing (*Ed. Jaeger*, *Mauthner*). The process is manifes

subjectively by a sudden central defect of the visual field, which may disappear in a few days, but may repeatedly recur at intervals of from two to three months. At first during the intermissions the vision is unimpaired, but later a diminution of the central acuity of vision occurs, and in many cases even a very marked metamorphopsia, and particularly a micropsia, is met with. The process is considered to depend upon syphilis. The best results have been obtained by the repeated use of mercurial inunction. Iodide of potassium and Zittman's decoction have proved of less value (*Graefe*).

In some cases there have been seen at the yellow spot "plaques" of a varying size, irregularly defined, of a rather deep green color, and without any elevation above the surrounding tissue, which were surrounded by a bright white border (*Ed. Jaeger*, *Mauthner*).

7. The diffuse opacities in the region of the macula and papilla, which occur in the so-called emboli of the central vessels and in ischæmia retinæ, are of considerable importance. It is as yet an undecided question whether these opacities are the sign of a real inflammation, or of the fatty degeneration preluding atrophy (See Atrophy of the Retina).

8. Particular mention should be made of the circumscribed œdema of the retina, *i. e.*, the collection of a serous product, more or less rich in albumen, in numerous cavities of a varying size. This œdema is observed extremely rarely, if ever, in children, but, on the contrary, very frequently in old persons, and in an extremely high percentage in hypermetropic eyes and in those affected with senile cataract. The most usual situation of the œdema is in the periphery of the retina, where it sometimes appears in isolated spots, sometimes extends like a belt of varying breadth, and even encroaches upon the ciliary portion of the retina. It may also occur in isolated spots in any portion of the retina. It involves only the granule layers and the intervening inter-granule layer or the external fibrous layer. It begins with small cavities without any inflammatory symptoms, generally in the external granule layer, or, more correctly, in the external fibrous layer, which thrust aside the perpendicular fibers of this layer and cause them to hypertrophy. When the œdema is situated in the equatorial region of the retina, these cavities are formed in the inner granule layer, in most of the cases simultaneously or somewhat later. The cavities are then arranged in two rows, one above the other, which are separated from one another by a dividing wall formed from the inter-granule layer and the remains of the internal granule layer. The dividing wall upon which the fibrous bundles on both sides are supported becomes constantly thinner according to the growth of the cavities, and finally disappears entirely, so that the fibrous bundles of the outer and inner layer extend from the hypertrophied granulated layer to the limitans externa. The atrophy of the granules in both layers then begins gradually to take place, and soon advances to complete destruction of the nervous elements and the bacillar layer, while the remaining layers of the retina are usually unimpaired, even when the development of the process is far advanced. The cavities are not however always formed so regularly in both layers. They often occur only in the external fibrous layer or exclusively in the inner granule layer.

The cavities occurring in the external granule layer often attain colossal dimensions, and then appear in the form of cysts, formerly described as coloid cysts, and certainly frequently confounded with detachments of the retina. The slighter opacity of the elevated part, the sharply defined limitation, the often very unusual situation, the long stationary condition, and the slight inclination to sinking, may all serve to distinguish between the two processes, which sometimes also complicate one another. The circumscribed œdema of the retina, in spite of its frequent occurrence, has hitherto excited but little attention, and has been only very exceptionally demonstrated with the ophthalmoscope (*Mauthner*). This is in part explained by the fact of its much more frequent occurrence in the most extreme periphery of the retina, and by the circumstance that, when highly developed, it is usually complicated with cataract.

It is believed that atheromatous degeneration and the consequent disturbances in the circulation of the smaller retinal vessels are the pathogenic causes of the œdema, and thus an explanation is given of the frequent combination with senile cataract. It is certain that such a degeneration of the vessels is a very common occurrence in circumscribed œdema of the retina. There have also been frequent opportunities of demonstrating similar cavities in the nerve-fiber layer along the veins, in cases of atheroma of the retinal vessels (*Iwanoff*).

9. An œdema occurs in the region of the papilla, which however is more diffuse, readily extends to the neighboring zone of the retina, and is, doubtless, of inflammatory origin. It occasions a considerable bulging forward of the optic-nerve entrance, generally unsymmetrical, and is usually combined with hypertrophy of the connective-tissue framework and of

the nerve-fibers, and sometimes with great swelling of the vessels and abundant hemorrhages (*Iwanoff*). In one case a portion of the papilla was bulged forward by inflammatory œdema in the form of a knobbed tumor, which projected into the vitreous humor (*Manz*).

10. Extravasations of blood into the retina and papilla are very common complications of neuro-retinitis, and natural consequences of injuries as well as of lacerations of the vessels, which are occasioned by a stretching of the retina in the region of the macula lutea in cases of rapidly growing posterior scleral staphylomata (Fig. R). They may also occur spontaneously in atheromatous degeneration of the vessels. In fact, they occur not very uncommonly in old people, particularly in those who have a tendency to capillary hemorrhages of the brain. Here they are sometimes premonitory of a pernicious glaucoma. They are also very numerous in the morbus maculosus, and after extensive burns of the integument (*Mooren*). Hypertrophy of the left ventricle (*Schweigger*), powerful contractions of large muscles, *e. g.*, in coughing, lifting of heavy burdens, etc. (*Secondi*), or sudden diminution of the intra-ocular pressure by the emptying of the dioptric media, increase the tendency to these hemorrhages. These extravasations are usually characterized by the sudden appearance of a more or less extensive dark cloud in the field of vision, which follows all the movements of the eye, and at first has sometimes a very distinct red color. The less the neighboring portions of the retina have suffered, so much the more sharply is it defined. On the whole, retinal hemorrhages, particularly those occurring in retinitis, frequently disappear entirely without causing any lasting injury. Sometimes, however, they leave behind them marked disturbances of vision, which must be explained by the destruction of the tissue and in part by the inflammatory reaction set up around them. Extravasations of blood in the macula lutea are particularly destructive; and these often occur in rapidly advancing staphyloma posticum. They almost always lead to a central defect of the visual field. Brownish and black masses of pigment sometimes remain after such extravasations.

Authorities.—Anatomy: ophthalmoscopic appearances: *W. Krause*, Zeitsch. f. rat. Med. XI. S. 175, Anat. Untersuchungen, Hannover, 1861, S. 61. Göttinger Nachrichten, 1867, Nr. 37; Arch. f. Anat. und Phys. 1868. S. 256, 258; die Membrana fenestrata. Leipzig, 1868; Centralbl. 1867, S. 767.—*Barkan*, Sitzungsber. d. Wien. k. Akad. LVI. I.—*Haase*, A. f. O. XIV. 1. S. 58.—*Meynert*, Vierteljahrschrift. f. Psych. 1867, 1. Taf. II.—*Iwanoff*, A. f. O. XV. 2. S. 51—*Hensen*, Arch. f. path. Anat. XXXIX. S. 475; Arch. f. mikrosc. Anat. IV. S. 347.—*Steinlin*, ibid. S. 10.—*Hasse*, Zeitschr. f. rat. Med. XXIX. S. 238, 242, 254, 265.—*Hulke*, ibid. XXXII. S. 130; XXVIII. S. 231.—*His*, kl. Monatbl. 1867, S. 133, 135.—*Ed. Jaeger*, Handatlas, Fig. 26, 29, 30, 34, 36, 43, 44.—*Mauthner*, Lehrb. d. Ophthscop. S. 259, 307, 311, 317.—*Mooren*, Ophth. Beobachtungen, Berlin, 1867, S. 265, 314.—*Coccius*, de Apparatu optico, Lips. 1868, S. 22.

H. Müller, Zeitschrift f. wiss. Zoologie VIII. S. 1; Anat. phys. Untersuchungen über die Retina. Leipzig, 1856; kl. Monatbl. 1863. S. 438; A. f. O. IV. 2. S. 41.—*Kölliker*, Mikr. Anatomie II. Leipzig, 1854. S. 648, 698.—*Henle*, Nachrichten der K. Gesellschaft der Wiss. zu Göttingen, 1864. S. 119, 305; Handbuch der Anat. II. 3 Braunschweig, 1866. S. 636.—*C. Ritter*, die Structur der Retina nach Untersuchungen am Wallfischauge. Leipzig. 1864; A. f. O. V. 2. S. 101; VIII. 1. S. 67; X. 1. S. 67, 74. 79; X. 2. S. 147; XI. 1. S. 89, 179.—*Ammon*, A. f. O. IV. 1. S. 93.—*Babuchin*, Würzburg. naturw. Zeitschrift IV. S. 70, 81; V. S. 127.—*M. Schultze*, observ. de retinæ structura penitiore. Bonnæ, 1859; Arch. f. mikrosk. Anat. S. 215, 237, 371, 404; IV. S. 22; V. S. 379–403; zur Anat. und Phys. d. Retina. Bonn. 1866.—*Manz*, Zeitschrift f. rat. med. X. S. 301; XXVIII. S. 231.—*Schiess-Gemusens*, ibid. XVIII. S. 129.—*Welker*, ibid. XX. S. 173.—*Virchow*, dessen Archiv. X. S. 190.—*Heinemann*, ibid. XXX. Bd. S. 256.—*Schelske*, ibid. 28. Bd. S. 482.—*Beckmann*, ibid. XIII. S. 97.—*Reckling-*

hausen, ibid. 30, Bd. S. 375; A. f. O. X. 2. S. 71.—*Klebs*, A. f. O. XI. 2. S. 251; Virchow's Archiv. 21. Bd. S. 188.—*Leber*, Denkschriften d. Wiener k. Akad. d. Wiss. 24. Bd. S. 323; A. f. O. XI. 1. S. 4.—*Kugel*, A. f. O. IX. 3. S. 129.—*Niemetschek*, Prager Vierteljahrschrift, 1866. 1. S. 132.—*His*, kl. Monatbl. 1865, S. 243.—*Liebreich*, A. f. O. IV. 2. S. 295, 299, 301; V. 2. S. 261; Atlas d. Ophthalmoskopie, Berlin. 1863. Taf. 1. 2.—*Schernier*, A. f. O. X. 1. S. 148.—*O. Becker*, Wiener med. Wochenschrift. 1861, No. 28-29.—*Dönitz*, Arch. f. Anat. u. Phys. 1864. S. 741.—*Schweigger*, A. f. O. VI. 2. S. 313; Vorlesungen über den Gebrauch des Augenspiegels, Berlin. 1864. S. 67, 96.—*Coccius*, über die Anwendung des Augenspiegels, Leipzig, 1853. S. 43, 46.

Senile Veränderungen, *Nosologie*: *Türck*, Zeitschrift der Wiener Aerzte. 1850. Nro. 4.—*Wedl*, Atlas, Retina-Opticus; Sitzungsberichte der Wiener k. Akad. 48. Bd. S. 384.—*Heymann* und *Zenker*, A. f. O. II. 2. S. 137; VII. 1. S. 132; VIII. 1. S. 173, 182.—*Heymann*, Ophthalmologisches. Leipzig. 1868. S. 30.—*Schneller*, A. f. O. VII. 1. S. 83.—*Schweigger*, ibid. V. 2. S. 220; VI. 1. S. 153; VI. 2. S. 259, 264, 277, 287, 291, 294, 300; IX. 1. S. 203; Vorlesungen über den Gebrauch des Augenspiegels. Berlin, 1864. S. 101, 111; kl. Monatbl. 1864. S. 399.—*Nagel*, A. f. O. VI. 1. S. 191, 220; kl. Monatbl. 1864. S. 394; 1868. S. 417, 419.—*Iwanoff*, A. f. O. XI. 1. S. 135, 137, 143, 146, 154; XV. 2. S. 10, 19, 29, 49, 59, 88, 92 u. f. 100 u. f.; kl. Monatbl. 1864. S. 415; 1865. S. 328; 1868. S. 298, 421; 1869. S. 470.—*Rudnew*, Virchow's Arch. 48. Bd. S. 494, 498.—*Klebs*, A. f. O. XI. 2. S. 244.—*Junge*, ibid. V. 1. S. 49, 55.—*Bolling Pope*, Würzburg. med. Zeitschrift III. S. 244; kl. Monatbl. 1863. S. 317.—*Sämisch*, Beiträge zur norm. u. path. Anat. des Auges. Leipzig. 1862. S. 18, 24, 29; 1869. S. 305.—*Förster*, Ophth. Beiträge. Berlin. 1862. S. 99.—*Virchow*, dessen Archiv. X. S. 170, 181.—*Wagner*, ibid. XII. S. 218.—*Beckmann*, ibid. XIII. S. 97.—*Demme*, Beiträge zur path. Anat. des Tetanus. Leipzig und Heidelberg, 1859. S. 93.—*H. Müller*, A. f. O. IV. 2. S. 41; Verhandlungen der Würzburger phys. med. Gesellschaft. 1856. 27. Dec.; 1858. 8. Mai; 1859. 28. Mai.—*Malmsten* und *Gyllenschiold*, Gaz. méd. de Paris. 1862. Nro. 36.—*C. Ritter*, A. f. O. VIII. 1. S. 14, 67, 72.—*Schiess-Gemusens*, ibid. IX. 1. S. 30, 36.—*Leber*, A. f. O. XIV. 2. S. 341, 342, 357, 369; kl. Monatbl. 1868. S. 299, 302; 1869. S. 312, 314.—*Berlin*, A. f. O. XIII. 2. S. 294; XIV. 2. S. 281.—*Manz*, ibid. XII. 1. S. 8, 16.—*Knapp*, ibid. XIII. 1. S. 159, 167; kl. Monatbl. 1868. S. 355.—*Mauthner*, Lehrb. d. Ophthalmoscop. S. 318, 326, 328, 336, 347, 354, 356, 373, 374, 382, 434, 436, 440, 451.—*Coccius*, de apparatu optico, 1868, S. 15.—*Kussmaul*, *R. Meyer*, Centralbl. 1866. S. 361.—*O. Becker*, Arch. f. Aug. u. Ohrenheilk. I. S. 94; kl. Monatbl. 1868. S. 300.—*Liebreich*, Atlas d. Ophth. Taf. X.; Deutsche Klinik, 1861. S. 15.—*Simon*, Centralbl. 1868. Nro. 53.—*Recklinghausen*, nach Liebreich's Atlas. S. 30.—*Ed. Jaeger*, Handatlas. Fig. 67, 89-97. *Graefe*, A. f. O. XII. 2. S. 211.—*Classen*, Ueber das Schlussverfahren. Rostock. 1863. S. 32.—*Donders*, Anomal. v. Ref. u. Acc. Wien, 1866. S. 302.—*Secondi*, Clinica oc. di Genova, Torino. 1865. S. 42.

1. Diffuse Neuro-retinitis.

Symptoms.—*The characteristics are a regular or ill-defined cloudy opacity of the retina and papilla, with consequent veiling or complete enveloping of the posterior choroidal boundary; congestion of the larger vessels, with inclination to hemorrhage, mistiness or darkening of the visual field.*

1. The ophthalmoscopic appearances, and among these the chief symptom, the cloudiness of the retina and papilla, are not always very decided. For the ophthalmoscope throws only direct light, and it falls almost perpendicularly on the retina, that is, at an angle that is not favorable for a sufficient diffusion. Hence the homogeneousness of the retina and papilla must be considerably impaired if the cloudiness is very evident. In fact, in some cases it is very difficult to determine with certainty on a pathological cloudiness. (*Chro. lith.*, B.) The diagnosis must depend principally on disturbance of circulation, extravasations of blood, and particularly on the rather characteristic subjective symptoms. This is the more necessary as delicate veil-like opacities of the posterior portion of the retina not unfrequently occur, and then the posterior choroidal boundary appears less distinctly.

In some cases this inflammatory cloudiness occupies only parts of the fundus; the retinitis appears, temporarily at least, partial. This is proportionately observed most frequently about the macula lutea.

Where the process is more intense and the product formation and excretion of fat more extensive, the optical irregularity of the retina and papilla, as well as the distinctness of the pathological cloudiness, increases in very rapid progression.

Then the retina is often found as a more or less thick, not always quite regularly clouded, whitish-yellow or gray layer, which is spread out over the choroid as a veil (*Mauthner*), and only permits this to glimmer through as a faint red color; hence, also, the optic nerve entrance is very faintly defined, and is only distinguished from the surroundings by its brighter color. In other cases the choroid is entirely hidden, the fundus appears dull, dirty yellowish-gray, with dark and light cloudy lines; the posterior choroidal boundary is completely enveloped, and the position of the papilla is often recognized only by the common exit of the central vascular trunks, and perhaps by a pit-shaped excavation at that point. (*Chro. lith.*, C.)

In the cloudiness which comes over the fundus we occasionally observe fine stippling, radiated striæ, and delicate marbled appearances, which, as before mentioned, depend on certain anatomical conditions.

The accompanying disturbance of circulation often shows itself by coarse radiated striæ, or striated reddening of the papilla and its vicinity; but more frequently, especially in chronic forms of inflammation of long standing, only by decided enlargement and tortuosity of the venous trunks and chief branches. The arteries at the same time appear of normal diameter or even contracted. Not unfrequently we then see darker and brighter spots in the veins (*Chro. lith.*, B, C), which are thus explained. Where the inflammatory product is extensive the veins do not run in one layer, but sometimes are pressed forward by the swelled part of the retina, sometimes sink backward, and hence are seen at intervals in a direction approaching their axis.

At the same time the vessels appear quite distinctly or are much veiled, a phenomenon which points to a far advanced inflammatory alteration of the inner layer of the retina, or still more of the vitreous.

In some cases, particularly in the very chronic form, we find the vascular trunks and their larger branches bordered by bright, glistening, white lines. These indicate hypertrophy of the walls, and are seen most clearly if, while examining with the upright image, we turn the mirror slightly so as to throw the light from different directions. (*Schweigger.*) The reflex is then usually very decided, particularly in the arteries. Exceptionally the vessels appear as white branching cords, which only permit a very indistinct view of, or altogether hide, the blood, thus giving the vessels the appearance of being obliterated. (*Nagel.*) We may then often bring the blood to view, and prove the permeability of the tube by throwing a very small reflection directly on the part of the vessel in question. If the column of blood does not then become visible, we may decide on impermeability of the vessel. (*Liebreich.*)

A very marked hyperæmia, extending to the finer twigs, is not by any means an ordinary symptom, but is quite rare, and then usually occurs at the very commencement of a retinitis, beginning with great intensity. It is characterized by a fine red stippling of the retina and by the appearance of a delicate, close, trellis-like or looped network of vessels. As a rule, this is absent, and at most the papilla, especially its peripheral zone, is found very hyperæmic; so that the optic disc is elevated but little if at all above the rest of the fundus.

Hemorrhagic extravasations (*Chro. lith.*, B, C) are, it is true, not constant symptoms, but still they occur very frequently. They appear as dark or bright blood-red points, striæ, or spots, whose boundaries are sometimes sharp, sometimes blurred. They frequently lie quite superficially on the veins, and are then very distinct, especially in the region of bright exudation patches. But more frequently they lie deeper, and are then hidden by the cloudiness as by a veil. Where they are very numerous or extensive we call it *neuro-retinitis apoplectica.*

This form occurs especially in old people, between the ages of 50 and 80, and is then probably connected with disease of the vessels (*Pagenstecher*). It should be regarded as a peculiar kind of retinal inflammation only so far as the extravasation sometimes represents the primary affection, and the inflammatory process the reaction.

The ophthalmoscopic appearance of diffuse neuro-retinitis is much influenced by inflammatory cloudiness of the vitreous.

Fig. 33.

And this is rarely absent in the cases that commence acutely, while it often occurs in the chronic cases, at least during exacerbations. It is sometimes so dense that the retina can not be seen at all through the ophthalmoscope. More frequently, however, it is only a delicate diffuse mist or slight cloudiness over the fundus, occasionally confined to parts of the latter, and showing indistinct borders when the light from the ophthalmoscopic mirror falls on it in certain favorable directions.

2. The eye affected with pure retinitis offers objectively little or nothing else that is characteristic. In spite of far advanced diffuse retinitis, it may appear quite normal.

3. The functional disturbances of the retina, caused by the inflammation, are of the greatest importance. It is these that call the patient's attention to the disorder, and lead him to ask for treatment.

Very frequently, especially in an equal distribution of the inflammatory product in the retina, the functional disturbance shows itself by an equable, more or less thick, rapidly or gradually increasing cloudiness of the entire visual field. In low grades of the affection the patient complains mostly of a whitish or whitish-gray, frequently, also, a yellowish or brownish-yellow fog, which envelops all objects in the visual field. Examination shows a marked decrease of central sharpness of vision with proportionate indistinctness of eccentric vision. In higher grades of the disease, the fog is thicker, its color is grayer, even to ash-gray, objects appear as if enveloped in smoke; central vision is diminished to a small amount, but peripheral vision disappears to simple perception of light. When the illumination is slight, vision is entirely lost; so-called amaurotic mist exists. In the highest grade, finally, the qualitative perception of light ceases, the affected eye can only distinguish between strong and weak illumination of the visual field.

With regard to the pathological conditions, it may be considered as probable that the bright veil, which in slight degrees of the affection lies over the visual field, is not only the expression of diminished perception and conduction of the nervous elements, but must be attributed mostly to the optical irregularity of the connective tissue; that is, it is like the disturbances of vision from opacities of the dioptric media, a result of the dispersion of the light in the inflamed layers of the retina.

In fact the quality of the disturbances of vision in these forms of retinitis offers striking analogies to those caused by corneal opacities covering the pupil. Bright illumination of the visual field, especially the action of intense diffuse light, increases the disturbance of vision by thickening the mist and giving it a brighter color. Darkness of the visual field, however, acts by not permitting the passage of sufficient direct rays through the anterior retinal layers to finally cause distinct images on the bacillar layer. With sufficient illumination of the visual field, and exclusion, as far as possible, of diffuse light, slight cloudiness of the inflamed retina does not prevent the patient from perceiving clearly, with the center of the retina, even small objects which contrast with the background, from reading ordinary print, &c. But the patient must bring the objects nearer the eye than he should normally do; so he strains himself and can not use his eyes long at a time. Of course with the increase of the inflammatory product, its optical effect and the disturbance of function of the nervous elements must increase. In decided cloudiness or complete opacity of the retina, central sharpness of vision and distinctness of eccentric perceptions, are, as a rule, but not always, much diminished. A complete exclusion of diffuse light is necessary to permit the perception of even large objects which are near, and contrast with the background. In many cases vision is even limited to quantitative perception of light.

There does not seem to be any steady proportion between the amount of disturbance of vision and the extent of the product. This is influenced by the extent to which the *nervous* elements are affected, and this is not by any means in proportion to the collection of product in the connective-tissue framework of the retina and optic nerve. On the contrary the nervous elements are not unfrequently well preserved in far advanced proliferation of the framework, and *vice versa*. Hence it not unfrequently happens that, with relatively slight cloudiness of the retina, great disturbance of vision (even only sensitiveness to light), may be observed, without any central disease or proportionate affection of the nerve-trunk being the cause.

In some cases of pure diffuse neuro-retinitis, limitations of the visual field occur, the functional activity of a smaller or larger section of the retina is entirely lost, while the rest of the retina functions with the above-described restrictions. Much more frequently there are interruptions in the visual field, *i. e.*, blindness of certain spots lying near the center. They appear as vacant, thickly-veiled, or dark spots in the field of vision. Frequently it is a single spot, lying centrically or eccentrically, a ring surrounding the center of the visual field, &c. In other cases there are several

spots, varying in form and size. The boundaries of these limitations and interruptions are usually less distinct than in those amblyopic states caused by cerebral or optic-nerve disease. (See *Amaurosis.*)

There is no doubt that extravasation of blood, and sometimes thick opacities in the vitreous, may cause partial darkening of the visual field (*Graefe*).

Besides these subjective symptoms, others often appear, which, however, on account of their inconstancy, are of but little value in diagnosis. Patients often complain of a peculiar glimmering, glittering, trembling obscurity in the visual field, which is now more, now less prominent. Sometimes the visual field appears colored, yellowish, reddish, greenish, &c. True chromopsia and photopsia, also, not unfrequently occur, at least periodically, after severe mental or bodily excitement. They are most frequently observed in the more acutely commencing processes, especially after the action of a decided irritation, and then by their intensity and duration are sometimes very painful. These subjective symptoms point to a continuance of the progressive period, and hence are important to consider in making a prognosis. In certain rare cases, the patients see objects elongated, irregular, or confused (*Metamorphopsia*), lessened (*Mikropsia*), enlarged (*Megalopsia*). More frequently disturbances of the color sense are observed (Leber).

Actual photophobia and pain are not, however, constant symptoms, but are frequently absent, especially in the more chronic forms, and in the later stages of the acute cases.

Causes.—1. Diffuse neuro-retinitis is often developed primarily without any assignable cause. More frequently, however, it is excited by discoverable internal or external injurious influences. Most commonly functional irritation and wounds are the direct causes—among the former, excessive intensity of illumination of the visual field by sunlight, whether direct or reflected from bright and glittering objects. Not less, however, may slight intensity of illumination, if it changes rapidly and often, lead, by long continuance, to retinal inflammation. But most frequently excessive straining of the eye, for the perception of small objects, is the source of this affection.

Among the first may be reckoned excessive illumination of the visual field, whether from direct light or from sun-light reflected from bright and glistening objects. A slighter degree of illumination, by rapid and frequent variation, may also after a length of time lead to inflammation of the retina. The most frequent cause of this affection is found in excessive straining of the organ of vision for the purpose of seeing small objects distinctly.

Thus, hypermetropia may form a strongly-disposing cause (*Secondi*). Dazzling colors and bright objects, as well as, on the contrary, slight contrasts with the background, flickering or weak artificial illuminations, and cloudiness of the dioptric media, as well as all else that influences the distinctness of the retinal images, have a great effect. However, the *duration* of the straining is more important than the *intensity*. Employments causing the latter, produce mostly only irritation; but continuance of the straining while the irritation is present produces the alteration of tissue.

Wounds cannot affect the retina and optic nerve (*His*) without greatly injuring the surrounding parts. Hence a neuro-retinitis developed as a result of concussion, blows, accidental or operative solution of continuity, etc., is rarely pure, but is usually accompanied by irido-choroiditis, and is often only a symptom of panophthalmitis.

The same thing holds good for inflammation of the retina occurring after injuries of the optic nerve, when the foreign body has passed through the globe and lodged in the nerve (*His*, *Stecnhagen*, *Graefe*). Division of the optic nerve in the orbit in animals (*Rosow*, *Kugel*, *Leber*), or as a consequence of accidental injury (*Pagenstecher*), without injury to the globe,

leads to intense white opacities of the retina and papilla. The margin of the optic disk is completely concealed by them; the central vessels appear partly empty of blood and partially covered by the opacity. When the ciliary vessels are partially divided, the fundus also becomes pale in spots at the periphery, but the collateral circulation being soon established, the opacity of the retina recedes and symptoms of atrophy appear. In one case (*Pagenstecher*) the retina and papilla remained deeply pigmented.

Among the traumatic forms belong also those cases of diffused inflammation which occasionally result from rupture of the vessels and escape of blood into the tissue of the retina and optic nerve (*Pagenstecher*). In this way congestions, or ultimately heart and lung disease, may prove causes of neuro-retinitis.

Heart disease, and especially endocarditis, causes retinitis sometimes also by throwing off masses of exudation, and causing embolism of the central artery of the retina (*Virchow*). Diffuse inflammatory cloudinesses of the retina are, in fact, constant symptoms of embolism of the retinal artery (see *Amaurosis*). Such a cloudiness of the central portions of the retina was observed once, also, in thrombosis of the cerebral sinus (*Knapp*).

2. It is also said that diseases of the liver may under certain circumstances cause inflammation of the retina (*M. Müller*, *Althof*, *Pagenstecher*). It is also supposed that a connection exists between retinitis and tuberculosis (*Galezowski*) and diabetes (*Heymann*, *Galezowski*, *Noyes*, *Ed. Jaeger*).

3. Diffuse retinitis most usually depends on constitutional syphilis, and is a localization of this disease. It is then occasionally accompained by irido-choroiditis and keratitis punctata, or with iritis alone. Frequently iritis precedes it, and the retinitis occurs after one or several attacks of the iritis, without the latter necessarily relapsing. Retinitis is peculiarly apt to occur, if, during convalescence from specific iritis, or before entire removal of the disease, the eye is exposed to functional sources of injury. As a rule, however, syphilitic neuro-retinitis exists alone in the eye. It sometimes affects one eye, sometimes both. It has no peculiar symptoms; its syphilitic nature is indicated solely by the presence or previous existence of the symptoms of constitutional syphilis.

4. Diffuse neuro-retinitis is also frequently secondary to some disease excited in the vicinity of the optic nerve or retina.

a. The inflammatory proliferation not unfrequently begins in the cranium, and thence proceeds along the optic nerve to the retina. This is called neuro-retinitis descendens.

It very rarely happens that the inflammatory action is propagated directly to the fibers of the optic nerve from the central organs of the sense of sight, or from other parts of the brain through which the optic nerve bundles pass, and passes in the connective-tissue sheath of the first to the roots and trunk, in order to reach the retina. Generally the manifest growth in central foci of inflammation is confined to the interior of the brain or to one of the two optic tracts; in the orbital portion of the optic nerve and in the retina it only reaches the degree of gray atrophy (see Atrophy of the retina). Still cases of the first kind do undoubtedly occur (*Blessig*, *Leber*, *Galezowski*).

In agreement with the anatomical relations, it is most frequently foci of disease, especially tumors, in the region of the middle fossa of the skull, and in the vicinity of the corpora quadrigemina, which lead to a descending neuro-retinitis (*Galezowski*). Hence, the usual symptoms of vomiting, headache, epileptiform attacks and convulsions are accompanied very generally by paralysis of all the cranial nerves from the 3rd to the 8th, and in case a root of the optic nerve has lost its functional activity by the primary inflammation, by symptoms of hemiopia.

A meningitis, coincident with the central affection, is much more frequently the cause of the transfer. The most various affections of portions of the brain lying at

a distance from the optic centers may moreover by such an inflammation of the membranes of the brain be combined with optic neuritis. Basilar meningitis must be regarded as one of the most important pathogenetic factors of neuro-retinitis, and we shall not go too far in saying that basilar meningitis makes its appearance in the majority of cases in the fundus, and that the ophthalmoscope is therefore an important aid in the diagnosis of meningitis. In fact great dilatation of the retinal vessels and œdema of the papilla are frequently met with in the latter affection; hemorrhages and even diffuse opacities and sometimes even large inflammatory extravasations in the form of white spots may be demonstrated, and these at a time when the symptoms of meningitis are not yet pronounced and while the diagnosis of the main affection is still difficult (*Bouchut*, *Clifford*, *Galezowski*).

It may be affirmed, that whatever may give rise to a meningitis may also prove a cause for the inflammatory affection of the nerve, *e. g.*, wounds with fracture of the base of the skull (*Manz*, *Jacobi*), tuberculosis (*Bouchut*, *Galezowski*), etc. Epidemic cerebro-spinal meningitis also plays a rôle in the causation of neuro-retinitis (*Schirmer*). Still, under such circumstances this is of a suppurative character, and will therefore be described under suppurative panophthalmitis. The agreement between the products of basilar meningitis and a neuro-retinitis dependent upon it by no means necessarily follows, however; on the contrary, diffuse varieties of the latter may easily appear as consequences of tuberculous or suppurative meningitis.

Moreover, the descending retinitis is not uncommonly observed in meningitis of the convexity of the hemispheres (*Bouchut*, *Blessig*), in tumors, etc. in the most different parts of the cerebrum and cerebellum (*Blessig*, *Leber*, *Galezowski*, *Benedikt*), and generally under conditions which do not admit of the hypothesis of a direct connection between the primary affection and that of the eye. Moreover, the orbital portion of the optic nerve appears entirely uninvolved in manifest descending neuro-retinitis, or can be only recognized as affected in slight degree and partially by small collections of nuclei in the neurilemma, or by partial fatty degeneration of individual bundles of nerve-fibers (*Iwanoff*, *Leber*). The manifest focus of inflammation then appears limited to the most anterior part of the nerve, the papilla and retina at any rate are separated from the primary intracranial inflammation by uninflamed portions. It is evident, that under such circumstances there can be no question of a propagation of the inflammation by contiguity of tissue; and that here nervous influences, particularly of a vaso-motor nature, must rather come into play (*Benedikt*), just as in the atrophy of the retina which frequently appears under similar relations.

The affection of the vessels manifests itself in not a few of such cases by very great dilatation of the central venous trunks and of the vascular network of the papilla by extravasations, etc. In addition to these, œdema soon occurs, in consequence of which the papilla swells up, with steep walls, which are only open towards the macula lutea. The entrance of the optic nerve may remain even for a long time in this condition without the neighboring retinal zone participating in the process, while the connective-tissue framework slightly hypertrophies. Sooner or later, however, a true inflammation appears, the nerve-fibers hypertrophy and in part undergo fatty degeneration, while varying quantities of neoplastic cells are collected together in its tissue, the reddened wall becomes more and more opaque, and later on the retina takes part in the changes (*Iwanoff*, *Leber*).

The above-mentioned prominence of the papilla has been described as a peculiar condition under the name of obstructive neuritis or choked disk (*Graefe*), assuming that the colossal dilatation of the vessels can only be caused by mechanical hindrance to the circulation. This

view was supported by the fact, that in the majority of the cases at first observed the affection was developed with tumors, which were situated in the middle fossa of the skull, and possibly or actually pressed upon the cavernous sinus (*Graefe*, *Hulke*). Still the absence of all signs of obstruction in the ciliary and orbital circulation, as well as the anastomosis of the central retinal vein with both ophthalmic veins, and indirectly with the anterior and posterior facial veins (*Sesemann*), have long since been regarded as valid objections to this view (*O. Becker*). Besides all this, in cases of obstruction of the cavernous sinus which have been anatomically demonstrated, in thrombosis (*Knapp*) or compression of the sinus by neighboring tumors (see pulsating orbital tumors), the cushion of the orbit as well as the conjunctiva and the lids presented all the symptoms of an extreme degree of congestion and œdematous swelling, but the visual power had not as a rule suffered, and the ophthalmoscopic examination was either negative or proved the existence of symptoms in regard to the thrombosis which have been found in connection with embolus and ischæmia (*Knapp*). In hydrocephalus (*Galezowski*) and tumors of the brain which are complicated by increase of the intra-cranial tension, the choked disk is an exceptional appearance; while on the contrary it has been found in secondary formations which ran their course without any increase of the intra-cranial tension, and from their situation could not possibly exert any influence upon the cavernous sinus or upon any portion of the optic nerve tract. Still it has been observed in softening and in tumors of the cerebellum (*Blessig*, *Leber*), and even in basilar meningitis (*Manz*). Moreover, certain observations point to the supposition that the disease of the vessels connected with it, like that lying at the bottom of the pulsating orbital tumors, may appear primarily without any obstructive cause (*Wecker*). Recently it has been believed that the key to the explanation of the choked disk has been found in the distribution of the lymphatic vessels (*H. Schmidt*). If the close lymphatic network ramifying in the lamina cribrosa is actually connected with the arachnoidal space by means of the space between the two sheaths of the optic nerve, then the œdema of the papilla and also the obstruction of the retinal veins in the region of the papilla may in the simplest way be connected pathogenetically with an abnormally increased intra-cranial pressure. In fact, experiments upon animals corroborate the correctness of this theory, which possibly enters deeply into the pathology of the eye (*Manz*). The circumstance that the so-called choked disk appears relatively but rarely in marked increase of the intra-cranial pressure, and, on the other hand, is met with in a perfectly normal state of the latter, is, however, unfavorable for the above view. Hence obstructive neuritis may for the present be regarded as a variety of neuro-retinitis, distinguished by the colossal dilatation of the vessels and œdematous infiltration. Mixed forms also are really by no means uncommon occurrences, and one form often passes over into the other (*Graefe*, *Leber*).

b. More rarely the process starts from the soft parts of the orbit. The neuro-retinitis is excited by neoplastic growths (*O. Becker*, *Mauthner*, *Hirschberg*), by simple abscesses, or those caused by caries of the bone, periostitis, etc. (*Hulke*), by erysipelatous swelling of the connective tissue in the orbit (*Arlt*, *Wecker*, *Graefe*), whether it be caused by the process of proliferation passing immediately to the sheath and inner neurilemma of the optic nerve, or by the mechanical effect, pressure, tension, etc., of the nerve. In the latter case symptoms of congestion in the retinal vessels are usually very perceptible (*Graefe*, *Pagenstecher*).

c. Finally, neuro-retinitis frequently starts from the uvea. Indeed, choroidal inflammations rarely terminate without participation of the retina and optic nerve. As a rule, this occurs quite early in the disease. When the symptoms of neuro-retinitis occur prematurely, the latter takes part in sympathetic ophthalmia (*Graefe*, *Moorem*).

In irido-choroiditis and irido-cyclitis we may often see the anterior zones of the retina far advanced in the inflammation, or even already atrophied, while the posterior parts are healthy enough (*Iwanoff*).

The Course is in most cases decidedly chronic; even the commencement often quite unmarked, as prominent symptoms are absent, and the process only betrays itself by a gradual decrease of sharpness of vision.

Hence in monocular chronic retinitis the affection is at first easily overlooked; in fact, this not unfrequently happens even where it is binocular, if the persons affected are not observant, and their occupation does not oblige them to employ themselves with small or distant objects. Then the disease sometimes exists for weeks or months before the increasing weakness of vision, the difficulty of going about at night, the appearance of dark spots in the field of vision, or its decided contraction, render impossible all doubt as to the existence of the disease. Ignorant persons often can not give the date at which vision began to fail.

Mistakes may the more readily be imagined as the decrease of function is not at all steady, but in many cases, improvements and relapses occur, as the conditions under which the patient happens to be are more or less favorable. Among the causes increasing the degree of visual disturbance, may be especially mentioned bodily and mental excitement, excesses in eating, drinking, and venery, and above all passive congestion of the superior vena cava.

In other cases the process develops more rapidly to a certain point, then becomes chronic and proceeds slowly to its termination, with gradual increase of the retinal alterations and consequent disturbances of vision, with or without temporary remissions.

Thus, without other marked symptoms, a decided diminution of central sharpness and clearness of excentric vision shows itself; the functional power of the retina fails from day to day, and in a short time has sunk very low—or the disease begins with more or less severe headache, ciliary neurosis, photophobia, chromopsia, or photopsia. These symptoms continue for some time with rapid decrease of vision, but then recede, while the disturbance of vision continually but slowly increases. The former is observed in syphilitic retinitis, the latter in those retinal inflammations which are excited by intense functional irritations.

Of course, the *descending* forms are, as a rule, preceded by symptoms of the original disease; but, exceptionally, the latter remains concealed for a time, and the disturbance of vision, with the characteristic changes in the optic papilla, appears first, and it is only subsequently that its dependence on an intracranial affection is discovered. Then the neuro-retinitis and accompanying disturbance of vision often develop very rapidly, one or several days sufficing for the complete development of the characteristic symptoms, and for reducing vision to the quantitative perception of light or entire blindness. Arrived at this point, the process becomes more chronic and goes on to its termination.

Results.—Diffuse retinal inflammation, with some exceptions, is to be classed among the curable diseases. This is particularly true of those forms that at their commencement and during their course are chronic, in which the inflammatory product is less extensive and is evenly distributed, provided that the process has not existed for months. Where the morbid material is extensive, whether it be evenly distributed or collected in spots, the hope of a complete return to the normal state is very slight: a diminution of the thick mist lying over the field of vision is the most that can be hoped for; for under such circumstances the nervous elements are usually affected very early in the disease.

Under otherwise similar circumstances the prognosis is more governed by the duration of the process than by the amount of diminution of central sharpness and excentric vision. Indeed, the reduction of vision to quantitative perception of light does not preclude all hopes of a cure. Interruptions, and especially limitations of the visual field, have, however, a worse significance, for they show a strong participation of the nervous elements. Limitations rarely, if ever, depart; a clearing up of the other misty parts of the visual field is all that can be expected. Interruptions of the field also are removed with difficulty; still this is attained sooner in recent cases of this kind than in contractions, provided that the case is one of pure diffuse neuro-retinitis, and has no connection with any intermediate exudative form.

Then the interruptions decrease in extent, the affected portion of the field of vision becomes clearer, more transparent, and is finally lost in the clear parts surrounding it. This clearing up is not unfrequently irregular. The blind spot divides into several smaller ones, between which objects appear more and more distinctly, till finally the blind spots are lost in the increasing bright intervals; or the spot clears from the center, forms a ring, which gradually loses in width and darkness, divides into arcs, and disappears.

Henceforth, even in the most favorable cases, a tendency to relapse remains, which the slightest external or internal injury can make the source of a new disease, and which consequently requires the strictest attention.

On the whole, even in the absence of contractions and interruptions of the visual field, a restoration of normal function is only attainable in the minority of cases. Frequently, with some cloudiness of the retina, a more or less decided mistiness of the visual field remains, which can not be neutralized by optical means, and not only decidedly interferes with distant vision, but also renders the patient unfit for continuous occupation with small objects, reading, writing, sewing, &c.

Not unfrequently, also, the clearing up of the visual field is only temporary, since sooner or later, under successive changes and partial absorption of the inflammatory product, *atrophy* occurs, which, in the commencement at least, may be confined to the connective tissue, but with time draws the nervous elements into the affection, and leads to new incurable cloudiness, to interruptions and contractions of the visual field. Of course, this result is the more to be feared the greater the intensity of the process and the greater the amount of the product, the longer the infiltration of the retina has existed, and the less suitable the condition of the patient during and after treatment.

The atrophy thus caused does not, however, present itself in the cloudy form. Exceptionally it has, in the later stages, more the stamp of pure or gray atrophy, and this is most frequently observed in the *descending* forms of neuro-retinitis. The inflammatory products in the papilla and the surrounding zone of the retina are then fully absorbed, but the atrophy goes on under the influence of the primary affection.

Treatment.—The leading indications for treatment in retinitis, as in all other inflammations, are, to avoid and remove all injurious influences which are calculated to excite, maintain, or increase the process; to restrain and suppress the development of tissue; to cause the removal and absorption of the diseased product, without endangering the still existing normal elements.

First of all, it must be decided whether the retinitis is a secondary affection, and, if it is, actively to combat the primary disease, if still existing. We must especially bear in mind the frequency of a syphilitic origin. Where this is found, or is probable, an energetic antisyphilitic treatment should be commenced.

In every case, by ordering a suitable regimen, we should attempt to restrain and remove all causes for increase of the existing disturbances of circulation and of the inflammatory state of irritation. For the latter purpose, it is most important to secure functional inactivity of the eye. Rest is recognized as an excellent antiphlogistic; indeed, it is the one least to be dispensed with. For securing perfect rest, we may best employ a well-fitting protective bandage, which perfectly closes both eyes. For this to fulfill its object, it should not be removed unless in a dark room, and while the lids are kept closed. Frequently lifting it, especially in bright places, or even trials of vision, are dangerous, as, on account of the long closure of the eyes, the contrast of bright light is much hightened, and its irritating influence

increased. Foolish and stupid patients thus often ruin, in a few minutes, all that constant guarding from the light had attained in a week: hence, in such individuals, the prognosis is much more unfavorable than in careful, sensible patients. Usually it is advisable to recommend remaining in a dark chamber, and, besides this, to apply the protective bandage.

Simply placing the patient in a darkened room does not answer the purpose so well as a protective bandage; for, with open eyes, the patient feels constantly tempted to try his vision, and thus strains his eyes not a little. Moreover, it is scarcely possible to darken a dwelling-room quite regularly, and shut out all contrasts of illumination, without necessarily impairing the ventilation, and thus injuring patients otherwise, in the course of a long treatment.

Many permit the patient to go about freely with open eyes, and simply warn him to shun dazzling light, contrasts of illumination, and employments requiring constant use of the eyes. Still, if these rules are most intelligently followed, the cure usually progresses slowly, and this is very disheartening, in a process in which long continuance is recognizedly of the worst influence on the prognosis.

As direct means, mercury is almost universally considered necessary, even without regard to a syphilitic origin of the affection. It is now, it is true, discovered that in *non*-syphilitic, and especially in recent, cases of diffuse retinal inflammation, wonderful results may be attained by the above-mentioned dietetic rules. However, in so destructive and (especially when long existing) dangerous a disease, the antiphlogistic powers of mercurials and their proved resorbent qualities, must always be regarded as a desirable assistance; and it appears at least advisable to proceed with the inunction treatment, or with the internal use of the bichloride in increasing and diminishing doses.

Local blood-letting and other antiphlogistic remedies render scarcely any service, and are best avoided.

Usually this proceeding is to be continued strictly and without interruption for ten to fourteen days. After this time the eyes are to be exposed in the dark, and the increase of the power of vision carefully tested, but at the same time all straining of the eyes is to be avoided. Then, in favorable cases, a decided increase in the clearness of perceptions shows itself, and often, also, some clearing up of any existing interruptions. If this is not the case, we dare not hope for much. A preservation of the still existing grade of functional power is then usually the most that can be attained.

Now the inconvenience of the treatment may be lessened, but the patient should continue the bichloride for some time, or, if inunction has been used, iodide of potash. The diet is to be improved, and the patient permitted to wander about the darkened room with his eyes open for an hour or so daily; or, in favorable weather, after sundown in the open air. Gradually the time for this freedom is lengthened, and finally, walks by daylight in shady places are permitted. The patient will, at the same time, with advantage, wear smoke-colored glasses. Direct and also dazzling diffused sunlight, lamplight, &c., are still most carefully to be shunned, and where the patient can only keep himself from them with difficulty, it is best to apply a protective bandage. When the patient has gradually accustomed himself to a bright light, he may go about under the protection of a broad-brimmed hat and smoke-colored spectacles, but had better always avoid dazzling light.

The patient often remains unfit for work which is at all straining, for continued writing, reading, sewing, &c., and perhaps it would be best to tell him so at first. Moreover, long after the commencement of entire convalescence, rigorous care of the eye and avoidance of all excesses of diet and regimen can not be too carefully

attended to, if we would avoid relapses. When any errors of refraction are present, suitable spectacles must of course be worn when work is resumed.

Authorities.—*Coccius*, Ueber die Anwendung des Augenspiegels. Leipzig, 1853. S. 115, 124. —*Liebreich*, A. f. O. I. 2. S. 346, klin. Monatbl. 1864. S. 397, 401, Atlas der Ophth. Berlin, 1863, Taf. 8, 10.—*Ed. Jaeger*, Beiträge zur path. Anat. des Auges. 1855, Taf. 10, 11, 12.—*Schweigger*, kl. Monatbl. 1864. S. 399, Vorlesungen über den Gebrauch des Augenspiegels. Berlin, 1864. S. 94, et seq.—*Schneller*, A. f. O. VII. 1. S. 70, 81, 83.—*Pagenstecher*, klin. Beobachtungen. Wiesbaden, 1861. I. S. 51, 54, II. S. 24.—*Nagel*, klin. Monatbl. 1864. S. 394.—*Graefe*, A. f. O. I, 1. S. 367, II. 2. S. 277, 290, 293, VII. 2. S. 58, 66, kl. Monatbl. 1863. S. 58, 59, 1864. S. 367.—*Tetzer*, Wiener med. Jahrbücher. 1864. S. 164.—*Secondi*, Clinica oc. di Genova. Riassunto. Torino, 1865. S. 57.—*His*, Beiträge zur norm. u. path. Anat. der Cornea. Basel, 1866, S. 132.—*Rosow*, Sitzungsberichte der Wiener k. Akad. 49. Bd. 1. S. 431, 50. Bd. 2. S. 369.—*Virchow*, desen Archiv. X. S. 181.—*Knapp*, klin. Monatbl. 1864. S. 402.—*H. Müller* und *Althof*, Würzburg. med. Zeitschrift II. 1861. S. 349.—*Galezowski*, Congress intern. d'ophth. Paris, 1863. S. 110.—*Hutchinson*, A clin. memoir on certain diseases of the eye, etc. London, 1863. S. 223.—*Heymann*, klin. Monatbl. 1864. S. 270 273, 1865. S. 281, A. f. O. VIII. 1. S. 173.—*Manz*, klin. Monatbl. 1865. S. 281.—*Horner*, ibid. 1863. S. 71.—*M. Fischer*, ibid. 1866. S. 164.—*Blessig*, ibid. S. 273.—*Leyden*, Virchow's Archiv 29. Bd. S. 202.—*Sämisch*, Beiträge zur norm. u. path. Anat. des Auges. Leipzig, 1862. S. 18, 24. 27.—*Iwanoff*, A. f. O. XI. 2. S. 138.—*Koster*, Zesde Jaarl. Verslag. Utrecht, 1865. S. 1, 8, 18.

Ed. Jaeger, Hand-Atlas, Figs. 62–65.—*Pagenstecher*, klin. Beobachtungen. Weisbaden, III. S. 70, 83; A. f. O. XV. 1. S. 233.—*Nagel*, klin. Monatbl. 1868. S. 315.—*Graefe*, A. f. O. XII. 2. S. 114, 116, 120, 148, 212, 215; Berlin, kl. Wochenschrift. 1868. Nr. 20.—*Knapp*, A. f. O. XIV. 1. S. 220.—*Galezowski*, Arch. gen. de med. 1867. II. S. 258; 1868. II. S. 662, 680; 1869. I. S. 47, *et seq.*—*Manz*, Centralbl. 1870. S. 113; A. f. O. XII. 1. S. 1.—*Iwanoff*, kl. Monatbl. 1868. S. 421, 424.—*Blessig*, Centralbl. 1866. S. 341; kl. Monatsblatt, 1866. S. 273.—*Czerny*, Sitzungsber. d. Wien. k. Akad. LVI.—*Mauthner*, Lehrb. d. Ophthscopic. S. 357, 361, 368, 374.—*Benedikt*, Electrotherap. 1868. S. 250, 256, u. f.—*Arlt*. Wiener Augenkl. Ber. S. 123, 126; kl. Monatbl. 1869, S. 92.—*Bouchut*, Gaz. med. de Paris, 1868, Nr. 45, 46.—*Noyes*, Transact. Amer. Ophth. Soc. 1868. S. 71.—*Hulke*, Ophth. Hosp. Rep. VI. 2. S. 89; Lancet, 1867, II. S. 395.—*Mooren*, Ophth. Beob. S. 287; Ueber symp. Ophth. Berlin, 1869. S. 96.—*Alexander*, kl. Monatbl. 1867. S. 223.—*Schirmer*, ibid. 1865. S. 275.—*Wecker*, ibid. 1868. S. 409.—*Clifford*, ibid. 1868. S. 252.—*Hirschberg*, ibid. 1869. S. 74.—*O Becker*, ibid. 1868. S. 313; Wiener Augenkl. Ber. S. 162, 168.—*Kugel*, A. f. O. IX. 3. S. 129.—*Jacobi*, ibid. XIV. 1. S. 147, 154.—*Leber*, ibid. XIV. 2. S. 333, 352, 363; XV. 3. S. 105; kl. Monatbl. 1868. S. 302, 307. —*Stavenhagen*, kl. Beobach. Riga, 1868, S. 79.—*H. Schmidt*, A. f. O. XV. 2. S. 193.

2. Exudative Retinitis.

Symptoms.—*The characteristic objective symptoms are light-colored spots, bordered by dark pigment, that appear in the fundus of the eye during or after a diffused or circumscribed inflammatory retinal cloudiness; these depend on the destruction of the tapetum, but ultimately also on the atrophy of the choroidal tissue.*

The ophthalmoscopic appearances vary greatly; they differ in almost every case and in the different stages of the process. Still the differences may readily be referred to certain types, which represent so many varieties of the inflammatory process.

a. The ophthalmoscopic appearance originally often exactly resembles that of a diffuse retinitis; only later, after the regular cloudiness of the retina and papilla has become less, do we see the changes in the tapetum and choroidal stroma. The yellowish-red tint of the fundus appears pale at intervals, or is in some places yellowish-gray, or even dirty white. Frequently the structure of the vasculosa may still be recognized in it. This is either indistinct, of a delicate dirty grayish-brown color, or deep shades of brown are very prominent; still the outlines of the individual parts are in places at least less regular or wholly distorted. Between them we usually see some tortuous vessels. Over the spotted, or more regularly pale fundus are scattered heaps of pigment of various sizes, with granular borders, varying from bright brown to coal-black, sometimes scanty, sometimes very numerous. (*Chrom. lith.*, F.)

b. In other cases the disease begins with the symptoms of a diffuse or nephritic neuro-retinitis; still from the first the collections of exudation are seen as figured spots of variable size, which are grayish-white, grayish-red, or yellowish-white, similar to the surrounding cloudiness, but deeper colored. (*Chrom. lith.*, C.) They are regularly or irregularly formed, sharply or indistinctly bounded, and not unfrequently surrounded by, or interspersed with, collections of pigment, which at first appear only indistinctly through the cloudiness. When the infiltrated retina subsequently clears up, and the exudation gradually disappears by absorption and atrophy, the individual foci (points of inflammation) retain the appearance which has just been or will soon be described.

Sometimes, and, as it would seem, particularly in the nephritic form, these spots are composed of small, very bright (when full formed, whitish-yellow or pure white, and then very brilliant), angular figures, which sometimes have rounded, sometimes acute angles. (*Chrom. lith.*, J.) These figures, arranging themselves in series, form a sort of star, whose rays all converge to the fovea centralis, or some point near it, and extend further upward and downward than laterally, thus giving the spot the appearance of being elongated vertically. It is believed that this condition is dependent upon fatty degeneration of the supporting fibres of the retina (*Mauthner*).

c. Less frequently the inflammatory process is originally developed in circumscribed spots, and forms a large amount of product, which partly infiltrates, partly lies on the posterior surface of the retina, and, under certain circumstances, is in the tissue of the choroid. Hence those spots, at first, not unfrequently appear raised,

and in certain recent cases it was thought that the retinal vessels running over them appeared elevated at their edges. They appear as reddish-gray or reddish-white, sometimes also pure white or yellowish white dull spots, which, surrounded by a slight blurred border, are distinctly defined from the normally colored fundus. (*Chrom. lith.*, D.) The tapetum is still hidden by the extent and opacity of the product in the foci, but occasionally, even very early, single groups of proliferating pigment-cells approach the surface and appear as blue-black or brown islands. Subsequently, after partial resorption, the foci become more translucent. Then we may often see the structure of the vasculosa through them, and between them some of the vasa vorticosa. (*Chrom. lith.*, D.) More frequently, however, the pigment is all lost, the choroid atrophies more and more, and the color of the spot becomes a regular grayish-red, whitish-red, whitish-yellow (*Chrom. lith.*, E), or dirty yellowish-gray, occasionally with a decided inclination to green. (*Chrom. lith.*, F.) The vessels of the vasculosa are then usually atrophied as far as the affected part reaches. On the border of the spot, and outside of it, are almost always to be seen clumps of dark pigment, which are scattered around irregularly—exceptionally have the contours of bone-corpuscles (*Chrom. lith.*, E), or are branched. In one case bright yellow, glistening crystals have been seen in the spots (*Nagel*).

Usually the individual foci have no typical form. Their figure is quite irregular (*Chrom. lith.*, D, E). They are usually few in number; often there is only one. But they frequently attain a considerable size, and may even cover the entire fundus (disseminated forms).

Not very uncommonly the process is limited solely to the macula lutea, and then assumes very peculiar forms. Sometimes there appears here a coal-black, round, or even angular spot, generally very sharply defined and of small size, which is occasionally surrounded by a clear white space of varying width, whose external border often appears marked by granular pigment. In other cases a round bluish or red spot appears in the region of the macula lutea, surrounded by a sharply-defined bright ring. More or less extensive circular masses have exceptionally been found in the region of the macula lutea, in which the tapetum has entirely disappeared, and consequently the vasa vorticosa of the choroid seem to lie open to the view (*Ed. Jaeger*).

There is scarcely a doubt that these forms (Retinitis circumscripta, *Förster*) are to be regarded as exudative. In fact, in one case growth of the layers of granules, destruction of the bacillar layer, and the formation of a vascularized tissue, deeply pigmented in its external layers between the choroid and retina, have been demonstrated as the origin of a circumscribed black spot in the macula lutea (*Sämisch*).

Another series of cases is characterized by the occurrence of numerous rather sharply-bounded foci, which all have a roundish or oval form, and are at least partly bounded by a line of dark pigment. These foci are occasionally pressed so close together that they unite to form large spots, and can only be distinguished from each other at their outer border (*Chrom. lith.*, H); or we find only in the vicinity of the macula lutea a few large round foci collected together: at some distance from this they become fewer, are more scattered, and are much smaller (*Chrom. lith.*, G); many appear only as pin-points surrounded by a broad band of pigment; or they appear as solid heaps of pigment. In some cases a closer connection between the foci and the retinal vessels is said to have been observed (*Nagel*, areolar form).

Where the exudative neuro-retinitis is pure, the objective symptoms are confined to the above-described ophthalmoscopic appearances. Regarded from without, the eye appears perfectly normal; even hyperæmia is usually absent. Still during the inflammatory stage, and the not unfrequent relapses, we frequently meet diffuse cloudiness in the vitreous, which renders ophthalmoscopic examinations difficult. Occasionally the uvea is sympathetically affected—the symptoms of irido-choroiditis are joined to those of retinitis.

The chief subjective symptoms are mistiness or darkening of the visual field; these are perfectly characteristic. They correspond to the points of exudation in position, more rarely in extent and form. The patients describe them as more or less thick, whitish or grayish, rarely greenish, bluish, &c., mists, or as dark, smoke-colored, brownish, or black spots, as irregular or even interrupted rings, &c., which lie over a certain part of the field of vision and hide the objects in that part. The sense of color is often markedly disturbed inside these spots (*Leber*).

The objects lying behind the darker parts entirely escape the vision of the patient, while those behind the clearer are seen as through a misty veil or smoke. With favorable illumination and suitable position of the object to the light, these brighter spots may often be considerably diminished, and so much cleared up, that the parts behind them appear much more distinctly. If the spots are in the center of the field of vision, as is frequently the case, on account of the preference of exudative neuro-retinitis for the vicinity of the macula lutea, reading and the recognition of small objects become very difficult. The patient must then frequently aid himself by false adjustment of the optic axes, so as to make the images fall on excentric, still sound parts of the retina. But if the center is free, the patient can often read the finest print. Yet general vision is impaired, the visual field appears interrupted in one or more directions, and hence the recognition of large objects is particularly difficult. These obstructions diminish in proportion as the boundaries of the darkened spots are removed from the center. Indeed, spots at some distance from the center are only perceived on careful examination, otherwise they are quite overlooked by the patient. The functional activity of the periphery of the retina usually remains unimpaired, as exudation does not readily occur there, and the nerve-filaments in any existing foci are affected late, if at all. If complete atrophy of the retina and choroid occur, there is also peripheral limitation of the visual field.

A very peculiar appearance is given by the curvature of lines which fall in arcs of the visual field corresponding to the different foci. This is seen rather often in exudative neuro-retinitis, and is particularly noticed at the edges of the interruptions. It is ascribed to differences in the level of the retina at the exudation spot, and to the thereon dependent change of position of the elements of the retina and optic nerve (*Förster*), which are again referred to the collection of morbid products (*Classen*), or to the contraction accompanying the subsequent atrophy of the retina and choroid. (*Knapp.*)

Of course the above-mentioned characteristic disturbances of vision are only witnessed in circumscribed exudation processes, and belong particularly to the later stages of the disease, where the inflammation proper is already over. When the entire retina is affected, and the vitreous also cloudy, the interruptions disappear in the generally thickly-clouded field; frequently vision is even reduced to quantitative perception of light.

Causes.—The etiology almost corresponds with that of diffuse neuro-retinitis. The exudative form is frequently developed along with the first. Where the latter appears alone, constitutional syphilis, either acquired or hereditary (*Hutchinson*), appears to be the cause. The development of posterior scleral staphyloma also plays an important part. In high grades of this, particularly when the patient is advanced in years, exudative retinitis, and the peculiar changes in the fundus caused by it, are often observed. (*Donders.*) Frequently, however, we can not discover a sufficient cause, or in fact any cause. Often not only the origin, but the time of the commencement, of the disease escapes observation.

Some cases of retinitis circumscripta are without doubt caused by hemorrhages into the macula lutea. It is also believed that sympathetic influences (*Graefe*), and even tuberculosis (*Coccius*) may lead to exudative neuro-retinitis.

Course.—In most cases the disease develops with very insignificant, and also very evanescent, symptoms of irritation, and progresses slowly and imperceptibly. If the points of exudation are not near or at the center of the retina, the patient often overlooks the existing disturbance of vision, and sometimes years pass before accident or the gradual advance of the spots of mist over the central part of the field of vision call attention to the defect, and the ophthalmoscopic examination shows old collections of inflammatory material. In other cases, particularly where injuries are the cause, exudative neuro-retinitis suddenly occurs pure or in the above combination, with marked and even alarming symptoms of inflammation. The process rapidly increases to a certain hight, but then again loses its intensity, the symptoms of irritation gradually disappear, the inflammation itself is extinguished; only its results, particularly the characteristic exudation and the partial clouding or darkening of the visual field dependent on it, remain. If the accompanying irido-choroiditis, hyalitis, &c., have not caused permanent injury, vision improves considerably, the darkened parts of the visual field separate, as it were, become smaller, clear up in some places, and spots which were only misty again become clear.

Arrived at this point, the process is arrested. Then months and years often pass without any decided change occurring in the symptoms. Frequently the arrest of the process is complete, no new points of exudation form, and the old atrophy more and more. In other cases the disease relapses, the process starts up again, with or without perceptible cause; besides the old foci, new ones are developed, then the inflammation recedes, to flicker up again after a longer or shorter remission, &c.

These relapses are particularly frequent when the disease has been caused by posterior staphyloma or syphilis, or when it has come on in circumscribed patches, unnoticed and without apparent cause, during youth. In such cases, also, the other eye is usually affected. On the other hand, when injuries were the cause, the inflammation is usually limited to the affected eye.

Results.—When the characteristic exudation is present, we can rarely hope to restore normal vision. In recent cases, proper treatment will, it is true, not unfrequently cause partial or entire resorption. But the affected portions of retina rarely become perfectly normal. The choroid, also, is frequently atrophied, and, by abnormal reflection of light, increases the disturbance of vision caused by the retinal changes. As a result of this, the images of objects in the region of the affected part are at least veiled or blurred. Occasionally, also, they are distorted.

Usually, the resorption is only partial, the remainder of the exudation becomes permanent, and gradually causes atrophy of the affected portions of the choroid and retina. Then the anterior layers of the retina often remain intact, while the posterior, as far as the collections reach, degenerate more and more. In other cases, the atrophy finally affects the whole thickness of the retina. Indeed, within the bounds of the point of exudation, the retina is not unfrequently transformed to a connective-tissue membrane, which, covered by the perforated membrana limitans, is firmly attached to the subjacent atrophied choroid, and, besides heaps of newly-formed pigment, usually contains only a few vessels, which, moreover, are partly atheromatous, or are changed to connective-tissue strings. Fortunately, this process of degeneration is usually very slow. Indeed, these collections often exist for years before the affected portion of the retina entirely loses the sensation of light. There

is good reason to suppose that atrophy of the nervous elements is not a necessary consequence; the changes in the retina may be permanently arrested at any point.

The portions of retina and choroid lying outside of the exudation patches, in simple cases, usually remain quite normal, and preserve their functional activity unimpaired. If the retina is not too much altered at the points of exudation, or if these are excentric, and not very large, the eye may remain moderately serviceable through life, and, under favorable circumstances, it not unfrequently does so. Sometimes, when the affection has run its course, the disturbance of vision is not at all proportionate to the changes in the fundus observable on ophthalmoscopic examination.

If the neuro-retinitis begins in youth, however, and the disturbance of vision is much felt on account of the central position of the affected parts, functional obtuseness occurs in the healthy portions of the retina of the eye that is solely or chiefly affected; because the patient soon learns to suppress the perceptions of the affected eye, so as to see better with the other, and the former is, consequently, thrown out of use. Strabismus not unfrequently occurs under such circumstances. Thus, the portions of retina remaining unaffected, often have their function impaired in the further course of the disease; if the points of exudation are extensive, this impairment may affect the whole fundus. The cause for this seems to be disturbance of nutrition of the entire retina: for, under such circumstances, we often find the chief branches of the retinal vessels much contracted, and less in number, or partially replaced by collateral branches.

Of course, the patient fares worst when the exudative retinitis is, at any stage of its course, accompanied by irido-choroiditis, which can not be quickly suppressed. Then the bad results of this disease concur with those of the neuro-retinitis, and the final result is not unfrequently entire blindness, or even atrophy of the eye-ball; that is, terminations that we rarely have to complain of in *pure* retinitis.

The treatment must always be suited to existing conditions, and corresponds almost exactly with that of diffuse neuro-retinitis. (See chapter on this.) For this disease, also, the inunction treatment during the proper inflammatory stage is the best, in fact the only reliable, remedy. When properly carried out in recent cases, the absorption of masses of exudation, and the clearing up of spots in the visual field, is often indeed very satisfactory. Where the condition has lasted some time, we can rarely expect more than an improvement. If the collections are already much atrophied, and there is, in fact, no product there to be removed by increased absorption, of course this treatment is as ineffectual as any other, and is only suitable when we suspect syphilis as the cause, and wish to prevent relapses. Then it is usually best to confine ourselves to proper care of the eye, and avoidance of the causes for a renewal of inflammation, and to the preservation of the existing vision. If a relapse occurs, it is to be treated just like a commencing disease.

Local blood-letting is of little or no use. The revulsives, especially the application of an issue in the back of the neck, which has recently been brought up again (*Pagenstecher*), are, at all events, superfluous, and had best be avoided.

Authorities.—*Cocoius*, Ueber die Anwendung des Augenspiegels. Leipzig, 1853. S. 110, 132, 134.—*Graefe*, A. f. O. II. 2. S. 258, 282, 291, 294.—*Ed. Jaeger*, Berträge zur path. Anat. des Auges. Wien, 1855, Taf. 5 et seq.—*Liebreich*, Atlas der Ophth. Berlin, 1863, Taf. 4, 5, 6.—*Pagenstecher* und *Sämisch*, kl. Beobachtungen. Wiesbaden, 1861, I. S. 23, II. S. 9.—*Sämisch*, Beiträge zur norm. u. path. Anat. des Auges. Leipzig, 1862. S. 29.—*Förster*, Ophth. Beiträge. Berlin, 1862, S. 1, 22, 31, 99.—*Schweigger*, Vorlesungen über den Gebrauch des Augenspiegels. Berlin, 1864, S. 86

88, 95, 110.—*Classen*, Ueber das Schlussverfahren des Schactes. Rostock, 1863. S. 32. A.
2. S. 155.—*Knapp*, kl. Montabl. 1864. S. 307.—*Secondi*, Clinica oc. di Genova. Riassunto.
1865. S. 42.—*Donders*, Anomalien der Refraction u. Accomm. Wien, 1866. S. 322.—*Hute*
A clinical memoir on certain diseases of the eye, etc., London, 1863, P. 129.—*Virchow*, Die F
Geschwülste II. Berlin, 1867. S. 462.—*Galezowski*, Gaz. des hôpit. 1862. Nro. 5.—*Coc*
apparat. opt. Leipzig, 1868. S. 15.—*Graefe*, A. f. O. XII. 2. S. 171.—*Leber*, ibid. X
104.—*Ed. Jaeger*, Hand-atlas, Figs. 64, 66–69, 92, 94, 96–102, 122–128.—*Knapp*, Arch.
u. Ohrenheilkd. I. S. 22. u. f.—*O. Becker*, kl. Monatbl. 1868. S. 352.—*Nagel*, ibid. S. 4
—*Mauthner*, Lehrb. d. Ophthalmoskopie. S. 431. u. f. 451.—*Heymann*, Ophthalmog
1868. S. 28.—*Landesberg*, A. f. O. XV. 1. S. 220.—*Niemetscheck*, Prager Vierteljahrsch
Bd. S. 41.

Nephritic Retinitis.

Symptoms.—*This disease is characterized by the formation of opaque, punctate, isolated spots in the diffusely cloudy retina, especially round the entrance of the optic nerve, accompanied by numerous hemorrhagic extravasations, great local congestion, and marked diminution of the vision.*

1. The ophthalmoscopic appearance varies according to the time of the examination. At the very commencement of the affection, great congestion is noticed; the optic-nerve entrance and surrounding zone appear reddened by numerous injected small vessels; the veins enlarged and very tortuous, and occasionally lighter and darker spots indicating inequalities of the retinal surface. The arteries, on the contrary, are rarely dilated, but are rather apt to be smaller than normal. Blood extravasations soon occur, which sometimes appear as delicate injections, sometimes as spots, and often collect so as to cover the vessels. To this is soon added an extended diffuse veil-like cloudiness of the retina, which in the vicinity of the optic papilla rapidly thickens at different places, and presents smaller or larger white-gray or milk-white spots, with irregular boundaries, which, as far as they extend, more or less completely envelop the vessels and the fundus of the eye (*Chro. lith. J, K*). Elsewhere, especially in the region of the macula lutea, small gray-white or milky points form, which rapidly increase, form clumps, and often unite by increasing turbidity of their interspaces.

If the process of proliferation still continues, the dusky and reddened papilla and neighboring zone of the retina continue to swell, the grayish or milky spots increase in size and number, spread over the papilla, enveloping it more and more, change their color, become bright whitish-yellow, entirely opaque, glistening like fat, but at the same time apparently retract into the posterior layers of the retina, so that the enveloped vessels and extravasations either partially or wholly advance again and become more or less distinctly visible. Finally, these spots, and after them also the groups of points lying in the vicinity of the macula lutea, coalesce to a ring-shaped, more or less extensive, fatty-looking, yellowish or grayish wall (*Iwanoff*), which is only indistinctly bounded from the swollen and grayish-brown or infiltrated and discolored papilla, but towards the equator usually ends in a zigzag line, whose salient points generally correspond with the larger vessels. This boundary is sometimes quite sharp, sometimes striated in radii, so that the zigzag has a flame-like appearance; sometimes it is indistinct, in places stippled, or has a marbled appearance (*Chro. lith.*, K). The peripheral portions of retina are often entirely normal or but slightly clouded; frequently, however, they have a marked veil-like cloudiness, and are in some places strewed with gray-white points (*Liebreich, Iwanoff*).

The ophthalmoscopic appearances, during the proper inflammatory stage, are not rarely indistinct on account of haziness of the vitreous. The globe also presents, as a rule, no prominent objective symptoms.

Subjectively the affection shows itself by a gradual diminution of vision, occa-

sionally interrupted by temporary arrests or improvements, by a generally irregular cloudiness or darkening of the field of vision, with or without peripheral limitations of it. Complete amaurotic darkening, however, rarely occurs from this form of retinitis alone.

Causes.—The form of inflammation of the retina here described may possibly be developed under the most varying pathogenetic relations. Similar ophthalmoscopic appearances have been observed in diabetes (*Ed. Jaeger, Noyes, Bouchut*), and even in neuro-retinitis descendens consequent upon cerebral affections (*Graefe, H. Schmidt*). As a rule however the form of retinitis in question is dependent upon Bright's disease of the kidneys. It often appears in the early stages of albuminuric nephritis, but it usually makes its appearance in the later stages of the chronic cases, and is frequently recognized only after fatty or coloid (amyloid) degeneration has appeared, or when the kidneys are far advanced in the shrinking process.

Hence we see that nephritic retinitis does not directly depend on the albuminuria. Clinical observation confirms this idea, for numerous cases occur in which there is no albumen in the urine, or if present, its percentage varies without any corresponding influence on the course of the retinitis. Just as little can the anomalous aeration of the blood (*Graefe*) be considered the final cause, for the changes of the blood recognized at the present time are common to all cases of Bright's disease, while neuro-retinitis is not a constant, or even among the most frequent, results. For a time organic disease of the heart and consequent congestion, edema, hemorrhages, &c., were thought to be the immediate cause (*Iman, Traube*), and this the rather, as hypertrophy of the left ventricle, valvular disease, &c., were constant accompaniments of nephritic neuro-retinitis. (*Schweigger.*) But the heart-disease may certainly be absent (*Nagel, Secondi, Horner, Pagenstecher*), and its frequent connection with the form of retinitis in question may be explained by the fact that Bright's disease very commonly leads to heart-disease, and on the other hand, the latter is an important pathogenetic cause of the former. (*Rokitansky.*)

Among the remote causes of nephritic neuro-retinitis belong, of course, every thing that can excite Bright's disease. Occasionally we find them both with marasmus and cachexia as a result of typhus, miasmatic fevers, protracted suppuration, tuberculosis, &c.; but especially as secondary affections after exanthematous diseases, particularly scarlatina, after cholera, pyæmia, after excessive use of spirituous liquors or active diuretics, &c. (*Rokitansky.*) Retinitis and albuminurea are also observed in the later months of pregnancy (*Pagenstecher, Secondi, Galezowski*), and then, as in heart-disease, the nephritis is referable to mechanical obstructions of the circulation in the kidneys. (*Virchow.*)

Course and Results.—Occasionally the development of the retinal trouble is very acute; even in a few days after the commencement of the affection of vision, while this increases, large quantities of inflammatory products have collected in the posterior half of the retina

As a rule, however, the course is slow from the commencement, and frequently interrupted by arrests of progress or even by removal of collections of product already formed. In such cases a long time intervenes before the characteristic fatty-looking prominence has fully formed.

The parts often maintain this state for weeks without much change; at most, further hemorrhages occur. Finally there is regressive metamorphosis, the products are gradually re-absorbed, the vessels that have been enveloped again appear here and there, the prominence becomes partly transparent, loses its bright fatty hue, divides up—in fine, the process approaches its termination.

It is not absolutely necessary that this prominence should form entirely; on the contrary, the process may recede at any stage, and the retina again attain its entire functional activity. Occasionally the process does not go beyond simple congestion

and hemorrhagic extravasations; in other cases an already-formed diffuse cloudiness dissolves without precedent thickening, and if this occurs, the plaque-like exudations disappear without uniting. But even completely-formed and extensive prominences may, under favorable circumstances, recede so that no trace, or only a delicate cloudiness, remains behind, which but slightly interferes with the functional activity of the retina.

The prognosis appears to be proportionately better when the albuminous nephritis is developed as a result of acute exanthemata (*Horner, Höring*), or in the course of pregnancy, and is not far advanced, so that the restitution of the normal functional activity of the kidneys is not difficult. Then the retinal trouble occasionally recedes, while the albuminurea continues for a time. (*Secondi.*)

On the whole, cures are uncommon; usually, extensive haziness with various functional disturbances, and subsequently atrophy of the retina, remain. Occasionally also, detachment of the retina occurs, and this may even come on quite early.

After clearing up of the clouded portions of the retina, or when the characteristic prominence recedes, the spots on the choroid, peculiar to exudative neuro-retinitis, are not unfrequently seen. (*Liebreich.*) They indicate a local exudation of inflammatory product on the outer surface of the retina. Sometimes they have exactly the peculiarities of the circumscribed form, sometimes they are characterized by remarkable brilliancy and bright white color, as well as by want of pigment collections, and by very irregular, ragged borders. Striated figures formed of small angular plaques are relatively quite often found near the macula lutea. (*Chro. lith.*, J.)

Frequently the retinal disease does not reach any termination, as the patient dies of the constitutional affection before the fatty prominence in the retina is fully formed or can retrograde.

Uræmic amaurosis frequently occurs in the course of Bright's disease. This, as the name indicates, is connected with the development of uræmia, and is explained by the influence of a blood pregnant with urea on the parts of the brain concerned. Hence it appears in company with other symptoms of uræmia, especially during attacks of severe headache, dizziness, loss of consciousness, paralysis, convulsions, maniacal excitement, &c. It is further distinguished from disturbance of vision caused by nephritic retinitis and neuritis by its rapid development; it not unfrequently causes complete blindness in a few hours or even minutes, and may, on the other hand, recede just as quickly.

It is, at the same time, to be remarked that uræmia does not always lead to amaurosis; that nephritic retinitis very often completely runs its course without uræmic amaurosis having occurred, and that this is especially apt to appear in the later stages of retinal inflammation; while, on the other hand, uræmic amaurosis without inflammatory affection of the retina is rarely witnessed. It is however worthy of remark, that a greater part of those affected with nephritic inflammation of the retina die of uræmia soon after the development of this local affection, and that occasionally, shortly after uræmic attacks, retinal inflammation occurs.

The Treatment must, of course, be first directed to the original disease. The works on special therapeutics treat of this.

Oculists generally recommend the internal use of acids, and for the eye-disease a derivative treatment, particularly the repeated application of natural or Heurteloup's artificial leeches. Abstraction of blood must be considered as dangerous on account of the already debilitated state of the patient, and is the more so as it is of little benefit. On the other hand, iron may be of advantage under certain circumstances. (*Horner.*) Secale cornutum (*Willebrand*) is inactive. In many cases where the kidney-disease was evidently receding, and the nutrition of the patient

had not suffered much, inunction treatment with the protective bandage was tried with fa able results, the clearing up and removal of the exudation patches going on very rapidly.

Authorities.—*Heymann*, A. f. O. II. 2. S. 137, 146.—*Liebreich*, ibid. V. 2. S. 265, VI. 2 318, Atlas der Ophth. Berlin, 1863. Taf. 10.—*Nagel*, A. f. O. VI. 1. S. 191, et seq.—*Grae* and *Schweigger*, ibid. VI. 2. S. 277, 282, 285.—*Schweigger*, ibid. S. 294, 311, Vorlesungen übe den Gebrauch des Augenspiegels. Berlin, 1864. S. 101.—*Iman*, Nederl. Lancet, 1852. S. 356.— *Rokitansky*, Lehrb. der path. Anat. Wien, 1861. III. S. 325.—*Virchow*, Monatschrift f Geburtskunde and his Archiv. X. S. 170.—*Traube*, Deutsche Klinik 1859. Nro. 7.—*Beckma* Virchow's Archiv. XIII. S. 97.—*A. Wagner*, ibid. XII. S. 218.—*Secondi*, Clinica oc. di Genova Riassunto Torino, 1865. S. 58.—*Horner*, kl. Monatbl. 1868. S. 11.—*Höring*, ibid. S. 215.—*Zehender* ibid. 1866. S. 136.—*Galezowski*, ibid. S. 150.—*Willebrand*, A. f. O. IV. 1. S. 341.—*V. d. Loa* Zesde Jaarlijksch Verslag. Utrecht, 1865, S. 161, et seq.—*Graefe* und *Schweigger*, A. f. O XII. 2. S. 120.—*Pagenstecher* und *Sämisch*, kl. Beobachtungen, Weisbaden, 1861. S. 52; III S. 80.—*Noyes*, Transact. Amer. Ophth. Soc. 1869. S. 71.—*Bouchut*, ibid. S. 72.—*Alexande* kl. Monatbl. 1867. S. 223.—*Iwanoff*, ibid. 1868. S. 423.—*Mooren*, Ophth. Beob. S. 283.— *Mauthner*, Lehrb. d. Ophthscop. S. 362, 366.—*Ed. Jaeger*, Hand-Atlas, Fig. 64.—*H. Schmidt* A. f. O. XV. 3. S. 252, 263, 266.

Detachment of the Retina, Subretinal Effusion.

Pathology.—By detachment of the retina we understand its separation from the choroid, by the interposition of a watery fluid full of protein matter. The detachment is at first always partial, confined to a small portion of the retina, and it often remains so; but it may progress in all directions. It may begin at any part of the retina, but when partial it is generally at the lower half, probably on account of the immediate sinking of the fluid. The border of the detachment sometimes describes a roundish or elongated oval, but is usually entirely irregular, and in the latter case its posterior section extends in a straight or slightly-crooked line, horizontally or obliquely, below the optic papilla.

The interspace between the detachment and the choroid is often small, but frequently projects like a pouch far into the posterior part of the eye. The base of the detachment is therefore sometimes perpendicular, sometimes it only projects gradually. With the progress of the detachment, its posterior border approaches the optic-nerve entrance, which it surrounds gradually from both sides, and finally only the upper inner quadrant of the retina remains in contact with the choroid; even this is sometimes separated, and the retina folds up like an irregular funnel, whose wavy walls are attached on the one hand to the ora serrata, on the other to the borders of the optic-nerve entrance.

In recent detachments of small portions of the retina, the tissue may remain quite transparent; when the detachment has existed longer, and is more extensive, the opacity is generally complete, sometimes regular, again cloudy, spotted, or striated. The detached portion of the retina always appears relaxed and in folds, and moves on rapid motion of the eye-ball—its motion being greater the more extensive the detachment and the further it projects into the eye; for the dislocation of the retina progresses at the expense of the vitreous, of which at least the posterior half, if not more, liquefies and is absorbed in proportion as fluid collects between the retina and choroid, so that the detached portion of the retina has fluid on both sides of it. (*Iwanoff.*)

In very small detachments, although the oscillations occur, they are too slight and of too short duration to be perceived with the naked eye. When large detachments do not move, as occasionally happens, it is probably because their borders are attached to the choroid; hence the fluid is encapsulated, and the part of the retina in question is kept tense. (*Schweigger.*) Then, however, it is usually not a case of hydrops subretinalis, but the retina is displaced by a choroidal tumor, a cysticercus, etc., or by some firm pathological product, which is usually indistinctly seen through the cloudy tissue of the retina stretched over it. But if under such circumstances effusion of watery fluid occurs, separating the retina from the surface of the tumor, the wavy motion may be seen.

In recent cases the subretinal fluid is serous, watery, colorless, slightly yellow or reddish, and, as analysis immediately after tapping showed (*Bowman*), contains much albumen, which occasionally coagulates even during life (*Liebreich*), and clings to the walls of the cavity, as thick floculi or striated masses. In old, and particularly in total, detachments, it often changes its chemico-physiological character, as the protein materials are mixed with various elements from the surrounding membranes.

Then, beside water, the fluid forming the subretinal effusion contains a variable but usually large amount of fibrinous material, which separates in clots on exposure to the air, or boiling coloid masses (*Rudnew*), hematin in solution, which gives the fluid a yellowish, reddish, or, if chemical transformation has occurred, a brown color; new and old blood corpuscles, single or in groups, in various stages of transformation, sometimes in such amount as to give the fluid the appearance of diluted blood; salts in solution, which are frequently precipitated and form actual deposits on the surface of the choroid; pigment granules of various colors, free or in groups, sometimes in cells of considerable size, which are probably newly formed, but possibly may be the metamorphosed remains of the tapetum; newly-formed pigment-cells, and nuclei with granular cells; fat in globules, large drops or crystals, occasionally so abundant that it may be seen by the naked eye as large balls, or as if the entire subretinal mass were changed to a pulpy clump of glittering cholesterine crystals.

The cloudiness of the detached portion of the retina certainly depends on changes of the retinal tissue, although coloring of the subjacent fluid may exercise a modifying influence. This latter can not be the chief cause, for, if we except the frequent distinctness of the protrusion, the darkest portions correspond, not to the summits of the folds, but to the depths of the waves. But if the cloudiness is in the retina itself, it is easy to ascribe it to an inflammation; and this is the more probable, as the anatomical examinations so far made (only in old cases, it is true) have very decidedly shown the characteristic symptoms of proliferation, or of the atrophy dependent on it. (See chapter on this.)

If we bear in mind that the cloudiness is almost always perceptible at the very beginning of the detachment, that is, commences with, if it does not precede, this, we necessarily arrive at the conclusion that subretinal effusion is, to a certain extent, dependent on retinitis, if it is not entirely a product of the inflammation.

From recent investigations we find that detachment of the retina is sometimes combined with circumscribed œdema of the retina, and is occasionally confounded with it. This œdema sometimes appears in the form of large cysts, which, proceeding from the external layers of the retina, cause this membrane to bulge forward into the posterior chamber like a vesicle, and ophthalmoscopically as well as in anatomical preparations may produce the impression of a subretinal effusion (*Iwanoff*).

For a long time extravasations of blood between retina and choroid were regarded as the real cause of detachment of the retina, and this view has been obstinately maintained in the face of a more reasonable hypothesis (*Graefe*). But it has now been entirely abandoned, since the symptoms as well as the actual appearance in operative division of the bulging portion of the retina and in the drawing off of the effusion have shown very forcibly the error of this supposition. Still it should not be denied that sometimes enormous subretinal extravasations of blood occur, which detach the retina like a sack or even separate it all round from the choroid (*Stavenhagen*). Such hemorrhagic detachments are found especially after injuries of the eye and partial evacuation of the intra-ocular media, and exceptionally in progressive staphyloma posticum.

Symptoms.—*a.* Often, especially when the pupil is dilated, the detached portion of retina may be distinctly seen with the naked eye, without the aid of the ophthalmoscope. This is particularly the case when the retina is clouded by inflammation and displaced forward within the focus of the dioptric apparatus. If, however, it is but slightly separated from the choroid and remains quite transparent, even when the pupil is dilated, the fundus appears but slightly clouded. Retinal detachments increase the brilliancy of the eye.

b. If the fundus be illuminated with the mirror, it is seen that at one spot, usually below, the yellowish-red appearance is suddenly changed into a grayish or greenish color with dark shadowing (Fig. N), and upon this are frequently seen one

or more vessels. The change is either direct or marked by a dark line of shadow. By more careful examination the detached portion of the retina then sometimes appears as a tense, smooth vesicle. As a rule it appears as a loose, folded surface, elevated above the surrounding surface, which trembles at every movement of the eye or sinks and rises, in more extensive detachments generally forms one or more elevations, which are joined at their bases, and between their summits appear portions of normal fundus (Fig. O). If the detached portion of the retina is still very transparent and only slightly elevated above the choroid, it easily escapes notice, only the bending and oscillation of the vessels in its vicinity are very marked. The fundus appears otherwise but little changed, or at most somewhat duller or slightly cloudy. Here and there however fine folds are often observed as delicate, bright, or whitish, movable lines, which are indistinct towards one side, sharply defined towards the other, and sometimes surrounded by a dark border.

If such a diaphanous vesicle projects more into the vitreous, the even red of the choroid and the *vasa vorticosæ* are only seen when the light from the mirror falls perpendicularly, and the subretinal fluid is more strongly illuminated; elsewhere the cavity remains dark, and the detached portion of retina appears between the brighter folds as a blue-gray or dirty-green. Often, however, the opacity is much thicker; on ophthalmoscopic examination the sac is distinctly seen, appears dirty yellowish-white, with deeper shadows in some places, or quite opaque, pale grayish-yellow, with brighter and darker parts.

Frequently the cloudiness extends beyond the bounds of the detachment and disappears gradually in the otherwise normal fundus, or totally envelops this in varying thickness. Where the detachment is below, we often find a portion of the retina to the side or above clouded, and it is then probable that the detachment was originally developed there, and that the fluid has subsequently sunk down. Not unfrequently, also, the optic-nerve entrance lies in the opacity, and then shows the signs of diffuse inflammation, while otherwise, except by slight redness, it evinces no changes, or in old cases it may have the signs of atrophy. Often, also, the character of diffuse neuro-retinitis appears in the entire retina, the papilla included.

In partial detachments, even at the first glance, the posterior border is seen as a dark, almost black line, blurred on one side, which renders still more evident the contrast between the detached portion and the surrounding parts of the fundus. This line is particularly sharp and dark when the base of the detachment is perpendicular or overhanging, and where the sac is very movable it may change in length, direction, and color, or even disappear temporarily, according to the position of the part of the wall in question, at any given time. It is the shade cast by the part of the base of the detachment not illuminated by the mirror. Where the base slopes gradually, this dark boundary-line is absent, and its place is only indicated by the curvature of the vessels, and perhaps by some signs in the cloudy retinal tissue.

Moreover, the papilla and yellow spot are not unfrequently permanently or temporarily hidden by the overhanging, as well as by the movements, of the sac. If this obscuration of the papilla is only partial, its shape varies continually with every motion of the detached retina; sometimes it appears in its natural circular shape, sometimes is indented on one side, and this change occasionally gives the deceptive impression that the papilla itself moves, as if it sometimes elongated, sometimes contracted.

In total detachments all these peculiarities are wanting, the entire discolored fundus waves hither and thither. If the papilla is recognized at all, it is only occasionally for a moment by the peculiar arrangement of the central vessels.

The *retinal vessels* are distinctly designated on the wavy surface. They usually appear much darker than normal, in some places even black, and this is particularly true when portions running over dark parts of the detachment are observed. Over thick, cloudy, opaque spots, or when the detached retina is more transparent, and the reflected light falls perpendicularly, thus brightly illuminating the space behind the detachment, they appear of a clear blood-red, showing a certain amount of integrity. (*Liebreich.*) Where the dioptric media are clear, the vessels are distinctly seen; rarely they appear powdered over or interrupted by cloudiness of the inner layer of retina. In advanced atrophy of the detached portion they are invisible in some places, or appear only as dense white or black granular-branched strings. Of course they follow the sections of retina containing them. Hence in the detachment they appear much curved, for, ascending an eminence, they seem arched anteriorly; then sinking back into a furrow, they disappear to appear at another spot, again to curve outward, etc. When the eye moves, they actually dance around the fundus.

If pigment collections, extravasations, cholesterine crystals, &c., cover the detached retina, it gives a very peculiar appearance. There is a motion over and through each other of the most varied objects, just as in a rotated kaleidoscope. But if the globe becomes motionless the excursions lessen, and the individual objects return to their former relative positions. These diseased products attached to the retina are thus distinguished from similar masses suspended in a fluid vitreous. These latter may also oscillate, but finally always sink to the floor without preserving a certain relative position.

Of course all these appearances presuppose the transparency of the dioptric media. But this requirement is not often fulfilled; on the contrary, opacities of the vitreous usually accompany subretinal effusion, and even precede it in most cases. They are occasionally partial, and appear like delicate clouds over the detachment. More frequently, however, they extend over a large part of the fundus. Usually, also, they tremble or even wave about on motion of the eye; they are moreover not permanent, for they sometimes increase in size and become more dense, at others contract and become clearer, or even totally disappear for a time. Before, as well as during, relapses of the inflammatory process, they usually increase in extent and density, and hence they should not be neglected in forming a prognosis.

Frequently, also, a view of the interior of the eye is hindered by cataract, especially by polar and capsular, more rarely by simple lenticular, cataract. The polar form depends mostly on the same causes as the detachment; the capsular cataract usually results from the irido-choroiditis which comes on subsequently. The lenticular cataract is probably usually the result of the disturbances of nutrition showing themselves by atrophy of the eye-ball.

c. The subjective symptoms are not less marked, provided that the functional power of the retina has not yet been affected by inflammation or atrophy; then the detachment is indicated in the field of vision as a bright but vacant spot. This is however, often reddish or brownish when there are extravasations of blood. When the patient looks at the sky or a distant bright wall, this spot assumes the appearance of a cloud with irregular contours. The detached retina rarely retains its functions so far as to permit the recognition of large objects. (*Pagenstecher.*) The interruption caused in the visual field corresponds in position to the detachment. Hence in recent cases it is *usually*, and in old cases *almost constantly*, in the upper half of the field of vision, so that simply from this localization of the blind spot we may with some probability infer the existence of retinal detachment. (*Graefe.*) The extent of the interruption, on the contrary, is often greater than correspond

with the base of the space filled with fluid, which is explained by the fact that the material changes of the retinal tissue extend beyond the limits of the detachment.

The clearness of perception in the rest of the retina may still be normal, and if the parts about the macula lutea are not involved in the detachment, a certain amount of sharpness of vision may still remain. More frequently, however, and in old cases, almost always the sharpness of vision is considerably diminished, and, as the detachment usually extends up to the horizontal meridian, or beyond it, the fixation is usually excentric. In many cases the function is even reduced to quantitative perception of light, or even this is wanting. This does not, however, depend entirely on the grade and extent of the detachment. A certain amount of sensitiveness to light has been observed in total detachments. It is remarkable that the impressions are then projected outwardly in the direction of the axis of vision. (*Graefe.*)

Where the retina has preserved a high grade of functional activity in some places, the patients often complain of distorted or colored vision. All over the field of vision, or only on the borders of the interruption, objects seem to have colored outlines, to be curved, bent, distorted, or partly hidden. They often partially disappear, rise again, and wind about in tortuous or zigzag lines, when the eye moves.

This shows a change of position of a part of the retinal elements which receive and localize the impressions of light. Hence, when the eye is at rest, a close correspondence of the apparent distortions of objects with the place and direction of the detachment may often be observed. (*Classen.*)

The colored border and wavy motion of objects are characteristic of the metamorphopsia dependent on retinal detachments. (*Knapp.*)

At the same time a certain state of excitability of the visual organ appears in the very commencement of the disease. The patient is much annoyed by the subjective appearance of colored or white balls, drops, twinkling stars, fiery wheels, shooting rockets, &c., which often surround the field of vision, and appear particularly after active movement or excitement of the circulation, &c.

Causes.—The detachment of the retina, like that of the vitreous humor, with which it is pathogenetically very closely connected, is either secondary and to be then referred to the shrinking of the vitreous, which has become adherent to the retina and has undergone tendinous degeneration; or it results from the pressure of a fluid inflammatory product which has been poured out between the retina and choroid, and it may then be described to a certain extent as primary. We have here to do solely with the latter, since the former is no subject for clinical treatment and has already been mentioned.

The primary detachment of the retina is doubtless favored in a high degree by ectasiæ of the sclera and by diminution of the intra-ocular media. It occurs in the majority of cases in eyes affected with staphyloma posticum, particularly of a rapidly progressive character, and here the way to it seems to have been opened by the detachment of the vitreous, usually existing with it. It is also frequently observed after perforations of the sclera, accidental and operative as well as ulcerative, if they are accompanied by extensive loss of vitreous. We must not however here regard merely an increased serous transudation as the cause of the detachment, as in detachments of the vitreous, since in such cases the separation of the retina is always preceded by a very marked opacity of the vitreous and even of the retinal tissue, which is without doubt of inflammatory origin.

This circumstance seems to have led to the belief that every detachment of the retina without distinction is owing to the traction of the inflammatory thickened and contracting vitreous. This view is however certainly gainsayed by the change of position of the primary subretinal effusion by sinking and by its curability.

Moreover, detachment of the retina has been observed not very uncommonly in eyes of perfectly normal structure and previously of apparently perfectly healthy appearance. It is also a not very unusual consequence of the most various forms of neuro-retinitis, especially of the exudative variety.

Abscesses (*Graefe, Berlin*) or tumors (*Hirschberg*) of the orbit have exceptionally given rise to the inflammatory process leading to detachment of the retina. The subretinal effusion however is often developed in consequence of secondary choroidal formations.

If under these conditions a large quantity of fluid has been poured out between the tumor and the retina, the detachment appears to depend simply upon pure inflammation, and the correct diagnosis is rendered very difficult. Still we often find a foothold in the very marked increase of the intra-ocular tension, with narrowing of the anterior chamber, which has lasted in spite of the long continuance of internal inflammation and very extensive detachment; in the extinction of the other etiological conditions of detachment of the retina (*Graefe*); in the often extremely rapid extension of the disease over the whole retina (*Alf. Graefe*); in the unusual position of the sac, and in the somewhat marked dilatation of the episcleral vessels in the vicinity.

Course and Results.—Subretinal effusion is often developed very gradually under very obscure symptoms, so that in patients of slight intelligence it remains for a long time entirely unobserved. Usually the delicate veiling and indistinctness dependent upon opacities of the vitreous, or the distorted and colored appearance of eccentrically situated objects first attracts attention; but the defect of the visual field only appears after careful examination, while the detachment is as yet scarcely indicated, and is only recognizable by careful manipulation of the ophthalmoscope. Weeks then often pass before the affection appears sharply defined objectively and subjectively. On the other hand, we sometimes meet with very rapidly developed, enormous subretinal exudations, especially after wounds with loss of vitreous, or the sudden growth of a staphyloma posticum.

If the detachment was not originally in the lower half of the retina, the effusion changes its place in the course of weeks or months; part of the fluid sinks downward, causing a secondary detachment, while the rest is absorbed. The formerly detached portion then becomes adherent to the choroid. It may re-acquire its normal appearance, and possibly, also, its full functional activity. But it usually remains more or less cloudy, and gives indistinct images; indeed, the *interruption* often continues, but it is usually less extensive. If the primary detachment was very near the yellow spot, or this was only hidden by the overhanging sac, without participating in the disease, vision may be very decidedly improved by the diminution of the fluid, and the restoration of functional activity to the retina, which becomes again attached. For as the effusion seeks the deepest part of the globe which corresponds to the equator, that is, to a very eccentric section of the retina, the secondary interruption falls in a part distant from the center of the visual field and in its upper half, and is easily overlooked, or, like the "blind spot" (*Mariotte's*), filled out by the judgment; and this happens the more readily as it is smaller than the primary interruption was.

But retinal detachments at any place, whether occurring there primarily or by

sinking, may disappear by resorption of the fluid. Thus, possibly, a permanent and true cure may result. Unfortunately, subretinal effusion does not often take this course, or does not follow it to the end. The above-indicated conditions are repeated. Frequently the detached portion is re-adjusted, but its tissue does not clear up, or the functional activity does not return, as the nervous elements have been seriously affected by the original disease.

Sometimes, also, the fluid leaves coagula, which attach the retina to the choroid, and are seen as indistinct cloudy striæ and laminæ, with some rupture of the tapetum. Exceptionally the adjustment of the sac is imperfect, but still it re-acquires a certain amount of qualitative sensitiveness to light (*Pagenstecher*).

Such an incomplete cure, and still more rarely a true one, can only be looked for in recent cases, or at least in those not yet very old, and where the detachment is not extensive. If such results have been observed in extensive or even total detachments, or after they have existed for months, they are rare exceptions, and can not influence the prognosis. Great cloudiness and excessive limitation of vision are unfavorable symptoms, for they lead us to suspect deep material change of tissue. The prognosis is most influenced, and is even governed by the cause. Indeed, experience teaches that, under otherwise favorable circumstances, those detachments recede most readily which have been developed in normal eyes as a result of injuries, with slight solution of continuity of the sclera, or none at all, as a result of disturbance of circulation, but above all, as a result of injuries which act temporarily, that is, in cases where the original cause quickly disappeared, and the state of the affected part allowed a complete removal of the disturbance of nutrition. Where the subretinal effusion forms on an already diseased base, perhaps it is only one symptom of a commencing or already progressing atrophy of the eye; or where the cause continues to act, as is usually the case in staphylomatous disease of the sclera and choroid, there is no hope, although even here temporary improvements and arrests of progress are among the possibilities.

Sometimes it comes to a permanent stand-still, or incomplete cure, in consequence of the spontaneous rupture of the detached portion of retina. The unhindered entrance of the subretinal fluid into the vitreous humor diminishes or does away with the tearing and tension to which the lower portions of the detached retina are exposed from the side of the watery exudation which is confined in tense vesicles, or shakes about in loose sacs. By these means, however, not only a source of irritation, but also a direct mechanical factor for the increase of the detached portion is done away with.

When the effusion is very extensive the favorable effect of the rupture is but slight, for there still exists in these cases the danger of a tearing of the lower part, since the detached portions of retina, by reason of their own weight, are subject to excursive movements whenever the eyeball changes its position rapidly. On the contrary, when the detachment is small or of moderate size, their range of motion is slight or inconsiderable, and the effect is often very marked. The sac collapses, its walls meet the choroid and become gradually adherent to it, and not uncommonly the new union becomes complete. Then only a small opening with irregular borders remains at the point of perforation, the edges of the wound having somewhat retracted by folding and partially rolling in upon themselves. They thus form a sort of wall, which appears bright white or yellow, by reason of the opacity of the retina and exuded adhesive matter, and contrasts strongly with the normal choroid, or with the choroid spotted by reason of destruction of the tapetum, which appears plainly in the opening (*Liebreich*).

When the treatment has been defective or entirely neglected, the affection steadily

increases in the majority of cases, and the detachment extends, constantly accompanied by repeated returns of the inflammatory process, or the opacity of the retina and papilla increases without any increase in the extension of the effusion, and the functional power of the eye grows less and less until it is finally entirely destroyed. Usually, however, symptoms sooner or later appear, which point to choroiditis or irido-choroiditis. The result is then decided—the eyeball becomes softer, and phthisis bulbi is unavoidable.

Frequently the loss of one eye does not end the evil; the second is sooner or later affected. Retinal detachment and finally atrophy occur in it also. In normally-formed eyes, and where the effusion is developed as a direct result of external injury, this most unfortunate of all terminations is, it is true, not to be dreaded. But where myopia and especially progressive posterior scleroidal staphyloma cause the process, as is generally the case, the second eye is, as a rule, affected, the cause acting almost always in both eyes.

Later in the progress of the disease, after atrophy has set in, intense photopsia sometimes appears, which becomes so annoying to the patient, that in some cases it has been thought advisable to divide the optic nerve (*Graefe*). Unfortunately this procedure has not proved of much value, for the phosphenes have again appeared shortly after the operation, and even iridochoroiditis has been observed to follow (*Landesberg*).

The Treatment is to be directed to the prevention of irritation that can maintain and increase the inflammatory process to the greatest possible limitation of the excursive movements of the eyeball, which foster, in a mechanical manner, the detachment, and to powerful incitation of absorption. Extensive experience teaches us that in simple detachments of the retina, and in those combined with staphyloma posticum, the procedure recommended for diffuse neuro-retinitis seems to offer the best results—*i. e.*, the mercurial inunction in connection with the strictest care of the eyes and the systematic use of the binocular protective bandage. In recent cases it has rendered exceedingly satisfactory results, and even in old cases and of great extent favorable results have sometimes been very unexpectedly obtained.

Recently it has been recommended to pierce the sclera, at the point where the retina is detached, with a fine knife, and draw off the subretinal fluid (*Sichel*), then to apply a protective bandage and treat antiphlogistically, as after other eye-operations. If necessary, the operation should be repeated once or twice. Its success has not been proved (*Graefe*, *Secondi*), although in some cases temporary improvement was obtained. Hence this operation, which is called "*ophthalmocenthese*," had better be avoided.

The favorable influence exercised by spontaneous rupture of the detached portion of retina in some cases upon the further course of the affection, has suggested the idea of an operative division of the sac (*Graefe*), and some successes obtained by this method have made it rather popular. Still we gain much less by it (*Pagenstecher*, *Hasner*, *Landesberg*) than by pharmaceutic treatment with an appropriate regimen; it is often entirely unsuccessful, and has not unfrequently induced or at least hastened the atrophy of the eye by inciting a degenerative iridochoroiditis.

That we may obtain a better view into the eye, the operation should always be performed with the pupil widely dilated, and the patient sitting up. The instrument to be used is a fine sickle-shaped needle, or, still better, a delicate double-edged Dalrymple "stop-needle," such as is used for discision of cataract by keratonyxis. The head, eyelids, and globe being securely held, the needle is to be passed perpendicularly through the sclera about four or five lines behind the edge of the cornea.

advanced about eight lines into the vitreous, and then turned to the detachment, to divide the latter by slight strokes (*Graefe*). At the same time we should avoid wounding the larger retinal vessels or the choroid, which, from the continual giving way of the sac, will require all the care of the operator.

As experience teaches that such sharp linear solutions of continuity readily adhere again, it has been recently recommended to tear the detached portion instead of simply puncturing. For this purpose, two needles are passed through the sclera at suitable distances from each other; then approaching their points through the vitreous at the surface of the sac, they are made to tear the latter sufficiently by making lever-like movements with them (*Bowman*).

It has also been attempted to combine tapping the subretinal fluid with division of the detachment. For this purpose a trocar needle is used, which is usually introduced through the sclera between the superior and external recti muscles, about four or five lines behind the border of the cornea, and then passed through the vitreous into the sac. The fluid is allowed to escape, and the opening in the retina is enlarged (*Wecker*).

The after-treatment corresponds with that of other operations on the globe. Keeping in bed, antiphlogistic regimen, and particularly the continuous use of a protective bandage over both eyes for several days, are the chief points. Vitreous opacities of an inflammatory character readily occur; these, however, soon disappear. The operation is not usually followed by great reaction.

Authorities.—*Coccius*, Ueber die Anwendung des Augenspiegels. Leipzig, 1853. S. 125, 128. —*Bowman*, Ophth. hosp. reports, VI. 1864. May. P. 134.—*Schweigger*, A. f. O. VI. 2. S. 324, 329; Vorlesungen über den Gebrauch des Augenspiegels. Berlin, 1863. S. 118.—*Stellwag*, Ophth. II. S. 100; Wiener med. Wochenschrift, 1864. Nro. 10.—*H. Müller*, A. f. O. IV. I. S. 369 et seq.—*Klebs*, ibid. XI. 2. S. 242, 249.—*Graefe*, ibid. I. 1. S. 358, 362, 369, II. 1. S. 222, II. 2. S. 260 et seq., III. 2. S. 391 et seq., IV. 2. S. 235, 238, IX. 2. S. 85, 88, 90; klin. Monatbl. 1863. S. 49, 57, 60, 1865. S. 137.—*Donders*, A. f. O. I. 2. S. 113, Anomalien der Refrac. und Accom. Wien, 1866. S. 335.—*Liebreich*, A. f. O. V. 2. S. 251, 256, 258, Atlas der Ophthalmoscopie, Berlin, 1863. Taf. 7.—*Secondi*, Clinica oc. di Genova. Riassunto, Torino, 1865. S. 61, 134.—*Pagenstecher* and *Sämisch*, klin. Beobacht. Wiesbaden, 1861. I. S. 50, II. S. 23.—*Tetzer*, Wiener med. Jahrbücher, 1864. S. 165.—*Kittel*, Wiener allg. med. Zeitschrift. 1860. Nro. 22, 23.—*Niemetschek*, Wiener Medicinalhalle, 1861. Nro. 47.—*Classen*, A. f. O. X. 2. S. 155, 160.—*Knapp*, kl. Monatbl. 1864. S. 307.—*Alf. Graefe*, ibid. 1863. S. 233.—*Berlin*, ibid. 1866. S. 77. —*Sämisch*, ibid. S. 111, 115.—*Steffan*, ibid. S. 75.—*Wecker*, ibid. 1865. S. 117.—*Hirschman*, ibid. 1866. S. 229, 238.—*Zehender*, ibid. S. 239.—*Sichel*, Clinique europ. 1859. Nro. 29.—*Rydel*, Wien. med. Jahrb. 1866. 4. S. 40, 45.

Stellwag, Der intraoculare Druck. 1868. S. 55.—*Graefe*, A. f. O. XIV. 2. S. 116; kl. Monatbl. 1868. S. 301; Congres ophth. Paris. 1868. S. 59.—*Pagenstecher* und *Sämisch*, klin. Beobacht. Wiesbaden. III. S. 49, 54, 55.—*Niemetschek*, Vierteljahrschr. 96. Bd. S. 38.—*Alf. Graefe*, kl. Monatbl. 1869. S. 166.—*Berlin*, A. f. O. XIII. 2. S. 286; XIV. 2. S. 290, 306, 317.—*Sämisch*, kl. Monatbl. 1867. S. 31.—*Rudnew*, Virchow's Jahresber. 1868. II. S. 498.—*Berthold*, A. f. O. XV. 1. S. 180.—*Leber*, ibid. XIV. 2. S. 226.—*Lubinski*, ibid. XIII. 2. S. 379.—*Mauthner*, Lehrb. der Ophthoscop. S. 388.—*Ed. Jaeger*, Handatlas. Taf. XVIII.—*Stavenhagen*, kl. Beob. 1868. S. 79.—*Gouvea*, A. f. O. XV. 1. S. 257.—*Mooren*, Ophth. Beiträge. S. 155, 318; Ueber symp. Ophth. S. 41.—*Arcoleo*, Conference clin. 1869. S. 9.—*Landesberg*, A. f. O. XV. 1. S. 194, 201, 202.—*Hasner*, Prag. Vierteljahrschrift, 93. Bd. Misc. S. 75.—*Iwanoff*, A. f. O. XV. 2. S. 88, 95; kl. Monatsbl. 1868. S. 297.—*Hirschberg*, ibid. 1868. S. 153-155; 1869. S. 79.—*Dohmen*, ibid. 1867. S. 60.

Atrophy of the Optic Nerve and Retina.

Pathology.—A distinction is usually made between pure, nervous, or pellucid and cloudy atrophy.

Pure, or better, *gray* or gelatinous, atrophy is always characterized originally by increase of the connective tissue. This swells from proliferation and the deposit of a gray, glutinous mass, which contains a large number of delicate, clear, nucleated cells in variable, often great, numbers, and becomes gelatinously translucent. The nervous elements appear separated, often broken up, and finally separate into various forms, but usually into spherical smooth masses, which partly undergo fatty disintegration, change to non-nucleated fat granular masses, but partly sclerose, and become coloid or amyloid bodies. Sometimes the proliferation of the neurilemma, sometimes the fatty degeneration and sclerosis of the medulla, preponderate. Finally the connective-tissue framework atrophies to a thick gray, vitreous, stiff mass, which falls into uneven laminæ on pressure, or to a hard, opaque, filamentary callosity, which contains in it the remains of inflammatory cell-proliferation, and fatty or sclerosed medullary substance. (*Rokitansky.*)

In *cloudy* atrophy the nervous elements conduct themselves in the same way, if they have not already become fatty during the inflammation; the difference lies chiefly in the prominence of the connective-tissue new formation; the process represents a degenerative hypertrophy of the connective tissue, and retains this character subsequently, even after atrophy has occurred.

1. In either form the nerve-trunk is finally reduced to a hard tendinous cord, in which the nerve-filaments, and often also most of the vessels, are destroyed. As the outer sheath of the orbital portion does not contract proportionately, it no longer fits the trunk, but lies loose and in folds around it, like a half-filled tube. The connection between the two is kept up by a delicate, relaxed, wide-meshed network of connective tissue, which is probably surrounded by a variable amount of serous fluid.

In excessive atrophy as a result of progressive shrinkage, even the base of the interval between the two nerve-sheaths is removed toward the level of the choroid, and on account of the diminution of the anterior end of the nerve, the interval widens, so that the anterior end of the interspace between the sheaths forms a broad ring-shaped sinus, which lies within the posterior scleral opening behind the lamina cribrosa.

In sections of the atrophied nerve-trunk, parallel to the nerve-axis and lying near each other, we may still recognize striæ of the formerly existing nerve-bundles and their neurilemma; but from the increase of the latter, the former are pressed more apart than normally. Instead of nerve-filaments we find a brownish-yellow translucent substance, formed into strings by the sheath, which consists chiefly of a molecular organic base, coloid, amyloid masses, and shrunken nucleated formations. At the same time we often meet groups of pigment free or inclosed in cells, which are caused by hemorrahagic extravasations or new formations, obliterated, often chalky vessels, cholesterine, and chalky masses. Sometimes the chalk is in excess in some places and collects into larger masses, which appear encased in the atrophied medulla of the nerve or papilla. (*Graefe.*) Exceptionally, also, partial ossification of the atrophied connective tissue may occur in some places.

2. In the optic papilla and in the retina, the two forms of atrophy are more distinct anatomically than symptomatically.

Pure or gray atrophy usually limits itself to the head and actual expansion of the nerve, hence to the filament and ganglion layers of the retina (*H. Müller*), and on the contrary, leaves undisturbed the mosaic layers of the latter as well as the tapetum and choroid. The destruction of the nervous elements and the atrophy of the connective-tissue framework necessarily cause a decrease in volume, which is especially perceptible in the optic papilla. For as the *cauda equina* of the optic nerve is reduced to a thin layer of obsolete connective tissue, which contains only a few coloid bodies and remains of nuclei, the papilla flattens, sinks in, and appears excavated. The deepest part of the excavation, which usually corresponds to the porta vasorum, does not often extend behind the posterior choroidal boundary. (*H. Müller.*) But such cases do occur; for the membrana cribrosa readily participates in the proliferation of the neurilemma. It is then relaxed like the latter, and naturally loses its power of resistance. If the diminution of resisting power reaches a certain point, even the normal intraocular pressure suffices to make the membrane give way; it, with the obsolete stratum lying on it, recedes; the result is a deep, sloping excavation, or exceptionally one with steep edges, such as constantly occurs in glaucoma.

The assertion that such excavations are exclusively found in glaucomatous affections, and are pathognomonic of this disease (*Graefe*), is disproved by actual observation. (*Mauthner.*)

A large portion of the numerous small vessels of the papilla and retina is entirely destroyed, and this is one cause of the peculiar paleness presented by the papilla affected with gray atrophy. The adventitious tissue on the trunks and larger branches of the central vessels often thickens decidedly, from participation of the framework in the original proliferation. As a result of the shrinking, the caliber often diminishes, and occasionally even complete obliteration of some of the chief branches occurs in advanced atrophy.

Cloudy atrophy usually, but not always, extends through all the layers of the retina, and the tapetum and uvea also generally sympathize to a marked extent; the retinal atrophy is only one symptom of atrophy affecting the entire globe. The excavation of the papilla is less distinct, even when, as often happens, the membrana cribrosa is pressed backward, for the cavity seems filled up by the increase of the connective tissue.

The anatomical characteristics of cloudy atrophy are most marked in complete retinal detachments.

For after the termination of the inflammatory process of tissue-development, the retina, folded into a funnel or spindle shape, appears discolored from extensive fatty contents of a dirty yellow-gray color, spotted with numerous small extravasations of blood. The framework filaments usually then exist, but only at intervals, in a distinct hypertrophied condition; they have mostly been destroyed in the proliferation, and together with the *gray* connective tissue are replaced by an indistinctly filamentary or perfect connective-tissue stroma, in which lie numerous oval or spindle-shaped nuclei, partly fatty or sclerosed, or even actual connective tissue corpuscles. When fully developed, the stroma usually shows an areolar stamp; in the intergranular layers, however, a radiated formation of bundle-shaped filaments running perpendicular to the surface is seen. In the neighborhood of the optic-nerve entrance the connective tissue often collects in long and thick twigged bundles, which spread out from the membrana cribrosa and lose themselves in the areolar tissue. This neoplastic connective tissue presses in every where between the other elements and winds around them; but, on the other hand, it continues through the limitans.

which has become perforate, into the degenerated vitreous, and unites the retina with this. What remains of the internal limiting membrane often appears thickened and cloudy, as a result of deposition of molecular detritus on its posterior surface. Not unfrequently these depositions are figured in various ways, and interwoven with remains of atrophied vessels. In the beginning, especially in the anterior zone, a large part of the nervous elements of the retina are still observable; nevertheless, they almost always show every where the character of advanced fatty degeneration and sclerosis. This is particularly true of nerve-fibres and ganglion-cells. The bacillar layer usually suffers quite early, its elements appear partly discolored, swelled, and clouded with fat. The granules, on the contrary, hold out longer, and then usually betray their participation in the disease by decided fatty brilliancy. Near to and between the nervous elements, strewed in the connective-tissue stroma, we find quantities of coloid bodies, free fat granules and fat globules, which latter are beginning to be destroyed, or have even already changed to cholesterine, whose crystals lie around in groups. Besides this, old and recent extravasations of blood are every where seen, but rarely large amounts of neoplastic pigment. The smaller vessels are usually destroyed or degenerated, and even of the trunks, only part are pervious. Their walls are mostly thickened, changed to loose connective tissue, which is united with the areolar stroma and contains numerous cells, partly fatty or sclerosed. Besides this, it is usually strewed with fat granules, pigment, and chalky salts, and with coloid disc-like pendants. In many cases the degenerated vessels traverse leaf-like connective-tissue new formations, whence they acquire the appearance of winged leaf-stems, or are beset with papillary outgrowths. Not unfrequently the vessels are entirely obliterated in spots, changed to solid connective-tissue strings, or filled with necrotic blood-cells or with coloid masses. Occasionally some are atheromatously degenerated, and then present themselves to the naked eye as twigged, chalky, white, hard, brittle strings. (*Wedl, H. Müller.*)

In the subsequent course the nervous elements are gradually destroyed by progressive fatty degeneration and sclerosis, so that finally only atrophied granules in variable amount are found; the fat granules are destroyed, in the same way the extravasations of blood, and even the coloid bodies, after precedent granulation, become scarcer. Fatty degeneration and resorption also occur in the connective-tissue stroma and its cellular elements; it diminishes decidedly in mass, and finally atrophies partially or entirely to an indistinct fibrous or indifferent hard, tough tissue, which is traversed by a few thick tendinous cords and degenerated vessels, and contains only a slight amount of free fat, granular pigment, atrophied cells and remains of granules, and here and there coloid bodies, and is also attached to the degenerated vitreous. Exceptionally small bony plates appear in it; indeed, as far as the degenerated retina is in contact with the bony plate covering the choroid, it also becomes bony.

Where the retina has remained attached to the choroid the signs of degeneration are usually less. As a result of inflammations with large morbid product, especially of the nephritic form, the posterior portions of the retina and the tissue of the papilla sometimes become denser, opaque, and dull, colored grayish-yellow or white. In some cases we may, even with the naked eye, see filamentary striae in this thickened portion, radiating from the papilla into the retina, and with their ragged, fringed ends extending beyond the opaque spot. Occasionally, also, we meet hard, white, variously-figured cicatritial masses of tendinous lustre, which extend clear through the retina; but these are exceptions. In much the greater number of cases, especially after simple diffuse retinal inflammations, degenerative atrophy shows itself only by some increase of the thickness, by a very delicate and scarcely noticeable gelatinous or whitish veil-like cloudiness, which is somewhat thicker, and sometimes also slightly striated about the optic-nerve entrance and its immediate vicinity, and by partial degeneration of the vessels.

In low grades of the atrophy we may often still distinguish all the layers of the retina with their peculiar nervous and connective-tissue arrangements, although the individual parts are already variously changed in the manner above described, and are partly replaced by coloid masses and fatty granules. But as the atrophy progresses the layer arrangement is lost.

According to the variety of the preceding inflammation, sometimes the inner, at other times the outer, layers of the retina are deteriorated into an indistinctly-striated tissue clouded by molecular masses; or else the entire retina has changed to a homogeneous or slightly-striated thin but tough and hard membrane, in which, of the former constituents, only atrophied cell-like formations and (about the optic-nerve entrance) atrophied vessels and bundles of connective tissue remain.

Very often collections of pigment-cells and granules appear in the degenerated tissue of the atrophied retina which lies on the choroid. Usually there are only a few scattered shoots, heaps, or clump-like masses which lie along the vessels or on the border of the optic papilla. In other cases the pigment is confined principally to the anterior and middle zones of the retina, and then appears in very small irregularly notched, elongated heaps, not unlike bone-corpuscles, whose long axis is generally directed toward the posterior part of the retina. And lastly, large amounts of neoplastic pigment occur, especially in the posterior half of the retina, and form large and small clumps that are irregularly situated and unite to form various figures and cover large portions of the fundus.

There is no doubt that, as a result of degenerative atrophy, pigment may form independently, by a transformation of the contents of the neoplastic cells (*Donders*, *Schweigger*); for not unfrequently pigment collections are found in the anterior layers of the retina, out of all connection with the cells of the tapetum, and when there is no pigment in the posterior strata. Extensive or even moderate developments of pigment in the retina are, however, only found after exudative inflammation, and then result from the transformation of the neoplastic cells in the retina, which has taken place under the influence of the proliferation of the tapetum cells; for various observations prove a direct connection between the pigment collections in the retina and the groups of proliferating tapetum cells, and the gradual pressing forward of the pigment formation from the latter through the different layers of the retina has been observed. (*H. Müller*, *Pope*.) (*Rudnew*, *Iwanoff*.)

This relation is usually very marked in large confluent groups of pigment. The peculiar delicate figures resembling bone-corpuscles, on the contrary, are generally only partly connected with choroidal collections of pigment. So far as has been hitherto observed, they appear to be connected with the finer blood-vessels, which greatly degenerate during the atrophy. This also explains their peculiar arrangement and radiated direction.

After exudative inflammations, we may often see the exudation layers, which attach the choroid to the atrophied retina. In old cases, however, this neoplastic stratum can rarely be any longer distinguished as a separate layer. The degenerated retina, often reduced to a delicate cloudy membrane, appears to lie immediately on the greatly atrophied choroid, and the union is often so intimate that the two membranes can with difficulty be separated.

In cases where the atrophy of the retina has not progressed far, the vitreous is usually perfectly preserved; at its peripheral parts alone may often be found delicate, gauze-like cloudinesses which are caused by cellular proliferations and their consequences. On the contrary, when the retina entirely degenerates, and is reduced to a delicate, indistinctly-striated membrane, which is firmly attached to the highly-atrophied choroid, the vitreous liquefies, and we find only some connective-tissue remains of it, which lie on the inner limiting membrane.

The Symptoms, in accordance with the anatomical conditions, vary considerably, even if we only take into consideration those cases where the atrophying retina has remained attached to the choroid, and where the clearness of the dioptric media permits us to see the fundus. The decided whiteness of the optic papilla is the only certain characteristic, as the other symptoms vary.

Pure or gray atrophy usually shows itself by decided paleness of the outer half

of the papilla. At the very commencement, we often see an oblique oval on the optic papilla; this is distinguishable from the surrounding parts by its bright color. Its inner pole usually surrounds the porus opticus, while the outer approaches the temporal edge of the papilla. Its indistinct border, and the passage of the vessels over it without curvature, prevent its being mistaken for physiological excavation. This paleness extends rapidly, mostly toward the yellow spot, and sometimes reaches the outer part of the connective-tissue ring; beyond this, however, it never advances. Thus the oval becomes a circle; then, as its branches separate more and more, while its zenith approaches the inner border of the papilla, the part remaining of normal color is reduced to a crescentic border on the nasal side of the optic-nerve entrance. This border, also, finally disappears, so that the entire papilla becomes bright gray or white, often with an inclination to blue, opaque, satiny, or mother-of-pearl brilliancy, and frequently appears slightly excavated. Hence it contrasts strongly with the rest of the fundus, which usually shows no change, and consequently appears more sharply bounded than usual. (*Chro. lith.*, M.) In gray atrophy its diameter is not perceptibly diminished. Previously existing physiological excavations are completely annulled by advanced atrophy. (*Ed. Jaeger.*)

The bright reflex sometimes shows itself by the brilliancy of the eye, hence may look like amaurotic cat's-eye.

The small vascular twigs, normally quite numerous on the papilla, are wholly or mostly absent. On the other hand, the chief trunks and large branches of the arteria and vena centralis are usually present. They no longer advance in curves from the porus opticus, but bend just in the level of the membrana cribrosa, and, close in contact with this, run to the retina. The thickening of their adventitious membrane shows itself ophthalmoscopically by a delicate bright, often shining, border, on both sides of the vessels. (*Liebreich.*) Even in far-advanced atrophy, their caliber is frequently unchanged. In other cases, however, the arteries appear contracted, but the veins normal, or even dilated; or veins and arteries are both much affected, thin, with few branches (*Chro. lith.*, M.), and often also much shortened. Sometimes, too, some of the branches are wanting; they are less numerous, or we find in their place others that differ from the normal state in position, direction, and in relation to the porus, and appear to be collateral. In very rare cases, the vessels are entirely absent. (*Graefe.*)

In cloudy atrophy, also, the ophthalmoscopic appearance of the optic-nerve entrance is much paler than normally; the color of the papilla inclines, at least at intervals, to white or gray. But, except in some old cases, the tendinous brilliancy and sharp contours of the above variety are wanting; for a more or less decided, veil-like cloudiness comes over the whole fundus, including the papilla, by which the border of the latter is more or less enveloped, and a whitish, grayish, or pale-yellow tone given to the fundus. (*Chro. lith.*, L.

Occasionally, however, in the papilla, we see the atrophied membrana cribrosa (which is often pushed forward, that is, excavated), with its tendinous or mother-of-pearl brilliancy, shining through the superficial hypertrophied connective-tissue layer. In the latter class of cases, thick, and hence strongly-refracting, striæ or spots are sometimes seen, partly covering the disc, or even projecting beyond it into the retina itself. Then it appears as if the border of the optic papilla were displaced, or as if cicatricial processes stretched out from the excavation over the retina.

In cloudy atrophy, the papilla not unfrequently appears smaller, or even irregularly angular.

This change is often only apparent, and is caused by the protrusion of pigment-cells from the border of the choroid. But where the atrophy of the optic nerve is accompanied by that of the whole eyeball, and the intra-ocular pressure is much diminished, the diminution of surface sometimes actually exists and depends on atrophy of the superjacent connective-tissue layer.

In cloudy atrophy the vessels usually suffer more than in pure atrophy, as well on account of the preceding proliferation as from the subsequent atrophy of the connective tissue. The chief branches of the arteria and vena centralis are more frequently contracted, deficient in offshoots, shortened (*Chro. lith.*, L), or even invisible ophthalmoscopically. But the vessels that are present appear, through the cloudy connective-tissue framework of the retina and papilla, as if enveloped in a mist. They are totally obscured, where there are thick tendinous masses

In some cases, instead of the branches, we see striæ of pigment, or dull, white strings which either represent vessels actually obliterated, or still pervious, but which from the thickness and opacity of their walls do not let the blood show through.

These atrophied vessels must be clearly distinguished from delicate, whitish-yellow, ramifying and anastomosing cords, which in a more rectilinear or winding course pass through the atrophied retina in the most varying directions. These are probably situated in the external layers, and their anatomical character has not yet been explained (*Ed. Jaeger*).

Moreover, in cloudy atrophy, the collections of pigment usually lie in the retina (*Chro. lith.*, L), and occasionally even in the papilla (*Liebreich*). They are sometimes irregular clumps, sometimes delicate outshoots, jagged lines and bodies resembling bone-corpuscles, again extensive patches, uniting at some points. The first two forms usually appear very distinctly ophthalmoscopically, as they ordinarily lie in the anterior layers of the retina. But the latter form appears flowered over by the hypertrophied framework of the retina, and accompanied by the changes of the fundus peculiar to exudative neuro-retinitis.

Exceptionally we find cicatricial laminated deposits and nests of cholesterine crystals in the retina (*Coccius*). The former are recognized by their bluish-white color, the latter by their mother-of-pearl brilliancy.

Atrophy always manifests itself subjectively by diminution of sharpness of vision, and usually also by increasing lateral limitation of the visual field. But in advanced stages there is usually complete amaurosis. The grade and extent of this disturbance of function are not, however, at all proportionate to the changes apparent on ophthalmoscopic examination. This is especially true of pure atrophy. In this, even when the papilla is clear-white or bluish, tendinous-looking and excavated, there is not unfrequently a very decided central sharpness of vision. When the illumination is good, the patient reads without hesitation the finer numbers of Jaeger's type, and limitation of the field of vision cannot always be made out. But, on the other hand, many cases occur where, when the papilla appears normal, or the signs of atrophy are just beginning, vision is reduced to quantitative perception of light, or is absolutely gone. That is, the destruction of the nerve-elements in the papilla and retina is not always in proportion to the changes apparent ophthalmoscopically; they often remain, at least partially, capable of conducting in spite of the connective tissue being greatly atrophied; but, on the other hand, it often

COOPER MEDICAL
SAN FRANCISCO, CAL.
...ed is not to be removed from the
Library Room by any person or
under any pretext whatever.

happens that the nerve-elements are destroyed before decided atrophy of the framework has occurred. Moreover, the disturbance of function of the eye is not solely dependent on the nutritive state of the retina and papilla. The atrophy occurring here is often only a symptom of the result of an identical or even of a different process running its course in the brain or spine, which may destroy the conducting power of the nerve, or the specific activity of its central organ, before the orbital portion of the optic nerve and its expansion have begun to suffer. These differences are intimately connected with the causes, and very much influence the entire type of the disease. This will be treated of in the chapter dedicated to Amaurosis.

1. By amaurosis however we understand nothing more than the inability to perceive objects lying in certain portions of the field of vision, with a degree of distinctness corresponding to the intensity of illumination and the size of the visual angle (amblyopia), or even to distinguish light from darkness (amaurosis). This inability is dependent upon certain material changes in the retina and optic nerve.

The impairment of vision not only varies in degree within the largest limits, but is often irregularly distributed upon the various parts of the visual field. This must, therefore, be carefully examined in all directions, in order to gain a clear idea as to the amount of impairment to the functions of the eye, and with this, perhaps, to form a conclusion as to the situation and extent of the principal disease.

The most careful estimation of the central acuteness of vision is very important, and the manner in which the distinctness of the perception diminishes in each individual sector of the field toward its periphery, as well as the size and form of the whole field of vision.

The measurement of the central sharpness of vision, after what has been said in a previous part of this work, needs no further description. Still, one method more may be mentioned, by which we are enabled to measure the sensitiveness of the center of the retina to light. The apparatus consists of a black disk, upon which a line of uniform thickness is drawn, from the center toward the periphery. This line is interrupted at several points. If the disk be turned quickly on its axis, the parts of the line appear as circles. Their distinctness decreases with their diameter, and may be expressed by the fraction $\frac{d}{2r\pi}$; d is the thickness of the line, l the radius of the circle, *i. e.*, the distance of the part of the line from the center or axis of the disk, and π indicates Ludolf's numbers. The sensitiveness of the diseased center of the retina to light is decided, then, by the proportion of the clearness of the largest circle recognized by the patient, to the clearness of one recognized by a healthy eye, in the same amount of illumination, and at the same distance from the circle (*Masson*, *Schelske*).

It is much more difficult to get an exact result as to the shape and extent of the visual field. For the purpose of a preliminary examination, it is sufficient if the surgeon place himself before the patient, with a lateral illumination, and, while the other eye is closed, causes him to fix his view on the eye of the examiner, and rotates one or two fingers of the hand, in a gentle manner, about the periphery of the visual field. We can easily find out, in this way, if the perception of the eye observed be inferior to that of the observer, especially if we avoid any self-deception on the part of the patient by constantly altering the number of the fingers, and causing the patient to name them, at the same time taking care that the line of vision is not directed upon the fingers instead of the eye of the surgeon.

For the same purpose we may bring a sheet of paper before the affected eye, at a distance of from one to one and a half feet, upon which a number of black points are made, which radiate from a common center. The picture of the field of vision may be made from the number and situation of the points, which the affected eye is able to recognize in fixing his view upon the center. The best method, however, is to place the patient before a blackboard, about one foot from it, then to cause him to fix his eye upon one point in it, while the examiner moves a piece of chalk around the periphery of the field of vision, and thus indicates exactly the spot where the chalk enters the visual field. Yet this does not make an exact boundary. Small interruptions, slight impairments in conductive power, are not made

distinct enough by this method. For the estimation of these, very weak and different degrees of illumination are required, which may be had with the aid of a photometric apparatus (*Graefe*, *Förster*).

For the purpose of recording the defect of the visual field, several very ingenious instruments have recently been invented (*Heymann*, *Houdin*). The perimeter gives the most exact results (*Förster*, *Moeser*), in so far as it regards the cup-like form of the visual field, without respect to other advantages, and consequently avoids a series of errors which necessarily arise from the varying distances of the test-object and from false projections of its retinal image.

In cases of cataract, closure of the pupil, etc., when the light, on its way to the retina, must pass through media which are optically irregular, greater interruptions may be discovered by the following method. The room is darkened, and the flame of a candle is swept around the visual field, and the various points noted from which the light is dimly seen or not noticed at all. Under such circumstances the reaction of the individual parts of the retina to externa pressure (*Serres d' Uzes*), or to galvanic irritations, may be diagnosticated (*Remak*). Yet the results are not as trustworthy as those obtained by the lamp. Where we desire to distinguish between partial anæsthesia and actual hindrances in conduction, they render very valuable assistance.

In the former, phosphœnes, sparks of light, are seen in the parts incapable of perceiving light, while they are wanting in amaurotic defects (*Graefe*). The examination as to the ability of distinguishing colors is also of some importance in completing the diagnosis. This becomes very much reduced in portions of the retina which are amblyopic.

A definite proportion however does not necessarily exist between its diminution and that of the acuity of vision, since the ability to distinguish colors has often suffered very markedly before a defect in the acuity of vision is noticed, and sometimes there is complete achromatopsia with an acuity of vision which is relatively but slightly injured (*Chisholm*, *Quaglino*). These cases of chromatodesopsia have already attracted attention and have prompted a number of experiments, which have demonstrated that the sensibility to colors lying at the extreme limits of the spectrum is the first to suffer, next that of the colors nearer the center, and finally the yellow disappears. Later experiments have corroborated these results in so far as they have proved that the color-amblyopia is first manifested by the characteristic defect of red blindness (*Schelske*, *Benedikt*), or even by the disappearance of the violet (*Galezowski*). More recently investigations with the spectroscope and Rose's cyanometer have rectified these results by proving that in the spectrum the red first disappears, then the yellow and green, and finally the blue. Thus we see that the colors cease to excite the retina qualitatively in the same order as they are arranged in the spectrum, with the single exception that violet disappears before blue. The same relation is therefore repeated, which may be demonstrated as regards the ability to distinguish colors in the normal eye, by the gradual diminution of the intensity of illumination. It has also been shown, that the chromatodesopsia in amblyopia increases from the centre towards the periphery; that in hemiopia it is usually confined to the amblyopic portion of the visual field, and often precedes considerably the diminution of the acuity of vision in central defects. Moreover it is often limited solely to the region of the central defect or else extends beyond this to a varying degree. It may also here begin with red blindness, and increasing by green and blue blindness, finally ends in complete achromatopsia (*Leber*).

Sometimes we also meet with subjective symptoms, as photopsia, chromopsia, etc. These offer less information of the extent of the interruption, than of the nature of the real affection and the morbid processes accompanying it.

[It is very useful to be able to record the state of the field of vision at different times in the course of a case of amblyopia or amaurosis. The following method will commend itself.

The examination is made in the usual way, letting the patient sit down in a chair and lean against the back, so as to keep the head more steady. The blackboard, about 4 feet × 3 feet, is placed exactly one foot in front of the eye, covering the eye not to be tested, and directing the patient to continue to look steadily at a small cross. The piece of chalk is approached in various directions, and when seen, the spot

marked on the board. Connecting these dots together, we have the periphery of field of vision, and can, in like manner, examine the central portion.

In order to have a permanent record of the case, a light frame is placed over blackboard, across which in both directions fine white thread is stretched at e three inches. The threads lie against the board, and it is thus divided up into squ Care is taken, of course, that the central cross at which the patient looks shall respond to the meeting of two threads.

Fig. 34.

RIGHT EYE.



LEFT EYE.



Then on the "register of the field of vision," which is reduced to $\frac{1}{12}$, and the squares of which are therefore $\frac{1}{4}$ inch, the outline of the field of vision is drawn, copying the line in each square from the blackboard. This gives a field corresponding to the eye, at one inch from the paper, being $\frac{1}{12}$ of the distance of the patient's eye from the blackboard. There are two registers printed, one for each eye. On the other side of the sheet the necessary data of the case can be written. The plates of the field of vision hitherto used in reports of cases published, give us, in reality, only the shape of the outline, and perhaps, by shading, some idea of the relative amount of vision of different parts. In this method we have the true size of the field, and should it be desired to have the case illustrated, the artist has a positive size to go by. The register has been adapted for an octavo volume. The examination and record in an ordinary case will not take more than fifteen minutes. The registers are $2\frac{1}{2} + 3\frac{1}{2}$ inches, corresponding to a $2\frac{1}{2}$ and $3\frac{1}{2}$ feet blackboard (*B. Joy Jeffries*).]

In general, we may distinguish between interruptions and contractions or limitations. By the first, we understand a defect fully inclosed in the monocular visual field; but by the latter, a deficiency extending from the periphery more or less into the visual field. Both kinds are very often evident in ordinary vision.

The interruptions seem to the patient like circumscribed spots, of varying shape, which lie immovably in, or near, the center of the visual field. Patients are apt to speak of them as vacant points on the visual field, or as a whitish-gray mist, more rarely as having colored boundaries, or as dark-gray or black clouds, which either completely cover the objects or allow them to glimmer through, and which, unlike scotomata, are not lost in the other portions. In some cases they surround a normal or clearer part like a ring, and this is usually the center of the visual field.

One case, however, was observed, where there was a central interruption, which was separated from the blinded periphery by a girdle, where the acuteness of vision was slightly impaired.

Interruptions appear most plainly in monocular vision. If they lie centrally, they disturb vision very much, particularly that of near objects, since they cover the words in reading, making them very indistinct, or causing them not to be seen at all.

The patient is thus compelled to allow the axis of vision to sweep by the objects, in order to use healthy parts of the retina. By continued exercise, eccentric portions of the retina gain a perceptive power far exceeding the normal. But if the interruptions are very eccentric, they are often overlooked, and only seen when the patient turns his attention to them. Small, eccentric interruptions may be even entirely unnoticed, perhaps because, as in *Mariotte's* spot [the blind spot] (*Wittich*), the excitations of the adjoining elements help to fill up the blanks, and give an idea as to the peculiarities of the object. For evident reasons, such eccentric spots are covered in binocular vision much more easily, by the perception of the normal eye. In central interruptions this is more difficult. This is apt to trouble binocular vision very much, particularly in the beginning of the appearances of the spots, since they diminish the distinctness of the perceptions of the corresponding parts of the healthy retina, dazzling, as it were, the healthy eye.

The contractions of the field of vision, as long as they are limited to the periphery, are much less marked than the interruptions. The patient frequently does not notice them at all. It requires some experiments to determine that they certainly exist. But as they extend toward the center of the retina, the impairment of vision begins to be of importance, particularly in monocular vision, and in binocular vision, its situation can not be covered by a corresponding part of the other retina. These also are seen by the patient in empty spots, or surrounded by a cloud, or as very dark places in which objects are not seen at all, or in dim outline. Their boundaries are

sometimes distinct, again ill-defined; that is, the distinctness of the retinal images suddenly increases on a certain line, or very gradually, within a certain zone. This is an important distinction, indicating with some probability, at least, the temporary limitation of the process, or the advance of the disease causing these contractions.

True amblyopic contractions of the field of vision most frequently begin on the temporal portion, but often, also, on the nasal side, rarely above or below. The border generally extends in a tortuous course, deviating more or less from the principal direction. If the defect extends, it does so more rapidly on the periphery of the field of vision than in the parts lying near the center, so that the ends of the boundary have often approached each other, or even run together before the contraction has reached the center or passed beyond it. The field of vision thus becomes slit-shaped.

Fig. 35.

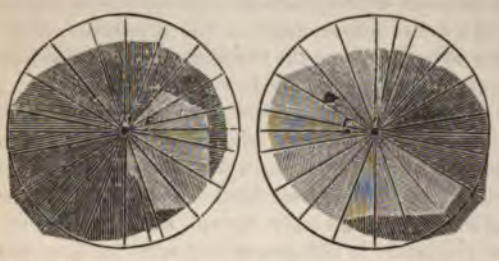

The form assumed by the field of vision in the different stages of the above processes is, moreover, extremely variable. For example, in progressive atrophy of the optic nerve dependent upon tabes, it inclines to the form of a sector, the point of which is turned towards Mariotte's spot (Fig. 35 M after *Förster*), and this almost always includes a quadrant, lying rather often upward or upward and outward, rarely inwards or downwards. This sector begins as a peripherical limitation which presses more and more towards the center F, while the lateral borders rapidly extend in the periphery, and, finally bending at an obtuse angle, surround a part of the visual field, in order to become limited to the slit-form (*Förster*).

In isolated cases we meet with concentric limitations, which extend from the outermost portion of the visual field more or less regularly to the center, and thus, in the beginning, diminish very much the function of the whole periphery of the retina, or render it blind. Hemopic contractions also occur, here and there; one half of each retina becomes amblyopic or amaurotic at the same time, or these affections occur within a short time of each other. The hemiopia is then generally in corresponding sides of the two retinas. It is to be ascribed to a disease of one root of the optic nerve.

Fig. 36.

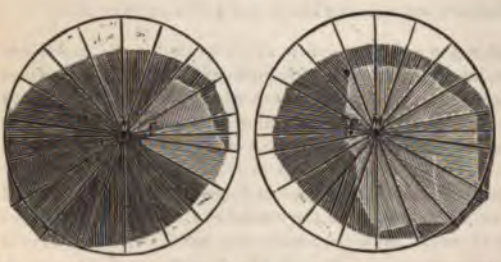

In case, therefore, the morbid process is here strictly limited, the hemopia is sharply cut off by the vertical line of separation of the two monocular visual fields. It descends perpendicularly through the point of fixation F, but has an irregular blunt-hooked appearance above and below the latter; it then bends at an acute angle, and at the periphery surrounds the still normal part in the form of a narrow margin (Fig. 36, after *Förster*).

form of the hemiopic field of vision corresponds to the division of the nerve fibers. rossed bundles of optic nerve fibers which pass through the chiasm, only supply a small f the external half of the retina; the rest receives its fibers from the crossed bundles, nerally enter at the inner side of the papilla, and, partially curving over upon the ex- le of the retina, likewise inclose the district of the uncrossed bundles.

onymous or lateral hemiopia has also been exceptionally observed. It is temporal, in which the temporal sides of both monocular visual fields have cured, that is, the inner halves of the retina are incapable of performing ctions. They are to be referred to defects of conducting power of the optic ndles crossed in the chiasm (*Sämisch, D. E. Müller, Loewegren*).

hemiopia occurs very rarely, in which the nasal sides of both monocular lds are obscured, that is, the external sides of the retina and the uncrossed of optic nerve fibers have lost their functional power (*Graefe, Pagenstecher*). ia of the superior or inferior halves of both retinæ has also exceptionally erved.

nptions and limitations of the visual field seldom occurring alone, we are speak of a partial amaurosis. This is most frequently the case in inter- not so often in hemiopia, or even in lateral and concentric limitation. Such on, where it really exists, is very often only temporary. As a rule, an exact ion of the visual field shows us that the defect is much more extensive, and combined with an impairment of vision extending over the whole of it. the symptoms exhibit only a partial increase in the loss of conducting the nerves, we generally recognize a very considerable loss in the central of vision, and with it, an abnormally rapid reduction of the relative power tion in the adjacent parts of the monocular fields of vision. In the inter- which lie in or near the center, on the contrary, we often find a regular in all directions of the relative acuteness of vision. More rarely, however, e an irregular loss.

rding to the above, such conditions differ chiefly from the so-called amauro- gree, and not in extent. In the latter affection the perceptive power in the ar visual field is reduced to quantitative perceptions of light, and is finally ly destroyed.

g as there is a quantitative perception of light, the iris may possess its reactive power d. Immobility of the pupil exists only in complete amaurosis, or where paralysis of system or mechanical hindrances render the movements of the iris impossible. A tive evidence of the reduction of vision to quantitative perception of light, and still bsolute amaurosis, is found in the unsteady, and particularly in the excessive, move- the affected eyeball. This evidence is only rarely wanting, if the other eye is covered, artial and indistinct qualitative perception of light is sufficient to keep the globe in a irection for a time.

er to detect a simulated amaurosis we scarcely need deceptive manœuvers with prisms roscope, as many think. They endeavor to confuse the patient by placing prisms base upwards or downwards before the supposed amblyopic eye, and thus try to pro- cular diplopia (*Graefe*); or by covering the pupil of the normal eye, sometimes partly, s entirely, with the angle of a horizontal prism unbeknown to the patient, and thus he conditions for monocular and binocular diplopia to change in a manner which is r the patient to determine (*Alf. Graefe*). Another method is to place a prism hori- efore the eye, and to choose as object lines, of which two run parallel to the axis, d perpendicular to them. These must necessarily be seen double in the binocular (*Berthold*). Others judge of the functional capacity by the corrective adduction bout in the interest of binocular single vision by a prism held before the eye with

which has become perforate, into the degenerated vitreous, and unites the retina with this. remains of the internal limiting membrane often appears thickened and cloudy, as a re deposition of molecular detritus on its posterior surface. Not unfrequently these deposition figured in various ways, and interwoven with remains of atrophied vessels. In the begi especially in the anterior zone, a large part of the nervous elements of the retina ar observable; nevertheless, they almost always show every where the character of advance degeneration and sclerosis. This is particularly true of nerve-fibres and ganglion-cells. bacillar layer usually suffers quite early, its elements appear partly discolored, swelled, clouded with fat. The granules, on the contrary, hold out longer, and then usually betray participation in the disease by decided fatty brilliancy. Near to and between the ner elements, strewed in the connective-tissue stroma, we find quantities of coloid bodies, free fa granules and fat globules, which latter are beginning to be destroyed, or have even already changed to cholesterine, whose crystals lie around in groups. Besides this, old and recent extra sations of blood are every where seen, but rarely large amounts of neoplastic pigment. The sma vessels are usually destroyed or degenerated, and even of the trunks, only part are perv Their walls are mostly thickened, changed to loose connective tissue, which is united with areolar stroma and contains numerous cells, partly fatty or sclerosed. Besides this, it is usu strewed with fat granules, pigment, and chalky salts, and with coloid disc-like pendants. many cases the degenerated vessels traverse leaf-like connective-tissue new formations, whe they acquire the appearance of winged leaf-stems, or are beset with papillary outgrowths. N unfrequently the vessels are entirely obliterated in spots, changed to solid connective-tis strings, or filled with necrotic blood-cells or with coloid masses. Occasionally some are ather matously degenerated, and then present themselves to the naked eye as twigged, chalky, whit hard, brittle strings. (*Wedl, H. Müller.*)

In the subsequent course the nervous elements are gradually destroyed by progressive fatty degeneration and sclerosis, so that finally only atrophied granules in variable amount are found the fat granules are destroyed, in the same way the extravasations of blood, and even the coloid bodies, after precedent granulation, become scarcer. Fatty degeneration and resorption also occur in the connective-tissue stroma and its cellular elements; it diminishes decidedly in mass, and finally atrophies partially or entirely to an indistinct fibrous or indifferent hard, tough tissue, which is traversed by a few thick tendinous cords and degenerated vessels, and contains only a slight amount of free fat, granular pigment, atrophied cells and remains of granules, and here and there coloid bodies, and is also attached to the degenerated vitreous. Exceptionally small bony plates appear in it; indeed, as far as the degenerated retina is in contact with the bony plate covering the choroid, it also becomes bony.

Where the retina has remained attached to the choroid the signs of degeneration are usually less. As a result of inflammations with large morbid product, especially of the nephritic form, the posterior portions of the retina and the tissue of the papilla sometimes become denser, opaque, and dull, colored grayish-yellow or white. In some cases we may, even with the naked eye, see filamentary striae in this thickened portion, radiating from the papilla into the retina, and with their ragged, fringed ends extending beyond the opaque spot. Occasionally, also, we meet hard, white, variously-figured cicatritial masses of tendinous lustre, which extend clear through the retina; but these are exceptions. In much the greater number of cases, especially after simple diffuse retinal inflammations, degenerative atrophy shows itself only by some increase of the thickness, by a very delicate and scarcely noticeable gelatinous or whitish veil-like cloudiness, which is somewhat thicker, and sometimes also slightly striated about the optic-nerve entrance and its immediate vicinity, and by partial degeneration of the vessels.

In low grades of the atrophy we may often still distinguish all the layers of the retina with their peculiar nervous and connective-tissue arrangements, although the individual parts are already variously changed in the manner above described, and are partly replaced by coloid masses and fatty granules. But as the atrophy progresses the layer arrangement is lost.

ing to the variety of the preceding inflammation, sometimes the inner, at other times the
yers of the retina are deteriorated into an indistinctly-striated tissue clouded by molecular
; or else the entire retina has changed to a homogeneous or slightly-striated thin but
nd hard membrane, in which, of the former constituents, only atrophied cell-like forma-
d (about the optic-nerve entrance) atrophied vessels and bundles of connective tissue

y often collections of pigment-cells and granules appear in the degenerated
f the atrophied retina which lies on the choroid. Usually there are only
attered shoots, heaps, or clump-like masses which lie along the vessels or on
der of the optic papilla. In other cases the pigment is confined principally
nterior and middle zones of the retina, and then appears in very small irreg-
otched, elongated heaps, not unlike bone-corpuscles, whose long axis is
r directed toward the posterior part of the retina. And lastly, large amounts
astic pigment occur, especially in the posterior half of the retina, and form
l small clumps that are irregularly situated and unite to form various figures
r large portions of the fundus.

is no doubt that, as a result of degenerative atrophy, pigment may form
ntly, by a transformation of the contents of the neoplastic cells (*Donders*,
r); for not unfrequently pigment collections are found in the anterior
the retina, out of all connection with the cells of the tapetum, and when
pigment in the posterior strata. Extensive or even moderate develop-
igment in the retina are, however, only found after exudative inflammation,
esult from the transformation of the neoplastic cells in the retina, which
place under the influence of the proliferation of the tapetum cells; for
servations prove a direct connection between the pigment collections in
and the groups of proliferating tapetum cells, and the gradual pressing
the pigment formation from the latter through the different layers of the
been observed. (*H. Müller*, *Pope.*) (*Rudnew*, *Iwanoff.*)

tion is usually very marked in large confluent groups of pigment. The peculiar deli-
resembling bone-corpuscles, on the contrary, are generally only partly connected
al collections of pigment. So far as has been hitherto observed, they appear to be
ith the finer blood-vessels, which greatly degenerate during the atrophy. This also
r peculiar arrangement and radiated direction.

dative inflammations, we may often see the exudation layers, which attach the cho-
atrophied retina. In old cases, however, this neoplastic stratum can rarely be any
guished as a separate layer. The degenerated retina, often reduced to a delicate cloudy
ppears to lie immediately on the greatly atrophied choroid, and the union is often so
; the two membranes can with difficulty be separated.

where the atrophy of the retina has not progressed far, the vitreous is usually per
red; at its peripheral parts alone may often be found delicate, gauze-like cloudinesses
used by cellular proliferations and their consequences. On the contrary, when the
ly degenerates, and is reduced to a delicate, indistinctly-striated membrane, which is
ed to the highly-atrophied choroid, the vitreous liquefies, and we find only some
issue remains of it, which lie on the inner limiting membrane.

ymptoms, in accordance with the anatomical conditions, vary consider-
if we only take into consideration those cases where the atrophying
remained attached to the choroid, and where the clearness of the dioptric
nits us to see the fundus. The decided whiteness of the optic papilla is
ertain characteristic, as the other symptoms vary.

r gray atrophy usually shows itself by decided paleness of the outer half

of the papilla. At the very commencement, we often see an oblique o
optic papilla; this is distinguishable from the surrounding parts by its br
Its inner pole usually surrounds the porus opticus, while the outer app
temporal edge of the papilla. Its indistinct border, and the passage of
over it without curvature, prevent its being mistaken for physiological
This paleness extends rapidly, mostly toward the yellow spot, and sometin
the outer part of the connective-tissue ring; beyond this, however, it
vances. Thus the oval becomes a circle; then, as its branches separate
more, while its zenith approaches the inner border of the papilla, the part
of normal color is reduced to a crescentic border on the nasal side of the
entrance. This border, also, finally disappears, so that the entire papil
bright gray or white, often with an inclination to blue, opaque, satiny, or
pearl brilliancy, and frequently appears slightly excavated. Hence it
strongly with the rest of the fundus, which usually shows no change,
quently appears more sharply bounded than usual. (*Chro. lith.*, M.) In gr
its diameter is not perceptibly diminished. Previously existing physiolo
vations are completely annulled by advanced atrophy. (*Ed. Jaeger.*)

The bright reflex sometimes shows itself by the brilliancy of the eye, hence ma
amaurotic cat's-eye.

The small vascular twigs, normally quite numerous on the papilla, are
mostly absent. On the other hand, the chief trunks and large branches of
and vena centralis are usually present. They no longer advance in c
the porus opticus, but bend just in the level of the membrana cribrosa, a
contact with this, run to the retina. The thickening of their adventitious
shows itself ophthalmoscopically by a delicate bright, often shining, bord
sides of the vessels. (*Liebreich.*) Even in far-advanced atrophy, their
frequently unchanged. In other cases, however, the arteries appear cont
the veins normal, or even dilated; or veins and arteries are both much aff
with few branches (*Chro. lith.*, M.), and often also much shortened. Some
some of the branches are wanting; they are less numerous, or we find in
others that differ from the normal state in position, direction, and in rela
porus, and appear to be collateral. In very rare cases, the vessels a
absent. (*Graefe.*)

In cloudy atrophy, also, the ophthalmoscopic appearance of the opti
trance is much paler than normally; the color of the papilla inclines,
intervals, to white or gray. But, except in some old cases, the tendinou
and sharp contours of the above variety are wanting; for a more or le
veil-like cloudiness comes over the whole fundus, including the papilla
the border of the latter is more or less enveloped, and a whitish, grayis
yellow tone given to the fundus. (*Chro. lith.*, L.

Occasionally, however, in the papilla, we see the atrophied membrana cribro
often pushed forward, that is, excavated), with its tendinous or mother-of-pearl brilli
through the superficial hypertrophied connective-tissue layer. In the latter class of
and hence strongly-refracting, striæ or spots are sometimes seen, partly covering
even projecting beyond it into the retina itself. Then it appears as if the border
papilla were displaced, or as if cicatricial processes stretched out from the excava
retina.

In cloudy atrophy, the papilla not unfrequently appears smaller, or even irregu-
ly angular.

This change is often only apparent, and is caused by the protrusion of pigment-cells from
border of the choroid. But where the atrophy of the optic nerve is accompanied by that
the whole eyeball, and the intra-ocular pressure is much diminished, the diminution of
ize sometimes actually exists and depends on atrophy of the superjacent connective-
ue layer.

In cloudy atrophy the vessels usually suffer more than in pure atrophy, as well
account of the preceding proliferation as from the subsequent atrophy of the
nective tissue. The chief branches of the arteria and vena centralis are more
quently contracted, deficient in offshoots, shortened (*Chro. lith.*, L), or even invisi-
ophthalmoscopically. But the vessels that are present appear, through the cloudy
nective-tissue framework of the retina and papilla, as if enveloped in a mist.
ey are totally obscured, where there are thick tendinous masses

In some cases, instead of the branches, we see strise of pigment, or dull, white strings
which either represent vessels actually obliterated, or still pervious, but which from the thick-
ness and opacity of their walls do not let the blood show through.

These atrophied vessels must be clearly distinguished from delicate, whitish-
yellow, ramifying and anastomosing cords, which in a more rectilinear or winding
course pass through the atrophied retina in the most varying directions. These
are probably situated in the external layers, and their anatomical character has not
yet been explained (*Ed. Jaeger*).

Moreover, in cloudy atrophy, the collections of pigment usually lie in the retina
(*Chro. lith.*, L), and occasionally even in the papilla (*Liebreich*). They are some-
times irregular clumps, sometimes delicate outshoots, jagged lines and bodies
resembling bone-corpuscles, again extensive patches, uniting at some points. The
ese two forms usually appear very distinctly ophthalmoscopically, as they ordinarily
in the anterior layers of the retina. But the latter form appears flowered over
the hypertrophied framework of the retina, and accompanied by the changes of
e fundus peculiar to exudative neuro-retinitis.

Exceptionally we find cicatricial laminated deposits and nests of cholesterine crystals in
retina (*Coccius*). The former are recognized by their bluish-white color, the latter by
ir mother-of-pearl brilliancy.

Atrophy always manifests itself subjectively by diminution of sharpness of
ion, and usually also by increasing lateral limitation of the visual field. But in
vanced stages there is usually complete amaurosis. The grade and extent of this
turbance of function are not, however, at all proportionate to the changes appa-
nt on ophthalmoscopic examination. This is especially true of pure atrophy. In
s, even when the papilla is clear-white or bluish, tendinous-looking and excavated,
re is not unfrequently a very decided central sharpness of vision. When the
amination is good, the patient reads without hesitation the finer numbers of
eger's type, and limitation of the field of vision cannot always be made out. But,
the other hand, many cases occur where, when the papilla appears normal, or
e signs of atrophy are just beginning, vision is reduced to quantitative perception
light, or is absolutely gone. That is, the destruction of the nerve-elements in
e papilla and retina is not always in proportion to the changes apparent ophthal-
scopically; they often remain, at least partially, capable of conducting in spite
the connective tissue being greatly atrophied; but, on the other hand, it often

COOPER MEDICAL COLLEGE
SAN FRANCISCO, CAL.
and is not to be removed from the
Library Room by any person or
under any pretext whatever.

happens that the nerve-elements are destroyed before decided atrophy of the frame-work has occurred. Moreover, the disturbance of function of the eye is not solely dependent on the nutritive state of the retina and papilla. The atrophy occurring here is often only a symptom of the result of an identical or even of a different process running its course in the brain or spine, which may destroy the conducting power of the nerve, or the specific activity of its central organ, before the orbital portion of the optic nerve and its expansion have begun to suffer. These differences are intimately connected with the causes, and very much influence the entire type of the disease. This will be treated of in the chapter dedicated to Amaurosis.

1. By amaurosis however we understand nothing more than the inability to perceive objects lying in certain portions of the field of vision, with a degree of distinctness corresponding to the intensity of illumination and the size of the visual angle (amblyopia), or even to distinguish light from darkness (amaurosis). This inability is dependent upon certain material changes in the retina and optic nerve.

The impairment of vision not only varies in degree within the largest limits but is often irregularly distributed upon the various parts of the visual field. This must, therefore, be carefully examined in all directions, in order to gain a clear idea as to the amount of impairment to the functions of the eye, and with this, perhaps to form a conclusion as to the situation and extent of the principal disease.

The most careful estimation of the central acuteness of vision is very important and the manner in which the distinctness of the perception diminishes in each individual sector of the field toward its periphery, as well as the size and form of the whole field of vision.

The measurement of the central sharpness of vision, after what has been said in a previous part of this work, needs no further description. Still, one method more may be mentioned by which we are enabled to measure the sensitiveness of the center of the retina to light. The apparatus consists of a black disk, upon which a line of uniform thickness is drawn, from the center toward the periphery. This line is interrupted at several points. If the disk is turned quickly on its axis, the parts of the line appear as circles. Their distinctness decreases with their diameter, and may be expressed by the fraction $\frac{d}{2r\pi}$; d is the thickness of the line, l the radius of the circle, *i. e.*, the distance of the part of the line from the center or axis of the disk, and π indicates Ludolf's numbers. The sensitiveness of the diseased center of the retina to light is decided, then, by the proportion of the clearness of the largest circle recognized by the patient, to the clearness of one recognized by a healthy eye, in the same amount of illumination, and at the same distance from the circle (*Masson*, *Schelske*).

It is much more difficult to get an exact result as to the shape and extent of the visual field. For the purpose of a preliminary examination, it is sufficient if the surgeon place himself before the patient, with a lateral illumination, and, while the other eye is closed, causes him to fix his view on the eye of the examiner, and rotates one or two fingers of the hand, in a gentle manner, about the periphery of the visual field. We can easily find out, in this way, if the perception of the eye observed be inferior to that of the observer, especially if we avoid any self-deception on the part of the patient by constantly altering the number of the fingers and causing the patient to name them, at the same time taking care that the line of vision is not directed upon the fingers instead of the eye of the surgeon.

For the same purpose we may bring a sheet of paper before the affected eye, at a distance of from one to one and a half feet, upon which a number of black points are made, which radiate from a common center. The picture of the field of vision may be made from the number and situation of the points, which the affected eye is able to recognize in fixing its view upon the center. The best method, however, is to place the patient before a blackboard about one foot from it, then to cause him to fix his eye upon one point in it, while the examiner moves a piece of chalk around the periphery of the field of vision, and thus indicates exactly the spot where the chalk enters the visual field. Yet this does not make an exact boundary. Small interruptions, slight impairments in conductive power, are not m

sometimes distinct, again ill-defined; that is, the distinctness of the retinal images suddenly increases on a certain line, or very gradually, within a certain zone. This is an important distinction, indicating with some probability, at least, the temporary limitation of the process, or the advance of the disease causing these contractions.

True amblyopic contractions of the field of vision most frequently begin on the temporal portion, but often, also, on the nasal side, rarely above or below. The border generally extends in a tortuous course, deviating more or less from the principal direction. If the defect extends, it does so more rapidly on the periphery of the field of vision than in the parts lying near the center, so that the ends of the boundary have often approached each other, or even run together before the contraction has reached the center or passed beyond it. The field of vision thus becomes slit-shaped.

Fig. 35.

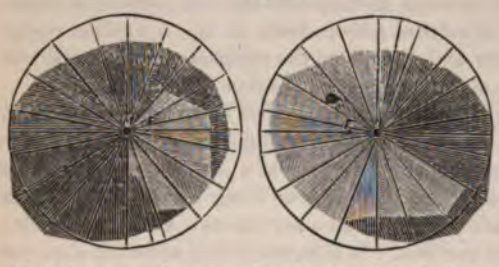

The form assumed by the field of vision in the different stages of the above processes is, moreover, extremely variable. For example, in progressive atrophy of the optic nerve dependent upon tabes, it inclines to the form of a sector, the point of which is turned towards Mariotte's spot (Fig. 35 M after *F.rster*), and this almost always includes a quadrant, lying rather often upward or upward and outward, rarely inwards or downwards. This sector begins as a peripherical limitation which presses more and more towards the center F, while the lateral borders rapidly extend in the periphery, and, finally bending at an obtuse angle, surround a part of the visual field, in order to become limited to the slit-form (*F.rster*).

In isolated cases we meet with concentric limitations, which extend from the outermost portion of the visual field more or less regularly to the center, and thus, in the beginning, diminish very much the function of the whole periphery of the retina, or render it blind. Hemopic contractions also occur, here and there; one half of each retina becomes amblyopic or amaurotic at the same time, or these affections occur within a short time of each other. The hemiopia is then generally iu corresponding sides of the two retinas. It is to be ascribed to a disease of one root of the optic nerve.

Fig. 36.

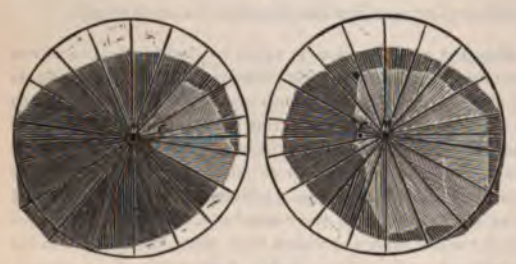

In case, therefore, the morbid process is here strictly limited, the hemopia is sharply cut off by the vertical line of separation of the two monocular visual fields. It descends perpendicularly through the point of fixation F, but has an irregular blunt-hooked appearance above and below the latter; it then bends at an acute angle, and at the periphery surrounds the still normal part in the form of a narrow margin (Fig. 36, after *Förster*).

This form of the hemiopic field of vision corresponds to the division of the nerve fibers. The uncrossed bundles of optic nerve fibers which pass through the chiasm, only supply a small portion of the external half of the retina; the rest receives its fibers from the crossed bundles, which generally enter at the inner side of the papilla, and, partially curving over upon the external side of the retina, likewise inclose the district of the uncrossed bundles.

Homonymous or lateral hemiopia has also been exceptionally observed. It is generally temporal, in which the temporal sides of both monocular visual fields have been obscured, that is, the inner halves of the retina are incapable of performing their functions. They are to be referred to defects of conducting power of the optic nerve bundles crossed in the chiasm (*Sämisch*, *D. E. Müller*, *Loewegren*).

Nasal hemiopia occurs very rarely, in which the nasal sides of both monocular visual fields are obscured, that is, the external sides of the retina and the uncrossed bundles of optic nerve fibers have lost their functional power (*Graefe*, *Pagenstecher*). Amblyopia of the superior or inferior halves of both retinæ has also exceptionally been observed.

Interruptions and limitations of the visual field seldom occurring alone, we are unable to speak of a partial amaurosis. This is most frequently the case in interruptions, not so often in hemiopia, or even in lateral and concentric limitation. Such a condition, where it really exists, is very often only temporary. As a rule, an exact examination of the visual field shows us that the defect is much more extensive, and that it is combined with an impairment of vision extending over the whole of it. Although the symptoms exhibit only a partial increase in the loss of conducting power of the nerves, we generally recognize a very considerable loss in the central acuteness of vision, and with it, an abnormally rapid reduction of the relative power of perception in the adjacent parts of the monocular fields of vision. In the interruptions which lie in or near the center, on the contrary, we often find a regular lessening in all directions of the relative acuteness of vision. More rarely, however, do we see an irregular loss.

According to the above, such conditions differ chiefly from the so-called amaurosis in degree, and not in extent. In the latter affection the perceptive power in the monocular visual field is reduced to quantitative perceptions of light, and is finally completely destroyed.

As long as there is a quantitative perception of light, the iris may possess its reactive power unimpaired. Immobility of the pupil exists only in complete amaurosis, or where paralysis of the ciliary system or mechanical hindrances render the movements of the iris impossible. A good objective evidence of the reduction of vision to quantitative perception of light, and still more of absolute amaurosis, is found in the unsteady, and particularly in the excessive, movements of the affected eyeball. This evidence is only rarely wanting, if the other eye is covered, while a partial and indistinct qualitative perception of light is sufficient to keep the globe in a certain direction for a time.

In order to detect a simulated amaurosis we scarcely need deceptive manœuvers with prisms or the stereoscope, as many think. They endeavor to confuse the patient by placing prisms with the base upwards or downwards before the supposed amblyopic eye, and thus try to produce binocular diplopia (*Graefe*); or by covering the pupil of the normal eye, sometimes partly, sometimes entirely, with the angle of a horizontal prism unbeknown to the patient, and thus causing the conditions for monocular and binocular diplopia to change in a manner which is difficult for the patient to determine (*Alf. Graefe*). Another method is to place a prism horizontally before the eye, and to choose as object lines, of which two run parallel to the axis, and a third perpendicular to them. These must necessarily be seen double in the binocular visual act (*Berthold*). Others judge of the functional capacity by the corrective adduction brought about in the interest of binocular single vision by a prism held before the eye with

the base outwards (*Welz*). Finally, the same end can be reached by bringing a ruler between the eyes and a specimen of type, and then changing its position unbeknown to the patient, so that sometimes one eye is covered, sometimes the other (*Javal*).

It is not to be denied, however, that some patients betray themselves by such a procedure, and the result shows that binocular double images exist. But these experiments indicate nothing more than that qualitative perception of light exists, but by no means exclude a severe amblyopic impairment of vision. Moreover, it is well to remember that all these experiments must fail where the common visual act fails, and that monocular vision is something very usual in cases in which one eye has been injured from whatever cause. These experiments may, therefore, lead so much the more easily to false conclusions, as by experience we know that simulated affections are but very rarely purely imaginary, but rather represent, as a rule, exaggerations of existing weakness.

[Graefe's method of detecting simulated amaurosis, by means of prisms placed before the sound eye, seems to us to be of more importance than is here ascribed to it by Professor Stellwag. We add another method. Since, in simultaneous vision with both eyes, the separated fields of the stereoscope are united in one, simulation becomes evident if we find this union in a case of alleged monocular amaurosis. We have, for instance, in the one field, horizontal parallel lines about one-quarter of an inch apart, in the other, vertical parallel lines the same distance from each other; then in the united field of vision both systems of lines are united in regular squares. As soon as these signs are seen, therefore, we know that there can be no monocular amaurosis.

We may even go a step further, and use the stereoscope quite independently of the existence of simultaneous vision with both eyes. In this respect it is superior to the prisms. If we draw in each separate field of vision a vertical line, whose image passes through the center of the retina, then in the united stereoscopical field, not only are both lines seen as one, but every object situated to the right of one of those lines is projected to the right side of the field of vision, and appears as if it were seen with the right eye. The same, of course, is the case with the left eye. This gives us the means of determining, in cases of simulated monocular amblyopia, the acuteness of vision, and, if necessary, even the range of accommodation.

For this purpose we arrange matters as follows: We have at the bottom of the stereoscope a sheet of paper marked only with the two lines above-mentioned. Now, if we have a case of alleged amblyopia of the left eye, we place in the left field of the stereoscope, but to the right side of the vertical line, any object, say a piece of printed paper. With this exception the whole of the bottom of the stereoscope is left blank. In the united stereoscopic field the paper will then appear as if on the *right* side. It will make so strong an impression of being seen with the right eye that it is doubtful if any one is able to resist it. With a stereoscope which allows the convex lenses to be approached to or withdrawn from the bottom of the stereoscope, we may, at the same time, ascertain the range of accommodation (*Schweigger*).]

Pathogenesis.—The opaque atrophy of the retina and optic nerve is always developed from a manifest neuritis or neuro-retinitis. The transition from one condition to the other is, as a rule, very gradual and not always entirely symmetrical in all parts of the previous inflammatory focus. It is usually connected with a marked clearing up of the inflammatory opacity, which is explained in part by the absorption of the fatty products alone; but is also due in part to a successive transformation of the connective-tissue stroma, and the increase of the optical homogeneousness connected with it. In fact the characteristic opacity of the fundus is not uncommonly seen to diminish considerably in course of time, with continual diminution of the power of vision, and it sometimes even happens that the periphery of the tendinous white papilla becomes again perfectly distinct and the retina almost invisible. In such a case the ophthalmoscopic appearances resemble entirely those of pure atrophy.

The transformation of the opaque into the gray atrophy naturally follows so much the more easily and completely, the less productive has been the preceding inflammation. Moreover, since the exudation is often extremely slight and difficult

to demonstrate ophthalmoscopically, it not uncommonly appears as if the neuritis or neuro-retinitis had passed directly into pure atrophy.

There is, therefore, a species of connecting link between the inflammatory atrophy and gray atrophy, in the latter of which the stage of irritation is only manifested by slight hyperæmia and swelling, and is, therefore, often overlooked. There is at first but little disturbance of vision, and the patients frequently only seek medical advice when the shrinking has already begun.

From all this it appears that there exists between the inflammatory and the primary atrophy not so much an essential difference, but rather one of degree; for we often meet simultaneously with both forms in different parts of the retina and optic nerve, and even near one another in the same region.

Cases moreover frequently occur, in which it is extremely difficult to make the ophthalmoscopic appearances and the subjective symptoms agree with the resulting atrophy. Very often the characteristic sign of atrophy, the paleness of the optic papilla, appears so rapidly after the development of the original disease or after the effect of some injury, that there cannot properly be any question of an intervening destruction or shrinking, even when the natural translucency of the papilla and the extinction of other objective signs do not militate directly against the idea of such a degeneration. The paleness, at first limited to a small portion of the papilla, rapidly extends, without any signs of a previous hyperæmia and swelling having been noticed in the affected parts, until finally the whole papilla appears clear white, and in the upright image has a bluish or greenish color, particularly with a mirror of low reflecting power, which is said to depend upon a peculiar change in the nerve-fibers (*Ed. Jaeger*, *Mauthner*). The disturbance of vision is also extremely variable in degree and time, and may in fact improve permanently or at least for a long time with or without a return of the natural reddish tint of the papilla, so that the acuity of vision approximates the normal standard, particularly at the center. As a rule, however, the power of vision diminishes more and more, with intervening improvements, while the objective appearances remain the same for months and even years. Finally the larger vessels begin to shrink, and we have the image of a true atrophy in all its well-marked characters.

Looking at all these signs together, we can scarcely divest ourselves of the supposition that it depends at first chiefly upon a lack of blood in the small vessels, and that the peculiar discoloration of the nerve-fibers as well as the indubitable atrophy, which is usually developed, are secondary conditions, which are caused by the defective blood supply. In so far now as there are grounds for believing merely in the rarest cases, which admit of the lack of blood in the small vessels being referred to a mechanical hindrance to the circulation, and because, even when this were actually supposable, the numerous anastomoses between the vessels of the optic papilla and choroid must very soon open a way around it by collateral circulation; therefore, there is evidently nothing left but to consider spasms of the vessels as the cause of the lack of blood, although the long continuance of the ischæmic condition can with difficulty be made to agree with this.

This hypothesis, being presupposed correct, would regard the relation of the simple discoloration of the optic papilla to true atrophy as that of cause and effect, and would require a strict separation of the two conditions. In practice, however, they are too little distinguished from one another, to admit of the separation being correctly carried out. It is true that the perceptible shrinking of the large vessels is designated as the indispensable condition for the recognition of a real atrophy, and where this is absent, we speak merely of a discoloration

(*Ed. Jaeger*, *Mauthner*); still it is evident, that when the symptom in question is unequivocally present, the atrophy must already be far advanced, and it is not an easy matter to arrange the lower degrees of development of the process in the nosological system as entirely different conditions, which cannot be distinguished from the discoloration.

If we recollect that one and the same cause leads primarily, under apparently exactly similar conditions, sometimes to discoloration, sometimes to rapidly progressive atrophy, sometimes to manifest inflammation; if we recollect further, that these conditions also pass directly into one another and are connected with one another by numerous intermediate forms: then we can scarcely doubt their close relationship, and we shall not perhaps err if we suppose them to be merely different forms of reaction of the sympathetic nerve. It may be inferred, moreover, from the frequently demonstrable sensibility of the cervical cord, and from the still small number of cases in which galvanization of the cervical sympathetic produced marked improvement of the above conditions (*Benedikt*), that the latter plays no unimportant rôle.

Causes and Course.—*A*. The affection of the optic nerve which culminates in pronounced atrophy of the nerve and retina, very frequently develops itself primarily. The process is then often limited to the anterior part of the optic nerve and does not extend beyond the chiasm. In other cases, however, it does extend over to the other optic nerve and corpus striatum of the same side. It may usually be followed in the latter as far as the geniculate bodies, exceptionally as far as the nuclei of origin in the optic thalami and corpora quadrigemina, or even along the connecting fibers into the posterior columns of the spinal cord or into the cortex of the brain.

1. The proliferative process, in the intracranial part of the nerve, often begins primarily, and passes through all its phases without affecting any other part of the cranial cavity. In such cases the impairment of vision, with any abnormal ophthalmoscopic appearances of atrophy of the nerve or of neuritis that may exist, are the only symptoms. At the greatest they may be united with paroxysms of headache.

The diagnosis of primary and pure affection of the optic nerve is chiefly based on the absence of any important concomitant symptoms. Still, it should be remembered, that not unfrequently destructive processes run their course in the cerebrum, morbid tumors grow to a considerable size, etc., without betraying any marked symptom. On the other hand, it should not be overlooked that exceptionally several cerebral nerves begin to proliferate at once, although there is no connection between the inflammatory foci, either in the substance or the membranes of the brain.

A greater diagnostic importance is ascribed by many to the pain in the head than it actually deserves. It may be wanting, or it may be present, in every pathogenetic variety of amaurosis. There is a source of irritation for amblyopic eyes in the increased straining to which they are subject. This, as in asthenopia, may be transferred to the vaso-motory nerves, as indicated by the overloading of the vessels of the conjunctiva, retina, and optic papilla. Such pain generally disappears after giving up all use of the eye. In isolated cases, however, the irritation from the seat of local inflammation may radiate, and thus the headache may play a similar part in primary affection of the nerve, as pain in the spinal cord in gray degeneration of the posterior portion (*Graefe*). Here, as there, the pain has a congestive character, increases at every disturbance of circulation, in stooping, or any sudden motion, etc. It thus is not very different from that which accompanies intracranial hyperæmia otherwise caused, and which often appears in company with true encephalitis or meningitis.

Primary affection of the optic nerve often occurs without any decided or sufficient cause. Occasionally there seems to be a hereditary disposition to the disease.

Thus cases by no means uncommonly occur, where several members of one family (*Himly*, *Mooren*, *Graefe*), even in several succeeding generations (*Beer*), become amblyopic during certain periods of life. Still it is here not always a question of primary disease of the nerve, but often of intracranial troubles of another kind, states of congestion, etc., which only lead indirectly to proliferation in the optic nerve.

In other cases there may be similar exciting causes, with those of diffuse and nephritic neuro-retinitis.

We can not see why such injurious influences chiefly affect the optic papilla. On the other hand, under such circumstances, the characteristic ophthalmoscopic symptoms occasionally precede the impairment of vision, and allow us to believe that the morbid process gradually proceeded from the deeper parts of the nerve to the eye.

The affection of the optic nerve may moreover be caused in a purely mechanical way by division of the connection or by sudden limitation of a part of the sensory apparatus by hemorrhagic extravasations, serous exudations, inflammatory foci or secondary formations in the orbit or within the skull (see Diseases of the Encephalon). It is then, however, usually not so much the compression as such, as the encroachment of the morbid process, which occasions the affection of the nerve.

In one case the affection of the optic nerve could be referred to an extravasation, which surrounded the chiasm and compressed it (*Stevenson*). One or both roots of the optic nerve have twice been found lacerated by splinters of bone which had been loosened from the base of the skull (*Steffan*, *Chassaignac*). The source of binocular amaurosis more often lay in apoplectic destruction of tissue or in compression of one optic thalamus (*Beck*, *Andreä* and others) or of other parts of the brain (see Diseases of the Encephalon).

2. In some cases local hyperæmia has been regarded as the cause. Conditions of congestion may doubtless be very important, where the nuclei of origin of the nerve fibers, or these latter have themselves already suffered limitation at any point in their course, whether by neighboring tumors, serous exudations, serous products, etc. Cases of actual amaurosis are then observed, which merely appear or become markedly worse, if a disposition to congestion is occasioned in consequence of increased activity of the heart; but they again recede, either entirely or to the former degree, when the disturbance of the circulation has been lessened or removed. It should moreover not be overlooked, that intracranial over-distention of blood may become indirectly mechanical impediments to function by the œdematous infiltrations accompanying them. Besides, they very easily excite and accompany inflammatory processes, which do not always betray themselves by the characteristic signs of inflammation, but remain concealed often for a long time, even when very rich in products, until finally the signs of gray atrophy or even of a manifest neuro-retinitis descendens are seen with the ophthalmoscope. Still, it is extremely doubtful whether these explanations apply to all cases.

The presence and precedence of certain symptoms of cerebral hyperæmia or perhaps of partial intra-ocular over-distention of the vessels, the often sudden appearance or still more rapid increase of the visual disturbance, the not uncommonly marked variation of the latter according as circumstances favor an increase or decrease of the obstruction; further, the occasional rapid recession of the amaurosis and the results attributed here and there to local blood-letting; finally, the absence of all symptoms pointing to changes of tissue, are sufficient grounds for insisting upon the congestive character of a part of the cases.

With such reservations we may call those cases of amaurosis congestive, which appear sometimes after amenorrhœa (*Mackenzie*, *Himly*, *Lawson*, *Graefe*), at certain periods of preg-

nancy (*Mackenzie*, *Ringland* u. A., *Lawson*, *Kraus*), after violent mental emotions (*Beer*), after attacks of coughing, sneezing, vomiting, during confinement (*Ullersperger*) or excessive muscular exertion of any kind, in consequence of constriction of the neck by tight clothing or by choking (*Himly*, *Mackenzie*), after over-exertion of the eyes, etc. With a like reservation we may class in this category also those cases of amaurosis which are said to have been observed after and on account of the suppression of certain habitual secretions and hemorrhages (*Mackenzie*, *Himly*, *Arlt*, *Graefe*), particularly of the foot-perspiration (*Deval*, *Spengler*, *Mooren*, *Erismann*, *Benedikt*) and the secretion of milk (*Beer*). Many of those cases of amaurosis may also be classed in this group, which have been observed during (*Seidel*) but more frequently after pneumonia, chronic pulmonary catarrh, anginæ, etc., and sometimes in blisters (*Sichel*). Whether the occasional intermittent disturbances of vision accompanying intermittent fever (*Himly*, *Zehender*), as well as the amblyopia occurring in the cachexia of intermittent fever (*Schreder*), should here find their proper place, it is hard to determine.

3. In other cases the affection of the optic nerve has been connected with an anæmic state. In this category are those cases of amaurosis which are met with, sometimes with great anæmia, in the later stages of diabetes, and after severe diseases in consequence of exhausting drain of the fluids of the body (*Mackenzie*, *Himly*), in extreme chlorosis (*Cunier*), but particularly after metrorrhagia (*Arlt*, *Mooren*), hæmoptysis (*Rittmann*), gastric hemorrhage (*Ed. Jaeger*, *Graefe*, *Fikentscher*, *Sellheim*, *Mooren*, *Jacobs*, *Colsmann*, *Hutchinson*). The amaurosis is generally bilateral, and was frequently preceded by disturbances in other nerves, so that they could only be regarded as one of the signs of extensive intracranial affections. The amaurosis was often announced by a gradual sinking of the relative acuity of vision throughout the whole extent of the visual field, generally with lateral deviation at first, sometimes varied in degree, or even receded completely. In other cases the disturbance of vision advanced very rapidly to complete loss of the perception of light, or appeared suddenly, remained several days or weeks at the same point, and gradually disappeared entirely, or left behind it considerable defects. As a rule, however, whatever the course taken, the signs of beginning atrophy of the optic nerve showed themselves within a short time, more frequently after certain signs of inflammatory proliferation had first appeared in the optic papilla and retina. Sometimes, it is true, there is a transient improvement of the visual power, but never a true cure; the atrophy rather appeared to be always progressive, even when subsequently the original affection had been permanently removed, and the function of the other affected nerves had been brought up to the normal standard.

As regards the connection between amaurosis and loss of blood, we should particularly consider that the former often did not make its appearance until after the hemorrhage, even after the equilibrium in the vessels had been restored; further, that the hemorrhage did not by any means appear so considerable as to admit of deducing from it alone an anæmic condition (*Graefe*). It is therefore very probable that the affection of the optic nerve must be referred to vasomotor disturbances. The extreme attenuation of the retinal vessels, which has been observed in same cases (*Graefe*), agrees with this view; and the marked opacity of the retina and papilla, seen by others (*Ed. Jaeger*), may be referred first as well to inflammation as to fatty degeneration of its elements, in consequence of defective blood supply.

Diabetic amaurosis has been discovered to be in great part merely a paresis of the accommodation (*Graefe*, *Nagel*). In some cases there was a manifest neuro-retinitis. The more frequent accompaniment and isolated occurrence of functional impediments in various other nerves (*Seegen*), as well as the observation of hemiopic limitations of the visual field (*Graefe*), indicate that the intracranial affection which lies at the bottom of the rest of the cases of amaurosis, and has also been demonstrated several times (*Luys*, *Tardieu*), may form foci, which vary very much in situation and size.

4. In another series of cases the cause is sought in the action of certain morbid or foreign substances, mixed with the blood, upon the central organs, nerve, and retina. At the head stands the saturnine amaurosis (*Beer*). It is true the suspicion has been justified that many of the older observations might be referred to mere paralysis in the ciliary system. In some cases albuminuria may also have been at work (*Danjoy*), or the cause may even have been a nephritic neuro-retinitis (*Desmarres, Lancereaux, Lecorché, Follin, Danjoy, Ed. Meyer*). Still it is a fact that lead-poisoning can really cause amaurosis. It has been exceptionally observed after a preceding violent headache, other nervous symptoms being absent (*Desbois, Tanquerel*), and has again disappeared (*Hirschler*), though it also may become permanent (*Rau*). As a rule, however, it is not developed until after repeated attacks of colic or other forms of lead-poisoning. It is then sometimes developed very gradually, and is soon associated with a demonstrable atrophy of the optic nerve. More frequently it appears suddenly accompanied by other alarming nervous symptoms during an acute attack of lead-poisoning, and then usually increases rapidly, to complete transient or permanent blindness. If all signs do not deceive, anæmia of the brain, with or without œdematous swelling, is the greatest cause, not only of the various nervous symptoms, among which we rank the disturbance of vision, but also the *constipation* and the *diminished secretion of urine*. The anæmia itself is again to be referred to the action of the lead, demonstrated chemically in the brain (*Bouillaud*), upon the small vessels (*Rosenstein*). Connected with this is the *uræmic amaurosis*, as this form seems also to depend upon *anæmia of the brain*, and is to be derived from the action of the urea retained in the blood upon the vasomotor nerves (*Traube*).

Recently the abuse of alcoholic drinks has again been regarded as a cause of amaurosis, and as a proof of this the circumstance that by complete giving-up of alcoholics the disease may often be brought to a standstill or may even be cured (*Sichel, Erismann*). Of this we are certain, that amblyopia is observed in an extremely large percentage of cases in habitual drinkers. Symptoms of irritation of the brain as a rule precede its appearance, and marked hyperæmia of the optic papilla may in the beginning be demonstrated in the majority of the cases. Later the symptoms point to torpor of the brain, while the optic papilla becomes gradually pale and finally shows all the characteristic signs of atrophy. The disturbance of vision often manifests itself at the beginning of the affection under the form of nyctalopia, but the amblyopia soon becomes entirely manifest. The latter generally increases slowly, often with interruptions up to very considerable degrees, without there being any limitation or defect of the visual field. The power of distinguishing colors as a rule remains perfectly normal. Sometimes, however, chromatodesopsia, sometimes red-blindness, may be demonstrated in the central portions of the retina (*Leber*). Amblyopia potatorum is always binocular, and is developed in both eyes to about the same extent. It seems that with the development of this condition, together with the action of alcoholized blood upon the brain, the most various disturbances of nutrition, caused by the drinking and the coincident irregular life, may be of pathogenetic significance (*Erismann*). Many believe that chronic meningitis should be regarded as a frequent exciting cause.

The abuse of tobacco is also said to play a part among the causes of amaurosis (*Mackenzie, Sichel, Loureiro, Hutchinson, Thielesen, Jackson*), and this hypothesis is corroborated by the

frequent recession of the affection after complete abstinence from this article of luxury. The tobacco amaurosis is said to appear independently but very rarely, and is much oftener connected with the alcoholic amaurosis, and moreover only occurs in persons who smoke the commonest sorts of tobacco in very dirty pipes. It is believed that the affection of the optic nerve is to be explained by the action of large quantities of nicotine upon the brain (*Erismann*).

As regards those cases of amaurosis which are said to have been occasioned by large or frequently repeated doses of opium, mydriatics, Ignatius bean, nux vomica, etc. (*Beer*, *Himly*), by ergot (*J. Meyer*), the same thing holds good. Still these forms have been much less sufficiently investigated, and we can only so far satisfy ourselves that the majority of the cases may have been confounded by mydriasis. Amaurosis has been twice met with after large doses of quinine, and it is believed that congestion is occasioned by the administration of quinine, from the fact that cures are brought about by local bleeding (*Graefe*).

5. There is no doubt that a pathogenetic connection exists between the amaurotic affection of the optic nerve and certain severe febrile diseases, acute exanthemata, typhus and puerperal fevers, etc., even pneumonia, angina, acute intestinal catarrh, etc. In the course of these diseases we sometimes meet with a bilateral amaurosis, which develops in a symmetrical manner very rapidly, and is then accompanied by a high degree of mydriasis. More rarely the amaurosis is unilateral, without there being any other symptoms which point to any portion of the brain or meninges being involved. This form of amaurosis often progresses without any demonstrable changes in the interior of the eye; sometimes, however, changes do exist, but are limited to slight, transient, and very variable swelling and opacity of the papilla, as well as to symptoms of slight congestion. The usual result is a cure, frequently with no trace of the preceding trouble (*Graefe*).

In some cases it has been believed that such cases of transitory amaurosis, appearing after typhus or scarlet fever, might be explained by œdema of the membranes of the brain or of the optic nerve (*Betke*, *Ebert*). On the whole, however, the exciting cause is obscure. The circumstance that the iris in this form of amaurosis reacts perfectly as well to reflex irritation as to direct innervation, proves that the hindrance to the conducting power of the optic nerve is situated beyond the corpora quadrigemina, nearer to the cortex of the brain (*Graefe*).

B. In another series of cases the affection depends without doubt upon a sudden interruption in the arterial current in the most anterior part of the retina and optic nerve, since the disturbance of vision always appears with lightning-like rapidity, or at least develops within the shortest time, to complete amaurosis, and is accompanied by a very marked diminution in caliber of some or all of the main branches of the central retinal artery. These branches seem under such conditions either completely empty, attenuated to fine, round, white threads, or else an extremely delicate, continuous column of blood, exceptionally interrupted (*Quaglino*), may be recognized in their axis as a red line. The attenuation generally affects the whole length of the arteries and is so considerable, that the secondary branches cannot be perceived, and even the main trunks can only be distinctly recognized at the entrance of the optic nerve and in its vicinity. In other cases the attenuation is limited to parts of the arteries, the portion nearest the porus opticus appears tolerably full, while the peripherical ends disappear entirely (*Knapp*), or the central are almost empty, and the vessels increase in size again towards the equator (*Blessig*). Again a vessel is contracted like a thread in the middle of its course, but contains blood both at the porus opticus and in the periphery (*Sämisch*, *Hirschmann*); or finally exactly the opposite takes place:

an artery appears well-filled for a certain distance, and then becomes attenuated in both directions (*Wecker*, *Just*). A particularly characteristic sign of the affection is that the attenuated arteries cannot as a rule be made to pulsate by a pressure exerted upon the globe, and that no change whatever can be remarked in the caliber of the arteries and veins in this maneuver (*Knapp*). In one case, however, the pulsations were very marked (*Secondi*).

The retinal veins are at the same time generally somewhat smaller than normal, and more rarely are attenuated to thin threads (*Steffan*, *Landesberg*). Sometimes they appear perceptibly contracted merely for a certain distance, particularly in the region of the papilla, but in other places somewhat dilated. Sometimes the central portion, sometimes the peripherical portion, sometimes a piece from the middle is contracted or dilated. In some cases they are very unsymmetrically filled, parts widely distended alternate with portions almost empty, and exceptionally the column of blood has been found several times interrupted, and its several sections seen in irregular, undulatory movements (*Ed. Jaeger*, *Graefe*, *Steffan*, *Liebreich*). In one case a vein contained coagulated blood for a distance, which was just undergoing disintegration (*Liebreich*). Shortly after the appearance of the disturbance of vision the optic papilla appears sometimes pale, sometimes of the same color as that of the sound eye, sometimes distinctly reddened, and usually its blood-contents vary during the cause of the affection. Its margin is at first entirely distinct, but sometimes, usually after the lapse of a few hours or days, rarely later (*Graefe*), the retinal tissue begins to become cloudy near the papilla as well as in the region of the macula lutea. The opacity is very dense, grayish or bluish-white, tolerably homogeneous, or slightly cloudy with diffuse edges, exceptionally finely dotted (*Graefe*), and later in the disease sometimes interlaced with vessels. It usually extends from both the above-named starting-points in all directions, but may also be limited to the region of ramification of a single main branch, in case the latter alone was empty of blood, and may be developed at any portion whatever of the fundus (*Just*, *Blessig*).

The fundus itself appears in its normal coloring where it is not covered like a veil by the opaque retina. In the region of the macula lutea, however, it becomes darker, as a rule, though not always (*Schneller*, *Quaglino*), and appears like a deep blood-red spot of varying size and form, in which extravasations of blood may often be demonstrated with certainty. Hemorrhagic extravasations are by no means uncommon, and are occasionally found in the most various spots, particularly in the region of the papilla. They sometimes do not appear until very long after the commencement of the affection.

The power of vision is almost always entirely destroyed from the first. In some cases, however, the amaurosis remains partial, and appears as a limitation, which in situation corresponds to the region of ramification of an empty main branch.

Sometimes the attenuated arteries again fill in course of time, but attain only very rarely a normal caliber (*Fano*, *Landesberg*). The veins, on the contrary, frequently regain their former degree of fullness. The opacity of the retina usually disappears completely within a short time or becomes somewhat loosened, and then appears under the form of a finely punctate cloud. The red spot in the region of the macula lutea also becomes gradually pale, and finally entirely unrecognizable. The power of vision, however, is only reëstablished in the most rare exceptional cases (*Schneller*); a temporary improvement is the most which is observed, which soon recedes if the first signs of the ever-succeeding gray atrophy appear.

The explanation of these symptoms has been sought sometimes in an embolus, sometimes in an over-balance of the contractility of the vessels over the intra-vascular blood-pressure, and sometimes in a compression of the central artery in consequence of a retrobulbar neuritis.

If we consider all the cases of so-called embolus of the central retinal artery which have been published, we find that the hypothesis of an obliteration of the central artery by an embolus can really be maintained only in a single case, in which an embolus is said to have been actually found (*Schweigger*). If, however, we study the drawings of the case, we cannot for a moment doubt the insufficiency of the observation, for it is perfectly impossible that an embolus, after existing for a year and a half, should appear like a clay pellet in a pea-shooter. After such a lapse of time, an embolus must have been completely destroyed in the shrinking masses of exudation, and thus it would be impossible to distinguish it from inflammatory thrombosis. In the remaining cases all direct signs of an embolus were absent; this was diagnosticated solely from the combination of circumstances, and its seat laid in the retrobulbar portion of the central artery. If, however, we recollect the intimate connection between the arterial branches of the retina and the nutrient vessels of the optic papilla, it becomes perfectly incomprehensible how an obstruction of the main trunk alone should lower the arterial supply to the retina permanently to the smallest amount, particularly as under other conditions, *e. g.*, in glaucoma, after division of the optic nerve close to the globe, etc., the development of a collateral circulation succeeds without difficulty. By the displacement of an embolus in the ophthalmic artery (*Steffan*), however, the difficulty of a correct explanation is increased, and it is entirely overlooked that during the whole course of these cases not a single symptom points to a transient deficiency of blood in the choroid and adjuvant tissues of the globe. Besides all this, the arteria ophthalmica is given off from the carotid at almost a right angle, and this is extremely unfavorable for the conduction of an embolus into the very narrow central artery (*Knapp*). Finally, the chief objection is, that in a very pronounced case of so-called embolism, the embolus has been searched for by trustworthy hands and has not been found, a sure proof that all the above symptoms may also be developed without obstruction of the central artery (*Iwanoff*).

In favor of the dependence of retinal ischæmia upon diminution of the lateral pressure in the arteries, it has been asserted that the condition appeared with an extremely weak scarcely perceptible action of the heart and pulse; that in one case an extreme depression of the general nutrition and extreme anæmia after typhus fever seemed to furnish the cause (*Hedäus*); finally, that a greater filling of the retinal arteries, and consequently a considerable increase in the power of vision, has been obtained by iridectomy (*Alf. Graefe*), or repeated paracentesis of the cornea (*Secondi*), relatively by improvement of the nutrition, which, in one case, ended in permanent cure. It has been assumed that the central artery has been compressed by the intra-ocular pressure, when its contents flow on under slight cardiac pressure, and that the supply of the blood might sink below the amount necessary for the functional activity of the retina (*Alf. Graefe*). In so far, however, as the intra-ocular pressure is determined in amount by the pressure of the blood, this hypothesis contradicts itself.

As regards finally the compression of the central artery by retrobulbar neuritic exudations (*Graefe*), not only are all objective proofs of this wanting, but several symptoms are moreover markedly opposed to this view. These are: the sudden blindness with previously normal power of vision, the absence of symptoms of congestion, and particularly the non-development of the collateral circulation in spite of the presence of anatomical conditions for an injection of the retinal vessels from the choroidal circulation. How else could the empty condition of a single main branch be explained?

Looking at all this testimony, we necessarily arrive at the conviction that we have here to do with spasms of the vessels (*Zehender*), which sometimes extend to all the trunks of the central retinal artery, even including their corresponding veins, sometimes are confined to several arterial trunks, or even to portions of them, and render the collateral injection impossible by reason of the active contraction of the walls of the vessels. The sudden blindness, moreover, and the frequent prece-

dence of temporary attacks, agree well with the spastic character of the affection (*Schneller*, *Knapp*, *Mauthner*), as well as the observation of a case in which the ischæmic amaurosis repeatedly recurred during a long time under the form of transitory attacks, and could even be produced at will by the action of cold (*Secondi*). Moreover, the circular, unflattened form of the narrowed vessels, the thread-like form of the column of blood contained in them, the generally almost imperceptible passage of the full parts of the vessels into the empty, and the attenuation sometimes of central, sometimes of peripherical, sometimes of intervening portions of the arteries and veins can be made to correspond solely to spasmodic conditions of the muscular walls. In like manner the unchangeableness of the caliber under an external pressure exerted upon the globe, and the impossibility of exciting pulsations by these means (*Knapp*), can not be satisfactorily connected with any other conceivable disturbance of circulation. The defective filling of the veins, so far as it does not depend upon spasmodic conditions, results naturally from the insufficient blood supply, and the interruption as well as the oscillatory motion of the column of blood contained in the veins can be very easily explained by the weakness of the cardiac pressure acting from the arteries through the capillaries. The dark-red spot in the region of the macula lutea, and the not unfrequent subretinal hemorrhagic extravasations, as well as the detachment of the choroid observed in one case (*Liebreich*), may be laid to the account of a great distention of the choroidal vessels, which is evidently of a compensatory character. The veil-like opacity in the region of the papilla and retina, which always yields sooner or later to the symptoms of gray atrophy, may, moreover, be referred as well to fatty degeneration and sclerosis of the elements, as to inflammatory exudations, until exact observations upon the cadaver have decided the question.

We must not object to these explanations, that the arterial current must be discontinuous in a pressure acting upon the globe from without inward, in order to cause darkening of the visual field, and that in the stage of asphyxia of cholera, with a diminished blood supply, the vision of the patient does not essentially suffer; for it is evident that the spasm, which frequently appears simultaneously in the arteries and veins, prevails to no less degree in the capillaries, and must naturally limit the function of the retina much more than is the case in the above-mentioned conditions, where the capillary net-work suffers little in distention, as the normal coloring of the fundus in respect of the choroid irrefutably represents. Besides all this, spastic contractions have also in fact been observed under other circumstances, during epileptic attacks, where they have with reason been connected with the accompanying disturbances of vision (*Jackson*), and once in glaucoma, where the veins presented the appearance of a pearl-necklace (*Liebreich*), and thus repeated a condition which is found in the intestinal vessels in cases of poisoning by calabar bean (*Bauer*).

C. The affection of the optic nerve causing amaurosis is very often the result of certain localized processes in the cerebrum.

1. Basilar meningitis is very prominent in this respect; it may be either primary or secondary. When appearing in an acute form the disease can not be mistaken.

In the chronic insidious cases, however, there are sometimes no decided symptoms. Febrile attacks may occur; permanent, often excruciating headache, which may be increased by tapping the side of the head; fullness in the head, tottering, frequent vomiting, etc., which will be diagnostic aids.

Occasionally these symptoms are very obscure, or are only seen at intervals, so that the affection may be easily overlooked; but there is generally an indication, from the fact that, corresponding to the great tendency to exten-

sion of surface which characterizes this form of meningitis, a number of cerebral nerves are generally affected, and symptoms of paralysis, as well as those of irritation, are apt to occur. This is not so much the case in other intracranial morbid conditions.

Paresis of some muscles, with morbid contractions of others, are very often observed. (*Graefe.*) The amaurosis itself is apt to be accompanied by evidences of hyperæsthesia of the optic nerve, photopsia, chromopsia, &c. A more important circumstance is, that the proliferation of tissue always passes from the arachnoid and pia mater into the cortical substance of the brain, and goes to a considerable depth, e. g. in the optic thalamus. (*L. Meyer.*) The affection of the optic nerve, under such circumstances, appears during the course of the meningitis. In acute forms of the latter, the impairment of vision often shows itself shortly after the appearance of the principal disease, and goes on rapidly to blindness. In chronic meningitis, on the contrary, the optic nerve frequently remains unaffected for a long time, or the impairment varies in the beginning, becoming worse and then better, or disappearing entirely for a time, until it is at last completely seated, and goes on slowly or rapidly. In the first case, the affection of the optic nerve has almost always the character of an inflammation, and the ophthalmoscope shows it to be a descending neuro-retinitis. In other cases there is gray atrophy of the nerve; at least, it appears like this, as seen with the ophthalmoscope.

Exceptionally, amaurosis and decided marks of atrophy of the optic nerve do not occur until a long time after the complete disappearance of the meningitis. It seems, then, as if the cause were not so much an immediate continuation of the inflammation from the membranes of the brain to the envelopes of the nerve-fibers, but rather a contraction of the intracranial portions of the nerve, and of the accompanying nutrient vessels, through shrinkage and obliteration of the portions of the membranes which have been inflamed. The post-mortem examination has often shown actual tying together of the affected nervous cords, by cicatritial tissues.

It is evident that all the causes of meningitis, whatever they may be, must be reckoned among the remote causes of amaurosis. Thus, tuberculosis, scrofula, rheumatism, pyæmia, typhus fever, puerperal fever, the exanthemata, injuries (*Pagenstecher*), on account of their frequency, deserve mention as such causes. We have already spoken of the great swelling of the optic nerve in inflammatory œdematous conditions of the membranes of the brain, such as exceptionally occur in Bright's disease. Finally, facial erysipelas may be mentioned as a cause of amaurosis, it frequently being accompanied by meningitis. More frequently, however, erysipelas seems to act on the optic nerve from the orbital tissue, and thus leads to amaurosis, whose origin is either a true neuritis, or simple atrophy (*Arlt*), and may be often a temporary affection, of not very decided character (*Fronmüller*).

2. In some cases periostitis of the base of the skull, with its coincident conditions and results, is the cause of intracranial affections of the optic nerve. If it appears acutely, there is generally pain in the head, in the beginning. This is usually described as violent in character; it continues for some time, but then recedes and only appears again at intervals. A slight tap on the temporal region, especially if one side be touched immediately after the other, causes pain, and this seems to radiate from a certain part of the base of the brain. The impairment of vision begins very early, and generally advances rapidly to a certain hight. Not unfrequently, in the beginning, diffuse cerebral symptoms are also observed, and, besides, paralysis or spasmodic contraction of some of the muscles supplied by cerebral nerves. Especially in acute periostitis, the inflammatory irritation extends far beyond the borders of the chief seat of inflammation, and involves parts lying some

distance off. But if the severity of the first attack be over-subdued, the seat of the disease narrows, and in the remaining morbid conditions a circumscribed affection of the base of the brain is observed.

The amaurosis is, then, in accordance with the situation of the latter-named affection, a hemiopia of the same side in both eyes (*Graefe*), or it may be a total blindness of one or both eyes.

But where, on the contrary, the periostitis is chronic in its course, from the beginning, even the characteristic pain may be absent, or only appear at intervals with slight severity, and not remain for a long time. Tapping on the head may also cause no pain. The diagnosis is then generally very difficult. The very vague and diffused cerebral symptoms, as well as the limitation of the affection to nerves which pass over a certain part of the base of the cranium, may also occur in tumors of the base of the brain.

Moreover, these symptoms are often obliterated by the existence of a secondary meningitis, extending over a large space. The affection of the optic nerve is doubtless, in the majority of cases, to be explained by immediate transplantation of the proliferation of tissue upon the neurilemma. In acute periostitis it is generally a true neuritis. In chronic periostitis it is frequently gray atrophy; yet it is sometimes to be referred to pressure upon the nerves and their nutrient vessels. The most favorable opportunity is afforded for this, if the morbid collection extends to the optic foramen, narrowing its caliber by the development of a tumor; yet even compression is not always the immediate cause, but often there is a transition of the proliferative process upon the interstitial tissue of the optic nerve. (*Horner*, *Koster*).

These conditions, and the immediate connection of the bones of the face with those of the base of the skull, furnish the key for the fact, that amaurosis sometimes results from traumatic periostitis of the orbit (*Horner*), from ozœna (*Jüngken*), from abscesses of the antrum, with subsequent caries of the orbit, as is often caused by diseased teeth. (*Salter*, *Buzer*.) In other respects, the etiology of basilar periostitis is the same as that of periorbitis.

3. Tumors of the base of the brain play a very prominent and exceedingly variable part, in the origin of intracranial affection of the optic nerve. It occasionally happens that the nerve itself is involved in the morbid growth, being perforated, as it were, by the tumor, and loses its conducting power through the destruction of the nervous elements, which takes place for some distance. The peripheral portion then generally becomes atrophied; exceptionally, however, the symptoms of a manifest inflammation are seen with the ophthalmoscope. Much more frequently the tumor affects the nerve in a purely mechanical way, surrounding a portion of it, and pressing it together; or it crowds it to one side, and thus causes a considerable distension; or presses it against the bones beneath, or finally compresses it within the optic foramen. The reaction of the nerve to these influences is almost always in the form of gray atrophy, which is continued with more or less rapidity upon the globe. But it is not necessary that there should be immediate contact between the tumor and the intracranial portion of the optic nerve. The brain itself is often the agent in transferring the morbid process; since, in consequence of the increase in the contents of the cerebrum, and of the intravascular pressure, it presses with increased power on the bony substratum, and thus cuts off or flattens out the optic nerve in some portions.

Exceptionally, the tumor presses the cavernous sinus together, or grows into it. Thus, venous congestions are caused in the veins belonging to the ophthalmic artery. These locate themselves by preference in the optic papilla, and the anatomical structure at that part increases the resistance to the vascular current.

Yet basilar tumors are most frequently injurious to the optic nerve and retina, by the irritation which they set up in their vicinity. Of course these are, in many cases, confined to the adjacent parts; but they often first attack the arachnoid and pia-mater, and thus reach more remote nervous tracts as meningitis, or the compressed cerebral portions are affected with inflammation, softening, gray atrophy, with or without cerebral hemorrhage. (*K. Fischer, H. Jackson.*) If, then, the optic nerve falls within any of these parts, where this reaction occurs, it is soon involved in the process in the form of gray atrophy or manifest neuritis. If the morbid process be once excited, it soon continues in a centrifugal direction, so that it may be observed with the ophthalmoscope. Yet the ophthalmoscopic symptoms do not always correspond to the intracranial morbid processes. An actual inflammation of the deep portions of the nerve is not unfrequently seen on the optic papilla as gray atrophy. Occasionally the character of the objective symptoms varies, the evidences of a descending neuro-retinitis give place to those of atrophy, or the latter begins the process, and in the course of the disease, its symptoms are concealed by those of a decided inflammation. It is certainly entirely incorrect to believe that the appearance of gray atrophy in the optic papilla renders the subsequent occurrence of a true neuro-retinitis impossible, but it is a somewhat rare occurrence.

From all this, it is seen, that an exact consonance between the anatomical situation of the disturbances of function and of a basilar tumor does not necessarily exist, or does not even frequently occur. Sometimes, however, we have an opportunity, from a temporal hemiopia and the coexistent symptoms, to conclude that the tumor is in the median line of the base of the brain, close in front of, or behind, the chiasma (*D. E. Müller, Sämisch*), or we may refer a hemiopia of the same side on each eye, to a laterally situated inflammation, or a total blindness of both eyes, to compression of the whole chiasma. As a rule, however, the symptoms become very much involved by the results of the disease. The diagnosis is more difficult, because the surface of the tumor often enlarges, and grows irregularly in various directions, or other inflammatory centers may spring from the original ones. In young persons, they may make room by pressure on the bones, and even when they reach a large size, do not necessarily cause correspondingly great impairment of function; for pressure, distension, and tearing of a nerve or its ganglion, if done gradually, is often borne wonderfully well. (*Lebert, Duchek.*)

Very recently a case has been recorded, where a large glio-sarcoma grew through the optic commissure and the adjacent parts of both trunks and roots of the nerve, so that the bundles of nerve-fibers could not be recognized, and there had not been a symptom during life of the existence of an intracranial affection. (*Graefe.*) A tumor, when it really appears, furnishes no characteristic symptoms which allow us to distingnish it from other intracranial affections. The chief symptom is pain, which extends generally over the whole head, often increasing paroxysmally. The pain is seldom localized, nor does it radiate from any definite spot on tapping the side of the head. There is, besides, weakness of certain muscles that readily increases to actual paralysis. These are symptoms which are observed in the most diverse intracranial affections in the most varied combination. (*Lebert, Duchek.*)

We need not say here that tumors of every variety may come into consideration in cases of amaurosis. Sarcomata, and cancerous tumors of the base of the brain, have been shown to be the proximate or remote causes of the affection. (*Lebert, Ladame, Türck, D. E. Müller, Sämisch. Cruveilhier, K. Fischer, H. Jackson, Graefe, Blessig, Koster.*) In rare cases, the cause was exostosis of the *sella turcica*, and in one case, a pointed excrescence, which perforated the optic commissure. (*Beer.*) In another case, there were tuberculous masses, which surrounded and pressed upon the commissure (*Türck, Hjort*); in another, aneurism of the carotid (*Stilling, Giraudet*), or of one of the principal intracranial branches (*Spurgin*), which pressed upon one root or the other of the commissure. In two cases gummy tumors were found, one in the *sella turcica*, from which it extended into the optic foramen. In the other case, there was a layer, several lines thick, which filled up the greater part of the middle cerebral fossa, and affected the conducting power of all the cerebral nerves there (*Graefe, Arcoleo*).

4. Finally, actual disease of the brain, in different forms, should be named as a cause of amaurosis, encephalitis, especially abscesses, softening, tubercles, gummy tumors, and tumors of any kind, hydatids, cerebral hemorrhage, &c. Their relation to amaurosis is much more complicated than that of the basilar tumors. Very often the key is wanting with which to explain the symptoms observed during life, from the post-mortem appearance, since morbid changes, which are seemingly identical, cause similar symptoms in different cases, and the same, or different symptoms, seem to originate from diverse conditions.

One of the chief reasons for the uncertainty in diagnosis still prevailing, doubtless, lies in the want of a sufficient amount of pathological investigation. With few exceptions, observers have confined themselves to an investigation of the site and extent of the disease, with the morbid changes to be observed with the naked eye or magnifying glass, without regarding the finer topography of the central nerve-tracts, and without testing the condition in which the original nucleus of the disease was, as well as the nerves traversing it. But it is certain that such morbid centers often inclose nervous elements, which are uninjured. Yet we see similar occurrences every day in the retina and optic papilla, because here all the morbid changes seen with the naked eye are not in an exact proportion to the impairments of function. Again, minute anatomical changes in the cerebral portions of the nerve easily escape notice, since they do not change its appearance very much. It may, therefore, very easily occur that affections of certain parts of the brain, which involve original nuclei, or connecting cords of one or more nerve-trunks, are at one time accompanied by impairments of function in one or another portion. On the other hand, impairments of function may arise during life, which can not afterwards be explained from the whole appearance and extent of the morbid collection. Besides this, the anatomical distribution of the extremities of the cerebral ends of the nerves is still very imperfectly known. We may easily imagine that, in quite a number of cases, nerves are affected, whose originating nuclei and connecting filaments, according to the present knowledge of their anatomy, are situated at points far removed from the morbid center.

The time has not yet come when we may reduce the situation and extent of a cerebral affection with any certainty from certain symptoms; an anatomical basis is yet to be made, and until this is done, the diagnostic evidences must remain very deceptive (*Lancereaux*), as is sufficiently shown by the long list of striking cases recently presented. (*Lebert, Lancereaux, Ladame, Duchek.*)

It is plain that morbid processes in any part of the brain from which it is known that the optic nerve derives a certain number of elements, or which is traversed by any cerebral or spinal bundles, may be much more frequently a direct cause of amaurosis, than others which are some distance from the portions supplying the optic nerve. The elements of the nerve may be primarily involved in the process, or become so in the reaction. They may also be excited to a proliferative process mechanically, by pressure, tension, or tearing, or their nutrition may be affected under the reflex action, exercised by the diseased center, upon the nerves of the adjacent vascular branches. But if gray atrophy or actual inflammation appears in one of the original nuclei or cerebral nerve-bundles of the optic nerve, the affection, as experience teaches us, is very readily extended along the fibers, in a centrifugal direction. It also attacks the adjacent parts, and appears extended over the whole thickness of the nerve. Since it generally presses toward the periphery, it is usually observed with the ophthalmoscope, and the optic papilla shows simple atrophy or neuro-retinitis. But if the cerebral point of disease is on one side, the changes of tissue proceeding from it undoubtedly affect only one root in the beginning, and therefore the impairment of vision must be confined to the same half of one or both retinæ. As a rule, however, the morbid process extends in a shorter or longer time over the region of the other optic-nerve stria, because, in addition to the opportunities subsequently to be spoken of, the optic commissure affords an exceedingly favorable point for the transferrence of the disease.

In accordance with the distribution of the cerebral portions of the optic nerve, and experience (*Lebert*, *Duchek*, *Ladame*, *Lancereaux*), affections of the *corpora quadrigemina*, and those of the optic thalamus, are almost always combined with amaurosis. The same is true of tumors of the pituitary gland. Yet in the latter case there is scarcely any direct advance of the proliferative process upon the cerebral portion of the optic nerve, but almost always a compression of the optic commissure and of the adjacent parts of the trunk of the nerve. Pathological processes in the lobes of the cerebrum and cerebellum lead to changes in the optic nerve and retina, in a relatively slight percentage of cases; and where they occur, mechanical conditions, such as increased cerebral pressure, or displacement of the optic thalamus and *corpora quadrigemina*, are the cause. Finally, affections of the spinal cord are not unfrequently combined with amaurosis. The centers of the optic nerve lying in the posterior cord are involved, when progressive atrophy is met with in that situation.

It is clear that imperfect development of large portions of the brain, where points of origin of the optic nerve are found, or degeneration as a result of fetal diseases, may cause congenital amaurosis. Cases have been recorded where vision, hearing, and the sense of smell, were absent from birth. (*Sichel.*)

In one case of amaurosis the *corpora quadrigemina* were found completely destroyed by proliferation of connective tissue, which extended into the *pons varolii* and contained numerous masses of tubercle. (*W. Wagner.*) In another case there was neuro-retinitis descendens, with a large apoplectic clot of the left middle lobe, with small blood extravasations in the *corpora quadrigemina* (*H. Jackson*). In a third case a tubercle pressed from the left large cerebral lobe into the substance of the corpora quadrigemina. (*Mohr.*) The latter have been several times found pressed upon by tumors of the hemispheres, and at the same time atrophied (*Jobert de Lamballe*, *Herrison*), or softened (*Bainbridge*), or partially destroyed, the optic thalamus being at the same time displaced and flattened. (*A. Weber.*) Amaurosis is very rarely absent in partial tuberculous degeneration of the region in question. (*Henoch*, *Steffen.*)

In so far as a center lies in the corpora quadrigemina, which conducts the reflex action of the optic nerve upon the papillary branches of the oculomotorius (*Flourens*, *Budge*), it is probable that in this variety of amblyopia the reaction of the pupil to light is more or less completely annulled.

The optic thalamus was entirely degenerated into a vascular substance, in the case of one amaurotic person (*J. Hunter*). In another case, descending neuro-retinitis, had been excited by a sarcoma, which involved the whole of the left part of the thalamus, and which had very much flattened the cerebral convolutions, the pons, and the intracranial portions of the optic nerve (*Leyden*). In one case amaurosis was found to be caused by an apoplectic cicatricial mass, which almost completely replaced the right thalamus, while on the left side there was a recent extravasation of blood (*Quaglino*). Softening of both thalami, with hemorrhage, has also been observed as a cause of amaurosis (*Dufour*). On the other hand, cases are known where, in spite of quite extensive destruction of a thalamus, amaurosis did not occur (*Ladame*). It is especially worthy of mention, that in a case of great flattening of the right optic thalamus, and where several apoplectic points existed in the left thalamus, and in the corpora quadrigemina, there was no amaurosis (*H. Fischer*). In connection with this case, the remark may be ventured, that disease of the corpora striata generally exists without amaurosis, when it does not involve the adjacent thalamus (*Duchek*). On the contrary, they are generally connected with a deviation of the line of vision of both eyes in the direction opposite to the seat of the deposit, and when this deviation is very marked, are sometimes also accompanied by a distinct rotation of the head towards the non-paralyzed side, a symptom which is distinguished as the beginning of the frequent rotatory movements occurring in diseases of the corpora striata (*Manz*, *Prevost*).

Tumors of the pituitary gland and their immediate vicinity, as a rule, cause amaurosis, by pushing the optic commissure upward and impairing its nutrition (*Lebert*, *Duchek*, *Ladame*, *Michel*). Of course the impairment of vision in this case is always binocular, or soon becomes so, if the tumor has arisen exclusively on one side (*Michel*, *Ladame*, *Hjort*), when hemiopia on

the same side of the two retinas, or even monolateral partial amblyopia, may occur. Sometimes such growths press upon the superjacent parts of the brain, push the optic thalamus and corpora quadrigemina to one side, and thus lead to morbid changes in the principal optic centers (*Habershon*, *Hoffmann*).

It may also occur, that both trunks of the optic nerve, shortly after their emergence from the chiasm, are actually ligated by the arteries of the *corpus callosum*, since the tumor presses upward against the arteries (*Türck*).

The amaurosis caused by tumors of the region in question is only temporary (*Beck*); in some rare instances it disappeared suddenly, probably because there was a change in the position of the tumor. (*Michel.*) It may have broken through below, and thus relieved the chiasm; at any rate, such perforations are not very rare. In small tumors of the pituitary gland, there may be no amaurosis. (*Dahl*, *Ladame.*)

Very large morbid centers often exist in the lobes of the cerebrum while the vision is perfect. (*Lebert*, *Lancereaux*, *Duchek*, *Ladame.*) Yet amaurosis often occurs, which can not be subsequently referred to any coincident conditions or results, but must be considered as in immediate connection with the primary diseased part. The amaurosis must be referred to organic changes in the points of origin or connecting cords. The upper and outer vicinity of the optic thalamus seem especially important in this respect, because many cerebral fibers of the optic nerve pass through it. (*Türck.*)

Yet amaurosis is not uncommon, whether the seat of disease be in the anterior, middle, or posterior lobe of the cerebrum, in its cortical (*Ladame*) or medullary layer. Where the morbid center is on one side, it generally affects only the parts supplied from one root. Where it appears on both sides in the beginning, or even in opposite halves (*Lancereaux*), there is scarcely any immediate connection, but a number of diseased centers. Meningitis, pressure on the brain, &c., may be also considered the proximate causes. Such a course is particularly observed in the case of large cerebral clots. The amaurosis appears bilateral in the beginning, but, with the absorption and shrinkage of the coagulum, is finally lost in symmetrical hemiopia, or interruptions and partial limitations of both visual fields. (*Graefe.*) When the hemorrhage recurs, or the reaction increases, the impairment of vision varies in degree and extent. In softenings of the brain (*Türck*, *Graefe*), tubercles (*Ladame*), tumors (*Graefe*, *Duchek*, *Ladame*, *Weickert*), this occurs more rarely. We may almost believe that small, circumscribed morbid centers, are the sources of the central interruptions of the visual field so often observed; particularly the disturbances of circulation confined to very narrow limits, inflammation and gray atrophy. (*Graefe.*) Yet nothing positive is known on this subject.

Diseases of the cerebellum (*Duchek*, *Ladame*, *Benedikt*) are very often accompanied by amaurosis. It is generally binocular. In one case of monocular amaurosis, the opposite root was affected, and it was accompanied by neuro-retinitis (*Demme*). There is generally enlargement of the pupil, less often deviation of one or both eyes (*Shearer*, *Leven*, *Ollivier*, *Duchek*). In some cases the disease was caused by morbid growths which were in one lobe (*Demme*, *A. Weber*, *Hitzig*, *Leber*), or pressed upon it (*Beronius*). In another the disease originated in a cyst pressed into both lobes (*H. Jackson*). Cysts in one lobe (*Marcé*), large deposits of tubercle (*Collin*), cysts in both hemispheres (*A. Weber*), have also been formed. It is believed that the loss of vision under such circumstances is occasioned by the participation of the *corpora quadrigemina*, and by the influence which the irritation of certain parts of the cerebellum exerts upon the nutrition of the optic-nerve centers (*Duchek.*) Pressure is certainly not the cause. We may just as little suspect nuclei of the optic nerve originating in the cerebellum, for in disease of this part there is often no loss of vision (*Duchek*, *Ladame*, *Moster*). Cases are known where one or both lobes were completely atrophied (*Lallement*, *Fiedler*), or were absent from birth (*Combette*, *Solly*), without any loss of vision. Cases of tumors of the cerebellum are usually characterized by headache, particularly in the back of the head, and disturbances of co-ordinated movements, expressed usually in the form of convulsions and by difficulty in walking and standing. Convergent squint also is often a common symptom. On the contrary mental aberration and disturbances of the sensibility are usually absent (*Ladame*).

In some cases, amaurosis has been observed in disease of the pons varolii (*Coindet*, *Boyer*, *Bright*, *Rosenthal*), and of the medulla oblongata (*Ladame*, *Biermer*, *Bright*). The amaurosis was then almost always in both eyes, either in the beginning or soon after. The center of the disease may be either in the substance of the parts, or press upon it from without. In affections of the pons, contraction of the pupil is frequently seen. In an affection of one side, this con-

traction is generally monolateral, and on the opposite side of the body. (*Duchek.*) It appears as if the cause of this loss of vision must be sought for in the passage through of those nerve-filaments which connect the optical centers of the brain and spinal cord to each other.

Diseases of the spinal cord, particularly *tabes dorsalis*, have been long recognized as sources of amaurosis—the so-called *amaurosis spinalis*. The symptoms of spinal disease usually precede such a loss of vision, especially paralysis of sensation, to which muscular paralysis of the extremities is generally soon added. There is then often great sensitiveness to any kind of external irritation, especially pressure in the region of the upper cervical vertebræ. Occasionally the loss of vision could be increased by pressing or pinching the adjacent soft parts; but by local blood-letting from the same part, a marked improvement of the amblyopia has been observed. (*Türck.*)

On post-mortem examination, progressive atrophy of the posterior layer of the spinal cord has been found. This could be traced upward into the optic thalamus, and generally advances very soon to the roots, the optic commissure, and to the two trunks of the optic nerve. (*Romberg.*) In regard to the pathogenesis of amaurosis, it is very important that the anatomical changes in the region of the optic nerve should agree entirely with those that are found in the portions of the spinal cord affected by Tabes (*Leber*). It is then seen by the ophthalmoscope as gray atrophy of the nerve. In the later stages of the disease the pupil is frequently very small (*Arlt*), yet this symptom is not always present.

Cerebral disease, like tumors of the base of the brain, often does not directly cause amaurosis, but does so by first exciting meningitis. This spreads rapidly, and extends to the intracranial portions of the optic nerve, or even carries the inflammatory irritation over to the optic centers.

Very recently cases have again been reported, where *cœnurus-like* hydatids occurring in the brain have led to descending neuro-retinitis, and others, where there was softening of the brain, or tumors, which have had the same result. (*Graefe, Koster.*)

Much more frequently, however, diseases of the encephalon lead to amaurosis through increasing cerebral pressure, and through the disturbances of nutrition thus occasioned. The increase in the cerebral pressure, in many cases, results directly from the increase in quantity of the cranial contents, and the increase in the intravascular pressure. The effect of this mechanical cause may remain a local one, so that only the adjacent parts suffer; chiefly those which can not yield sufficiently on account of the contiguity of the bony wall. (*Türck.*) More frequently, however, it is more general. All the cerebral convolutions appear obliterated; a great number of nerves extending over the base of the brain are flattened and atrophied, particularly the optic nerves. (*Türck, Koster.*)

In other cases, increase of the cerebral pressure is caused by hydrocephalus. This disease accompanies the most different cerebral diseases, in whatever part of the brain they may have occurred. It may also appear primarily, and be the real cause of amaurosis, or, to speak more exactly, produce atrophy of the intracranial portions of the optic nerve, by mechanical contraction. It is to be considered that the inner surfaces of the two thalami are pressed away from each other by collections of fluid of any great amount in the ventricles. The larger *crus cerebri* is thus made more divergent, and the optic nerve, lying on its lower surface, may be stretched. At another time, the optic commissure is flattened by pressure from the floor of the third ventricle, and by a vesicular protrusion of the *tuber cinereum*. At the same time, the upper wall of the sphenoid cavity and the *sella turcia* are enlarged. Finally, a further cause lies in the constriction of the two optic nerves by the posterior communicating arteries which run under them. This constriction sometimes causes deep transverse fissures, or even complete divisions of the nervous tissue (*Türck.*)

Results.—These naturally depend on the nature, situation, and extent of the original disease. If this be incurable, or if it be progressive, and intracranial portions of the opic nerve and retina are completely destroyed by the disease, we can not expect that vision will be restored, but there will be a further loss. But the matter is quite different when the amaurosis is only in an intermediate relation to the original seat of the disease—when it is caused by an increased cerebral pressure, by proliferations of tissue, or disturbances in circulation. These latter may originate in the reflex action from the original seat of disease upon the vasomotor nerves of the adjacent parts. In other words, the prospect of relief to the loss of vision is better when the lesion of the optic nerve and retina are secondary conditions, that is, are capable of recession, or which are only temporary. It is not uncommon to see a partial or entire clearing-up of the darkened portions of the visual field. It is even observed, although rarely, in tumors of the base of the brain, and of the cerebral structure. It is quite frequent in cerebral hemorrhage. Such an amaurosis, in the beginning, generally extends over the whole tract of one or both of the roots of the optic nerve. With the absorption and shrinkage of the clot, it generally diminishes, and is gradually limited to the half of one or both retinas or less, or may even wholly disappear. Such a favorable result is, of course, better prognosticated when there is a probability that the primary disease will be recovered from, e. g. when it is a pure inflammation, which was either directly excited by injury, or by morbid conditions of a more general character, disturbances of circulation, &c.

If such a result be attained, the optic nerve and retina must not have suffered very much. It is presupposed that they have not been involved in a morbid process, which, when once excited, readily progresses of itself, without any further impulse from the primary disease.

If the whole pathological process, in all its parts, could be estimated with certainty from the symptoms, we should be able to give a prognosis in each case with the same degree of probability as in other diseases. But the hidden nature of intracranial diseases, and the doubtfulness of their symptoms, place great difficulties in the way of even an approximate diagnosis. It is generally almost impossible to do any thing more than surmise the connection existing between the amaurosis and the original seat of disease. We must then confine ourselves to an opinion as to the condition of the optic nerve and retina, from the presence or absence of certain symptoms, in order to give a rational judgment as to the future of the patient's vision, the loss of which is the most painful symptom.

The appearance of the optic papilla is, therefore, of the greatest importance. If gray atrophy is seen here, our hopes are very slight. This disease has a great progressive tendency. In case it proceeds from deeply-lying parts, it very frequently attacks the roots of the other nerve, so that we have to fear that both eyes may become blind, when only one is as yet affected. Yet we should not forget that a pure atrophy is not necessarily propagated; it may, under favorable circumstances, cease to progress at any moment, and be permanently limited. Therefore, we can only make a correct prognosis in these cases, by repeated examinations of the eye with the ophthalmoscope.

Besides, the loss of vision is not always in proportion to the objective marks of atrophy. Exceptionally, in spite of very great discoloration of the optic papilla, the eye has quite satisfactory vision. In case it was very amblyopic, a portion of the sight may be restored, or even preserved, without change in the appearance as seen with the ophthalmoscope. (*Ed. Jaeger.*)

We should also guard ourselves against the misinterpretation of ophthalmoscopic symptoms. Every marked partial bleaching of the optic papilla does not indicate atrophy. In a normal condition the periphery may appear of a bright, white, tendinous color. The distinction between such a physiological whiteness and actual atrophy is not unfrequently very difficult. It is only possible in long observation of the case, that is, by the final proof of the enlargement of the discolored portion. Yet there is frequently an indication in the fact that the atrophic degeneration begins at the *porus opticus*, clasps this, as it were, and then extends to the temporal border of the papilla in the form of a pointed arch or gusset (*zwickel*), and gradually increases in breadth.

Neuro-retinitis is on the whole very serious, yet there is a far larger space for a favorable prognosis than in the gray atrophy, which insidiously advances with no very marked symptoms, unless it is a very productive inflammation, or has existed for a long time, and the characteristic tendinous brilliancy and bright color of the degenerated tissue is seen beneath the turbid optic papilla.

We may have the most hope, other conditions being favorable, as long as there are no organic changes in the papilla.

Some valuable prognostic aids result from the manner in which the functions of the eye have been performed, and the way in which the loss of vision has occurred. (*Graefe.*) We can not say that complete blindness occurring suddenly or very quickly in one or both eyes, by any means involves the worst prognosis, for such a loss of sight is not unfrequently completely or partly restored. It is a very bad symptom, however, when the appearance of gray atrophy is seen at the same time with the neuro-retinitis in both eyes, although even this does not cut off all hope of a partial clearing-up of the visual field. We have the least reason to hope for such a temporary or permanent improvement of the condition in a case of complete amaurosis, which has been very gradually developed with the symptoms of progressive pure atrophy of the optic nerve.

Amblyopia also, with a proportionate loss of the relative acuteness of vision, in any of the zones of the visual field, allows us to give, on the whole, a favorable prognosis. Even when there are also concentric limitations in the field, it does not necessarily involve immediate danger. Yet the concentric limitations make the affection more serious, although they sometimes depend on curable conditions, e. g. simple anæsthesia, and are often a premonition of progressive atrophy, particularly when the cause is still acting; for example, habitual intemperance. (*Graefe.*) Atrophy is always to be expected when there is an irregular lateral limitation of the visual field.

Interruptions and lateral limitations of the visual field are very unfavorable, not because they always cause us to look for a further loss of vision, but because they have a slight tendency to retrocession. Here, as a rule, but of course not without exceptions, sharply-bounded defects in the field cause us to fear a further enlargement much less than limitations with illy-defined borders; but on the contrary they clear up wholly or in part in a much less proportion of cases.

The former seem to depend more frequently on small, circumscribed, and permanent morbid collections, e. g. apoplectic destruction of tissue, while the latter more frequently have their origin in diffusive processes, which are then temporary and curable; for instance, local pressure, inflammatory proliferation of tissue, and disturbances in circulation. The nervous elements may actively participate from the beginning, and thus exclude all hope of a return to the normal condition. Cerebral softening and gray atrophy of the optic nerve are examples of the latter-named processes.

Central and eccentric interruptions, when they occur in a visual field which is in other respects normal, are not apt to depend on progressive atrophy. We may exclude the idea of the latter, when the interruptions have been of the same extent for a long time. It is all the same, then, whether they exist in one eye or both; even a partial paleness of the optic papilla does not alter the case. But we generally have a progressive atrophy when they are combined with marked lessening of the relative acuteness of vision in the remaining portions of the visual field, especially when the loss of vision decreases very irregularly in different directions toward the periphery.

There are other dangers to the patient affected with amaurosis. The discussion of these dangers belongs to another field of investigation. Here we can only say that atrophy of the optic nerve, no matter how it originated, generally takes a centrifugal direction. Occasionally it goes backward toward nerve-centres that are not near each other, and thus the functions of nerves are impaired, which do not stand in any close relation to the primary seat of disease. The occasional appearance of mental diseases, in the later stages of progressive amaurosis, is thus explained, particularly paralytic weakness of intellect, or tabes dorsalis. Such conditions, however, generally occur first, and amaurosis results from a common cause with them.

Treatment.—We must, of course, attempt to reach the cause, and the treatment will vary in accordance with this. It is not appropriate for us to speak more minutely on this point. This belongs to the therapeutics of the various diseases which may cause amaurosis. Ophthalmology only has to participate so far as neuritis or atrophy of the optic nerve come into consideration. The treatment for neuritis had already been given in the appropriate section. The surgeon finds himself in an extremely unpleasant position in treating pure atrophy. The disease obstinately resists all direct treatment. It is often increased rather than diminished by vigorous attacks upon the nutrition, by mercurials, local blood-letting, &c. We therefore do well, in those cases where the atrophy seems to appear independently of any local fundamental disease, or if this has been subdued or deprived of its injurious influence upon the eye, to confine ourselves to taking good care to keep all injurious influences away from the eyes, and to rendering the state of the nutrition as favorable as possible. The patient should avoid all straining of the visual apparatus by reading, writing, sewing, &c. He should be kept from all strong light or contrasts of light. By way of experiment, he may remain, when the disease first begins, for several days in a dark room, or subsequently, having his eyes bandaged, in shady places for some time. The mode of life should be strictly regulated; all excessive use of alcoholic stimulants should be given up, and the amount of tobacco-smoking should be very little. The diet should be simple. The patient should take much, but not tiresome, exercise in the open air, cool baths, &c. All mental excitement is to be avoided. If there is any congestion, or if its existence is probable, the diet will be carefully considered, and, in case of necessity, methodical local blood-letting, by means of natural or artificial leeches, should be practised. A systematic course of mildly-laxative mineral waters may do good, certainly no harm. Setons, which have unfortunately again been recently advised (*Graefe*), can be entirely dispensed with, and unnecessary trouble may thus be avoided. Where we have any reason to suspect imperfect action of the skin as having any thing to do with the affection of the optic nerve, Turkish baths may be taken. Where these can not be had, warm Zittman's decoction may be used every morning, or perspiration induced by wrapping the patient in blankets. (*Graefe.*) When the patient's condition is depressed, an invigorating treatment is imperatively indicated. On the whole, we can not be too careful not to do too much. The surgeon may bear it, but the patient will certainly not.

In that form of optic nerve trouble which is caused or at least furthered by excessive use of alcohol and tobacco, an indispensable requisite for a possible cure is the total abstinence from these substances, together with most rigid care of the eyes, and when this is impossible, at any rate the greatest restrictions in their use. The greatest stress is to be laid upon the regulation of the mode of life, and hence it is often considered advantageous to withdraw the patient from his home surroundings, and treat him for a time in the hospital. When the patients are excitable, absolute rest in bed is to be recommended, as well as digitalis when the pulse is frequent, and morphine for sleeplessness, which is frequently present in patients accustomed to spirits after abstinence has been advised. When sleep returns it is to be regarded as a favorable prognostic sign, even when there appears no change in the disturbance of vision. Moreover, in order to induce perspiration the patient should be enveloped every morning in wet cloths and warm coverings, and plenty of hot drinks should be administered, particularly in ataxic drinkers with weak pulse and great disturbance of nutrition. When the feet do not perspire, they should be enveloped in wet cloths or stockings and thus forced to perspire. It is also believed that the administration of senna and sarsaparilla induce a favorable action. In plethoric patients a local blood-letting with Heurteloup's leech should be performed at intervals of from four to six days, particularly when the optic papilla shows signs of hyperæmia, etc. The results of this mode of treatment are represented as being on the whole very satisfactory (*Erismann*).

The internal use of nitrate of silver should be mentioned as an empirical remedy, in spinal paralysis, and amaurosis depending upon it. Good is said to have been done with it in certain cases (*Wunderlich*, *Herschel*). The same is said of hypodermic injections of a solution of strychnine in the supra-orbital region (*Seamann*, *Späth*, *Talko*, *Lacerda*). Yet the cause of the cases in question is not at all clear. It is well to expect very little from the use of these remedies. The galvanic current might be tried in suitable cases. With respect to the as yet very few successes (*Benedikt*), and where vasomotor influences seem to come into play, it should be applied particularly to the cervical sympathetic.

Authorities: ***Rokitansky***, **Lehrbuch der path. Anatomie. Wien. 1856. II. S. 432, 435, 463, 488, 499.—*Türck*, Sitzungsberichte der Wiener k. Akad. IX. S. 229; Zeitschrift der Wiener Aerzte. 1852. II. S. 301; 1855. II. S. 521.—*Wedl*, Atlas, Opticus-Retina; Sitzungsberichte der Wiener kais. Akad. 48. Bd. S. 384, 386, 388.—*Virchow*, dessen Archiv. VI. S. 268.—*Klebs*, ibid. 19. Bd. S. 336; 21. Bd. S. 171; A. f. O. XI. 2, S. 244.—*Stellwag*, Ophth. II. S. 583, 591, 632, 686. Nota 73; Wiener med. Wochenschrift 1864. Nro. 11. S. 163.—*H. Müller*, Würzburger med. Zeitschrift III. S. 252; kl. Monatsbl. 1863. S. 318; Verhandlungen der Wurzb. phys. med. Gesellschaft 1856. S. 46; 1858. S. 52; 1859. S. 449; A. f. O. III. 1. S. 96; IV. 1. S. 363, 370, 375, 379, 383; IV. 2. S. 1, 12, 13, 15.—*Graefe*, A. f. O. I. 1. S. 367, 381, 403; II. 1. S. 266, 271; II. 2. S. 258. u. f. 288, 319; III. 2. S. 444; IV. 2. S. 153; VIII. 2. S. 285; 1865, S. 131-154.—*Ammon*, A. f. O. VI. 1. S. 15, 17, 33; kl. Darstellungen. Berlin, 1847. S, 59. Taf. 19.—*Ed. Jaeger*, Einstellungen des dioptr. Apparates. Wien. 1861. S. 39, 42.—*Quaglino*, Congres. int. d'ophth. Compte rendu. Paris, 1863. S. 229.—*Pagenstecher*, Würzburger med. Zeitschrift. III. S. 399; kl. Beobachtungen. II. Wiesbaden, 1862. S. 76, 82; A. f. O. VII. 1. S. 94, 96.—*Bolling Pope*, Würzb. med. Zeitschrift III. S. 244; klin. Monatsbl. 1863. S. 317.—*Sämisch*, Beiträge zur norm. u. path. Anat. d. Auges. Leipzig, 1862. S. 18, 24.—*Donders*, A. f. O. III. 1. S. 139; Verhandlungen der Augenärzte in Heidelberg. Berlin. 1860. S. 10.—*Junge*, A. f. O. V. 1. S. 49, 58.—*Schiess-Gemuseus*, ibid. IX. 3. S. 175; XI. 2. S. 62, 76.—*Schweigger*, ibid. V. 1. S. 96; V. 2. S. 221; IX. 1. S. 203, 206; Vorlesungen über den Gebrauch des Augenspiegels. Berlin, 1864. S. 113, 146; klin. Monatsbl. 1864. S. 400. —*Graefe*, A. f. O. XII. 2. S. 122; kl. Monatbl. 1863, S. 617.—*Ed. Jaeger*, Handatlas, Figs. 45-51, 73, 74.—*Quaglino*, Schmid's Jahrb. 142. Bd. S. 322.—*Pagenstecher*, kl. Beobachtungen, III. Wiesbaden, 1862, S. 73.—*Sämisch*, kl. Monatbl. 1865, S. 51.—*Mooren*, Ophth. Beiträge, S. 260, 290; Ueber Sympath. Ophthalmic, S. 94.—*Masson*, n. Helmholtz, Karsten's Encyklop. IX. S. 314.—*Schleske*, A. f. O. XI. 1. S. 171; Deutsche Klinik, 1865, S. 115.—*Foerster*, Die Hemeralopic, Breslau, 1857, S. 3; Congres Ophth. 1868, S. 125, 127, 130.—*Joy Jeffries*, Boston Med. a. Surg. Journ. 1868, I. S. 195.—*Wecker*, Congres Ophth. 1868. S. 64.—*Houdin*, ibid. S. 70.—*Welz*, *Javal*, ibid. S. 123, 124.—*Glezowski*, ibid. S. 164.—*Berthold*, kl. Monatsbl. 1869, S. 300.—*Moeser*, Das Perimeter, etc., Diss. Breslau, 1869.—*Berlin*, A. f. O.**

XIV. 2. S. 280.—*Nagel*, kl. Monatbl. 1869, S. 151.—*Chisholm*, Ophth. Hosp. Rep. 1869, VI. S 124.—*Serres d'Uzes*, *Remak*, nach Graefe, kl. Monatbl. 1865, S. 140.—*Hirschmann*, kl. Monatbl. 1866, S. 39, 40.—*Heymann*, ibid. 1864, S. 127; 1868, S. 415.—*Alf. Graefe*, ibid. 1867, S. 53, 57.—*Wittich*, A. f. O. IX. 3. S. 1, 6, 12, 22, 24, 33, 35, 37.—*Zehender*, ibid. X. 1. S. 152.—*Tritzer*, Wien. med. Jahrb. 1864, 5. S. 155 u. f.—*Leber*, A. f. O. XIV. 2. S. 210, 333, 356, 367; XV. 3. S. 26, 30, 37, 39, 46, 51, 55, 60, 65, 71; kl. Monatbl. 1868, S. 302, 312.—*Mauthner*, Lehrb. d. Ophthscop. S. 282, 283, 294, 397.—*Rudnew*, Virchow's Archiv. 48. Bd. S. 494, 498.—*Benedikt*, A. f. O. X. 2. S. 185; Electrotherapie, S. 249, 251, 254.—*D. E. Müller*, A. f. O, VIII. 1. S. 160.—*Loewegren*, Virchow's Jahresber. 1868, II. S. 499.—*Remak*, Deutsche Klinik, 1865, S. 115.—*Zagorski*, kl. Monatbl. 1867, S. 322.—*Alexander*, ibid. S. 88.—*Bjort*, ibid. S. 166.—*Testelin*, ibid. S. 331.—*Oglesby*, Lancet, 1868, II. S. 8; Ophth. Hosp. Rep. VI. 3. S. 190.

Amaurosis Idiopathica: Himly, Krankheiten und Missbildungen, II. S. 411.—*Beer*, Lehre v. d. Aug.-Krankheiten, II. S. 443.—*Graefe*, A. f. O. IV. 2. S. 266; kl. Monatbl. 1865, S. 260.—*Mooren*, Ophth. Beobacht. S. 309.—*Mackenzie*, Traité des mal. d. yeux. Trad. p. Warlomont et Testelin, II. Paris, 1857, S. 811, 814.—*Law*, *Stevenson*, ibid. S. 813.—*Andreae*, Zeitschr. f. Ophth. I. S. 409.—*Beck*, ibid. V. S. 447.—*Stellwag*, Ophth. II. S. 696, Nota 133.—*Steffan*, *Hübsch*, *Chassaignac*, kl. Monatbl. 1865. S. 167-170.

A. Congestiva: Beer, l. c. II. S. 444, 563, 572.—*Mackenzie*, l. c. II. S. 807, 824, 826, 827, 834.—*Himly*, l. c. II. S. 412, 422.—*Arlt*, l. c. III. S. 152, 159, 173.—*Graefe*, kl. Monatbl. 1865, S. 193.—*Spengler*, *Deval*, A. f. O. I. 2. S. 330, 332.—*Zehender*, Seitz Handb. S. 632, 634.—*Nagel*, A. f. O. VI. 1. S. 231.—*L. Kraus*, Allg. Wien. Med. Zeitg. 1861, S. 387.—*Schreder*, ibid. S. 76.—*Lawson*, nach Seitz l. c. S. 632; kl. Monatbl. 1864, S. 38.—*Ringland*, u. A. Ann. d'oc. XIX. S. 123.—*Stellwag*, Ophth. II. S. 694, Nota 129, 130, 131.—*Seidel*, nach Seitz l. c. S. 634.—*Sichel*, Gaz. d. Hôpit. 1861, Nro. 64. *Ullersperger*, kl. Monatbl. 1867, S. 183.—*Zehender*, ibid. S. 233.—*Testelin*, ibid. S. 331.—*Mooren*, Ophth. Beob. S. 310.—*Erismann*, über Amaurosis intoxicativa, Diss. Zürich, 1867, S. 12, 47.

A. Anæmica: Mackenzie, l. c. II. S. 840.—*Himly*, Krankheiten u. Missbildungen, etc., II. Berlin, 1843, S. 426.—*Cunier*, Ann. d'oc. II. S. 178.—*Arlt*, Krankheiten d. Auges, III. Prag. 1856, S. 175.—*Rittmann*, Aerztl. Bericht. Brünn, 1865, S. 18.—*Fikentscher*, A. f. O. VIII. 1. S. 209.—*Sellheim*, kl. Monatbl. 1866, S. 52.—*Seegen*, Wien. med. Wochenschr. 1866, Nro. 23.—*Galezowski*, Congres intern. d'Ophth. Paris, 1863, S. 110.—*Nagel*, A. f. O. VI. 1. S. 231.—*Luys*, Tardieu, nach Duchek, Wien. med. Jahrb. 1862, 4. Jahresber. S. 10.—*Mooren*, Ophth. Beob. S. 310.—*Jacobs*, kl. Monatbl. 1868, S. 90.—*Colsmann*, ibid. 1869, S. 11.—*Graefe*, A. f. O. IV. 2. S. 230; VII. 2. S. 143; XII. 2. S. 149.—*Hutchinson*, Ophth. Hosp. Rep. VI. S. 218.—*Ed. Jaeger*, Staar und Staar-Operationen, Wien, 1854, S. 104.—*Benedikt*, Electrotherapie, S. 475.

A. Intoxicativa: Beer, Lehre v. d. Augenkrankheiten, II. Wien. 1817, S. 445, 499.—*Rau*, A. f. O. I. 2. S. 205, 208.—*Stellwag*, Ophth. II. S. 674.—*Danjoy*, Arch. Gén. de Méd. 1864, 3. S. 402, 407, 409, 415-419, 422.—*Desmarres*, *Lancereaux*, *Lecorchi*, *Follin*, ibid. S. 417, 418.—*Hirschler*, Wien. med. Wochenschr. 1866, S. 7, 8.—*Himly*, l. c. II. S. 428.—*Mackenzie*, l. c. II. S. 828, 830, 844.—*Arlt*, l. c. III. S. 174.—*Graefe*, A. f. O. III. 2. S. 396, 399; kl. Monatbl. 1865, S. 145, 151.—*Sichel*, Mélanges Ophth. Bruxelles, 1865, S. 1, 10, 12, 16; kl. Monatbl. 1866, S. 46.—*Loureiro*, kl. Monatbl. 1865, S. 394.—*Hutchinson*, Ophth. Hosp. Report, 1864, 1. S. 33; Schmidt's Jahrb. 133. Bd. S. 114.—*Richardson*, *Ygonin*, Ann. d'hygiène, publ. 1867, Janv. S. 217, 219.—*Wordsworth*, kl. Monatbl. 1863, S. 364.—*Zehender*, Lehrb. S. 635, 636.—*Pagenstecher*, kl. Beobachtgn. 1. S. 57.—*Rosenstein*, Virchow's Archiv. 39, Bd. S. 1, 12, 13, 174.—*Desbois*, *Tanquerel*, *Bouillaud*, *Traube*, ibid.—*Jackson*, kl. Monatbl. 1867, S. 92.—*Haase*, ibid. S. 225.—*Mooren*, Ophth. Beob. S. 276.—*Thielésen*, *Loureiro*, Congrès Ophth. 1868, S. 168, 170.—*Ed. Meyer*, Virchow's Jahresber, 1868, II. S. 496.—*Erismann*, über Amaurosis intox.—*Leber*, A. f. O. XV. 3. S. 60, 85.

A. nach Typhus u. s. w.: *Ebert*, kl. Monatbl. 1868. S. 91.—*Betke*, ibid. 1869, S. 201.—*Graefe*, ibid. 1868, S. 93; A. f. O. XII. 2. S. 135.

A. Embolica ischæmica: Steffan, A. f. O. XII. 1. S. 34, 39, 41, 43, 47, 53, 55, 58, 59.—*Fano*, ibid. S. 34, 43; Annal. d'oc. LII. S. 239.—*Sämisch*, *Hirschmann*, kl. Monatbl. 1866, S. 32, 37.—*Just*, ibid. 1863, S. 265.—*Schweigger*, Vorlesungen, etc. S. 138, 140.—*Ed. Jaeger*, Staar und Staaroperat. Wien. 1854, S. 104-109; Wien. med. Presse. 1868, Nro. 44; Handatlas. Fig. 70.—*Liebreich*, A. f. O. V. 2. S. 261, 263; Deutsche Klinik. 1861. Nro. 50; Atlas der Ophth. Berlin, 1863, Taf. 8. 11.—*Graefe*, A. f. O. IV. 2. S. 230-234; V. 1. S. 136, 141, 142, 144, 146, 148, 150, 154, 156; VII. 2. S. 143, 144, 146, 148; XII. 2. S. 143, 144, 149, 207.—*Blessig*, A. f.

O. VIII. 1. S. 216, 223, 225.—*Schneller*, ibid. VII. 1. S. 90; VIII. 1. S. 271, 278.—*Zehender*, *Seitz*, Handbuch der ges. Augenheilkunde. 1866, S. 568, 617, 619, 631.—*Leber*, A. f. O. XI. 1. S. 7, 11, 12.—*Alf. Graefe*, ibid. VIII. 1. S. 143, 144, 149, 153, 156.—*Heeläus*, kl. Monatbl. 1865, S. 285.—*Rothmund*, ibid. 1866, S. 106, 108.—*Secondi*, Clinica, etc. S. 40, 72, 74, 75, 77, 84, 138; Caso di amaurosi per ischemia, etc. Torino, 1864.—*H. Jackson*, nach Seitz, Handb. S. 619; kl. Monatbl. 1864, S. 42, 156-158; Ophth. Hosp. Rep. IV. 1. S. 14; VI. 2. S. 131.—*Geissler*, Schmidt's Jahrb. 139, Bd. S. 76.—*Wecker*, ibid. Virchow's Jahresbericht, 1868, II. 497.—*Schirmer*, kl. Monatbl. 1868, S. 38.—*Iwanoff*, ibid. S. 349.—*Knapp*, A. f. O. XIV. 1. S. 207, 209, 237; Arch. f. Aug. u. Ohrenheilk. I. S. 29, 33.—*Landesberg*, A. f. O. XV. 1. S. 214.—*Pagenstecher*, ibid. S. 223, 236.—*Mauthner*, Lehrb. d. Ophthscop. S. 336, 342, 337, 350.—*Quaglino*, An. d'ocul. LIV. S. 159.—*Berthold*, Wien. med. Presse. 1867, S. 467.—*Bauer*, Centralbl. 1866, S. 577.

A. Cerebralis: Türck, Zeitschr. d. Wien. Aerzte. 1852, II. S. 299; 1853. I. S. 214, 216, 1855. 517-522, 531; Sitzungsber d. Wien. k. Akad. d. Wissensch. IX. S. 229-234; 36 Bd. S. 191, 194, 196, 197; Oesterr. Wochenschr. 1843, Nro. 44.—Beer, l. c. II. S. 443, 539, 576, 580, 582.—*Graefe*, A. f. O. VII. 2. S. 24, 33, 58-71; XII. 2. S. 100, 114, 116—120, 123, 124, 126, 127, 129, 130, 133, 135; Kl. Monatbl. 1863, S. 3, 4, 6; 1865, S. 201.—*L. Meyer*, Centralbl. f. m. Wiss. 1867, Nro. 8, 9, 10.—*Quaglino*, Congres. intern. d'ophth. Paris, 1863, S. 229.—*Stellwag*, Ophth. II. S. 660, 661, 697-702, Nota 135.—*A. Weber*, kl. Monatbl. 1863, S. 406-412.—*H. Jackson*, ibid. 1864, S. 44, 143, 146, 149, 150-158, 254; 1866, S. 48; nach Duchek Wien. med. Jahrb. 1864, 4 Jahresber. S. 47, 54.—*Alexander*, kl. Monatbl. 1867, S. 88.—*Lanquem*, ibid. 1864, S. 275, 279.—*Pagenstecher*, kl. Beobachtungen I. Wiesbaden 1861, S. 57.—*Fromüller*, kl. Monatbl. 1863, S. 229.—*Horner*, ibid. 1863, S. 71, 74, 77.—*Mackenzie*, l. c. II. S. 803, 807.—*Salter*, *Brück*, *Pollock*, kl. Monatbl. 1863, S. 180, 182.—*Jüngken*, Lehre v. d. Augenkrankheiten, Berlin, 1832, S. 841.—*Hutchinson*, A. Clin. Memoir, etc. London, 1863, S. 161-174.—*Griesinger*, nach Duchek Wien. med. Jahrb. 1862, 4. Jahresbericht, S. 15. *D. E. Müller*, A. f. O. VIII. 1. S. 160, 163, 164.—*Sämisch*. kl. Monatbl. 1865, S. 51, 53, 54.—*Landame*, Symptomatologie u. Diagn. d. Hirngeschwülste, Würzburg, 1825, S. 17, 43, et seq.—*Lebert*, Virchow's Archiv. III. S. 463, 473, 477, et seq.—*Lancereaux*, Arch. gén. de méd. 1864, III. S. 47, 64, et seq.—*Duchek*, Wien. med. Jahrb. Jahresbericht, 1862, 1. S. 19, 21-31; 1862, 4. S. 6, 11-15; 1864, 4. S. 17, 21, 24-56; 1865, 1. Text S. 99, 114.—*Cruveilhier*, nach Mackenzie, l. c. II. S. 807.—*Spurgin*, ibid. S. 815.—*Stilling*, Zeitschrift f. Ophth. III. S. 465.—*Blessig*, nach Graefe A. f. O. XII. 2. S. 123, 127; Centralbl. 1866, S. 341.—*Weickert*, Arch. f. Heilkunde. VIII. S. 97, 100, 101.—*Koster*, Zesde Jaarl. Verslag. Utrecht, 1865, S. 1, 2, 8, 18, 22.—*K. Fischer*, kl. Monatbl. 1866, S. 164, 167.—*Sichel*, Melanges Ophth. Bruxelles, 1865, S. 16—24.—*W. Wagner*, kl. Monatbl. 1865, S. 159, 160, 163.—*Henoch*, *Steffen*, nach Ladame l. c. S. 57.—*Mohr*, ibid. S. 108, 137.—*Baimbridge*, *Jobert de Lamballe*, *Herrison*, nach Lancereaux, l. c. S. 199.—*Hunter*, *Quaglino*, *Dufour*, u. A. ibid. S. 199, 201, 202.—*Leyden*, Virchow's Archiv. 29. Bd. S. 202; Kl. Monatbl. 1865, S. 121.—*H. Fischer* nach Duchek l. c. 1864, 4. S. 24.—*Michel*, ibid. 1862, 1. S. 27.—*Habershon*, kl. Monatbl. 1865, S. 57.—*Hoffmann*, *Dahl* u. A., nach Duchek l. c. 1864, 4. S. 27.—*Beck*, nach Ladame l. c. S. 145.—*Shearer*, *Leven*, *Ollivier*, nach Duchek l. c. 1864, 4. S. 49-56.—*Demme*, ibid. S. 45 u. 1862, 4. S. 14.—*Colin*, ibid. 1862, 4. S. 14.—*Beronius*, *Marcé*, ibid. 1864, 4. S. 45.—*Lallement*, *Duguet*, ibid. S. 46.—*Fiedler*, ibid. 1862, 1 S. 34.—*Combette*, ibid. 1864, 4. S. 54.—*Solly*, Canstatt's Jahresber. 1864, III. S. 146.—*Rosenthal*, nach Duchek, l. c. 1864, 4. S. 32, 44.—*Coindet*, *Bright*, *Boyer*, nach Ladame l. c. S. 106, 10.—*Biermer*, *Bright*, u. A. ibid. S. 143, 147.—*Romberg*, nach Arlt l. c. III. S. 168.—*Arlt* kl. Monatbl. 1869, S. 92.—*Hjort*, ibid. 1867, S. 166.—*Girandet*, ibid. 1868, S. 101.—*Arcolee* Congres Aphth. 1868; S. 183.—*Zagorski*, kl. Monatbl. 1867, S. 322, 325.—*Testelin*, ibid. S. 331.—*Magnan*, Gaz. Méd. de Paris, 1868. S. 510.—*Leber*, A. f. O. XIV. 2. S. 165, 333, 339, 363; Kl. Monatbl. 1868, S. 302.—*Benedikt*, Electrotherapie, S. 250, 252, 256.—*Buzer*, Centralbl. 1868, S. 399.—*Prevost*, ibid. 1866, S. 125; A. f. O. XII. 1. S. 6.—*Manz*, A. f. O. XII 1. S. 1, 5.—*Moster*, Virchow's Archiv. 43. Bd. S. 220. *Flourens* after *Budge*, Ueber die Bewegung der Iris. S. 130.

Results, *Treatment:*—*Graefe*, A. f. O. II. 2. S. 296; VII. 2. S. 96; Klin. Monatbl 1863, S. 9; 1865, S. 131, 132, 133, 136, 141, 144, 148, 150, 152, 155, 194-201, 203, 205, 208, 211 220, 224, 260, 273.—*Wunderlich*, nach Duchek l. c. 1862, 1. S. 33.—*Herschel*, Bulletin génér. de Thérapie, 30 Oct. 1862.—*Sämann*, kl. Monatbl. 1865, S. 118.—*Späth*, ibid. S. 248.—*Talko* klin. Monatbl. 1868, S. 79.—*Lacerda*, ibid. 1867, S. 239.—*Erismann*, über Intox. Amaurosen S. 32.—*Benedikt*, Electrotherapie, S. 254.

Typical Pigment Degeneration.

Symptoms.—This very peculiar retinal affection, which is usually described as *retinitis pigmentosa*, or "spotted retina," and is by many classed with cloudy atrophy, is objectively characterized by the appearance of numerous groups of black pigment, which sometimes form irregularly curved lines, sometimes oval or elongated spots with jagged edges or delicate branched processes which, by their shape, remind us of bone-corpuscles. These are chiefly in the middle zones of the retina, and in the anterior layers, i. e. those which are toward the vitreous. As they probably originate from disease of the walls of the vessels, they mostly turn their long axes to a point at the back of the fundus. (*Chro. lith.*, M.) The retina itself and the optic papilla usually offer the appearance of pure atrophy. The trunks and large branches of the central vessels usually have bright borders, from thickening of their walls; they are often remarkably contracted, even quite early, and are occasionally invisible, or reduced to white strings. In places they often appear covered or surrounded by pigment, with pigment striæ proceeding from them. In pure cases the choroid appears quite normal, or has the wainscoted appearance peculiar to senescence; more rarely we find larger streaks where the tapetum is entirely destroyed or thrown together in heaps. We sometimes meet with places where, besides the pigment epithelium, the choroid is also atrophied, so that spots appear which resemble those of retinitis disseminata, and like these, are partially surrounded by masses of pigment. A very marked, bright punctate appearance of the choroidal surface also sometimes appears (*Schweigger*). In exceptional cases cloudy opacities have been found in the vitreous, but *polar cataract* is often seen (*Mooren*).

From its very commencement, the disease is subjectively characterized by the occurrence of night-blindness, by a circular limitation of the visual field, passing very gradually but very regularly from the periphery toward the center, and by a relatively slight decrease of central sharpness of vision.

In some cases a zonular interruption of the field of vision, progressing regularly toward the center, with proportionately good central and peripheral vision, was observed. (*Graefe.*)

The concentrive diminution of the field of vision and the generally slight affection of central sharpness clearly distinguishes the disturbance of vision dependent on typical pigment degeneration from those amblyopias originating in gray or cloudy atrophy of the retina and optic nerve; for in these the limitation is usually lateral and very irregular, and the field of vision is finally reduced to a horizontal slit.

The concentric limitation of the field of vision renders the frequent complication of this disease with polar cataract and myopia very unfortunate; for in polar cataract the darkening of the center of the retina is prejudical, and in myopia, the circumstance that the absolute enlargement of the field of vision in the fixation of distant objects, is rendered useless by the error of refraction.

In one case, instead of hemeralopia, nyctalopia was observed with enlargement of the visual field in the dark (*Hasner*).

Causes.—In a series of cases, typical pigment degeneration has proved to be hereditary (*Alf. Graefe, Mooren, Graefe, Picard*). Statistics show that it occurs much more frequently in children whose parents were blood relations, than other-

wise (*Liebreich*). As it moreover very frequently occurs with impairment of hearing, deficiency of intellect, microphthalmus, stunted growth or superabundance of fingers, etc., the existence of a congenital predisposition is scarcely doubtful in the majority of cases.

Syphilis has also been considered by many as one cause of the disease (*Galezowski*, *Mannhardt*). Still it seems, that the typical pigment degeneration has here been confounded with the opaque atrophy of the retina, which is developed after exudative neuro-retinitis and sometimes accompanied by extensive formation of very similar masses of pigment. It is perhaps also the fact in cases in which the typical pigment degeneration is said to have developed itself at a later period of life. In fact we sometimes have the opportunity of observing inflammations of the retina which run a chronic course. These at first are exactly like the diffuse form, but gradually lead to atrophy of the retina, and then in the course of time masses of the characteristic pigment, constantly increasing in number, are developed in the periphery of the retina, while the opacity of the tissue diminishes more and more, so that the ophthalmoscopic appearances are finally very like those of the typical pigment degeneration.

Course and Results.—As a rare coincidence the typical pigment degeneration occurs in connection with complete amaurosis. As a rule, however, the peculiar condition is only developed later. The beginning of the disease always dates from the earliest childhood, and is evinced during this period by marked impairment of vision as the illumination diminishes. The characteristic disturbance of vision generally appears to precede considerably the formation of pigment, at least the latter is often absent in children already suffering from the first, and only appears towards puberty. On the whole the mass of newly-formed pigment is by no means always proportioned to the development of the subjective appearances or to the age of the individual and the duration of the disease. The pigmentation generally begins at the nasal side of the retina near the equator and advances in the same zone, but also at the same time backwards and forwards in a meridional direction. The belt is thus completed more and more, without, however, necessarily closing at the temporal side, and gains in breadth. As an exceptional occurrence, the characteristic masses have even been seen upon the papilla (*Secondi*, *Mooren*). As the pigmentation advances the disturbance of vision also increases, and the concentric narrowing generally reaches complete amaurosis, before the visible changes have advanced as far as the yellow spot.

The course is usually very slow; as a rule, the disease does not cause blindness before mature age. There is a recorded case of an old man of eighty-one years, in whom the disease began in childhood, and who still had some vision in one eye (*Secondi*).

As a rule, the disease is binocular, and progresses quite evenly in the two eyes, but still, so that in one eye the limitation of the field of vision and the decrease of central sharpness is always somewhat further advanced than in the other (*Mooren*). The typical pigment degeneration has, however, been found limited to one eye (*Pedraglia*).

Pathogenesis.—The anatomical examination of a case showed adhesion of the retina to the vitreous; atrophy of the nerve elements of the retina, more complete in the external layers, less in the fiber layer, increasing gradually from the center towards the periphery; hyperplasia of the connective tissue framework with the appearance of a newly formed mass of connective tissue upon the inner surface of the fiber layer, thickening and sclerosis of the walls of the vessels, reticular pigmentation in all the layers of the retina, following the

vessels especially; partial destruction of the choroidal tapetum, partial loss of its pigment, and its occasional replacing by neoplastic cells, which, lying in several layers one upon the other, projected into the tissue of the retina and were distinctly connected with the reticularly arranged masses of pigment found there. Besides this, the elastic lamina of the choroid appeared much thickened and thickly strewn upon its surface with coloid glands, which involved the posterior layers of the retina, moreover masses of exudation, undergoing fatty degeneration, were also found between choroid and retina, corresponding to the bright spots demonstrated in the fundus by the ophthalmoscope, while the subjacent portion of the choroid was filled with small cells of an inflammatory origin (*Leber*).

Based upon this result, we should scarcely doubt, that the affection is of inflammatory origin and nearly allied to the exudative forms of retinitis, which is also corroborated by the actual similarity of the objective symptoms with those of the opaque retinal atrophy accompanied by extensive development of pigment. In the case in question the condition was, however, congenital, and was accompanied from the beginning by complete amaurosis. It is a question, whether it should be classed in the same category with the majority of the other cases, in which the affection was developed very gradually, was marked by extremely characteristic signs, and during its entire course never showed a trace of inflammatory complications.

Authorities.—*Graefe*, A. f. O. II. 2. S. 282; IV. 2. S. 250; XV. 3. S. 5.—*Alf. Graefe*, ibid. IV. 2. S. 252.—*Liebreich*, ibid. V. 1. S. 110; Deutsche Klinik. 1861. Nro. 6; Atlas der Ophth. Berlin, 1863. Taf. 6.—*Mooren*, klin. Monatbl. 1863. S. 93, 97, 104; Ophth. Beobachtg. S. 261.—*Höring*, kl. Monatbl. 1864. S. 233; 1865. S. 236.—*Pedraglia*, ibid. 1865. S. 144.—*Stör*, kl. Monatbl. 1865. S. 23.—*Pagenstecher* und *Sämish*, klin. Beobachtungen. Wiesbaden, 1861. I. S. 53; II. S. 26.—*Schweigger*, Vorles. über den Gebrauch des Augenspiegels. Berlin, 1864. S. 112, 116.—*Secondi*, Clinica oc. di Genova. Torino. 1865. S. 60.—*Haase*, kl. Monatbl. 1867. S. 228.—*Picard*, Gaz. méd. de Paris. 1868. S. 332.—*Joy Jeffries*, Boston Med. and Surg. Jour. 1868. I. S. 183.—*Galezowski*, Congrès ophth. 1868. S. 162.—*Mannhardt*, A. f. O. XIV. 3. S. 48.—*Ed. Jaeger*, Handatlas, Fig. 76–78.—*Mauthner*, Lehrb. d. Ophthscop. S. 383.—*Leber*, A. f. O. XV. 3. S. 1, 7. 17.

FIFTH SECTION.

IRITIS.

Anatomy.—The iris is a diaphragm, having an opening, the pupil, which deviates a little from the center, and is contracted and enlarged by muscular action. The peripheral or ciliary border is suspended by the *ligamentum pectinatum* to the peripheral fibrous network of the membrane of *Descemet*. It is continuous with the stroma of the ciliary muscle and the ciliary processes, the heads of which the iris covers anteriorly. The pupillary margin, when the pupil is at its maximum dilatation, floats in the aqueous chamber. When the pupil is moderately dilated, it rests upon the anterior capsule, which extends beyond the plane of the iris at its origin, and shuts off the posterior from the anterior chamber. When the pupil is still more contracted, it rests upon the convexity of the capsule. A broad zone of the iris comes in contact with the anterior surface of the crystalline lens, and the iris itself seems bulged forward like a miniature dome. The posterior chamber exists, then, as a separate space, in certain conditions only, and then forms a narrow canal, which is triangular, on a vertical section, and runs around the equator of the orb like a circle. The fluid which fills the aqueous chamber—the aqueous humor—is pellucid, only exhibiting a trace of albumen, and is to be regarded as dilute serum.

The anterior surface of the iris is uneven on account of little bands, having a reticulated branching arrangement, which project from the surface, and have little shallow fossæ separating them. Its surface is covered by a layer of small, granular, irregular cells, which is prolonged over the ligamentum pectinatum into the epithelium of the membrane of Descemet (*Rollet*, *Iwanoff*).

The posterior surface of the iris, on the contrary, is covered by a thick stratum of small, roundish cells, which are filled with dark pigment molecules. The aggregate of these cells is generally described as the *pigment* layer or *tapetum* of the iris. It is a continuation of the pigment stratum of the choroid and ciliary processes. The *tapetum* is somewhat prominent on the pupillary margin, and forms, as it were, a border about it.

The stroma is a beautiful, loose, wavy, striated connective tissue, the bundles of which intertwine with each other, partly in a radiated, partly in a circular course, and stand in direct connection with the stroma of the choroid and of the ciliary muscle. This fibrous layer is interspersed with numerous, generally fusiform or stellate, more rarely roundish, molecular cells, whose branches unite with each other in a reticulate manner.

In the most anterior layer of the iris, the ends of the fibres of the *ligamentum pectinatum iridis* mingle with the connective tissue, but do not extend over the middle of the iris. On the whole, the tissue is here much more thickly woven, so that it may be described as a peculiar layer, as the anterior boundary layer of the iris (*Henle*).

The radiating fibers of the latter incline more towards one another at the edge of the layer and unite into denser trabeculæ, which bend forward like a hook at the periphery, and spread out like a fan at the edge of the membrane of Descemet.

These trabeculæ, whose structure differs markedly from the fibrillary connective tissue, represent the suspensory ligament of the iris. When the iris is tense, this appears under the form of projecting teeth, the intervening spaces of which are filled with a less dense trabecular tissue, and like the denser fiber bundles are covered by a continuous epithelial layer, so that the anterior chamber appears completely closed at the edge. Backwards and outwards the ligamentum pectinatum is lost in a coarse meshwork of ramifying and anastomosing trabeculæ without nuclei, which fills up the intervening space between the periphery of the iris and sclera. It is connected with the connective-tissue stroma of the ciliary body, and represents a rudiment of Fontana's canal, often so well developed in animals (*Iwanoff*, *Rollet*).

The middle and strongest layer is very loose, spongy, and has wide meshes. In it lie the vessels which make up the principal part of the structure of the iris. These stretch out in rows of two or three, in a radiate course, and when the pupil is wide, in a zigzag or spiral course; they branch at sharp angles, and are distinguished by the extraordinary firmness of their adventitious tissue, as well as of their structural portion. This is thickened iris stroma, and contains, instead of long oval nuclear cells, those which resemble them, *i. e.*, nuclear cells, with many projections, lying between the bundles of connective tissue, parallel to the axis of the vessels.

The vessels of the iris are visible through the cornea, and produce the beautiful radiate appearance which is especially marked in light-colored eyes.

Blue irides often appear entirely without pigment in their structure. Their color is an "*interference phenomenon*," an effect of the parallel arrangement of very fine colorless fibers in the anterior boundary layer (*Henle*). Frequently, however, there are found, especially in the pupillary zone, irregularly interspersed, yellowish-brown spots and striæ, which have their origin in a collection of golden-yellow, dark-red, or brownish granular pigment, in the ramifying cells, and in the interstices of the tissue. In brown and black irides these cells are thickly filled with dark pigment, and quite a quantity of it lies free in the stroma.

Enveloped in the stroma are bundles of smooth muscular fibers, having a circular course. These are mostly collected on the border of the pupil, and form there a very marked *sphincter* muscle. The radiating fibers which represent the dilator of the pupil are united in bundles, which extend in a radiating manner from the ciliary border of the iris towards the pupillary margin. They are connected with one another in their course by fibers ramifying at an acute angle, and end towards the pupillary margin in a kind of network, and finally pass into the sphincter of the pupil (*Kölliker*, *Merkel*, *Dogiel*). These radiating fibers, in connection with others running concentrically, which cut the first at almost a right angle and are intimately connected with them, form a peculiar thin layer, the posterior limiting layer (*Henle*), which lies between the loose middle layer and the pigmentary layer, and has been often regarded as a tissue allied to the limiting membrane of the choroid.

The arteries come entirely from the great vascular circle of the iris, which lies within the ciliary muscle, close to the borders of the iris, and which is formed from the two long posterior and from branches of the anterior ciliary arteries. They extend with much division and reunion to the pupillary border, where they pass into the veins. In this way they give off little branches, which are lost in a fine network in the tissue of the iris and of the sphincter muscle. In the neighborhood of the pupillary border, some of their branches, which pass out at nearly right angles from the main trunk, form by anastomosis a second very superficial vascular circle, the *circulus arteriosus iridis minor* (*Leber*).

The veins of the iris have a very similar course, but lie nearer to the posterior surface than the anterior. They are connected by the blood-vessels of the ciliary muscle with the anterior ciliary veins. The principal part of their blood, however, passes to the inner surface of the ciliary processes, through fasciculated branches, which communicate with each other very frequently. The thick venous network of the ciliary processes extends itself directly into the *vasa vorticosæ* of the choroid and collects again in the posterior ciliary veins (*Leber*).

The nerves of the iris and of the ciliary muscle are, chiefly, branches of the trifacial (5th) and oculo-motorius (3d); and the sympathetic.

They appear chiefly as short ciliary nerves, passing out from the ciliary ganglion to the posterior surface of the sclerotica, and passing through this, continuing themselves forward into the so-called *lamina fusca* of the choroid.

Only one branch, or more frequently two small branches pass directly off from the naso-ophthalmic nerve, of which one generally takes a branch from the ciliary ganglion, and passes through the sclerotica on the inner side of the optic nerve, after having divided into several branches.

These are called the long ciliary nerves. The corneal nerves pass off from the long and short ciliary nerves in the ciliary muscle.

The remainder are lost in an abundant and thick tissue, from which the muscle itself and the iris are provided to some extent with nerves. The nerves proper of the iris generally have a radiate course; they are, however, much divided, and anastomose with each other, so that numerous arcs are formed with their convexity toward the pupillary margin and a network which is continued even to the outermost border of the iris.

Nosology.—The point of origin and the principal seat of the tissue proliferation are the stroma-cells; still, the connective-tissue intercellular substance and muscular fiber-cells, as well as the tapetum, take an active part in the process.

So far as our observations hitherto extend, only those processes repeat themselves in an iritis, which characterize inflammation in other parts having a basis of connective tissue. The cellular elements first swell somewhat, their contents become turbid, and they excrete a molecular mass, which, under some circumstances, may be a fatty granular substance. This is chiefly collected about the nucleus, which becomes somewhat increased in size, roughly granular, and even changes its form.

These changes are the most striking from the beginning, in the stroma-cells, especially in those which belong to the connective tissue accompanying the blood-vessels. Their nuclei are often found in a state of germination and separation. Less striking, if at all evident, are the alterations in the tapetum and in the muscular filamentary cells. In the pigmented stroma-cells the process is often not very marked. The fact that these cells often retain their normal appearance for a long time, may support the assumption that they take little or no part in the changes. Still, there often have been observed very striking alterations in the color and amount of pigment in these cells, fatty degeneration of the cellular contents, even outgrowths and true proliferation; and on the other hand also their partial destruction has been observed. The intercellular substance is also occasionally relaxed, and swells somewhat on account of the dilatation of the vessels, and the infiltration with a serous or gelatinous, finely-molecular substance interspersed with fat corpuscles, and occasionally of a reddish color, from dissolved hematine.

Subsequently a variable quantity of neoplastic elements calls our attention to the tissue of the iris. They are often arranged in rows, which generally follow the course of the vessels. In other cases they are collected together, or appear scattered without order in the intercellular substance. Their shape and subsequent condition change according to the character and stage of the inflammation. It is generally the recent nuclear cells which proliferate and undergo the most different stages of higher formation. The newly-formed elements often never reach a higher form of development. They change rather into pus-corpuscles. In very many cases even, only a small portion of the contents becomes true nuclear cells. The proliferation results in nuclei, which are in great excess, and either go on to further proliferation, or immediately again undergo fatty degeneration and are destroyed.

Sometimes the morbid product is very scanty. It contains no new formations which can be distinctly separated from the tissue proper of the iris, but is indicated only by a more or less marked discoloration and swelling of the membrane. The name *serous* has been given this form of iritis. In by far the greater number of cases the inflammatory tissue proliferation leads to the development of neoplastic growths, which may be distinguished with the naked eye.

1. These latter are chiefly of the nature of connective tissue. Their shape varies exceedingly. They most frequently occur as

a. Papillary excrescences, which are scattered near the pupillary margin, in the stroma proper of the iris, perforating the anterior or the posterior boundary layer, and coming in contact with the anterior capsule, which they quickly adhere to, causing a so-called posterior synechia.

They are originally of a warty or nodular shape, but, after their union with the capsule, often are spun out to threads. If they are close to each other, they readily run together, and thus form a more or less broad ridge, which reaches from the pupillary margin to the capsule. When there is a considerable development of such products in the whole circumference of the pupillary border, the pupil becomes completely closed, the papillary excrescences unite to form a more or less thick pseudo-membrane, which covers the center of the capsule, and either unites itself to it, or, what is more rare, it may be separate, and freely raises up from it. In exceptional cases this new formation, on account of its great thickness, deserves rather the name of a plug (*propf*) than a membrane.

These papillary outgrowths generally consist of a structureless, finely granular or radiated stroma or base, in which not unfrequently isolated neoplastic vessels, but always a varying number of cellular formations, lie imbedded. These latter generally contain much pigment, are sometimes irregularly shaped, and subdivided into larger and smaller divisions. Sometimes they are exactly like the normal stroma-cells, elongated, and furnished with numerous processes. Besides this, there are often found in the various stages of development, in not so large number, nucleated cells devoid of pigment, free nuclei, masses of free pigment, &c. Where such outgrowths have united and become broad zones, or a membrane closing the pupil, we may not unfrequently see in their structure a number of bundles of fibers, which extend in a radiate direction toward the center of the pupil, and then form a very irregular network. On the pupillary margin of the iris, however, they pass out of the pseudo-membrane, and extend to the anterior or posterior surface of the pupillary zone of the iris, in the form of isolated fibers, and these are lost in the stroma. (*Wedl.*)

b. Granulations.—These are most frequently and beautifully developed in prolapsed portions of the iris, which thus not unfrequently acquires the appearance of a beautifully granulating ulcer. Where, however, the cornea has preserved its continuity, the peculiar granulations are only rarely elevated above the surface. Generally the tissue of the iris becomes loosened in consequence of a luxuriant development of connective tissue, and becomes somewhat spongy. True granulations are most frequently seen on the anterior surface of the iris. In some cases they cover the whole iris, and even the pupil. On the posterior surface they are rare; they have, however, been known to occur even there, in isolated cases, as a continuous layer, which covered the whole iris posteriorly, and thus closed the pupil. They are found in the stroma proper of the iris, and are not seen on the surface.

The granulating iris appears interspersed, throughout its whole thickness, with neoplastic nuclei and cells. These are partially arranged in rows, and press upon the stroma, and seem to disarrange its nuclear cells, which have been very much altered by diseased action. They them-

selves, however, exhibit the most different degrees of development, here growing in a fusiform shape, and lying on each other in cords or strings, in order to form vessels; in another place they have processes, and become similar to connective-tissue corpuscles; again, by an abundant production of pigment, they often change to dark stroma-cells, and excrete a greater or less quantity of intercellular substance, which frequently completes the picture of neoplastic, vascular, and pigmented connective tissue by distinct fibrous striæ. The posterior boundary layer and the tapetum take an active part in the process, and also pass completely into the process of proliferation, if granulations arise on the posterior surface.

c. Gummy Tumors.—These are nodular collections of inflammatory products varying greatly in size, which have their origin deep in the stroma of the iris, and extend out from its anterior surface, uniting themselves to larger tumors, then covering considerable portions of the iris, and to some extent the anterior chamber. They contain a varying amount of pigment and vessels.

The gummy nature of the nodules appearing in iritis was conjectured some time since. (*Virchow*). Recently, exact examinations have shown the formations of such tumors to be the same with that of the true syphilitic gummy tumors. A tumor of this kind, as large as a pea, was found to be composed of recent connective-tissue cells, thickly crowded together with strongly-refracting nuclei, which were in the process of proliferation; also, composed of fusiform cells with a distinct cell-wall. These were generally arranged in a certain course, and indicated incipient neoplastic vessels. The tumor in question contained stroma-cells in the process of increase, and scattered masses of pigment. The organic muscular fibers, involved in the tumor, were destroyed. The vessels of the iris were very much distended and increased by new formation; that is, the tumor was very vascular. (*Colberg*).

Again, cases were also observed where the elements indicated the incipient degeneration by the haziness and fatty contents of the cells, or which were even in part dissolved in fatty detritus. The condition of these tumors is at least variable according to time and circumstances, as their different terminations teach us (*Hippel*, *Neumann*).

Their appearance is also not necessarily connected with the existence of secondary syphilis; and on the other hand, with an undoubted syphilitic basis, they show nothing by which they may be distinguished from simple inflammatory products. (*Virchow*).

2. In another class of cases the products of the proliferation of tissue have, from the beginning, the character of pus. In individual cases pus-cells have been found in the tissue of the iris, arranged according to the course of the vessels. Exceptionally, small collections of pus, true abscesses occur. They occasionally break through anteriorly and leave behind an ulcerative loss of substance, or a true perforation with shreddy edges infiltrated with pus. Under certain circumstances the iris, as a whole, may be changed into a mass of pus, and be entirely destroyed by purulent infiltration.

As a rule, however, the pus appears more in the form of a secretion on the surface of the iris. The stroma is interspersed with recent cells. Still, these do not bear the character of pus-corpuscles. Only a coating of luxuriant nuclei and cells is found on the surface, which are shown to be the proximate source of the pus by their fatty contents and their whole structure. It gradually collects on the floor of the aqueous humor, and forms a hypopyon.

Hypopyon often consists entirely of fluid pus, which changes its position with every movement of the eye. The pus of hypopyon, however, often contains thick, flaky coagulations, which are not movable; first, on account of their weight; secondly, because of their disposition to adhere to the walls of the aqueous chamber.

Sometimes these coagulations project forward in mass, and form a kind of framework, in which the fluid pus is, as it were, divided into compartments, so that on a

change of position of the eye, it does not alter its situation. The pus appears sometimes streaked with red, from extravasated blood, or it may even be of a uniform red color.

It is now certain that its origin is not to be exclusively sought for in the iris, but a portion of it, at least, arises from the epithelial layer of the *membrane of Descemet*, and from the ciliary muscle, which is affected with it. (*Hasner, Roser, Graefe.*)

Complications.—Besides the ciliary muscle, whose participation is probably a rule, the ciliary body often takes part in an inflammation of the iris, in which case the process takes the name of *irido-cyklitis*. If, however, the ciliary body be drawn into the process, it not unfrequently happens that the corresponding portion of the sclerotica falls into a state of inflammatory proliferation, in which even the anterior portion of the vitreous humor participates, and brings to light connective tissue, or purulent products in its structure.

Irido-choroiditis, also, frequently occurs. It generally appears connected with retinitis and hyalitis. Not unfrequently the iritis is only a symptom of panophthalmitis. Most frequently, however, the iritis is complicated with inflammation of the cornea, the so-called kerato-iritis, and with capsulitis, irido-capsulitis. An inflammation of the whole lenticular covering is rarely observed in connection with an iritis.

Symptoms.—*These are, a peculiar discoloration of the iris, loss of its normal appearance, and sluggishness or immobility of the pupil, which is generally very much contracted, together with the symptoms of a more or less severe ciliary irritation. To these characteristics, in the greater number of cases, may be added symptoms which are caused by morbid products, varying in amount and nature, and which are not recognizable with the naked eye.*

1. The change of structure of the iris, depending upon the proliferation of tissue, makes the arched, vascular ramifications less distinct, so that the surface of the iris, which in a normal state is so beautifully marked, has more of a regular, velvet-like, a dull, glistening appearance; with this the color itself changes. Blue and gray irides become discolored to a dirty slate-color or yellowish green. Black or brown irides change to an ochre, a cinnamon-color, a ferruginous red or brownish red.

In order to find these symptoms in every case, a comparison of both irides is indispensably necessary. Without this precaution, considerable changes in color will be often overlooked. Moreover, it should be remarked, that an iritis is not present in every case where the iris is discolored, and its normal appearance seems to be gone.

These appearances are also a part of the symptomatology of many of the permanent results of iritis.

Besides, even very striking discoloration of, and indistinctness in the normal appearance of, the iris, are frequently only apparent, and occur with perfect integrity of the iris, and belong entirely and alone to the account of inflammatory opacity of the cornea, or turbidness of the aqueous humor. Only the most exact observation of all the other symptoms, but especially testing the mobility of the pupil, can here protect us from an error in diagnosis.

2. A further necessary result of the proliferation of tissue is the inability of the iris to react to variations in the illumination, i. e., *sluggishness or complete immobility of the pupil.* Indeed, there can be no idea of an inflammation of the iris, where its mobility has suffered but little. Even if the muscular elements have preserved their integrity, they must be very much limited in their action in the stroma, swollen by the proliferation of the elements, as well as in the overloaded vessels of

the iris. Great sluggishness, or complete immobility of the pupil, is therefore an indispensable requirement in order to enable us to make a diagnosis of iritis. Still, at the same time, the fact is to be considered, that an iritis is occasionally, and especially in the beginning of the process, confined to a part of the iris, and therefore the disturbance of function may be also partial.

In the investigation of these symptoms, the greatest care is necessary to guard against deception. In order to test the reaction of the iris, the patient should be so placed that a moderately strong light (ordinary daylight is best) falls obliquely, from one side only, upon the eye. The unaffected eye should be closed, not only with the hand, but also with a folded cloth, so that every trace of light be absolutely excluded from it. The examiner now places himself in such a position before the patient, that, while he throws a very dark shadow on the uncovered eye with his hand, he keeps the pupil in plain sight. Now, fixing his eye upon the edge of the pupil, by removal of the hand a bright light is thrown upon the eye, and then the eye is again shaded, and so on. One or two changes of light and shade will, as a rule, enable us to conclude as to the reaction of the iris, and by attentively following all the precautionary rules, the slightest puckering of the pupillary margin may be detected. Covering the unaffected eye with a folded cloth is necessary, because simple closure of the lids, or covering the eye with the hand, is not sufficient to keep away all the light. A light acting upon the unaffected eye narrows also the pupil of the one that is diseased, and thus considerably weakens the contrast between the light and shadow acting upon the latter, so that with a slight amount of reactionary power, the iris in the affected eye may appear firmly fixed, although it is still movable. A strong light, and a deep shadow, are necessary in order to excite a sufficient contrast, and thereby produce the strongest possible reaction. The edge of the pupil should be kept in view, as well in the shadow as in the light. If this is not done when the hand is removed, the contraction of the pupil is already over before the examiner has distinctly seen it, so that even considerable contractions may escape observation.

Where, in spite of all this careful examination in repeated changes of light and shade, no motion of the pupil is seen, we conclude that there is probably loss of reactionary power on the part of the iris. In doubtful cases, a solution of atropine furnishes a means of making one's self certain. Where, after the use of this, the pupil is greatly and regularly enlarged, a severe, complete iritis is certainly not present.

When partial inflammation of the iris exists, a partial dilatation of the pupil by the use of atropine, or by shading the eye, is naturally not prevented. It should not, however, be forgotten that a want of effect of atropine does not always indicate an iritis, since the immobility of the iris may also have its origin in very many other conditions; in posterior synechia, in paralysis, atrophy, &c. Besides, it is well to consider that very severe conditions of irritation of the ciliary nervous system, such as those which not unfrequently accompany keratitis, may very much lessen the effect of atropine, or even cause it to have no effect at all.

3. Furthermore, an intumescence results from the inflammatory proliferation of tissue, and from the accompanying hyperæmia and serous infiltration of the tissue. This becomes evident as well by increase in thickness, as by enlargement of the width of the iris; that is, contraction of the pupil. The thickening is generally not very marked. Of course, the inflamed iris often appears relaxed and pushed forward somewhat, so that the aqueous chamber appears smaller; but this latter symptom is generally rather the result of a diminution of the aqueous humor. The contraction of the motionless pupil is generally very evident, although it is not a constant symptom, for the iris may be inflamed, with every possible diameter of the pupil.

Contraction of the pupil has been by many described as resulting alone from an increased contraction of the sphincter-muscle. But it is often first seen in stages of iritis in which we have every reason to suppose that the functions of the sphincter have been completely destroyed. Besides, the proof of the dependence of the phenomenon on the *swelling* lies in the fact that, even in old paralysis, or entire degeneration of the iris, such as occurs in inveterate glaucoma, a quickly-appearing iritis causes an angular projection of isolated parts of the pupillary margin, and in general after adhesion of two parts of the pupillary margin, the arch of the latter lying

between is not necessarily limited to a projection forward in a straight line, but presses out over this with a distinct convexity back upon the capsule. This process is exactly opposite to any muscular action.

It is shown by this, that muscular action does not come into consideration in inflammatory contraction of the pupil, but that it can be only considered as an adjuvant.

4. *Hyperæmia*, on account of the density of the walls of the vessels of the iris, is not readily perceived even when it exists. It has already been said, that the hæmodynamic conditions of the intraocular space are not favorable to the development of severe hyperæmia.

Very exceptionably, we find that one or more greatly enlarged branches, evidently venous, appear on the surface of the iris, and have a very irregular course. This is occasionally the case in the later stages of chronic iritis, when the tissue of the iris has already suffered very much and is far advanced in atrophy.

Blood-extravasations, as a result of the disturbance of circulation, however, are not often observed here. They appear as blood-colored, macerated spots in the parenchyma of the iris. Occasionally they show themselves by the bloody color of iritic products, or as free effusions into the aqueous chamber, as the so-called hämophthalmia or a hypohäma.

If, however, the hyperæmia in the iris itself be not very distinct, it is marked on the anterior ciliary vessels, and its collateral branches, by the development of an extremely fine vascular network in the anterior episcleral zone. This is one of the most constant symptoms of iritis. It is even found in the simple irritations of the iris, and belongs in general to the first premonitions of the inflammation in question. The injected episcleral tissue is at the same time generally infiltrated with serum. Often the conjunctival tissue lying over it participates in the hyperæmia and edematous swelling, and elevates itself in the form of a broad, flattish ring—a so-called *vascular ring* around the cornea.

The hyperæmic redness of the episcleral vascular network is generally very bright, evidently arterial, and, on account of the deep situation of the network, plays more or less into a rose or lilac color. Occasionally the sides exhibit a very distinct shade of brown. The conjunctival vascular ring varies in its color from a bright blood-red to a bluish red, indicating the more arterial or venous character of the disturbance in circulation.

Formerly an unjustifiable diagnostic value was ascribed to the various shades of the episcleral redness. It was believed that a syphilitic basis for the iritis could be found when the color was brown; when blue, that it was due to gout; when of a bright-red color, to rheumatism, &c. This is decidedly incorrect. The origin of the brown shade is by no means explained. The predominance of a bright or a bluish color depends upon the excess in the disturbance of the arterial or venous circulation.

It is still important to remark, that exceptionally a very severe iritis may run its course without any exhibition of marked hyperæmia of the episcleral tissue. In the course of puerperal fever, of typhus, of pyæmia, &c., we often have an opportunity of observing such a variety of inflammations of the iris.

The hyperæmia is frequently not limited to the vascular ring. The whole conjunctiva, and even the lids, appear very much reddened and swollen. Especially the border of the upper lid is often decidedly swollen and markedly red, its integument tense, shining, and sensitive.

5. The most inconstant symptom of iritis is the pain. This is not unfrequently entirely absent, or so slight that it scarcely excites the attention of the patient. In other cases it appears among the prodomata, and gradually increases, becoming very severe.

It is c[illegible] different patients as biting, boring, sticking, pressing, and so on. Every external c[illegible] ritation increases it. Very often it is united with photophobia, appearing sometime[illegible]rruptedly, sometimes with remissions and exerbations, again in an intermittent form, and with paroxysms occurring at regular or irregular times of day, it shadows the picture of the disease in the most varied way. To this may be added that it very often does not remain confined to the globe, but radiates in various directions in the course of the frontal nerves, more rarely in the course of the infra-orbital or infra-maxillary.

The cerebrum also very often shows its participation by more or less severe cephalalgia. [illegible]gh it the intestinal canal often participates in the morbid process. Loss of appetite, coating [illegible] tongue, perverted taste, an inclination to vomit or actual vomiting, betray this participation. [illegible]ere is often febrile action.

6. There is always considerable impairment of vision in iritis. This is occasionally the only symptom which [illegible] the patient's attention to the existence of the affection. It results, on the on[illegible]d, from the paralysis of the muscles produced by the proliferation of tissue, and from the loss of the power of accommodation, and the ability to contract the pupil as is required. On the other hand, it may be a result of inflammatory products deposited in the pupil. (See *Capsular Cataract.*)

7. The papillary growths on the pupillary margin are frequently so exceedingly small and scattered so sparingly, that they are only with difficulty recognized with the naked eye: so long as the iritis exists and the pupil remains immovable, and the more so, since, on account of the great amount [illegible]f pigment which they contain, they are scarcely to be distinguished from the blac[illegible] pupil, we must look very closely, and often seek the assistance of oblique illumin[illegible]tion, in order to recognize them as very small brown or black elevations. Of course, they become more marked in proportion to the increase in size. Ridges formed by the deliquescence of the outgrowths thickly pressed together can scarcely be overlooked.

These are from a light-brown to a dark-brown and even dull-black color, often a quarter of a line broad, surrounding a larger or smaller arc of the pupillary margin, following all its deviations, or surrounding the entire pupil, and have a jagged or indistinct margin on the anterior capsule. By no means unfrequently there may be distinguished on them a small central zone, devoid of pigment and therefore of a grayish-white color, with a cloudy, blurred inner border, in which collections of pigment can be discovered only by oblique illumination.

The pupil often appears nearly or completely opaque, when extensive posterior synechia exists. This only shows that there is a capsulitis coincident with the iritis.

The neoplastic border of the pupillary margin, colored by pigment, is lost, toward the center of the capsule, in a pure or yellowish white, which, being irregularly divided, causes maculated, striated appearances, between which the fundus of the eye appears of a bluish color. Often, however, this opacity is actually caused by iritic products, and is only made more striking by a coincidental capsulitis. Deposits on the anterior capsule made under such conditions always exhibit brown or black pigment-contents, at least with oblique illumination and the magnifying glass. Generally the coloring matter is evident to the naked eye.

By means of the irregular distribution of this coloring matter, brown or black spots are formed in the opaque pupil, which, like fruit, are placed on branched striæ of the same color, or there is seen in the pupil a network interwoven with pigmented threads, which are connected with the pigmented exudation-border through whose meshes we may indistinctly see the fundus of the eye.

But occasionally the pigment is more evenly distributed, and so thickly interspersed in the

membranous-like new formation that the pupil, on hasty examination, appears to retain its natural black color, and it is only on more exact observation that the dark brown or even deep black ink-color of the neoplastic growth is recognized.

8. *Gummy tumors and granulations* are, on account of their size, very striking, and scarcely to be mistaken. The real gummy tumors are generally nodules of the size of a poppy-seed or a grain of millet, with conical apices. Occasionally they are more like knobs or warts, with roundish heads. They are distinctly elevated above the anterior surface of the iris. They are often found alone. Occasionally we find them connected to a warty ring, which completely covers the pupillary zone of the iris. Their color, in light irides, is generally a yellowish gray or red, from a great quantity of vessels, sometimes even of a cinnamon-color. In dark eyes they are from a tan-color to a dark brown.

The larger tumors, whether gummy or simple fleshy condylomata, are apt to have more of a cauliflower appearance. Their surface is, as a rule, very rough, glandularly condylomatous. It is then that they extend to the membrane of *Descemet*, where the surface becomes smooth from mechanical reasons. They are often of a dirty flesh color. Not unfrequently the red is changed to a brown color by the pigment contained in the tissue, and even to a decided brown, especially in dark irides, and after long existence of the excrescences. Occasionally they cause repeated hemorrhages (*Secondi*). Growths, which, on account of their structure, incline more to suppuration, have generally a dirty-yellow color, which is occasionally sprinkled with dark pigment.

9. In iritis with purulent products, the iris appears covered over only with a thin gauze-like coating. The pus is quickly thrown off, mixes with the aqueous humor, renders this turbid, and gives it the appearance of whey. Thick flocculi not unfrequently are seen in it, which are deposited every where on the walls of the aqueous chamber, on the posterior surface of the membrane of *Descemet*, and collect on the floor of the cavity in the form of a *hypopyon*.

In other cases the iris is covered over at intervals, or in its entire extent, with yellowish, smeary, cream-like masses, which often appear spotted or streaked from the pigment and extravasated blood which they contain. They form a hypopyon secondarily by their deliquescence. They frequently lie in the form of an even stratum, of greater or less consistency, on the iris and middle of the capsule. Not unfrequently the deposit is also very irregular; often here and there are even seen isolated threads with cloudy or striated edges. Such masses appear most frequently confined to the pupillary portion. They often form there dense plugs, which fully cover the pupil and extend over the central portion of the iris with radiating branches.

10. The purulent deposition, hypopyon, often scarcely elevates itself above the hight of the *limbus conjunctivalis*, and is only found on careful examination in the form of a small pus-colored line. In other cases the hypopyon extends to the lower border of the pupil, more rarely over the pupil, or exceptionally it completely fills the aqueous chamber. It is generally flattened out above, especially when the fluid pus is predominant, where the upper edge, changing its position with every motion of the globe, is a plane surface. But in case the placenta-like formations predominate, the upper margin of the hypopyon may be very uneven.

In primary hypopyon the fluid pus is often mostly absorbed within a short time, while the denser portions resist this process, and are gradually raised above the plane of the hypopyon. This is another mode of formation from that which frequently obtains, where the hypopyon pro-

ceeds from the disintegration of dense morbid products, which are closely adherent to the iris. We usually find these denser portions as little lumps, lying on the anterior surface of the iris, or closing the pupil like a plug.

It is difficult to decide, under such circumstances, whether the hypopyon was primary or whether it has resulted from the partial deliquescence of these solid portions. It is not usually difficult to distinguish hypopyon from onyx.

Causes.—The causes of iritis are very numerous.

1. Almost every imaginable injury which affects the eye may lead directly or indirectly to an inflammation of the iris.

a. The mechanical injuries which most frequently cause an iritis are: foreign bodies which have remained for some time in the conjunctival sac or cornea; stretchings, tearing, and actual separation of continuity of the iris, whether done accidentally or as the result of operations; the mechanical influence of a foreign body in the anterior chamber (*Horner*); or detached portions of cataract, or of a luxated lens; exposure of the iris in consequence of perforations, with loss of substance, and of extensive destruction of the cornea.

b. Chemical injuries are: the effect of severely cauterizing substances acting upon the eye, such as the improper use of irritating ointments, eye-lotions, caustics, etc.

c. Among the physical injuries, probably, sudden changes of various degrees of heat, and their results, elevation and decrease in the heat of the body, play a part. Besides this, the effect of very intense light, especially brilliant contrasts of light, upon the eye, may be numbered among the possible causes of iritis.

d. Among the functional causes, excessive straining of the eye, for the purpose of distinct vision, stands in the first rank.

2. Iritis is frequently secondary; the result of the continuation of the process upon the iris from parts which are either in anatomical or functional union with it.

Choroiditis is in this way often connected with iritis, but it is most frequently combined with keratitis.

The power of transmitting irritative conditions, and of thus exciting the inflammation, is, besides, not confined to single parts of one and the same globe. Many recent observations indicate that inflammations of one globe, particularly iritis and irido-choroiditis, under certain exceptional circumstances, through the aid of the nervous system, may, through sympathy, draw the other globe into participation, and be in a condition again to excite an iritis. (See *Irido-choroiditis.*)

3. Finally, certain constitutional affections are to be named as possible causes of inflammatory processes, which sometimes are confined to the iris, but which sometimes appear in the form of a suppurative panophthalmitis. (See *Panophthalmitis.*)

Thus iritis with hypopyum is said to occur in the intermittent form as a symptom of a vaso-motor neurosis occasioned by malaria, and to be curable by quinine like other latent intermittent fevers (*Staub*, *Eulenburg*).

Among all the so-called dyscrasia, syphilis leads more frequently to iritis; we may say that quite a large percentage of all inflammations of the iris rests on a syphilitic basis.

As a rule, under such circumstances, the iritis appears without any evident external injury. Occasionally, however, one of the causes which have been named is the exciting cause of the inflammation.

Generally iritis first occurs after syphilis has existed for some time, and has

been variously localized. Still, the contrary may take place; the iris may be one of the first parts attacked, or be among the first of the local secondary syphilitic affections.

The combination of syphilitic iritis with a papular syphilitic skin-affection is very common. By many, there has been supposed to be an essential causal connection between the two, and the more so, since iritis not unfrequently occurs during such a papular eruption. The coincidental appearance of iritis and the papular syphilitic eruption, is rather to be explained by the fact that this is one of the most frequent evidences of the existence of the constitutional disease.

Besides, we often find an inflammation of the iris which cannot be denied to be syphilitic, in a case where not a trace of a syphilitic papular eruption can be found, or can be shown in the history. The syphilitic character of the eye-affection betrays itself, however, by the presence of syphilitic ulcers in the pharynx; or, in the absence of all other peculiar local affections, by the swelling of the lymphatic glands of the neck, axilla, elbow, or at least in the inguinal region, which always occur in constitutional syphilis, or by the cicatrix of a chancre. Where there is no evidence of the presence of a secondary syphilis from any of the peculiar local manifestations, not even from the swelling of the lymphatics, every reason for diagnosticating an iritis dependent on syphilis is wanting, even if there be a primary syphilitic ulcer, or one has existed; and yet the iritis may undoubtedly have a syphilitic character; and we will be justified in considering this in the therapeutics, if it appears during the existence of a primary ulcer, without any sufficient external cause, or within a short time after one has healed. The iritis may be a genuine one in the strict sense of the word.

The diagnosis can then only be made from the results of treatment. The syphilitic nature is decided by the insufficiency of simple antiphlogistics, and by the necessity and efficacy of anti-syphilitic remedies.

It has been asserted by many that syphilis shows in iritis some very peculiar evidences, which are not seen in an iritis arising from any other cause, and that we may thus decide from the symptoms as to the syphilitic or non-syphilitic character of the disease. This, however, is certainly an error, as is partly evinced by the fact that different oculists ascribe totally different symptoms to syphilitic iritis. There are no local symptoms and no combination of these which allow us to designate a given iritis as syphilitic; and, on the other hand, any iritis, whatever may have been its peculiar character, may depend upon syphilis, and be subdued by anti-syphilitic treatment.

The syphilitic character of an iritis can only be determined from the positive proof of the existence of constitutional syphilis. For this purpose we must see certain changes on the other parts of the body, the existence of syphilitic eruptions, ulcers of the pharynx, or at least the peculiar swelling of the lymphatic glands. We may say, in general terms, that where the existence of constitutional syphilitic disease is demonstrated by its peculiar localizations, there the syphilitic character of an iritis occurring at the same time is more than probable; but in an opposite class of cases we may say that, at times, grounds for suspicion are furnished by the history, but never premises for a decided opinion.

Time of Appearance.—Iritis occurs at every time of life. It often destroys the good result of an operation for cataract in the most advanced old age, and it is also observed in the newly-born. There are even recorded experiences which render possible the belief in an iritis occurring during fœtal life. (*Himly*, *Pagenstecher*.) The middle period of life, from the twenty-first to the fortieth or fiftieth year, certainly furnishes the greatest percentage. This may be in part due to the greater frequency of traumatic influences and constitutional syphilis at this time of life. Sex seems to exercise no peculiar influence upon the mild or severe course of an iritis. Whether the left iris and irides of a dark color are more disposed to the affection, as some believe, is not yet sufficiently decided.

The occurrence of syphilitic iritis in children, during the first month of life, deserves especial

notice. It is easily overlooked, since it is apt to run a very insidious course, with no very striking symptoms. The ordinary accompaniments of such attacks of iritis, syphilitic eruptions, aphthæ, condylomata about the anus, &c., enable us to recognize the existence of syphilis without difficulty. Such children generally have mothers who had acquired syphilis at a time not far removed from the period of parturition. Well-nourished children are said to be more disposed to it than the opposite class. (*Hutchinson.*)

Course.—Iritis is almost always divided into the acute and chronic forms. Indeed, an iritis often occurs which reaches its highest point within a few days, and quickly [illegible] s of inflammation, which disappear quite as quickly. In other [illegible] furnishes products only very gradually, and, sometimes remitting, [illegible] rbating, lasts for weeks and months before its decline is reached. [illegible] er, only the extremes, which are connected to each other by a great [illegible] diate varieties, and in practice they frequently lose their significa- [illegible] iritis not unfrequently passes into a chronic course, and a typical [illegible] occasionally exacerbates and shows all the characteristics of the [illegible] mation.

The c[illegible] s certainly an influence upon the rapidity or slowness of the process. Inflamma[illegible] f the iris which are caused by external irritants are always more inclined to an acute course than others. The rapidity of this is apt to be proportionate to the amount of injury done by the irritating cause.

Syphilitic iritis is sometimes acute, and sometimes chronic, in the widest sense of the term. Secondary iritis is apt to have a course in accordance with that of the primary affection. Where passive hyperæmia or sympathy has been the chief occasion, the disease is generally chronic.

Staphylomatous corneal cicatrices, as well as complete or nearly complete posterior synechia of the pupillary border, may maintain an iritis caused by them for weeks and months, and produce such a great inclination to relapses, that the slightest provocation is sufficient to set up the process anew. Indeed, cases not unfrequently occur in which the patient, with shorter or longer intervals, is troubled with chronic iritis for years. Generally, choroiditis and retinitis are added sooner or later, if they do not accompany the iritis from the beginning or precede it. Atrophy of the entire globe is then generally the final result. (See *Irido-choroiditis.*)

Results.—The percentage of cures in iritis is, on the whole, large. Very often, however, the inflammation leaves sequelæ, which render the preservation of the functions of the eye more or less doubtful, or which entirely destroy them.

In consideration of this latter fact we should distinguish between changes which the constituent elements of the iris themselves undergo, and those which have their origin in further transmutations of the plainly-marked inflammatory new-formations before described. Frequently morbid conditions of both kinds, in the greatest variety of combination, are the final results of the process. Often, however, the true iris tissue returns to the normal condition, while the neoplastic growths assume a permanent form, and impair the functions of the eye. It very rarely occurs that the iris loses its normal character, when the proliferation of tissue was not sufficient to cause neoplastic formations.

1. As is easily understood, the inflamed tissue of the iris regains its normal condition the more easily, the less it is already changed by proliferation. A short duration and slight degree of intensity of the process, in conjunction with an easy removal of the cause, are especially favorable to a return to the normal condition. On the contrary, a longer existence of the iritis, even with less intensity, as well as

great intensity of the process, and great development of new elements even with a shorter duration of the disease, do not give us so good a prospect for perfect cure, especially when there are difficulties in the way of removing the causes of the affection. Under such circumstances atrophy is a very common result. The prognosis is most unfavorable when the iritis is accompanied by choroiditis, for then the nutrition of the whole globe is in danger. (See *Irido-choroiditis.*)

True atrophy may be sometimes defined as a deliquescence of the elements into material capable of resorption, with a subsequent carrying off of these through the vessels. Sometimes it is a change of the proliferating tissue into dense cicatritial masses, being a kind of shrinkage, obsolescence. Frequently both forms of atrophy are found together. Sometimes they are confined to a portion of the iris. As a rule, however, the whole becomes atrophied.

Atrophy is known to have occurred in light irides by their discoloration, they being changed to a very dirty-slate color, while brown irides acquire a dirty-red or tan-color, occasionally even a fawn-color.

The normal appearances of the iris have disappeared, the variously ramifying, arch-shaped inosculating vessels have been mostly destroyed. In their place we frequently find very irregularly distributed tendinous striæ; some of them straight, some of them branching out like a tree or forming a network; sometimes mixed with spots of the same kind, whose edges appear blurred or fringed.

These tendon-like, neoplastic formations are very plainly distinguished from the dense dark-colored groundwork, by their white or bluish gray, sometimes even bright yellow, color, and satin-like brilliancy, and, according as the number of them is great or small, modify very considerably the whole appearance of the iris. They are very firm and tenacious. Where they are developed in abundance, the consistency of the iris appears increased, often to such a degree that it is torn with difficulty, and then causes a crackling sound. Where, however, they are only sparingly formed, or are entirely wanting, the iris is generally friable, easily torn, even rotten, so that at the slightest touch it is torn in shreds. With this the iris is generally thinned, rarely spongy. The rarefaction sometimes goes so far, that the iris has more the appearance of a gauze-like, extremely delicate transparent membrane.

This degeneration is, as a rule, connected with the formation of false membranes upon the posterior wall of the iris, and is not easily found in a simple iritis, but is almost a constant result of irido-cyclitis or irido-choroiditis.

The dirty-gray, plumbago-like coloring of the thinnest portions is in reality only the appearance of the black fundus of the eye, through the rarefied tissue of the iris.

This has an entirely structureless, molecular basis, in which only here and there strings, or a real network of connective tissue, is found, and which contain in varying quantity free pigment, variously-formed pigment-cells undergoing fatty degeneration, fat corpuscles, free nuclei, choloid bodies, etc. The tendon-like striæ and spots, which occasionally stretch over the surface of this iris as delicate pseudo membranes, but generally are deeply situated in its substance, or permeate the iris in its entire thickness, bear the character of disintegrated connective tissue, containing pigment (*Schiess-Gemuseus*). On the surface of extensive neoplastic plaques the tissue appears at times translucent, exceedingly tough, striated with fibers or completely structureless, and resembles the hyaline very much. Some recognize in it real newly-formed hyaline membranes, which have occurred on the surface of these plaques, by the secretion in layers of a peculiar rigid product (*Donders, Coccius*). It appears, however, as if this explanation were only sufficient for those cases in which the tendon-like neoplastic growths come in immediate contact with the membrane of *Descemet*, or are even adherent to this on account of the complete removal of the anterior chamber, where we consequently may believe that there is a secretion from this membrane (*Graefe*).

Where, however, the aqueous chamber still exists to any extent, that is, where the membrane

of *Descemet* does not participate, this idea of the origin is somewhat forced, and can scarcely be maintained as against the direct proof of the origin of this structureless layer from the degenerating superficial layer of the neoplastic plaques. (*Junge.*) We find that the muscular fiber-cells of the sphincter are either undergoing fatty degeneration, or that they have already completely disappeared. Instead of them appears a smooth bundle of delicate connective-tissue fibers, with interspersed fatty detritus and pigment. The nerves also become atrophied very quickly as a general rule, and are entirely destroyed. We often find numerous remains of the vessels in an atheromatous condition or completely obliterated, and a few advanced in retrogressive metamorphosis. Occasionally such remains of vessels form the chief part of individual parts of the iris. Between them not unfrequently are other vessels, still permeable, which are then often enormously distended, so that they may be appreciated by the naked eye on the living subject as very irregular branches of a venous appearance, curving on the surface of the iris.

These alterations in the vessels explain the very profuse hemorrhages which occur on injury to the atrophied iris. The posterior boundary layer is occasionally thickened, very friable, and delicate; more often, however, it appears to be wanting, having deteriorated into a shrunken mass. The posterior limiting layer is almost always involved in the shrinking false membranes.

It is evident that under such conditions the functions of the iris are always completely destroyed. This is indicated, on the one hand, by the complete immobility of the pupil and loss of the power of accommodation, and on the other hand by striking changes in position and by loss of the normal tension of the iris.

2. *a.* Papillary excrescences on the pupillary margin frequently recede again, so that they cease to maintain the posterior synechia which they have caused. Under the action of the returning muscular power of the iris they are torn even after they are drawn out to thin threads. The remains are easily removed by absorption and shrinkage, so that they are no longer visible to the naked eye. Still, not unfrequently spots, which are richly pigmented, remain on the anterior capsule as an evidence of previously existing synechia of this variety, which appear very plainly on examination with the ophthalmoscope, or by oblique illumination.

Such papillary excrescences are often permanent, however, either in their original form or spun out in longer or shorter threads. They are indicated by a permanent distortion of the pupil, and, when it is dilated, by a very acute prominent angle which the pupillary border forms at the point of attachment. When the sphincter is strongly contracted, and especially when the eye is brightly illuminated, and under great straining of the accommodation, these small growths readily escape observation. Since they are chiefly situated on the peripheral surface, it not unfrequently occurs that, after the inflammation has run its course, the sphincter-muscle, which has again become fully capable of doing its work if properly excited, approaches the center of the pupil, passing over the adhesions. Thus the posterior synechia are completely covered by the pupillary zone of the iris, and the pupil appears round, although its border is adherent to the capsule at several points, and at different distances from the center. The sphincter must then be paralyzed by mydriatics, in order that we may perceive the irregularity of the pupil.

If under such circumstances the iritis recurs, it may easily happen that portions of the iris become adherent to the capsule, and the points of adhesion being stretched to cords, pass beyond the pupillary margin like bridges. It appears that it is such formations which have of late years been described as remains of the pupillary membrane (*H. Cohn, Keyser, Korn, O. Becker*). At any rate they cannot be easily made to agree with the anatomy of the pupillary membrane (*Ammon, Schoeler*).

In exceptional cases even a complete posterior synechia is detached by muscular action. If the pupil were at the same time small, and the capsule in its bounds

covered by iritic new-formation, this remains behind, after the freeing of the pupillary border, occasionally, as a small, strongly demarcated spot on the center of the capsule, representing a so-called central capsular cataract, which increases greatly in thickness by a cataractous transformation of the parts of the lens lying behind, and may become a pyramidal cataract.

b. Dense iritic products in the bounds of the pupil always become permanent. They shrink somewhat, but in spite of this maintain a very considerable thickness. These neoplastic plugs are generally called *false cataracts*, a name which appears to some extent justified by the almost constant association of the condition in question with lenticular cataract. According to this, false cataracts are only distinguished from capsular cataract caused by iritic deposits, by the density of the neoplastic formation.

Various special names are given to the false cataracts, which are derived from the anatomical character of the new-formation. Thus a lymph-cataract is spoken of when the new-formation which has become permanent resembles tendinous tissue in its external appearance, or when the greater part appears composed of it. The name is not changed, if from the symptoms a calcareous or osseous degeneration has occurred. But if the plug has become hardened by hemorrhagic extravasation, or even if the principal part be the remains of a blood-coagulum, and the blood then changes into pigment, the new-formation takes the name of blood-cataract, *cataracta spuria cruenta* or *grumosa*.

A permanent but not very dense new-formation, closing the pupil, is generally described as a pigment-cataract, *cataracta choroidalis*. It is very richly supplied with neoplastic elements, and therefore very dark. These may be perceived as branch-like or reticulate striæ, or may even be of a color varying between a uniform brown and black.

c. In order to be able to speak of a capsular-cataract united with posterior synechia, or a false cataract in the just-described signification of the word, it is assumed that the pupil is quite large.

But it not unfrequently occurs that the pupil is contracted to the size of a head of a pin, or to a narrow, usually irregular, fissure, and retains form from the neoplastic tissue, since an adhesion of the pupillary margin has occurred. This condition, which is incapable of spontaneous relief, is called *atresia pupillæ*, closure of the pupil.

The atresia occurs even during the proper inflammatory condition, but is just as often completed after the iritis has run its course, since the product poured into and infiltrated through the pupillary zone of the iris shrinks, and thus narrows the pupil more and more.

Where the lens with the capsule remains, the pupillary border is always adherent to the crystalline body by the new-formation closing the pupil, and therefore the name capsular-cataract is generally given it. But often, after complete loss of the lens, atresia of the pupil occurs. Then the iris either falls into the aqueous chamber, or is drawn backward in a funnel-shape, since the plug which closes the pupil is in organic connection with the vitreous humor, which is generally already advanced in connective-tissue degeneration and shrinkage.

3. Gummy tumors are quickly absorbed. They may, however, become permanent degenerations.

The smaller then shrink into hard, more or less pigmented, nodules, which often contain much fat and lime. The larger outgrowths, and the granulations which are akin to them, on the contrary, when they are destroyed, change to a tough tendon-

like cicatritial mass, which either only lies upon the surface of the iris, or appears disseminated in the depth of it.

Suppuration is also no very uncommon termination. Suppuration does not often occur in small nodules, or ulcerative losses of substance, which are apt to leave a small radiated cicatrix. Larger gummy tumors, and condylomatous outgrowths, on the contrary, are often removed by suppuration.

Those excrescences especially incline to suppuration which, from the beginning, have more of a caseous color. The result is then generally a formidable *hypopyon*.

4. Hypopyon, whether it be primary or secondary, that is, when it has resulted from the deliquescence of inflammatory tumors, is generally absorbed without especial difficulty. The difficulties are the less, the smaller the collection of pus in the aqueous chamber, and the slighter the amount of dense material which they contain. Sometimes a few hours only are sufficient to cause quite a large hypopyon to disappear, while in other cases days and even weeks are necessary for the same result. Besides, the absorption is by no means always a steadily-advancing process; often there is an increase and decrease of the hypopyon observed. It even not unfrequently disappears several times in the course of an iritis, again appearing, until finally the process comes to an end.

Frequently, however, an iritis accompanied by hypopyon leads to morbid conditions, which very much impair the functions of the eye. On the one hand, in such cases, the abundant development of papillary excrescences on the pupillary margin is the rule; and besides, degenerative atrophy of the iris, after so severe a process, occurs very frequently. But, on the other hand, the absorption of the hypopyon is not always complete; portions of it remain behind in the eye. Especially in the case of large accumulations of pus in the chamber, a complete disappearance is one of the rarer occurrences, although it is not to be denied that occasionally a hypopyon which fills up the entire aqueous chamber is quickly and completely absorbed. It is especially the flocculent coagulations in hypopyon which readily become permanent. A portion of it changes to a rigid tendinous mass, while the remainder undergoes calcareous and fatty degeneration.

Most frequently such new-formations, after hypopyon, are found in the deepest portions of the aqueous chamber. It fills up the crescentic periphery of the chamber to a varying height, and is continued upon the membrane of *Descemet*, and the anterior surface of the iris, in the form of cloudy, striated spots, covering over these parts to a greater or less extent. After a very large hypopyon, the entire posterior and anterior walls of the chamber remain covered by such depositions. They are apt to be especially abundant in the pupil, and to form a firm plug, which completely covers it, and thus makes a false cataract. These conditions assume that the cornea was able to preserve its normal state, which is frequently not the case. A suppurative iritis often begins in company with a suppurative keratitis, or the inflammatory process in the course of an iritis is continued upon the cornea. This is partially destroyed by ulceration, perforated, and thus a way opened for the exit of the hypopyon.

Not unfrequently the process is here arrested, the iritis recedes, and a perforating corneal ulcer is added to its consequences. On the other hand, the process often proceeds still further, the globe is destroyed by atrophy or phthisis, the deeper-lying parts of the eye being involved in the process. With a very large collection of pus in the aqueous chamber, such a transition of the iritis to suppurative panophthalmitis is quite frequent, and results either before the suppurative perforation of the cornea, or certainly after it.

Treatment.—The therapeutic indications are:

1. Removal of the causes that are still somewhat active.

2. Keeping away all sources of injury which may maintain or even increase the inflammatory process.

3. Diminution and limitation of the proliferation of tissue, and a reduction to the normal mean of the increased nutrition.

4. Prevention of the possible dangers from iritic neoplastic formations.

5. In case this latter does not succeed, the direct removal or lessening of the disturbance of function caused by them.

1. In order to fulfill the indications arising from the cause of the disease,

a. Operative means are, by no means unfrequently, necessary. Where foreign bodies which are in the conjunctiva, in the cornea, or in the interior of the globe, are the proximate cause of the iritis, their operative removal is the imperative duty of the surgeon. If this be not done, the globe, as a rule, is completely destroyed, or becomes incapable of performing its functions. This rule is also applicable in cases in which the lens has fallen into the anterior chamber, or pieces of cataract have become detached, and, lying in the anterior chamber, irritate the iris, or where a lens which has been incised swells greatly, and thus presses or stretches the iris mechanically. Extraction of the lens can then scarcely be avoided without great danger, and is best performed as quickly as possible, when, for reasons to be subsequently given, iridectomy does not appear more appropriate. Where there is reason to believe that an existing iritis has been excited from sympathy with an inflammatory process in the other eye, accompanied by severe irritation, the latter may require the formation of an artificial pupil, and, under some circumstances, even the enucleation of the globe. In the case of chronic iritis, in which relapses constantly occur which are maintained or favored by existing *synechia* of the pupillary margin, we should not delay the performance of an iridectomy, since by its postponement the treatment of the inflammation is apt to have only a transient effect. Besides, at each relapse, the danger of atrophy increases, and the prospect of the restoration of a certain amount of vision is lessened. As the best time for the performance of the operation, we choose the first decided remission. As long as the inflammatory symptoms are still somewhat prominent, the operation is apt to be very painful; hemorrhage often occurs, and, as a further result, the newly-formed pupil is again closed. In general, when thus performed, the danger of a severe reaction is great, and the hope of a successful result is therefore slight.

b. As to the rest, iritis demands a severe dietetic regimen. In the great danger which is attached to every iritis, even when it runs its course with no very marked symptoms, the watchfulness of the physician, and his care in keeping away all possible sources of injury from the eye, can not be too assiduous. The greatest bodily and mental rest of the patient, his abode in a darkened room, the recumbent posture, the avoidance of every thing which may cause the slightest straining of the eyes, the removal of opportunities for hyperæmia and congestion, are indispensable requirements.

c. Very especial causal indications arise from the dyscrasial origin of many inflammations of the iris. In syphilitic iritis, especially, the rapidity with which the process, when once established, may excite conditions which, having occurred, are only removed with difficulty, or which oppose every therapeutic procedure, and permanently impair or destroy the functions of the eye, should be considered.

We should therefore treat the constitutional disease with remedies which act the most powerfully and certainly in the shortest time, but which do not easily do

harm to the general system, causing results which lead us to interrupt the treatment at a time in which the iritis still exists, as well as the constitutional disease. According to experience, these requirements are best secured by a well-conducted inunction treatment. In marked cases the treatment should be commenced at once, except where we know that it will not be borne. Trifling with the other mercurials and other unreliable remedies is often bitterly punished.

2. The *indication from the disease*, and the treatment of the iritis proper, in accordance with this, are in the main directed according to the severity of the process, and the vascular and nervous disturbances accompanying it. On the whole, the rules here hold good which are to be observed in the direct treatment of keratitis, and any other inflammation. The process is every where the same, only the substratum is different.

3. From the beginning of an attack of iritis, there are a number of urgent indications to be fulfilled, resulting from the frequent appearance of certain neoplastic formations. These indications aim at the prevention of permanent results of inflammation, which impair the functions of the eye.

***a.* The papillary outgrowths of the pupillary margin play the most important part in this respect, with the adhesions of the iris to the anterior capsule caused by them. There is scarcely an iritis in which one or the other form of pupillary excrescences does not occur, or at least the danger of a partial adhesion of the pupillary margin to the capsule. From this, the necessity is seen of uniting the therapeutic means, intended to secure the limitation and suppression of morbid proliferation of tissue, with instillation of a strong solution of neutral sulphate of atropia once or twice a day, in order to oppose recent synechia as rapidly as possible.**

Of course, in a true and complete iritis the effect of the mydriatics is not observed at once to a marked degree. A dilatation of the pupil only occurs when the inflammation proper has passed over its point of culmination, and the muscular fibers under the retrocession of the newly-formed elements have again become capable of performing their functions. But it is not possible to exactly fix the time of the appearance of these conditions, and every delay is punished by increasing firmness of the adhesions and difficulty in removing them. The timely use of the mydriatic has for its object, aside from its effect in lessening irritation, the preparation of a way for the enlargement of the pupil, in order to accomplish this at the moment when the muscular fibers have attained the necessary freedom.

b. Collections of pus in the anterior chamber occur much more rarely, and require special treatment. The old belief in the absorbent power of mercurials and the preparations of iodine has been very much lessened in modern times; but the direct evacuation of the aqueous chamber by means of a paracentesis of the cornea is constantly gaining more friends. There is, indeed, no doubt that this procedure far exceeds all others in efficacy in the case of hypopyon, and that it often produces astonishing results. Where, therefore, the hypopyon is quite large, the evacuation should not be long postponed, and in case of necessity it may be repeated. The greater the amount of pus collected, the severer the condition of irritation, the more intense the disturbances in circulation and the nervous excitement, the more imperative become the indications, and far more dangerous the postponement of the operation. Where the deeper parts of the eye are also affected, and a marked increase of the intraocular pressure is evident, or the cornea is already attacked, and a spontaneous perforation is to be feared, the danger has risen to the highest point, and the immediate paracentesis of the cornea is the vital indication for the affected eye.

The favorable results and the relative want of danger of the paracentesis have led, as will be understood, to a greater frequency in its indication. In later times, the operation in question is said to be one absolutely indicated in depositions of pus in the smallest hypopyon, and even when the aqueous humor is only turbid. There is nothing really to be urged against this, especially in those cases in which the inflammation is still progressive, and we may expect an increase of the pus in the chamber. But no objection can be made to some delay, since it is well known that a small hypopyon often disappears spontaneously in the shortest time, without leaving behind any evil results.

Paracentesis has, on the one hand, a favorable effect, by evacuating the pus directly from the aqueous chamber, and thus preventing the flocculent coagulations which resist absorption from being developed on the walls of the chamber, and there consolidating. On the other side, the diminution of the intraocular pressure is not to be lightly estimated.

4. The after-treatment requires scarcely less care than the treatment of the iritis itself. It is first directed toward protecting the eye from every source of injury. The patient may only gradually return to his ordinary avocations.

An extremely important part of the after-treatment is the removal of certain permanent results of iritis; and among others, the so frequently occurring adhesions of the pupillary margin to the anterior capsule, or the removal of their distinctive influence upon vision, and the subsequent nutrition of the eye.

The means for fulfilling these indications are especially the use of powerful mydriatics, and the performance of certain operations. In the cases in which the condition of the tissue of the iris allows us to suppose that muscular fibers capable of performing their functions still exist, the treatment of posterior synechia should always be begun by the application of strong mydriatics, and be continued until the pupillary margin is free, or the remedy has shown itself insufficient. It generally requires some time to secure the end. If, therefore, the first application is not successful, we should not hesitate to repeat it. In peripheral adhesions, the preparations of calabar-bean may be of use. (*O. Becker.*)

Very recently it has been recommended to separate posterior synechia, which are troublesome, and which can not be detached in the manner described, and to then keep the pupil dilated by powerful mydriatics for as long a time as possible, thus keeping the divided parts away from each other, and preventing their reunion. (*Streatfield.*) The brilliant result, and the entire want of danger in the operation, which has been called *corelysis*, are estimated highly. (*A. Weber, Hamer, Passavant*).

The necessity of a mydriasis which is powerful, and which continues for some time, is shown by the fact that *corelysis* can only be properly performed where the muscular system of the iris has preserved its functions, and where the pupillary margin, at least in its greatest portion, is easily distended. A good result may be especially expected from a corelysis in a partial posterior synechia, whether this is produced by numerous scattered papillary outgrowths, or by delicate, small, border-like neoplasia. So long as irritation still exists in the iris, or the neighboring parts, corelysis does not appear advisable, since the muscular power of the iris is very much impaired, and, therefore, the effect of the atropine is insufficient, not to speak of the possibility of a severe reaction.

In the same way, corelysis is not indicated where the pupillary margin is adherent entirely, or chiefly, to the capsule by means of formidable inflammatory products, or where its structure is altered to any great extent, or where the whole iris appears atrophied.

Where the whole pupil is covered by iritic depositions or by the products of a capsulitis, the separation of the pupillary margin is evidently not sufficient to re-establish even a moderately satisfactory amount of vision. Corelysis can then, at the most, only serve to make an iridectomy possible and useful.

An artificial pupil is indicated where, in the existence of a complete or nearly complete posterior synechia, the mydriatics can not accomplish their object, or where,

on account of the condition of the tissue of the iris, it is seen beforehand that a powerful muscular contraction is impossible, and then the operation should not be long postponed. It is here, as has been said, not only a question of the reestablishment of a passage for the rays of light to enter, and of an improvement of vision, but also the prevention of the very unpleasant and not rare consequences which may result from this condition. The tissue of the iris is more and more changed at each relapse, and approximated to the final atrophy. The deposition on the anterior capsule is increased, and thus the prospect of the success of a subsequent operation lessened. The principal danger of the postponement of the performance of an iridectomy lies, according to experience, in the inclination of the choroid to participate in such relapses. Besides, the fact is to be taken into consideration that, in long continuance of the condition in question, the nucleus of the lens often becomes affected, and thus a complete cataract is formed. The removal of this involves many difficulties, while, by a timely iridectomy, we might have reasonably hoped to somewhat clear up the opacities of the capsule. It is sufficiently shown from all this, that the extent and thickness of the capsular opacities can only secondarily influence the indication for an iridectomy, and that the operation appears advisable in cases in which attacks of inflammation and ciliary neurosis are often recurring, or even cause us to fear a transition of the process to the deeper parts of the eye, even when the vision is relatively little impaired. The damage which may be done to the expression of the face by the artificial pupil, is easily made very small by making it upward.

Authorities.—*Kölliker*, Mikr. Anatomie, Leipzig, II. 2. 1854, S. 637.—*Henle*, Handbuch der Anatomie, 1866, II. S. 628, 685.—*Brucke*, Beschreib. des m. Augapfels, Berlin, 1847, S. 12.—*Arlt*, A. f. O. III. 2. S. 87, 97.—*Cramer*, Het Accommadatie vermogen, Haarlem, 1853, S. 61.—*Stellwag*, Zeitschrift der Wiener Aerzte, 1850, S. 125, 129.—*Cramer's* Phys. Abhandl. über das Accommodationsvermögen der Augen, übersetzt von *Doden*, Leer, 1855, S. 89. J. Arnold, Virchow's Archiv. 27 Bd. S. 345, 366.—*Grunhagen*, ibid. 30 Bd. S. 481.—*Wittich*, A. f. O. II. 1. S. 131.—*Rosow*, A f. O. IX. 3. S. 63, 65.—*Leber*, Denkschriften der Wiener k. Akad. d. Wiss. 24 Bd. S. 287, 305, 307, 311, A. f. O. XI. 1. S. 1.—*Wedl*, Atlas Iris-Choroidea.—*Alf. Graefe* and *Colber*, 9 A. f. O. VIII. 1. S 288.—*Virchow*, dessen Archiv. XV. S. 217, 305, 321, 326, die Krankh. Geschwülste, II. Berlin, 1864, S. 462.—*Graefe* and *Schweigger*, A. f. O. VI. 1. S. 143, 151, 152, 161, VI. 2. S. 267, 272.—*Hasner*, Entwurf einer anat. Begründung der Augenkrankheiten, Prag, 1847, S. 110. Klin. Vorträge, Prag, 1860, S. 165. Prager Vierteljahrschrift, 76 Bd. S. 137. Congress intern. d'ophth. compte rendu. Paris, 1863, S. 75.—*Roser*, A. f. O. II. 2. S. 151.—*Junge*, ibid. V. 2. S. 200, Med. Centralzeitung, 27 Jahrg. S. 301.—*C. Ritter*, A. f. O. VIII. 1. S. 63.—*Schiess Gemusseus*, ibid. IX. 3. S. 174, 183, 193.—*Horner*, kl. Monatbl. 1863, 395, 396, 400.—*Sämisch*, ibid. 1865, S. 46.—*Zander* and *Giessler*, die Verletzungen des Auges, Leipzig und Heidelberg, 1864, S. 160, 169, 177, 181.—*Graefe*, A. f. O. II. 2. S. 202, et seq. III. 2. S. 387, IX. 3. S. 127.—*Himly*, Krankheiten und Missbildungen des Auges, Berlin, 1843, S. 100.—*Pagenstecher* and *Sämisch*, kl. Beobachtungen, Wiesbaden, 1861, I. S. 17, 2. S. 9.—*Schön*, Beiträge zur prakt. Augenheilkunde, Hamburg, 161, S. 88, 123.—*Hutchinson*, A clinical memoir, &c., London, 1863, P. I. 25, 192.—*Secondi*, Clinica oc. di. Genova, Riassunto, Torino, 1865, S. 28.—*Donders*, A. f. O. III. 1. S. 150.—*Businelli*, Zeitschrift der Wien. Aerzte, 1859, S. 108, 137, 155, 217.—*Coccius*, über die Neubildung von Glas-Häuten, Festrede, Leipzig, 1858, S. 9, 12.—*M. Langenbeck*, die insulation des m. Auges, Hanover, 1859, S. 18.—*O. Becker*, Wiener Med. Jahrbuch, 1866, 4. S. 37.—*Streatfield*, Ophthalmic Hospital Report, 1857, October.—*A. Weber*, A. f. O. VII. 1. S. I. VIII. 1. S. 354.—*Grünhagen*, Virchow's Archiv. XXXI. S. 403, 406; XXXVI. S. 40, 45.—*Dogiel*, Centralbl. 1869, S. 337.—*Merkel*, Zeitschrift f. rat. Med. XXXI. S. 136, 142; XXXIV. S. 83.—*Haase*, A. f. O. XIV. 1. S. 47.—*Iwanoff*, *Rollet*, ibid. XV. 1. S. 38–50; XV. 2. S. 8.—*H'ppel*, *Neumann*, ibid. XIII. 1. S. 64, 70.—*Passavant*, ibid. XV. 1. S. 258.—*Graefe*, ibid. XII. 2. S. 151.—*Schirmer*, kl. Monatbl. 1867, S. 107.—*Wecker*, ibid. S. 243.—*H. Cohn*, ibid. S. 62, 119.—*Keyser*, ibid. S. 217.—*Korn*, ibid. 219.—*Dobrowlski*, ibid. 1868. S. 239.—*Ammon*, A. f. O. IV. 1. S. 149.—*Heymann*, Ophthalmologisches, 1868. S. 23.—*Schoeler*, De oculi evolutione, Milan, 1849, S. 33.—*Staub*, *Eulenburg*, Wien. med. Wochenschrift, 1867. S. 1140.

THE OPERATION FOR THE FORMATION OF AN ARTIFICIAL PUPIL, IRIDECTOMY.

Indications.—Iridectomy is undoubtedly the most frequently performed of any of the operations on the eye. It serves not only to open a new way for the rays of light to enter the eye, to enlarge the morbidly contracted or displaced pupil, but also to diminish the increased intraocular pressure, as well as to restore to the capsule of the globe a certain degree of distensibility, and therewith to permanently relieve any disturbances in the circulation and nutrition of the inner parts of the eye.

The formation of an artificial pupil appears to be indicated, or at least is recommended, by many, under the following circumstances, viz.:

1. In the existence of dense opacities of the cornea which can not be cleared up, and which cover the greater part or the whole of the pupil, whether they are connected with anterior synechia of the iris or not.

2. In *atresia pupillæ*, closure of the pupil, false cataract, especially in complete or nearly complete posterior synechia of the pupillary margin, with or without coincident opacity of the capsule and chronic iritis depending upon it, irido-choroiditis, panophthalmitis, as well as where there is sympathetic affection of the other eye.

3. In ulcerative processes in the cornea which require a relaxation of tension by a paracentesis, but which, on account of their position and extent, cause us to expect a corneal opacity, which will require an artificial pupil.

4. In the various forms of corneal and scleral staphylomata.

5. In glaucoma.

6. In lateral displacements of the lens, when a portion of the transparent crystalline displaces the pupil, and thus becomes the cause of impairment of vision.

7. In partial opacities of the lens and capsule, which greatly injure the sight, and which are stationary or advance very slowly, and therefore do not allow us to expect the maturity of the cataract for a long time, and which, besides, can not be directly removed without considerable danger, so long as the cataract is not further advanced.

8. In swelling of a cataractous lens, if the capsule has been opened by an accident or by an operation, but in which the evacuation of the larger part by a paracentesis of the cornea does not succeed, and if the cataractous-lens substance presses the iris forward, or lies in the pupil or aqueous chamber, and thus mechanically irritates the iris and threatens a closure of the pupil by inflammation.

9. As an auxiliary in the various cataract operations.

10. To assist the removal of foreign bodies which lie in the aqueous chamber, or are in the iris, and which can not be removed without tearing or injuring it.

11. In obstinate myosis.

Method of Performance.—Up to this time an incredible number of methods, more or less different, have been recognized. (*Himly.*) The so-called iridectomy,

cutting out a piece of the iris (*Beer*), stands highest as to success and safety. All the other methods have been almost entirely abandoned, and properly so, since iridectomy, under almost all circumstances, is more easily performed, and, with only very slight modifications, successfully.

The instruments required are a straight, or, in case the artificial pupil is to be made inward or upward, an angular, lance-shaped knife, a delicate straight hook or slightly curved *Fischer's* forceps, and a small *Louis's* scissors.

Instead of the forceps, the little iris-hook is much used. It is harder to manage than the forceps. It easily injures the capsule, and does not so readily allow a measurement of the size of the pupil. Whoever wishes to use it, should choose one with a neck which may be bent (*Himly*). It is often necessary to bend the hook in order to reach over the nose.

Recently it has been thought that the linear incision could be better made with Graefe's narrow cataract knife (*Wecker*, *Le Gad*). Special advantages have been promised from it in cases of extensive corneal cicatrices, where only a very small peripherical portion of the cornea has remained transparent; in ulcers of the cornea with suppurative iritis or iridocyclitis, in iritis with hypopyum and disease of the vitreous, in formation of false membranes upon the posterior wall of the iris, for removing a cysticercus or foreign body from the vitreous, etc. In glaucoma this procedure seems more dangerous, on account of the easy rupture of the zonula, adhesion of the iris in the wound, and cystoid cicatrization (*Graefe*).

The so-called ophthalmostat, an instrument for keeping the ball fixed in a certain position, is especially to be recommended when the artificial pupil is to be made upward. Even with very quiet patients the eye readily rolls upward and is covered by the upper lid. When the eye thus turns upward, in spite of every precaution, injury to the capsule is easily caused. We are not always able, after the entrance of the knife into the aqueous chamber, to turn it quickly enough when the eyeball rolls upward, and thus the point of the knife enters the capsule. On withdrawing the knife from the chamber, when the eye is forcibly turned upward, we are obliged to turn the point very far back, and thus the capsule is easily torn.

A toothed forceps, by which the ocular conjunctiva is seized near the cornea, answers the best as an ophthalmostat. Forceps whose grasp is insured by a slide, are not so well fitted for use, because they can not always be opened quickly enough and the instrument removed, when the patient unexpectedly moves his head. Seizing the conjunctiva at a greater distance from the cornea, and fastening with it a portion of one of the recti muscles, we avoid tearing the conjunctiva, but are apt to cause rotary movements of the eye, which render the operation very difficult. In very restless patients, especially in children, fixation does not answer at all, since it is painful, and makes the patient resist more, or renders the muscles very tense. In such cases anæsthesia is imperatively necessary.

Any especial preparation for the operation is superfluous. Still the operation should not be performed in an entirely empty state of the stomach, or after a full meal. The patient may sit during the operation, or lie down; the latter position is preferable. An assistant holds the lid open; the other eye is closed by a protective bandage.

Contracting the pupil with the calabar-bean (*Graefe*), when it has been previously very much dilated by mydriatics, or in consequence of morbid processes, does no harm, but is of no especial advantage. Where the reactive power of the muscles of the iris still exists, the flowing off of aqueous humor after the section of the cornea is sufficient to excite a powerful contraction of the pupil.

The operation is divided into two quite different steps. The first consists in opening the cornea by an incision from two to two and a half lines long; the second consists in drawing forward and cutting off of the piece of iris to be removed.

The incision in the cornea should always be made perpendicular to the meridian

of the piece of iris to be cut out. Where the iridectomy aims at making a way for the rays of light, and where a somewhat central pupil may be made, the incision should fall a little outside of the middle of the corneal curvature. But where we are obliged to content ourselves with more of an eccentric pupil, it is best to make our incision a quarter of a line from the border of the cornea, in order that the remaining peripheral portion of the iris may intercept the outermost peripheral rays. Where there is only a small space for the pupil on the corneal border, we should cut into the sclerotica about half a line from the margin of the cornea, and carry the knife in such a way that it enters the chamber exactly at the ciliary margin of the iris. The firm adherence to this rule is of the greatest importance in those cases in which the iridectomy is intended to influence in a remedial way the circulation and nutrition in the interior of the eye. If under such circumstances the incision is made within the corneal border, the operation is always fruitless. The knife should then be held obliquely when it is entered into the sclerotica. If, however, the incision is made in the cornea, the instrument should penetrate almost vertically through it, and as soon as it has entered the aqueous chamber it should be immediately turned, and its point pushed as far between the iris and the membrane of *Descemet* as the required length of the incision may demand.

The knife should be withdrawn very slowly, in order that the aqueous humor may not escape too quickly; otherwise the very sudden relaxation of the globe may easily cause intraocular hemorrhage with all its evil results, especially when morbid processes in the uvea and retina have considerably altered their vessels. Under such circumstances it is also well to exert a little pressure with the finger on the globe, and keep it tense until the bandage is applied. (*Graefe.*)

The second step in the operation always requires both hands of the operator. One hand uses the forceps, the other the scissors. The forceps should be held very lightly, and carefully placed in the corneal wound, with the convexity toward the globe, and carefully pushed forward to very near the pupillary margin of the piece of iris to be cut out. Then they are to be opened, just wide enough for the breadth intended of the artificial pupil. As soon as this portion of the iris near the pupillary margin is fairly and certainly seized, it is separated by delicate and gradual traction from any existing adhesions, and (Fig. 37) slowly drawn out with the forceps. During this, the scissors are placed with the convexity of their blades flat upon the globe, and as soon as a sufficiently large portion of the iris appears to be drawn forward, it is quickly cut off close to the edge of the corneal wound.

Fig. 37.

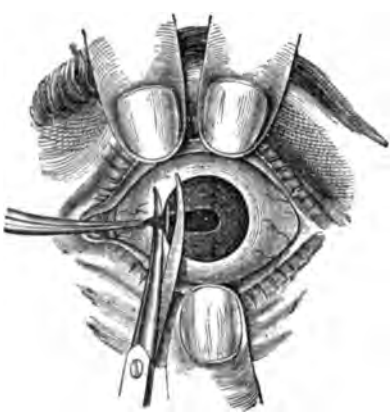

The greatest care must be observed that no part of the iris remains in the wound, which easily occurs at the angles, so as to avoid the consequent irritation and subsequent unfortunate lacerations of the iris. If, therefore, the adherent portion of the iris does not recede after a slight rubbing of the closed eyelids, then we must resort to Daviel's spoon.

Where the artificial pupil is intended to furnish a new way for the rays of light through the dioptric media of the eye, or to enlarge the natural one laterally, a section, one line in breadth, is sufficient; a larger pupil is apt to considerably impair the vision; because, when the visual field is powerfully illuminated, it readily causes very disturbing, dazzling sensations, and, besides, the circles of dispersion, arising from the want of accommodation, give too large a diameter to the retinal images. This circumstance renders it advisable to make the artificial pupil upward, when the operation is performed in a clear cornea, on account of extensive or complete posterior synechia, and the central portion of the capsule is still transparent enough to render quite distinct perceptions possible.

In the case of central corneal opacities, the interior and lower quadrant of the iris should be cut out wherever it is possible. In every case very opaque or cicatrized portions of the cornea are to be avoided, in order that a *cicatricial* keratitis may not be excited.

If we suspect the presence of thick false membranes upon the posterior surface of the iris, which do not lie in folds and are difficult to grasp, we must introduce the forceps in a very vertical manner. A peculiarly constructed pair of forceps (*Liebreich*) is not needed. As the false membranes are often very deeply pigmented, and after removal of the superjacent layers of iris are frequently with difficulty perceived, it is necessary, in operating on these cases, to employ oblique illumination (*Knapp*).

When we desire to oppose the evil influences which a firm, unyielding globe, or an increase of the intraocular pressure, exerts upon the circulation and nutrition of the eye, it is imperatively necessary to give the incision in the sclerotica a length of more than two lines, and to cut out a large segment of the iris.

Often even this is not sufficient; the sclerotica becomes tense again in a short time, and the unpleasant consequences reappear. If we then wish to attain to the end in view, the operation must be repeated, a second incision being made near the first one, and another portion of iris removed. In order to limit the dazzling sensations as much as possible, under such circumstances, the pupil should always be made upward.

If a foreign body is to be removed from the aqueous chamber, or from the iris, the meridian of the scleral border corresponding to the body should be chosen for the incision. In this case it is well not to incline the point of the lance-shaped knife straight toward the center of the pupil, but to push it obliquely to one side of the foreign body, and to keep as close as possible to the posterior layers of the cornea, in order not to disturb the foreign body in its position, or to strike at the place which would be with difficulty reached with instruments through the wound. If granulations or any kind of vascular exudations have formed around it, such a separation of these exfoliations is often attended by severe hemorrhage, which completely fills up the aqueous humor, and renders the extraction extremely difficult, or entirely impossible. This circumstance causes the attempt to seize the foreign body alone, and extract it, to seem improper. This attempt rarely succeeds, without twisting the foreign body a great deal; and if it has sharp angles or corners, it generally causes severe injury to the iris, or even to the capsule of the lens; and this is the more apt to occur, since after the escape of the aqueous humor the parts in question are pressed forward by the vitreous humor, and the foreign body is, as it were, hemmed in. It is, therefore, well to introduce the forceps into the aqueous chamber with opened blades, so that the foreign body may lie quietly between them, then to push the forceps as far forward as the pupillary margin, then to open the

forceps somewhat wider, and finally to close them. This fastens the portions of iris lying on each side of the foreign body, these being forced between the branches by the pressure of the crystalline lens, and the foreign body is brought out, as it were, in a protecting envelope. (*Horner.*)

Sometimes the extraction of a foreign body may be assisted, by withdrawing the knife quickly after the incision is completed, and thus securing a speedy evacuation of the aqueous humor.

Not unfrequently, then, the iris, with the foreign particle adherent to it, is pushed out of the wound, and the prolapsed iris has only to be cut off, after the foreign body has been secured with the forceps. Besides all this, however, peculiar circumstances require peculiar rules and manipulations.

It is not unimportant to remark, that the artificial pupil seldom shows its true size and form immediately after the operation, since the adjacent portions of the iris are pushed against the opening in the cornea by the forceps, and are held there by the lens, which presses against the membrane of *Descemet*. It assumes its natural position when the wound has united, and the aqueous humor has again appeared.

A binocular protective bandage should be applied after the operation is finished. It is also advisable to close, with isinglass-plaster, the lids of unreliable patients who are apt to try their vision too soon, or who from carelessness and want of intelligence may push the bandage to one side. Where there is danger of intraocular hemorrhage, the pressure-bandage should be drawn tighter, and be loosened only some hours after. The bandage should remain on several days, but the charpie or cotton may be changed frequently. In the mean time, the patient should be kept in a state of perfect bodily and mental rest. The recumbent posture, in bed, is the best. Where this is, however, very difficult, it is of advantage to cause the patient to lie on the side that has not been operated upon, or even to recline on a sofa. The diet should be, the first few days after the operation, confined to soup, vegetables, steamed fruit, &c. Lond talking, as well as every vigorous exercise of the masticatory and respiratory muscles of the face, is to be strictly forbidden.

If symptoms of irritation or of inflammation appear in the globe, these rules are to be enforced with double strictness, and antiphlogistic treatment should be begun. In favorable cases the bandage may be removed in from six to eight days, and the patient gradually return to his ordinary occupation.

Accidents.—1. *An incision which is too oblique.*—If the lance-shaped knife passes very obliquely through the thickness of the cornea, so that the points of entrance and of exit are far removed from each other, the forceps may easily seize the posterior lip of the corneal wound instead of the iris. This is thus bruised, pressed open, and occasion given for severe inflammation—opacity of the part of the cornea in question. It may even suppurate, and atrophy of the entire globe result. The same danger is incurred with such an incision, even if the iris is seized, since it can not follow the forceps without rolling up and passing the posterior lip of the corneal wound. If the iris does not *tear* out, as generally happens, but is removed by the traction, its connection with the border of the membrane of *Descemet* and with the ciliary body may be separated, or it may suffer an extensive tension, and in spite of it the pupil may be very small, since the greater part of the piece of iris seized with the forceps lies within the corneal wound, and consequently can not be touched by the scissors. This unpleasant accident is particularly to be feared when the operation is performed with the angular iridectomy-knife, without any consideration of the fact that, in order to penetrate the cornea vertically with this instrument, its point should be directed somewhat toward the opposite side of the eye from the incision.

2. *Tearing the piece of iris seized by the forceps.*—This accident is less to be feared in the use of the forceps than in the employment of the little hook. It is

particularly to be feared when the iris is greatly atrophied, when its tissue, as is not unfrequently the case, is very weak and rotten. The repeated bringing forward of small bits for the purpose of enlarging the pupil, is generally very difficult, particularly when hemorrhage occurs and the blood covers every thing. This generally leads to severe irritation. Where the iris is very much changed in its external appearance, the forceps should be widely opened and a broad piece seized, in order to obtain a sufficiently large pupil in case the iris should tear.

3. *Remaining behind of the pupillary margin of the iris.*—Where the pupillary border is firmly adherent to the capsule, it often remains there in spite of slow traction with the forceps. This is, however, of not much importance where the operation is done on account of complete posterior synechia. A forcible separation by means of the little hook would lead to injury of the capsule and much worse consequences. It is therefore well not to make any further attempts at detachment. But where the portion of iris in question is free, in order to break up the bridge the little hook should be introduced, and the double pupil changed to a single one.

4. *Remaining behind of the altered pigment-layer, or rather of membranous new-formations in the field of the artificial pupil.*—It sometimes happens that the fibrous tissue of the iris is removed to a sufficient extent, and that immediately after the operation the pupil appears black. But after the bandage is removed, and absorption of any blood which may be in the anterior chamber has taken place, it is seen that the newly-made pupil is covered over by a membranous new-formation richly supplied with pigment. The necessity of not seizing the iris with the forceps too superficially is seen from this. But if this has already occurred, the mistake can only be remedied by a repetition of the operation.

5. *Tearing the iris from the ciliary ligament.*—A quick withdrawal of the forceps, but more particularly restlessness of the patient while the forceps are drawn out, may cause the iris to be separated partially or entirely from the ciliary ligament. In order to avoid this accident, it is imperatively necessary to hold the forceps very lightly, so as to be able to let go at any moment, to quickly follow the motions of the eye, and to firmly hold the head of the patient. If then the accident occurs, the separated bit of iris should be brought forward and removed.

6. *Severe hemorrhage.*—When the tissue of the iris has not been very much changed by previous inflammation, the hemorrhage is scarcely of any account, and is of less importance since the extravasation is usually very quickly absorbed. If the iris is far advanced in atrophy, perhaps is even spongy, or traversed by enlarged vessels, the hemorrhages are very much of an impediment during the operation, and besides are with great difficulty absorbed. They easily produce irritative conditions, and not unfrequently destroy the result of the operation; their coagula, in connection with iritic products, closing the artificial pupil like a plug. Occasionally the whole globe is destroyed by atrophy. Where the globe has not suffered very much, we may often permanently remove the extravasation by introducing a Daviel's spoon into the opening, after the completion of the operation, and, by gentle pressure of the posterior lip, allow an exit for the blood. Immediately after this a pressure-bandage should be applied. But where the iris is rotten, friable, spongy, or the globe is already atrophied, and therefore softer to the touch, the exit of the blood does no good, since that which is evacuated is always replaced. Therefore, a well-applied pressure-bandage is the only means by which to overcome excessive extravasations, and to prevent their not unfrequent repetition. In such cases it is sometimes well not to cut off the prolapsed iris, but to simply leave it in the wound in order that it may heal up in it. This procedure is particularly to be recommended,

if after an iridectomy, the cutting off of the iris has been followed by a severe hemorrhage which has destroyed the effect of the operation, and rendered its repetition necessary. Several cases have justified this procedure by exceedingly favorable results.

7. *Escape of a fluid vitreous.*—This accident is chiefly to be feared when the uvea and retina have been involved in previously-existing inflammation, or when the lens is wanting, or its normal attachments have been removed. If a large quantity of vitreous escapes, which especially happens in restless patients, who contract the ocular muscles very much, the globe wrinkles, the cornea sinks in, the iris recedes, and it is often scarcely possible to seize it with the forceps.

8. *Closure or excessive contraction of the pupil.*—This condition is particularly threatening, where the iris has become atrophied by previously-existing inflammation, but especially if spongy in texture, and where a chronic iritis or irido-choroiditis exists at the time of the operation, or when severe hemorrhage has occurred. In such cases sometimes quite large pupils become completely obliterated by adhesion. We should here attempt in the beginning to make a large pupil. If, however, closure follows, the operation should be repeated, as in those cases where the pupil does not answer the purpose on account of its smallness. The second iridectomy should be made close to the first.

9. *Choroidal hemorrhage, apoplexy of the retina, and detachment of the retina from the choroid by sub-retinal effusion.*—These accidents show that there have been very considerable previous alterations in these structures. Prevention of a sudden escape of the aqueous humor and a pressure-bandage are the best means of avoiding them.

10. *Severe inflammatory reaction.*—This is extremely rare after an iridectomy; still it does occur, and it may possibly lead to suppuration of the globe in spite of a seemingly good condition of the eye. (*Rothmund.*) A severe antiphlogistic regimen is the best means of counteracting it.

11. *Corneal opacity near the point of incision.*—This occurs quite frequently after an iridectomy, particularly in cases in which the cornea has suffered very much by preceding morbid processes, and where the iridectomy was performed on account of partial obscurations. They are so extensive at times that the success of the operation is considerably endangered by them, because they again cover a part of the artificial pupil. They naturally occur most frequently when quite a severe inflammatory reaction follows the operation. Still, sometimes the cornea becoms opaque when the reaction was very inconsiderable, or seemed to be absent.

Substitutes for Iridectomy.—The object of these is partly to diminish or avoid evil conditions which are connected with the artificial pupil proper; they are also employed to avoid certain impediments which occasionally prevent the performance of an iridectomy, and thus to insure and increase the success.

1. Corelysis, or the operative separation of the pupillary margin which has become adherent to the capsule (*Streatfield, A. Weber*), may accomplish something when numerous scattered and extensive partial posterior synechiæ exist, if the muscles of the iris are able to act freely after the operation, and if a considerable *portion of the center* of the capsule has remained transparent. The operation should be preceded by the repeated application of strong solutions of atropine. The muscles of the iris are thus prepared for the most extensive mydriasis, and all the fine portions of the pupillary margin are as far as possible retracted. The operation is divided into two steps. The first is the opening of the anterior chamber by a linear corneal incision; the second is the instrumental breaking-up or separation of the adhesions. It is performed with the

same precautions as an iridectomy. It always requires, however, the fixation of the globe, and with very restless patients the use of an anæsthetic. The incision of the cornea should always be made with a lance-shaped knife on its outer periphery, at about the center of the horizontal meridian. After this, a peculiar hook is introduced into the chamber, which is not unlike a strong iris-hook, but differs from it in that its surface is flattened, but not cutting; moreover, the hook portion, which is about three mm. long, is attached to the shaft at an angle of less than 45°, and is rounded off at the point of *curvature*, both *anteriorly* and *posteriorly*.

By means of this hook, beginning at a free point, the adhesions are separated by detaching the new formations from the capsule, with the convexity of the hook, or they are torn with its free end. It is here of the greatest importance that the neoplastic formation be not simply torn, but as it were shelled out from the capsule by careful manipulation, because the remains of it frequently continue attached to the capsule, and render vision indistinct. It is also very important that the axis of the instrument be always in the level of the pupil, and that the broad surface of the hook always lie flat on the capsule, never meeting it at an angle. Therefore, in case it is necessary to turn the free end of the hook, it should be pulled back into the corneal wound, and after the turning, again introduced.

Immediately after the separation of the synechia, a strong solution of atropine is allowed to remain in the eye for some minutes, and then the eye covered by a folded cloth, the room darkened, and the patient placed in a quiet, recumbent position. In about two hours the instillation of atropine is repeated and the eye examined. If the pupil is not enlarged, atropine is applied at frequent intervals, and then a light binocular protective bandage employed. In other respects the after-treatment is the same as after iridectomy. Complete darkness, the *greatest* bodily rest, and the avoidance of cold applications to the eye, are still imperatively indicated, and from the third or fourth day on, for some time, a mydriatic should be applied once or twice a day, according to necessity.

Recently it has been recommended to do away with the hook entirely, and replace it by a pair of blunt-hooked forceps, by means of which the adherent portion of the iris is simply seized and torn off. It is claimed that this method may be employed without any danger in simple anterior and posterior synechiæ, and that it gives very excellent results (*Passavant*). Great care should always be recommended on account of the great sensitiveness displayed by the iris to bruising, which is shown by violent and often destructive inflammation.

2. *Displacement of the whole pupil by causing an artificial prolapse of the iris.*

This procedure is intended to remove the pupil without impairing its movability from the field of greatly-curved or opaque portions of the cornea or lens, and thus to remove the cause of impairment of vision, or at least to reduce it to a very slight amount. The particular indications for it occur in pyramidal cataract, in displacement of the lens (ectopia lentis), but principally in kerataconus, ectasia of the cornea in partial malcurvatures and opacities of the cornea, when the pupillary margin is free. It is also sometimes with advantage substituted for iridectomy, if we have reason to fear severe bleeding from the cutting out of the iris.

Displacement of the pupil is not conceivable unless there is a tearing of the pupillary margin, and mainly of the portion of iris opposite the artificial prolapse. If the operation accomplishes its purpose, we can not limit ourselves to approaching a portion of the pupillary margin to the internal lip of the incision in the cornea, (*Critchett*), but it must be drawn out through this (*Pagenstecher, Berlin*). The tension is then so great that the iris, with quick and careless traction, is sometimes partly separated from its ciliary attachments (*Alf. Graefe*). On the whole, the operation is quite well borne. At the most the portion of iris which undergoes the greatest tension becomes atrophied. In the later stages single tendon like gray striæ or spots devoid of pigment are seen enveloped in the structure. Inflammation is exceptionally excited. In isolated cases destructive irido-choroiditis and the formation of a false membrane (*schwarten*), on the posterior wall of the iris and of the ciliary body, has been observed, with entire loss of sight of the eye. (*Alf. Graefe, Steffan, Höring, Worlitschek, Secondi*).

In view of this, the necessity of cutting off the portion of iris, put on the stretch some time after the displacement, was spoken of quite a long time ago. (*Himly*). It has been recently recommended to follow the operation in threatening cases by an iridectomy. (*Alf. Graefe*).

It is, however, plain that the peculiar purpose of the displacement, i. e., the exclusion of opaque or astigmatic surfaces of the cornea, is not attained when this subsequent operation is performed. It seems wiser, therefore, to perform the iridectomy instead of the displacement, in cases where the stretching may lead to unpleasant results.

The danger is especially incurred when an anterior synechia exists, or when a portion of the margin of the pupil is adherent to the capsule, and when we may certainly expect that it will tear loose under the traction of the forceps. The tension then can not be distributed over the whole iris, but principally affects the part between the morbid adhesion and the artificial prolapse. But the pupillary margin is apt to suffer, since the parts of the iris opposite the incision can exert no counter-pressure. But this bears the excessive tension worse, because it often becomes degenerated like a cicatrix to some extent, or is interspersed with shriveled products of proliferation, and is therefore less distensible. For this reason anterior synechia, and those which can not be broken up, are almost always recognized as contra-indications to displacement.

Some recommend, in the existence of posterior synechia, to precede the displacement of the pupil by a corelysis. (*Ad. Weber.*) But by this the stretching of the pupillary margin is not sufficiently regulated, because the cicatricial rigidity of the pupillary zone, which is combined with the posterior synechia, can not be easily removed. The displacement of the pupil toward opposite sides, by producing an artificial prolapsus at each end of a corneal diameter (*Bowman*) is, in consideration of the dangers already mentioned, not to be recommended.

The operation is performed in very different ways by oculists. In general, two principal methods are distinguished: *Iridodesis* (*Critchett, Pagenstecher*), in which the artificial prolapse is fastened by a ligature, and *Iridenkleisis* (*Himly, Wecker*), in which the strangulation of the prolapsus by the wound in the cornea is also expected. For the purpose of doing an iridodesis, a fine silk or linen thread is introduced through the *limbus conjunctivalis* of the proper portion of the corneal margin, by means of a delicate curved needle. Its ends are for the time laid upon the forehead and cheek.

Fig. 88.

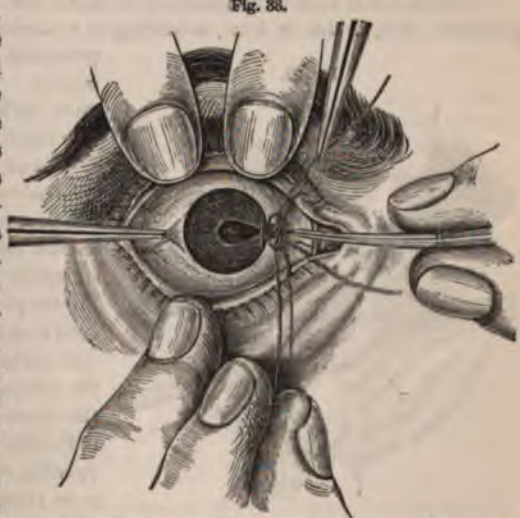

Then an incision exactly as in iridectomy is made in the cornea, close to the conjunctival ridge. The thread is then made into a loop, and *Fischer's* forceps are introduced through this into the chamber. The iris is seized

near to the pupillary margin, and a portion of it is drawn out of the wound (*vide* Fig. 38). The loop is then tied, and the prolapsed portion is thus fixed. Of course, the ends of the thread are then cut off (*Snellen*). The operation is best performed with the patient under the influence of an anæsthetic. The globe should always be fixed. One assistant holds one of the lids open, and with the other hand draws one end of the thread, when it is required to be tied. The operator, while holding the forceps with one hand, holds the other lid with the ring and middle finger of the other hand, at the same time drawing the thread with the index-finger and thumb of this same hand engaged in holding the second lid. A second assistant fixes the globe.

The after-treatment is like that of iridectomy. The loop generally falls off in about 24 hours. Sometimes it remains, and should then be removed. The reaction is generally very slight, and causes no danger.

Carrying the thread through the limbus conjunctivalis assists considerably the proper application of the ligature, and renders the various loop-holders (*Schuft* [Waldau], *Forster*), which have been devised to avoid the difficulty of tying the knot, unnecessary.

Unfortunately, the knot gives no guarantee against a partial retraction of the artificially-induced prolapsus, and the success of the operation is by no means rarely endangered by such an occurrence. The loop, especially when it is tied somewhat tightly, falls off before the portion of iris can be fixed in the relatively short canal of the wound sufficiently to resist the traction of the other parts of the iris. There are two circumstances very favorable to such a partial retraction of the prolapsus. One is, the fact that the prolapsed portion of iris is pressed close to the external opening in a small bunch, which only fills a part of the canal formed by the wound, and thus only a small surface is furnished for adhesion. Secondly, the fact that the proportionately *wide* opening is scarcely adherent enough at the time of the falling off of the loop.

From this it is seen to be necessary to make the opening as long and narrow as possible. But, if this is done, according to a number of experiments, tying up the prolapsus with a thread is entirely unnecessary. The prolapse heals quickly and more certainly than after an iridodesis. The result is also as good and permanent as that of a successful iridodesis.

Fig. 39.

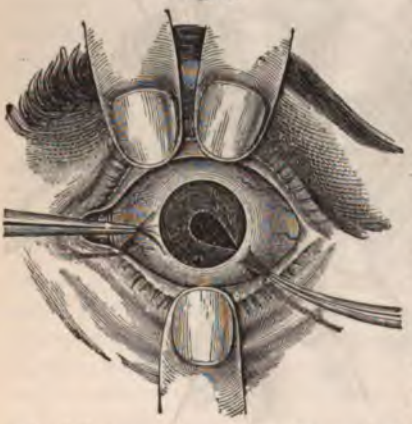

Iridenkleisis.—Strangulating an artificially-excited prolapsus in a long and narrow opening, is then an advantageous substitute for the complicated *iridodesis*. For the purpose of performing this we proceed exactly as in iridectomy; but the incision is made three-quarters of a line from the corneal border on the sclerotica, and the lance-shaped knife is entered very obliquely, and only so far that the inner opening of the wound has a length of not more than a line. Then the iris is pulled out of the opening, as may be required, with the forceps (*vide* Fig. 39), but the prolapse is simply left. The after-treatment is the same as in iridectomy. The

prolapsed portion falls off after some days. In case it remains longer, and becomes finally troublesome, it may be simply removed. No reaction follows, as a rule.

3. *Intra-ocular myotomy, or division of the ciliary muscle* (*Hancock, Solomon*).—This is said to just as certainly and permanently secure a relaxation of the walls of the globe as iridectomy. It is said that it may be substituted in all cases where it is desirable to secure a diminution of the intra-ocular pressure. It has also this advantage, that the eye is less deformed than by the artificial pupil. By some it is especially recommended in *glaucoma*, in *sclero-choroidal staphyloma*, in *staphyloma posticum* of the sclerotica, and even as a remedy for asthenopia and progressive myopia. It is done by introducing a cataract-knife in the lower and outer margin of the cornea, with the point directed backward and downward, and entering into the vitreous along the edge of the lens. According to some, the surface of the knife, in making the incision, should be in the plane of the meridian, so that a wound in the anterior scleral zone, about one and a half times long, results (*Hancock*).

Others place the cutting surfaces vertical to the meridian, so that one looks toward the sclerotica, the other toward the margin of the lens. An iridectomy-knife may be used in this method.

In the latter case the knife should be inserted so deep that an opening from two to two and a half lines long is made (*Solomon*). It should be introduced and removed slowly. The operation is said to be painless, and to be followed by no severe reaction.

4. *Iridectomy through a peripherical linear incision with extraction of the lens* (*Graefe*).—This is appropriate in cases in which firm tendinous new-formations cover over the posterior surface of the iris, completely obliterating the pupil and extensively uniting it with the capsule. When we suspect the presence of such pseudo-membranes on the posterior wall, or have learned of their existence by a preceding unsuccessful iridectomy, a linear section should be made on the lower border of the cornea, as in cataract extraction. If this be done, the iris is cut through with the cataract-knife or with a lance-shaped knife on its ciliary margin for about three lines and more, and from this wound, by means of delicate scissors, a large piece is cut out. In the mean time the lens is often evacuated, and unfortunately generally also a great part of the vitreous, which is usually fluid. If the lens is not evacuated spontaneously, it should be brought out by a hook or by a deep cataract spoon. Then a protective bandage is applied, and the after-treatment carried on exactly as after a simple cataract extraction.

On the whole, this operation is a dangerous one, because it is almost always united with a large evacuation of the fluid vitreous. Thus collapse of the globe, with all its dangers, rupture of vessels, detachments of the retina, are its immediate consequences. But it is a last resort in doubtful cases in which there is not much to lose.

5. The iridotomy, or simple cutting off of the iris, has recently received a reputation in desperate cases of iridocyclitis with fattening of the anterior section of the eye and retroiritis false membranes after cataract operations, and in aphakia (*Horner*). It may be done as well with a falciform as with a lance-headed knife, by introducing the instrument perpendicularly through the cornea and iris into the vitreous humor and immediately withdrawing. The tissues are generally sufficiently retractile to form, by the aid of the protruding vitreous, a permanent opening, which admits of the entrance of light. The slighter injury, the inconsiderable hemorrhage, etc., also cause less reaction and less tendency to reclosure of the wound than is usually the case in forcible excisions of a piece of iris.

Authorities.—*Beer*, Lehre von den Augenkrankheiten. II. Wien. 1817. S. 200.—*Himly*, Krankheiten und Missbildungen d. m. Auges II. Berlin, 1843. S. 127, 156, 160.—*Graefe*, A. f. O. II. 2. S. 177, et seq. III. 2. S. 548. IV. 2. S. 271. VI. 2. S. 150. VIII. 2. S. 261, 262. IX. 3. S. 126.—

Hasner, Klin. Vorträge. Prag. 1860. S. 152, 291. Prager Vierteljahrschrift. 76. Bd. S. 137. Congress intern. d'ophth. Paris. 1863. P. 75.—*Knapp*, klin. Mntbl. 1869. S. 165, 167.—*Businelli*, Zeitschft. de. Wiener Aerzte. 1859. S. 250.—*Frobelius*, A. f. O. VII. 2. S. 118. Congress intern. d'ophth. Paris, 1863. S. 222.—*Horner*, kl. Mntbl. 1863. S. 395. 396, 402 —*Heymann*, ibid. 1864. S. 365.—*Rothmund*, Deutsche Klinik. 1865. S. 170.—*Streatfield*, Ophth. Hosp. Rep. 1857, Nr. 11.—*Bowman*, ibid. 1859. Nr. 9. S. 154.—*Critchett*, ibid. 1859. Nr. 9. S. 145; kl. Mntbl 1863. S. 466.—*A. Sichel*, Des indicat. de l'iridectomie etc. Paris. 1866.—*A. Weber*, A. f. O. VII. 1. S. 1, 30, 35, 37, 42. VIII. 1. S. 354; kl. Mntbl. 1863. S. 86.—*Donders*, A. f. O. VII. 1. S. 196.—*Berlin*, ibid. VI. 2. S. 73, 78, 88, 92, 95.—*Pagenstecher*, ibid. VIII. 1. S. 192.—*Pagenstecher* und *Sämisch*, kl. Beobachtungen Weisbaden. 1860. I. S. 19, 39.—*Warlomont*, Ann. d'oc. 1864. S. 1.—*Alf. Graefe*, A. f. O. IX. 3, S. 199, 205, 207.—*Steffan*, ibid. X. 1. S. 123, 130.—*Krüger*, kl. Mntbl. 1865. S. 33. 55, 40.—*Höring*, ibid. 1865. S. 42, 45.—*Rydel*, Wien. med. Jahrb. 1866, 4. S. 39.—*Schuft*, nach Krüger l. c. S. 35 und Seitz, Handbuch der Augenheilkunde. Erlangen. 1855. S. 480.—*Förster*, nach Krüger l. c. S. 36.—*Snellen*, Derde Jaarslijksch Verslag. Utrecht. 1862. S. 280. Congress intern. d'ophth. Paris. 1863. S. 235.—*Wecher*, kl. Mntbl. 1863. S. 114, 117, 278.—*Stellwag*, Wien. med. Wochenschrift. 1865. Nr. 29.—*Hancock*, The Lancet. 1860.—*Solomon*, James Vose. Med. Times and Gaz. 1861. Jan. March, British Med. Journ. 1862. Jan. 11, kl. Mntbl. 1866. S. 118.—*Graefe*, A. f. O. XII. 2. S. 159; XIV. 3. S. 139-147.—*Knapp*, A. f. O. XIV. 1. S. 262.—*Horner*, kl. Monatbl. 1868, S. 325; 1869, S. 431.—*Le Gad*, ibid. S. 126.—*Liebreich*, ibid. 1868, S. 324; Arch. f. Augen- und Ohrenheilkd. 1. S. 66.—*Mooren*, Ueber sympath. Ophth. S. 47. —*Worlitschek*, Centralbl. 1866, S. 383.—*Passavant*, A. F. O. XV. 1. S. 259.—*Birkbeck*, Schmidt's Jahrbücher. 140. Bd. S. 310.—*Secondi*, Sulla cura del cheratocono, S. 8, 16, 26.

SIXTH SECTION.

INFLAMMATION OF THE CHOROID AND OF THE CILIARY BODY. CHOROIDITIS AND CYKLITIS.

Anatomy.—The choroid lies immediately on the inner side of the sclerotica, and is loosely adherent to it. The optic nerve passes through its posterior portion by the round *foramen opticum choroidea*, and is supported there by an elastic connective-tissue structure. This passes around the edge of the opening in concentric fibers, and forms an actual ring, the so-called fibrous ring, which is intimately connected with the neurilemma of the optic nerve. Anteriorly the choroid has an imaginary boundary line at the *ora serrata*, where it is also firmly united to the retina. The uveal tissue is continued over this boundary, and forms the projections known as ciliary processes, whose aggregate is described as the ciliary body.

We distinguish a number of layers in the choroid, which in order, from within out, are:

1. External pigment layer, or Lamina Fusca.
2. True vascular layer, or Tunica Vasculosa.
3. Membrana chorio-capillaris, or Ruischiana.
4. Lamina Elastica, or Membrana Limitans.
5. Stratum pigmenti, or Tapetum.

The lamina fusca is a loose filamentous tissue, from brown to black in color, which envelops the long ciliary vessels and nerves passing between the choroid and sclerotica. Since it proceeds from the external surface of the choroid, and enters partially into the innermost stratum of the sclerotica, it connects these two membranes with each other. It consists of an elastic network (*Henle*), and of a structureless hyaline intercellular substance filling out the meshes of it. Embedded in this tissue are found a great number of free nuclei and very differently-formed nucleated cells, partly stellate, entirely colorless, or more or less pigmented. These have longer and shorter, generally very delicate, occasionally anastomosing, processes.

According to later investigations, a lymph-space, lined with the characteristic endothelium, is situated between the choroid and sclera. This communicates by lymph-canals, which pass outwards into the venæ vorticosæ, with the lymph-spaces of the cavity of Tenon's capsule, but is otherwise completely closed, and is in nowise connected with the anterior and posterior chambers, which are likewise regarded as lymph-spaces (*Schwalbe*).

The proper vascular layer, which is always less highly colored, and the colorless delicate chorio-capillaris, represent the real structure of the choroid. The stroma of this is similar to that of the lamina fusca. Yet the cells in the tunica vasculosa are more pressed together. They are also to a great extent colorless, have only short branches, and pass gradually inward into an entirely homogeneous or slightly striated tissue, but which is partially nucleated, and can not be distinguished from certain elastic lamellæ of the innermost vascular membrane. Upon the inner surface of this stratum, somewhat sunken in it, is the very thick capillary network which has given the layer in question its name. Its vessels have a very even caliber, and are partly arranged in a stellate manner around isolated nodules, but in general they form a fine web without any middle point.

The lamina elastica, or membrana limitans of the choroid, is a delicate, perfectly hyaline, structureless membrane, covered by isolated, very bright nuclei, which appears analogous in its structure to the hyaline membrane. It extends over the whole of the inner surface of the chorio-capillaris, and is closely connected to it. It may, however, be separated from it in large pieces, especially in the macerated choroid.

The pigment-stratum is on its inner surface. This consists of regular hexagonal cells, lying close together, and having extremely thin walls, pressed together compactly. These cells contain brownish-black pigment corpuscles in great number, which are partly suspended in fluid cellular contents, and lie partly on the surface, looking toward the retina. The nucleus, therefore, generally appears only as a yellow spot. The pigment-cells are held together by a firm, delicate, homogeneous connective substance. They are closer together, change their shape, become longer than broad in the region of the macula lutea, and partly envelop the elements of the layer of rods of the retina. The pigment granules of these cells are larger and longer than in the other parts of the choroid and iris. (*Henle, Rosow.*) They may be bleached by chlorine. (*Wittich, Rosow.*) Considered from the stand-point of its development, the choroidal tapetum appears to be a portion of the retina. (*C. Ritter, Babuchin.*)

The ciliary body is an immediate continuation of the choroid, and it may be considered as its ciliary portion. Regarded posteriorly, it appears made up of some cribriform, closely united, club-shaped projections, which are intimately connected with each other, lying in a meridional direction. These are embedded in the depressions of the folds formed by the zonula, and fill them up to within a short distance of the border of the lens. Their heads do not rest on the latter under any circumstances. (*Arlt, O. Becker.*) These projections—the ciliary processes—are really only folds, in whose anterior concavity the ciliary muscle rests. Its free surface has a covering analogous to the membrana limitans of the choroid, upon which rests a stratum of pigmented epithelium, which is quite closely connected to the ciliary portion of the retina, and, on removing the ring, remains attached to the zonula.

The structure of the ciliary processes is very analogous to that of the choroid. It may be divided into the same layers, with the exception of the chorio-capillaris, which ends at the *ora serrata*, and is traversed by vessels which have a meridional direction, and which are somewhat sparsely ramifying. The basis-structure of the ciliary processes forms a very vascular, loose, wavy connective tissue, which is arranged in fine bundles lying parallel to each other, and in a meridional direction. In the region of the *ora serrata* little bands are seen which cross each other constantly, and present a lattice-work constantly becoming finer and thinner—the reticulum of the ring. The structureless membrana limitans extends over this meshwork, adherent to all its elevations and depressions, which again, on its side, is covered by the pigment-layer. The cells of the latter fill up the spaces of the reticulum, and cause the surfaces of the processes to appear smooth and even. The pigment bodies are here round. (*Rosow.*)

The ciliary muscle lies embedded (*Todd* and *Bowman*) in the anterior concavity of the ciliary process, or, as it is also called, the *tensor choroideæ*. (*Brucke*, see Fig. 2.) It was formerly described as the ciliary ligament. This is seen as a quite thick and broad ring, which, on a vertical section, is three-sided, prismatic, of a whitish-gray color. It consists of smooth, muscular fibers, which have, in part, a meridional direction, partly a circular course.

All the fibers arise in the form of a muscular ring from the border of the cornea. The insertion is formed by connective tissue, which is arranged in firm, compact layers. Only a very small portion of these layers is connected with the membrane of Descemet, the main portion is continued directly into the substance of the cornea, and another subjacent portion passes over into the anterior scleral border. In the muscular ring all the fibrous bundles run longitudinally, the most anterior or external bundles preserve this direction and hug each other closely, forming a dense layer of longitudinal fibers, *l*, more or less extensive, which is firmly attached to the choroid, and is separated from the sclera only by a thin layer of loose connective tissue often pigmented, a prolongation of the *lamina fusca*. Internally the individual bundles detach themselves constantly from the layer of longitudinal fibers, run more directly

backward or backward and inward so as to turn toward the free surface of the ciliary processes, separate from each other in a fan-shape manner, interlace and form a coarse network, the interspaces of which are filled with connective tissue, thus interweaving. The direction of the fibers also gradually changes by this interweaving, passing from the longitudinal into the circular. It becomes in the most anterior fibers of the muscle, and in those which separate the surface of the muscle from the groundwork of the ciliary processes, a perfectly circular one; the fibers here spread out and unite again into a thicker layer of muscular fibers, which bounds the body of the entire muscle like the (*catheten*) of a rectangular triangle, forward and inward, and backward and inward. Then come the circular fibers of *Müller*, *o*, which lie more isolated, outside the body of the muscle, in front of the anterior and internal narrow fibrous layer, and are united like a net as well with each other, as with the main body of the muscle. The longitudinal fibers of the external anterior layer draw the anterior choroidal border forward, and therefore relax the zonula; the circular fibers act like a sphincter and draw the parts directly inward, increasing the relaxation of the zonula (*F. E. Schultze, Iwanoff, Rollet*).

The *choroid* proper is principally nourished by the short posterior ciliary arteries, but the ciliary muscle, the ciliary body, and the iris, by the long posterior and the anterior ciliary arteries. The principal portion of the venous blood passes through the vasa vorticosæ, and reaches the orbital tissue through the posterior ciliary veins. A smaller portion of them, and especially those returning from the ciliary muscle, have their outlet through the anterior ciliary veins.

The posterior ciliary arteries appear in the form of small ramifying branches on the globe, coming immediately from the ophthalmic artery. The shorter perforate the sclerotica on its posterior portion in quite a vertical direction. The most numerous and the largest enter in the neighborhood of the yellow spot. Having reached the inner surface, they extend for some distance on the choroid, become more and more divided, sink gradually between the vasa vorticosæ of the tunica vasculosa, and are finally lost in the chorio-capillaris in a fine net-work. The most posterior of these anastomose freely with the posterior vascular ring of the sclera, and the nutrient vessels of the optic papilla, and are thus connected with the retinal vessels. The rings, which lie more anteriorly, extend with their ramifications to the ora serrata; some of them even extend beyond this, and unite with the anterior branches of the ciliary muscle, and of the ciliary branches.

The two long posterior ciliary arteries enter the sclera a little farther forward, pass through this in a very oblique direction, without giving off a branch, and run directly forward, one on each side, in a horizontal direction, to the choroidal surface. They divide in the ciliary muscle, and pass, deviating in a lateral direction, to the anterior border of the muscle, forming here the large vascular ring of the iris.

The anterior ciliary arteries emerge from the bellies of the four straight muscles, perforate their tendons, and ramify in the most anterior zone of the episcleral tissue. A number of branches then pass through the sclerotica in quite a straight course. They divide in the ciliary muscle into smaller and larger twigs, and are finally lost in a capillary net-work, which is interwoven with the *tensor choroidea*. A portion of the little branches unite with such of the long posterior ciliary arteries and complete the *circulus arteriosus major iridis*—great arterial circle of the iris. Another portion forms more posteriorly, about in the center of the breadth of the muscle, a second but more incomplete vascular ring, to which the twigs of the posterior long ciliary arteries contribute. Finally, a third portion passes backward to the choroid, anastomoses here with the terminal branches of the posterior short ciliary arteries, and supplies the anterior zone of the chorio-capillaris with arterial blood. (*Leber.*)

The veins extend in a radiate direction into the *tunica vasculosa* of the choroid, with a predominately meridional course, however, toward certain points, and thus form the well-known vorticose vessels, of which there may be counted five to six large ones, and one to six smaller. The little branches in which the vortices collect perforate the sclera in a very oblique direction,

and unite within the emergent branches with other neighboring twigs, and finally appear, about six in number, on the equator of the eye, passing into the orbit, and emptying into the ophthalmic vein. The delicate veins which pass out from the posterior surface of the sclerotica belong entirely to it, and have no supply from the choroid. They do not, then, correspond to the posterior short ciliary arteries. In the same manner, long posterior ciliary veins are wanting. All the blood passing through the vorticose vessels has passed through capillaries. An immediate passage of arteries into veins (*Brücke*) does not take place in the uvea.

The principal origin for the venous twigs in question is evidently the chorio-capillaris. Still the iris, the ciliary processes, and the ciliary muscle, furnish very important tributaries. No venous blood goes directly from the iris through the anterior ciliary veins, but their emergent vessels rather unite as a whole with those of the ciliary processes in a coarse net-work, which passes to the choroid beneath the muscles, and here unites with the anterior radiation of the vasa vorticosæ. This net-work, however, takes venous branches from the ciliary muscle, whose vascular tissue sends out the greater part of its contents directly through the anterior zone of the sclerotica. Numerous twigs emerge from the muscle and pass into the sclerotica, and unite in part, within this, to the venous ciliary plexus (improperly called the canal of Schlemm), but in part pass through the sclerotica in a straight course through independent branches. All the little veins appearing on the anterior zone of the globe are described as anterior ciliary veins. They are in connection with the anterior scleral vessels, as well as with the tissue of the conjunctiva and cornea.

In a normal condition of things, the anterior ciliary veins evacuate only venous blood from the tensor of the choroid (ciliary muscle); that is, the venous blood is in great preponderance. There is then no considerable flow of blood from the other parts, except when the current is impeded in the trunks of the vasa vorticosæ. (*Leber.*)

The connection between the *venæ vorticosæ* and the veins of the cornea, which has lately been much spoken of (*Winther*), is certainly very distant. The arterial vessels of the choroid have a proportionately large circular muscular layer. Besides, their adventitious structure is surrounded by bundles of fiber-cells. These bundles are directly connected with the tensor of the choroid. On the posterior part of the choroid they anastomose in a reticulate manner. (*H. Müller.*)

The ciliary nerves ramify very much in their course through the lamina fusca, and even give off branches which pass backward, which contain partly dark-bordered, partly pale, primitive fibers. They are connected with a network of pale fibers, which lies principally in the posterior half of the outermost pigment layer, and its finest branches seem to be lost in the arteries. Ganglion cells, singly or in groups, have been found in these networks, as well as in the stems of the ciliary nerves (*H. Müller*, *Schweigger*).

Ophthalmoscopic Appearances.—The choroid, by means of its supply of blood and dark pigment, gives the color to the fundus of the eye in the ophthalmoscopic image. This is generally a light-yellowish red (*chrom. lith.*, A), with a more or less marked mingling of brown. The yellowish-red color is the reflex of the blood circulating in the tunica vasculosa and chorio-capillaris. The mixture of brown depends on the pigment-stratum and partly on the coloring material of the choroid proper. It is the more distinct, the more abundant are the pigment contents. While the fundus of the eye appears of a very light-yellowish red-color in light blondes, in dark-haired persons with brown or black irides it has generally a light-brownish red-color. The kind of illumination and the light used have the greatest influence in this respect. In the indirect image the color appears darker than in the upright, and it is the lightest when daylight is used.

The pigment-layer is thus proven to be diaphanous, which may be explained by the fact tha the pigment molecules are not thickly collected within the cells, and that the pigment-cells are separated from each other by a pellucid intercellular substance, although very slight in quantity. Interstices also exist, through which the light may pass in any direction. This irregular distribution of coloring matter in the tapetum is the cause of the finely stippled appearance of the fundus of the eye which is often seen. The closer the pigment granules are pressed upon each other in the cell-cavities, the more in disproportion are they to the fluid cell-contents. Of course,

the transparency of the tapetum must be lost in the same proportion, and its color have an influence on the ophthalmoscopic image. Indeed, the fundus occasionally appears almost black, with a bluish, wavy cloud over it. This latter appearance is caused by the retina, and is especially marked in negroes. (*Liebreich.*)

Very frequently, in dark-haired persons with a dark skin, we find the ocular fundus having an inlaid appearance (*chrom lith.*, G, R, S). This depends on excessive pigmentation of the stroma of the choroid, and on the quantity of the coloring material in the tapetum. (*Mauthner*).

Inasmuch as the *vasa vorticosæ* make up the principal part of the choroidal structure, and the basis of this, which contains pigment, only appears in abundant quantity in the meshes of the choroidal net-work, the difference in color when the stroma-cells are greatly pigmented is very prominent. The fundus of the eye is then seen as a trellis-work of broad, tortuous, red bands, whose interspaces are filled with angular spots with granular border. These spots vary in color from light-brown to the deepest black. They are smaller in the region of the *macula lutea*, roundish in contour, but toward the anterior boundary of the choroid their circumference increases, and they become elongated, having their long axis in a meridional direction. The regular arrangement of these spots, and their exact insertion in the meshes of the venous twigs, do not readily allow us to mistake them for morbid disintegration of pigment.

Moreover, it is not at all unfrequent, in entirely normal conditions on the most different parts of the fundus oculi, for the stroma-cells to be collected, particularly around the optic-nerve entrance, and to form isolated, irregular, dark spots, with granular borders. The region of the macula lutea is generally somewhat more deeply colored, and occasionally has a marked shade of brown.

Senile Changes.—These appear in the choroid as in other parts of the body, at different ages in different persons. They attain at the same time of life a higher or lower degree of development in different individuals. They are almost identical in appearance with simple atrophy, often produced by morbid processes.

The structure of the choroid and of the ciliary processes becomes at the same time more rigid, brittle, dry. Some of the larger vascular twigs are often atheromatous, and also completely obliterated. The capillary net-work is frequently destroyed, especially in the chorio-capillaris, and in places is entirely gone. The membrana limitans appears in some places, or over the whole choroid, thickened, rough, and opaque from coloid deposits, and decidedly unyielding in texture. The pigment, however, suffers most strikingly. This is gradually changed in color, becomes bleached, and is partly destroyed. The tapetum thus becomes more transparent, and the previously-described inlaid appearance of the choroidal stroma in senile and atrophying eyes, is apt to appear much more marked. It is often seen as a light shading of brown, by means of the changed and partial solution of granules of coloring matter. When the change has gone on farther, the cells of the stroma and of the tapetum disappear to a great extent. The choroid is then found more or less evenly discolored, having a grayish-white hue, and so diaphanous that the sclerotica under it seems to be exposed. (*Wedl*, *H. Müller*).

These changes are of course recognizable with the ophthalmoscope, and modify its image very much.

The stroma-cells generally remain a long time. Still their contents often appear turbid and interspersed with fat molecules. The coloring matter is then either very pale or entirely wanting. Extensive layers of free fat corpuscles are often seen between the cells, and exceptionately scattered

coloid bodies. The atheromatous vessels are often recognized, with the naked eye, as thick, ramifying, firm white lines. They sometimes end in an atheromatous net-work, and not unfrequently are entirely wanting. Their walls appear very much thickened, fibrous, and interspersed with fat, calcareous matter, and sometimes with pigment.

The chorio-capillaris is often entirely free from blood, to a quite large extent. The capillaries in it often appear to be destroyed, and reduced to an illy-defined, irregular net-work, which is scarcely distinguished from the fine granular, structureless molecular mass, often containing fat which lies between. In other cases the impermeable remains of the vessels still appear very plainly as a delicate and elegant trellis-work. This sometimes looks as if it were made of connective tissue, but sometimes exhibits no structure whatever, and appears to be woven of fibers of a homogeneous substance, which has great refractive power. This net-work, with the molecular intervening substance, is always closely adherent to the lamina elastica.

The thickening of the membrana limitans is proven to be the result of an abnormal deposit of hyaline matter, which was originally soft but became gradually hardened, and then entirely identical with the membrana limitans itself, of which it is a continuation. These deposits are at times diffuse, with an undulating surface; at other times they are seen as glands, resembling segments of a sphere in shape, more or less close together, or even outgrowths resembling stalactites, which give to the eye the same impression as grains of sand. They are generally translucent, but often contain calcareous bodies and pigment granules, which render them very turbid. They push the superjacent pigment-cells forward and to one side, so that their base seems ridged about with pigment, and the pigment-layer attains a reticulate appearance. This alteration is very often seen in the entire extent of the membrana limitans. In other cases it is confined to individual parts of this.

In many instances it seems united to the course of the vessels, appearing particularly prominent in the interstices of the twigs in the tunica vasculosa. Thus, in connection with the pigment metamorphosis it produces the prominent reticulated appearance on the inner choroidal surface. It is apt to be very decided on the elastic ring of the *foramen opticum choroideæ*, and also on the reticulum of the ciliary body, and gives the latter a very glandular and condylomatous appearance. (*Wedl, Donders, H. Müller.*)

We may also sometimes recognize, with the ophthalmoscope, the round openings which the spherical deposits on the membrana limitans have caused by the displacement of the pigment. With a very abundant development a fine reticulated appearance, with a roundish mesh work, is seen. (*Liebreich.*)

The cells of the tapetum are more or less advanced in fatty degeneration. Its pigment is already strikingly lessened in the brighter spots, and is besides discolored to a light-brown yellowish red, &c. Between the pigment molecules the fat granules of the cellular contents then appear very distinct. Here and there the pigment is entirely wanting, and is replaced by fat. In isolated cell-groups the polygonal borders of the cells have been destroyed, perhaps by rupture. In other groups the cell-bodies and the nucleus were wanting; the contour of the cells has been retained as a delicate polygonal net-work, which was closely adherent to the membrana limitans. For considerable spaces the last trace of the cell-walls was removed, the membrana limitans exposed, or only interspersed with free pigment granules or fat-corpuscles.

Very analogous changes are observed in the ciliary processes and the ciliary muscle.

Here also the fatty degeneration of the stroma and muscular fiber-cells, the rarefaction and paleness of the pigment, the atheromatous degeneration of the vessels, the deposition of the choloid masses in the tissue, are very plain. To this is added a marked thickening and increase in quantity of the reticulum, whose interstices have increased considerably in depth and width, and which often give a glandular condylomatous appearance to the inner side of the ciliary body. The deposition of calcareous formations often takes place, sometimes to such an extent that the meshes of the net-work are entirely filled by them. (*H. Müller, Wedl.*)

Nosology.—Choroiditis and cyclitis are almost always only parts of an inflammatory process, which is extended over a great portion, or the whole, of the eye. The coincidental affection of the vitreous humor and retina is apt to be most markedly seen, but that of the iris and lens is frequently very plain, but less often that of the

sclerotica. The inflammatory changes of the neighboring parts are usually so prominent that they give the disease the character of an affection of the whole eye. The older ophthalmologists were therefore accustomed to speak, not so much of choroiditis and cyclitis, as of *internal ophthalmia*, and to distinguish this according to the principal situation, and according to its extent, by the names anterior, posterior, and general. The modern names irido-cyclitis, irido-choroiditis, choroiditis, and panophthalmitis, with their present signification, are about equal to those formerly used.

The constant passage of the inflammatory process beyond the boundaries of the choroid and of the ciliary body, is partly to be accounted for by the intimate anatomical connection which exists between the tissue and vessels of the cornea with those of the neighboring parts. But it is also to some extent a natural result of the disturbances of the regulative influence which the choroid and the ciliary body exercise upon the entire current of blood, and through this upon the nutrition of the interior of the eye.

A. The proliferation of tissue in the interior of the inflamed choroid and ciliary body is generally not very great, so that the evidence of its existence can only be shown by the microscope. A predominantly secretory character has been ascribed to such inflammations, and they have been called *serous*, it being assumed that a serous or gelatinous product passes out through the retina into the vitreous humor.

The cells of the stroma do not, as a rule, show much change. At the most, they are found somewhat puffed out in some places; their fluid contents appear turbid, or interspersed with fat globules, while the coloring matter is diminished in quantity, and is bleached. A number of fructiferous and separating nuclei have been seen only in exceptional instances. In isolated cases, however, they grow in groups, and acquire a darker color by an increase in their pigment contents, or they are utterly destroyed. Occasionally, groups of free nuclei have been observed, which are heaped up in the parenchyma, arranged in a straight course following the dilated and often atheromatous vessels. They are sometimes greatly pigmented.

In the chorio-capillaris the capillaries are generally greatly enlarged, and some of them dilated like a sac. The intervening substance appears interspersed with collections of nuclei and fat molecules. The membrana limitans is generally thickened, opaque, and covered by choloid masses. The cells of the tapetum often undergo fatty degeneration, their coloring material lost, or is bleached, and acquires a light-brown or yellow color. In consequence of the destruction of its walls in the later stages, groups of free nuclei, as well as free coloring granules, are often seen on the surface of the lamina elastica. Besides, the cells of the tapetum not unfrequently, at least at some points, take a direct part in the process of proliferation. They grow with more or less luxuriant nuclear separation, and at times are very much increased.

The recent cells are apt, then, to accumulate in some places, while the old ones all around are found in the most different phases of proliferation. They appear smaller, are generally oval, rarely round or angular. The amount of pigment varies greatly; sometimes it is very abundant, sometimes very sparing, in quantity, and at times it is entirely wanting. The granules of coloring matter differ very much in form and size. (*Rosow.*) In the ciliary processes the increase in the basis of connective tissue causes a very marked development of the reticulum. The process is seen in the ciliary muscle by the nuclear separation and deposition of fat in the fiber-cells, as well as by the growth and increase in number of the connective-tissue bodies, and by serous or gelatinous infiltration of the reticulated structure. (*Wedl, Schweigger.*)

The ciliary nerves herein contained usually show in their neuroglia young cells, more or less crowded together. Their medullary sheath is often destroyed, and can be seen in the form of drops or as a molecular mass near the naked axis-cylinders (*Wedl, Schweigger, Iwanoff*).

The further formation of the process chiefly depends upon the relations of the circulation in the interior of the organ. If the venous reflux is in any way diminished, or even if its acceleration be hindered by any cause whatever, the

quantity of blood circulating in the interior of the globe must increase a little with every arterial pulsation, and the internal pressure approach a certain maximum, at which it corresponds to the effective lateral pressure of the arterial blood during the arterial diastole. The process then assumes a peculiar character, since all the tissues of the eyeball are finally drawn into sympathy with it, and the process is like that which obtains in glaucoma.

The pressure acting more directly upon the ciliary nerves, and perhaps also their abnormal tension, determines interferences in the conductive power of the nerves which manifest themselves in the diminished functional power of the parts involved, particularly in anæsthesia of the cornea, and sometimes even in neuro-paralytic ulcerations. With the increase of the scleral tension the amount of the elasticity and the regulating influence, which the cornea and sclera exert upon the internal circulation, sink, the course of the blood becomes irregular, and this is manifested by the appearance of, or at least an inclination to, pulsation. The increased resistance which the arterial current meets with produces a retardation of the circulation in the smallest capillaries, and with it a further diminution of the functional power, and finally an inclination to atrophy. The stoppage of the venous circulation favors an increase of the exosmosis and the increased exudation of white blood-corpuscles; the dioptric media become cloudy and in the vascular tissues inflammatory products collect in spots. Added to this the vitreous humor increases perceptibly in quantity, corresponding to the preponderating vascular contents of the choroid, whilst the aqueous humor, in consequence of increased transfusion through the cornea, is diminished, and the anterior chamber consequently narrowed. If the intra-ocular pressure passes beyond a certain height, that part of the capsule of the globe, the least capable of resistance, the *lamina cribrosa*, is also pressed backward, distended, and the adjacent posterior zone of the internal layers of the sclera torn apart. The characteristic glaucomatous excavation develops itself, as well as the so-called connective-tissue ring belonging to it, explained by the stretching and final atrophy of the posterior zone of the choroid.

The excavation of the papilla of the optic nerve, according to all this, is a secondary condition, which is first developed in the course of a glaucomatous process. In the beginning it is often partial, and consists in the yielding of a smaller or larger section of the periphery of the optic-nerve entrance. On more complete development it is always total, and by this feature it may be distinguished from the congenital variety. The optic-nerve entrance is pressed back in its entire surface, and is seen as a pit of more or less depth, (Fig. 40, after *Ed. Jaeger*,) with a trough-shaped excavated base, and steep, occasionally even overhanging, borders, *a*, which pass into the concave surface of the fundus of the eye at an angle very decidedly and obtusely rounded off.

Fig. 40.

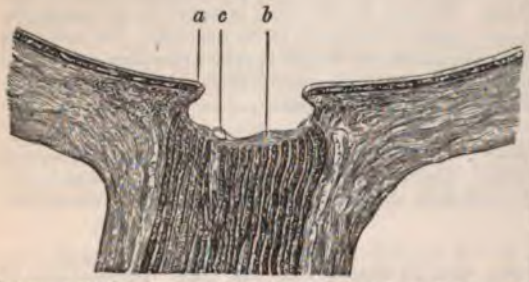

The walls of this pit are formed by the lamina cribrosa, which is considerably distended and pressed backward. Above this are occasionally found, as a thin coating, *b*, nervous filaments, which pass over into

the retina. But as a rule the optic-nerve fibers are entirely destroyed, and are replaced by a delicate layer of connective tissue, which adheres closely to the floor and sides of the excavation, and is connected to the atrophied anterior layer of the retina. The branches of the central vessels, *c*, are adherent to the sides of the excavation, and therefore undergo a double bending in their course. Isolated twigs of these branches are apt to be altered, or disappear in the manner before described. It even happens that all the vessels of the optic-nerve entrance are destroyed. As substitutes, then, a varying number of vessels is generally found, which by their abnormal position and course are seen to be collateral, and which have become greatly enlarged in consequence of the impermeability of the normal principal branches.

The kettle-shape of the excavation depends upon the fact that the anterior lid of the nerve runs in a coniform way, that is, becomes broader posteriorly. The lamina cribrosa of the porus opticus is also often excavated, so that the floor of the excavation appears funnel-shaped, and the vessels pressed to the nasal side (*Schweigger*).

B. Some forms of uveitis are different from the serous choroidal inflammation. In these the inflammatory products are not only distinctly perceptible, but exactly indicative of the whole external appearance of the process.

1. We have already spoken of one of these forms: exudative retino-choroiditis.

2. Another form is characterized by a larger or smaller organizable product, which is brought to light in the anterior uveal portion, while the true choroid either appears entirely changed (irido-cyclitis), or takes part in the inflammatory process with the symptoms of serous choroiditis (irido-choroiditis).

Thus we sometimes find, as well in the *lamina fusca* as in the *vascular* layer, tolerably large masses of unpigmented, roundish young cells, particularly in the neighborhood of the vessels, the adventitia of which often seems completely lost in the cell-mass. From the venæ vorticosæ the growth advances often upon the sclera, and even upon the fascia of the globe. No less does the *choriocapillaris* sometimes conceal large masses of young cells, and the capillary network, otherwise distended, often becomes in the new formation almost unrecognizable. The *tunica elastica* is then often perforated over such nuclei, so that the mass of cells, soon to be vascularized, extends into the retina, whilst the surrounding *tapetum* is partly destroyed, partly increases by proliferation (*Czerny*).

The proliferation in the iris is seen chiefly by the papillary excrescences which unite a great part of the pupillary margin, or all of it, to the anterior capsule (closure of the pupil) [pupillar abschluss], but which frequently completely fills the pupil in the form of a capsular or false cataract. With this, occasionally, gummy tumors, granulations, or a hypopyon, are found. But generally the iris is seen only relaxed by inflammation, and soon atrophies, undergoes partial tendinous degeneration, and is, to some extent, brittle and friable, like tinder. Not unfrequently it becomes spongy and is entirely destroyed, while its vessels are completely degenerated, distended, and appear on the surface of the membrane like the thyroidal veins. Very frequently the development of tough, tenacious, tendinous membranes occurs on the posterior aspect of the iris. These result from the luxuriant development of the posterior boundary layer and of the tapetum, and are very apt to shrink. Their thickness differs very much. The thinner membranes are often so full of pigment that they appear almost of a uniform black color. The thicker are like tendinous tissue, and generally are a spotted and darkish gray.

They often hang loosely to the iris, or rather the tinder-like brittle remains of anterior iris-layers. Exfoliations may be easily separated from the posterior stratum in great shreds. In other cases the tendinous masses involve the whole thickness of the iris. The pseudo-membrane is only in spots coated with short-fibered brittle rudiments of loose atrophied stroma. These membranes are always in direct connection with the new growths closing the pupil, and are, as it were, a continuation of them. They adhere to the anterior capsule occasionally up to near the edge; but more frequently their peripheral portion is separated from the capsule by fluid. The adhesion is confined to the pupillary region.

The same state of things is repeated in the ciliary body. The process of proliferation is here particularly seen by a loosening of the reticulum, or rather of that thick layer of connective tissue which forms the posterior wall of the ciliary body. Numerous half-spherical or elliptical, often pedunculated, nodular papillomata grow from this, which give the part a very rough condylomatous appearance. But generally the prolification is far more luxuriant, and the neoplastic formations become, by a gradual thickening and shrinkage, extensive membranes, which are connected to those of the iris, and are lost posteriorly in a villous-like open work, which extends into the turbid anterior portion of the vitreous, and is undergoing the same process of proliferation.

The contraction of these masses occasions not uncommonly linear detachments of the ciliary body from the sclerotic, and a filling of the intervening space with a plastic exudation, which becomes partially organized into a meshwork of connective tissue (*Iwanoff*, *Knapp*, *Hirschberg*).

This false membrane (*schwarte*) consists of a ground-work of connective tissue, more or less distinctly fibered, opaque in a varying degree from molecular deposits and fat-granules, and interspersed with free pigment. This contains a greater or less quantity of recent oval nuclear cells and free nuclei, which are fructifying, and in a state of nuclear separation. These are generally without pigment, have here and there considerable quantities of coloring material, and then exhibit a very peculiar shreddy structure. The pigmented typical elements are collected in some places and form true layers; in others, they are arranged in fibers, which are often hollow, and have generally a blind, nodular, swollen extremity. These are the beginnings of the newly-formed vessels, which are gradually filled with blood, again branch out and extend into the vitreous humor (*Wedl*, *Schiess-Gemuseus*, *Iwanoff*).

In the connective-tissue stroma of the ciliary muscle, and upon the walls of its vessels, the increase of the nuclei and the infiltration of a serous or gelatinous substance, often cloudy and containing fat, points to the inflammatory participation. Sometimes it also leads to enormous collections of neoplastic cells and to an abundant vascular development. The fiber-cells of the muscle often resist for a long time, but finally they become involved in the process, turn opaque and undergo fatty degeneration. In the ciliary nerves at times no changes have been seen (*Schiess-Gemuseus*, *Hirschberg*), sometimes very marked thickening of Schwann's membrane, with more or less distinct increase in size of the nuclei, crumbling of the medullary sheaths (*Iwanoff*), and finally atrophy of the fibers.

The degeneration of the ciliary body and of the iris drains off (dries up) the aqueous humor, so that the anterior chamber becomes smaller and smaller. Instead of it, quite an adhesive, yellowish, coagulable fluid, rich in albumen, is often exuded into the closed posterior chamber, and the iris pressed forward by it, in the shape of a circular pad, or, when there is an unequal resistance of its tissue, distended into irregular humps.

3. A rarer occurrence is the detachment of the choroid. Post-mortem examinations have long since proved that they do occur (*Ammon*), but attention was first directed to the subject after they had been observed with the ophthalmoscope. (*Graefe, Liebreich.*) It has many analogies with detachment of the retina. A serous or gelatinous albuminous exudation is secreted by the choroidal tissue, collects especially in the outermost pigment layer, separates its elements from each other, finally tears through and separates the choroid more and more from the sclerotica. It has generally a yellow color, and leaves small coagulations on the walls of the cavity formed by itself. Cellular structures of various kinds are seen in the firmer parts, mingled with pigmented remains of the lamina fusca and of free coloring material. The tissue of the choroid has then, according to anatomical investigations, the characteristics of a more or less luxuriant proliferation process—is even at times hypertrophied and spongy, from similar products. Such detachments have been seen among the results of irido-choroiditis, with advancing atrophy of the globe, and sclero-choroidal staphyloma, as well as in company with choroidal tumors. They sometimes attain to considerable size. It may happen that the whole surface of the choroid is loosened from the sclerotica and pressed inward, so that the connection is only kept up by a few isolated vessels. (*Iwanoff.*)

Occasionally they are primarily and quickly developed. Their size is then limited, and they are seen as spherical elevations of varying hight and extent, whose sides are tense and incapable of any wavy motion. The retina either runs smoothly over the vesicle or appears somewhat elevated at its base. By holding the ophthalmoscope properly we may see the vessels of the retina climbing over the tumor, and again descending on the opposite wall. Immediately behind, in the reddish fundus, we see the branches of the vasa vorticosæ dimly shining through. Then the diagnosis of a watery or gelatinous exudation under the choroid is verified, and any confusion with blood-extravasations or with new-formations avoided. (*Liebreich.*) Extravasations of blood in the retina and choroid are common. The morbid process declares itself by a great loss of the vision—up to complete blindness. Sometimes a true detachment of the retina is added to it. (*Graefe.*) The ordinary final result is atrophy of the globe, with the symptoms of irido-choroiditis.

4. A fourth form of choroidal inflammation—suppurative choroiditis—is characterized by purulent products. This is partly formed from the choroidal tissue itself, and is in part separated from the free surface of the choroid. The pus is generally first seen on the vessels of the tunica vasculosa and lamina fusca. Its elements are pressed together in the connective tissue accompanying the vessel, and not unfrequently fill their caliber, so that isolated twigs may be followed for some distance as ramifying, pus-colored fibers. When the process advances, the stroma is impregnated with pus, and this is either regularly diffused through the tissue, or at intervals is collected in a great quantity, so that the mass projects forward into the posterior chamber. The pus from the beginning is at times fluid, or of a creamy consistency. In isolated cases it has the signification of true tubercle. Very often it is evenly discolored or speckled with exuded blood.

If the pus be fluid, the stroma of the choroid in the large collections is generally destroyed, except a few pigmented, shreddy remains, and the vessels themselves do not long resist the deliquescing process. If the pus be more consistent, however, the elements of the stroma may still be often recognized. The pigmented stroma-cells are strewn together very irregularly, and pressed apart by masses of neoplastic elements, which have the characteristics of pus-corpuscles, and lie in a turbid, fatty, more or less consistent, fibrinous, intermediate substance, which often permeates the tissue in great quantity and causes it to swell. The pigment-cells often appear at the same time entirely unchanged, or only a little paler, partially deprived of their coloring material. But they are often filled with fat even up to their offshoots, yet seldom in a state of nuclear increase.

The cells without pigment, on the contrary, are involved in the proliferation process. In places, particularly in the inner strata of the tunica vasculosa, they are often entirely wanting, having been completely destroyed in the proliferation process, even to their prolongations, which are woven about the neoplastic elements in a delicate, fine net-work. When they are still present, they appear very much pressed forward. They grow in a fusiform shape, and contain two or

more opaque nuclei. These become free afterwards by a destruction of the cell-envelope, and change to true pus-corpuscles. The vessels of the tunica vasculosa are generally at the same time impaired to a great extent, are compressed, and finally entirely destroyed. The chorio-capillaris occasionally preserves its integrity for quite a long time, as well as the tunica elastica and the tapetum. But sooner or later, in the larger collections of pus, these strata also are completely destroyed. The chorio-capillaris is then entirely unrecognizable in the purulent product; the tunica elastica is partly perforated and broken up. Since the pus pushes inwards, the tapetum is partly displaced, its elements confused, and to some extent driven inward. A portion of the cells is lost by fatty degeneration, while another part perhaps increases, and causes the formation of greater masses of pigment, or assists somewhat in the development of the purulent deposits occurring on the free choroidal surface. (*Wedl, Schweigger, C. Ritter, Schiess, Knapp, Berlin.*)

The formation of pus is often confined to one or the other portion of the choroid; the rest of this membrane, as well as the ciliary body, has the appearance of a simple serous inflammation. It is very hyperæmic, ecchymosed, infiltrated with serum, very moist, spongy, being saturated with a turbid fluid. In other cases, the greater part of the choroid has already been changed into large collections of pus. Only isolated spots are found in which the choroid still exists, but has been in part deprived of its pigment. It is very hyperæmic, ecchymosed, infiltrated with serum, and, besides, interspersed with little pus-globules, and at times appears traversed by vessels filled with pus. Finally, we not unfrequently meet with cases in which the entire choroid is destroyed, and is, as it were, replaced by a more or less thick stratum of purulent, tuberculous pus, interspersed with a pigmented, shreddy material. This stratum is sometimes swollen out to a large nodule. Suppurative choroidal inflammation is never uncomplicated. The other parts of the globe are always affected at the same time, and often to such an extent that the process is rather a suppurative panophthalmitis. The retina appears, as a consequence of its inflammatory participation, very opaque, and often thickened by decided purulent infiltration, or even changed into a caseous mass. It is generally entirely detached from the choroid by the great amount of exudation of a fatty, turbid, thin, purulent fluid, and is folded together. In spots it deliquesces, so that its remains float in the vitreous like shreddy tatters, and, in case the deliquescence affects the posterior portion especially, rolls together over the posterior wall of the crystalline in a thick mass (*Schweigger*). In the later stages, the retina is completely destroyed by suppuration. The vitreous is in the beginning very opaque, its cellular elements being involved in an exceedingly luxuriant proliferation process. Perhaps, also, a partial washing over of pus-elements from the membranous surroundings occurs (*Ritter, Schiess-Gemuseus*).

Now and then we find it interspersed with compact masses of pus, or deliquesced to a turbid fluid, filled with purulent flocculi. In isolated cases the entire anterior portion of the vitreous is changed to a mass of pus or tubercle, being completely compressed by a caseous product. This latter then generally, also, fills the canal of *Petit*. Usually considerable quantities of pus lie in the ciliary body. These occasionally form small abscesses, and give rise to loss of substance on their deliquescence, or evenly permeate the tissue, and may destroy the parts in question by suppuration. A large hypopyon always accompanies this state of things; it may even fill up the aqueous chamber. The cornea is also generally very early infiltrated with a purulent product, and becomes an abscess. Its entire surface is often changed into a mass of pus, and deliquesces, or is destroyed by gangrene. The sclerotica, even, is infiltrated with a fatty, opaque product, becomes softened, is distended, and swells to an astonishing thickness. Sometimes it ulcerates, and thus

gives an exit to the intra-ocular pus. Sometimes the surrounding orbital tissue is changed to a mass of pus.

6. The tubercular deposit is localized in the choroid, partly in the form of a more diffuse, rigid, and finally liquefying infiltration, partly in the form of discrete nodules, or else heaped together in masses like tubercles.

The first form has been very seldom observed, and up to this time only in the last stages of general tubercular phthisis. It usually appears as panophthalmitis, confined to one eye, with slight signs of irritation, develops itself in a tolerably rapid manner, but is interrupted in its further course by the patient's death. All the tissues of the globe appear infiltrated, the whole globe soon becomes changed into a caseous tuberculous mass, in which the individual constituents of the globe are often very difficult to be separated from one another. After a short duration the mass begins in several scattered spots to undergo fatty degeneration, and to coalesce into a greasy purulent pulp. In this way circular cavities result, inside which the individual tissues, where they can still be recognized, appear completely disintegrated and limited by sharp eroded edges. In the cornea and choroid, especially, losses of substance often show themselves, as if beaten out with a punch, and with densely infiltrated precipitous edges. The individual excavations in some places soon coalesce with each other and exude a portion of their contents, if an exit has already been formed through the sclera; still, even then the globe does not collapse on account of the enormous quantity and stiffness of the products still present, but retains for a time about its original form, whilst the opening in the sclera gapes wide and opens to view a deep irregular cavity, from which exude proportionally small quantities of greasy pus, which becomes rancid under the influence of atmospheric air, and smells very strongly of butyric acid. Finally, if the patient does not die, all that remains of the globe is a much thickened sclera. In one case even the sclera was destroyed as far as its most posterior zone, and this presented in connection with the optic nerve a kind of plate with very irregularly jagged borders, in the opening of which lay a mass of tuberculous matter about the size of a hazel-nut. The surface of this rigid tubercular mass, firmly connected with the sclerotic, was glandular, warty, partially eroded, and abundantly strewn with pigment from the completely unrecognizable choroid. The doubts, which are raised on many sides against the really tuberculous nature of these products (*Graefe*, *Leber*), are unwarranted, and soon disappear by a careful examination as well as by the consideration of the history of the patients.

Discrete tubercle has been observed but rarely in the region of the choroid in chronic general tuberculosis (*Ed. Jaeger*, *Cohnheim*, *Arcoleo*, *Vernon*), but on the contrary, frequently, though by no means constantly, in acute miliary tuberculosis (*Manz*, *Cohnheim*, etc.). It is developed under such conditions sometimes very early, sometimes not until a few days before the death of the patient, and where it appears may be regarded as a very valuable, even pathognomonic, sign of the general disease, sometimes so extremely difficult to be diagnosticated, while, on the contrary, its absence by no means excludes, according to authorities, the existence of the latter (*Steffen*). Ophthalmoscopically the discrete tubercle appears in the form of tolerably regular circular spots of very variable size. The smaller of these appear as yellowish or reddish-yellow discolorations of the fundus; the larger ones, on the contrary, as distinctly prominent bright nodules, which are surrounded by a more or less deep brownish zone. Only the largest extremely prominent nodules have exceptionally a more deeply pigmented border. Moreover, the ophthalmoscopic image changes to

some extent with the subsequent exacerbations (*Graefe, Leber, Coccius*). There appears to be no marked disturbance of vision caused by the process, according to previous experience, even when the individual nodules are developed to a proportionally considerable extent (*Fränkel*).

According to anatomical investigations, both eyes are generally involved. We find sometimes one, sometimes several nodules, and these in the latter case sometimes scattered, sometimes grouped together. Their favorite situation is the neighborhood of the papilla and the yellow spot, yet they occur also in the periphery (*Steffen*). They are generally very small, and then are transparent; if they attain a larger size they become caseous. They always proceed from the *chorio-capillaris* (*Busch, Cohnheim*), and, as they enlarge, invade the remaining layers of the choroid. In the beginning they occasion no bulging forward of the *tunica elastica*, but later this occurs, and then the pigment of the tapetum cells covering them becomes atrophied, whilst the latter suffer no change. Only in the large nodules does the pigment appear heaped up at the periphery. The tubercles are developed by luxuriant growth, and probably by enormous proliferation of small circular cells, which exist also in the normal condition; the fixed stroma cells are primarily but slightly or not at all affected (*Cohnheim*).

7. Rupture of the choroid, which not unfrequently occurs, deserves special mention. Such ruptures, with uninjured sclera and retina, have been only once proved anatomically to exist (*Ammon*). Still a number of ophthalmoscopic observations already exist. The cause is always a blow, a kick, a fall, etc., which strikes the eye with great force, causing a sudden change of form, with stretching of the sclera. Shortly afterwards extravasations of blood are found in the posterior portion of the eye, which are usually soon associated with opacity of the vitreous, and conceal the fundus from view. Later on the extravasations are absorbed, and often leave behind scattered streaks of dark-colored coagula, which lie upon the choroid, and become gradually changed, at least partially, into heaps of blackish-brown granular pigment. They finally appear plain, as the dioptric media clear up more and more, and near by are seen in the ophthalmoscopic image the rents in the choroid, in their extremely peculiar form, which is scarcely to be confounded with anything. They appear, namely, as narrow, long, bright streaks, which contrast very strongly with the surrounding background, which is generally but little changed. They lie, with few exceptions (*Sämisch*), in the posterior half of the choroid, and almost always on the outer side of the papilla, at varying distances from it. Their axis stands usually almost always perpendicular, or at least at a great angle to the direction of the meridian, and is often remarkably bent, forming an arch concentric with the border of the optic-nerve entrance. Only very seldom do they run obliquely or even horizontally (*Ed. Jaeger, Mauthner*). In one case, in consequence of the springing of a piece of iron against the inner portion of the right eye, a bifurcated rupture of the choroid was produced in the equatorial region, inwards from the entrance of the optic nerve, the longer leg of which was the length of two or three diameters of the optic papilla, and ran vertically; whilst the short leg, the length of one diameter of the papilla, ran horizontally, and formed with the upper end of the first almost a right angle. The edges of the choroidal wound were rough and deeply pigmented. At some distance from them were seen the wavy, glistening, fatty edges of the very irregularly ruptured retina, concealing from view, for a little distance, the red background. On the other side of the external edge of the rupture, as far forward as the ora serrata, the retina was detached

in the form of a bladder in folds. The vitreous appeared slightly cloudy. The affection manifested itself subjectively by a very considerable diminution of the acuteness of vision, and by an extensive limitation of the external periphery of the field of vision.

The main color of the rupture is caused by the exposed sclera. Upon this are seen dirty yellow or brownish marks, with cloudy, diffused borders, irregular heaps of dark pigment, here and there a choroidal vessel, which proceeds from the sclera, and immediately passes over into the ruptured edge of the choroid, or runs diagonally across the entire breadth of the streak. The borders of the rupture are sometimes sharp, sometimes somewhat everted, frequently deeply pigmented. Sometimes, however, they appear raggedly rough or washed-away red. The ruptures divide often into two or three legs or hooks, which, however, maintain in general the direction of the main part. The separate ends run acutely towards each other, and preserve their sharp borders; sometimes they lose themselves very gradually in the normal fundus, proceeding for a certain distance as bright red, cloudy-drawn borders. Sometimes the choroid ruptures in a single spot (*Ammon*, *Graefe*, *Sämisch*, *Schweigger*, *Knapp*, *Mauthner*, Fig. 41); sometimes there are two ruptures (*Hirschler*, *Frank*, *Streatfield*, *Knapp*, *Sämisch*, *Wilson*). Cases also occur where the choroid is torn in three (*Haase*, *Sämisch*, *Ed. Jaeger*, *Stavenhagen*), and more places (Fig. 42). The retinal vessels run, with rare exceptions (*Graefe*), without interruption or deviation, diagonally across the bright rupture, provided that the retina is not likewise ruptured (*Sämisch*). The retina, moreover, easily takes an active part in the process under the form of neuro-retinitis. This, however, frequently soon passes away, and often leaves behind no perceptible morbid changes. Even the functional disturbance is in such cases sometimes proportionally trifling; the central acuity of vision can even rise again almost to the normal standard (*Sämisch*, *Knapp*). As a rule, however, the functional power of the retina remains injured in a high degree. The acuteness of vision, which immediately after the accident is reduced by the extravasations of blood and the succeeding inflammatory reaction to the quantitative perception of light, improves but slightly with the progress of absorption, the field of vision remains enveloped in mist or smoke, and not uncommonly extensive peripherical limitations (*Hirschler*) or interruptions (*Talko*) can be demonstrated in it. As later consequences of the affection, without referring to the results of irido-choroiditis, there have frequently been observed detachments of the retina (*Sämisch*), once progressive atrophy of the optic nerve (*Frank*), and once glaucoma (*Streatfield*). The frequently coexistent sluggishness, dilatation and irregular form of the pupil, can possibly be dependent upon a stretching or rupture of the ciliary nerves running in the *lamina fusca* (*Ammon*, *Hirschler*).

The reason why the posterior part of the choroid is inclined to rupture under the action of violent blows is not sufficiently explained. The closer connection with the sclera here seems to have something to do with it. At any rate this hinders a rapid division of the traction, which, in a forcible stretching of the sclera, must necessarily be exercised upon the membranes covering them on the inside. In the loosely-attached anterior zone of the choroid and in the very slightly attached retina, a rapid division of the tension is much more easily possible. At first the edges of the rupture do not seem to gape (*Ammon*), but only later to separate from each other, possibly in consequence of contraction.

The bright red streaks and the diffused reddish ends of the tendinous-white ruptures should be referred not so much to real losses of substance in the con-

tinuity of tissue, but rather to atrophy of the structure, caused by great stretching. In one case a number of white, striped cicatricial bands were observed, which extended over the sickle-shaped surface of the rupture, enveloped several of the retinal vessels very distinctly, and projected unmistakably somewhat above the cicatricial tissue (*Knapp*).

8. Of no less interest are simple ruptures of the vessels in the choroidal structure, and the resulting hemorrhagic extravasations. These occur sometimes spontaneously, or in consequence of sudden disturbances in the circulation by sneez-

Fig. 41.

Fig. 42

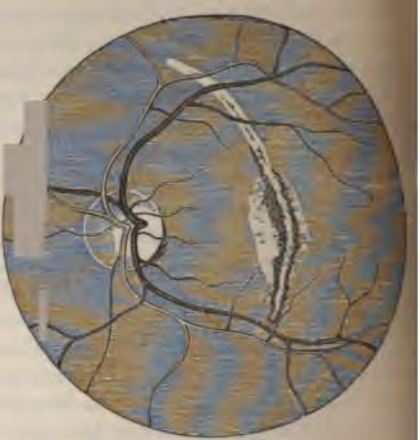

ing, coughing, vomiting, dependent positions of the head, etc., presupposing, however, always disease of the walls of the vessels by atheromatous processes or inflammatory loosening, etc. More often, however, are they of traumatic origin, or to be inferred as caused by a diminution of the intra-ocular pressure in consequence of pathological changes, or on account of partial evacuation of the dioptric media through an opening in the cornea or sclera. Where the contents of the globe are diminished by means of commencing atrophy of the parts or on account of simple exuding through a loss of substance in the sclera, the extravasations may become enormous, break through the limiting membrane of the choroid, push the retina before them or rupture it, and force an entrance into the vitreous, tear off even the ciliary muscle by perforating corneal wounds, and give rise to serious losses of blood. Where, however, the sclera is uninjured and the intra-ocular pressure is not much under the normal degree, profuse extravasations and the consequent ruptures of the limiting membrane and retina are exceptions; the hæmostatic relations of the interior of the eye with difficulty admit of them, the conditions for a rapid absorption of the vitreous may then be favorable, where, it must be admitted, blood can recede according as the normal contents of the globe diminish. The extravasations as a rule are situated between the choroid and sclera, or partially in the true vascular layer, very rarely between the limiting membrane and *tunica vasculosa*, are sometimes very numerous, and are

usually absorbed in a short time, leaving small masses of pigment behind. Ophthalmoscopically they appear when fresh or not very old as dark blood-red spots, with irregular, sometimes indistinct borders. They are distinguished from retinal hemorrhages by the fact that the retinal vessels in their region are very distinctly distinguished with their sharp borders, and do not disappear as the latter do in extravasations. Where, however, no such vessel runs across the extravasation, the deeper situation and the fact that the retinal hemorrhages are often streaked on their edges, enables us to make a diagnosis, since they are usually spread out in the spaces between the nerve-fibers. Occasionally larger choroidal extravasations shine through the sclera, and can be thus directly recognized. Visual disturbances are not easily occasioned directly by simple choroidal hemorrhages. Where such exist the accompanying injuries and the subsequent inflammatory action are probably the reason. Even in the case, as where the retina was bulged forward in consequence of the enormous quantity of exudation, the functional disturbance thus occasioned cannot manifest itself, because such an occurrence presupposes deeply diseased changes, and the hindrances to the power of perception connected with them completely conceal them.

Authorities.—*Kölliker*, mikr. Anatomie II. Leipzig, 1854. S. 628.—*Henle*, Handbuch der Anat. II. Braunschweig, 1866. S. 611.—*H. Müller*, Würzburger Verhandlungen der phys.-med. Gesellschaft, X. S. 179; Würzb. naturwiss. Zeitg. II. S. 221; A. f. O. II. 2. S. 35; III. 1. S. 1; IV. 2. S. 277.—*Rosow*, A. f. O. IX. 3. S. 63, 65.—*Wittich*, ibid. II. 1. S. 124.—*C. Ritter*, ibid. X. 1. S. 67; X. 2. S. 148.—*Babuchin*, Würzb. naturw. Zeitg. IV. S. 70, 81.—*Arlt*, A. f. O. III. 2. S. 87, 102, 103, 110.—*O. Becker*, Wiener med. Jahrbücher, 1863. S. 159, 170, 175.—*V. Recken*, Ontleedkundig onderzoog. v. d. Toestel v. acc. Utrecht, 1855, S. 37, 46.—*Cramer*, Het acc. vermogen, etc. Harlem, 1853. S. 68.—*Helmholtz*, A. f. O. I. 2. S. 65.—*Henke*, ibid. VI. 2. S. 53, 57.—*Klebs*, Virchow's Archiv. 21. Bd. S. 176.—*Todd* and *Bowman*, Phys. Anat. 1847. II. S. 27.—*Kölliker*, l. c. S. 635.—*Brücke*, Med. Zeitg. des Vereines f. Heilk. in Preussen. 1846. S. 130; Anat. Beschreib. des m. Augapfels, Berlin, 1847. S. 12, 17, 20.—*Mannhardt*, A. f. O. IV. 1. S. 269.—*G. Meyer*, Virchow's Archiv, 34. Bd. S. 380.—*Leber*, Denkschriften der Wiener k. Akademie der Wiss. 24. Bd. S. 299, 305, 308, 312, A. f. O. XI. 1. S. 1.—*Winther*, Experimental-Studien über die Path. des Flügelfelles, Erlangen, 1866. S. 5, 8-13.—*Kugel*, A. f. O. IX. 3. S. 128.—*Schweigger*, A. f. O. V. 2. S. 216; VI. 2. S. 820; IX. 1. S. 200; Vorles. über den Gebrauch des Augenspiegels, Berlin, 1864. S. 63.—*Sämisch*, Beiträge zur norm. und path. Anat. des Auges. Leipzig, 1862. S. 26.—*Coccius*, Ueber die Anwendung des Augenspiegels. Leipzig, 1853. S. 53.—*Liebreich*, A. f. O. IV. 2. S. 286, 290, 294.—*F. E. Schultze*, Arch. f. mikr. Anat. III. S. 477, 487.—*M. Schulze*, ibid. S. 376.—*Flemming*, ibid. IV. S. 353.—*Schwalbe*, ibid. VI. S. 1, 3, 28; Centralbl. 1868, S. 849.—*Haase*, A. f. O. XIV. 1. S. 57, 64, 66.—*Iwanoff*, *Rollet*, ibid. XV. 1. S. 43, 46, 51, 54.—*Hippel*, *Grünhagen*, ibid. XIV. 3. S. 237.—*Czerny*, Wien. Augenklinik, Ber. S. 183.—*A. Frisch*, Sitzungsber. d. Wien. k. Akad. LVIII. 2.—*Sesemann*, Arch. f. Anat. u. Phys. 1869, S. 154, 169.—*Manthner*, Lehrb. d. Ophthscop. S. 407, 411.

Senile Changes.—NOSOLOGY: *Wedl*, Grundzüge der pathol. Histologie. Wien, 1854. S. 330, Sitzungsberichte der Wiener k. Akad. der Wiss. 48. Bd. S. 384, 385, 386, 388; Atlas Cornea-Sclera, Retina-Opticus, Iris-Chorioidea.—*Donders*, A. f. O. I. 2. S. 106, IX. 2. S. 215, 217; kl. Monatbl. 1863. S. 505, 1864. S. 433.—*H. Müller*, Verhandlungen der Würzb. phys.-med. Ges. 1855. 28. April, 1856. 8. März, 27. Dec., 1859. 28. Mai; A. f. O. II. 2. S. 1, 13, 28, 32, 40, 64; IV. 1. S. 363, 366; IV. 2. S. 1. 18, 20. 23, 30, 39.—*Schweigger*, Congrès intern. d'ophth. Paris, 1864. S. 79; A. f. O. V. 2. S. 216, 219, 223, 227, 231, 233, 234; VI. 1. S. 143, 150, 151, 163; VI. 2. S. 258, 261, 265, 271, 274; IX. 1. S. 192, 202; Vorlesungen über den Gebrauch des Augenspiegels. Berlin, 1864. S. 126, 127, 144.—*Rosow*, A. f. O. IX. 3. S. 63, 75, 82.—*Iwanoff*, ibid. XI. 1. S. 191, 193, 198.—*Mayrhofer*, Zeitschrift der Wiener Aerzte, 1860. Nro. 47.—*Liebreich*, kl. Monatbl. 1863. S. 488; Traité prat. des mal. d. yeux, par Mackenzie, Bruxelles, 1857. II. S. LIII.; A. f. O. V. 3. S. 259.—*Graefe*, A. f. O. I. 1. S. 371, 378, 380; II. 1. S. 210; III. 2. S. 457, 461, 464, 475, 479, 481, 484, 487, 551, 554; IV. 2. S. 143, 146; VIII. 2. S. 271, 276, 279, 284, 286; kl. Monatbl. 1864. S. 435.—*Hoffmann*, A. f. O. VIII. 2. S. 124, 143, 157, 176.—*Ed. Jaeger*, Zeitschrift der Wiener Aerzte.

1858. S. 465, 470, 484, 488; Oesterr. Zeitschrift für prakt. Heilkunde, 1855. Nro. 4.—*Coccius*, Ueber Glaucom. Entzündung, etc. Leipzig, 1859. S. 9, 12, 44; A. f. O. IX. 1. S. 1, 13, 16, 19.—*G. Braun*, A. f. O. IX. 2. S. 222, 225.—*Mackenzie*, Prakt. Abhandlung über die Krankheiten des Auges. Weimar, 1832. S. 685.—*Galezowski*, kl. Monatbl. 1865. S. 58.—*Klebs*, Virchow's Archiv. 19, Bd. S. 337; A. f. O. XI. 2. S. 242.—*Schiess-Gemuseus*, IX. 1. S. 22, 24, 33, 38, 39; IX. 3. S. 170, 175, 181, 184, 186, 193, 195.—*Pagenstecher* and *Sämisch*, klin. Beobachtungen. Wiesbaden, 1861. II. S. 74, 77, 83, 90.—*Ammon*, Zeitschrift f. Ophth. II. S. 247.—*Warprop*, Essays on the morb. anat. etc. London, 1818. II. S. 64.—*Stellwag*, Ophth. II. S. 98, 146, 150, 151.—*C. Ritter*, A. f. O. VIII. 1. S. 1. 30, 52, 55, 60, 65.—*Heyman*, ibid. VII. 1. S. 127, 130.—*Manz*, ibid. IV. 2. S. 120. 124; IX. 3. S. 133, 135, 139, 140, 142; kl. Monatbl. 1863. S. 450.—*F. E. Schultze*, Arch. f. mikr. Anat. III. S. 477, 487.—*M. Schultze*, ibid. S. 376.—*Flemming*, ibid. IV. S. 353.—*Schwalbe*, ibid. VI. S. 1, 3, 28; Centralbl. 1868. S. 849.—*Haase*, A. f. O. XIV. 1. S. 57, 64, 66.—*Iwanoff*, *Rollet*, ibid. XV. 1. S. 43-54.—*Hippel*, *Grünhagen*. ibid. XIV. 3. S. 237.—*Czerny*, Wien. Augenklinik, Ber. S. 183.—*A. Frisch*, Sitzungsber. d. Wien. k. Akad. LVIII. 2.—*Sesemann*, Arch. f. Anat. u. Phys. 1869. S. 154, 169.—*Mauthner*, Lehrb. d. Ophthscop. S. 407, 411.—*Rosow*, Centralbl. 1867. S. 488.—*Iwanoff*, Ueber symp. Ophth. v. Mooren. S. 161 u. f.; A. f. O. XV. 2, S. 16, 22-49.—*Graefe*, Congrès ophth. 1867. S. 174.—*Graefe*, *Leber*, Berl. klin. Wochenschr. 1867. S. 324; A. f. O. XIV. 1. S. 183, 184; kl. Monatbl. 1867. S. 299.—*Ed. Jaeger*, Handatlas, Fig. 121.—*Coccius*, de apparatu optico. 1868. S. 14.—*Galezowski*, kl. Monatbl. 1868. S. 61; Arch. gén. de méd. 1867. II. S. 266.—*Ammon*, A. f. O. 1. 2. S. 124.—*Stellwag*, der intraoc. Druck. S. 34.—*Laqueur*, Centralbl. 1869. S. 362.—*Rydl*, Wien. Augenklin. Ber. S. 136.—*Czerny*, ibid. S. 178, 181.—*Hirschberg*, kl. Monatbl. 1868. S. 153; 1869. S. 66, 67, 299, 300.—*Gouvea*, A. f. O. XV. 1. S. 257.—*Berlin*, ibid. XIII. 2. S. 297; XIV. 2. S. 283, 287, 291, 296, 314.—*Knapp*, ibid. XIII. 1. S. 127-167; kl. Monatbl. 1868. S. 320; Arch. f. Aug.- u. Ohrenheilkd. 1. S. 12-28.—*Mauthner*, Lehrb. d. Ophthscop. S. 441, 443, 449.—*Cohnheim*, Virchow's Archiv. 39. Bd. S. 49.—*Busch*, ibid. 36. Bd. S. 448.—*Bouchut*, Gaz. méd. de Paris, 1868. S. 644; Compt. rend. 67. Bd. S. 940.—*Arcoleo*, Congrès Ophth. 1867. S. 189.—*Clifford*, Lancet, 1869. 1 S. 638.—*Fraenkl*, kl. Monatbl. 1869. S. 123; Jahrb. f. Kinderkrankh. 1869. S. 113.—*Steffen*, ibid. S. 315, 319.—*Vernon*, Schmidt's Jahrb. 140, Bd. S. 310.—*Hirschler*, Wien. med. Wochenschr. 1865, Nro. 91, 92.—*Sämisch*, kl. Monatbl. 1866. S. 111; 1867. S. 31.—*Haase*, ibid. 1866. S. 255.—*Schroetter*, ibid. S. 255.—*Talko*, ibid. 1868, S. 269.—*Soelberg*, *Wells*, ibid. S. 221.—*Dohmen*, ibid. 1867. S. 160.—*Stavenhagen*, klin. Beobachtungen. Riger, 1868, S. 91.—*Streatfield*, Ophth. Hosp. Rep. II. S. 241.—*Frank*, ibid. III. S. 84.—*Wilson*, nach Knapp. Arch. f. Aug.- und Ohrenheilkunde, I. S. 10.

1. Irido-cyclitis, Irido-choroiditis.

Symptoms.—*These affections, besides having the symptoms of exudative iritis, are characterized by a very great impairment of vision, and inflammatory opacity of the vitreous humor.*

1. The appearance of the inflammation of the iris varies exceedingly, according to the intensity and course of the process. The only constant symptom is the generally complete adhesion of the pupillary margin to the anterior capsule. In the first stages, hypopyon occasionally is seen, gummy nodules, &c., but in the later stages such products are almost always wanting, the uveal portion being usually quickly atrophied, and thus the productive power is destroyed. Where the disease exists for some time, we therefore generally find the symptoms of inflammation with those of atrophy. As a rule, there is added to this, evidences of deeper vascular degeneration. Isolated and large vascular twigs appear on the surface of the iris, run there some distance, branch off, and again disappear. The extravasations of blood that not unfrequently appear and are occasionally repeated, and which have been observed in the aqueous humor, are to be referred to them. A considerable decrease in the aqueous humor is connected with the atrophy, the chamber becomes smaller and smaller, until finally the iris rests on the membrane of the aqueous humor. The iris, which is very much discolored, and in spots tendinously degenerated, then often appears very tense. In other cases it is in some places projected forward like a hump, by the collection of a yellowish, albuminous, tenacious fluid, in the posterior chamber, or the whole of it lies on the cornea, in the form of a circular cushion, whose middle wall falls away abruptly from the mass, closing the generally irregular and narrow pupil, while the outer wall slopes superficially toward the periphery. Occasionally the iris, which is discolored to a lead-gray or pale-brown color, is evidently relaxed, or has a spongy, puffed-up appearance. Its surface is full of glandular elevations and ridges, velvety, or occasionally covered by a discolored, moldy deposit.

2. Around the cornea, a more or less severe episcleral vascular injection is always seen. The anterior zone of the ocular conjunctiva often takes part in the congestion, and causes the formation of a large vascular ring, and occasionally this is accompanied by inflammatory œdema of the conjunctiva, and even of the lids. The hyperæmia is but rarely arterial, and then in the beginning it generally has a decided venous character. We may often observe, especially in the later stages of the affection, a great number of greatly-distended twigs, swollen with dark blood issuing from the anterior zone of the sclerotica, becoming a rough net-work, and then joined to larger twigs, and stretching out posteriorly in a tortuous course. This overloading of the anterior ciliary veins indicates hindrances to the circulation in the vasa vorticosæ. It thus gives evidence of a decided collateral circulation, and is dependent upon the changes in the choroid itself.

3. The tension of the capsule of the globe is frequently somewhat increased in the first stages of the affection. It varies in degree in given cases within short periods of time, and also causes changes in the intraocular pressure to be observed.

In the later stages the globe is, as a rule, very soft, and indicates a decrease in its contents, and advancing atrophy of the inner structures.

4. In case the pupil is still permeable for direct light, the ophthalmoscope only shows great haziness of the vitreous, which hides the whole fundus from view. The turbidness is generally diffuse; it is only here and there thickened to some indistinctly bounded string or leaf-like filaments. More rarely it appears figured. In the thick cloud behind the pupil, branching tufts or a rough open-work are seen interspersed with flocculent masses. This cloudiness is generally extended over the entire vitreous, but is occasionally concentrated in some places, especially in the region of the ciliary body.

If it so far clears up in its further course that the light from the ophthalmoscopic mirror can pass through, no further change in the fundus is, as a rule, apparent, except a remarkably deep reddening of the optic papilla, which is to be explained by the connection between the choroidal vessels and the nutrient vessels of the optic nerve.

5. The acuteness of vision is always very much impaired, much more so than may be entirely explained by the exudation in the pupil or even by the opacity of the dioptric media. The eye has become *amblyopic* in the true sense of the word, and shows the participation of the retina and optic nerve. The patients complain of a thick cloud or smoke which hangs over the visual field. This is apt to be lighter in the beginning, but varies very much in degree, becomes darker with time, and renders the recognition of objects more and more difficult, if not entirely impossible. On more exact examination, we often plainly recognize limitations in the field of vision, which begin from a peripheral portion, gradually extend, finally pass over the center, and destroy the vision entirely, or leave only a quantitative perception of light. Generally, then, there is not only a simple inflammatory sympathy of the retina and of the optic nerve, but also much greater changes in the nutrition of the eye. These are apt to accompany the later stages of the course of the disease. There is usually progressive atrophy of the optic nerve, also detachment of the retina, excavation of the optic papilla. The position and boundaries of the limitation in the field of vision enable us generally to diagnosticate with some probability one or the other condition.

6. With impairment of vision subjective photopsic symptoms are often observed, *e. g.*, colored or white points, stars, wheels, flames, sparks, etc., etc. They appear principally in the dark, and increase when there is any excitement of the nerves or circulation.

7. Pain is often present and varies exceedingly in degree and kind. It is situated sometimes in the eye itself, sometimes extends along the course of the separate twigs of the fifth pair of nerves. It is very apt to occur in paroxysms, which return regularly or irregularly, and have more or less complete remissions between them. They occur usually only so long as the tension of the globe is increased. Coincident with these there often appears a slight sensitiveness to pressure in the ciliary region, which may be explained by the greater tension of the nerves and the consequent limitation in the conducting power of peripherical impressions. In the later stages, where the globe has already become softer, the pain is wont to be slighter or to be entirely absent; on the contrary, the ciliary region is very frequently extremely sensitive to every external pressure, at least in individual places, which, we believe, should be referred to the better conducting power of the relaxed nerves (*Graefe*).

Occasionally some affection of the gastric nerves is observed, indicated by loss of appetite, nausea, and vomiting. Febrile action is somewhat common in acute cases.

8. Irido-choroiditis appears frequently combined with keratitis punctata, with symptoms of hydromeningitis, capsulitis, and sometimes also with phakitis (inflammation of the lens). In the later stages polar and vitreous cataract are not very rare. In inflammations of the uvea almost all the parts of the eye are involved, and the complications are more or less distinctly perceived objectively

Causes.—The etiology of irido-choroiditis is to a great extent the same as that of simple iritis. Indeed, the same injuries which have been described as the ordinary causes of iritis may, under some circumstances, lead to inflammatory proliferation in the ciliary body and choroid.

Occasionally the severity and extent of the irritation, is the reason that the process is not limited to the iris, and that we have in the beginning an irido-choroiditis. This happens most frequently in consequence of severe concussions of the eye, of penetrating wounds, especially when united with tearing or bruising of the parts, or with loss of a large amount of vitreous. It may also occur if a foreign body enters the anterior part of the eye, and remains there for some time, or if considerable blood has been exuded into the interior of the eye; if the crystalline body has been dislocated, and presses upon parts abundantly supplied with vessels and nerves; if the capsule has been injured, the lens swells, and the inner parts of the eye have been mechanically injured, &c. Cataract operations, therefore, play an important part in the etiology of irido-choroiditis, especially those in which large pieces or the entire lens remain behind, or where, for the purpose of bringing out a large nucleus, an extensive wound is made, or where the operation was a very difficult one, and some force was used.

The location of the irritation is also not without influence. Injuries of the ciliary region, even insignificant ones, are, according to experience, much more dangerous, and lead much oftener to irido-choroiditis than analogous injuries to the iris or choroid. It appears as if the great nervous supply of the ciliary body were of great importance in this respect.

More frequently, however, the duration of the irritation is the cause, rather than the severity, extent, and location of the injury, of the gradual extension of the process from the iris to the ciliary body. Where, after the outbreak of the iritis, the cause, or any other source of irritation, becomes confirmed in its destructive influence, the process soon becomes an irido-choroiditis. This often has a syphilitic character, and is a result of the neglected or improper treatment of a specific iritis.

Besides, an exceedingly efficacious factor for the continuance of conditions of irritation is found in the adhesions of the pupillary margin with the anterior capsule, which are often established by inflammations of the iris. These irritations may be continued by a gradual extension of the inflammatory process over the entire uveal tract, and therewith over the entire globe. (*Graefe.*) Partial and scattered posterior synechia is, in accordance with daily experience, less dangerous than that which is nearly or quite complete. Where such a shutting-off or closure of the pupil exists, attacks of iritis, as a rule, are repeated again and again, and soon the deeper parts of the eye are involved. To the symptoms of iritis are added those of cyclitis and choroiditis, and very often the other eye is involved in sympathetic inflammation. At any rate, such a posterior synechia is an exceedingly powerful disposing influence in causing transitory external or internal irritations, which

otherwise would be borne without any harm, or bringing the existing morbid conditions to a process of proliferation.

It does not always, then, require an external injury for the excitement of a recurrent inflammation. The bruising and tension to which the adherent iris is exposed are enough, possibly, of themselves to cause severe irritations and inflammations. The fact that removal of the tension by a partial excision of the iris lessens or subdues the tendency in the iris to relapses, speaks for this view. On the other hand, as has been proven, anterior synechia may be also a cause of recurrent iritis, if a high degree of tension is imposed upon the iris by a bulging forward of the cicatritial part of the cornea. Such an iritis has a very similar course to one caused by posterior synechia. (*Graefe.*)

Irido-choroiditis is often, also, secondary, inasmuch as the uveal portion is only secondarily attacked, or was originally affected in another form. Its appearance often forms the closing scene of other processes, which have been exceedingly various —detachment of the retina, exudative retino-choroiditis, glaucoma, staphyloma of the sclerotica, &c.

A direct connection with scrofula (*Arlt*), rheumatism, gout, etc., does not exist, though it does with the so-called recurrent typhoid fever, the chief cause of which can be found in starvation and mal-nutrition (*Mackenzie, Blessig, Estlander*).

The ophthalmia does not seem to occur with the same frequency in all epidemics of this disease. It generally asserts itself several weeks or even months after the last febrile attack, that is, after the patient seems to be convalescing, seldom earlier, attacks most frequently individuals between ten and thirty years of age, is usually confined to one eye, and is characterized by great opacities of the vitreous, and a more or less violent iritis. The opacities of the vitreous are at first diffuse, soon, however, become flocculent and form denser masses, in individual cases they even contract to purulent or white masses, reflecting light strongly, which lie at the bottom of the fundus. They are accompanied by very considerable disturbances of vision, which manifest themselves at first in the form of cloudy or flocculent bodies, increase, however, by further progress of the disease to complete blindness, and demonstrate indubitably the sympathy of the retina, choroid and optic nerve. The iritis is not developed in many cases until after the appearance of the opacities of the vitreous, or does not occur at all (*Estlander*); in other cases it appears distinctly at the commencement of the ophthalmia (*Mackenzie, Blessig*). It bears, in general, no malignant character, but limits itself to partial adhesions of the pupillary margin, seldom leads to complete closure of the pupil, but often to *hypopyum*. In the latter case it may lead exceptionally to atrophy of the globe; but the disease, as a rule, recedes completely, without leaving behind any evil consequences, since the posterior synechiæ can be broken up by the use of atropine, and the opacities of the vitreous soon begin to lessen and gradually to be absorbed. Only the dense purulent masses remain usually for an uncertain length of time in the vitreous, and manifest their presence by the disturbances of vision. As a whole the disease runs a sub-acute course, with variations of the intra-ocular pressure, the latter being often decidedly lessened, but scarcely ever increased. The duration of the disease varies between two and three months. It is usually shorter in children, but where the posterior synechiæ cannot be broken up by atropine, it will last even beyond this period. A special local treatment is usually considered superfluous, because it exerts no influence upon the course of the disease (*Estlander*). Still the energetic employment of atropine is urged for the sake of breaking up the synechiæ.

The connecting link between the *ophthalmia post-febrilis* (*Mackenzie*, *Blessig*) and the recurrent fever is unknown. The assumption, that changes in the blood, especially a great number of white cells, are the most probable cause, is rendered very doubtful by the fact that the ophthalmia usually makes its appearance long after the last febrile attack, and, therefore, after the quality of the blood has become essentially improved.

If, however, this hypothesis could be proved (*Estlander*), the ophthalmia post-febrilis might be arranged in the same category with the maladies of the deeper tissues of the globe occurring in leucocythemia (p.189). As a matter of fact, a sympathetic affection of the uveal tract has been observed in the latter (*Sämisch*).

Course.—If an irido-choroiditis be developed in consequence of a severe irritation acting upon the eye, its appearance is generally in an acute form. It has then a sthenic character, and within a short time reaches its highest point, with very severe pain and the symptoms of an intense local afflux of blood, and leads just as quickly to permanent results, or declines gradually into a chronic course, and creeps along, with occasional exacerbations and remissions, for weeks and months, and even years; till, finally, a pause occurs, or the complete atrophy of the different parts of the globe gives no more room for inflammatory action.

If the remaining cases are chiefly in the secondary forms, the irido-choroiditis often appears in a subacute manner, but inclines to a chronic course, into which it soon passes, only at times flaming up spontaneously, or in consequence of injuries. Often, however, the symptoms of irido-choroiditis only appear very gradually, being united to those of the primary disease.

Thus the patient often complains of a marked sudden loss of visual power in one eye. He speaks of a thick cloud or smoke over the entire visual field, which increases from day to day. Pain is not apt to be present, or is not very great. Sometimes there is some photophobia. Objectively, we notice a generally very slight episcleral, vascular injection, which, passing beyond this region, is often limited to isolated segments of the anterior scleral zone. On the other hand, the aqueous humor generally appears turbid, and occasionally with flakes. The corneal epithelium is often also loosened, or even spotted, dotted, or maculated, while the corneal substance proper has lost some of its transparency, and has a gelatinous appearance. In isolated cases, the characteristic exudative collections of keratitis punctata—a frequent accompaniment of the latter stages—appears. The iris is, in some places corresponding to the episcleral injection, quite relaxed, greatly discolored, and not unfrequently covered by a fawn-colored, moldy substance. It is also sluggish, only little capable of dilatation by atropine, and its border is almost always united to the anterior capsule by isolated papillary excrescences. At the same time a few distended vessels filled with dark blood are developed on the discolored iris, which ramify on the surface, and readily cause hemorrhage in the aqueous chamber.

The vitreous humor, so far as it can be seen with the ophthalmoscope, is diffusely turbid. Having once reached this point, the process either advances regularly, or occasionally becomes decidedly worse, during which time the ciliary injection increases. The intraocular pressure is also somewhat increased, especially when the impairment of vision, on account of decided increase of the turbidness of the vitreous, is progressive. Then the original inflammatory collections on the iris extend more and more; the blood-vessels on its surface advance further and further, or new collections are formed, which gradually run together. The relaxation of the iris-tissue becomes more distinct, so that finally the iris projects into the aqueous chamber irregularly, attaining a spongy appearance. In the mean time, the adhesions of the pupillary margin to the anterior capsule increase, the pupil becomes smaller and more irregular, until finally nothing more than a small, serrated, tendinous plug is seen in the center of the puffed-out and bulging iris. From this point on, the iris-tissue begins to undergo tendinous degeneration. It shrinks in spots to hard, gray striæ and flakes, whereupon the distended vessels again disappear. The vision decreases more and more down to a quantitative perception

of light. Large, tortuous, venous twigs are seen in the anterior episcleral zone, and the diminution of the resistance of the globe leaves no more doubt that the whole eye is undergoing atrophy.

In other cases, the disease begins with a severe vascular injection of the anterior episcleral zone, and with a more or less severe ciliary neurosis. The iris appears then somewhat discolored, especially when the aqueous humor is at the same time turbid, but moves quite readily, and only a few, if any, scattered papillary growths are seen on the pupillary margin, or a hypopyon is formed from time to time, with the well-known symptoms, which quickly disappear, or it varies very much in size. The marked redness and sensitiveness of the ciliary region, in connection with the subsequent flocculent opacity of the anterior peripheral portion of the vitreous, and the diminution of the peripheral acuteness of vision, depending on this turbidness, are evidences of a special affection of the ciliary body. Therefore, recently these cases have been described as pure and suppurative cyclitis (*Graefe*). The process often recedes, although the latter variety often shows itself very obstinate. But it often goes further, especially in the second form. The participation of the iris becomes plainer and plainer, until finally the symptoms of choroiditis are added, and the disease runs its course as an irido-choroiditis, in the manner already described.

The affection is in the beginning, as a rule, confined to one eye, and often remains so. More frequently, however, the second eye sympathizes sooner or later with its fellow. Undoubtedly the prevalence of similar pathogenetic conditions and of similar causes lie at the bottom of many of these cases of disease of the fellow-eye. More often, however, the sympathetic origin—that is, the transplantation of the inflammation by means of the ciliary nerves, especially by reflex action, which is transmitted from the sensitive branches of the ciliary region upon the vasomotor branches of the second eye—can scarcely be denied.

Usually material changes of the ciliary nerves, manifest inflammations of the neurilemma (*Iwanoff*), calcifications, etc., explain the conditions of nervous irritation. Sometimes, however, the ciliary nerves are found in the cases under consideration completely unchanged (*Schiess-Gemuseus, Czerny*); and we must regard irritations acting from without upon the ends of the nerves as the causes of the affection.

The transition to the second eye not uncommonly occurs very early, before the process has passed beyond the iris in the eye first attacked. Usually, however, this only happens when the diseased action in the first eye has become an irido-choroiditis. The ophthalmia of the second eye then generally bears a benign character, and exhausts itself frequently in the development of more or less numerous posterior synechiæ, which of course bring with them the tendency to further relapses.

The second eye is in much greater danger if the affection of the first leads us to suspect a marked condition of disease in the ciliary muscle, especially if it appears with a moderate collection of inflammatory products upon the posterior wall of the iris and ciliary processes; since, then, the sympathetic ophthalmia is very often, even if not always, hyperplastic cyclitis, and opens the way usually to the destruction of the other eye by the subsequent shrinking of the false membrane, the sympathetic ophthalmia may even then break out during the first attack, especially if the injurious influence which has attacked the first eye exerts and maintains a violent irritation upon the sensitive ciliary nerves, as is frequently the case—for example in foreign bodies penetrating the ciliary body, in lacerated wounds of the ciliary region, in dislocated cataracts, etc. As a whole, however, the acute forms of hyperplastic irido-choroiditis seem to exert less influence in producing sympathetic participation of the fellow-eye. The fact is, the latter much more rarely manifests itself, so long as the inflammatory process in the eye first attacked is of a sthen

character, with terrible pain, and perhaps perceptible increase of tension of the globe. But, on the contrary, it very frequently presents itself in the latter stages, especially when the globe begins to shrink under the advance of the degenerative process, and shows this by constant decrease of its tension; whilst the continual and remarkable sensibility of the ciliary region to the touch points to the existence of a chronic insidious cyclitis (*Graefe*). This cyclitis is without doubt maintained in many cases by the mechanical stretching to which the ciliary body, and perhaps also the nerves, are exposed from the shrinking of the plastic deposits, and which often leads to complete detachment of the ciliary body from the sclerotic. In other cases, however, the globe has ceased to be irritable, and the cyclitis is again set up by a new injurious influence—for example, by the wearing of an artificial eye (*Mooren, Lawson*), by intra-ocular hemorrhages (*Critchett*), etc., or by calcification of the products exuded into the structure of the ciliary body, or even in the neurilemma of the ciliary nerves (*Schiess-Gemuseus*). The second eye is most imperiled by the peculiar degenerative forms of irido-choroiditis (p. 295). The contraction of the extensive fibrous deposit is probably also here the usual exciting cause of the sympathetic affection. Still the disease of the fellow-eye not rarely appears at a time in which there can be no possibility of the existence of a degeneration of the plastic products, and a laceration of the ciliary processes produced thereby. Very often the pain is wanting, and the peculiar pain on touching the ciliary region, which is significant of degenerative cyclitis; hence there is no reason for assuming in these cases manifest irritations of the ciliary nerves as exclusive causes of the sympathetic inflammation.

In the subject of sympathetic ophthalmia there is, moreover, still very much that is obscure and remarkable. For instance, acute as well as mere insidious purulent processes in the interior of the organ very seldom imperil the second eye in a sympathetic manner, even if they ever do, although they are often connected with very marked irritation of the ciliary nerves.

Prodromal appearances very frequently precede the actual outbreak of sympathetic irido-choroiditis. The second eye shows its participation, first of all, by great sensibility and inability to bear bright light, or any straining of the accommodative apparatus. There is also temporary clouding of the field of vision, annoying sensations of pressure and tension; subsequently more frequent attacks of pain spreading all over the head, and episcleral congestions; or there may be transient marked discolorations of the iris, with complete dilatability of the pupil by atropine (*Mooren*); finally, after more frequent recurrence of these attacks, true iritis is developed with formation of synechiæ.

The sympathetic irritation of the nerves does not always, however, lead to exudative iritis, or finally to iridochoroiditis, with its further consequences. In some cases the participation of the second eye is manifested a long time merely by the most violent photophobia and complete incapacity for use (*Donders, Maats*), or by photophobia, with periodical darkening of the field of vision during from thirty seconds to a minute (*Liebreich*), or by amblyopia with concentric limitation of the field of vision (*Mooren*). Cases also occur in which a rapidly increasing amblyopia is matured by development of a glaucomatous excavation of the optic nerve (*Graefe, Horner*). The last-named condition is found relatively most frequently in older individuals, and is always connected with a marked increase in hardness of the globe. We might almost believe that it is the rigidity of the sclera which has forced the process into a simple glaucoma (p. 279). In individual cases sympathetic inflammation of the retina is said to have been caused in the second eye (*Graefe*). Finally, even epileptiform attacks have been explained by the reflex actions, which can be communicated from the diseased globe to the vaso-motor nerves of the brain (*Mooren*).

Results.—Irido-choroiditis may be cured by proper treatment, and may possibly get well spontaneously. A complete restoration of the normal condition, however, presupposes that the constituent elements of the uveal tract, and especially those of the retina, have not as yet suffered very much, and is therefore only to be reasonably expected in recent cases. Where the irido-choroiditis has already existed for some time, and besides has perhaps appeared secondarily, and is prepared for by material changes in important parts of the eye, the prospect of complete cure, and even of improvement of its functions, is only very slight. The process is more apt to lead to permanent injury of the organ.

Sclero-choroidal staphyloma is a frequent result. It occurs very readily in young persons, although it is not very uncommon in older persons. It may be developed in any stage of the process, as long as the intraocular pressure is not sunk below the normal. It often appears in the first beginning of irido-choroiditis, but more frequently in the later stages, and then generally during the inflammatory exacerbations.

The most common result is the atrophy of the entire globe. First the aqueous humor and the vitreous are lessened, the globe becomes softer, relaxed, and wrinkles under the traction and pressure of the ocular muscles, while its size is decreased; in the vitreous, connective-tissue striæ and membranes are developed as a consequence of progressive proliferation of tissue. These gradually shrink, and therefore the vitreous contracts into a smaller space, and finally has the appearance of a pedunculated shell (Fig. 43, *a*), upon which the crystalline lens and ciliary processes rest.

Fig. 42.

The retina, *b*, which is quite closely adherent to the metamorphosed vitreous, follows the latter, is detached from the choroid, becomes wrinkled, and assumes a funnel-shape. In the space which is thus made by the detachment of the retina, between it and the choroid, a watery or more consistent yellowish-red or brown fluid is collected, a so-called *hydrops subretinalis*. At the same time, or at a later stage of the disease, fibrinous-like products are separated from the choroid. This occurs chiefly in the vicinity of the optic-nerve entrance, and thus more or less extensive membranes, with beveled, often indistinct, edges are formed. By no means unfrequently, they cover the greater part, or the whole, of the inner choroidal surface, in the form of a continuous layer of varying thickness. Its structure has then always the character of more or less developed connective tissue, and contains a varying number of vessels, which are, for the most part, connected with the vessels of the proliferating or already atrophied choroid, and are apt to ossify very early.

The choroid itself, so long as the process is still in progress, appears hyperæmic, and shows all the characteristics of luxuriant proliferation of tissue. In the later stages it is generally found hypertrophied, exhibiting a vascular, relaxed, and in spots also thickened, stratum of connective tissue, in which lie a very large quantity of proliferating nuclear cells, but besides free nuclei, free pigment, fat, choloid bodies, calcareous bodies, rarely newly-formed osseous particles. (*Pagenstecher.*) The vascular walls are in places very much thickened, and often contain a great quantity of choloid bodies, or are calcified. (*Wedl.*) The surface of the choroid, so far as it is not covered by the membranes upon it, is coated by the very much thickened *lamina elastica*, upon whose surface very often numerous choloid bodies rest, together

with scanty remains of the tapetum. These sometimes reach an astonishing degree of development, so that it seems as if the choroid were thickly sown with small opaque hyaline granules. These vitreous-like bodies are sometimes so hard, that a sound is caused on drawing a hard body over them. In isolated cases they have been found pedunculated, arranged in layers internally, and partially interspersed with pigment granules, calcareous material, and angular crystals, probably of a fatty nature. (*Klebs.*)

The ciliary body and the iris, under such circumstances, are generally very much atrophied. Their posterior surface is covered, in the greater number of cases, by thick, tendinous membranes, which contain in part calcareous matter, or even osseous scales. These are by no means rarely connected with those of the choroid, and continued anteriorly up to the plug, closing the pupil. From the inner surface of this membrane numerous connective-tissue flakes and striæ run into the degenerated vitreous, or the membranes pass immediately over into a thick tendinous layer, which lays on the crystalline body posteriorly, and is a result of the thickening of the tendinously degenerated vitreous body.

The ciliary muscle is generally atrophied down to a few fiber-cells, seized with fatty degeneration, or is only a layer of absolute connective tissue, which is interspersed with nuclear formations, fat, and calcareous matter. The vessels are in the same condition with those of the choroid. The nerves are deprived of their medullary substance, or entirely destroyed, and have become unrecognizable. In case the shrunken globe is already wrinkled, the membranes follow all the irregularities of the inner scleral surface, and look as if formed by a deposition of fibrinous material, after the wrinkling of the sclerotica, out of the fluid which fills up the space between the choroid and retina. They are always perforated at the situation of the optic-nerve entrance, in order to allow the retina to pass through. In the beginning they seem quite soft, but soon become rigid, and then resemble boiled albumen or cartilage. They continue to grow after they have once begun to be developed, not only on the surface, but also in thickness, and not unfrequently reach to a very considerable thickness of from one to two lines. On a vertical section a layering is generally evident, which seems to indicate that one stratum is formed after the other. This is, besides, probable, because the layers toward the sub-retinal fluid, being the most recent, are much softer than the deeper ones, and are often still found having the consistency of a briny fluid.

The ossification of these new-formations begins from the external layers, while new connective-tissue layers are placed on the inner surface. (Fig. 44, *a*.) They proceed sometimes from one point and sometimes from many. Soon the outer strata are simultaneously and evenly ossified in their entire circumference.

Fig. 44.

In cases in which the bony shell extends forward to the ciliary process, the excavation of the vitreous humor adjacent to the posterior surface, *b*, which has been transformed into connective tissue, also ossifies, and its periphery unites with the borders of the bony choroidal shell. The result is a closed capsule, which is externally covered by the choroid, *c*, striking with its anterior wall the ciliary processes and the posterior capsule, but having a small hole posteriorly, through which the retina enters into the cavity of the capsule. This cavity varies much in size, according to the size of the globe, and according to the thickness of the new-formation, which is sometimes very great. It is filled with the fluid described above. We find the funnel or cord-shaped retina washed about by the latter in the axis of the space within the capsule (*d*), while anteriorly it is spread out, and thus covers over the posterior surface of the anterior bony capsular wall. Occasionally tuft-like, opaque, whitish-gray outgrowths are seen on the tendinous covering of the inner surface of the osseous capsular walls, which float freely in the cavity. Occasionally also we find a real open-work, *e*, of threads and membranes of the appearance of connective tissue, which extend from the inner wall of the osseous capsule to the external surface of the retina, and cross the interspace in the most different directions. These are generally structureless, but often a

distinct [illegible] d nuclear formation may be recognized in them. The gelatinous-like, innermost layer of [illegible] bony shell is sometimes in a very similar condition. The subjacent tendinous or cartilaginous strata separate sometimes from each other and form meniscoid spaces, which are filled with a fluid exactly like that of *hydrops subretinalis*. The layers are in part structureless, but partly plainly striated, and are then dispersed over the borders in fibrous bundles. In this mass, connective-tissue bodies often appear very plainly together, with a varying quantity of dark molecules, pigment granules, fat-bodies, calcareous masses, metamorphosed blood-corpuscles. In isolated cases, here and there blood-vessels are found, occasionally in such abundant quantity that the vascularity is evident to the naked eye.

The bony layers are generally very compact, and then consist of a firm, apparently structureless or fibrously-striated ground-work, in which calcareous bodies and bone-corpuscles are scattered about here and there. In other cases, especially when they reach a very considerable thickness, they appear porous, like *diploe* or the cancelated structure of the vertebræ, composed of a number of bony lines and lamina, which cross each other in the most diverse directions, or consist of a structureless connective-tissue basis and numerous scattered, interspersed bone-corpuscles. Occasionally a distin[illegible] microscopic structure is found in this new-formation, with indications of [illegible] *edl.*) The organic basis-substance often contains pigment. The osseous su[illegible] tely on the choroid. Rarely, a tendinous layer appears between the bone and [illegible] arely, the bone is devoid of the tendinous covering on both sides. The inner surface i[illegible] t to be very rough, and occasionally even serrated outgrowths appear on it. Under th[illegible] ation microscope these new-formations are seen to be exactly like ordinary bone-substa[illegible] .) Its vessels are generally connected to those of the choroid. (*Pagenstecher.*) The for[illegible] fat-cells is at times very abundant.

The changes in the retina and vitreous h[illegible] been described in another place.

These stumps often remain for [illegible] t annoying the patient in any way. They are often very devoid of sens[illegible] d bear without the least trouble a properly-fitting artificial eye. In [illegible] e stump remains very irritable, and severe inflammatory attacks very often occur, which finally lead to suppuration and perforation. Frequently there is also danger of sympathetic inflammation.

Sometimes violent flashes of light make their appearance in atrophic eyes with deposits of chalk and detachment of the retina, which last for a long time and annoy the patient to such an extent that the subcutaneous section of the optic nerve is deemed justifiable (*Graefe*).

Treatment.—The indications for treatment are the removal of the conditions that invite and maintain the inflammatory process, as well as the direct removal of the inflammation, and the accompanying disorders of circulation and of the nervous system. An especial enumeration of these would be only a repetition of what was said on iritis, the usual forerunner of irido-choroiditis. We need, therefore, only say, that when, together with a closure of the pupil, there are indications of the affection of deeper parts of the globe, the indications for iridectomy are imperative.

The antiphlogistics and mydriatics are then not sufficient to bring the process to a satisfactory termination. They may only serve as adjuvants, in diminishing the violence of exacerbations, and preparing the globe for an operation. It is not advisable to operate during a severe inflammatory attack, for reasons already given; but when a foreign body, a dislocated lens, swollen lens fragments, &c., excite and keep up a severe irritation, in consideration of the great danger every precaution of this kind should be cast aside, and the irritant should be removed. At the same time it would be well to perform an iridectomy.

A well-conducted inunction treatment is one of the best antiphlogistic means, especially when combined with the systematic wearing of a protective bandage, and when the rules laid down in neuro-retinitis are strictly carried out. This is very especially to be recommended in the existence of very dense opacities of the vitreous,

since these are apt quickly to recede under its influence. In view of this, it is often very efficaciously employed after an iridectomy, when the clearing up of the dioptric media is imperfect. Where syphilis is the origin of the process, it is well in every case to precede the operation by a course of inunction of mercury.

Where the iris appears very tense, very much disorganized, discolored, and traversed by thick vessels, from dense tendinous neoplasia which lie on its posterior surface, the performance of an iridectomy is quite as difficult.

Not unfrequently it can not be done at all, because the iris can not be seized by the forceps, or it tears in shreds, while the neoplasia remain behind. But if we succeed in making an opening in the neoplastic membrane and the iris, the success is generally very slight; the attacks of inflammation and ciliary neurosis are repeated, and lead finally to the loss of the eye, perhaps also to destruction of the globe. In such cases, according to recent experience, it seems advisable to combine the iridectomy with extraction of the lens. Regard for the latter need not cause us to be restrained from this procedure, for it is generally cataractous. But the fact should not be overlooked that this is a more formidable operation than the simple iridectomy, and that the danger of a severe inflammatory reaction is much greater. In general, therefore, the operation is scarcely adapted to those cases in which we wish to prevent a sympathetic affection of the other eye. If the ciliary region is very sensitive to pressure, we should strictly avoid the method in question. It is much more advisable to enucleate the eye. Iridectomy, combined with extraction of the lens, does the best, when the other eye has already lost its functions, and requires no more consideration where there is no kind of irritation present, and the whole idea of treatment concentrates in the replacement of a moderate degree of vision of one eye.

Where the symptoms of a cyclitis connected with the formation of plastic deposits present themselves distinctly in one eye, therapeutic procedures should have reference chiefly to the second eye, particularly if the globe first affected is already incurably blind, and if the prodromal signs of the sympathetic affection of the other eye are already manifest.

The most certain procedure is the immediate enucleation of the eye, provided that the inflammatory process does not have a predominantly sthenic character, or is generally accompanied by violent vascular and nervous symptoms. In such a case we do better to limit ourselves at first to a purely antiphlogistic treatment, and to try the warm poultices mixed with narcotic agents (*Mooren*), recommended so strongly by many persons, in order at first to break the intensity of the process.

According to experience the enucleation meets with relatively the greatest success when performed during a complete remission of the inflammatory process (*Critchett*).

Iridectomy upon the eye first attacked is in such cases certainly insufficient to put a stop to the sympathetic affection of the other eye; we even run the risk of causing its appearance by kindling up a cyclitis in the operated eye, or at least of favoring it. On the contrary an iridectomy may be of use upon the second eye, if the prodromal symptoms of the sympathetic affection are already present there, since it perhaps aids in keeping the process in a milder form. It will therefore be well to make the corneal section as peripherical as possible, and the artificial pupil very wide, in order not to allow the subsequent contraction of the latter to cause complete closure. If however the process in the second eye should advance accompanied by only moderately violent vascular and nervous

symptoms, the iridectomy is dangerous and is at any rate to be postponed un we have succeeded by appropriate antiphlogistic means in stopping the proce or at least in obtaining a complete remission.

Recently section of the ciliary nerves inside the eye has been proposed as a substitute fo enucleation (*Graefe*). This may as well be performed intra-ocularly by means of a fin neurotome, as by dividing diagonally for a short distance all the coats of the globe in th equatorial region from without by means of a fine knife. This operation has already be repeatedly performed with favorable results (*Ed. Meyer*, *Laurence*, *Secondi*), but is unreliab (*Critchett*, *Mooren*), leads in half the cases to phthisis bulbi (*Ed. Meyer*), and succeeds onl in those cases in which one or the other bundle of ciliary nerves is manifestly irritated, an the second eye is becoming involved; it must, however, necessarily fail where the ciliar body is completely involved in the cyclitic process, and where this is indicated by the sens tiveness to palpation at every single point of the anterior scleral zone.

Repeated paracentesis of the anterior chamber is still less to be recommended (*Dobrowolsky*) The same would hold good of the suppuration of the eye artificially induced (*Graefe*), fo although suppurative processes do not easily induce sympathetic affections of the second eye still the increase of a cyclitic process already present, and threatening the second eye must be regarded as hazardous in a high decree.

If, however, we should desire to produce by enucleation the greatest possibl result, it will be well not to wait for the premonitory symptoms of sympathetic ophthalmia, but to proceed with the operation as a prophylactic means, when the chronic insidious cyclitis has already indubitably manifested itself in th one eye by the peculiar painful feeling under palpation, by commencing softenin of the globe, and other symptoms.

At any rate the operation comes too late if the sympathetic affection in th second eye is already fully underway; for here the enucleation has from experienc little or no influence upon the cyclitic process in the second eye, which advance independently, and the result is limited solely to the lulling of the existing hyperæsthesiæ in the sensitive parts of the ciliary region (*Critchett*, *Graefe*).

We should moreover reflect, before proposing this exceedingly painful opera tion and one which detracts so much from the personal appearance, that its succes is by no means completely assured, even when undertaken under apparently th most favorable circumstances; that sometimes the sympathetic ophthalmia i the second eye breaks out in spite of the enucleation having been performed a the proper time, and constantly advances (*Mooren*, *Sichel*, *Ainsiaux*, *Testelin*); tha on the contrary, however, the sympathetic affection of the second eye, in spite o the omission of the operation, is developed in by no means every case, even when the case furnishes all the necessary indications, and that, when it occurs, the oph thalmia often appears in the mildest form, and exhausts itself in the formatio of posterior synechiæ. We should never lose sight of the fact that the subject o sympathetic ophthalmia contains much that is obscure, and scarcely allows of an very precise rules being laid down.

The most difficult cases in which to lay down specific rules for treatmen are those in which there is the peculiar degenerative form of irido-cyclitis (p. 295) Here we may justly call in question the advantages of enucleation. At any rat the enucleation of the eye first attacked is of very little use when the second ey

[NOTE BY EDITORS].—Where any doubt of a favorable termination exists, no matter ho slight, enucleation should be immediately performed, as affording the best chance for th fellow-eye.

is already distinctly involved in the process. This, however, participates as a rule very early, and generally long before the process in the first eye has reached complete and incurable blindness, and therefore long before its operative removal is justified. We can then protect the second eye when it begins to be affected perhaps better by the immediate formation of a very wide artificial pupil made posterior to the sclero-corneal margin (*Graefe*). Still in such cases the iridectomy is an operation by no means devoid of danger. The degeneration of the vessels favors very profuse hemorrhages, which rapidly fill the whole anterior chamber, and, as fast as the chamber is emptied, return, since the vessels can not contract.

These exudations are always of a pronounced venous character. They are absorbed with difficulty, since, in the same measure as the serum of the blood is absorbed, new blood always pours out from the torn or cut ends of the vessels now entirely incapable of contraction. If, however, the hemorrhage ceases, large coagula still remain behind, which, together with the products of the inflammatory reaction, become dense, deeply pigmented plugs, and always close up the pupil, even if a large one was made, which seldom happens, owing to the extreme rottenness of the structure. The final result is therefore usually *nil*, and often an aggravation of the condition. Every new trial increases the dangers, until finally the atrophy of the globe shows itself unmistakably.

On the whole, in such cases of degenerative irido-choroiditis the results are quite as good if we limit ourselves to an appropriate antiphlogistic procedure, and wait patiently the results, in order then to proceed to an operation if necessary. It is scarcely prudent to risk the operation before the inflammatory products have become firmly consolidated. So long as they are still soft and highly vascularized their destruction is very possible, but by no means the formation of a broad and permanent opening, without regard to the fact that by the operative procedure the inflammation is again violently kindled, and by the accompanying hemorrhages is maintained in its destructive tendencies.

Authorities.—*Graefe*, A. f. O. I. 1. S. 402; II. S. 202, 210, 218, 220, et seq.; III. 2. S. 337, et seq.; IV. 2. S. 150, 152; IX. 2. S. 105, 109; kl. Monatbl. 1863, S. 447, 449, *Graefe* und *Schweigger*, A. f. O. VI. 2. S. 116, et seq.—*Secondi*, Clinica oc. di Genova. Riassunto. Torino. 1865, P. 29—*Ammon*, A. f. O. I. 2. S. 119, 124, 127.—*Hirschler*, Wiener med. Wochenschrift, 1865, Nr. 91, 92.—*Frank* und *Streatfield* nach Hirschler.—*Sämisch*, kl. Monatbl. 1866, 111, 113, 115.—*Haase*, ibid. S. 255.—*Stellwag*, Ophth. II. S. 143, et seq.—*Arlt*, Die Krankheiten des Auges. Prag. 1853, II. S. 71, Zeitschrift der Wien. Aerzte. 1859, S. 149, 151.—*Businelli*, ibid. S. 203, 264.—*Tetzer*, *Rydl*, ibid. Jahrb. 1866, 4. S. 27, 30, 31.—*Critchett*, kl. Monatbl. 1863, S. 440, et seq.—*Donders*, ibid. S. 448.—*Liebreich*, ibid. S. 450—*Horner*, ibid.—*Pagenstecher* und *Sämisch*, kl. Beobachtungen, Wiesbaden, 1861, I. S. 21, et seq.—*H. Müller*, A. f. O. IV. 1. S. 364, et seq.; Verhdlgen. der. Würzburger phys.-med. Ges. 1858, 8. Mai d.—*Pagenstecher*, ibid. VII. 1. S. 99, et seq.—*Klebs*, ibid. XI. 2. S. 235, 237, 240.—*Wedl*, Atlas Iris-Chor., Sitzungsberichte der Wiener k. Akad. d. Wiss. 48, Bd. S. 384, et seq.—*Maats*, Zesde Jaarlijksch Verslag. Utrecht, 1856, S. 25, et seq.—*Graefe*, A. f. O. XII. 2. S. 149-171; XIV. 3. S. 139; Congrès Ophth. 1867, S. 59.—*Secondi*, Di una neurosi simp. Torino. 1868.—*Knapp*, Arch. f. Aug.- u. Ohrenheilkd. 1. S. 13.—*Critchett*, Congrès Ophth. 1868, S. 138.—*Testelin*, *Sichel*, *Ainsiaux*, ibid. S. 139, 141.—*Blessig*, ibid. S. 114.—*Pagenstecher*, kl. Beobachtungen, Wiesbaden, 1861, 1. S. 21; II. S. 44-94.—*Sämisch*, kl. Monatbl. 1869, S. 309.—*Dobrowolski*, ibid. 1868, S. 239.—*Hirschberg*, ibid. 1869, S. 297.—*Rudnew*, Virchow's Arch. 45 Bd. S. 197.—*Haynes*, *Walton*, Lancet, 1868, II. S. 13-16.—*Lawrence*, ibid. S. 633.—*Schiess-Gemuseus*, A. f. O. XIV. 1. S. 85-92; Mooren's Symph. Ophth. S. 131.—*Mackenzie*, ibid. S. 5; Traité d. mal. yeux.—*Ostlander*, A. f. O. XV. 2. S. 108.—*Berlin*, A. f. O. XIII. 2. S. 308.—*Czerny*, Wien. Augenkl. Ber. S. 178.—*Lawson*, Ophth. Hosp. Rep. VI. S. 123.—*Iwanoff*, Mooren's Symph. Ophth. S. 164, 166; A. f. O. XV. 2. S. 8, 9, 26.—*Colsmann*, kl. Monatbl. 1869, S. 149.—*Ed. Meyr*, ibid. 1868, S. 380; Virchow's Jahresber. 1868, S. 493; Congrès Ophth. 1867, S. 135.—*Mooren*, klin. Monatbl. 1868, S. 393; Ophth. Beobacht. S. 141, u. f.; Ueber Symph. Ophth. Berlin, S. 12, 24, 36, 59, 143, u. f.

2. Glaucoma.

Symptoms.—*These comprehend the sensible increase of hardness of the globe, the ophthalmoscopic appearances of excavation of the optic nerve, the symptoms of hyperæmia and inflammation, as well as a great variety of disturbances of vision.*

1. The hardness of the globe is best perceived by the sense of touch, by placing the index-finger of each hand on the inner and outer side of the anterior half of the eye-ball, the lids being closed, and making slight pressure toward the center of the eye. The instruments devised for this purpose, *tension measurers, ophthalmotonometer* (*Hamer, Don*), by no means answer the requirements which may be reasonably demanded.

In the greater number of cases the increase of resistance is exceedingly marked; the globe often feels quite as hard as bone or wood. From this extreme, the hardness descends by various gradations to those degrees which may be, not unfrequently, found in normal eyes. It frequently even varies in the same eye, within large limits, at one time increasing, at another decreasing. Its amount is decided as well by the greatness of the resistance which the capsule of the globe offers to its distention, as from the amount of the intraocular pressure. This latter is very changeable in glaucoma, since it depends considerably on the intravascular lateral pressure, and this is influenced here, as in other places, by a variety of circumstances. Especially in inflammatory episodes of glaucoma, and congestive conditions, whether they depend upon mechanical grounds or proceed from the vasomotory nerves, there is almost always very great increase of the intraocular pressure, and consequently resistance of the eye-ball.

Where one eye is still normal, the difference in that and the affected one shows how much of the hardness of the latter is to be ascribed to the increase of intraocular pressure, for then it is more than probable that the other element of the resistance of the globe, the rigidity of the capsule, has been extended on both sides to the same degree. But where the other eye is glaucomatous, or in any other way affected, such a comparative test can not easily estimate the increase of internal pressure. It would, even, often be impossible to show an increase of intraocular pressure, were there not united with it certain symptoms which have characteristics enough to allow us to come to a conclusion. Among these are: very decided pulsation in the central portion of the retinal vessels; narrowing of the aqueous chamber; dilatation, sluggishness, or complete rigidity, of the pupil, limitation of the accommodation, and, often, decrease in the refraction of the dioptric apparatus; finally, anæsthesia of the cornea.

The pulsation appears principally in the veins (p. 4), and in fact it is always either the one or the other main trunk which nearest the porus opticus shows the peculiar rhythmical filling and emptying (p. 172). In the acute and sub-acute forms of glaucoma it may also usually be demonstrated in several of the arteries, whilst in the simple non-inflammatory glaucoma spontaneous arterial pulsation is usually wanting and can only be produced by a pressure upon the globe.

The narrowing of the aqueous chamber brings the increase of the fluid of the vitreous immediately to our perception. This plays an important part in the increase of pressure. In the first stages of the disease this is not always very distinct, but in the advance of the process, the iris and lens are always pressed forward, and finally the chamber is entirely removed, since, with the atrophy of the anterior uveal portions, the sources of the aqueous humor are exhausted.

The increase of the intraocular pressure is most plainly indicated by the impairment of the mobility of the iris. The pupil becomes somewhat wider, and reacts very sluggishly, or not at all, to light. This symptom is never absent where an increase of the intraocular pressure really exists, but it may be wanting where the hardness of the globe is to be ascribed to resistance of the sclerotica. In the advanced stages of the process the iris is generally reduced to a small border. The mydriasis is of the highest degree, except when in the course of the glaucoma an iritis has been developed, which has left adhesions of the pupillary margin.

The diminution of the refractive power of the dioptric apparatus is a necessary result of the flattening of the cornea, and this again is the result of the attempt of the capsule of the globe, with its increased tension, to approach the spherical shape. In very marked increase of the intra-ocular pressure, the effect of this mechanical agent may be often recognized as the immediate effect of the abolition of the ridge, which the corneal border forms with the anterior boundary of the sclera. The limitation of the range of accommodation may be explained by the pressure, and perhaps also by the stretching which the ciliary nerves in the interior of the globe must suffer under the circumstances in question. But it is only a rapid loss of this which may be ascribed to increase of intra-ocular pressure, since *gradual* lessening of the refraction and of the range of accommodation very frequently precede glaucoma, and are the symptomatic expression of senile involution, which, as it were, prepares the way for the whole process, and finds, as is well known, the most favorable footing in the crystalline lens (*Schelske*, *Haffmans*).

Anæsthesia of the cornea is only present, as a rule, when there is very considerable increase of the intra-ocular pressure. It is not always evenly developed in the various parts of the cornea, and varies in degree very much. Often the want of sensitiveness of the cornea in completely developed glaucoma is so great, that touching the part with the finger or a feather is scarcely perceived. Like the impaired mobility of the iris and of the muscles of accommodation, this is for the greater part to be ascribed to the effect exercised upon the nerves. In the later stages material changes in the nerves, and the affected parts themselves, may act as causes (*Graefe*).

2. The glaucomatous excavation is chiefly shown by the ophthalmoscope, by the bending of the retinal vessels on the outermost border of the optic-nerve entrance, by a lateral displacement of the point of exit of the vessels, and by the papilla being encircled by a bright, light ring (*Ed. Jaeger*).

In partial excavations we notice only a deviation on each vascular twig, which passes out of the excavated portion of the optic papilla. It passes over the peripheral portion in an acute arch, or appears actually bent. (*Chrom. lith.*, P.) The remaining twigs reach in a straight direction over the edge of the papilla toward the porus opticus, which is often plainly distorted, being inclined toward the inner border of the optic-nerve entrance.

If the excavation be already complete, but not far advanced in its development, we find all the retinal branches on the edge of the nerve-entrance curved back-

ward, but not yet interrupted. We may see them all at once, in their entire length, up to the laterally displaced porus opticus.

On the contrary, in fully-developed flask-shaped excavations (*chrom. lith.*, Q), the vessels appear sharply cut off on the outermost border of the papilla, and in case they pass over in an oblique direction, we find them beak-shaped, since the curved extremity of its long axis comes in sight, and appears generally of a dark-red color. If the central vessels lying in the papilla are present, they appear displaced from the side toward the branches, which are bent over the edge of the excavation. But if the mirror be so turned that the affected portion of the lateral wall of the excavation is seen, we may often easily recognize the twig uniting the vessels running down on the side, but covered by the overhanging border, by holding the mirror directly before the eye.

The central portions of the vessels present themselves, especially in the first stages of the process, often in a very clear and distinct image. The arteries are of normal diameter or somewhat narrowed; the veins, on account of pressure, are decidedly broader, and frequently woven over by a net-work or convolution of small, frequently anastomosing collateral branches. In the further course of the disease, on the contrary, some or all of the central twigs become gradually paler, and appear veiled over by a more or less opaque, grayish tissue. Isolated central branches finally disappear entirely. We find in the excavation only one or more vascular twigs, which, considering their abnormal direction, may be considered as collateral, and are generally venous. Often all the vessels recede from the porus opticus, which has been displaced laterally. The excavated optic-nerve entrance appears completely deprived of vessels, and all the retinal vessels seem sharply cut off on the edge of the papilla.

The excavation itself, when fully developed, gives, on examination with the ophthalmoscope, the impression of an elevation instead of a depression. This is a deceptive appearance, due to the refraction (*Ad. Weber*). Still we recognize its concavity by the form of the shadow. (*Chrom. lith.*, P, O.) The breadth and darkness of this always falls to the side from which the light comes; accordingly it changes its appearance with the position of the ophthalmoscope. This shadow is ring-shaped, more or less broad, and surrounds the porus opticus, which is generally very markedly pressed inwards at a greater or less distance. It is always indistinct on its central border, but sharply bounded toward the periphery of the excavation.

Where the glaucomatous excavation is developed on a papilla, which has also a congenital excavation, we may often, in the early stages, distinguish both forms. We observe quite distinctly the double sinking-in of the optic-nerve entrance, especially the double distortion and displacement of the vessel. Subsequently the congenital excavation becomes more indistinct, and is lost in the complete excavation (*Ed. Jaeger*).

The color of the optic-nerve entrance inclines in the beginning to red, on account of the existing venous congestion, or, in consequence of abundant extravasations, to a blood-red. Later on, the color runs into a gray or a grayish blue, on account of progressive atrophy of the nerve-elements. Sometimes it inclines to green or a tendinous white; sometimes the floor of the excavation is spotted with a dirty gray-yellowish color.

A light yellowish-white arch or ring (*chrom. lith.*, Q), which encircles the excavated optic-nerve entrance, is very characteristic. This is the more distinct and

broader the more the excavation is developed, and the further advanced is the atrophy of the parts.

Recently it is said to be established by pathological investigations, that the border in question is caused by complete atrophy of the choroidal ring surrounding the papilla; and a further point of origin is found in the great tension and stretching of the quite large fibers which sometimes reach from the choroid ring to the lamina cribrosa (*Schweigger*).

3. The congestion in the inner vascular region is made evident by the great enlargement of the anterior ciliary venous twigs. We observe a great number of dark, swollen vessels suddenly bursting forth from the sclerotica on the anterior aspect of the globe, which pass over its equator with a tortuous and anastomosing course. A high degree of tension increases the number and the caliber of the distended veins. The hyperæmia is especially marked during the inflammatory attacks. Then there appears a finer vascular net-work, forming a sort of vascular ring about the cornea, which betrays its venous character by its bluish or brownish color, and is not unfrequently accompanied by an œdematous swelling of the surrounding tissue and of the conjunctiva. In the later stages of glaucoma, where the degeneration in the inner parts of the eye and in the walls of the vessels is already far advanced, the collateral branches generally preponderate, the episcleral tissue appears every where traversed by much-enlarged venous twigs, part of which come directly from the vessels of the anterior scleral zone, loop into large meshes and irregular arcs, and posteriorly unite in largely-developed trunks. They then run in the most varied directions toward the equator of the globe. Very often these congestions lead to hemorrhages, both in the internal parts of the eye and in the episclera, especially when they are suddenly increased by a rapid change in the amount of intra-ocular pressure.

4. The glaucomatous inflammation is evinced, apart from the accompanying episcleral inflammation, chiefly by a greater or less yellowish-gray or gray-diffuse opacity of the vitreous, of the cornea, and the aqueous humor. When the inflammatory process is very severe, this is often so considerable, that the iris appears enveloped in a thick cloud, and the examination of the fundus of the eye is impossible. On the recession of the inflammation, this opacity is greatly lessened, the cloud over the fundus becomes thinner and thinner, and finally allows the boundaries of the individual parts to glimmer through, or even completely disappears, so that we see clearly with the ophthalmoscope. We do not find any special ophthalmoscopic evidences of serous choroidal inflammation. The cloudiness of the dioptric media, in connection with the dilatation of the pupil, causes a peculiar grayish-blue or grayish-green reflex from the fundus. This reflex, coming from the depth of the globe, was formerly regarded as the chief symptom of the disease, and from it the process was called "glaucoma, green cataract." It may, however, be absent, and is only then remarked when decided dilatation of the pupil has occurred, and hence can not be recognized as a pathognomonic symptom.

It is, moreover, only an increase of the reflection perceived in mydriasis, irideremia, &c., and this increase results from the cloudiness of the dioptric media. In this regard, cloudiness of the aqueous has a particular, direct, determining influence, as the results of paracentesis corneæ show with certainty. The bluish cloudiness of the fundus is changed to a grayish green by the *senile* gilding of the nucleus of the lens. The gray cloudiness of the vitreous, also, decidedly increases the intensity of the reflected light, and the not unfrequent yellow color of this part doubtless increases the cause for the reflections appearing yellow or greenish.

5. Disturbances of vision are particularly noticeable in glaucoma. They are usually very marked from the commencement. In the acute inflammatory form, it even not unfrequently happens that vision is reduced to quantitative perception of light in a few days, or even hours. In the great majority of cases, however, a gradual loss of vision is observed. Then, at first, the patients often complain only of a disturbing *indistinctness* of the impressions (especially when small objects are looked at), which can not be entirely removed by neutralizing the existing anomalies of accommodation or refraction, but may be lessened by stronger and more suitable illumination of the objects, as well as by bringing them nearer to the eye, that is, by increasing the visual angle. Gradually the indistinctness of the perceptions increases. In ordinary daylight a more or less thick fog lies over the visual field; but with artificial illumination, a light placed in a dark space appears surrounded by a halo, which often gives all the colors of the rainbow, and this in such a way that on the outer side, greenish blue, on the inner, red, is in excess. (*Haffmanns.*) The fog thickens so that it actually envelops objects, or the visual field darkens to such an extent that going alone becomes impossible; even the qualitative perception of light entirely ceases.

Before it attains this point, limitation of the visual field, as a rule, manifests itself. This begins almost always at the inner side of the monocular field of vision, and its boundary extends like the chord of an arc. Gradually, or suddenly, with temporary increase of central disturbance of vision, this boundary-line advances to the middle of the visual field, while simultaneously the two ends at the upper and lower periphery of the visual field progress outwardly and finally unite, so that the field of vision appears contracted from all sides. The further reduction of the field of vision is then very exceptionally concentric; as a rule, it is contracted to a small slit, whose direction is almost always diagonal, and in which more or less clear perceptions are still possible. Sooner or later this remainder of retinal sensibility also disappears, and absolute amaurosis occurs (*Förster*, Fig. 45).

Fig. 45.

Often enough, however, limitations of the visual field are entirely absent (*Laqueur*), the diminution of the acuteness of vision is everywhere quite proportional; or there occur very irregularly, more or less sharply-defined defects in the field of vision (*Graefe*, *Landesberg*).

The cause of haziness in the vision is doubtless intimately connected with the opacities of the dioptric media, as it usually increases and diminishes, and even disappears with the latter. In the same way the brightness that is to be seen around a light in a dark place, is to be imputed to the opacities; it is a purely *physical* phenomenon, which probably depends on interruption of the rays. The arrangement of the various colors points to this. Inasmuch as the ring of colors disappears if the pupil is contracted, or the patient looks through a small hole, it is to be supposed that the rays passing through the peripheral parts of the media participate most in the deviation caused by the interference (*Haffmanns*).

The perception of smoky cloudiness of the visual field, and especially actual darkening of the latter, are, on the contrary, the expression of an actual disturbance of the retina and optic nerve. They are partly to be ascribed to the material changes of the tissue of the optic nerve and retina. They are partly, however, to be referred to increase of the intra-ocular pressure. It is certain that such darkenings may be artificially excited in a normal condition, if the tension of the sclerotica is elevated to such a degree by external pressure, that the arteries

begin to pulsate. On the other side, this view is supported by the fact of the influence which the relaxation of the tension of the capsule exercises upon the impairment of vision.

It appears that the increase of resistance which the arterial blood meets with on its entrance into the interior of the eye, is the proximate cause of these obscurations of the field of vision, inasmuch as by it a retardation of the capillary current, and therefore of the assimilation, is necessarily produced. Such disturbances established in a mechanical manner may probably lie at the bottom of those cases of complete blindness occurring often very rapidly in the course of acute glaucoma; for here neither an excavation nor any other material change can be demonstrated in the commencing stages of the process from which the absolute blindness could be inferred.

The limitations of the field of vision are in part certainly a consequence of the laceration and bending of the nerve-fibers in the region of the excavation. The *regular* limitations can be explained from the circumstance, that the nerve-fibers running in great bows to the *periphery* of the retina, seem to pass through the *middle* of the lamina cribrosa, and therefore exactly in that part which experiences the greatest distortion and stretching by the excavation, whilst the fibers of the optic nerve going towards the *macula lutea*, at least those near the eyeball, are probably situated on the extreme periphery of the nerve trunk, and hence suffer proportionally little by the yielding of the lamina cribrosa (*Leber*). Still this hypothesis does not suffice to explain the many deviations in the form and position of the defects of the field of vision. Still other circumstances must act in connection. This is particularly true of the very irregular sharply-defined interruptions. According to later investigations it appears that the extravasated products connected with the stoppage of venous circulation, which detach the layer of rods and cones from the superjacent retinal layers, and which are adherent to the choroid, reminding us of the exudative forms of retinitis, play an important part in the formation of those defects (*Graefe*, *Leber*).

The limitations of the visual field and the final amaurotic blindness are the results of the tension and degeneration of the nerve-filaments in the excavation, as well as of the gradual progress of the atrophy within the globe, and of the optic nerve. It is remarkable that, with already existing amaurosis, the patient is often deceived about the state of his eye, by subjective illumination of the visual field. At certain times of day, or on certain regularly returning days, he sees the entire visual field in a bright whitish-yellow or bluish light, and is only too much inclined to consider this as an objective perception. This deceptive sensation is the expression of the inflammatory excitement, in which the elements of the optic nerve are maintained by the glaucomatous process gradually progressing in them in a centripetal direction. Since this progress is, as a rule, slow, the patient often counts his bright and dark days, after the globe has long been hopelessly atrophied.

6. The symptoms occurring with glaucoma are chromopsia, photopsia, and pain. These are very inconstant, and may vary in all possible degrees of intensity. Appearances of sparks and colors are partly connected with disturbances of circulation, and are decidedly increased by increase of the latter. Pain may be absent throughout. In inflammatory glaucoma, however, it is often very severe, occasionally even excessive. It often radiates in various directions. Maddening headaches, especially, are common accompaniments. Sympathy of the stomach also often shows itself, and in some cases nausea and vomiting are observed.

Etiology.—Pure glaucoma develops itself as a rule only in eyes which have a stiff, rigid sclerotic. Such an unyielding capsule offers the most favorable ground for congestion in the internal circulation, and this increase of the intraocular pressure is the actual nucleus of the affection. A rigid capsule exercises on the one hand a much slighter regulatory influence upon the circulation in the interior of the eye, and on the other it renders the dilatation of the emergent vessels difficult, when an increase of the effective arterial lateral pressure demands the acceleration of the venous blood (p. 2, 4). In addition to this it

occurs, that according to every probability the rigidity is not uniformly developed in all parts of the sclerotic, but is concentrated in its external layers. In fact not the slightest increase of circumference can be demonstrated in glaucomatous eyes, which have been for a long time of a bony hardness; some indeed have claimed to have recognized rather a diminution in diameter, and trace it back to contraction of the sclerotic in consequence of fatty degeneration (*Coccius, Cusco*). On the contrary a very great distention of the cribriform fascia is seen in the excavation, and in the development of the ring of connective tissue a considerable tearing and displacement of the posterior zones of the inner scleral layers which stand in direct connection with the cribriform membrane. The very great distention of the cribriform membrane induces necessarily a partial narrowing of its interstices and with this a drawing together of the separate main trunks of the retinal veins, while their bending in under the wall of the excavation easily leads to compression of those nutrient vessels which are immediately connected with the region of the choroidal circulation. It is also easy to imagine that the laceration and displacement, which the posterior zone of the internal scleral layers undergo, causes a diminution in caliber of the *venæ vorticosæ*, which enter very obliquely through the sclera at the equator. We therefore find that the excavation itself is a cause of the congestion, and thus cause and effect maintain and increase each other alternately. If however the congestion exists for a length of time, obstruction and permanent obliteration of single emergent vessels, with or without the aid of inflammatory infiltrations, which is of so much the greater consequence, as their number is very limited, the congestion becomes then a permanent one, the natural means of exit do not any longer exist, venous blood continues to flow off by collateral channels, even when the original causes of congestion have long since disappeared, and the globe, having atrophied, has become shrunken and soft. The rigidity of the capsule of the globe is quite common, and is pretty frequently hereditary in many families, even in races—for example, the Jews. The predisposition is the only thing that is congenital, but is wont to develop itself very rapidly with advancing years. To this predisposition is due the very early appearance of glaucoma, the development of which occurs between the twentieth and thirtieth years, or even during childhood. As a rule, however, the loss in elastic extensibility is to be referred to the senile change of the capsule of the globe, and, as a result of this, glaucoma is also a disease pre-eminently of advanced life, and occurs usually after the fiftieth year. The intimate relations which can very frequently be demonstrated between the rigidity of the sclera and atheromatous processes in the walls of the vessels, explain the remarkable etiological significance, which has been from of old attributed to gout.

Where the rigidity of the sclera appears as an habitual state, material changes should certainly be absent in the tissue of the sclerotica. In other cases similar processes to those in the *arcus senilis*, and the atheromatous degeneration of the vascular system, may be at the bottom of it, so much the more that such conditions are almost constant accompaniments of glaucoma. The microscope has proved a fatty degeneration to be the proximate cause (*Coccius*). It appears however, according to chemico-microscopical investigations, that it is a question rather of chalky deposits than of the formation of fat (*Donders*).

Statistics lead us to believe that the eyes affected by glaucoma are in a very large percentage hypermetropic, scarcely a fourth myopic in a low degree, and only very exceptionally, if ever, highly myopic (*Laqueur, Rydl*). It appears that in a hypermetropic structure of the eye, the greater thickness of the sclerotic increases its unyielding properties; the fact

may also be of importance, that in eyes of smaller circumference the same amount of lateral pressure is distributed upon a smaller number of component parts; the tension with the same intra-ocular pressure will therefore be greater than in eyes of more considerable size.

If the rigidity of the capsule of the globe has reached a certain height, the slightest shock suffices to cause the glaucoma to break forth. It is therefore very usual that the exciting cause remains entirely unobserved by the patient, and the affection develops itself apparently spontaneously.

In many cases general disturbances in the circulation—for example, temporary increase of the cardiac pressure or slight obstructions in the region of the superior vena cava—may be the proximate cause, since they propagate themselves to the internal vessels, but can not be compensated for rapidly enough on account of the abnormal relations, and hence remain permanent.

In other cases, however, there are certainly purely local disturbances in the circulation, which give rise to glaucoma. Still the slight compensatory increase of contents of the choroidal vessels after violent action of a mydriatic is sometimes sufficient to induce the glaucomatous process in eyes predisposed to it (*Graefe*, *Haskel*, *Derby*).

Most usually, however, paralyses of the vessels may be brought into account, which are excited in a reflex manner by the ciliary nerves in the region of the internal circulation, and by means of the dilatation of the caliber of the vessels are in a position to produce as well an increase of the effective lateral pressure in the arteries, as a retardation in the rapidity of the venous reflux.

At any rate, irritations of the trigeminus, and particularly of the sensory ciliary nerves, play an important part in the etiology of glaucoma. On the one side, namely, neuralgia of the fifth nerve has already been repeatedly demonstrated as the proximate cause for the occurrence of glaucoma (*Wegner*, *Hutchinson*, *Hippel*, *Grünhagen*); on the other side, however, external injuries and various kinds of inflammations which may cause irritation of the ciliary nerves usually act as evident exciting causes of the affection. Moreover, it is an undisputed fact, that wounds and inflammations which in themselves, or by their consequences, can excite irritated conditions in the ciliary system, and maintain them for a long time, lead tolerably frequently to increase of intra-ocular pressure and to excavation of the optic disk in eyes not previously disposed thereto, and generally to conditions which have much in common with true glaucoma, and therefore, as regards their origin, should be classed as secondary glaucoma.

This influence which the sensory ciliary nerves, under diseased conditions, may exert upon the intra-ocular pressure, has been claimed as evidence of the secretory nature of the glaucomatous inflammation. Besides the objections already mentioned, and the results of new physiological investigations instituted with improved instruments (*Adamük*), the fact may, however, be brought to bear against the view that glaucoma is dependent upon a kind of secretory neurosis, that the increase of tension in the disease under consideration lasts for months and years, presupposes, therefore, a pathogenetic cause acting for an equal length of time. A venous congestion in connection with the continuously acting blood-pressure may be well considered as such a cause, but scarcely a nervous irritation.

Among the pathological conditions which are connected most frequently with glaucomatous increase of tension and with excavation of the optic disk, we may include anterior synechiæ, old pannus, as well as dense, extensive, and deep

corneal cicatrices, particularly when they tend to progressive *ectasiæ;* further, numerous and wide posterior synechiæ, particularly after complete closure of the pupil; oblique positions of the lens on account of partial attachment of the capsule to ectatic corneal cicatrices, or on account of unsymmetrical stretching of the ciliary body in staphylomatous formations of the anterior half of the globe, or by reason of partial rupture of the zonula, in the latter two cases by preference, when the crystalline lens oscillates, and consequently causes mechanical injuries to the posterior surface of the iris and ciliary body; injuries of the capsule of the lens, in so far as they cause a swelling of the lens substance, its projection through the wound in the capsule, and by these means a pushing forward of the iris.

These conditions, it is true, may exist as a rule for a very long time, particularly when they affect the young, without any signs of secondary glaucoma making their appearance. In the mean time, the older the person becomes, and the more quickly the senile changes are developed, the disposition becomes so much the greater, slighter shocks so much the more easily suffice to produce permanent venous congestion. Moreover, the glaucomatous affection appears sometimes also under such conditions in individuals, where there is properly no senile change, and where the normal hardness of the second eye does not admit of presupposing a habitually rigid sclera. We must, therefore, assume either that conditions for permanent venous congestion lie in the paralysis of the vessels themselves, or that secondary changes of the sclera prepare the way for the glaucomatous process.

The peculiar porcelain-like appearance of the sclera of the eye really points in not a few cases of secondary glaucoma to sclerosis, and this can be deduced logically from the frequently returning and obstinate attacks of intra-ocular inflammations, to which the conditions above mentioned are in a high degree disposed. In other cases the inflammations lead, primarily at least, to relaxation of the scleral tissue as well as of the cribriform membrane, further on, however, to staphylomata of the sclera, and to excavation of the optic disk. In these ectasiæ, however, under certain conditions, we may find a source of permanent diminution or entire obliteration of certain individual vessels, which so much the more easily produce venous congestion, as this is still often favored by the subsequent sclerosis of the atrophic sclerotic tissue. In such a way may be explained the exceptional occurrence of glaucomatous increase of tension and excavation with posterior scleral staphylomata, particularly such as are connected with extensive sclero-choroiditis, without, however, the possibility of certain habitual dispositions being excluded, since such conditions have become hereditary in many families (*Graefe*). Finally it is evident that inflammations with moderate exudations, exactly like results of choroidal inflammation, occasion the mechanical closure of separate venous trunks, especially when the products infiltrate the scleral tissue in larger quantities, without destroying its resistance to the intra-ocular pressure.

Spontaneous retinal hemorrhages are an etiological source of great importance, as they occur sometimes in old persons with a tendency to apoplexy of the brain. These occur usually in large number in the neighborhood of the papilla and macula, form generally small masses, and very soon unite under appearances of retinal inflammation. These, by the deep opacity and by masses of exudation often resemble a nephritic neuro-retinitis (*O. Becker*), but are usually very soon diagnosticated by the symptoms of advancing acute or subacute glaucoma. This form of glaucoma, which is described as hemorrhagic or apoplectic, entirely without regard to the fatal cerebral hemorrhages threatening the patients, is so far of the worst prognostic signification, as the extensive disease of the vessels which causes them paves the way for a similar result, almost in half of the cases, in the second eye

within a short time, so that the only therapeutic means of aid, the iridectomy, usually fails in accomplishing its purpose (*Coccius, Laqueur*). The operation may very easily cause enormous retinal hemorrhages which hasten the final atrophy of the globe (*Graefe*). In other cases the iridectomy indeed removes the very intense pain, but new attacks soon appear with increased violence, and here the operation can do nothing more, so that in many cases we must resort to enucleation (*Pagenstecher, Horner*).

[A case of monocular glaucoma supervening on binocular retinitis hemorrhagica, reported by D. B. St. John Roosa, M. D., of New York, in the Transactions of the American Ophthalmological Society for 1869.]

Course.—Glaucoma presents great varieties in its commencement, development, and whole course, which are of the greatest practical importance; so that, in fact, they have been made a ground of division, and a series of different forms distinguished from them, which, however, are variously connected, and often pass into each other. (*Graefe.*)

A. In certain cases, glaucoma appears as such from the commencement, without any peculiar signs preceding it.

1. The development of glaucoma is, under such circumstances, often quite unnoticed, quietly progressing, so that the patient overlooks his state, and is often first disturbed when the disease is far advanced. Patients usually complain of a rapid diminution of vision in one or both eyes, which occasionally and temporarily is especially marked as well in distant as in near vision, in reading, writing, &c. On more careful examination, we find a decided decrease of accommodation and refraction, often also hypermetropia, and frequently a certain obtuseness of the retina. The weaker eye usually feels somewhat harder, indicating an increase of the intraocular pressure. The pupil is frequently, but not by any means always, somewhat dilated and more sluggish in its motions; the dioptric media are, however, without perceptible change. Ophthalmoscopically, we perceive a partial or even total, if not quite fully developed, glaucomatous excavation, with or without decided displacement of the porus opticus, much-enlarged venous trunks, and the occurrence of arterial pulsation, on a comparatively slight pressure of the finger on the globe. Then a non-inflammatory or simple glaucoma exists.

Glaucoma may remain in this state for months, or even longer, without a material change in the symptoms, and especially without the impairment of vision being decidedly increased; but the excavation increases more and more. As a rule, however, very perceptible increase of symptoms is felt; the disease progresses gradually, or with temporary exacerbations and remissions, or intermissions; the globe becomes harder, the congestions become more and more distinct, the cornea less sensitive, the aqueous chamber narrower, the pupil wider and more sluggish, or even fixed, the excavated papilla acquires the peculiar pale color of atrophy, the limitation of the visual field increases, while simultaneously central sharpness of vision diminishes more and more, and finally complete amaurosis exists.

Not unfrequently all these symptoms reach a maximum development; the completely blind eye becomes hard as bone, the cornea anæsthetic, the aqueous chamber almost nothing, the otherwise unchanged iris is reduced to a narrow ring, the deeply-excavated papilla is greatly atrophied, without symptoms of inflammation ever having clearly appeared. Sometimes the state above described exists for a long while, even for years, till finally the appearance changes, with all the symptoms of phlogosis. More frequently, however, evident inflammations occur earlier; the affection acquires

the character of inflammatory glaucoma. This occurs suddenly under the form of an acute, severe, inflammatory attack; or gradually, and then usually by starts, that is, under the action of slight and evanescent injuries, and with more or less complete intermissions. The attacks announce themselves, under such circumstances, by rapid diminution and cloudiness of vision, frequently also by ciliary neurosis; objectively by rapid increase of intraocular pressure, great dilatation and immobility of the pupil, as well as by discoloration of the iris, sometimes also by congestion of the episcleral vessels and formation of a vascular wreath, but especially by haziness of the media. These symptoms are more or less clearly pronounced according to the intensity of the temporary attack, and often change in degree in a few hours. Usually the attacks are slight at first, but increase, little by little if not regularly, in regard to intensity, duration, and frequency, till finally the disease appears constantly of the inflammatory character, and henceforth only remits.

2. In certain cases glaucoma appears from the first, without any signs whatever preceding it, as a more or less severe acute inflammation, and develops completely in a short time.

Exceptionally, in eyes previously normal, vision is destroyed entirely, or reduced to the indistinct perception of light in a few hours, or even half hours (fulminating glaucoma). Nothing is to be observed, objectively, but a decided cloudiness of the dioptric media, and great congestion of the retinal vessels; increased tension is only *subsequently* observed, but increases rapidly, while more or less marked ciliary neurosis and symptoms of congestion appear in the episclera. Just as often, however, the blindness is combined with the last-mentioned symptoms from the very commencement. The fulminating glaucoma bears from its start the character of inflammatory, and is distinguished from the ordinary acute form by the sudden blindness and the glaucoma, rapid development of the other symptoms, and soon changes into the latter form. Fulminating glaucoma has been observed especially beyond the age of fifty-five; in hereditarily disposed individuals, however, it occurs also at puberty. It always leads in a very short time, in a few weeks or days, to glaucomatous excavation, and degenerative atrophy of the deeper parts of the eye. (*Graefe.*)

B. In the great majority of cases, premonitory signs precede the glaucoma for a longer or shorter time. The repeated occurrence of headache usually opens the series. The eye itself appears somewhat tense, and some enlarged venous trunks appear on its surface. Then more or less evident inflammatory attacks occur, which announce themselves subjectively by rapid and decided decrease of the accommodation and of the refraction, by foggy vision, the peculiar play of colors around a flame, and often also by varying grades of ciliary neurosis; and objectively by marked increase of intraocular tension and evidences of congestion, further by dilatation and fixedness of the pupil; often, also, by narrowing of the anterior chamber, but especially by more or less cloudiness of the aqueous and vitreous. In greater intensity of the ophthalmia, even limitations of the visual field occur. Sometimes, also, the arterial pulse may be seen.

These attacks recur more or less frequently, with or without external causes, at irregular intervals or periodically; but usually recede completely, or at most leave behind a somewhat increased tension of the eye-ball and a decided diminution of accommodation, or, perhaps, also of the refraction. The preliminary stages may last for a long time, even for years. Usually, however, they end soon, even after the second or third attack has developed; that is, a regular intermission does not again occur, but certain symptoms belonging to the glaucoma remain permanently. In this relation various decided differences are to be noticed.

1. In many cases, after one or other attack, the typical inflammatory symptoms [illegible], except that the globe remains considerably harder, the aqueous chamber [illegible]row, the pupil dilated and sluggish, or immovable; quite gradually the charac[illegible]ic excavation of the optic disc develops, while, simultaneously with increasing [illegible] of accommodation, a very disturbing susceptibility of the retina and an [illegible]ing limitation of the field of vision show themselves. Then we have a [illegible]ple glaucoma, which either exists as such for a long time, and develops [illegible] and more, or else by further manifest inflammatory attacks, which recur [illegible] time to time and again entirely recede, it spasmodically approaches its termi[illegible]ions.

2. In other cases, after several attacks, the inflammatory symptoms do not entirely [illegible]; they only remit, sooner or later to start anew. Often the process vibrates [illegible], for months and years, between exacerbation and remission, till it finally termi[illegible] with the extreme development of the symptoms occurring in glaucoma. In [illegible] cases we speak of chronic inflammatory glaucoma.

3. Finally, it happens that, after a longer or shorter duration of the prodromal [illegible], the glaucoma breaks out all at once under the form of an intense inflamma[illegible]y attack. Intense pain in the head, a maddening ciliary neurosis, and often, also, [illegible]jective appearances of light, occur suddenly; vision diminishes decidedly, or is [illegible]tirely removed. The episcleral tissue and conjunctiva appear thickly injected, the [illegible]ter often swelled to actual chemosis. The globe has become remarkably hard, the [illegible]rnea hazy, the aqueous chamber narrowed, the aqueous humor cloudy, the iris [illegible]ly discolored, the pupil immovable, dilated, and irregular, the vitreous not trans[illegible]rent, so that the examination of the fundus becomes impossible. Often a few [illegible]ys or even hours suffice to complete the picture of glaucoma in all these details. It [illegible] usually a painful night that brings the disease to development in its completeness. [illegible]nce, under such circumstances, the disease is called acute inflammatory glaucoma. [illegible] remains a few days or weeks, with more or less decided remissions, at this degree, [illegible] even increases; but after this time the inflammatory symptoms decrease perma[illegible]ently or temporarily. Still, the globe and its functions do not return to the normal [illegible]te, but the process rather advances further and further after entering the chronic [illegible]ge, till finally all trace of sensitiveness to light has disappeared, and in individual [illegible] of the globe degenerative atrophy appears.

4. This state, which may be called complete glaucoma (*glaucoma absolutum, con[illegible]atum*), is characterized objectively by bony hardness of the globe, development [illegible] a very coarse venous net-work on the anterior half of the sclera; by decided rigidity, [illegible]ucency in places, and a peculiar porcelain-look of the atrophied sclera; by flat[illegible]ing out of the border running between the latter and the cornea; smoky opacity [illegible] the entirely anæsthetic cornea; obliteration of the aqueous chamber; retraction [illegible] the iris to a small ring, which is always discolored, and in some places is com[illegible]ely robbed of pigment, so that the connective-tissue stroma appears in the form [illegible] a bluish-white, fine net-work, or in thick, tendinous patches; by pigment atrophy [illegible] the choroid and the symptoms of a highly-developed glaucomatous excavation, [illegible]h partial or entire absence of the central vessels, and their replacement by col[illegible]ral circulation, with marked contraction of the pulsating arteries and the tendi[illegible]s appearance of the floor of the excavation peculiar to atrophy.

Absolute glaucoma often exists months and years without any material change in [illegible]ymptoms, only the atrophy in individual parts of the eye, especially in the iris, [illegible]oid, and optic-nerve entrance, always appears more distinct, and sooner or later a [illegible]ractous cloudiness of the lens occurs. So-called glaucomatous cataract is developed

in consequence of the impairment in the nutrition. Frequently, however, the symptoms change from time to time, in so far that, after as before, inflammations occur, which usually run their course with headache, ciliary neurosis, and subjective perceptions of light, often continue for a long time, and then render life a burden to the patient. They sometimes occur spontaneously, sometimes as a result of external cause, and in fact the slightest injurious influence, as an error of diet, &c., suffices to produce them.

C. Secondary or consecutive glaucoma bears, on the whole, the character of the acute or chronic inflammatory form, runs a similar course, and is distinguished from it by being preceded and accompanied by the primary disease.

It must not be confounded with complicated *glaucoma*, i. e., with the glaucoma which occasionally develops itself with other pathological processes in the eye, without a direct connection between the causes of the two diseases. Thus, glaucoma occurs sometimes in eyes where the lens was already cataractous. In some cases, also, glaucoma is complicated with cerebral amaurosis. The early atrophic discoloration of the papilla which is being excavated, and the peripheral limitation of the visual field, together with the evidences of the cerebral disease, give the symptoms for correctly diagnosticating the state.

D. Glaucoma always develops itself first in *one* eye. It may remain confined to this eye for life. This is, however, exceedingly rare, and only occurs where a severe external injurious influence, as a blow, &c., has been the only cause, or where the glaucoma has proceeded secondarily from some disease confined to the affected eye. In such cases, however, a predisposition always exists in the other eye, for very often a somewhat severer attack, a cataract operation, an accidental injury, &c., calls up the glaucomatous process—a fact which it is well to remember in practice. Primary glaucoma, on the contrary, scarcely ever remains monocular. If one eye is affected, the second is in great danger. It is true, years sometimes pass before the disease shows itself in the latter. Very frequently, however, the preliminary symptoms manifest themselves early, a few days or weeks after the appearance of the glaucoma in the other eye, and the disease becomes binocular.

Results.—With proper treatment, under favorable circumstances, glaucoma is to a limited degree curable. But if left to itself, or unsuitably treated, the individual parts of the eye gradually undergo atrophy, and become incapable of recovering their functions.

Attacks of irido-choroiditis, with exudations in the pupil and ciliary processes, generally form the termination of the morbid process. The globe then becomes softer, wrinkles and shrivels, while osseous scales are deposited on the inner wall of the globe, and the retina is drawn up like a funnel, in consequence of the vitreous humor having degenerated into connective tissue.

Partial or total sclero-choroidal staphylomata exceptionally develop in the course of glaucoma—a result which, on account of accompanying pressure on the ciliary nerves, often causes maddening pain, and this the more certainly the earlier the sclera gives way, that is, the less the ciliary nerves have suffered by the disease. Usually, under such circumstances, extensive degeneration of the vessels also occurs. These frequently show themselves in the eye by extensive extravasation of blood in the interior. Occasionally they appear to extend to the base of the brain—at least the symptoms of cerebral hyperæmia indicate this, especially constant and severe headache. The atrophy of the individual parts is then always very decided, the iris and the conjunctiva are rotten, and tear like tinder. This state is called glaucomatous degeneration. (*Graefe.*)

In isolated cases the product of the proliferation is pus. It has been found in the choroid (*Schweigger*). But generally the ulceration is primarily confined to the cornea. Such ulcers may again heal. But they often break through, and finally end in phthisis of the globe. Sometimes, however, they become dangerous by giving rise, after perforation, to excessive, even exhausting hemorrhages from the vascular coats of the eye (*Rydl*).

Treatment.—The first and most important task is to equalize to a certain extent the loss which the sclera has suffered in extensibility, and thereby to render the conditions of circulation in the internal current as normal as possible. The means to this end lie in the interpolation of a cicatricial layer of loose connective tissue in the degenerated tissue of the sclera. By these means the possibility will be offered to the external layers of fibers of the sclera, of yielding somewhat whenever it may be necessary, and of doing away with the abnormal condition in which venous obstructions and increase of intra-ocular pressure with a rigid capsule are maintained and increased. For this purpose an incision made as smooth as possible through the anterior scleral zone, and several lines in length, as is recommended in the iridectomy of glaucomatous eyes, suffices. The excision of a segment of the iris is of very secondary significance in regard to the curative action (*Wecker*, *Stilling*, *Hasner*), but is so far to be urgently recommended for all cases, as the simple scleral paracentesis very frequently causes prolapse of the iris, even in the moment of operation, but more often not till later, which, since they can not usually be replaced, may lead to disagreeable irritation, and moreover cause a disfigurement similar to that established by iridectomy.

Ophthalmologists have endeavored to prove the efficiency of the iridectomy by the results of physiological experiments on animals (*Hippel*). These however can not be here considered as standard, since the measurements have been instituted with very unreliable instruments, namely, with monometers (p. 6), and since more recent experiments with improved instruments have proved the errors of conclusions based upon the preceding ones (*Adamük*). Practical experience is also opposed to them. It is universally recognized, that even extensive excisions of the iris, with a scleral wound not sufficiently long, or when they are made through a corneal section, can do nothing against glaucoma. It has been further found, that sometimes a partial dialysis and even complete tearing away of the iris do not effect a curative result (*Arlt*). It is moreover a matter of consideration, that in England, and especially in America, not a few ophthalmologists, certainly endowed in a high degree with good judgment still at this time prefer the intra-ocular myotomy to the iridectomy, or, according to its curative effect, regard it as equally valuable.

We can not now however assert, that in the latter the section of the ciliary muscle is the essential thing, since the incision is usually made obliquely through the sclerotic, and hence only a small part of the muscle falls in the plane of the incision. Still less should we assert, that in the iridectomy performed correctly the attachment of the ciliary muscle is at all loosened, and that thus a relaxation of the internal muscles is brought about, since the line of the incision, according to anatomical investigations, lies entirely outside the range of the tensor of the choroid. It should also not be forgotten that the ciliary muscle is *without any influence* upon the internal tension (p. 14). The paracentesis as such, that is, the emptying of a portion of the internal media, can not however be regarded as the real means of cure, since the opening of the chamber by a corneal incision would bring about the same result, whereas a numerous experience has proved with all certainty, that even repeated paracenteses of the cornea often annul only very temporarily the intra-ocular tension, and can not bring about a lasting cure of glaucoma (*Graefe*, *Coccius*, *Secondi*, *Nagel*). After all this, therefore, there remains nothing but to consider the division of the most anterior zone of the external scleral layers as that means which is most effective in combating the glaucomatous conditions. Its influence upon the pathological increase of tension can then be

really naturally referred to the condition, in agreement with the theory assumed of the pathogenesis of glaucoma (p. 310), that penetrating wounds of the sclera never heal by direct adhesion of their edges, but always by the deposit of a cicatrix of connective tissue between them, which proceeds from the conjunctiva and the uvea, and penetrates all the incised parts (*Lubinski*). We should not object to the curative effect of the simple paracentesis of the sclera, that cystoid cicatrices rather endanger the success of the operation than warrant it (*Arlt*), for in this manner the whole line of argument becomes deranged. Neither the paracentesis of the sclera nor the iridectomy involved in it can give a retrograde direction to the already induced pathological processes, but can merely obstruct one source of venous stasis by the restoration of a certain degree of elasticity, and thus favor resolution. This indication is more than filled by the cystoid cicatrization, for the eyes thus affected feel, as a rule, softer than normal. If, moreover, after the paracentesis of the sclera, the diminution of the pathological hardness of the globe often remains unsatisfactory, this objection affects the iridectomy in like measure. It must here be taken into account, that a greater resistance of the globe does not necessarily include in itself an elevation of the internal pressure (p. 1); further that different degrees of abnormal rigidity of the sclera can not well be always neutralized by a similarly measured operation, therefore by interposition of a like quantity of yielding cicatricial tissue, and that by well-performed paracenteses of the sclera or by iridectomies of two quadrants of the iris, either lying opposite to one another, or next to one another, the effect of the operation in lessening the pressure is essentially increased, has been proven, and corresponding to this in not a few cases a way has been opened for resolution, in which the simple paracentesis or iridectomy has already proved insufficient.

The paracentesis of the sclera moreover in connection with the emptying of a portion of the vitreous has been recommended for a long time as a means of lessening the hardness of the globe (*Mackenzie*). Since, however, the technical performance of the operation was not adapted to produce a permanent relaxation of the sclerotic, it could only obtain transient and therefore unsatisfactory results. Its union with the *iridenkleisis* (*Critchett*, *Coccius*) has theoretically very much to be said for itself, but is to be avoided on account of favoring cystoid cicatrices, and subsequent threatening irritation. The proposal to draw out the iris very much in iridectomy, in order to rupture the zonula, and thus to establish a connection between the vitreous and aqueous humors (*Coccius*), should find few friends, in consideration of the dangers which can accrue to the nutrition of the lens and even of the entire globe from a partial rupture of the ciliary body.

Certain objections still cling to iridectomy; still these are not all in proportion to the beneficial effects which usually follow a timely and suitably-performed operation. Hence they do not remove the indications for it, but only render a guarded prognosis more necessary.

a. Thus, the sudden relaxation of the globe, and the over-filling of the blood-vessels of the deeper tissues of the eye caused by it, easily induce intraocular hemorrhage, and this occurs the more readily, the further the process has already advanced, and the more the walls of the vessels have already suffered. In acute and especially in fulminating glaucoma, they occur frequently and extensively. As a rule, such extravasations are rapidly absorbed, especially in the retina, and usually leave behind no functional disturbance. Occasionally, however, particularly when the hemorrhage becomes somewhat more abundant, the result is a partial darkening of the visual field.

b. If the iridectomy be done in the first stages of an acute inflammatory glaucoma, during or just after one of the first manifest attacks of inflammation, in a great percentage of cases it *hastens* the appearance of the disease in the other eye, provided that this has already shown the premonitory symptoms—possibly, also, in case this eye is still sound. Ordinarily, in acute inflammatory glaucoma, the first manifest attacks of inflammation in the two eyes are separated by intervals of months, or even years. After iridectomy the second eye is often affected within the first four weeks, or even after fourteen or eight days. This objection is abundantly

overcome by the fact that, just in the first periods of acute glaucoma, iridectomy is followed by the best results, and this may be made use of as well in the first eye affected as in the other, while every delay of the operation under such circumstances is bitterly punished; of course, however, the physician must not neglect to inform the patient, before the operation, of the possibility that the second eye may be affected in a short time, and that this may be hastened by the operation.

c. Many believe that iridectomy often causes rapid formation of cataract in the eye operated on. There is, however, no doubt that, in most cases of this kind, an injury of the capsule has caused the cataract. In some rare cases, however, the rapid evacuation of the aqueous may have caused a rupture of the capsule or zonula, and thus have laid the foundation for cataract. (*Graefe.*)

d. Recently attention has been called from various quarters to a peculiar mode of consolidation of the incision regularly made through the sclera. This peculiar form of healing, called "cystoid cicatrization," has been frequently observed, and especially in those cases where the signs of increased tension were strongly marked before the operation, and where excavation of the optic disc was added to the posterior staphyloma, and had rendered iridectomy necessary. In such cases the two edges of the wound frequently do not remain in immediate contact, but the neoplastic tissue uniting them bulges forward like a cushion. It consists of strong tendinous filaments, with thin, membranous, more prominent vesicle-like bunches between them. Usually this ectatic substance in the interspaces breaks through from time to time, and the aqueous enters under the conjunctiva, pushing it forward. This occurrence is often repeated for months after the operation. Cases have even been witnessed where, after two years, ruptures still occurred. Usually under such circumstances the globe remains abnormally soft; still the chamber has its normal size. In slight degrees of cystoid cicatrization, a few months after the operation the tissue becomes, as a rule, thicker between the cicatricial cords, the escape of aqueous gradually ceases, and, finally, a nearly normal closure of the wound occurs. In higher grades, however, the thickening and flattening-out of the vesicle-like cushion require a long time. Great injection of the conjunctiva and a decided irritability to external injurious influences often exist during the whole period. Sometimes then fatal inflammations occur, which may increase to suppuration, and even cause destruction of the globe. (*Graefe.*) To avoid such unfortunate occurrences, it is necessary, in cases which, during the first weeks after the operation, show a tendency to cystoid cicatrization, to enforce especially stringent dietetic rules, in order to prevent, as far as possible, external injurious influences, and, besides this, to compress the globe periodically by a light pressure-bandage. In great ectasia of the interstitial tissue, with coincident conjunctival irritation, it is advisable to favor the normal healing of the wound by dividing the vesicle along one edge with a cataract-knife, and cutting off the rest of it with scissors, while the globe is firmly fixed, and, after applying a pressure-bandage, to keep the patient carefully in bed for several days, just as after other severe operations on the eye. The ordinary rules suffice for the treatment of severe inflammation. (*Graefe.*)

On the whole, we may say iridectomy answers better in glaucoma the sooner it is done and the less the material changes undergone by the internal parts of the globe. Its chief effect consists in the diminution of intraocular pressure, and in the consequent restitution of favorable conditions of circulation and nutrition. It only assists the removal of the existing disturbance of nutrition. If the elements are again to perform their functions, they must still exist. Hence comes the rule, *the operation should be done as early as possible.*

1. In the incipiency of glaucoma, where the premonitory symptoms are not severe, and when they increase slowly, we shall certainly undergo no great risk, if we direct the treatment toward the keeping away of all sources of injury which may become the causes of a glaucomatous process, as well as the lessening and removal of all disorders of circulation, or of an already-existing congestive condition.

In the first respect, we can not insist too much on the giving up of any occupation which in any degree strains the eyes, e. g., reading, writing, sewing, &c. At the same time the patient should be protected from the effects of bright light, direct sunlight, bright reflections, as well as great contrasts of light, such as are caused by artificial illumination. This is to be done by the avoidance of all opportunities for such influences, or, in case of necessity, by the weakening of these injurious influences through the proper use of protective apparatus. But wind, smoke, dust, acrid vapors, great change in temperature, and the like, may, as experience teaches us, become provocations for an inflammation already prepared for. At least, they may increase the existing hyperæmia and irritation of the parts, and hence the disposition to glaucoma.

They should, then, be considered in prescribing a regimen for the patient. The patient may be recommended to spend the best part of the year in the country, in a climate that is not too warm, to take a moderate amount of exercise in the open air during the cool part of the day, in places free from wind and dust. In consideration of the existing local hyperæmia, all bodily and mental excitement is as far as possible to be avoided. The diet is also of the greatest importance. Drinking strong wines, beer, strong coffee, spirituous liquors, is to be strictly forbidden. Small quantities of diluted wine, weak coffee, and tea, can scarcely cause any harm. The meals should consist principally of easily-digested and masticated food, that which is not strongly seasoned, and chiefly vegetable. Overloading the stomach is strictly to be avoided, and to guard against this the meals may be taken often during the day. It is also important that the patient do not sleep immediately after dinner. An elevated position of the head, and an avoidance of lying on the back, are to be recommended at night. The reasons for this are the same which render easily fitting garments necessary, and tight ones, especially about the neck, dangerous.

Among the direct means of treatment, the occasional application of cold cloths to the eyes and forehead is to be recommended. The local removal of heat is, however, only appropriate when the symptoms of hyperæmia plainly appear in the eye and brain, and are accompanied by elevated temperature. The existence of gout by no means contra-indicates the use of cool applications. But they should always be employed with care, and constant consideration of the local temperature. Douches are to be avoided, on account of their irritating effect. Cold baths also not unfrequently cause temporary hyperæmia, and are in such cases best avoided. If there be severe pain, hypodermic injections of morphia may be used.

Moreover, the affection causing the local hyperæmia often requires treatment at the same time. Thus, in abdominal affections, the systematic use of mild laxatives, especially certain mineral waters, and in affections of the heart, digitalis is to be recommended. The indications for their use belong to special therapeutics. Still, it should be mentioned here that the use of the water of warm springs for bathing and drinking involves great danger; therefore cool waters, and those as far as possible not creating any excitement of the system, should be substituted.

But if the attacks of obscuration of the visual field come at shorter intervals, it is well not to postpone the operation, as the outbreak of glaucoma may soon be expected, and it is doubtful in what shape it may come. It may, perhaps, quickly cause changes against which iridectomy will avail little. After the operation the attacks usually remain away, and the retina is usually raised to its former functional activity, so that patients can again take up their former occupation. Only exceptionally does it happen that, in spite of lasting diminution of intraocular pressure, a glaucomatous affection of the optic nerve and gradual atrophy of the papilla, with more or less decided disturbance of vision, is developed, or that new relapses, with increase of tension, require a repetition of the operation.

2. If the glaucomatous process has broken out in an acute form, the treatment with antiphlogistics, narcotics, mydriatics, &c., is mostly time lost. Delaying the operation lengthens the intense suffering of the patient and diminishes the possibility of a restitution, as it gives the degenerative changes time for development. Especially in fulminating glaucoma is immediate operative interference urgently required, as in this even a few days suffice to produce incurable lesions. In ordinary acute glaucoma we may rather wait a few days to let the worst of the excitement in the course of the vessels and nerves pass over; in many cases the prece-

dent reduction of the severe inflammation, and maddening ciliary neurosis, have seemed favorable to the final effect. Still, according to experience such a delay is only indicated when the inflammatory attack is not accompanied by too great a decrease of vision. Where this has rapidly diminished to quantitative perception of light, or *limitations* of the visual field occur, it would be dangerous to delay the operation in order to oppose the intensity of the inflammation and ciliary neurosis by antiphlogistics and narcotics. Besides this, the operation has shown itself as the most certain and powerful antiphlogistic and pain-quelling remedy.

In fact, the hitherto often insufferable pain usually ceases almost immediately after the operation. At most, slight pains of the brow, or tenderness, as after any operation, remain for a day or two. The symptoms of inflammation also very quickly recede, or are very remarkably lessened. In the same way, the power of vision increases immediately after the operation, in so far, namely, as its disturbance depended on the haziness of the aqueous which has escaped, and on the increase of the intraocular pressure. The disappearance of the inflammatory changes, and of the retinal ecchymoses, almost always occurring in such cases, then causes a further gradual increase, which is especially observable in the first fourteen days, but usually progresses even after this time, so that in most cases the highest point is only reached after six or eight weeks.

If the operation be done soon enough, we may, as a rule, in *acute* glaucoma, restore and preserve to the eye nearly or entirely its full former functional power. Experience teaches that we may count on this brilliant result with most certainty, in a case of ordinary acute glaucoma, when the iridectomy is done within fourteen days after the first attack; and the hope is the more justified the sooner it is undertaken within this time, always provided that the eye in question was normal before the attack; that, at the time, the visual field had not suffered a decided limitation, and the sensitiveness to light was still very acute. In less recent cases, and particularly where a limitation of the visual field is already observable, and the power of qualitative perception of light is lost, such a result very *rarely* occurs, and should never be expected. As a rule, the sharpness of vision remains decidedly diminished; the visual field also does not attain its former extent. Under such circumstances there are almost always degenerative changes in the parts sensitive to light, which are little affected by the iridectomy.

This want of power, in iridectomy, against degenerative changes, is also seen very markedly in the more superficial parts of the eye. Even in comparatively recent cases, the normal sensitiveness of the cornea does not return, the aqueous chamber often remains somewhat narrowed, the iris appears as discolored as before the operation, the pupil somewhat enlarged and sluggish, or even rigid, and the impairment of the power of the muscle of accommodation is shown by a removal of the near point of vision.

Moreover, the fact should not be concealed, that the operation may fail even when performed at the proper time, with care, and under what seem to be favorable auspices. Cases occur in which new acute inflammations arise, with more or less severe ciliary neurosis, which can not be subdued by a repeated iridectomy, but may cause permanent harm. Cases are also observed, and not very rarely either, in which glaucoma develops itself, after iridectomy, into the chronic inflammatory or simple non-inflammatory variety.

It is then urgently necessary to repeat the operation as soon as possible in the neighboring or opposite quadrant, and thus increase the yielding nature of the sclera.

3. In the later stages of acute glaucoma, there is very little hope of the restoration of the functions of the optic nerve and retina. The glaucomatous process does not, of course, always lead with equal rapidity to degenerations in these parts of the

eye, but occasionally cases occur, where, after repeated acute attacks, the visual power spontaneously reaches a high point after a time, and no excavation can be observed. Under such circumstances iridectomy may be of very great service. It may completely reëstablish the eye, These, however, are rare exceptions. In the later periods of acute glaucoma, as a rule, we find the visual field contracted and the papilla decidedly excavated. A return to the normal state is then impossible. Still, when the excavation is but little developed, and the contraction of the visual field slight, especially concentric, it sometimes permanently increases the sharpness of vision a little, and also widens the visual field. We may allow ourselves the greater hope the more the vision is affected by the cloudiness of the dioptric media and the increase of intra-ocular pressure. Where, however, the field of vision is decidedly contracted, especially on one side, or is even *eccentric*, or where the sensitiveness to light begins to be indistinct, as well as where the excavation is already far advanced in development, we must, as a rule, be satisfied with bringing the process to a stand-still.

Moreover, in such cases, the favorable results obtained by iridectomy are not always of long continuance. In many cases, sooner or later, the visual field contracts again, with a decrease of central vision, is reduced to a small eccentric patch, and at last, not unfrequently, all perception of light is lost. The symptoms observed by the naked eye may gradually increase more and more, so that the disease appears later with the symptoms of simple non-inflammatory or chronic inflammatory glaucoma. Then, as a result of iridectomy, the existing excavation, if recent, not unfrequently flattens to a decided degree. It becomes trough-shaped, but the degenerative atrophy of the elements, once advanced to a certain point, can not be checked by the operation, but it advances, as a rule, and sooner or later the optic nerve entrance, by its tendinous, white color, and the slight satin-like brilliancy, betrays the connective-tissue degeneration of the papilla.

It is here important to remark, that such tendinous discolorations of the papilla occur almost regularly after iridectomy in glaucoma (*Liebreich*), without any danger to the power of vision necessarily arising therefrom. They are only dangerous and really to be referred to progressive atrophy when accompanied by a diminution in the acuteness of vision. Often, however, the decline of the power of vision follows very rapidly after the iridectomy and leads in a very short time to complete blindness (*Berlin*, *Mauthner*).

4. In the chronic inflammatory and in the simple non-inflammatory glaucoma there is one unfavorable circumstance, that the patients usually only seek professional aid late in the disease, at a time when the material changes in the internal tissues of the eye are already far advanced. Still, we also succeed here, not uncommonly in clearing up central weakness of vision existing for a short time, and even eccentric limitations, or at least in lessening them considerably; at least we can hope in the majority of cases for a cessation of the process, for a permanent preservation of the still existing degree of visual power and of the material conditions of the internal tissues. Finally, we have so much the more ground for a favorable prognosis, the earlier the operation is performed, the greater the relaxation resulting therefrom, and the more quickly the anterior chamber is refilled after the operation.

Where the relaxation after the exit of the aqueous humor remains incomplete, the prospect of even a moderately good result is very slight; generally, the anterior chamber is not reëstablished, and the tissues of the globe under continual unfavorable conditions soon lose their functional power entirely (*Graefe*, *Mooren*, *Ed. Meyer*). It appears that, under such circum-

stances, the sclerosis of the sclera is already very far advanced, and the simple iridectomy no longer suffices to give a sufficient degree of elasticity to the capsule of the globe. In individual cases, the repeated iridectomy in neighboring or opposite quadrants may then, perhaps, bring about the desired result. As a rule, however, this operation does not suffice to hinder the degeneration. It is an important practical rule to avoid the compressing bandage in these cases immediately after the operation, as it is liable to increase disagreeably the tension of the interior of the globe. The artificial leech has also been favorably mentioned in such cases (*Graefe*).

[In cases of chronic irido-cyclitis, or chronic glaucoma, where there is a doubt that one iridectomy will not suffice to stay the process, *Mr. Bowman* is in the habit of doing a double iridectomy. He introduces the knife on one side into the anterior chamber, holds the globe steady with it, and then introduces another iridectomy knife at a point exactly opposite, pulls out the iris and cuts it off, and then completes the first iridectomy.]

It also exceptionally occurs, that directly after the iridectomy, the resistance of the globe increases markedly, the globe even becomes of a stony hardness. Such cases always run an unfavorable course, according to previous experience (*Liebreich*).

If we pass judgment according to a few observations, the increase of resistance seems to depend upon moderate extravasations of blood into the vitreous (*Nagel*).

Not uncommonly after an iridectomy, the anterior chamber reëstablishes itself only slowly and incompletely, or else not at all, or the aqueous humor in the meantime collected, after the expiration of weeks or days again disappears, and the anterior chamber remains empty. Such cases have a bad prognosis, since the absence of aqueous humor points to extensive disturbances in the osmotic relations of the vascular internal tissues, and indirectly indicates further advanced material changes in them. In fact, such eyes only seldom attain a satisfactory power of vision, although this hope is not entirely excluded (*Mauthner*).

In general the favorable effects of iridectomy appear less quickly in chronic simple glaucoma, than in the acute form, where the opacity of the media, the temporary considerable disturbances in the circulation, etc., occur in connection with the visual disturbance, and meet with a rapidly acting remedy in the iridectomy. It needs often months, and even longer, before the improvement in the power of vision, or even the stoppage of the previously advancing disease can be demonstrated with certainty. It is necessary to call the patient's attention to this circumstance, in order that he may not expect too much from the operation.

5. The same therapeutic and prognostic rules hold good in general for the secondary glaucoma, as in primary and pure glaucoma, so far, namely, as it relates to the glaucoma as such. It is here also extremely necessary not to allow the increase of tension and the excavation to advance so far in their development, or to wait until the conditions of circulation inside the eye have become permanently less favorable by the sclerosis of the sclera. We would really do better to perform the iridectomy immediately as a prophylactic agent. At any rate, we should delay no longer, when the increase of tension makes itself distinctly manifest, or even if the excavation of the papilla has begun. Besides, the primary affection not uncommonly demands the operation in order to be cured, or at least to be brought to a stand-still.

6. Against absolute glaucoma, i. e., *glaucoma* of the old writers, iridectomy is of no use; hence it is better not to perform the operation, unless frequent acute attacks, severe pain, troublesome chromopsia, photopsia, &c., require direct therapeutic action. If, then, the operation has no result, in imperative cases enucleation of the globe is justified (*Graefe*).

7. In cases of glaucomatous degeneration, iridectomy is apt to make the disease worse, as it usually causes extensive intraocular hemorrhage. Where continued inflammatory attacks, or frequent attacks of ciliary neurosis, render therapeutic interference necessary, the enucleation of the eye is far more advisable. Sometimes this operation has the most favorable effect on the treatment of the other eye, which is perhaps still capable of being cured, as it puts an end to a fruitful source of sympathetic irritation. (*Graefe.*) When the other eye is free from irritation, or is to some extent guarded against it by an iridectomy, or is already lost, we may, instead of the enucleation, induce artificial suppuration of the globe by a thread drawn through it. (*Graefe.*) (See treatment of sclero-choroidal staphyloma.)

Authorities.—*Hamer, Donders*, kl. Monatbl. 1863. S. 502, A. f. O. IX. 2. S. 215.—*Dor*, kl. Monatbl. 1865. S. 351.—*Stellwag*, Ueber doppelte Brechung etc. (Denkschriften der Wein. k. Akad. der. Wiss. V.) Wien, 1853, S. 62.—*Scheeske*, A. f. O. X. 2. S. 1, et seq.—*Jacobson*, ibid. X. 2. S. 54.—*Haffmans*, ibid. VIII. 2. S. 124, et seq.—*Ed. Jaeger*, Staar und Staaroperationem. Wien. 1854, S. 103, 104, Wien. med. Wachenschrift. 1854. S. 36, Zeitschrift der Wiener Aerzte. 1858. S. 465, et seq.—Einstellung des diopt. Apparat. Wein. 1861. S. 37, 42, Fig. 12-17.—*Graefe*, A. f. O. I. 1. S. 371, 375, I. 2. S. 299, et seq. II. 2. S. 291, III. 2. S. 456, et seq. IV. 2. S. 127, et seq. VI. 2. S. 150, 254, VIII. 2. S. 242, et seq. IX. 2. S. 105, 110.—*A. Weber*, ibid. II. 1. S. 133, 141.—*Schweigger*, ibid. V. 2. S. 233, Vorlesungen über den Gebrauch des Augenspiegels. Berlin, 1864. S. 127, 130.—*Förster*, A. f. O. III. 2. S. 81.—*Coccius*, ibid. IX. 1. S. 1. 8, 12, Ueber Glaucom, Entzündung, etc. Leipzig. 1859. S. 11, et seq.—*G. Braun*, A. f. O. IX. 2. S. 222, et seq.—*Alf. Graefe*, ibid. VII. 2. S. 113.—*Pagenstecher* und *Sämisch*. Klin. Beobachtungen. Wiesbaden, 1860. I. S. 26, 39. II. S. 13.—*Mackenzie*, Prakt. Abhandl. etc. [Translation], Weimar, 1832. P. 689.—*Rothmund*, Jahresbericht. 186. 1-2. München, 1863. S. 18.—*Tetzer*, Wiener allg. med. Zeitschrift. 1862. S. 210.—*Bowman*, British med. journ. 1862. S. 377, 381, klin. Monatbl. 1866. S. 267.—*Knapp*, Dritter Jahresbericht. Heidelberg, 1865. S. 19, Canstatt's Jahresbericht. 1864. III. S. 155.—*Critchett*, Ophth. Hosp. Rep. II. S. 59.—*Solomon*, kl. Monatbl. 1866. S. 116, 118.—*Secondi*, Clinica di Genova. Riassunto Torino, 1865. P. 89, 51.—*Businelli*, Zeitschrift der Wien. Aerzte, 1859, S. 269.—*Stellwag*, der intraocul. Druck. Wien, 1868, S. 34-52.—*Ed. Jaeger*, Handatlas, Figs. 52-60.—*Graefe*, A. f. O. XII. 2, S. 153; XIV. 2, S. 116; XIV. 3. S. 147; XV. 3, S. 108.—*Förster*, Congrès Ophth. 1867, S. 128.—*Coccius*, der Mechanismus d. Accom. S. 92-98.—*Pagenstecher*, kl. Monatbl. 1869, S. 392-396.—*Laqueur*, Centralbl. 1869, S. 361-363.—*Rydl*, kl. Monatbl. 1869, S. 395; Wien. Augenklinik. Bericht, S. 132-153.—*O. Becker*, ibid. S. 29; kl. Monatbl. 1869, S. 397.—*Arlt*, Wien. Augenklinik. Ber. S. 39; kl. Monatbl. 1869, S. 386.—*Mooren*, Ophth. Beob. S. 96-195; Ueber symp. Ophth. S. 141, 145.—*Heymann*, kl. Monatbl. 1867, S. 147, 155.—*Wegner*, A. f. O. XII. 2, S. 1, 15, 18, 21.—*Hutchinson*, ibid. S. 1.—*Horner*, ibid. kl. Monatbl. 1869, S. 391, 396.—*Wecker*, ibid. S. 385-395.—*Vagel*, ibid. S. 388, 394.—*Meyer*, ibid. S. 390.—*Liebreich*, ibid. S. 393, 400, 403.—*Berlin*, ibid. S. 402.—*Reuss*, ibid. S. 400.—*Hippel*, ibid. S. 376.—*Adamük*, ibid. S. 380, 383; 1867, S. 327.—*Lubinski*, A. f. O. XIII. 2, S. 378.—*Arcoleo*, Conferenze clin. S. 8.—*Hasket Derby*, Transact. Am. Ophth. Soc. 1869, S. 35.—*Cusco*, nach Coccius, der Mech. etc. S. 93.—*Leber*, A. f. O. XIV. 2, S. 216.—*Landesberg*, ibid. XV. 1, S. 204, 208.—*Mauthner*, kl. Monatbl. 1869, S. 392, 402; Lehrb. d. Ophthscop. S. 271 u. f.—*Stilling*, A. f. O. XIV. 3, S. 266.—*Hasner*, Prag. Vierteljahrschrift, 101. Bd. Lit. Anz. S. 21.

k—Besides the general symptoms of inflammation, particularly an chemotic swelling of the lids and conjunctiva, the disease is characterized nce of a dense pus-colored haziness in the depths of the eye, and the ntirely blinded.

itive proof of the existence of collections of pus in the choroid is only nce the dioptric media are from the beginning also affected, and their nts a view of the fundus with the ophthalmoscope. Before masses of y be recognized with the ophthalmoscope, are formed in the choroid, as lost its transparency in consequence of the inflammatory prolifera- rs, besides, a marked increase in size. We find the iris discolored with or less pushed forward, and even lying upon the cornea, and behind generally enlarged pupil there is a diffuse opacity, rapidly increasing nerally of a yellowish-green color. This is often traversed by strongly- n crossing each other.

symptom may often not be demonstrable, for, together with the suppu- lal inflammation, similar processes may readily appear in the anterior ye. The capsule may be opaque, the pupil covered over or displaced, humor simply turbid or encroached upon by a large hypopyon, the ne from purulent infiltration, perhaps partly ulcerated, or entirely

nosis of suppurative choroiditis rests then only on symptoms, which in y indirectly indicate this affection; but soon an opening in the sclera the welling-out of pus dissipates every doubt as to the existence of a ss in the posterior part of the eye.

one of these symptoms which indicates the existence of suppurative s constant, and that is, the early loss of perception of light; all the other re changeable, and make the picture of the disease extremely variable.

pperative choroiditis often bears the character of a sthenic inflammation, es with fever and severe local nervous irritation. The lids appear ply reddened, tense, hot, and very sensitive to any pressure. The ocular is puffed out in a bluish-red swelling, which extends to the palpebral entirely covers the globe. The conjunctival secretion ceases, the refore appears dry, and covered with exudative coatings, which have e hardened to crusts, and are colored by exuded blood. The eye-ball

In other cases, in spite of equally speedy and great formation of pus, all the symptoms are much milder. The fever is slight, or is entirely wanting, the lids and conjunctiva only slightly reddened, œdematous, and of a doughy softness. The conjunctiva secretes more or less muco-pus. The globe, in case no perforation has occurred, is moderately distended, and protrudes but slightly or not at all. It is movable and somewhat sensitive to pressure. The subjective chromopsia is less severe and is only evident at times. Pain is sometimes wanting entirely, or is confined to drawing, throbbing sensations, with occasional periods of greater severity.

Cases exceptionally occur when the lids and conjunctiva appear only slightly injected and swollen, the hyperæmia in the episcleral tissue is not great, the intra-ocular pressure has scarcely increased, and the subjective symptoms of irritation are almost entirely wanting, although perhaps the vitreous and aqueous humor are already full of pus.

Causes.—1. As exciting causes, we may name severe and extensive traumatic or chemical injuries, concussions, blows, cuts, rebounding blows, with or without separation of continuity in the walls of the globe; cauterizations, scalds, burns; the mechanical irritation of a body accidentally or artificially pushed into the anterior chamber, or a dislocated lens in the back part of the eye, an intraocular cysticercus, &c.

Punctured wounds are a prominent cause. Foreign bodies, which remain on or in the eye-ball, lead as a rule to extensive suppurative inflammations, and at last to phthisis of the globe, when they are not removed in time. In case the foreign body is in the cornea, the danger to the existence of the eye is, of course, not so imminent, since the purulent inflammation at first is frequently limited to the cornea. The foreign body is readily loosened under the progressive deliquescence of the tissue surrounding it, and thus further destruction avoided. But the proliferation process quite often continues itself upon the deeper parts, and iritis, irido-choroiditis, and, later, not unfrequently phthisis of the entire eye, occur. If the foreign body has entered the aqueous chamber, or remained in the iris, the eye-ball is at once in more danger, and, as a general rule, is finally lost by suppuration.

It only exceptionally occurs that the inflammation is limited to the immediate surroundings of the foreign body, and, furnishing only plastic organizable products, prepares the way for encapsulation. If the foreign body adheres to the lens, this generally becomes cataractous. Occasionally it occurs that the foreign body, surrounded by secondarily metamorphosed cataractous remains, stays in the cavity of the capsule, and is rendered permanently harmless; but generally, with the progressive cataractous solution of the lens, it becomes loose, sinks down to the floor of the aqueous chamber, and causes the severest reaction, which generally ends in suppuration of the globe. The danger is exceedingly great on account of the difficulty of its removal. When the foreign body is fixed in the ciliary region, or lies in the posterior space of the eye, suppuration is, as a rule, the immediate result. The proliferation, under such circumstances, proceeds chiefly from the vascular and nervous envelops of the vitreous humor (*Ed. Jaeger*), especially when these were severely affected by the injury itself, or were torn, or bruised, or held in a continuous state of irritation, by the foreign body. Occasionally, however, the proliferation begins in the vitreous, in the immediate neighborhood of the foreign body, and along the course traversed by it. It is only later that the retina and choroid participate in the process (*Graefe*), and finally the remaining existing portions of the globe are involved in the suppuration. Encapsulation, with a normal

condition or slight participation of the more distant parts of the globe, of course may also occur here.

But it is an exceptional case when a foreign body remains for some time in the eye without exciting a marked inflammatory irritation, and without being enveloped by exudations. It is much more exceptional, when it lies exposed, so that, with the aid of the ophthalmoscope, it may be perceived in the fundus of the eye. (*Graefe.*) Besides, encapsulations in the posterior part of the eye, when they occur, have a short existence. Sooner or later severe inflammations again arise, which end in phthisis of the globe. Small pieces of metal, and round bodies, without prominent edges and angles, e. g., a shot, are most capable of a permanent encapsulation by circumscribed inflammation. It is scarcely to be expected of jagged splinters, and least of all of fragments of gun-caps, since these act not only mechanically, in exciting irritation, but chemically also. (*Graefe.*) Gun-caps are, however, the foreign bodies which most frequently enter the eye. The number of injuries caused by them, especially in children, exceeds by far that of all other causes of lacerated wounds of the globe; their number, viewed absolutely, is astonishingly great. (*Boissonneau, Cunier.*)

Operations on the eye belong to the more frequent causes of suppurative inflammation of the globe. Apart from the greater or less irritation of the operation as such, many injurious circumstances are here combined. First, a certain predisposition can not be denied. The diminution of the intraocular pressure, which, under some circumstances, may last for some time, and which is connected with the partial laceration of the contents of the globe, is a more important cause, with its immediate results, disturbances of circulation, hemorrhage, &c. The mechanical irritation of the bits of the lens, which, through wounds of the capsule, pass into the aqueous chamber, and then come in contact with the iris, here plays an important part. (See *Cataract Operations.*)

2. Ulcerative perforations of the cornea, through diminution of the intraocular pressure, especially when combined with evacuation of the lens, or even of a part of the vitreous, are a source of suppurative inflammations of the globe. The latter may, then, in a certain respect be considered as secondary affections, which have their origin in an ulcerative keratitis, ophthalmo-blennorrhœa, diphtheritic conjunctivitis, &c.

3. There is, however, no doubt that true suppurative choroiditis may be also secondarily developed, by transplantation of the inflammatory process from the conjunctiva, cornea, iris, &c., upon the choroid. In the epidemic cerebro-spinal meningitis, and in many cases of typhus, puerperal fever, pyæmia, accompanied by meningitis, the inflammation appears to go from the meninges, along the sheaths of the nerves, to the internal parts of the globe, and here to give rise to abundant inflammatory products.

It is true that the ophthalmia appearing under the last-named conditions are not always exactly the same in character. In certain cases, we have only a severe catarrhal conjunctivitis, which subsequently may be combined with ulcerations of the cornea, and thus possibly destroy the eye. Similar agencies, perhaps, may work together here, as in the neuro-paralytic ophthalmia, since the dangerous condition is first seen when the lids are opened, and the nervous conduction has become limited, and very many injurious influences act upon the exposed globe. (*Schirmer.*)

In other cases the ophthalmia has from the beginning the character of a suppurative iridochoroiditis, and is developed with severe inflammatory symptoms, with intense redness, swelling of the lids, and conjunctiva, which always quickly leads to adhesion of the pupillary margin to the anterior capsule, and causes large purulent products, which are partly exuded into the anterior

chamber as a hypopyon (*Kreitmair*), and partly infiltrate the vitreous humor, especially its anterior portion, while the greater impairment or entire loss of vision announces the internal participation of the retina, choroid, and optic nerve. The infiltration of the vitreous is betrayed by a very marked, bright yellow reflex, which evidently proceeds from a thick opacity, lying immediately upon the posterior surface of the lens, and which, from its want of vessels, may be plainly distinguished from a detached portion of retina lying upon the crystalline body. (*Jacobi.*) This reflex is recognized as characteristic, since it is never wanting, unless the lens has been already involved in the process of proliferation, and has become cataractous, or unless inflammation is not yet completely developed, but remains confined to the iris, without affecting the deeper parts of the eye. Such suppurative inflammations of the eye have been seen as a result of meningitis in the various stages of the disease (*Jacobi*), the occurrence of which is explained by the conduction of the proliferation process along the sheaths of the nerves. Pathological investigations support such a view. (*Schirmer.*)

4. Suppurative panophthalmitis is sometimes a metastatic process, since it arises from *thrombosis* of individual vessels of the inner part of the eye. (*Virchow.*) It is then almost always seen in company with collections of pus, of a similar origin in other parts of the body. The great number of cases of suppurative ophthalmia which arise in the course of pyæmia and puerperal processes, from anomalous variola, scarlet fever and typhus, and from glanders (*Graefe*), belong to this category. They are accordingly developed when deleterious and especially purulent and infectious material are allowed passage to the blood.

Some epidemics of these acute exanthemeta are peculiarly marked by the frequency of such suppurative inflammations and other purulent depositions of the eye. Now-and-then an ophthalmia, appearing in consequence of epidemic cerebro-spinal meningitis, has the character of a metastatic process. Some, on the basis of epidemics observed singly, hold this to be the rule, and support their views by the fact that here, as in pyæmia, purulent serous exudations in the joints, pneumonia, pleuritis, &c., are frequent complications. (*Jacobi.*)

5. Finally, suppurative choroiditis occurs as a result of purulent deliquescence of intraocular tumors, as well as a termination of tuberculous localization.

The Course, until the disease has reached its hight, is almost always very acute. Only very exceptionally does the disease require some weeks to reach its highest point, and thence terminate in a subacute or chronic manner. The principal differences which are seen in the course of a suppurative choroiditis affect the character of the process, and depend for the most part on the cause.

1. Thus, a suppurative choroidal inflammation, induced by traumatic or chemical injuries, is as a rule characterized by a sthenic or even hypersthenic character. Still, there are degrees of difference here also, and it may even occur, that a traumatic suppurative choroiditis runs its course with relatively obscure symptoms.

In cataract operations we are often, indeed, deceived as to the condition of the eye. The lids merely become œdematous, are not much reddened, the conjunctiva secretes muco-pus, the pain is slight, or only occasionally troublesome, the subjective chromopsia not marked, and there is no fever; but when the eye is opened, all the signs of an already far-advanced suppurative choroidal inflammation are found.

If a foreign body be in the eye, attacks of the severest inflammation, often with agonizing pain, are interchanged with considerable remissions or even entire cessations. The disease is less often chronic in its course; its character varies for months between a subacute irido-choroiditis with prominent organizable shrinking products, and occasional exacerbations with abundant secretion of pus, until the

eye becomes quiet, at least for a time, in consequence of suppurative perforation and the removal of the foreign body, or in consequence of an enveloping of the latter by large neoplastic membranes.

2. Suppurative choroiditis, which is developed after ulcerative perforation of the cornea, seldom has a sthenic character. The symptoms of irritation are generally much milder, and the subjective symptoms especially less severe. The course is generally *subacute*.

3. The metastatic form is often developed under similar violent symptoms with the traumatic. But often the accompanying symptoms are in no proportion to the results of the process. Frequently the swelling and redness of the outer envelops of the globe may be called insignificant, and the quite sudden loss of sight calls the attention of the surgeon, and causes him to look at the condition of the inner parts of the eye, which are then generally very much changed. The globe is often destroyed in the course of a few days.

This form of suppurative choroiditis, exactly like that dependent on cerebro-spinal meningitis, is frequently binocular, either both eyes being attacked at once, or the inflammation advances from one eye to the other in the course of a few days. The remaining varieties of suppurative choroiditis generally remain confined to one eye.

Results.—Recovery, in the strict sense of the word, is very rarely possible, and then only when the opportunity for the resolution of the disturbances is afforded at the very beginning of the process, before great morbid changes have occurred. In general, we must consider ourselves satisfied, when we succeed in smothering the process in its incipiency, and if we preserve the form of the globe, or if it be only slightly diminished in size. In the greatest number of cases, the globe shrivels to a small misshapen nodule, from simple atrophy, by corresponding lessening in size of the tunics of the eye, or in consequence of true phthisis, i. e., suppurative deliquescence and partial evacuation of the contents of the globe.

Possibly, under very unfavorable conditions, pus may be taken up by the blood, and the most dangerous results occur. In isolated cases a continuation of the suppurative process to the brain has been observed, and generally with a fatal result. (*Graefe.*)

The prognosis is the most grave in the metastatic, and especially in the tuberculous form. The patient generally dies of the constitutional disease before the process in the eye has reached its termination. If, however, the patient gets off with his life, the globe is generally atrophied. In exceptional instances, when there is a very slight amount of pus formed in the globe, it becomes to a certain extent capable of again performing its functions.

In the variety of suppurative choroiditis seen in epidemic cerebro-spinal meningitis, atrophy is the ordinary result, and is often evident at an early period by a very marked softness of the globe. Still, suppurative perforation, and, as a further consequence, phthisis of the globe, has been observed. (*Lindström.*) The phthisical destruction of the globe is not always carried on in the same way. Generally the cornea is completely infiltrated throughout, is changed to a mass of pus, and deliquesces. Then the contents of the globe are to a great extent evacuated, and the remains of intraocular structure consumed and thrown out by continued suppuration. This often first occurs when the sclerotica has become in part or wholly much distended by the increased intraocular pressure. Its tension is then sometimes so great, that the bursting of the cornea takes place with an audible snap, and the

contents of the globe are spirted out to some distance. In consequence of the abnormal pressure, the circulation and nutrition are considerably affected. The cornea, with or without a part of the sclerotica, undergoes necrosis, and thus an exit is secured for the already necrosed contents of the eye-ball. Cases have also been observed, where the intraocular pus breaks away through an enlarged vessel of the sclerotica, or where the sclerotica to a greater or less extent actually sepa ated, and thus an evacuation of the chambers of the eye was rendered possible.

After the perforation, the suppuration still continues for a time. Still, the inflammatory symptoms are quickly and permanently removed. The pain, which was before often unbearable, is, as it were, cut off. But cases always occur in which, during the existence of the intraocular suppuration, a considerable swelling and redness of the conjunctiva and lids continues, and where, besides, there is great sensitiveness evident, and at times even severe pain appears. This sometimes happens in spite of free exit of the pus. If the opening becomes closed, or if its edges adhere, the inflammatory symptoms increase all the more certainly to a fresh outbreak. Sometimes the entire process is repeated, especially when a foreign body remains in the eye. Occasionally the perforation brings with it only temporary relief or none at all. The swelling and redness in the vicinity of the eye remain very great, the pain continues undiminished, or even becomes severe, rages day and night with slight intermissions, radiating over the whole head, depriving the patient of sleep, and pulling him down the more, because the terrible affection, under such circumstances, may be protracted for weeks, and even months, and is often accompanied by fever. To all this there should still be added the fact, that in the existence of severe ciliary neurosis, and especially when there is a foreign body in the eye, the other globe, by no means unfrequently, participates in the morbid process, and is destroyed by irido-choroiditis. At last the globe shrinks more and more together, the inflammatory irritation recedes, the suppuration ceases, and the perforation closes. The atrophied or phthisical stump becomes a little nodule, varying in size from a pea to a hazel-nut, with a smooth or wrinkled surface, and generally appears deeply sunken in the orbit. The lids are retracted, immovable, and closed. In young persons the orbit also becomes smaller in time, even to such a degree that the features appear markedly deformed.

Fig. 46.

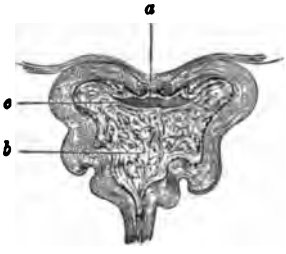

In the examination of phthisical stumps (Fig. 46), we generally find the sclerotica very much thickened, since its elements, in the process of shrinking, slide over each other, as it were. The anterior opening of the sclera is closed with a small plate, *a*, of neoplastic tissue, which is only distinguished from the normal corneal substance by its opacity and pigment, the latter being from the iris. It is very often superficially covered over by a stratum of loose connective tissue, seemingly a process of the conjunctiva. In the cavity, *b*, of the shrunken globe we find friable remains of pigmented uvea, mingled with newly-formed tendinous striæ and membranes, with clumps of amorphous nuclear masses, interspersed with fat and calcareous bodies. True osseous bodies, *c*, are also occasionally found. A tuft of connective-tissue fibers generally passes out from the atrophied optic nerve, which is lost in the pigment-mass which fills up the globe, and represents the remains of the destroyed retina.

Stumps from diffuse suppurative inflammations generally act quite differently from those which result from chronic irido-choroiditis, with membranous and

osseous formations. Still, in these latter also, as well as in the former, severe inflammations occur, which leads to new outbreaks, and may endanger the other eye from sympathetic inflammation. This is chiefly to be feared when the stump conceals a foreign body. Then the shrunken eye-ball may remain irritable for a lifetime.

Treatment.—The chief therapeutic indications are: to limit and suppress the rapidly-advancing process of proliferation, and with this to remove every thing which may excite and maintain the suppuration; furthermore, to subdue the inflammation by direct means, and, as far as possible, to favor the resolution of the morbid processes already existing.

1. The indications springing from the cause often demand, as prophylactic treatment, the extraction of a swollen cataractous lens, or an iridectomy to render it harmless, paracentesis of the cornea on account of a large hypopyon or a corneal abscess, the opening of an orbital abscess, &c. The removal of any foreign body in the quickest and most careful manner is of the greatest importance, and never to be neglected. The method of proceeding in this latter case varies, of course, according to the situation of the foreign body. If it is in the aqueous chamber, or protrudes into it so that it may be seized, it should be extracted by a linear incision united with an iridectomy; but if it adheres to the lens or capsule, the extraction of the lens by a flap-section is to be recommended, cutting out at the same time a piece of iris. This latter appears especially necessary, when the cataractous process is not yet far advanced, and when it can not be awaited on account of the threatened loosening of the fragment. If the foreign body have entered the ciliary body, and it remains fixed there (which may be readily ascertained by a probe, apart from the situation of the wound, or from the sensitiveness of the affected part), we should cut directly down upon it, and enlarge the incision to the proper direction and length for the purpose of its extraction.

If the foreign body be in the posterior part of the eye, it is first necessary to find its situation as exactly as possible. In the beginning, it may be often recognized with the ophthalmoscope, or from a dense, circumscribed opacity of the vitreous. Later, this often becomes extended, diffuse, and envelops it completely. Probing the entrance is then very dangerous, because the fragment, which perhaps lies immediately beneath it, may be easily loosened and pushed deeper into the eye. Occasionally probing the sclera with a button-headed probe is an assistance, the situation of the foreign body, in case it lies near the outer wall of the globe, being readily indicated by a marked sensitiveness of the affected portion of sclera. Occasionally this is found just opposite the point of entrance—an indication that the fragment has passed through the vitreous humor to the opposite side of the ball. In the majority of cases, however, the foreign body lies at the bottom of the vitreous humor, a little in front of the equator (*Berlin*).

If, in one way or the other, the position of the foreign body be made out with certainty, an incision should be made in the sclerotica in its immediate vicinity, most properly in a line parallel with the corneal border, avoiding the horizontal meridian of the eye on account of the course of the long ciliary vessels. A portion of the vitreous is then either of itself evacuated, or by a slight pressure, made by means of a Daviel's spoon. The foreign body often follows, or lies close to the incision, so that it can be seized. If not, there is nothing to be done but to search for it with the forceps. As a rule we appear to do better when we make for ourselves an entrance to the space occupied by the vitreous by the linear extraction of the lens (*Graefe, Berlin*). It can not be denied that, after such a procedure, especially

where there are great difficulties in the way of its extraction, and if very much vitreous escape, or free hemorrhage occurs, the eye-ball is often destroyed by suppuration. But there are always cases where some of the functions of the eye, at least its form, are preserved, and in the worst event, the suppuration proceeds more quickly, and with much milder symptoms; it does not so readily endanger the other globe, which is far less sensitive, and is less inclined to new inflammations, than when the fragment remains in the eye. In case the foreign body, in spite of every effort, can not be found and seized, a regard for the coming permanent trouble to the patient, and the danger to the other eye, will force us to consider the expediency of following up the fruitless attempts at extraction by the enucleation of the eye-ball. This operation should be taken into consideration in advance, and the patient's attention called to the possible eventual necessity for it.

The most improper course is to delay the removal of the foreign body, or to cherish the hope of its being thrown off by suppuration (*Tetzer*), or of any permanent encapsulation; because with the progress of the inflammation, especially with the new formation of dense coatings and their adhesion, which always occurs, the conditions for an extraction of the body become always more unfavorable, and finally it can not be done at all. But, furthermore, the suffering of the patient, and the danger to the other eye, may finally render the enucleation imperatively necessary.

2. The direct treatment is essentially antiphlogistic. The kind varies according to the character of the process. With slight hyperæmia, and inconsiderable œdema of the parts about the eye, when there is little or no heat, it will be sufficient, after carrying out the indications from the cause, to cover the affected eye with a dry cloth or a protective bandage. When there is more hyperæmia and swelling of the parts, and marked increase of temperature, cold applications should be made at intervals. These may be assisted, if necessary, by the local extraction of blood. When, however, the nervous irritation predominates, or the ciliary neurosis is out of proportion to the other inflammatory symptoms, warm applications are better borne. Where these are not sufficient, the use of narcotics is to be advised. In case the inflammation has a true sthenic character, the continuous and energetic use of iced applications, the repeated application of leeches, administration of cooling remedies, absolute antiphlogistic regimen, and occasionally narcotics, are necessary.

3. These means only suffice so long as the intraocular pressure is not decidedly increased, and no great secretion of pus or abundant hemorrhage has occurred in the eye. When the hardness of the globe evidently increases, or a large hypopyon is seen in the anterior chamber, we should have recourse to a paracentesis of the cornea without delay, and this operation should be repeated several times if necessary, if we wish to prevent the entire destruction of the globe. and to free the patient from the pain, which is often agonizing. If we have reason to suspect only an inextensive collection of pus or hemorrhage in the posterior part of the eye, if perhaps the sclerotica is already somewhat distended, no time is to be lost, but immediately a meridional incision, some lines in length, should be made in the sclerotica, and thus a way provided for the exit of the pus.

4. If there be no hindrance to the exit of the pus, either a pressure bandage is applied and an antiphlogistic regimen maintained, or a more strictly antiphlogistic course of treatment will be necessary, according to the severity of the inflammation. In cases in which the suppuration is already far advanced, so that phthisis of the globe seems unavoidable, warm, moist applications are especially to be advised, whatever may be the character of the process. They are pleasanter to the patient

than cold applications, they favor suppuration, and thus diminish the duration of the process.

5. If the suppuration be long continued, and threaten to impair the strength of the patient, or to found a permanent and troublesome affection, it will be perhaps justifiable to proceed to enucleation of the globe. Suspicion of the presence of a foreign body increases the indication. Still, it is always well to await the diminution of the severe inflammatory symptoms, because the operation, if undertaken during the hight of the process, readily excites excessive reaction, and in some cases has led to the death of the patient, by a continuation of the inflammation upon the retro-ocular cellular tissue and concentric meningitis. (*Graefe.*)

6. If the severity of the inflammation has very much diminished, and pus within the globe is already being absorbed, or if the suppuration has already become scanty, a simple pressure-bandage is always sufficient. This should be worn until either recovery has occurred, or the globe is contracted in a state of atrophy or phthisis. It keeps the eye from injury, limits to some extent the proliferation of tissue, favors resorption, lessens the suppurating surface, and favors adhesions of the inflamed parts lying opposite each other. Astringents should only be used when there is also a considerable relaxation and morbid secretion of the conjunctiva.

7. If the stump of the eye be very sensitive, if it really never gets perfectly quiet, if, without external cause, attacks of severe ciliary neurosis or real inflammations occur, or if the other eye threatens to be involved, the enucleation of the stump is to be urgently advised.

If in such a stump a suppurative process, with active vascular and nervous irritation, be suddenly excited, which resists the ordinary antiphlogistic remedies, it will be best to partially evacuate the contents of the globe by an incision into it. The suffering of the patient is thus often alleviated, and the inflammation, under the use of warm applications, rapidly recedes. If we have reason to fear repetitions of the attacks, we may at any time remove the stump by enucleation, without incurring the danger of excessive reaction.

Authorities.—*Graefe* und *Schweigger*, A. f. O. VI. 1. S. 134, et seq. VI. 2. P. 261, et seq.—*Graefe*, A. f. O. 1. S. 406, et seq. III. 2. S. 337 et seq. IX. 2. S. 79, kl. Mntbl. 1863. S. 456. 1865. S. 384.—*Heymann*, A. f. O. VII. 1. S. 127.—*Ed. Jaeger*, Oesterr. Zeitschft. f. pract. Heilkd. 1857. No. 2.—*Schön*, Beiträge zur prakt. Augenheilkunde. Hamburg. 1861. S. 92, 107.—*Zander* und *Geissler*, Die Verletzungen des Auges. Leipzig und Heidelberg. 1864. S. 202, 211, 213.—*Boissonneau* und *Cunier*, nach Zander, l. c. S 18.—*Rothmund*, Jahresbericht 1861-2. München. S. 19.—*Schirmer*, kl. Mntbl. 1865. S. 275, 277.—*Kreitmair*, ibid. S. 384. Aerzt. Intelligenzblatt f. Baiern. 1865. No. 21, 22.—*Knapp*, kl. Monatbl. 1865. S. 378, Canstatt's Jahresbericht. 1864. III. S. 144.—*Jacobi*, A. f. O. XI. 3 S. 156, 162, 165.—*Lindström*, according to Jacobi l. c.—*Virchow's* Archiv. X. S. 181.—*Nagel*, A. f. O. VI. 1. S. 220.—*Arlt*, Zeitschrift der Wien. Aerzte. 1859. S. 149.—*Critchett*, kl. Mntbl. 1863. S. 440. 442.—*Tetzer*, Wiener med. Jahrb. 1866. 4. S. 9. 11.—*Graefe*, A. f. O. XIV. 2. S. 120; 3. S. 146.—*Knapp*, A. f. O. XIII. 1. S. 127, 173.—*Jacobi*, ibid. XIV. 1. S. 138, 142.—*Wecker*, kl. Monatbl. 1867. S. 36.—*Biermann*, ibid. 1869. S. 146.—*Berlin*, A. f. O. XIII. 2. S. 275, 298; XIV. 2. S. 275, 279, 319, 324; Arch. f. Aug. u. Ohrenheilkunde 1. S. 150.—*Schiess-Gemuseus*, A. f. O. XIII. 2. S. 389.—*Wilson*, Prag. Vierteljahrschrift, 97. Bd. Ann. S. 66.—*Duchek*, Wien. med. Jahrb. 1868. 5, 6. S. 30, 31.—*Rudnew*, *Burzew*, Virch. Arch. 41. Bd. S. 73.

SEVENTH SECTION.

INFLAMMATION OF THE SCLERA, SCLERITIS, SCLEROTITIS.

Anatomy.—The sclerotica or sclera, the white or hard membrane of the eye, forms a tough and firm, very slightly-expansive capsule, which every where closely envelops the choroid and the ciliary body, and is organically connected with them. It consists of connective tissue, whose elements unite into broad bands which run through the whole thickness of the membrane, alternating quite regularly from a longitudinal to a horizontal direction, and thus on a perpendicular section give the appearance of a lamellar formation, the individual layers of which, however, are very intimately connected.

In general terms, we may say that in the external layers the striæ are meridional, while in the inner layers they are equatorial. Woven in with these is a fine and close net-work of elastic elements, which, as we go inward, becomes closer, and unites the sclera with the choroid. (*Henle.*) From it, numerous elastic filaments enter the choroid. Granular pigment is scattered through the tissue in clumps, which resemble in shape the stroma-cells of the uvea.

In some rare cases the pigment is heaped up in the innermost and outermost layers of the scleral tissue, so that the white of the eye has in spots a dark, bluish-gray or slate-like color (*Talko*).

At the anterior edge, the connective-tissue filaments of the sclera pass immediately into those of the cornea, and are transformed into corneal elements. There they have an almost equatorial course, and form, as it were, a firm frame around the border of the cornea. From the elastic net-work of this frame, some filaments, accompanied by vessels and nerves, pass into the cornea. In front of the ring, but still in the scleral tissue, and quite near its inner surface, the bundles of connective tissue separate, to take up the venous ciliary plexus, which has been described as the canal of Schlemm (Fig. 2, *h*), and is a thick patch of fine veins, coursing around the periphery of the cornea. On the one side it is connected with the veins of the ciliary muscle, on the other with the vascular net-work of the sclera. (*Leber.*) It is bounded by many layers of a finely-filamented elastic membrane, similar to that lining the blood-vessels. (*Henle.*)

The sclera is thickest posteriorly, just at the optic-nerve entrance, for here the outer sheath of the optic nerve becomes directly attached to the scleral tissue. Within this portion of sclera, surrounding the papilla, lies the posterior vascular zone. (*Ed. Jaeger.*) It is formed from two or more small vessels, which enter the sclera near the angle formed by the sheath of the nerve and the sclera, and, in its course around the papilla, gives branches to this as well as to the choroid, thus forming a direct communication between the ciliary and retinal vascular systems. (*Leber.*) The branches are not regularly given off; hence the zone is often imperfect, or not formed at all.

Besides the above, the sclera is perforated by a number of canals, giving passage

to the vessels and nerves of the uvea, which, like Schlemm's canal, are surrounded by a thick net-work of elastic filaments (*Henle*). At the anterior and posterior zones these vessels are particularly numerous, but are very small; they usually run perpendicular to the surface. Near the equator they are more scanty, but larger, and pass obliquely through the membrane.

The sclerotic contains many nerves, which, arranged in bundles, and anastomosing constantly with one another, form a large-meshed network. Most of these nerves, after having run for a certain distance in the sclera, perforate it, in order to reach the inner tissues. A number of them however end in the scleral tissue itself, after they have lost their medullary sheath and have ended in the finest fibres (*Helfreich*). Delicate vessels give off branches also in the sclerotic, which arise from the ciliary vessels.

The outer surface of the sclera becomes a stratum of loose connective tissue, which is more scanty, loose, and ragged, at the middle and posterior part, and is there connected with the ocular capsule. But anteriorly it has shorter, thicker filaments, and is immediately transformed into subconjunctival tissue. This may be called the episcleral layer. It contains a fine, close, vascular net-work, composed mostly of ciliary vessels. At the circumference of the cornea, the episcleral tissue is greatly developed, and very vascular, so much so, in fact, that in great hyperæmia it is protruded like a pad, and is then described as a vascular ring.

Normally, and especially in young persons, the only vessels visible are the anterior ciliary arteries, which proceed in pairs from the branches in the four recti muscles, pass forward very tortuously along these muscles, divide up once or twice, then into twelve to fifteen branches, and enter the sclera from a half to three millimetres from the margin of the cornea. Being covered by the conjunctiva, they appear dark-colored. The very delicate net-work of their anastomosing branches is only seen after irritation of the eye. If such a cause of vascular injection occurs, the otherwise invisible subconjunctival or episcleral veins also appear. They form a delicate blue or violet coloration around the cornea, in which larger branches may be distinctly traced, sometimes surrounding the cornea in arcs, at others branched; again, apparently proceeding from the sclera, they unite to large trunks, which pass directly backward and disappear in the palpebral fold. On account of the firmness of the tissue in which they lie, these vessels (veins as well as arteries) are but slightly, if at all, movable, and are thus distinguished from the superjacent vessels of the cornea, with which, however, they are partly connected. (*Leber*, *Donders*.)

Senile Changes.—Senile involution of the sclera shows itself chiefly by diminution of the elasticity peculiar to the tissue, and thus produces the changes in the states of the circulation that lead to glaucoma, when the exciting causes for it arise. The physical cause of this loss of elasticity is connected with the calcareous formations which, it is said, are never absent in the posterior part of the sclera of old people. (*Donders*.)

Nosology.—Inflammation of the sclera is characterized at first by proliferation of its peculiar connective-tissue corpuscles; these swell, their granular contents become cells, which multiply more or less rapidly by division and endogenesis, press more and more on the intercellular substance, and then on section appear in the form of nests, which are either quite irregular, or somewhat resemble connective-tissue cells, as a body and branches may be recognized in them, which anastomose with analogous branches of other nests of cells. At the same time, the intercellular substance appears but little changed. Only in acute and extensive morbid processes

does it become clouded by a molecular precipitate, and a more or less extensive separation of granular fat; then also a sort of relaxation, a kind of swelling from serous fluid, with a consequent diminution of normal resistance, and some increase of the blood-contents, is remarked. During life the existence of scleritis is often overlooked, or is first recognized by its results, such as staphyloma or atrophy.

Still, however, cases also occur where, with a rapid process of development, the peculiar tissue of the sclera, after a precedent relaxation, and molecular fatty cloudiness, is in places almost destroyed, and is then changed to an easily-torn, friable, purulent mass, which has either the character of pus or of decomposing tubercle. This substance consists entirely of cells, dividing and becoming fatty, fatty detritus and true pus-cells, but scarcely a trace is left of the true scleral elements.

It is uncertain if scleritis ever occurs independently; hitherto it has only been observed accompanying and dependent on inflammation of the neighboring vascular parts. But in connection with these processes it is a common occurrence.

In fact, every moderately severe keratitis and conjunctivitis appears to be accompanied by scleritis. It is especially rare for a blennorrhœa or diphtheritis to run its course without a perceptible development of cells occurring in the anterior parts of the sclera.

In the same way herpes of the conjunctiva is, doubtless, not rarely accompanied by proliferation of scleral connective-tissue corpuscles. Occasionally, under such circumstances, the scleral proliferation increases even to the development of true herpetic nodules. These are seated in the episcleral tissue, but sink more or less deeply into the superficial strata of the sclerotic, and are capable of various terminations; for in some cases they simply recede, in others they degenerate, become tendinous, cartilaginous, or calcareous. Sometimes they suppurate and form small conjunctival abscesses, which spread rapidly. Finally, in other cases deep ulceration occurs, which may lead to partial scleral staphyloma, or to prolapse of the uvea.

It appears that it is this process which has been by many described as *episcleritis* (*Mooren*, *Mannhardt*). Another, much more rare form of disease appears, however, to have more right to this name, which by its chronic course, by extreme obstinacy, as well as by a tendency to relapse, is very troublesome, and is distinguished by a more diffuse, yellowish, gelatinous product. The latter is developed under the appearances of slight ciliary irritation with great injection of the episcleral tissue, and œdematous swelling of the conjunctiva. It is collected in larger quantities in one or more points and here pushes up the conjunctiva of the globe (*Heymann*).

In the same way the sclera is sympathetically affected by inflammatory processes in the choroid and ciliary body, and partial chroroiditis is usually accompanied by partial scleritis, total choroiditis by inflammation of the entire sclera. Then the inflammatory change of tissue sometimes appears more in the uvea, sometimes in the sclera. The name of "sclero-choroiditis" has been appropriately used for the latter cases.

When scleritis does not lead to suppuration, it frequently leaves behind no trace of its existence; sometimes it causes some hypertrophy of the tissue, or even partial *sclerosis*. More frequently partial atrophy results, the sclera becomes thinner at the part affected, and therefore appears bluish. Very often, also, scleritis is the immediate cause of protrusion of the sclera, for the relaxation decidedly diminishes the resistance of the tissue, and thus gives a preponderance to the intra-ocular pressure. The dependence of scleritis on other diseases renders a more complete enumeration of the symptoms, causes, course, and treatment, at this time superfluous.

Authorities.—*Kölliker*, Mikrosk. Anat. Leipzig, 1852, II. S. 606.—*Henle*, Handbuch der Anat. Braunschweig, 1866, S. 588, 607.—*Leber*, Denkschriften der Wiener k. Akad. d. Wiss. 24. Bd. S. 318, 324; kl. Mntbl. 1864, S. 426; A. f. O. XI. 1, S. 35, 38, 42, 47.—*Ed. Jaeger*, Einstellungen des diopt. Apparates. Wien, 1861, S. 52, 55.—*Donders*, Vijfde Jaarlijksch Verslag, etc. Utrecht, 1864, S. 231, 260; kl. Mntbl. 1864, S. 422; A. f. O. IX. 2, S. 217.—*Schelske*, A. f. O. X. 2. S. 33.—*Wedl*, Atlas Cornea-Sclera.—*Sichel*, A. f. O. III. 2, S. 226.—*Graefe*, ibid. S. 409.—*Pagenstecher*, ibid. VII. 1, S. 117.—*Helfreich*, Ueber die Nerven der Conj. und Sclera. Würzburg, 1870, S. 24.—*Pelechin*, A. f. O. XIII. 2, S. 423.—*Winther* Experimentalstudien, etc. Erlangen, 1866, S. 13.—*Rollet*, *Iwanoff*, A. f. O. XV. 1, S. 54.—*Talko*, kl. Monatbl. 1869, S. 204, 209.—*Biermann*, ibid. S. 91, 97.—*Schiess-Gemuseus*, ibid. 1867, S. 83.—*Knapp*, A. f. O. XIII. 1, S. 136.—*Mannhardt*, ibid. XIV. 3, S. 26.—*Stavenhagen*, kl. Beob. Riga, 1868, S. 69, 77.—*Mooren*, Ophth. Beob. Berlin, 1867, S. 111.—*Heymann*, Ophthalmolog. 1868, S. 22.

Scleral Staphyloma.

Nosology.—The development of a scleral staphyloma presupposes a diminution of the normal resistance of the sclera; and secondly, a continuance of the normal intra-ocular pressure. Increase of this pressure, such as is occasionally caused by increase of the contents of the eyeball, as well as by strong simultaneous contractions of the recti muscles of the eye, decidedly favors such protrusions.

In inflammatory relaxation of the capsule of the globe the normal intra-ocular pressure suffices to produce such staphylomata. If namely the resistance of the capsule of the globe, and consequently also the resistance which the lateral pressure finds in the internal vessels, diminishes, the intra-ocular vessels, with undiminished impellant force of the blood, being undiminished, must become dilated, or exude fluid into the interior of the eye for just so long a time as the tension of the capsule of the globe is not equally balanced by the intra-ocular pressure; in other words: the internal space must increase until the cornea and sclera oppose a resistance to further stretching, it holding the balance against the intra-ocular pressure. The greater the latter, so much the more advanced must the stretching of the sclera be, before that equilibrium is produced, so much the quicker will the staphyloma be developed, and so much the more considerable will it be.

These ectasia are, however, never confined to the sclera; the corresponding portion of the choroid is always protruded with it, since sclera and choroid are intimately organically connected throughout their extent; hence the name sclero-choroidal staphyloma is more indicative. Ordinarily, however, this name is only used for those ectasia which are directly caused by inflammatory relaxation of the tissue of the membranes in question; or at least have for substratum parts altered by inflammation. They are distinguished from the *staphyloma posticum scarpæ*, which is congenital, and in which the partial diminution of resistance is due to an original fault of formation; that is, to a deficient development of the globe.

1. Sclero-choroidal Staphyloma.

Pathology and Symptoms.—Occasionally the entire sclera and choroid are protruded. In other cases the staphyloma is limited to a part of those membranes. Hence the division into total and partial sclero-choroidal staphyloma is made, and the latter, according to its seat, is called anterior, lateral, or posterior.

a. Total Sclero-choroidal Staphyloma.

This is characterized by more or less decided increase and change of form of the whole eye-ball, for usually the cornea (or a cicatrix, under the form of a keratoglobus, or cicatritial staphyloma, as the case may be, replacing the cornea), participates in the protrusion; hence for such sclero-choroidal staphylomata the names "transparent or cicatritial total staphyloma of the globe" are used.

Under such circumstances the eye-ball sometimes appears egg-shaped, with the

apex either anterior (Fig. 47) or posterior (Fig. 48), sometimes cylindrical, roundish, or quite irregular. The anterior scleral opening is almost always much enlarged, and considerable tension of the ciliary body, iris, and zonula, is thus caused. At the same time the anterior scleral zone has a less inclination to, or is even parallel to, the optic axis, so that the sclera passes into the cornea without there being any dividing furrow between them.

From the great increase in size, the eye-ball projects from the orbit, pushes out the lids, and impedes their closure. Some greatly dilated ciliary vessels appear on the surface. The sclera is thinned in proportion to its increase in surface, and as the dark fundus of the eye shows through, it has a dark-blue look. If the dioptric

Fig. 47.



Fig. 48.



media remain transparent and the light is favorable, the fundus, which has but little pigment, reflects red light, or actually sparkles (*amaurotic cat's-eye*). Vision becomes very limited, or even all perception of light may be gone.

In transparent total staphyloma, the cornea is greatly protruded, thinned, and somewhat greenish. The limbus conjunctivalis is much widened, as it participates in the staphyloma. The anterior chamber appears increased in depth and extent, and filled with pellucid, aqueous humor. The iris is often discolored by progressing atrophy. Its breadth has increased, for the original circumference becomes greater, while the sluggish or fixed pupil changes its diameter but little. Not unfrequently the iris oscillates, as it is no longer supported by the lens, which, from enlargement of the anterior scleral opening and consequent rupture of the zonula, has lost its attachments. The anterior capsule is often found cloudy from inflammatory depositions, adherent to the pupillary margin and the lens cataractous.

In total cicatricial staphyloma, of course, there is no anterior chamber, the iris having disappeared in the ectatic cicatricial tissue, which closes the globe anteriorly. Frequently the cataractous lens, which is also often chalky, is attached to the posterior wall of the cicatrix, hence is removed from its normal position. By the

gradual expansion of the anterior part of the eye-ball, the ciliary processes are ruptured, and the crystalline drawn forward.

The parts lying further back are always much atrophied in both forms of staphyloma. This depends partly on the precedent severe inflammation, partly on the expansion and tension of the membranes. This is the chief cause of the destruction of the power of vision.

The ciliary muscle is generally shrunken to a thin circular band, destitute of muscular fibers, and exactly resembling connective tissue, or it has been transformed to a stiff, hyaline, delicately-filamented substance, totally devoid of formed elements. The ciliary processes are stretched in length and breadth, separated and flattened, and where the tension of the globe is unequal they are deviated from their meridional direction and variously distorted. Their inner surface is often, though by no means always, covered with cyclitic membranes, which with villous processes project into the anterior part of the vitreous. The choroid is still preserved at some places, at least the chorio-capillaris and vasculosa as well as the lamina fusca can still be distinguished. As a rule, however, far-advanced atrophy appears every where; the vessels of the chorio-capillaris and vasculosa appear mostly or entirely destroyed. The stroma-cells are scanty, and are mostly in a state of fatty degeneration; the pigment is pale and diminished in quantity, or all gone except a few groups of granules. The basis is a delicate filamentary net-work, covered by the elastic membrane and more or less firmly attached to the sclera. Sometimes the choroid is shrunken to a thin layer of hyaline, stiff, dry substance, in which we can only see an indistinct striation, and which can only be detached from the sclera in small scales. Still, we sometimes meet cases where, as a result of precedent proliferation and subsequent atrophy, the choroid appears in places as a thick, wrinkled, irregular layer of nucleated tissue, held together by a net-work of the remains of the choroidal stroma. The elastic lamina often remains quite normal, but just as often it is thickened, and is then usually covered with numerous choloid bodies. The tapetum is always much thinned, the individual epithelial cells are separated and often form large cavities; some appear enlarged, flattened, and irregular; they are pale, their granules are distributed without order, and they are less numerous. In some places the tapetum-cells appear without pigment, shrunken, and filled with cloudy contents; in places, however, groups of cells occur loaded with pigment which, from their size and variable form, must be considered as new formations. The ciliary nerves running under the choroid are partly without medulla, hyaline and translucent, sometimes wholly destroyed. Hence diminution of sensibility of the cornea and iritic neuralgia are among the ordinary symptoms. As a rule, the retina is decidedly cloudy and anæmic, atrophied and thinned; occasionally this occurs in the immediate vicinity of the vessels, so that these appear inclosed on both sides by gauzy, translucent bands. (*Schiess.*) The limitans is often perforated. (*Wedl.*) Sometimes the retina is detached from the choroid. In other cases all that we can find of it are pigmented connective-tissue remains, which are firmly attached to the choroid. Sometimes the retina is entirely destroyed or reduced to a few ragged remains, which are attached at the optic-nerve entrance and float about the vitreous. As the optic nerve is usually atrophied, the papilla is generally much discolored. In many cases it seems excavated, as in glaucoma. The vitreous, at least its posterior half, is almost always fluid and flocculent. The anterior half is usually preserved longer, and not unfrequently contains connective-tissue new-formations. (*Wedl, Schweigger, Schiess-Gemuseus.*)

b. Partial Sclero-choroidal Staphyloma.

This appears as a bluish or slate-gray transparent projection with thin walls, more or less elevated above the surface of the surrounding sclera. It often protrudes perpendicularly, or is even pedunculated, and then appears as a sharply-bounded, round, vesicular nodule of the size of a millet-seed or a bean, whose surface is sometimes smooth, again is furrowed by projecting cross or oblique tendinous striæ, and thus it acquires the appearance of a cluster of grapes. In other cases the staphyloma presents quite a *flat* protrusion, with smooth surface and indistinct boundaries, whose diameter is sometimes scarcely a line, but is often considerable, as the anterior or posterior half of a quadrant of the sclera, or even more,

is protruded. In many cases the staphyloma forms a more or less long and broad protrusion, divided into irregular vesicles by tendinous bands, which surround a greater or less arc of the eye-ball. Such protrusions are found in the most varied zones of the sclera, e. g., in the equatorial zone (Fig. 49). But they most frequently occur in the anterior scleral zone. (Fig. 50, *b*.)

Fig. 49.

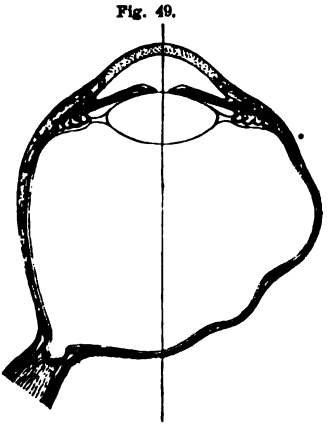

The walls of the staphyloma consist mostly of strongly-pigmented scleral tissue, which has suffered more or less from the precedent inflammation and the protrusion. It usually appears quite cloudy from molecular precipitation, and its filamentary formation is often less clear, or only sharply defined in certain directions. The inner surface of the vesicle always appears lined with a pigmented brown or black spotted, delicate membrane, which adheres closely to the remains of the uvea protruded with the sclera. This membrane can rarely be separated from the subjacent sclera. The uveal tissue in it is already quite unrecognizably atrophied to an indistinctly striated mass, without vessels or nerves. In this mass, variable amounts of pigment-cells are deposited, some of which still appear roundish, and rich in pigment; others contain little pigment, are angular, elongated, or even spun out to pigmented filaments. The elastic lamina, on whose inner wall lies the tapetum, is often still perceived. The cavity of the staphyloma is rarely filled with firm, inflammatory product, but almost always with watery fluid. Occasionally the retina stretches out free from the foot of the staphyloma. But not unfrequently there is a corresponding protrusion into the concavity of the staphyloma, to whose inner wall it is often firmly attached, spreading over it as a delicate membrane, which consists of connective-tissue filaments strewn with molecular masses, containing no trace of nervous elements or vessels, but variable amounts of pigment, and covered by the membrana limitans, which is usually ragged. (*Wedl*, *Schweigger*, *Schiess*.)

In the immediate vicinity of the staphyloma, the sclera is often found very hyperæmic, relaxed by a cloudy serous infiltration, and strewn with connective-tissue corpuscles, which have been changed by inflammation. A large portion or the whole of the choroid usually appears affected by inflammatory atrophy, particularly as evinced by great pigment rarefaction. Still, in spite of the tension to which the choroid is subjected, the vasculosa and chorio-capillaris are sometimes well preserved, the vessels of the latter are even dilated, and the tapetum-cells, although very small, are close together, thus indicating a rich new-formation. (*Schweigger*.) The larger vessels of the vasculosa terminate abruptly at the foot of the staphyloma, or pass very slightly beyond it, and then disappear. This is also true of the ciliary nerves of the lamina fusca; hence, when the staphyloma is somewhat extensive, there is a diminution of sensibility of the cornea and of motion in the iris. A large portion or the whole of the retina also is atrophied. Not unfrequently it is in places attached to the choroid, and at this part it is always atrophied to a delicate connective-tissue membrane, strewn with pigment. The optic nerve entrance often appears excavated.

On the whole, the anatomical and ophthalmoscopical examination of the eye usually shows decided traces of an extensive and severe inflammation of the uvea and retina, that has run its course, as well as cloudiness of the dioptric media, fluidity of the vitreous, &c. As a result of these changes, vision is usually entirely destroyed, or limited to a quantitative perception of light. But exceptional cases of anterior sclero-choroidal staphyloma occur, when the posterior portions of the retina have preserved their normal function, and hence only limitations of the field of vision occur.

If opacities do not hide the fundus, we readily discover such staphylomata with the ophthalmoscope, as more or less sharply bounded, irregularly pigmented spots, variously shaped, and colored dirty-grayish-white or brownish, whose prominence is often shown by the variation in the

length and form of the shadows cast by the mirror, when the latter is moved, also by the position of the retinal vessels running over it. In very extensive staphylomata the protrusion is not unfrequently evident to the naked eye by the *white reflex* from the fundus. The diagnosis, however, scarcely requires this symptom. Even *posterior* staphylomata are easily brought into view by directing the eye strongly inward or outward, and then pressing back the commissure of the lids.

Causes.—1. With some rare exceptions, this staphyloma is always the result of sclero-choroiditis, or, more accurately, of weakening of the scleral tissue and increase of the intraocular pressure accompanying the inflammation. Total sclero-choroidal staphylomata result only from a total sclero-choroiditis. Partial sclero-choroidal staphyloma, on the contrary, may proceed from a total or partial sclero-choroiditis.

a. This inflammation alone is sufficient cause for sclero-choroidal staphyloma. Ectasiæ caused by inflammation alone may occur at any point of the choroid. They are characterized by a very slight convexity of the summit and great flatness of the lateral walls, which gradually lose themselves, without decided boundaries, in the part of the sclera not protruded. This corresponds with the fact that the points of inflammation are not sharply bounded, and hence the resistance decreases only gradually toward the center of the part inflamed.

b. In many cases, passive hyperæmia of the ciliary vessels acts with inflammation in producing sclero-choroidal staphyloma; for where many vessels close together perforate the sclera, the tissue becomes more porous and less resistant. If, then, an enlargement of these vessels, and consequently of the canals through which they pass, occurs, it requires only a slight serous moistening and inflammatory softening to give even to the normal intraocular pressure a preponderance, and compel the parts of the sclera in question to give way. Ectasiæ thus produced are, as a rule, sharply bounded and have steep sides, or are pedunculated, forming strongly convex vesicles. Corresponding to the anatomical location of these points, such staphylomata are found especially in the posterior and anterior, but may occur in the middle zones of the sclera.

The ectasiæ of this kind occurring in the anterior zone of the sclera usually come in groups, and form a connected, more or less broad, cushion, which girdles the cornea in a greater of lesser arc, and hence is usually called *staphyloma annulare.*

On anatomical examination of ectasia of the latter kind, which have come to a stand-still, we find, on the inner surface of the anterior scleral zone, a number of fossæ in the inner layers, which are separated from each other by thread-like cords half a line long, belonging to that layer, and running in a meridional direction. These lead into cul-de-sacs, formed of the *outer* layers, and which from without appear as bluish, translucent swellings.

c. Sclero-choroidal *staphyloma anticum* or *annulare* often develops, however, in another way. If, during the existence of a sclero-choroiditis, the relaxation of the tissue is increased by congestion in the ciliary vessels, the thin scleral layer covering the inner side of Schlemm's canal occasionally bursts, under the increased intraocular pressure, whereupon the more extensible outer substance, which has remained uninjured, is protruded.

At the very commencement of this state, the outer surface of the scleral zone affected, appears wholly unchanged. On anatomical examination, close behind the border of Descemet's membrane, and covered by the ciliary muscle, we find in the scleral tissue a longer or shorter shallow furrow, running concentrically with the corneal margin (Fig. 50, *a*), with a somewhat serrate border, which is formed by the retracted ends of the ruptured filaments. By a continuance of the mechanical actions the furrow becomes broader, since the outer scleral layers, forming i

floor, are expanded more in a meridional direction, and so lengthen at the expense of their thickness. Finally they become translucent, and cause the appearance of a bluish arc on the anterior scleral border. During this time the furrow increases in length, and progresses at both ends to circumscribe the cornea.

Subsequently, under this tension, the outer layers of sclera bulge forward, as bluish or even blackish elongated bosses, which, separated by tendinous whitish filaments running antero-posteriorily, form a variable series of elevations and depressions, and surround a greater or less arc of the corneal periphery, in some cases even its whole circumference.

Occasionally the protrusion goes further in some places, while the furrow continues around the cornea, and constantly widens. Then, on the outer surface, the regular elongated elevations disappear, and at this point the sclera protrudes as a dirty-blue, glandular, berry or grape-like tumor, as large as a pea or a nut, *b*, which presses between the lids, and often hinders their closure, and always renders the axis of the eye oblique.

Fig. 50.

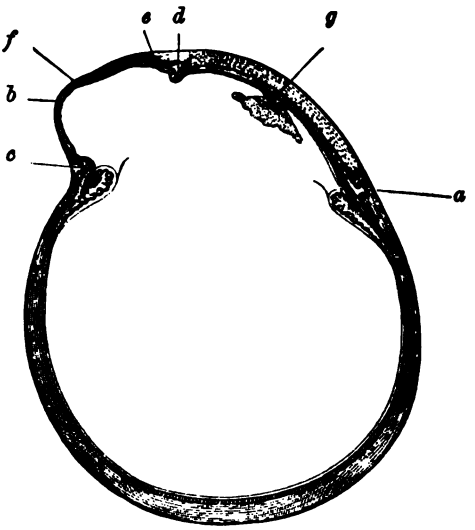

This great increase in surface of the anterior scleral zone is to be explained not only by protrusion of the scleral layers originally forming the floor of the furrow, but an addition to the scleral substance in the walls of the protrusion also occurs. For while the ruptured inner layers of the sclera are fully stretched, and the torn ends are retracted to two knobs, *c* and *d*, the external layers have to stand all the force of the intra-ocular pressure. Hence, also, the parts beyond the borders of the furrow are protruded; but as these give way to the pressure, they become separated from the subjacent parts, and the torn edges recede more and more from each other. This is especially evident at the anterior border of the staphyloma; for the anterior layers of the cornea are stretched by the tension of the outer layers of the sclera, and are not unfrequently so increased that the limbus conjunctivalis, at the part affected, reaches three or four times its normal width, while the posterior corneal layers retain their normal dimensions.

Hence, at the point of ectasia, the boundary between cornea and sclera is much widened, and finally the corneal layers separate at the foot of the staphyloma; a part of the inner wall, *e*, is formed by the exposed edges of the superficial corneal layers, and appears ragged, uneven, and translucent.

By the protrusion of the anterior scleral zone, the parts immediately connected with it (the vessels, nerves, and ciliary body) suffer, as may be easily understood. The vessels and nerves in the ectasia, atrophy, are totally destroyed, or are at least ruptured. In far-advanced ectasia the ciliary body is occasionally torn through transversely, so that the heads of the ciliary processes cling fast to the iris on the anterior, the rest of the body to the posterior, edge of the rupture. The separation more frequently occurs between the iris and ciliary body, so that the former remains attached to the anterior, the latter to the posterior, border of the rupture. Sometimes, however, the rupture occurs in the anterior choroidal zone, so that the iris and corpus ciliare appear drawn forward. The ciliary muscle is always ruptured except in these latter cases. The ruptured margins of the uvea are connected together by a fine, pigmented membrane, *f*, which covers the posterior wall of the staphyloma, and consists of prolapsed remains of uvea.

2. In some rare cases, superficial ulcerative loss of substance in the sclera is the cause of partial sclero-choroidal staphyloma. In proportion to the diminution in thickness of the sclera affected, the resistance decreases, the floor of the ulcer and subjacent uvea is protruded, pressed forward into a vesicle, which can not retract, and therefore becomes permanent. If the surround-

ing portions of sclera are inflamed, they also give way; the base of the staphyloma becom larger than the original ulcer was.

3. Just as rarely, it is caused by a rupture of the sclera and prolapse of the uve The rupture may be of ulcerative origin. More frequently it is from a penetratin wound of the sclera. The uvea thus exposed is pressed outward by the contents o the globe, becomes vesicular, commences to proliferate, to form fleshy granulation which gradually change to tendinous tissue, and finally give the wall of the staphylom the appearance of true scleral tissue. Such staphylomata are sometimes roundis sometimes oval, according to the shape of the rupture; in linear openings it is usuall pad-like; at its base it usually appears pedunculated. (*Traumatic sclero-choroida staphyloma, Sichel.*)

According to the position of the perforation, the prolapsed portion of uvea i sometimes choroid, sometimes ciliary body or iris. It is to be remarked that, even in perforations of the sclera quite a distance from the corneal margin, the iris may be prolapsed. The pupil then appears drawn out toward the perforation, like a coloboma. Often a part of the whole breadth of the iris and its pupillary margin grow fast to the scleral opening.

Course.—As a result of acute processes which progress with great intensity, sclero-choroidal staphyloma occasionally develops very rapidly, and is then usually accompanied by severe pain, and not unfrequently with subjective perceptions of light. Under such circumstances the ectasia occasionally reaches a considerable size in the course of a month, and then, while the original disease becomes chronic it remains stationary, or gradually progresses.

But, as a rule, the formation and growth of sclero-choroidal staphyloma is slow It often even happens that the original inflammatory affection has already existed a long time, or has even receded before the ectasia shows itself. When this has happened, months and years often pass before an increase is perceptible. The increase is sometimes gradual, sometimes spasmodic. The latter occurs especially when the chronic sclero-choroiditis causing it has frequent exacerbations.

During such apparently acute attacks, the ectasia usually grows rapidly, with severe pain, but when remissions occur, it becomes stationary, or even recedes somewhat, to increase again with the next exacerbation. Such cases greatly threaten a sympathetic affection, and subsequent loss of the second eye by irido-choroiditis.

Results.—A true spontaneous cure is scarcely to be expected. It is only recent prolapse of the choroid that can recede, as the neoplastic tissue, developing on and in it, shrinks and contracts to a flat cicatrix. As a rule, we have cause to be thankful when, after years of suffering, the globe finally becomes quiet, the inflammatory attacks remain absent, and the protrusion does not advance, since the intraocular tissues, through atrophy, lose their inclination to inflame.

Frequently the inflammatory process is propagated along the optic nerve, and then occasionally causes quite insupportable photophobia. The final result is usually atrophy of the optic, frequently with excavation of the papilla. Not very unfrequently, during severe inflammatory exacerbations, suppuration occurs, and subsequently phthisis bulbi. Occasionally also, as a result of atrophy, the globe becomes soft, and later, shrinks up.

Besides this, a rupture of the prolapsed sclera is possible. This has been observed most frequently in partial staphyloma, and only very rarely in total. The most com

mon cause was a decided momentary increase of intraocular pressure, as by a blow on the eye, or a strong contraction of the muscles. More rarely it is spontaneous. After the bursting, a great part of the contents of the globe is evacuated, and, as a result of the sudden decrease of intraocular pressure, profuse hemorrhage not unfrequently occurs. This may continue for hours and days, and may even kill the patient, if it is not stopped soon enough. Severe inflammations, which cause the globe to shrink by suppuration or atrophy, are the usual results of such ruptures. Still, the edges of the wound may again heal up, and the staphyloma again appear; this may even be repeated several times before suppuration or atrophy occurs.

These hemorrhages, in connection with the bluish color and the external form of the partial staphyloma, were the cause of the belief that it was a varicose condition, and it received the name of cirsophthalmus.

Cancerous formations do not belong to the results, but to the possible causes, of sclero-choroidal staphyloma.

Treatment.—The chief indications are, to oppose the inflammation affecting the tissue, and diminish the intraocular tension to or below the normal amount. Iridectomy, with suitable after-treatment, best fulfills this indication.

1. As a prophylactic, the formation of an artificial pupil should never be neglected, when, during a choroiditis, the globe appears harder, or severe pain indicates tension of the nerves, or even if the commencement of an ectasia is already perceptible. Paracentesis cornea, even if repeated, gives less certain results, as its action is more transient. Future observation must decide how far division of the ciliary muscle answers the purpose.

To avoid prolapse of the uvea, in rupture of the sclera, it is best to keep the patient in bed, and put on a protective bandage; or, when the inflammation is very intense, to institute a regular antiphlogistic treatment. Attempts at replacement are almost always fruitless, and often dangerous, on account of the irritation that they cause.

In very small and quite recent prolapses, we may, however, occasionally succeed in causing a retraction of the prolapsed part by slight friction over the globe, by moving the fingers back and forth over the closed lids. These small prolapses, however, especially when the perforation is linear and short, are not very dangerous. They are usually again flattened out by shrinking of their neoplastic envelop.

The removal of prolapses in extensive perforation, by curved scissors, after the previous division of the uninjured conjunctiva over them, is the most certain, in fact the only advisable, remedy. The after-treatment consists in wearing a protective bandage, and in avoiding strong muscular contractions, and at first keeping in bed. This is to be persevered in till the consolidation of the cicatrix.

Cauterizations of the prolapse with nitrate of silver, laudanum, etc., apart from their irritation and power of exciting severe inflammation, are dangerous, because the pain accompanying them is apt to induce strong contraction of the muscles of the eye.

2. If sclero-choroidal staphyloma is once developed, it can only be removed by operation.

a. In small staphylomata which are not old, iridectomy, and subsequently wearing a protective bandage, often suffices to cause the entire removal of the ectasia. Most frequently, however, the staphyloma develops again on the same spot, or near it. Iridectomy, with one or more paracenteses of the protruded sclera, offers somewhat more certainty; still, even this does not always avoid relapses.

b. In old, extensive staphylomata, and especially in those with steep walls, iridectomy with paracentesis does not always suffice. With the iridectomy, the splitting of the prolapsed portion, or even its removal, is frequently necessary. In staphylomata of slight prominence, the splitting may best be done with a cataract-knife,

which divides the walls in a meridional direction; in those with steep walls, it is best done with a lance-shaped knife, which is laid flat on the sclera, and then so advanced that its point enters at the base of the staphyloma, and comes out at the opposite side.

For the removal, a cataract-knife serves best, as, in excision of corneal staphyloma, the knife is passed flatwise through the corneal wall, so that a flap is formed, which is seized with the forceps, and removed with the scissors. It is not necessary to take off the entire staphyloma; in extensive ectasia this would be dangerous. In general, the opening left should not exceed the circumference of a small pea. If, during the splitting or removal of the staphyloma, only a little vitreous escape, a protective bandage is sufficient; but if a large amount of the contents of the globe is evacuated, and, as a consequence, the eye-ball collapses, the bandage must be applied tighter, to replace in some degree the lost intraocular tension, and prevent, as far as possible, excessive hemorrhage and inflammation. This danger can not be altogether avoided; it is not even rare that, immediately after opening the wall, large vascular branches burst and cause extravasations, which fill a large part of the eye-ball, and, as they collect between the retina and choroid, or between the latter and the sclera, lift up the inner membrane to a purse-shape. In some cases the membrane, covering the continually-increasing extravasation, ruptures, the blood empties into the cavity of the eye, and presses outward through the scleral opening, sometimes to a frightful amount. Then all means for arresting the exhausting hemorrhage are usually fruitless; if we would avoid endangering the life of the patient, we should immediately enucleate the eye. In other cases, however, the resistance offered by the detached choroid or retina suffices to stop the hemorrhage. The extensive extravasation then usually leads to loss of the eye by suppuration.

Quiet of the patient is decidedly advantageous, and especially the avoidance of strain on the muscles of the eye; hence, it is advisable to keep him in bed at first. Prudence also recommends antiphlogistic diet, even if no inflammation is present, requiring direct treatment. The bandage must not be removed, or the patient allowed to return to his ordinary employment, till the cicatrix is consolidated.

After splitting, it often happens that the edges of the wound heal rapidly, and the staphyloma again appears in its former shape and size. Then a repetition of the operation becomes necessary. Some authors recommend cauterizing the staphyloma, after the irritation has passed, to produce greater development of tissue and a firmer cicatrix. Where reaction is slight, a careful cauterization with nitrate of silver, repeated two or three times weekly, may favor the results of the operation.

In favorable cases, after the removal, the scleral opening soon closes over with a gray, cloudy membrane, which thickens and gradually contracts; occasionally fleshy warts develop, and hard, firm cicatrices form, whose extent is usually less than the scleral opening was. If this new formation goes on too slowly, it may be aided by applications of laudanum or nitrate of silver when there is no irritation present. (*Sichel.*)

c. In total staphyloma it is occasionally possible to restore the globe to nearly normal size and form, by an iridectomy and repeated paracentesis of the sclera, or by excision of a small lance-shaped flap from the wall of the sclera. But just as often this operation is without result, or leads to intraocular hemorrhage and severe inflammation, which, as above stated, may prove dangerous.

Phthisis of the globe is of itself no particular loss; it may even be regarded as a gain, when the eye on its occurrence becomes quiet and is freed from painful inflammatory relapses; besides, the stump permits the subsequent application of an artificial eye, and gives it some mobility.

With this idea, it has again been recently recommended to bring about suppuration of the globe, by passing a thread through the sclera and vitreous at the ciliary region, and leaving it there from one to four days—that is, till chemosis appears as the first sign of a commencing suppurative choroiditis. (*Camper*, *Ford.*) The entrance and exit should be in the ciliary region, and about three lines apart. (*Graefe.*)

We must, however, remember that the suppurative process does not always run on quite smoothly. Apart from the possible danger of pyæmia, the suppuration often continues for a long while, with great pain to the patient; it may sympathetically endanger the other eye, and even imperil the patient, from the great loss of fluids. Moreover, suppuration does not insure the certainty of complete atrophy and the prevention of relapses.

d. In view of the danger incurred and the doubtful results of this operation, we can not too strongly warn against its being thoughtlessly undertaken. It is only justifiable when cosmetic interests render it very necessary.

3. Where repeated relapses, constantly-recurring attacks of pain, or troublesome photopsia, render the state unendurable, and still more when there is danger of sympathetic inflammation of the other eye, or if this has already occurred, the uncertainty of the result, and the possibility of a continuance of the irritation after the above operations, render them of doubtful propriety, or even to be rejected. Then all aims at cosmetic effect should cease, and the eye-ball should be immediately enucleated. This operation has the advantage of certainly and rapidly attaining the end without causing great danger. The chief objection, viz. that the subsequent application of an artificial eye is more difficult, does not always hold good, but is only true when the fat bolster of the orbit has been compressed and atrophied by the continued expansion of the eye-ball.

Authorities.—*Ammon*, Klin. Darstellugen etc. I. Berlin. 1837. Taf. 3, 4, 7, 10.—*Stellwag*, Zeitschft. der Wiener Aerzte. 1852. II. S. 305, Wien. med. Wochenschft. 1864. Nr. 11, Ophth. II. S. 711, 716, 718.—*Wedl*, Atlas, Cornea-Sclera, Iris-Choroidea.—*Graefe*, A. f. O. II. 1. S. 242, 245. 249, IV. 2. S. 156, IX. 2. S. 105, 109.—*Sichel*, ibid. III. 2. S. 211, et seq.—*H. Müller*, ibid. IV. 1. S. 364, 365.—*Schweigger*, ibid. V. 2. S. 219, IX. 1. S. 192, 197, 198.—*Graefe* und *Schweigger*, ibid. VI. 1. S. 156, 158, 160, 166.—*Althof*, ibid. VIII. 1. S. 114, 122.—*Schiess-Gemuseus*, Virchow's Archiv. 24. Bd. S. 561, A. f. O. IX. 3. S. 171, et seq. XI. 2. S. 47, et seq.—*Iwanoff*, ibid. XI. 1. S. 144, 145.—*Ed. Jaeger*, Zeitschft. der. Wien. Aerzte. 1858. S. 487.—*Arlt*, ibid. 1859. S. 148.—*Pagenstecher* und *Sämisch*, Kl. Beobachtungen. Weisbaden 1861. II. S. 87, 89.—*Camper*, *Ford*, nach Himly, Krankheiten und Missbildungen. II. Berlin, 1843. S. 194.—*Graefe*, A. f. O. XII. 2. S. 151, 155; XV. 3. S. 136; kl. Monatbl. 1868. S. 165.

2. Posterior Staphyloma of the Sclera.

Pathology.—The substratum of this ectasia is, originally, that small ring-shaped zone of the inner scleral fibrous layer which closes anteriorly the interval between the two optic sheaths. (Fig. 26, *Ed. Jaeger.*) The protrusion begins almost always at a point in the outer half of the zone, and thence gradually progresses upward and downward along the circumference of the optic disc. The zone in question becomes broader, and acquires a resemblance to a crescent, whose inner concave border is immediately in contact with the connective-tissue ring of the optic papilla, while the corresponding part of the interval between the sheaths undergoes an equivalent opening, and, in a meridional section (Fig. 51, after *Ed. Jaeger*), appears knobbed, *a*, or slit-like, *b*. With further growth of the ectasia, the crescent (also called conus) usually acquires the shape of a rounded, pointed arc, since the extension takes place more rapidly in a meridiona than in a circular direction. Sometimes, however, the superficial contour of the crescent is more like a section of a circle or ellipse, or it is quite irregular, or even bulged out in places. At the same time, under the intraocular pressure, the walls of the crescent recede, and so narrow again the interval between the sheaths; finally the anterior and posterior walls of the horizontal part of the slit come partly or entirely in contact. If the tension goes still further, the two walls of the horizontal part of the slit unite, and, with progressive increase of surface and corresponding decrease of thickness, are bulged out posteriorly. When the ectasia at the outer border of the optic-nerve entrance has progressed to a certain extent, so that the external scleral layer evidently participates in the expansion, the inner half of the zone is not unfrequently affected, a second crescent forming there. This is at first small, and not readily distinguished from the connective-tissue ring, but it soon widens and gradually protrudes its two horns. These horns finally unite with those of the outer crescent, and the staphyloma appears as a ring, that is wider at its inner and outer part, and surrounds the optic papilla. (*Ed. Jaeger.*)

Fig. 51.

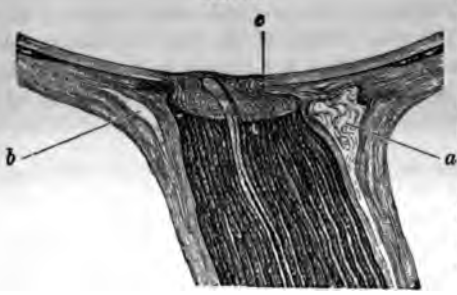

The greatest width of the external crescent is generally below, rarely in or above, the horizontal meridian of the eye. If two cones exist, they usually lie exactly opposite each other, so that their greatest breadths fall in the same meridian. A solitary cone is rarely found at the inner side of the papilla, and cones at the upper or lower border are still more rare (*Ed. Jaeger*, *Manthner*).

The increase in surface of the affected zone is necessarily accompanied by a change in form of the posterior half of the eye-ball. But circumstances greatly

modify these changes. It is different in simple and double, in small and broad, cones. Thus, in extensive posterior scleral staphylomata, the polar portion of the sclera is sometimes much flattened (Fig. 52), sometimes the eye-ball runs to a point at the optic-nerve entrance (Fig. 53). In extensive double crescent the posterior end of the globe appears bulged out like a bladder (Fig. 54). As ectasia is not accompanied by a coincident increase of the equatorial diameter, an elongation of the optic axis always

Fig. 52. Fig. 53. Fig. 54.

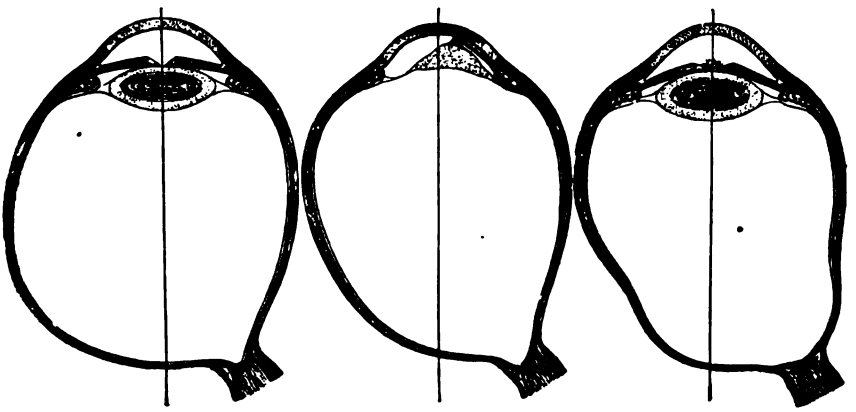

occurs. The portion of membranes corresponding to the yellow spot moves backward and to the side, so that the relative positions of the optic and corneal axes are altered. At the same time the position of the optic disc is changed, the papilla stands at an angle to the optic axis, and somewhat recedes if the crescent is double.

The tissue of the sclera in the crescent does not appear decidedly changed; the filamentary elements give only a more or less *striated* appearance.

It is different with the choroid; this atrophies as far as the staphyloma extends. For as its posterior surface is firmly united with the inner scleral wall, especially in the region of the yellow spot, it must take an intimate part in the ectasia, without the local tension thus caused being decreased by the addition of neighboring portions, and the disturbance of its nutrition being thus annulled. Atrophy first occurs in the pigment-cells of the tapetum. Their coloring matter is partially destroyed and chemically changed, while the cells themselves become larger and flatter. Finally the latter are destroyed, leaving heaps of free pigment. At the borders of the crescent the cells collect, at least their pigment increases, and the coloring matter becomes darker, often black. As a result of this, the very tense portion of choroid covering the conus at first appears as a delicate, dirty-brownish and darkly-clouded or marbled membrane, in which some vessels of the vasculosa and remains of the chorio-capillaris may still be recognized. The stroma-cells often continue to exist for some time, but their coloring matter becomes more scanty and paler, and finally disappears. If the development of the staphyloma progresses, the ectatic choroid entirely changes its anatomical character; it is reduced to a very fine, indistinctly-striated, often almost homogeneous, membrane, which is with difficulty separated from the subjacent sclera. Here and there it contains groups of pigment and empty cells, deformed by pressure, and some vessels affected in their caliber and walls, and mostly covered over with ectatic remains of the lamina elastica.

Inflammatory products and their derivatives, which are found here and there over the crescent (*H. Müller*), do not result from the disease itself, but depend on a complicating process of proliferation.

In sclerectasia of a lower grade and slower development, the parts of sclera and choroid lying outside of the conus usually preserve their integrity, or at most we only find some choroidal hyperæmia. In rapidly-developing staphyloma posticum, even if of low grade, there is, as a rule, congestion of the neighboring portions of choroid. Subsequently at this point the choroid appears slightly atrophied, and in large ectasia the atrophy is marked even throughout a considerable space; at least the tapetum is pale and uneven. It is usually simple atrophy, and depends on the tension of the membrane, and especially on the local disturbance of circulation, necessarily caused by the separation of the scleral elements and the consequent displacement and contraction of the posterior opening for the vessels. Sometimes, and particularly when the process advances rapidly, the tension causes actual inflammation, which appears as sclero-choroiditis, and not unfrequently leads to sclero-choroidal staphyloma. Indeed, about the yellow spot, these enlargements are often observed. They occasionally develop quite early, even before the crescent has attained any considerable size.

The same is true of the retina. If the ectasia develops slowly and only to a low grade, the expansion incident to the increase of the posterior wall of the globe is more easily divided up, and the elements of the retina have time to accommodate themselves to the new circumstances; hence the process is usually uninjurious to the nutrition and function of the membrane. But if the ectasia has reached a large size or has developed rapidly, the posterior portions of the retina almost always suffer, as is shown by the diminution of sharpness of vision, &c. In certain excessive cases the atrophy is very marked, the retina over the conus appears, even to the naked eye, much thinned, and under the microscope it is found reduced to a delicate connective-tissue net, without a trace of nervous elements, covered by the limitans, which is perforated in some places. (*Wedl.*) The tension often causes severe irritation, with great hyperæmia and even scattered retinal extravasations; even inflammations not unfrequently occur; these are usually exudative, or cause detachment of the retina. The inflammations also mostly affect the vicinity of the yellow spot, and the part lying between it and the papilla, because the macula lutea clings very closely to the choroid, and hence the tension is greater at this point, as the axis of the conus usually falls in this direction, and a compensating traction from the neighboring parts is more difficult.

Generally the retina stretches freely over the ectatic portion of the fundus. If this is excavated, the retina over it occasionally appears slightly concave; that is, it projects into the cavity of the staphyloma, which is filled with a watery liquid. Exceptionally, the retina is found attached by exudation to the edge of the ectasia.

In recent, and particularly in rapidly-developed, ectasia, the optic papilla is often very hyperæmic; otherwise it and its connective-tissue envelop do not show much change, except in extensive staphylomata.

The prominence which the inner nervous sheath forms in its passage to the anterior scleral layer, and over which the tubes of the optic nerve curve to pass into the retina, with the arc of choroid attached to it, recedes at the base of the crescent, or is even drawn outward in the direction of the axis of the latter. The result of this is that the filaments of the optic nerve, going to the conus, are curved as soon as they escape from the lamina cribrosa. In extreme cases, even the whole of the posterior

choroidal opening is displaced toward the conus, so that the nervous tubes directed toward the latter are sharply bent at the fibrous ring, and the porus opticus falls at the edge of the choroidal opening (Fig. 51, *c*, *Ed. Jaeger*).

In ectasiæ of a higher degree of development, the vitreous is not uncommonly cloudy in its posterior part and separated from the retina by a fluid, serous-like product. The vitreous does not increase in volume, when the posterior chamber of the eye is increased in size by the staphyloma, but the space is filled by a watery transudation, which detaches the vitreous from the limiting membrane, and separates the latter not uncommonly from the subjacent retina, in the form of small elevations (*Iwanoff*). A cataractous opacity has often been observed in the posterior pole of the lens.

Symptoms.—The existence of posterior staphyloma is always most certainly determined by the ophthalmoscope. Its commencement usually betrays itself by collections of pigment at the affected arc of the posterior choroidal opening. This dark border then divides into two or three concentric arcs, or simply recedes from the connective-tissue ring of the optic-nerve entrance, and the ectatic scleral zone appears as a bright, small seam, which gradually widens and takes on a crescentic (*chro. lith.*, A, E, T) or quite irregular form. If the staphylomatous protrusion continues, the outer border of the crescent continually recedes from the edge of the optic-nerve entrance, the conus acquires the appearance of a pointed arch (*chro. lith.*, R), or with a section of an oval (*chro. lith.*, G) or circle, or it is irregularly bulged out (*chro. lith.*, S). Usually, large cones pass beyond the diameter of the optic disc, or even surround the latter like a ring (Fig. 55); it even not unfrequently happens that the arc of the ring, diametrically opposite to the crescent, is also widened, forms a crescent, pointed arc, &c.; hence a double crescent is perceived. (Fig. 56.)

Fig. 55.

Fig. 56.

1. Recent and rapidly-formed crescents are not usually very characteristically distinguished from the surrounding parts of the fundus. The tendinously white surface of the ectatic sclera looks quite dull through the thinned choroid, which still contains pigment and vessels. It appears covered with a more or less thick, grayish-

brown or brownish-red powder, in which dark, cloudy figures, often also groups of blackish pigment, rather large vessels from the vasculosa, and occasionally small blood extravasations, may be seen. The part of the choroid affected with atrophy is not sharply defined from the neighboring normal part of the fundus, but forms a quite irregular, zigzag, and blurred zone, behind which the border of the crescent is with difficulty recognized.

If the staphyloma has existed long, and progressed slowly, the conus appears very bright and very bluish-white, on account of far-advanced atrophy of the superjacent choroid, and thus strongly contrasts with its surroundings (*chro. lith.*, G), especially when it is bordered by dark pigment. Still, the color is not always *regular;* the crescent is often clouded, brownish, or gray, in places strewn with groups of dark pigment, or it has the marbled appearance peculiar to a senile choroid (*chro. lith.*, E, R). Delicate branches of vessels are also occasionally perceived, which may appear at any point of the conus, and pass quickly to its edge, there to disappear in the choroid.

Occasionally, on the surface of the bright figure, we may observe quite irregularly-formed shady spots, which are somewhat modified in shape and position by change of direction of the light thrown in by the mirror. They indicate excavations in the crescent, and consequently elevations on the staphyloma. More frequently, a crescentic shadow is observed, which is sometimes nearer, sometimes further from, the outer edge of the crescent, and is also influenced in position and shape by the direction of incident light. It is a sign of protrusion backward of the staphyloma wall. This protrusion may, moreover, be recognized from the fact that, while it exists, the retinal vessels run some distance above the surface of the crescent, or, in case the retina participates in the protrusion, they curve backward, again to resume their original direction at the edge of the conus.

In extensive posterior staphyloma, on ophthalmoscopic examination, the optic disc usually appears oval (*chro. lith.*, G, R, S, Fig. 55), for its outer wall is then displaced backward, and its surface presents itself to the eye of the examiner at a great angle.

Still, it is said that this change of shape is not simply apparent, and caused by the conditions of projection, but that it actually exists. (*Liebreich*, *Donders.*)

The ophthalmoscopic appearance is of course also modified by pathological changes in the vitreous, lens, the part of choroid surrounding the staphyloma, &c. We most frequently find extensive choroidal atrophy, the results of exudative neuro-retinitis, &c. (*Chro. lith.*, E, E, G, R, S, Fig. 55.)

In rapidly-growing ectasia, in the vicinity of the crescent, the vessels of the vasculosa frequently appear very distinctly, are enlarged, and, like reddening of the papilla, indicate congestion. (Fig. 56, *chro. lith.*, R.)

2. Extensive posterior scleral staphyloma may frequently also be diagnosticated without the ophthalmoscope. If the patient turns the eye inward as far as possible, and we press the outer commissure and neighboring conjunctiva back, we may quite distinctly see the blue, translucent, and even pad-like prominent zone, at the border of the optic-nerve entrance. In highly-developed posterior staphyloma, the elongation, and consequent protrusion of the eye, often also its oblique position and disturbed mobility, are so decided, that they are even observed at a distance, and permit a diagnosis at the first glance.

3. The development of the posterior scleral staphyloma is always connected with an increase of the refraction, on account of the displacement backwards of the center of the retina caused by it. Eyes of a high degree of hypermetropia become thus

hymetropic in a less degree, emmetropic or myopic; emmetropic eyes on the contrary become myopic, and in myopic eyes the degree of myopia increases.

4. Otherwise the functions of vision are far less disturbed in posterior staphyloma than we should suppose from the anatomical and ophthalmoscopical appearances. Low degrees of ectasia usually betray themselves by no subjective symptoms, and even extensive staphylomata, which envelop the papilla in more than half its circumference, are not necessarily connected with great disturbance of vision referable to them. The rule usually holds good, that equal degrees of development of the staphyloma disturb vision the more easily and more decidedly, the more rapidly they have occurred. In suddenly occurring posterior scleral staphyloma, even when not extensive, such disturbances almost always occur. They are of very different sorts, and in special cases combine very variously.

Sometimes we have the recognized symptoms of congestion of the retina and choroid, or those of a more or less advanced hyperæsthesia of the retina and optic nerve and the ciliary system.

Movable and fixed scotomata occur very frequently, and are very annoying. These are immediately caused by proliferation of the cells of the vitreous, but ultimately, like the above-mentioned diseased states, by protrusion of the retina and choroid, and the consequent disturbance of circulation and nervous irritation.

Among the disturbances of vision directly caused by the staphylomatous formation, belongs especially the enlargement of the blind spot. This results immediately from the material changes which the retina in the territory of the staphyloma undergoes in rapidly-developed or far-advanced ectasia, and which may at first be defined as a separation of the elements sensitive to light, but later becomes a true atrophy of the nervous portions. Perhaps, also, the short curvature of the nervous tubes coming from the lamina cribrosa, and the displaced border of the bacillar layer toward the crescent, is a chief cause. At the commencement, moreover, the enlargement of the blind spot is not particularly remarked; it is rather filled in by the pigment, and only appears on careful attention, when sharp and clear perceptions are required. It then often appears as a very thin mist, covering parts of the object lying outward from the point of fixation. Subsequently, however, the parts in question of the visual field become more and more indistinct; an actual interruption occurs, which follows the patient constantly in the shape of a vacant spot, and materially interferes with reading, writing, &c., although central vision may not be in the least disturbed.

Staphyloma often causes metamorphopsia also. Patients see objects, or parts of objects, lying in certain sections of the visual field, distorted in certain directions, sometimes also interrupted, and the parts shoved up against each other. This displacement is especially noticed in lines and in bodies composed of lines. There is ground for supposing this to be due to change of position of the rods and cones, and for referring this to the irregular tension on certain retinal layers, especially on the central portions, which are firmly adherent to the choroid.

In large staphylomata, the great expansion and consequent disturbance of nutrition of the retina, usually cause decided decrease of sharpness in the whole field of vision, and also interruptions and limitations of the latter. Cases are not rare where vision is even limited to quantitative perception of light, or complete amaurosis exists.

Causes.—The predisposition to staphyloma posticum is probably congenital, and is to be sought in a slighter firmness of the seam which closes up the fissure of the fœtal eye. The circumstance that the staphyloma, with few exceptions, begins at the external and lower circumference of the sheath of the optic nerve, indicates this; therefore at a point which corresponds to the position of the cleft in the fœtal eye, and to the so-called "protuberantia scleroticæ" (*Ammon*). The exquisite hereditary character of the affection, which has been wrongly denied (*H. Cohn*), can also be brought forward as proof of this view.

Trustworthy investigations of a large number of children have proved that the staphyloma posticum is disproportionately frequent in the descendants of myopic parents, and that the position and the special form of the staphyloma in mother and child, even in the different brothers and sisters, and in both eyes of one and the same individual, are often remarkably similar, or even exactly alike (*Ed. Jaeger*).

It appears that eyes with an elongated axis are more disposed to it; at least the staphyloma posticum is found in such eyes in a remarkably high percentage of cases. Still the staphyloma in question is developed usually in every form of eye, and if it appears in the greater number of cases to be united with myopia, the reason is that the elongation of the axis of the globe thus produced carries along with it an increase of the refraction. In fact we meet with the staphyloma posticum by no means rarely in eyes decidedly hypermetropic (*Dobrowolsky*); the elongation of the axis is not sufficiently great in order to change the highly hypermetropic globe into an emmetropic or a myopic one.

The staphyloma posticum is without a doubt favored and occasioned in its development by congestive conditions of the posterior scleral zone. The latter are, under certain conditions, to be referred to disturbances of circulation in the region of ramification of the superior vena cava. Their chiefest and most frequent source is found in the long-continued and violent straining of the accommodation of the eyes. It is a fixed fact that the staphyloma posticum occurs but *very seldom* in the lower classes of the population, especially in half-civilized countries, where the school education is very slight, and is generally entirely neglected by the majority of individuals. It even occurs but rarely among such people when a high degree of myopia exists. On the contrary, according to exact statistical investigations (*H. Cohn*), the frequency and the degree of development of the staphyloma posticum increase with the amount and duration of the efforts to which the eyes during life at school are exposed.

It is, however, also known that in such overworked eyes a considerable hyperæmia of the entrance of the optic nerve is almost constantly present, which propagates itself without a doubt by the natural vascular connections to the posterior scleral zone, and can here so much the more easily occasion a relaxation of the parts, as the region of the posterior scleral circulation is removed from the regulating influence of the elastic capsule of the globe.

More recently it is believed that a prominent part in the production of the staphyloma posticum should be attributed to the action of the ciliary muscle, whose longitudinal fibers are usually very highly developed in very myopic eyes, upon the posterior line of insertion of the choroid (*Horner*, *Iwanoff*). Still opposed to this view is the fact that the staphyloma in question is developed primarily, with few exceptions, merely on the external circumference of the papilla, therefore exactly in that position in which the ciliary muscle can produce the least effect, since it is here the farthest removed from the optic papilla, and its action, moreover, is made ineffective by the tolerably firm attachment of the choroid to the sclerotic in the neigh-

borhood of the macula, even when otherwise the effect of its contraction were in a condition to propagate itself through the very extensible choroid up to the edge of the papilla.

The observation of cases in which the staphyloma in question manifests itself immediately from the commencement with the appearances of an advancing intra-ocular inflammation, or its consequences, with opacities of the retina or vitreous, with excavations of the optic nerve, etc., has led to the error, that an inflammation was the source of the staphyloma posticum (*Graefe*, *Heymann*)—an error which is already refuted by the fact that products of proliferation and appearances of inflammation as a rule are wanting in the staphyloma in question, and that on the contrary primary sclero-choroiditis very seldom gives rise to staphyloma posticum.

Course and Results.—The first symptoms of the staphyloma often appear in infancy (*Ed. Jaeger*). The further development after birth is in many cases exceedingly slow, and very frequently interrupted, so that it requires many years for its full development. In other cases, however, it progresses very rapidly, and then reaches a high grade in a short time. (See Course and Results of *Myopia.*)

The staphyloma may become stationary at any stage. Not unfrequently cases occur where staphylomata exist unchanged from earliest youth to old age. A disappearance of an ectasia once developed, even if of the lowest grade, is scarcely to be hoped for; at least no such cases are reported. But occasionally large vesicular staphylomata burst, their watery contents are diffused in the orbit, but are soon absorbed, while the amaurotic globe shrinks and decreases in size.

The greater distensibility of the sclerotic, which is manifested in staphyloma posticum, is on the whole unfavorable to increase of intra-ocular pressure, and hence glaucomatous processes occur very seldom in such eyes, particularly when they are of a myopic formation. Still the posterior scleral staphyloma by no means offers security against subsequent sclerosis of the sclerotic, and may cause even obstruction of some venous vessels by the stretching of the posterior scleral ring, and thus lead to increase of the intra-ocular pressure.

The detachment of the retina, which not unfrequently occurs, is most to be feared, as it is usually injurious to both eyes, and causes them finally to atrophy. Hemorrhages in the vicinity of the yellow spot not unfrequently occur (*chro. lith.*, R), especially if the ectasia increases rapidly. They are mostly from the vasculosa, and depend on the rupture of vessels caused by the excessive local tension. Still, the elastic membrane often ruptures, and the blood presses under the retina or even into its tissue, breaking it up. Inflammation always occurs in the vicinity of the hemorrhage, and the consequent changes in the retinal tissue forbid all hope of complete restoration of functional activity. As a rule, a central interruption of vision remains.

Treatment.—In very myopic eyes, attention must, from the first, be paid to the great danger of scleral protrusion, and every thing must be avoided that may cause congestion or an increase of intraocular pressure. (See Treatment of *Short-sightedness.*)

If the ectasia has already shown itself, and is progressing, of course the eyes must be most carefully used till the process is arrested. If the development is rapid, or if the disease has already caused disturbance of vision, the danger to the functional integrity of the retina is so increased, that all other considerations must give way, and, the possible results being explained to the patient, he must, in every way, be urged to protect the eyes. He should lay aside his customary glasses, and avoid every effort of accommodation, dazzling light and strong contrasts in illumination, as well as every thing that may cause local congestion.

Intercurrent congestions increase the indications for strict care, and are to be treated most carefully on general principles.

But we must warn against repeated and large local blood-lettings. Their advantage is problematical, and their effect on the general health of the patient is often bad. The same is true of mercurials.

Irritating foot-baths and laxative mineral waters, moderately used, at least do no harm, if they do not benefit.

Iridectomy has already proved incapable of arresting the progress of the ectasia. (*Graefe.*) It is, however, proper, if, with some increased hardness of the globe, the optic-nerve entrance begins to be excavated. Repeated paracenteses of the cornea are dangerous, and therefore are to be avoided. (*Secondi.*) The division of the ciliary muscle is certainly of no more benefit than a well-done iridectomy; it is at the same time more difficult and dangerous.

Authorities.—*Scarpa*, Trattato d. princ. mal. d. occhi. Pavia. 1816. II. S. 146.—*Ammon*, Zeitschift. f. Ophth. I. S. 55, II. S. 248; Klin. Darstellungen, &c. I. Berlin, 1837. Taf. 7; A. f. O. IV. 1. S. 40.—*Stellwag*, Ophth. II. S. 723.—*Ed. Jaeger*, Einstellungen des dioptr. Apparates. Wien. 1861. S. 25, 33, 42, 46, 50, 54, 62, 70.—*Donders*, Die Anomalien der Refraction und Acc. Wien. 1866. S. 296, 302, 304, 306, 311, 313, 316, 318, 322, 324, 330, 332, 337.—*Graefe*, A. f. O. I. 1. S. 390, 394, 397, 399, I. 2. S. 307, 309, 310, II. 2. S. 241, 294, III. 2. S. 394, 396, IV. 2. S. 153, 155, VIII. 2. S. 304, 306.—*Heymann*, ibid. II. 2. S. 131, 134.—*Sichel*, ibid. III. 2. S. 234, 243.—*Schweigger*, ibid. IX. 1. S. 194, 196; Verlesgn. über den Gebrauch des Augenspiegels Berlin, 1864. S. 81, 84.—*H. Müller*, Verhandlgn. der Würzburg. phys. med. Gesellschft. 1858. 8. Mai. c.—*Wedl*, Atlas, Iris-Choroidea, Retina-Opticus.—*Liebreich*, A. f. O. VII. 2. S. 124; Atlas der Ophth. Berlin. 1863, Taf. 3.—*Coccius*, Ueber Glaucom. Entzündg. &c. Leipzig. 1859. S. 40.—*Secondi*, Clinica oc di Genova. Riassunto. Torino, 1865. S. 49.—*Stellwag*, der intraoc. Druck. 1868. S. 58.—*Ed. Jaeger*, Handatlas, Fig. 41–43, 59, 60, 109–128.—*Graefe*, A. f. O. XV. 3. S. 173.—*Heymann*, Ophthalmologisches. 1868. S. 27.—*Coccius*, der Mechan. d. Acc. Leipzig, 1868. S. 71, 84, 87.—*H. Cohn*, Untersuchungen von 10060 Schulkindern, Leipzig, 1867. S. 60; Berlin. kl. Wochenschrift, 1867. No. 50; 1868. No. 50.—*Dobrowlski*, kl. Monatbl. 1868. Beilage. S. 99, 193.—*Power*, Lancet, 1868. 1. S. 16.—*Mauthner*, Lehrb. d. Ophthscop. Wien, 1868. S. 419–426.—*Iwanoff*, A. f. O. XV. 2. S. 31, 55, 58; XV. 3. S. 295.—*Horner*, ibid.

EIGHTH SECTION.

INFLAMMATION OF THE CONJUNCTIVA. CONJUNCTIVITIS, SYNDESMITIS.

Anatomy.—The conjunctiva is a mucous membrane. It begins as the immediate continuation of the external integument on the edges of the lids, and, as palpebral conjunctiva, covers the posterior surface of the eyelids. Close to the orbital border its course is interrupted, and it extends over the globe as a reflection of the conjunctiva. Here it unites closely with the sclerotica, and covers its anterior half from near the equator up to the border of the cornea, having the name of conjunctiva of the globe—ocular conjunctiva. It even passes over the outermost border of the sclerotica, and appears upon the cornea as a small border—*limbus conjunctivalis.* It here completely unites with the corneal tissue. The portion of the reflection corresponding to the inner angle of the lid appears in the form of a crescentic fold, the *plica semilunaris.* The lachrymal caruncle rests upon the anterior part of this fold. The caruncle is a conglomeration of hair-follicles, held together by connective tissue, with rosette-shaped sebaceous glands, and fat-cells lying between.

This is united by a bundle of tendinous fibres to the capsule of the eye, at the place in which the latter is perforated by the rectus internus (*Luschka*).

The conjunctiva consists of reticulated connective tissue, the chief constituents of which are the so-called connective-tissue corpuscles, and a loose fibrous intercellular substance situated between them. In the first period of childhood this tissue is tolerably clear; later, however, it appears, particularly in the tarsal and retro-tarsal portions, interspersed with numerous lymphoid cells, and thus gains an adenoid character (*Henle*). Anteriorly the tissue is condensed into a compact basal membrane, which is covered by several layers of epithelium, generally of a cylindrical shape.

The connective tissue corpuscles are spindle-shaped or stellate nucleated cells, from the walls of which proceed a number of very fine, tubular, ramifying processes, which anastomose with similar processes of neighboring connective-tissue corpuscles, and thus form a kind of network, the mesh-knots of which are represented by the cells themselves. The intercellular substance is transparent, homogeneous, but scissile in certain directions, by which it gains the appearance of being composed of matted bundles of very fine, wavy, contorted fibres, running parallel to one another. Mingled with these elements are found elastic fibres in varying quantity. The epithelium consists in the most inferior layers of round cells, in the more superficial layers however of cells, which approach decidedly the cylindrical form, are however somewhat flattened, and thus represent transitions to those of squamous epithelium (*Wolfring*). In the region of the conjunctiva palpebrarum, ridged or thorny cells have been demonstrated (*M. Schultze*).

Each of the separately named portions of the conjunctiva has its anatomical peculiarities. The conjunctiva of the lid consists of a dense layer of connective tissue corresponding to the cutis, which is closely connected with the posterior surface of the cartilage of the lid, since a number of the short, straight fibres proceed brush-like from the latter to the conjunctival tissue (*Wolfring*). Still, both tissues are very plainly distinguished in fine sections by the remarkably dark tint which the conjunctiva receives from the enormous number of lymphoid bodies embedded in

it. The surface of the tarsal conjunctiva is interspersed with numerous furrows, or indentations, running in all directions, very often crossing each other, sometimes deep, sometimes shallow, sometimes running perpendicularly, sometimes obliquely, ending here and there in blind extremities, which in transverse sections resemble very strongly glandular spaces, and in fact have been regarded as such. In children these furrows and indentations are still but slightly developed; in adults however they are very sharply defined (*Stieda, Wolfring*). Towards the border of the eyelid, where the conjunctiva is very thin and is closely united with the tarsus, they appear denser, more numerous, and very flat; towards the convex border of the tarsus they become less numerous, but are deeper; upon the tarsal border itself, where the conjunctiva is thicker and only more loosely attached to the tarsus, they commence to pass directly into the deep furrows, which separate the folds of the retro-tarsal portion from one another, and are generally arranged parallel to the border of the tarsus. In a similar degree we find the conjunctiva directly upon the free border of the lid, also still perfectly smooth, and close by are seen the smallest papillary elevations, which can scarcely be perceived, even with the lens; further on towards the retro-tarsal portion of the conjunctiva, and towards the angle of the eye, they become gradually larger, until they finally can be seen even with the naked eye, and pass into the folds of the mucous membrane on the convex border of the tarsus. It is usual to describe the elevations as papillæ; but strictly speaking this character does not fit them. At any rate, the loop-like endings of the vessels are wanting in them; the division of the vessels is everywhere rather more uniformly net-like. (*Stieda, Wolfring.*) The retro-tarsal portion of the conjunctiva is much more loosely woven, particularly richly interspersed with lymphoid cells (*Blumberg*), thicker, and is connected with the orbital tissue, particularly with its fascia-like condensed portions, by a very long-fibered, wide-meshed, flocculent connective tissue, which admits of considerable displacement. Instead of the papillary elevations, deep furrows are found upon its surface, as was already mentioned, the largest of which run tolerably parallel to the tarsal border, and cause the portion of connective tissue under consideration to appear transversely folded.

Inside the furrows of the tarsal and retro-tarsal portions, the cylinder shape of the epithelial cells is generally somewhat more sharply defined than on the surface of the elevations, which is much more exposed to pressure of the lid and to scratching. Between the epithelial cells of the conjunctiva, very numerous circular spaces, of the form of a bottle, very much bulged out, are often found, which open upon the free surface by a very narrow neck, and are brought into nearer connection with the secretion of mucus. They are usually described as cup-cells (*Stieda, F. E. Schultze, Eimer, Fries*). In addition to these occur a number of compound, grape-shaped glands in the retro-tarsal portion, which lie in the sub-conjunctival tissue, open by long excretory ducts obliquely upon the surface, and correspond in their entire structure to the lachrymal gland, and hence are also described as accessory lachrymal glands (*Krause*).

[NOTE.—*Recapitulation of the minute anatomy of the conjunctiva.* The palpebral conjunctiva consists of a basement membrane or mucosa, covered by an epithelium disposed in three or four layers, the superficial ones being flattened, the deeper ones approaching the columnar in shape. The surface is flat and perforated by the openings of blind intestinal-like glands which are embedded in the mucosa. The walls of these glands are formed by convolutions of the basement membrane, and they are lined by cylindrical epithelium. At the retro-tarsal fold the pavement epithelium is changed into the cylindrical form, and the papillæ, which are rarely found on the tarsal portion, become prominent. The glandular culs-de-sac become larger and we meet with two new kinds of glands. The one is constant, *acinous* in nature, and are most numerous near the openings of the lachrymal ducts; they are lenticular in shape and lined with pavement epithelium. The second variety are conglomerate, tubercular in shape,

and are found singly, or in groups along the fornix. As the conjunctiva passes on to the globe, the epithelium again becomes squamous, and the whole conjunctiva is thinner. There are here no papillæ, and but few glands. Thus we see that the conjunctival structure consists of the so-called adenoid tissue, that is, of a mesh-work of connective-tissue fibers, with a large number of cells resembling lymph corpuscles.]

The ocular or sclerotical conjunctiva is less tough and thick than that of the lids. It contains many elastic fibers, and is loosely and movably attached to the membrane of the globe, covering the anterior zone of the sclerotica by a connective tissue, containing fat-cells in varying quantity. There are no papillæ or glands on this portion. On the other hand, the epithelium is strongly developed, and is continued uninterruptedly upon the cornea.

The vessels are abundant in all portions of the conjunctiva, especially on the tarsal portions and limbus conjunctivalis. These are divided into anterior and posterior vessels. The former supply the zone next to the ocular conjunctiva, and are most intimately connected with the episcleral vessels, and are ultimately branches of the anterior ciliary arteries. The posterior conjunctival vessels supply the posterior zone of the ocular conjunctiva, the reflection, and the tarsal portion.

Its arterial twigs are branches of the vessels of the lids and the lachrymal glands, and also receive accessions from the angular, the temporal, and infra-orbital arteries. The veins pass for the most part over into the vena angularis, and to the temporal veins. They also anastomose with the orbital veins. The posterior conjunctival vessels are connected with the anterior, and through these with the ciliary system; an immediate connection with the latter, however, does not exist, or it is exceedingly slight. (*Leber.*) The anatomy explains the existence of the so-called vascular ring, that is, the dense injection of the most anterior zone of the episclera and ocular conjunctiva, in irritation and inflammations in the cornea, iris, and the ciliary region.

The arterial branches supplying the conjunctiva of the lid proceed for the most part from the arterial arches, situated upon the anterior surface of the tarsus, perforate the cartilage, and run upon its internal surface parallel to the meibomian glands, giving off a quantity of small branches, part of which run backward to the tarsal glands, and part enter the papillary elevations of the conjunctiva. The veins of this region take an exactly similar course (*Wolfring*).

The injection is apt to be greatest in the *limbus conjunctivalis*. Here it is seen as an evenly red little band, sharply bounded anteriorly, and lying on the corneal margin. The episcleral vascular tissue is more strongly developed in its immediate vicinity; a large number of small arteries bend around and run into the limbus, which, deprived of the sub-conjunctival tissue, lies immediately on the cornea. It gives off at the same time a number of little branches, which unite with each other in arches. Smaller branches proceed from these arches, which again unite by anastomosis, and thus form an exceedingly dense network, which reaches to the central margin of the conjunctival layer, and on the one hand serves as the origin of the peripheral, looped network of the cornea, but on the other transmits numerous branches to the conjunctiva, and is connected to the posterior conjunctival vessels by means of its ramifications. The finest terminal loops of the network in the limbus pass into veins, are collected in fine branches, which, in a similar manner, are woven into a thick mesh-work, and empty chiefly into the scleral twigs of the anterior ciliary veins, allowing, however, a proportionately slight amount of blood to pass into the peripheral conjunctival veins (*Leber*).

Lymphatic vessels are very numerous in the conjunctiva. They are said to form a thick network on the margin of the cornea, which extends toward this in a great number of slightly curved arches. On its periphery a large lymphatic vessel has been seen, which passes around the corneal margin in quite a regular circle. From this a great number of branches

are said to pass over to the cornea, while on the other side branches run backward, and open into actual lymphatic twigs, which are subsequently united to the sub-maxillary glands (*W. Krause, Mauchle*).

It appears that they open freely in the interstices of the connective tissue (*Billroth, Tomsa.*)

The conjunctiva is also richly supplied with nerves, especially the palpebral portion, the *limbus conjunctivalis*. The reflection has less. They arise chiefly from the fifth nerve (*tri-facial*).

These enter the posterior portion of the conjunctiva, near both angles of the eye, compressed into two large bundles, ramify rapidly, and spread out over the entire conjunctival sac. In the most anterior layers they form a wide-meshed texture, which is situated partly beneath, partly above the capillary layer, and gives off a large number of fine fibers without medulla, which run horizontally directly beneath the epithelium for some distance, in a slightly tortuous course, give off some few branches, and finally as a rule end free, without entering the epithelium itself (*Helfreich*). In the scleral conjunctiva and in the semi-lunar fold, club-shaped terminations occur, even though few in number (*Kölliker*). In many papillary elevations some individual nerve fibers are said to pass over into tactile bodies (*Krause*).

The unequal division of the conjunctival nerves is the cause of the palpebral conjunctiva appearing most sensitive, while the retro-tarsal fold displays a lower degree of sensibility, so that foreign bodies may lie there for a long time without causing pain. These nerves are connected very closely in function with the other branches of the trigeminus, particularly with the ciliary nerves, and by these indirectly with the retina and optic nerve. Hence great irritation of the conjunctival nerves easily lead to hyperæsthesia of the ciliary and optic nerves, and vice versa.

The secretion of the conjunctiva is not only mucus, but also the lachrymal fluid. We may properly say that a greater part of the tears constantly covering the conjunctival sac have their origin in the conjunctival vessels. The conjunctiva has a great power of resorption, on account of the vascular richness of the conjunctival tissue.

Nosology.—A. The inflammation in the conjunctiva, as elsewhere, is characterized by enormous exudation of white blood corpuscles from the vessels and by increase of the latter by proliferation. The young cells appear densely packed together along the walls of the vessels, and form in the deeper layers of the conjunctiva more or less thick rows, which branch frequently, and by anastomosing with one another form a species of network, the wide meshes of which are filled with the connective tissue, infiltrated with serum, and sparsely interspersed with exuded cells. Anteriorly the meshes become narrower, the tissue of the conjunctiva constantly becomes more displaced, and near the surface its place is completely supplied by a layer of young cells varying in thickness, which follows all the elevations and excavations, and is separated from the over-lying, extremely swollen integument merely by the basic membrane. This in its deeper layers is formed in great part or entirely of young cells of a lymphoid character, and only the superficial strata remind us, by their angular, flattened form, of epithelial structures. When the inflammatory process is more intense, however, this difference disappears in the epidermal layers, and for a certain distance the basic membrane is also often destroyed in spots, so that the infiltration of the connective-tissue structure and the cellular layer which replaces the epithelium form a single connected stratum, which can often be perceived with the naked eye, and at some distance, as an opaque precipitate upon the conjunctival surface.

1. The outermost layers of this stratum become constantly loosened. This excretion of neoplastic elements is the more extensive, the more rapidly the process

runs its course, the more luxuriant is the proliferation of tissue; that is, the more quickly new elements press upon them from the deeper layers.

In less severe inflammations, the newly-formed cells which are thrown off have chiefly the character of recent epithelial cells. They are, however, in part, presented under the microscope as mucous corpuscles, recognizable by their opaque contents and their disproportionably small nucleus. As the process increases in severity, the elements become more and more removed from the epithelial form. They generally change into mucus or pus-corpuscles. In very severe cases, real nuclear cells at last cease to form. The neoplastic elements appear as incompletely developed nuclei, which are involved in rapid separation, or often in fatty degeneration.

At the same time an intercellular substance is always separated, which, as it were, represents the menstruum in which the elements are suspended. This intercellular substance also varies in an extraordinary manner in quantity and properties, according to the intensity of the process at the time, and thus influences the quality and quantity of the so-called inflammatory secretion. This latter is nothing less than a mixture of the intercellular substance with the described elements, thrown off from the surface of the conjunctiva.

In the lowest degree of intensity of the inflammatory process, the excretion of the intercellular substance and of the cells is scanty, and exhibits all the properties of mucus. The secretion rolls up in a ball, and does not mix with the tears. The mucus is thicker and more transparent, the more slowly the process advances. When the course is speedier and the inflammation more intense, the mucous-basis becomes more turbid, the secretion is striated from the increase of mucus and pus-cells, which have been thrown off, or it becomes completely opaque from a large mixture of pus-corpuscles, and of an even whitish-yellow or greenish-gray color (*catarrhal secretion*).

When the inflammatory process is very severe, not only is there an abundant production of pus-elements, but also a large excretion of intercellular substance. The latter loses its consistency and becomes thinner. It does not, however, lose its capability of being drawn out into threads, and does not mix with the tears. The secretion, which runs over the conjunctival sac in great quantity, appears of the consistency of thin mucus, evenly turbid and greenish-yellow, or perfectly opaque and of a purulent yellow color (*blennorrhœal secretion*).

When the inflammation is at its hight, the mucous character of the intercellular substance completely disappears. This becomes a thin fluid, opaque from molecular masses and fatty detritus, and *mixes with the tears*. According as the quantity of pus-elements which it contains is greater or smaller, the secretion is then seen as a creamy, thickened pus dissolved in the tears, sometimes of a grayish-white or yellowish color, a whey or broth-like fluid (*pyorrhœal secretion*).

2. A greater or less quantity of neoplastic intercellular substance is produced in the deeper layers as well as in the surface of the inflamed conjunctiva. This exudes, to some extent, and increases the mass of the morbid secretion. It is also infiltrated in the tissue of the conjunctiva, and, together with the increase in volume of the connective-tissue corpuscles and with the hyperæmic distention of the vessels, causes a marked swelling of the membrane. The infiltration can never be very great in the palpebral portion, on account of the tenseness of the conjunctival and subconjunctival tissue, and on account of the pressure which is exerted upon the latter. But it may appear in the reflection, and in the ocular conjunctiva where the loose-

ness of the tissue, and the lessened external pressure, render the intumescence much easier. In fact, we generally find the palpebral folds very much swollen. On everting the lids it appears as one broad swelling, or several smaller ones lying parallel to each other. This swelling is sometimes so broad as to render the return of the lids to their normal position difficult. In the same way the ocular conjunctiva is sometimes enlarged to double its normal size or more, and presses out from the palpebral fissure. It is not unfrequently even pressed forward, and forms a great swelling, which renders the closure of the lids troublesome, and partly or wholly covers the cornea.

In less severe forms of the inflammatory swelling, conjunctivitis is only marked in the reflection, and is even then often very slight. In the severe and severest forms, however, it is usually very great, and is not confined to the conjunctiva and the sub-conjunctival connective tissue, but attacks the lids and surrounding parts. If, then, the swelling is very tense, if it is deeply and evenly red, and also very hot and sensitive, we call the condition *chemosis.*

The swelling of the conjunctiva and of its neighboring parts is, in rare instances, very great in slight cases. This frequently occurs in children and in adults with a relaxed, wrinkled skin. But then the infiltration does not bear the inflammatory character, and it has very few firm component parts. It is a pure serum, and the condition is to be considered as a true œdema.

The swelling is apt to increase until the morbid process has reached its hight. When it has once passed the acme, the infiltration generally decreases, the swelling recedes, the conjunctiva wrinkles, becomes soft, its tissue relaxed, while the vessels remain enlarged and injected. The neoplastic elements finally degenerate, the connective-tissue corpuscles and their branches assume their normal appearance. The intercellular substance is reduced to its natural size with complete absorption of the infiltration. The vessels contract, the superficial cellular layer atrophies and throws off the superfluous material, and attains exactly the character of normal epithelium, with higher formation of the cells.

The secretion is not necessarily immediately decreased in quantity in the beginning of the relaxation. On the contrary, we may not unfrequently observe an evanescent and slight increase in the secretion. This occurs either because the circulation and the nutrition are favored by the diminution of the swelling and of the pressure exerted upon the conjunctiva, or the relaxation of the tissue alone favors the secretion. As the process still further recedes the secretion is always less, the pus-corpuscles disappear from the secretion, and are replaced by mucous corpuscles and cells with larger nuclei; the mucous basis becomes thicker, cellular, and more transparent, until, finally, the quantity and quality of the secretion corresponds to the normal conjunctival mucus.

8. Yet the conjunctiva does not always return to its normal condition in the manner above described. On the contrary, it very often occurs that neoplastic elements are more completely formed in proportion as proliferation of tissue ceases. In consequence of this, the conjunctiva becomes entirely hypertrophied.

The proliferating process may also produce a very similar result, if its intensity does not advance beyond a certain degree. The new formation is apt to be most striking in the tarsal portion of the conjunctiva. This swells somewhat in consequence of the process of proliferation, and wart-like elevations are seen on its sur-

face, which are the characteristic evidences of the appearance of trachoma or granular ophthalmia. When not highly developed, they resemble the normal papillæ very much, and are therefore described as papillary granulations. In the higher stages of development, these growths have a very great resemblance to granulations on suppurative wounds. They run together, and the name "diffuse granulations" may be given them.

Such growths do not occur in the reflected portion (palpebral fold). It seems as if their formation were connected with the presence of the papillæ. The conjunctiva in the reflection is a delicate, velvety membrane, which swells more or less. But this intumescence is not regular. We very easily recognize on the surface of the swollen palpebral fold a number of small longitudinal swellings, running nearly parallel, which appear to be crossed by shallow furrows, and thus look as if they were composed of a number of granules lying in rows, whose summits only project from the conjunctiva, while their bodies are embedded in the parenchyma. They there unite with each other and the hypertrophied stroma of the conjunctiva, without any distinct boundaries. We may distinguish these inequalities by the name *trachomatous bodies.*

Neither granulations nor round granules are developed in the ocular conjunctiva. The hypertrophic increase is there always regular, and, as a rule, comparatively small.

The surface of the trachomatous conjunctiva appears under the microscope to be covered with a thick layer of young cells, which follows all inequalities of surface, and hence in perpendicular sections seems to be thrown into very irregular folds, cutting deep into the tissue. The elements of the most external layer bear the epithelial character, particularly in the older cases, which run a more chronic course. Those of the succeeding stratum are, by reason of their minuteness and circular form, still less removed from the type of formation-cells of the youngest period of life. In the innermost layer the neoplastic cells are already full-grown, are of an oval and fusiform shape, already in part possess processes, are arranged in rows, exhibit, moreover, traces of a striped intercellular substance, and are traversed by a thick network of newly-formed capillaries. They thus, therefore, indicate indubitably the transition to vascularized connective tissue. This granulation layer is usually thickest in the region of the tarsal conjunctiva, and raises here, moreover, not uncommonly, warty, club-shaped, sometimes even cauliflower-like outgrowths, which increase very considerably the roughness already existing. In the retro-tarsal fold this layer recedes somewhat more, and usually has a tolerably uniform thickness. Posteriorly it is continued into the subjacent adenoid tissue of the conjunctiva, in the form of branched framework. The lymphoid cells appear in the latter considerably increased, and are crowded together in the looser portions, particularly in the papillary elevations of the conjunctiva of the lid, and in the folds of the retro-tarsal portion, in the form of nests (*Wolfring, Blumberg*). These nests are often sharply defined from the surrounding tissue by a thin layer of condensed connective tissue, in which a rich vascular network ramifies, and then by reason of their circular form show a great similarity to swollen glandular follicles, for which they have actually, for a long time, been mistaken. Still their basis is nothing more than a meshwork of connective tissue, poor in vessels, which, like the envelope, owes its form only to the displacement by the crowding together of the cells. In addition to this, it happens that the envelope is frequently only demonstrable upon the side turned towards the surface, or is entirely wanting, and hence

the cell-nest without distinct limit is lost in the surrounding tissue. Inside the nests ramify lymphatic vessels, which are connected with the trunks running in the conjunctiva (*Wolfring.*)

The lymphoid groups of cells increase very much the circumference of the papillary excrescences in the region of the tarsal conjunctiva. In the retro-tarsal fold, where they are usually most enormously developed, and the overlying granulation layer is less thick, they form the actual groundwork of the trachomatous granules, and determine their form and size. As a rule they are completely covered by the highly vascularized granulation layer, the diseased conjunctiva shows everywhere a tolerably uniform redness, which is more or less modified with gray by the greater or lesser thickness of the overlying stratum of epithelium. Not uncommonly, however, larger quantities of a gelatinous intercellular substance or of a serous fluid are secreted inside the lymphoid cell-nests. The trachomatous granules then increase, of course, very considerably in extent, and may also cause a thinning of the granulation layer covering them by pressure, and deprive it in part of its vascular contents. The consequence is that the lymphoid nests of cells now project very much above the surface of the conjunctiva as pale, semi-circular, brawny, or lymphoid, transparent granules of the size of mustard or hemp seed, which resemble very strongly the eggs of frogs or fish-spawn.

These spawn-like granules are frequently found alone in the reflection, and few in number, or scattered together with typical trachoma of the previously-described variety. They generally appear interspersed between the opaque granules, and from the very many transition forms, we may readily see that the former are really nothing but modifications of the latter. But occasionally the reflection is also infiltrated with such a gelatinous material, and its surface is so thickly covered with the spawn-like granules, that the bases of these are flattened out, and the interstices entirely disappear.

The remaining portions of the conjunctiva may, at the same time, be altered in a very similar manner, as in the usual form of trachoma; or there may merely be recognized the symptoms of a slight catarrh of the tarsal conjunctiva, with inconsiderable swelling of the papillary elevation; or, finally, the conjunctiva of the globe and lids is traversed by a very loose vascular network, and is infiltrated by a gelatinous or serous fluid like the retro-tarsal portion.

The pure spawn-like trachoma has been declared to be a peculiar kind of conjunctival inflammation, and distinction made between trachoma proper, and that form accompanied by papillary granulation, to which some give the name of chronic blennorrhœa (*Piringer*, *Arlt*). Not much can be urged against this, since the line of distinction between the different varieties of conjunctivitis must always remain somewhat arbitrary. It is probably more correct to recognize in the two forms named the terminal links of the connective chain of modifications of one and the same process.

The frog-spawn granules occur on the reflection by far most frequently in typical papillary trachoma of the tarsal conjunctiva, and by this difference render imperatively necessary the maintenance of an intermediate form, the mixed trachoma. It is also not to be overlooked that severe cases of papillary and mixed trachoma, when they become old with the development of the spawn-like granules, pass over very readily into gelatinous degeneration of the conjunctival tissue.

The proliferation of tissue is in cases of higher degree by no means to be limited to the conjunctiva in the narrow sense of the word. The loose sub-conjunctival tissue suffers in the same way, and very commonly is enormously distended by brawny infiltration. Moreover, the inflammation is easily propagated to the cornea, causing

the appearances of keratitis vasculosa. It also frequently encroaches upon the cartilage of the lid, the tissue of which becomes richly interspersed with lymphoid cells, particularly in the vascular neighborhood of the glandular follicles (*Wolfring*); the intercellular substance swells up, becomes looser, more juicy, and the tarsus by these means not uncommonly becomes so softened, that under the pressure of the conjunctival swelling it spreads out considerably in all directions.

4. In rare cases the whole conjunctiva is involved in a chronic process of proliferation; it becomes relaxed throughout its whole thickness, and changes into a condylomatous-looking tissue, which bleeds easily. From its rough, velvet-like surface relaxed, vascular, or pale, whitish-gray tumors of different size proceed, which rapidly unite with the parts of the conjunctival surface lying opposite, and are generally soon continued upon the cornea, which has been previously infiltrated and partially ulcerated on its surface. The process advances for weeks and months without cessation, no kind of treatment having any especial influence upon it. At last the conjunctiva shrivels to a tough, tendinous tissue, and is so shortened that the palpebral fissure becomes a small slit, which is coated with fibrous masses. The result is then XEROPHTHALMIA. We may also designate the process by the name of degenerative conjunctivitis.

It seems that the disease has been very recently described as *lupus of the conjunctiva*. (*Arlt.*) The distinct line of demarcation on the edge of the lid argues against the idea of a lupous nature. If at any time a lupous affection occurs at the same time on the facial integument, it may depend on mere chance.

5. In the forms of conjunctivitis thus far described, the intercellular substance developed with and from the proliferating cells seems to have a relatively small amount of coagulable component parts. It is then partly effused on the surface of the conjunctiva, and has the character of mucus, or of a turbid fluid (*secretory form*). It is partially infiltrated into the tissue, and is either absorbed or gradually thickens, and is finally changed into connective-tissue stroma (*hypertrophying form*). In certain cases, where there exists a severe proliferating process, the newly-formed intercellular substance is exceedingly rich in plastic material. It coagulates very rapidly, and, in union with the neoplastic cell-elements, exhibits a tough, unyielding, morbid product.

a. Occasionally, it is only in the superficial vascular layers of the conjunctiva that the excretion of such a rigid mass occurs. In the deeper layers of the conjunctiva a gelatinous product, or even one like serum, having very little plastic material, is excreted. This rigid, coagulable, fibrinous material, analogous to intercellular substance, envelops the superficial proliferating cell-strata, and presents itself under the form of membranous patches of greater or less thickness. These lie upon the conjunctival surface, and are closely united to this, since numerous filamentous processes extend into the conjunctival tissue, so that a separation is only possible by exciting bleeding from the parenchyma. These patches are characteristic marks of the so-called *membranous conjunctivitis*. They are frequently extended over the entire conjunctiva, but more frequently appear at intervals, while on the remaining portions of the conjunctival surface the intercellular substance appears as mucus.

Here the intimate relation of membranous conjunctivitis to the secretory form is seen. This relation is also shown by the fact, that the latter is often developed from the former; and that, on the other hand, membranous conjunctivitis often passes over into the secretory form of the tissue-proliferating process, or changes indirectly into a trachoma.

b. In other cases, which are quite rare, when the inflammatory process is very severe, not only is this rigid product excreted upon the surface, but the tissue of the conjunctiva and even the subconjunctival tissue becomes infiltrated to such an extent, by a rapidly coagulating material, that it presses upon the vessels. The parenchyma, thus deprived of blood, becomes pale, and not unfrequently is partly destroyed from lack of nutrition. The greatest quantity is generally produced on the most vascular portion of the conjunctiva, especially where there are papillæ. Occasionally, thick exudation-patches are formed, and the tarsal conjunctiva becomes, as in trachoma, rough from papillary excrescences (*diphtheritic conjunctivitis*).

The diphtheritic product presents itself, according to more recent investigations, upon the mucous membrane of the larynx, microscopically, as a bright glistening network, the fibers of which vary much in thickness and breadth. The spaces between them often contain no other elements; more frequently, however, lymph-corpuscles or pus-corpuscles in proportionately large cavities and in very varying quantity are found (*E. Wagner, Billroth*).

c. In a third class of cases, a rigid inflammatory product collects on isolated spots on the tissue of the conjunctiva, but quickly breaks down, and forms masses of pus, which appear in a variety of forms, according as their position is superficial or deep, or according to the kind of boundary which they may have, etc.

α. Sometimes they are abscesses of greater or less size, which at times are diffused in the subconjunctival tissue, perforate this and heal up, or first change into an open, more rarely into an excavated, ulcer.

β. Sometimes an open ulcer results immediately from the deliquescence of a superficial collection of inflammatory product.

γ. In very rare cases pustules are formed during the course of measles, or facial eczema. The most frequent situation of these is the zone of the tarsal conjunctiva next to the edge of the lid and the reflection. The pustules shooting up on the last-named position are exactly like the spawn-like trachoma granules in form and structure. The only difference consists in the purulent nature of the product, and the opacity depending upon this, with the purulent yellow color of the granular elevations.

δ. Exceptionally in chronic pemphigus of other parts of the body, the repeated springing-up of larger vesicles with opaque contents has frequently been observed on the conjunctiva. The vesicles, after their rupture, leave behind an excoriation with opaque secretion, and lead later to shrinking and xerosis of the conjunctiva (*White Cooper, Wecker*).

ε. Very frequently such points of inflammation occur, which are really herpetic efflorescences. These are roundish, sharply-bordered nodules, about the size of a millet or hemp seed. They are quickly changed into superficial, sharply-contoured little ulcers, by the rapid deliquescence of their most anterior layers, and very gradually take a deeper hold. Occasionally, however, they deliquesce entirely at one period, and then they cause ulcerative cavities with abrupt edges. The infiltrated floor of these ulcers often sinks below the level of the real conjunctiva.

B. It can not be too distinctly remarked, that in these described differences there are really no essentially different morbid processes; but in them only modifications of one and the same process are to be found. These modifications depend on various circumstances; on external conditions, on the severity and kind of noxious material, on the duration of the irritation, on the stage of the process, on

the condition of the vessels, on the greater or less participation of the conjunctival nerves, etc.

Indeed, all the distinctions between the different forms of conjunctivitis may only be carried out in theory. In reality the forms of conjunctival inflammation, which appear to be strictly separated, run into each other by numerous intermediate forms and combinations, so that the form of conjunctivitis that may be diagnosticated will frequently depend on the manner in which the physician views the case. Besides, in one and the same case, the kind and quantity of the inflammatory product, as well as its distribution, varies with the severity of the proliferating process. It appears, then, as if one form of conjunctivitis may be developed from the other. For example, the process appears as a blennorrhœa, passes over into diphtheritis, again becoming a blennorrhœa, and finally gets well under the symptoms of catarrhal conjunctivitis, or becomes trachoma, by hypertrophy of the conjunctival tissue. Just as frequently, mixed forms occur, e. g., trachoma with blennorrhœal secretion, with continually relapsing herpetic efflorescences, catarrh with membranous patches on isolated portions of the conjunctiva; herpes which is gradually combined with catarrh, with trachoma, &c.

C. Inflammation of the conjunctiva is always characterized by more or less marked hyperæmia of the eye. This is generally proportionate to the severity of the affection and its extent, and the amount of the inflammatory product. Yet some exceptions may be seen. In the most severe forms of conjunctivitis, in diphtheritis of the conjunctiva, the infiltrated membrane is not unfrequently deprived of blood on account of compression of the vessels. In the pure spawn-like trachoma, from similar reasons, the hyperæmia is relatively less. The tint of the redness varies greatly. Sometimes it approaches the bright red of arterial blood; sometimes the bluish color of the venous blood is more prominent. In this way the greater or less arterial or venous character of the hyperæmia is seen. In scorbutus, the color is markedly changed to violet and brown. The condition of the epithelial layer has also a very marked influence on the shade of the color. Since the integument becomes thicker under the inflammatory proliferation, the redness of the conjunctiva has a grayish or grayish-yellow hue, which appears the more plainly the greater is the increase in the neoplastic elements, and the more turbid they are. In consequence of this the conjunctiva approaches a pale-rose or a lilac color, or a dirty-yellowish red. Besides, the redness of the conjunctiva is often changed to a bright yellowish or brownish red by imbibed hematine.

Extravasations of blood not unfrequently occur in severe injections of the conjunctiva. These are seen in the beginning as very irregular bright-red spots, which later change their color to a bluish or brownish red, and may even appear black. These spots are particularly characterized by the evenness of their color and the fading away of their edges into a bright-red, yellowish, or brownish hue.

D. The process of proliferation of tissue in the conjunctiva, as elsewhere, is generally accompanied by some elevation of temperature; yet this is only objectively seen in severe forms, chiefly when chemosis occurs. In less severe forms of inflammation the local increase of temperature generally escapes observation. We may only recognize it by the heat of the tears, in case they flow abundantly.

Authorities.—*Kölliker*, mikrosk. Anat. II. Leipzig 1854. S. 721.—*Henle*, Handb. der Anat. II. Braunschweig. 1866. S. 702, 705.—*M. Schultze*, Centralblatt f. med. Wiss. 1864. Nro. 12. 17.—*Virchow*, ibid. Nro. 15, 19.—*W. Krause*, Etudes ophth. par Wecker. I. Paris. 1863. P. 1, 4, 5, 6.—*Frey*, kl. Monatbl. 1863. S. 123.—*Manz*, Zeitschrift für rat. Medicin. 3. R. V. S. 126.—*Kleinschmidt*. A. f. O. IX. 3. S. 145.—*Leber*, Denkschriften der Wien. k. Akad. d. Wiss. 24. Bd. S. 319, 321, A. f. O. XI. 1. S. 34, 38, 42, 47.—*Donders*, kl. Monatbl 1864. S. 425.—*Piringer*, Die Blennorrhoe am Menschenange. Graz. 1841. S. 5. 131, 141, 147, 154, 212, 222, 279.—*Eble*, Ueber den Bau und die Krankh. der Bindehaut. Wien. 1828. S. 9-78, 77-123, 132, 147, 150. Die sog. contag. oder egypt.

42. Bd. S. 490.—*Mauchle*, ibid. 41. Bd. S. 148, 154.—*Helfreich*, Ueber die Nerven u. Sclera. Würzburg. 1870. S. 7-23.—*Billroth*, kl. Monatbl. 1868. S. 35; Wien. XVIII. 4, 5. S. 21, 27.—*E. Wagner*, Centralbl. 1867. S. 43.—*White*, *Cooper*, Monatbl. 1868. S. 232.

1. Catarrhal Conjunctivitis.

Symptoms.—*The disease is characterized by the secretion of a varying amount of turbid mucus or muco-purulent material. There is always a considerable quantity of this secretion, and some hyperæmia and swelling.*

1. The hyperæmia varies greatly in severity and extent, according to the grade of the catarrhal affection. It may be confined to the papillary portion, but more frequently, even in the lowest grades of the catarrh, it attacks the palpebral folds, including the semi-lunar fold and the caruncle. In severe forms, together with the uniform redness of the lids and of the palpebral folds, there is a reticulate injection of the ocular conjunctiva. In the severest forms of the catarrh, the whole conjunctiva is reddened. The redness in the beginning, so long as the symptoms of irritation predominate, is of a light hue. When the catarrh has existed for a long time, it plays into a bluish color, and is very perceptibly mingled with gray, lilac, or violet-gray. On account of the increase in density of the superficial cell-layers, extravasations of blood not unfrequently appear in the beginning of the severe catarrhal conjunctivitis.

2. The swelling of the tissue, in less severe forms of the inflammation, is chiefly seen in the semi-lunar fold and caruncle. In severer forms the palpebral fold also appears somewhat swollen. In the severest cases, we occasionally find a puffiness of the conjunctiva resembling chemosis. In the first stage the swelling is more tense, and therefore the surface of the infiltrated conjunctiva is smooth and brilliant. In the further course of the inflammation the membrane becomes relaxed, wrinkled, and decidedly spongy. The tarsal portion of the conjunctiva has a velvety appearance from the swelling of the papillæ.

The magnitude of the swelling is, however, by no means dependent alone on the severity of the inflammatory process, for even a slight catarrhal conjunctivitis is not unfrequently accompanied by œdema of the conjunctiva and of the lids. These parts then swell very considerably, in spite of which the injection is very pale. Cases even occur in which there is only a very vascular net-work weaving through the puffed-out conjunctiva. This fact, as well as its doughiness, prevents us from easily mistaking the character of the swelling.

3. A marked elevation of temperature is only seen in very severe catarrhal conjunctivitis, and even this immediately diminishes when the catarrhal relaxation begins to be established.

4. Severe pain and photophobia are not very common symptoms in catarrhal conjunctivitis. It generally runs a painless course. Burning, biting, itching sensations, or a feeling as if a foreign body, sand, were in the eye, are experienced. Even these subjective symptoms only annoy the patient at certain times, while remaining in impure or overheated air, on the action of powerful light or great contrasts in the illumination, especially that which is artificial, also after and during great straining of the eyes for the perception of small objects, after great exercise of the muscles of mastication, if hyperæmia or congestions in the superior vena cava have been excited, as after a hearty meal.

Severe pain, especially when accompanied by photophobia, and a profuse flow of hot tears indicates that the parts connected to the ciliary nerves are involved in the process. When these symptoms exist, there is generally a severe injection of the episcleral tissue, and even herpetic efflorescences, a keratitis, superficial exfoliation of the corneal margin, &c.

But where the even injection of the vascular conjunctiva renders it impossible to perceive any episcleral injection, we shall seldom err in supposing it to exist, and in taking the appropriate precautions.

5. The catarrhal secretion varies to some extent as respects quality and quantity, according to the severity of the inflammation. In the beginning of the disease, shortly after the reception of the virus, only an increased secretion of tears is generally seen. These appear somewhat more viscid, easily become frothy, are yellowish or reddish colored, and contain a few small flocculi of turbid, delicate mucus. While the inflammation gradually increases, the mucous secretion diminishes in quantity, becomes more turbid, and in severe cases may even assume the color and opacity of pure pus. It is, however, distinguished from the latter by its consistency, and by its incapability of being dissolved in tears. If the inflammation has passed its hight, if the relaxation of the conjunctiva begins to be more evident, the secretion of the characteristic material is increased, and this is not unfrequently more turbid and more like pus than before. But the secretion of tears diminishes, the catarrhal secretion gradually predominates. Subsequently the quantity of the latter decreases, or it becomes clearer, more transparent. Finally it exhibits only turbid striæ, and these acquire a greater similarity to the normal mucus of the conjunctiva. In a chronic catarrh the abundantly-secreted mucus may be even transparent, like glass.

The morbid secretion is also influenced by every thing which may temporarily increase the irritation of the conjunctiva and the hyperæmia of the vessels. Hyperæmia and congestion, dust, impure air, great heat, bright light, straining the eyes, &c., markedly increase the quantity of the material and its turbidness, while the opposite condition of things, residing in cool, pure, and fresh air, in moderately illuminated places, rest of the eyes, &c., diminishes the secretion and causes it to become more normal.

The secretion is apt to be the most abundant in the evening, and during the half-waking hours in the morning. In profound sleep, at night, it is somewhat less, and in slight attacks of catarrh is sometimes so little, especially in chronic cases, that the patient, on awaking from sleep, is unable to open his eyes on account of the want of the moist and lubricating conjunctival secretion. He must first rub the lids, or moisten them with saliva, thus increasing the hyperæmia and the secretion, before the lids again become movable. The patients often complain, principally of this dryness of the eyes. It is their most annoying and therefore most observed symptom.

We can not always detect the catarrhal secretions in a slight attack, but generally, at least in the lower palpebral fold, some flocculi occur, when we draw the affected lid away from the ball, and cause the patient to look up.

Besides, we generally find the secretion in the inner angle of the lids either fresh or dried, in yellowish or brownish crusts. The flocculi, which have reached the canal formed by the lids not quite shutting together, are pressed into the inner canthus by the motion of the lids, and, not being able to pass the lachrymal puncta, collect there and become dry.

During sleep, when no motion of the lids takes place, it is not possible to press the secretion with the inner canthus in this way. The mucous products, under the pressure of the orbicularis muscle, merely passing into the palpebral fissure, remain between the eye-lashes, then become dry,

and cause the outer lips of the two edges of the lids to adhere. In severe attacks of catarrhal conjunctivitis, thick crusts are formed on the edges of the lids during the night, and there is also during the day a great quantity of catarrhal secretion in the conjunctival sac and the palpebral fissure. If the patient be not cleanly in his habits, the recent secretion often collects, and large crusts are developed in such quantity that, on the first moment of examination, we may think that we have a blennorrhœa. By cleansing the parts, however, we may decide as to the true quantity of the secretion.

6. Catarrhal conjunctivitis is generally accompanied by impairment of vision. In mild attacks, this at times forms the chief source of complaint of the patients. They become considerably disturbed in their daily avocations, and often even prevented from them. The flocculi suspended in the tears are diffused over the cornea by the motion of the lids, and by their optical irregularity affect the vision, since they render objects just as cloudy as if the patient held a smoked glass before the eye.

The image of a flame appears as if surrounded by a dusty halo, and not unfrequently by the colors of the rainbow. Other objects are perceived as if covered by a veil or a cloud, which becomes the denser, the more the patient attempts to see plainly, because he thus increases the irritation of the conjunctiva. Consequently, the patients complain that they can not continue to read and write, because all objects appear murky, only seeming clear when the eyes have just been cleansed. If the patient looks upon a brightly-illuminated white wall, or upon the sky by daylight, the visual field appears striated with myriads of dark and light points, spots, rings, chains, &c. These figures are all movable, and show a marked and constant tendency to sink downward (*spectrum muco-lachrymal*). This phenomenon appears especially prominent when the patient looks through a small hole in a card. These figures are the shadows of the mucus collected on the cornea, and of the detritus of epithelium contained in it, as well as of the air-vesicles formed in them. (See *Scotoma.*)

Causes.—1. Catarrhal conjunctivitis is quite frequently developed secondarily, and is then founded in the anatomical or functional union which exists between the conjunctiva and the neighboring parts. Thus it is only rarely that severe inflammations occur in the ramifications of the ciliary nervous-system, in the nasal mucous membrane, in the lachrymal region, unless the conjunctiva participates in it. The morbid process is frequently continued from the facial integument upon the conjunctiva. Very generally, in facial erysipelas, the conjunctiva becomes injected, and projects as a large swelling, which, according to the character of the eczema, sometimes resembles œdema, sometimes chemosis, and, on the disappearance of the erysipelas, the conjunctiva is left in a true catarrhal condition. In impetigo, eczema, herpes, zoster, &c., of the face, the conjunctiva not unfrequently participates in the form of catarrhal inflammation.

2. The conjunctiva is almost always affected in the acute exanthemata, in smallpox, measles, and scarlet fever. The conjunctivitis is seen in the beginning of the eruptive stage, and is sometimes characterized by simple irritation; sometimes it is seen as a more or less severe catarrh; the conjunctivitis may even become a blennorrhœa. The conjunctiva, as a portion of the general integumentary system, participates in this, and, therefore, the designation of this form as *ophthalmia variolosa*, *morbillosa*, *scarlatinosa*, is perfectly correct.

Yet it should not be forgotten, that very different conditions have been described by the above names, e. g., metastatic and embolic panophthalmitis especially, which sometimes arise in diseases which take on an anomalous course. Herpes of the conjunctiva has also thus been described, because in the stage of dessication of these exanthemata, it is very apt to shoot up upon the cornea and conjunctiva.

3. In by far the most cases, catarrhal conjunctivitis is primary, being caused by injuries, which have directly affected the conjunctiva. Traumatic influences, foreign bodies, and chemical agents, which have accidentally entered or have been placed in the conjunctival sac, take the first place, on account of the frequency with which they cause the disease. Impure air, especially that mingled with ammoniacal or excrementitial exhalations, tobacco-smoke, or dust, is a powerful agent in causing conjunctival inflammation. Crowded rooms of all sorts, where people stay a large portion of the day, and shops where workmen are employed with dusty objects, overcrowded vessels, houses, and sleeping-rooms, prisons, barracks, &c., are universally recognized as true breeding-places for ophthalmia. Among the physical sources of injury, wind and a draught of air are especially to be noticed. The continued action of the atmospheric air upon a portion of the conjunctival sac, which is generally unexposed, may be the cause of catarrhal conjunctivitis. Ectropion, loss of the lids, exophthalmus, &c., are, as a rule, complicated with catarrhal conjunctivitis. Excessive straining of the eyes for the purpose of distinct vision is among the organic causes of this affection. Working over small objects with insufficient illumination, and limitation of accommodative power, are very common sources of the ophthalmia under consideration.

In fact catarrhal conditions of the conjunctiva very commonly accompany asthenopic troubles, and are then sometimes extremely obstinate, particularly if the correction of the error of accommodation is neglected. These conjunctival affections usually betray themselves more by troublesome feelings and redness than by increased secretion of mucus, and hence a peculiar name has been proposed for them, namely, "dry catarrh" (*Schirmer*).

4. Finally, the probable transmissibility of catarrhal conjunctivitis from one person to another, through the secretion, should not be forgotten. This contagious property is, at least, scarcely to be doubted of the secretion, which is more like pus. But in chronic catarrhal conjunctivitis, according to direct experiments, the secretion has no contagious property. (*Piringer.*)

5. Relaxation of the conjunctival tissue, and of the vessels, comes into consideration as a predisposing cause, especially in old people; but, besides, it has been frequently observed as a result of often-occurring or long-existing conjunctival inflammation.

The Course is in general the more tedious, the less the patient is able to withdraw himself from the action of the exciting causes. But if this be possible, the inflammation is the more obstinate the longer it has existed. Affections which have but recently begun, coming accidentally from causes which have excited an influence but for a short time, generally allow the most favorable prognosis. With a proper condition of the patient and correct treatment, and even with no treatment at all, in a few days, in severe cases in from two to three weeks, the disease comes to an end.

In ectropion, loss of substance of the lids, &c., where the causes are constantly acting, as well as in old people with very relaxed tissue, the cartarrhal conjunctivitis becomes habitual, and resists all attempts at cure. This is, of course, only true when we speak in general terms; exceptions may occur. Moreover, the course is not always uniform. The process gradually develops itself to a certain stage, and by degrees recedes to a cure. There are, in some cases, periods in which first the symptoms of irritation, and then those of catarrhal relaxation, with increase of secretion, are more prominent. Very frequently the course is modified by complication of the catarrhal conjunctivitis with an irritation of the ciliary nerves.

Results.—The common result is recovery. Under unfavorable circumstances, however, catarrhal conjunctivitis may increase to blennorrhœa, or pass on to trachoma. In old chronic catarrh, not unfrequently marked thickness and swelling of the conjunctiva occur. This becomes hypertrophied, and to a great extent at last degenerates, leaving behind tendinous, firm, cicatritial spots and shortening of the palpebral fold, often with inversion of the inner surface of the edge of the lid (*entropion*). This has been explained by supposing a precedent trachoma. Yet this is incorrect, since in many cases, during the entire course of the disease, every trace of the characteristic granulations is wanting, and only a uniform swelling of the mucous membrane, with secretion of mucus, is seen.

In other cases, and especially in old people, ectropion results from chronic catarrhal conjunctivitis. The cartilage finally is affected under the continuation of catarrhal inflammation of the conjunctiva, becomes gradually softened, and, its resistance no longer being sufficient to support the lower lid, it becomes lifted somewhat away from the globe, and sinks down. The eversion of the lachrymal puncta, which is connected with this, increases the difficulty which is found in carrying off the tears in this false position of the edge of the lid. The tears trickle continually over the lids and the cheeks; these become excoriated, erythematous inflammations are excited, and finally shriveling of the tissue, by which the ectropion is increased. At the same time, on account of the exposure of a portion of the conjunctiva, its inflammation and the affection of the cartilage are increased and maintained.

Catarrhal conjunctivitis, especially when it lasts a long time, leads to *blepharitis ciliaris*, the inflammation being continued directly from the conjunctiva upon the surroundings of the palbebral glands. This occurs more frequently, because the crusts arising from the drying of the catarrhal product are torn by the contraction of the epithelium of the border of the lid, causing fissures, and thus the air and tears act upon the exposed tissue of the lids. The patients sometimes rub off the crusts themselves, and thus cause the exposure.

Treatment.—Besides the removal of any existing causes, this has for its object the following, viz. limitation and suppression of the inflammatory proliferating process, subsequently the subjugation of the relaxed condition in the connective-tissue stroma and in the vessels, and, besides, the prevention of the consequences of catarrhal inflammation, especially the prevention of the formation of crusts on the edges of the lids.

1. Where the symptoms of irritation predominate, the treatment should be non-irritating, antiphlogistic. This is true whether it be in the beginning of the disease, or if, during the further course, accidental causes have increased the existing inflammation, but especially when a simultaneous injection of the episcleral tissue appears, and great pain, photophobia, and similar symptoms, show the irritation of the ciliary nervous system. When the inflammation is very severe, it is advisable to keep the patient in his room, and to take great care of the eyes. As direct remedies, cold applications are especially to be recommended, and, in case the nervous symptoms are very prominent, instillations of atropine.

Yet we must guard ourselves against a too constant employment of cold applications, because in catarrhal inflammation the local development of heat is too slight to allow the continuous effect of cold to be tolerated. It is generally sufficient to apply some well-wrung-out cold compresses several times during the day, especially during the exacerbations. We should be especially careful in children, and in persons with very light hair, since these applications readily excite excoriations or œdema. If this has already occurred, or if the catarrh from the beginning

has had the symptoms of a simple œdema of the lids and conjunctiva, cold applications will be harmful rather than beneficial. Then we may cover the eyes by a fold of linen and a bandage. Under such circumstances other direct remedies are not indicated. This is especially true as to the anti-irritative and demulcent remedies, which very recently were much in fashion.

2. If the symptoms of inflammatory irritation become less, if the conjunctiva becomes somewhat paler, if relaxation is indicated by subsidence of the swelling, and softness of its folds, and if, besides, all symptoms of ciliary irritation are absent, it is time to begin the use of astringents. Pure antiphlogistics are not then sufficient to bring the process to a close in the shortest possible time.

It is then only necessary in the severer cases to keep the patient in his room. In mild cases, and where the conjunctivitis is subsiding, the patient is much more comfortable in the open fresh air, and he recovers quicker than in a confined room. But he must be warned to avoid wind and dust, and not to visit places which are overheated, or in which the air is impure or smoky. He is especially to be warned against pursuing any occupation over a fire, and to avoid bright light or great contrasts of light, straining the eyes by reading, writing, or sewing, especially by lamp or gas light, all of which may cause hyperæmia and congestion. Cold compresses, in this stage, should only be used at long intervals, and with the greatest care. They are to be used for cleansing the eyes, and for the removal of the frequent burning, itching sensations, &c. Cloths dipped in cool, fresh water answer this purpose excellently well, while pressure, or rubbing the lids, although pleasant to the patient at the moment, increase the irritation very markedly, and are therefore to be carefully avoided.

In the use of astringents, we should remember that they always irritate more or less, and that their therapeutic value depends on this effect. Astringents can, then, only be indicated where an irritation is desirable of itself, or for the purpose of overcoming a relaxation of tissue and of the vessels. In cases in which neither the irritation nor relaxed condition are very prominent, where it is therefore doubtful whether the anti-irritative or astringent treatment be proper, it is advisable to keep on for a few days with the antiphlogistic treatment, or to try the ground with the experimental use of a mild astringent, and in case the latter is not borne, to again take up the antiphlogistic method, and wait till the relaxation is more distinct, and the astringents are indicated.

Penciling the conjunctiva with a solution of nitrate of silver, five grains to the ounce, does by far the best service. Wherever the relaxation of the tissue is quite prominent in catarrhal conjunctivitis, and the symptoms of irritation do not contra-indicate, the treatment should be begun and continued with this remedy, until the relaxation and morbid secretion of the conjunctiva are removed. If under such a treatment the morbid condition is subdued, except as to some hyperæmia of the conjunctiva, or if the catarrh from the beginning has been but slight, and the relaxation of tissue little noticeable, or if the patient be not in a position to consult the physician daily and allow the pencilings to be made, the astringent collyria should be advised.

3. In old chronic catarrhal conjunctivitis, and in general where the relaxation of the conjunctiva and its vessels has reached a very high grade, especially in the habitual catarrhal inflammation of old persons, the treatment above indicated will not be sufficient to attain the desired result. Then the daily application of a smooth crystal of sulphate of copper to the tarsal portion and the palpebral folds will do very well. But if the patient can not visit the physician every day, we may substitute an ointment of five grains of sulphate of copper to two drachms of simple cerate, which the patient causes to be introduced, or places, in the conjunctival sac with a camel's-

hair brush. If, however, the very-much relaxed and loosened conjunctiva is superficially rough, velvet-like, or even granular, it is better to first pencil the conjunctiva daily, for some time, with a solution of ten grains of nitrate of silver to the ounce of water, continuing this until the conjunctiva becomes smoother, when the sulphate of copper, in the form of a crystal or an ointment, may be continued until the end of the treatment.

4. In order to prevent the formation of crusts and its evil results, the edges of the lids may be cleansed with a piece of soft linen. At night, the lids should be smeared with fresh fat, with glycerine cream, simple cerate, or the like. It is best to apply the ointment with a brush upon the edge of the lids, and it must be got between the lashes. The application is made when the lids are closed, and the patient should not open them for some time after. The parts should be covered by a *thin* layer of fat. If, in spite of all these precautions, or on account of insufficient treatment, thick, hard crusts are formed on the edges of the lids, which adhere closely to the ciliæ and epidermis, these should be first completely softened by soaking them in warm water with a sponge or a piece of soft linen; otherwise their removal will cause excoriations. Lukewarm milk may be used instead of water.

Authorities.—*Eble*, Ueber den Bau und die Krankheiten der Bindehaut. Wien. 1828. S. 84.—*Piringer*, Die Blenn. am Menschenauge. Graz. 1841. S. 2, 4, 267, 271, 275.—*Arlt*, Die Krankheiten des Auges. I. Prag. 1751. S. 8. kl. Monatbl. 1863. S. 182.—*Guls*, Die sog. egypt. Augenentzündung. Wien. 1850. S. 22.—*Stilling*, kl. Monatbl. 1869. S. 189.—*Galezowski*, Gaz. des höp. 1868. Nro. 108.—*Schirmer*, kl. Monatbl. 1867. S. 114.

2. Membranous Conjunctivitis.

Symptoms.—*Besides the symptoms of severe hyperæmia and swelling, the disease is characterized by the development of a fibrous product on the surface of the conjunctiva, which may become a membranous patch.*

The hyperæmia generally extends over the entire conjunctiva, often even over its surroundings, especially the lids. It is evinced by a very uniform, more or less bright, but often dark or brownish, redness. The swelling is generally very severe, often really chemotic. Local elevation of temperature, as well as severe pain in the eye, and the corresponding half of the head, are seldom wanting in the beginning of the affection. In some cases there is fever.

The inflammatory product appears, in mild cases, as a thin and delicate, gauze-like, reticulated coating. In other cases it is denser, and appears as a thick membranous patch, resembling fibrous material of greater or less consistency, sometimes half a line or more in thickness, completely covering the conjunctival sac. This membrane does not extend over the cornea, and generally has a sharp border on the inner lip of the lid, but sometimes involves the edge of the lid. In rare cases it even unites the edges of the lids which are in contact, shutting up the palpebral fissure. The inflammatory product is translucent and grayish, but when the membranous patch is very thick, it is completely opaque, tendinous, or of a yellowish color. It does not have much tendency to deliquescence, and is, therefore, almost always separated from the conjunctiva in shreds, or the whole membrane is thrown off at one time. Where the product deliquesces, it is not so much a pure membranous conjunctivitis as a transition-form of diphtheritic conjunctivitis.

Generally speaking, membranous conjunctivitis is rarely observed in a pure form. Setting aside the instances which are passing over to diphtheritic conjunctivitis, we quite frequently meet with cases in which the membranous patch involves only an isolated portion of the conjunctiva, usually the palpebral folds and the tarsal conjunctiva, while the other parts secrete simple catarrhal or blennorrhœal material, which is not adherent.

Causes.—The etiology is about the same as that of catarrhal conjunctivitis. It is also very probable that membranous conjunctivitis may be propagated by contagion; but it is not necessary that the secretion should be from exactly this form of disease for this to occur; catarrhal, blennorrhœal, even trachomatous, secretion, may cause a membranous conjunctivitis; and, on the other hand, the secretion of the latter may by contagion cause a catarrhal inflammation, a blennorrhœa, a trachoma, &c. The disease in question is always a rare one. At times, however, it is more frequently observed. In Spring and Summer, in very hot and continually dry weather, it is often seen in connection with cases of acute trachoma, blennorrhœa, &c.

Course.—If the disease appears more independently, it is generally developed with quite violent symptoms, and reaches its hight within a few days. In favorable cases, the inflammatory symptoms then recede, the swelling declines, with diminution

of the local temperature, the pain and fever. The tissue becomes softer and more relaxed, a mucous secretion appears, the membrane is thrown off in shreds, or as a whole, and the membranous conjunctivitis appears to be changed to a catarrhal conjunctivitis, or a blennorrhœa. But it not unfrequently occurs that, after the membrane is cast off in this way, either completely or partially, or after it has been artificially removed, patches of exudation are here formed, and thus the characteristic signs of membranous conjunctivitis remain for some time unchanged, before the secretion under the gradual relaxation of the tissue attains more of a catarrhal or blennorrhœal character.

In the greater number of cases, however, membranous conjunctivitis represents, as it were, only an episode in the retrogression of a severe catarrhal inflammation, or of a blennorrhœa, it being formed from this in some temporary change in the product of inflammation, and again passes into the catarrhal or blennorrhœal form.

Results.—Membranous conjunctivitis, as described, does not directly end in recovery, but, as a rule, passes over into the other forms of conjunctival inflammation, usually into catarrhal inflammation, blennorrhœa, or trachoma.

It is not very dangerous of itself, with careful treatment, but it may always lead to bad results. Thus it quite frequently occurs that certain portions of the conjunctival sac which come in contact, become adherent through the inflammatory product, and in case this union is not broken up, they are firmly united, and actually degenerate. It is in the swollen palpebral fold, especially, that such adhesions are quite common, and may lead to shortening of the conjunctival sac (*posterior symblepharon*), with all its evil results, perhaps even to xerophthalmia. Besides, in severe cases of inflammation, the transplantation of the process upon the cornea is to be feared. The result may be permanent opacities. Ulcerations of the cornea, however, are to be ascribed less to membranous conjunctivitis than to its combinations with blennorrhœa, especially in the varieties which become diphtheritic conjunctivitis.

Treatment.—Besides the removal of all sources of injury, which may keep up or increase the process, or favor its extension upon healthy parts, the treatment aims to overcome the tissue-proliferating process, and at the avoidance of all the evil results which may promote the adherence of the rigid membranous inflammatory products to any portions of the conjunctiva.

1. Prophylactically, it is advisable to protect the sound eye with an hermetical protective bandage, to prevent the possible inoculation of this eye. This bandage (the charpie being occasionally renewed) is to be worn until the quality of the inflammatory product leaves no fear of inoculation. But when the first traces of the affection are seen on the previously healthy eye, the bandage should be immediately removed and the treatment begun. (See *Blennorrhœa.*)

2. The direct treatment, in accordance with the character of the inflammation, should be rigidly antiphlogistic. This should be the more vigorously carried on, the more acute the process, the more rapidly it advances, the greater the disturbances in circulation, the tenser the swelling, and the severer the inflammatory pain. In the greater number of cases cold applications, and perhaps the use of leeches, will be proper. Mercurials are, to say the least, superfluous.

3. When the inflammatory symptoms subside, the antiphlogistic treatment should also be less active. If, in the course of the disease, the redness becomes paler, the swelling soft and relaxed, the conjunctiva wrinkled; if the local temperature sinks below the normal; and if, finally, the secretion becomes more catarrhal and blen-

norrhœal, while the membranous masses are thrown off in shreds, without being replaced—it is now time to pass on to the use of astringents, to begin the treatment of the catarrh or blennorrhœa, or to oppose the development of trachoma. This must be begun with great care. If the inflammation again increases under the use of astringents, we should return to simple antiphlogistic treatment, and suspend the application of astringents until the indications for their employment again become urgent.

4. The membranous exudations should always be most carefully observed. So long as the inflammation is still severe, and the whole membrane is firmly adherent to the conjunctiva, an artificial removal is scarcely to be advised, because this causes a severer inflammation and may excite a new exudation. But if the membrane becomes loosened in some places, it is necessary to remove it with forceps or a piece of soft cloth, since it will wrinkle at every motion of the lids, and irritate more as a foreign body than if carefully removed. Particular attention is to be paid to any adhesions between the parts of the conjunctiva which are in contact. We should never neglect to examine the palpebral folds most carefully, in order to ascertain the presence of any such adhesions. We may sometimes find very superficial grooves, running parallel to the palpebral folds, situated on the swelling, and these grooves are found to be the edges of deep folds, the sides of which are completely adherent. The separation is readily induced with the finger, a pencil or the like. The dropping-in of oils, placing a piece of goldbeater's skin or such substances, are of no use in preventing adhesions, because they are very irritating, and are not sure to accomplish their object.

Authorities.—*Arlt*, Die Krankheiten des Auges. I. Prag. 1851. S. 85.—*Guls*, Die egypt. Augenentzündung. Wien. 1850. S. 34.—*Hulme*, kl. Monatbl. 1864. S. 44.

3. Blennorrhœa.

Symptoms.—*The disease is characterized by true chemosis, and by great secretion of muco-purulent or purulent product of inflammation, which rolls up in flocculi, or dissolves in the tears.*

1. The hyperæmia extends over the whole conjunctiva, generally upon the integument of the lid, and may at times go still further. The redness is very uniform, generally quite dark, with a tint of blue. In the later stages, or where the affection is less intense, there is a yellowish hue. Where the relaxation has already attained the preponderance, the color inclines rather to gray, approaching a dirty-lilac or violet, on account of the collection of a dense layer of newly-formed cells.

There is great swelling of the parts. The lids appear like thick, red swellings. They are almost immovable, the palpebral fissure is closed, and the upper lid frequently pushed over the border of the lower one. If the lids are forcibly opened, the palpebral fold, which is greatly swollen, presses forward and readily everts the lid. The ocular conjunctiva is raised up around the cornea like a little wall, and covers its periphery. The cornea often appears buried in the swellings, its center only being seen. In the first stages, the swelling is more or less elastic, but subsequently it becomes soft and yielding, may be easily displaced, and changes its situation by means of its own weight, according to the position of the patient. The formerly immovable lids become again movable, although to a less extent, and the globe, which was almost rigid, begins to follow objects more easily.

The local temperature is always markedly elevated in the first stages, but gradually sinks to the normal standard as the relaxation appears.

Pain is also only apt to accompany the first stages, when the sthenic character of the inflammation predominates. It may be very severe, radiating over the entire half of the head, especially when there is at the same time a severe irritation in the ciliary system. In the later stages the pain generally recedes, or entirely disappears, provided it is a pure blennorrhœa which exists. Fever is a common symptom, both in the beginning and at the acme of the process.

The product of inflammation, in less severe cases, corresponds entirely to that of catarrh. The difference exists only in the quantity; therefore it quite often depends on the pleasure of the surgeon, whether he will diagnosticate a severe catarrh, or a blennorrhœa. In the severer stages of the process, the mucous basis of the secretion disappears. It becomes purely suppurative, and is, as it were, dissolved in the tears. In consequence of this, the mixed secretions are sometimes like turbid water, similar to broth or whey; sometimes it is more like thin milk, and sometimes it resembles a thick, yellowish, or greenish cream, and is completely opaque. True coagulations are seldom found in it.

Strictly speaking, we should separate the cases, where the morbid secretion has a mucous basis, from those in which it bears more the character of true pus, and is soluble in the tears. Blennorrhœa is the proper name for the former, pyorrhœa for the latter. Such a distinction is justified, because the two forms are not exactly the same in respect to their possible results, and also

demand different treatment. There are always different degrees of the same process, since we often find the muco-purulent flocculi of blennorrhœa with the secretion of true pyorrhœa, floating about in it.

In the beginning, the secretion is not very abundant, rather watery, but quickly increases in quantity, and in firm inflammatory products. It is then often so great that a short interruption of the cleansing of the eyes is sufficient to fill all the space between the swellings of the conjunctiva, and to completely close the palpebral fissure with secretion. The inflammatory product soon passes over the edges of the lids, and runs in quite a thick stream over the cheeks, covering them with crusts, and causing excoriations. Even during profound sleep, when the secretion is somewhat lessened, the amount of the product of inflammation is always still so great, that a complete adhesion scarcely occurs, because the constant flow of secretion breaks through the crusts as they are formed.

Causes.—Blennorrhœa frequently arises as a consequence of injuries of the most diverse character, also from other forms of conjunctival inflammation, especially catarrhal inflammation.

Why it is, that from the same cause there is in one case a catarrh excited, in another case a blennorrhœa, is not explained. The severity of the irritating cause is certainly not always the reason of the different effect, for we often observe that severe irritation sometimes causes a simple and quickly-receding irritation, while in other cases, injuries, which were so slight that they escaped observation, have resulted in severe attacks of blennorrhœa. This difference has been ascribed to the presence or absence of a special disposition. The fact that blennorrhœa is more frequently observed at certain times, and occurs from relatively slight causes, even extending at times in an endemic or epidemic form, while at other times, and seemingly under the same circumstances, the blennorrhœal affections occur less frequently than the other conjunctival affections, indicates that, besides the peculiar disposition of any individuals, there may be other circumstances, independent of this, which have some influence in determining the greater or less severity of the blennorrhœal affection.

An extremely important cause of blennorrhœa, furthermore, is inoculation, in consequence of the direct carrying over of blennorrhœal secretion from an affected conjunctiva to the healthy one of another eye. Indeed, the contagiousness of the blennorrhœal secretion is very great, and the greater the more severe is the blennorrhœa, and in proportion to the amount of pus in the inflammatory product, and the fresher and purer the state in which it is carried over to the conjunctiva.

The contagious property of the secretion is greater during the increase and high stages of blennorrhœa, than in the stage of decrease, and after the secretion has obtained a predominantly mucous appearance. The secretion loses much of its contagiousness by drying, and by diluting it with at least forty times the quantity of water. It then does not adhere so easily (*Piringer*), although the danger of inoculation still remains. In general, it may be said that the contagious property is somewhat lessened by the frequent carrying over of the secretion, for it is a common observation, that when the second eye is affected by the secretion of the one first attacked, the process has a less severe course here, and does not reach so high a grade.

Yet this is only true when we speak in general terms. There are many exceptional cases, which, in consideration of the importance of the matter, require careful consideration. We should pay particular attention to the fact, that the severity and even the special form of an inflammation caused by the carrying over of such secretion, does not always correspond exactly to the disease from which the contagious material was taken. There are cases where secretion from a severe catarrh, a mild blennorrhœa, has caused an extremely dangerous purulent ophthalmia, while, on the other hand, the secondary disease may be milder than the primary.

Gonorrhœal secretion from the urethra or vagina acts in the same way as the blennorrhœal, and may cause true pyorrhœa or purulent conjunctivitis. The principle holds good here also, that the severity of the inflammation is not always in unison with the severity of the gonorrhœa. Numerous observations have established it beyond doubt, that a gonorrhœa which has passed the acute stages, even inclining to become chronic, may cause a purulent secretion from the conjunctiva, of the worst form, while the reverse condition of things is exceedingly rare.

It should here be mentioned that the circumstances must be peculiarly favorable, in order that an inoculation of the conjunctiva from the genital mucous membrane may occur, and that it occurs much more rarely than we are inclined to believe. The rarity of ophthalmo-blennorrhœa in syphilitic wards and in private practice, compared with the frequency of gonorrhœa and with the carelessness of those affected with the disease, is an undeniable evidence of this. There is also reason for believing that the gonorrhœal secretion has less affinity for the conjunctiva than blennorrhœal secretion, and vice versa. This conclusion is deduced from the fact that the mucous membrane of the genitals is rarely affected in primary conjunctival blennorrhœa.

The period of incubation after successful inoculation of the contagious material varies between some hours and days. The outbreak of the blennorrhœa follows the more quickly, the more favorable are the conditions for the inoculation, i. e., the more powerfully the secretion was able to act.

There is no positive reason for believing in the transmissibility of the virulent material through the air, and we have every reason to doubt the correctness of this hypothesis. Very recently epithelial cells have been said to be found in the atmosphere of eye-wards (*Frank, Eiselt*), and some direct experiments (*Marston*) indicate that a strong current of air, which passes over a cloth saturated with recent pus, may carry pus-corpuscles with it. But these experiments, even if entirely correct, are far from proving inoculation through the air, especially if we consider that the experiments were made with dilute and dried pus. (*Piringer.*) They show, however, that the greatest care should be observed, and we shall always do well to proceed as if the contagion through the atmosphere were an assured fact.

When we see the myriads of fine filaments, dust-particles, which are observed in the sunlight after sweeping out a ward or sick-room, we can not avoid the belief that there may be among them bits of charpie, &c., which have been saturated with pus, have become dry, and are now whirling about in the air.

It is difficult to believe that fresh pus-elements can be freed from the secretion by evaporation of the menstruum, and that they may be kept suspended in the atmosphere for any long time, under ordinary circumstances, when there is no strong current of air. (*Alf. Graefe.*)

A circumstance should be mentioned which some have explained as due to inoculation. The inflammatory product, which is quite viscid, often throws off little vesicles, on the movements of the lids, which burst, and eject a portion of their contents for some distance. This may be frequently seen on careful observation. It may easily happen that small quantities of infectious material enter the eye when one converses with or examines a patient, especially when the faces are near to each other.

Course.—Blennorrhœa proper always has an *acute* course, lasting from only a few days to three weeks at the highest. The whole process may be drawn out for months, but then, we are not dealing with a pure blennorrhœa, but with other forms of conjunctival inflammation, which have either only temporarily assumed the character of a blennorrhœa, or which have been gradually developed from it. Indeed, it often happens that a catarrhal inflammation, by an increase in the quantity

of the secretion, advances to a blennorrhœa, or that a membranous or diphtheritic conjunctivitis passes over into the same disease by the change in the inflammatory product, which then, exactly like a blennorrhœa occurring primarily, either quickly goes on to cure, or becomes a catarrhal inflammation or a trachoma, and, as such, has a more or less chronic course. On the other hand, the process may become chronic in consequence of the participation of neighboring structures, the cartilage, the cornea, &c., conditions being produced which take some considerable time for their resolution. If we do not consider these circumstances, and if we regard blennorrhœa in the above-described signification, we can only speak of an acute course; and we may say that, where the course is not modified by opposing conditions, the blennorrhœa quickly developed reaches its hight within a few days, and then recedes in a short time, with evident relaxation of the tissue, and passes over into a simple catarrh or a trachoma, where the disease ends.

Where fresh injuries act upon the conjunctiva, or the former ones continue, or where an irrational method of treatment is undertaken, it often occurs that, after the blennorrhœa seems evidently on the decrease, it again appears in greater severity, and exacerbations interchange with remissions. The blennorrhœa may become a catarrh before the process terminates.

The speediness with which the symptoms develop and increase enables us to diagnosticate the disease in its incipiency, before the symptoms of the inflammation and the secretion complete the idea of a blennorrhœa. In primary blennorrhœa we always find, within a few hours of the beginning of the disease, the tarsal conjunctiva and the palpebral portion greatly relaxed and almost evenly reddened. The ocular conjunctiva, and especially that portion in the palpebral fissure, is woven through with a coarse net work, gelatinously infiltrated, often swollen at intervals, while a large quantity of yellow-colored and viscid tears, mixed with exudation flocculi, are excreted in abundant quantity. On the second or third day the blennorrhœa is generally fully developed.

Results.—Blennorrhœa is one of the most destructive diseases of the eye. Very often, in spite of the most careful treatment, and that which is recognized as correct, it causes great injury to the eye, or completely destroys it by phthisis.

The chief danger lies in the possible extension of the disease to the cornea, and the formation of an abscess or the occurrence of an ulcer.

So-called vascular keratitis may be developed during the course of a blennorrhœa, and pass into pannus. This is, however, a very rare result It belongs rather to those cases in which, at the beginning of the morbid process, the papillary bodies swell very much, and increase in size—that is, where a blennorrhœa is developed, as it were, in combination with trachoma, or, as we may rather say, where a trachoma occurs in a very acute form with the symptoms of blennorrhœa.

Any portion of the cornea, the center as well as the periphery, may be the chief seat of the secondary suppurative process. We have greater reason to fear this result, the severer are the inflammatory symptoms in the conjunctiva, the greater the redness, the larger and more tense the conjunctival swelling above the cornea, and the greater the increase in the local temperature. These dangers are particularly threatening when there is added to all these symptoms marked evidence of ciliary irritation, severe pain in the course of the frontal nerves, accompanied by severe photophobia, lachrymation, and spasm of the lids. Not unfrequently one or more herpetic efflorescences shoot up on the cornea, but generally on the *limbus conjunctivalis.* These are quickly changed into secondary ulcers of greater or less extent, and cause serious changes. More frequently the cornea becomes turbid in

the beginning, the surface being generally first affected, the epithelium, relaxing, assumes a grayish color, and acquires a rough appearance from the throwing off of isolated collections of cells. The turbidness soon becomes denser, its color yellow, and within a short time an abscess or an ulcer occurs, which rapidly enlarges in all directions. The unfavorable results are then the same as those from a primarily developed abscess or an ulcer.

In the severest form of the process, with a purulent character of the product of inflammation, there is danger from another sort of corneal affection, which is indeed the most dangerous. It often leads, without any intermission, to the destruction of the cornea, and with it of the eye. It may proceed from any point of the corneal surface; but the destructive inflammatory process generally begins from some point on the lower periphery of the cornea. The epithelium becomes opaque, and is thrown off at this point, causing a small loss of substance. This gradually deepens while it rapidly advances on the periphery, but proceeds slowly toward the center of the cornea. In this way a crescentic depression or furrow occurs, which surrounds more or less of the corneal periphery. It is always the deepest and broadest at the point of origin. On a vertical section there is seen an outer wall, which is almost at right angles with the surface, and an inner one, which penetrates the cornea very gradually, being hollowed out, or, as it were, having steps. The base and edges of the excavation are infiltrated and covered by a very abundant purulent product.

It is probable that this ulcerative process has a near causal connection with the free purulent secretion, and that its effect on the corneal substance may be excited, or at least favored, by a sort of decomposing action.

The fact that the crescentic ulcers are almost exclusively observed in pyorrhœa, and in diphtheritic affections which are so closely allied to it, and scarcely ever in blennorrhœa, where the inflammatory product is mostly mucus, favors such a view, although in blennorrhœa all the symptoms, except as to the nature of the secretion, are the same. This belief is also strengthened by the fact that the destruction of tissue always begins from the surface and gradually involves the deeper structure, and that the process generally proceeds from the deepest lying part of this furrow, which is formed by the bulging-out of ocular conjunctiva and the corneal periphery, that is, by the lower, or lower and outer, circumference of the cornea, where the secretion collects most easily in the greatest quantity, and may act upon the corneal tissue.

When the disease has begun, it generally advances rapidly. This is especially to be feared when the corneal border begins to be affected immediately on the commencement of the disease, and if the blennorrhœa, after the occurrence of such a loss of substance, does not immediately assume a benign character. The greatest part of the cornea is then generally destroyed. But if the ulceration does not begin until the process has lost some of its severity, we may count somewhat on the preservation of the cornea.

The further consequences of the crescentic ulcers are large cicatrices, united with anterior synechia, when a perforation has occurred. These impair the vision, or even completely destroy it. The fact that the cicatrix, by means of the gradual shrinkage of the flap of cornea surrounding it, yields to the intraocular pressure, gives way, and becomes distorted, causing the cornea to bulge forward, and giving it a false curvature, contributes to the impairment of vision.

If a perforation of the cornea occurs, the lens is evacuated, and a part of the vitreous. The result is then generally phthisis of the globe. This occurs more certainly when, as is quite frequently the case, the corneal portion which has, up to

this time, remained intact, becomes infiltrated and ulcerates, or the large flap of cornea is completely destroyed.

In some cases, especially in a typical and sthenic character of the inflammation, and with very severe tension of the parts, the entire cornea is destroyed in the beginning, becomes opaque, and changes to a grayish, smeary, pultaceous substance, which sometimes lies for a while on the iris, but is generally thrown out by the pressure of the contents of the globe, after which the globe is lost by phthisis.

2. Trachoma is also to be considered as a very common result of blennorrhœa. We may very often observe the characteristic roughness of the conjunctiva quite early in the course of the affection, at the hight of the blennorrhœa. In other cases, however, these granulations do not occur until the later stages of the ophthalmia. The trachoma may then be designated as a result of blennorrhœa.

3. Ptosis (falling down of the upper lid), and ectropion of the lower or of both lids, may also be reckoned among the consequences of blennorrhœa. Ptosis occurs, on the one hand, from the swelling of the upper palpebral fold, which renders it difficult to raise the thickened lid between the roof of the orbit and the surface of the globe. On the other hand, the increase in volume and weight which the lid undergoes comes into consideration. There is also an important factor, in the circumstance that the cartilage is greatly distended by the chemosis and the softening of the tissue, which accompanies the proliferation. This often occurs to such a degree that the lid, after the subsidence of the chemotic swelling, can not lie upon the globe, but hangs in front of it in the form of a curtain.

Ectropion often occurs during the course of a blennorrhœa, but the lid may be easily replaced, and the condition thus prevented from becoming permanent, which easily occurs when the replacement is neglected. Eversion of the lid generally results from clumsy handling of it by the patient or his attendants, but sometimes of itself. By the swelling of the lids and of the palpebral folds, the former are pressed forward, and put very much on the stretch. The resistance is the greatest on the borders of the lids, on account of the firmness of the cartilage and the ligaments attached to the orbital border, and, therefore, these are bulged out less than the surfaces of the lids.

The result is, that the palpebral swelling appears divided by the deeply-intersecting tarsal borders into two oval obliquely-situated swellings. If, now, the greatly-swelled palpebral fold has once an opportunity to come between the globe and the intersecting border of the lid, it is easily bulged forward from the external pressure exerted upon it, and, the cartilage attached to the palpebral conjunctiva being irritated also, the lid is everted. The pressure from the edge of the lid acts on the base of the tumor, which is forced outward. The vessels are compressed, and thus congestion caused, and an enlargement of the swelling by serous exudation. Replacement then becomes more difficult, and is at last impossible. This is particularly the case when the tarsus is involved, becoming soft and gradually distended. The lid can not then preserve its normal position after the decrease of the conjunctival swelling, and it has been artificially replaced.

Treatment.—We should endeavor to prevent the inoculation of the other conjunctiva, by the transference of the very contagious secretion, also to keep away all sources of irritation from the affected eye, and thus place it in the most favorable condition for recovery. We also aim to overcome the proliferation of tissue, and thus avoid the results which make blennorrhœa a disease very much to be feared.

1. *a.* When one eye only is affected, the healthy one should be carefully covered by a hermetical bandage, in order to prevent contagion. The ordinary protective bandage is easily displaced during sleep, and when patients are restless. Besides, the flannel and charpie are too permeable to great quantities of thin fluid-products. On the contrary, the so-called hermetical or collodion bandage (*Graefe*) affords perfect protection, when it is well applied, and is, therefore, to be urgently recommended.

In order to apply it, the closed lids are thickly covered by small and loose bunches of charpie, and the surrounding depressions filled up; a piece of oiled silk is then placed upon this, and over this a double one of linen, of oval shape. After it has been evenly fitted, the edges of the linen covering are to be carefully fastened with collodion all around the orbit, without leaving even a small opening, and, finally, the surface is to be painted over several times with the same material. We may lift up this covering daily or every two days, in order to assure ourselves of the condition of the eye, and in case it is still unharmed, it may be again attached.

The suggestion to cover the whole eye with a glass coating, and thus to render the use of the affected globe possible (*Snellen*), is scarcely practicable. The dense vapor which arises from the conjunctiva and cutis is not here taken up, as in the collodion bandage, by the charpie, and may become dangerous to the eye, causing catarrh, &c.; while, on the other hand, the greatest portion of it precipitates on the inner side of the glass, and nullifies the chief advantage of the method, i. e. the power of using the eye. *Aqua chlori* deserves to be mentioned as a substitute for the bandage, on account of its disinfecting power. When we can not use the collodion bandage, the charpie may be saturated in the chlorine water. When, however, we can not trust the protective bandage, applications of dilute *aqua chlori* afford some protection. It is scarcely advisable to drop it in the eye, on account of its irritating effect (*Graefe*).

b. Those about the patient should be warned from any unnecessary contact with him, or with any thing that he uses. The attendants should see to it that, after each assistance they render the patient, they wash the hands with soap and water, and especially avoid any contact with their own eyes. The linen of the patient, and especially the bed-linen, the handkerchiefs, towels, &c., are only to be used again after boiling with soap and water.

c. If a gonorrhœa exists, it should be cured as quickly as possible. The patient should avoid unnecessarily touching the genitals, and carefully cleanse his hands after any contact. This is necessary to avoid new inoculation, for nothing is more dangerous than a relapse of a blennorrhœa.

d. If by accident any blennorrhœal or gonorrhœal secretion has been transferred to healthy conjunctiva, a few drops of a solution of *arg. nit. bi-chloride of mercury*, *aq. chlori*, or common salt, if nothing else be at hand, are to be immediately placed in the conjunctival sac, and brought in contact with all points of the mucous membrane. If this be done within a very short time, we may reasonably hope that an inflammation will not occur. If it be done later, there is slight hope, or none at all, of preventing its occurrence.

e. So long as the affection retains the blennorrhœal form, the patient should not leave his bed. In hospitals, care should be taken that there are not many persons put together in one ward. The rooms should be kept as clean as possible, well ventilated, not over-heated, and protected from bright and irregular light by curtains and lamp-shades. The patient himself should be kept as quiet as possible.

2. As to direct treatment, it is well to be remarked, that the principal danger in blennorrhœa is a continuation of the inflammation from the conjunctiva upon the cornea, and that this continuation occurs the more easily, the greater is the severity of the inflammation. According to this, the participation of the cornea is favored by every thing which can keep the inflammation at a certain hight, or cause it to run higher. So long, then, as the relaxation of the cornea is not very marked, the treatment of the blennorrhœa should be predominantly antiphlogistic, and this should be the more energetic, the more prominent the sthenic character of the

inflammation. The best means for this are strict antiphlogistic regimen, local blood-letting, and cold applications.

a. Iced compresses, which are frequently changed, are much to be preferred to all other means for the purpose of applying cold. It is only in case of necessity that cloths dipped in cold water are to be substituted for them. When the inflammation is very severe, they are to be uninterruptedly continued day and night, until the local temperature of the orbital region has been reduced to the normal standard. When the inflammation is less severe, applications of cold at intervals is sufficient, since excessive abstraction of heat may even do harm.

b. Local blood-letting is especially of advantage, before and during the exacerbations of the inflammatory process. But when the redness is intense, the swelling great, hard, and tense, and when besides there is much heat; when the inflammatory pain is very severe, and the use of cold does not prove to be sufficient to reduce these symptoms, we should not wait for the exacerbations, but in consideration of the suffering of the patient, and the danger of the cornea, should proceed immediately to the application of a number of leeches, and repeat this according to necessity.

c. If the danger appears very great, it will be well to make a horizontal incision in the external canthus, through the integument, but avoiding the conjunctiva, in order not to favor the occurrence of an ectropion. (*Graefe.*)

Several venous and arterial branches being met with in such an incision, which is several lines long, the hemorrhage is generally very abundant, but it may be easily stopped. On the other hand, the pressure which the swelled conjunctiva, and to some extent the globe, have to sustain from the lids rendered very slightly distensible by the softening of the cartilage, is considerably lessened. The relief to the circulation by the direct evacuation of blood, and by the lessening of the excessive external pressure, improves the nutrition of the affected parts. It is universally recognized that it favors the resolution of the existing disturbances in severe blennorrhœa with great tension of the parts.

If the cornea has begun to be turbid at any points, or even if ulcers exist, which, in the severity of the inflammation, threaten a sudden extension and destruction of the cornea to a great extent, we shall have the most reason for trying this means of treatment.

Scarification and exsection of the chemotic conjunctiva, which were formerly much recommended, are, at least, very untrustworthy in their curative action. They are, besides, open to the objection that granulations readily arise on their surface, which become cicatrices, and cause a great tendency to constant irritations of the eye, and often even lead to incurable pannus.

d. If deeply-penetrating corneal ulcers have already occurred, which have become or threaten to be perforating, the same rules of treatment hold good as in primary corneal ulcers. But a paracentesis or iridectomy in the course of a blennorrhœal process should be avoided, because the inflammatory reaction in the vicinity of the edges of the wound is very apt to excite extensive ulcerations. Besides, the operation may deter us from the energetic use of the irritants which the main disease imperatively demands.

e. We need give ourselves no trouble about the use of internal remedies. Mildly acidulous drinks, barley-water with nitre, &c., may, however, be used with advantage when there is much fever. Mercurials should be avoided; even the inunction-treatment has been tried and found to exert no marked influence on the course of a blennorrhœa. Enemeta and eccoprotics may be used

for any constipation of the bowels. Narcotics generally do no good so long as the severity of the inflammation is unsubdued by the antiphlogistic treatment; but when this has been accomplished they are scarcely indicated.

8. One of the most important duties in the treatment of blennorrhœa is the careful removal of the secretions. That which exudes from the palpebral fissure is best removed by a little bunch of picked lint; all rubbing is to be avoided, since it easily leads to excoriation. For the purpose of cleansing the conjunctival sac, a stream of cold water may be conducted upon it, while the patient is lying down. As long as cold applications are being made, the patient will not bear tepid ones, on account of the great change in temperature. The stream of water is best conducted upon the eye from a sponge. Syringing the eye is very dangerous. The fluid may easily spirt back in the eye of the attendant; besides, it is very irritating. The palpebral folds should be exposed by everting the lids during the cleansing, or the operation will not be thoroughly done.

These manipulations should not be undertaken too often, because they become irritating and increase the inflammation. Generally speaking, five to six cleansings within twenty-four hours is the right number. Any more ablutions increase the swelling, render it tenser and hotter, and make it exceedingly sensitive to any contact, and thus the condition becomes considerably worse.

If crusts have formed on the lids and lashes, they should be softened by applications of cold water before they are removed; tepid water should not be used until the cold applications have been abandoned. When there are excoriations, an ointment should be applied.

In blennorrhœa of a milder form, with an inflammatory product which has a decided mucous character, we do well to confine ourselves, during the increase of the inflammatory action, and when it is at its hight, to a strict antiphlogistic treatment, as has been previously described, in connection with the cleansing with water. Astringents, caustics, and all irritants are not indicated under such circumstances, and, according to very large experience, are harmful rather than useful. They are only advantageously used when the inflamed conjunctiva is relaxed.

In true pyorrhœa, however, where the decomposing power of the inflammatory product comes into consideration, cleansing with water can only prevent the harmful influences of the secretion upon the cornea, when it is kept up day and night with very short intervals; but this, as has been said, can not be borne even if it were possible to carry it out. We are obliged to employ these means, which may for a time check the purulent secretion by a chemical alteration of the most superficial layers. An opportunity is thus afforded the surgeon of carrying out an energetic antiphlogistic treatment during the intervals.

Besides the nitrate of silver, we may use bichloride of mercury, alum, sulphate of zinc, sulphate of copper, as such applications. All these have, in addition to their destructive effect, an astringent action, by which gentle contraction of the walls of the vessels and of the connective tissue is caused. The nutrition of the organic material is impaired, and thus the amount and quality of the inflammatory product is influenced. Nitrate of silver, however, is to be preferred to all other remedies. It has the greatest chemical power, irritates the least, its action being limited to the surface, while the other remedies, if used in strong solutions, act very deeply, and therefore more readily excite irritations, which are especially to be avoided on account of the cornea.

During and before the highest stage of true pyorrhœa, weak collyria of one to three grains of nitrate of silver to an ounce of water are most to be recommended.

They should be dropped in immediately after the careful cleansing of the conjunctival sac. The lids should be freely moved about, and the solution brought in contact with all the folds of the conjunctiva, and left in the sac until its turbidness no longer increases. Then a little more of the collyrium may be dropped in. If this second application do not cause any more turbidness, the lids may be closed, and cold applications energetically used until a repetition of the application is demanded.

The instillation of even weak solutions of nitrate of silver is not perfectly free from danger. It must be confessed that its irritative effect, in a decidedly sthenic character of the inflammation, is disadvantageous, and may become very destructive. The chemical effect of the agent upon the cornea, which is scarcely to be avoided, should be considered. The cornea is deprived of its natural protection by the loss of the epithelial layer, and thus becomes more sensitive to the purulent secretion as well as to the subsequent instillations of the solutions of nitrate of silver. Considering these facts, some have entirely given up the use of solutions of nitrate of silver as eye-drops. Instead of using them, they pencil the suppurating conjunctiva, once to twice a day, with the nitrate of silver in substance, or with the mitigated nitrate of silver (nitrate of silver and nitrate of potash), or they pencil it with strong solutions of nitrate of silver, as is done in trachoma. It can not be denied that, by the careful employment of this method, the cornea can be certainly protected from injury. Yet the enormous swelling of the lids, the impossibility of everting them on account of the conjunctival intumescence, renders it almost impossible to pencil the whole conjunctival surface.

There are also decided disadvantages in these cauterizations. In using the solid stick, the depth of the action can not always be limited as we wish, on account of its deliquescence; furthermore, too strong a cauterization may cause cicatrices on the conjunctiva. The mechanical irritation of the slough, formed after a severe application, should also be considered. This slough is denser and more rigid, and consequently a greater irritant, the more vigorously the caustic is employed.

It must be evident that this irritation causes serious consequences in proportion to the severity of the inflammation. The pressure of the slough, and the difficulty of its separation by the movements of the lids, increase with the amount of the swelling and tension.

From this we may theoretically conclude that the advantages of severe cauterizations are considerably lessened by the effects of the slough which they cause. Experience confirms this theory.

A number of exhaustive and unprejudiced experiments have shown that, in a case of purulent conjunctivitis having a sthenic character, no preference can be given to the use of the solid stick or penciling, over that of weak solutions dropped in the eye. Indeed, the latter are to be preferred.

Nitrate of silver, excellent as its action may be as a caustic astringent, interferes with the energetic combating of the inflammatory process, on account of its irritative effect. It is, therefore, in a certain sense, to be considered an injurious agent.

4. In a mild attack of blennorrhœa, having chiefly a mucous secretion, it is time to pass over to the use of astringents, when the following symptoms have shown themselves: When the inflammatory redness has decreased or changed into a grayish or yellowish hue, from the deposition of turbid cells on the surface of the conjunctiva; when the swelling becomes softer, relaxed, its temperature only slightly elevated, and the secretion is still very abundant. Penciling the conjunctiva once a day, at most twice, with a solution of five to ten grains of nitrate of silver to the ounce of water, is generally the best method of application. In beginning this treatment great care is necessary. We must particularly observe whether the inflammation increases again after the application; if this be the case, we should proceed again to the antiphlogistic treatment.

5. If the lid has become everted, it should be replaced as quickly as possible It will generally be the lower lid which requires bringing back to the normal posi

tion. For this purpose we grasp some of the cilia, draw the border of the lid as far away as possible, at the same time bringing it upwards, and with the index-finger of the other hand pressing the protruding portion between the surface of the globe and the cartilage of the lid. When the swelling has disappeared from the level of the border of the lid, we let go; it easily returns to its normal position, and the tension of the edge of the lid prevents the tumor from returning.

But if the tarsus has become softened and elongated in a horizontal direction, the border of the lid can not keep back the swelled palpebral fold, and the lid returns again to its abnormal position. Then the treatment of the blennorrhœa should be energetically continued, and the lid left for the time in its false position, since all attempts to retain it in its place will result in harm. But when the secretion has become less, the replacement should be immediately undertaken, and the lid held by a proper bandage. Closing the palpebral fissure by long strips of isinglass-plaster, about two lines broad, will be sufficient to keep the lid in its normal position. It will be safer to place a bunch of charpie on the swollen lid, covering the swelling and the lower lid again with a flatter piece, and fastening the whole with a flannel bandage. Sometimes a few days suffice to replace the lid, and to cause the conjunctival swelling to disappear. Quite an amount of relaxation of the lid and of the conjunctiva is apt to remain, however, and frequently a trachomatous swelling in the latter. In order to remove this swelling we should pencil the conjunctiva daily with an ointment of sulphate of copper, or with solutions of nitrate of silver of medium strength, as in the treatment of trachoma.

Authorities.—*Eble*, Ueber den Bau und die Krankheiten der Bindehaut. Wien, 1828, S. 92, 164, et seq., die sog. contag. o. egypt. Augenentzündung. Stuttgart, 1839, S. 89.—*Piringer*, Die Blennorrhœ am Menschenauge, Graz, 1841, S. 7, 15, 40 et seq.—*Gulz*, die sog. egypt. Augenentzündung, Wien, 1850, S. 32, 49 et seq.—*Arlt*, Die Krankheiten des Auges, I. Prag, 1851, S. 18, 40 et seq.—*Stellwag*, Ophth. II. S. 782, 784.—*Frank* und *Marston*, kl. Monatbl. 1863. S. 124.—*Eiselt*, Zeitschrift der Wien. Aerzte, 1861, Wochenblatt, S. 97.—*Graefe*, Deutsche Klinik, 1864, S. 79; A. f. O. I. 1. S. 168 et seq.; II. 2. S. 242; VI. 2. S. 123, 124, 127; IX. 2. S. 122; X. 2. S. 191, 192, 196.—*Snellen*, kl. Mntbl. 1864, S. 394.—*Welz*, ibid. 1863, S. 502.—*Niemetschek*, Prag. Vierteljahrschft. 101. Bd. S. 70.—*Gosselin*, Schmidt's Jahrb. 127. Bd. S. 204; 134. Bd. S. 75.—*Mooren*, Ophth. Beiträge, S. 71.—*Kämpf*, Virchow's Jahresber. 1868. II. S. 489.

4. Ophthalmo-blennorrhœa infantum. Ophthalmia neonatorum.

From a purely scientific point of view, a mucous discharge from the eyes of children can not be regarded as a peculiar form of conjunctivitis. In individual cases it is sometimes a catarrhal inflammation, sometimes it is a pure blennhorrhœa, or one inclining to diphtheritic blennorrhœa. Again, it appears under the form of trachoma. Practically, however, a division of the ophthalmo-blennorrhœa of infants is desirable, since the peculiarities of the infant organism modify not only the course and results, but also the treatment, to a considerable degree. We may distinguish two different forms—the catarrhal and blennorrhœal. These are, however, connected together by numerous intermediate forms, and there often occur cases which may be counted with either variety.

Symptoms.—The most prominent symptom is the swelling of the parts. This is, as a rule, very great, and it is only in the milder forms of the inflammation that it is slight. The delicacy and looseness of the infantile tissue is very favorable to great exudation. Even in slight cases the lids then appear as large tumors, in front of the orbital opening. They are immovable, and the palpebral fissure appears closed. The upper lid often is pushed over the lower, nearly completely covering it. The palpebral conjunctiva is generally very puffy and relaxed. The palpebral fold projects, on drawing the lid away from the eye, as a large swelling, and therefore readily causes eversion of the lid, with all its consequences. The ocular conjunctiva is very often puffed up like a wall all around the cornea, so that the latter appears, as it were, buried in the swelling.

In the catarrhal form, the swelling has rather the character of pure or congestive œdema. The secretion is less abundant, or is not dense, and contains, together with flocculi and lumps of thick, turbid mucus, a large proportion of pus-elements, and hence looks like pure pus.

In the blennorrhœal form, the swelling is always chemotic, greatly reddened, hard, and tense, therefore shining, hot, and exceedingly sensitive to the touch. There is severe pain and photophobia, and, as a rule, active fever. Subsequently the swelling loses its erysipelatous appearance, becomes soft and wrinkled, while its color is bluish, the temperature and sensitiveness decrease. The secretion is very profuse. It is constantly evacuated from the conjunctival sac, and often runs in a stream down the cheeks, excoriating the integument, and thus causing inflammation. Particularly on a forcible opening of the generally spasmodically-closed lids, a considerable amount of the peculiar secretion flows out. This is generally very consistent grayish or greenish pus, having mucous flocculi, and only occasionally containing fibrinous deposits. It sometimes appears of the consistency of cream, again thinner, and even like whey. It is always seen intimately mixed with the tears.

Causes.—It is more than probable that bright light on the eyes of the newly-born may induce this form of ophthalmia. Sudden changes in temperature may also

produce it, and are often spoken of as causes of the disease. It is undeniable, however, that the most common sources of the affection are the impure air of a room filled with excrementitial exhalations, smoke, dust, or acrid vapors, as well as the musty, damp air of an unventilated room, uncleanliness of the clothing and body of the child, as well as uncleanliness of the hands of the attendants. The children of the poorer classes, especially in large cities, are much more frequently attacked than children who are well-cared for. The same is true of foundling hospitals, where all these deleterious influences, as well as others, may act, as it were, in a concentrated condition upon the poor little ones, and thus make the percentage of the affected ones very large. Sporadic cases are seldom wanting in these institutions, and very often their number becomes enormous. The disease appears as an endemic, in which not only infants, but also children of from one to two or more years old, are involved, as well as the nurses and attendants.

The proportion of those affected, and the relative number of the severer and milder forms of the disease, may be very different. Even during the same endemic, variations are observed. But generally the number of milder cases is by far the greater. True blennorrhœal forms are usually found in a relatively small proportion. It is rare that they exceed the number of the catarrhal affections. What produces this variation is not decided. It is probable that the character of the endemic is chiefly dependent, according to the time and circumstances, upon various unfavorable conditions under which the foundlings live, and which result from the collection of children and nurses in one room, and from the greater or less facility of ventilation, and a sufficient airing of the bed-linen. But all this by no means fully explains the variability in the severity and extent of an endemic, and therefore there remains considerable room for the acceptance of a varying *genius epidemicus*.

There is a great tendency to ascribe an especial influence to the constitution of the patient upon the severity of the process and the kind of secretion. But the variability in the character of a single endemic, when compared with the great stability which prevails in the material condition of the children, prevents us from considering this as more than a subordinate influence. It is certain that, during the same endemic, strong and well-nourished children are often affected with the severest forms of the disease, while feeble little ones have only a slight catarrh. If, in a bad endemic, the badly-nourished children furnish the largest number of severe cases, we may explain it by the fact, that such children are far more numerous than healthy ones in foundling hospitals.

But inoculation certainly should be considered as a cause of purulent ophthalmia in foundling hospitals. It is a very important factor in the spread of the disease, particularly if the unfavorable conditions have already caused a great number of persons to be affected with blennorrhœa. The necessary handling in the case of the children furnishes an exceedingly favorable opportunity for the transference of the contagious material.

Such a transference of blennorrhœal secretion, not only from the conjunctiva, but also from the mucous membrane of the mother's genitals, actually does exist, and often causes sporadic cases of purulent ophthalmia.

Much importance has been ascribed to the passage of the child's head through a vagina affected with blennorrhœa. (*Mackenzie.*)

Yet this is certainly not a very frequent cause of purulent ophthalmia. The eyes of the child are closed during parturition, and are also covered by sebaceous material; hence inoculation at that time is scarcely possible. Moreover, children are often attacked, whose mothers have no morbid genital secretion. The time of the outbreak of the disease shows that the inoculation must occur at a later period than that of birth.

In the existence of a blennorrhœal affection of either mother or nurse, there are very many opportunities for inoculation, especially if the mother be at all uncleanly in her habits.

It is even possible that the lochial discharge may give rise to ophthalmia neonatorum by being placed on the conjunctiva. It is, of course, true that the disease often begins just after birth, but it can not be denied that, in a very great number of cases, it first occurs in from two to four weeks after.

Course.—The ophthalmia almost always appears at first on one eye alone, the other being affected some days after, if it is not prevented by great care. The transference of the secretion from one eye to the other, seems to be the usual origin of the disease in the second eye.

In the beginning, the inflammatory symptoms usually predominate, and the characteristic secretion is not very abundant. If the disease be less severe, the hyperæmia, swelling, and local heat generally, increase more slowly, and it is often from five to eight days before they have reached their hight. In the worst cases, however, one or two days are often sufficient to fully develop the chemosis. Having reached its hight, the inflammation generally remains at this point one or more days, while the secretion evidently increases, and enables us to recognize the real character of the process as a catarrh or blennorrhœa. Then the swollen parts begin to be relaxed more and more, a profuse secretion occurring at the same time. The affection generally remains for some time at this stage. It is rarely possible to subdue it within eight to fourteen days, except it be a very mild case. The disease generally lasts several weeks before the eye is brought to a normal condition, as evinced by gradual decrease in the hyperæmia and swelling, a return of the proper color, and drying up of the secretion. The pyorrhœa then passes over into a simple catarrh.

Yet the course is by no means always a regular one. Just as in the blennorrhœa of adults, the character of the process is often different at different times in the same case. The severity of the inflammatory symptoms varies with the nature and amount of the secretion, which is a fact of great importance in respect to the treatment.

Results.—These are generally dependent upon the severity of the inflammatory process in a given case. The milder forms of the ophthalmia, in which true chemosis does not occur, in which the swelling has more of an œdematous character, and the secretion is predominantly mucous, are not generally dangerous, provided the disease does not increase or is not increased by improper treatment. With intelligent treatment it generally terminates in complete cure. Even a slight trachomatous swelling of the papillary bodies is not of much importance, because trachomatous granulations occurring in children are readily subdued.

Cases in which the inflammation is very severe, that is, where there are great chemosis and redness, and there is great heat of the parts, are much more dangerous, even though the quantity of the secretion may be quite small, and not of an alarming nature. Such cases are far more dangerous than severe blennorrhœa in adults, because experience teaches us that an extension of the inflammation from the conjunctiva upon the cornea occurs more readily in children than in them, and thus the functions of the eye are threatened by abscess and ulceration.

If the cornea begins to be turbid in some points, the danger has reached its hight, and every thing depends upon the extent that the destructive process may attain. Abscesses and circular ulcers are, in general, more favorable, because they rarely destroy the whole cornea. They allow more hope of a preservation of a portion of the visual power, or of slight injury to it, the more peripheral is their situation, and the more quickly the inflammation recedes under the employment of proper treatment.

Crescentic ulcers of the periphery, on the contrary, which appear to depend on a disorganizing effect of the secretion upon the corneal substance, have always a bad import, for they seldom stop, and often lead to complete destruction of the cornea, with all its results. Where peripheral softening and a central abscess occur together, it is only rarely that even a small portion of the cornea is preserved.

Eversion of the lid and permanent ectropion depending upon it, as well as the relaxation of the upper lid, on the whole, are of not much importance, because they may be removed by proper treatment.

Treatment.—The indications of treatment are, of course, not different from those in the same affection when occurring in adults. The means, however, of fulfilling these are somewhat different from those which may be properly employed in adults. On the one hand, they may become dangerous, because they are not well adapted to the exceedingly delicate infantile organism; on the other hand, they may be very troublesome or even painful to the child, and thus cause severe crying or struggling, which increase not only the irritation, but also the disturbances in circulation, by congesting the blood, and consequently augment the swelling and secretion.

1. We should attempt to prevent the occurrence of the disease. For this purpose it is to be recommended, in the case of the newly-born, or infants, to keep away, as far as possible, all dazzling light. We should prevent all contrasts in light or heat, endeavor to secure good ventilation, great cleanliness of the body and clothing of the child, as well as of the hands of the attendants and of the mother, in case she suffers from a lochial discharge, and still more if she is affected with vaginal blennorrhœa.

If the ophthalmia has once broken out, all these precautionary rules should be more carefully observed. In foundling institutes and children's hospitals, we must separate eye-patients from each other, and, besides, not allow nurses to take care of diseased and healthy children at the same time. We should see to it that the clothing of the affected children is not placed on the others without thorough cleansing, and that there be no crowding in the wards.

Of course, such precautions will increase the expense of carrying on an institution; but small souls may be quieted by the reflection, that even a moderate number of blind children going out of the hospital, cause the State much more trouble than it would to take these precautionary measures; so that the expense, on the whole, will not be any greater.

2. The direct treatment is mainly decided by the stage of the disease.

a. So long as this is not very severe, we should guard ourselves from doing too much, since this will certainly only cause harm. If the symptoms of irritation are slight from the beginning, if there is no great amount of swelling and the secretion scanty, we shall do well to simply confine ourselves to removing the secretion, by delicately washing the edges and angles of the lid with the finest picked lint, together with keeping away, as far as possible, any injurious influence. But if the secretion be somewhat more abundant, it is advisable to order applications of lead-water from time to time. Instillations of this agent should only be employed when the irritation has very much subsided, and the relaxation is very prominent, and when, besides, the abnormal secretion has continued a very long time, and external astringent applications have no effect. Even here we should always use mild means, collyria of lead-water, aq. destillat., in equal parts, of aq. opii, solutions of pure tannin gr. x. to the ounce of distilled water, which should be employed, according to indications, two or three times a day. We will do still better with a 1–8 grain solution of nitrate of silver, which can be brushed over the lids once or at most twice daily.

b. If the inflammatory swelling is very great, and if the ophthalmia on the whole is of a severe variety, or if a real blennorrhœa is present, these remedies are no longer sufficient; the disease demands an energetic treatment. This will be merely antiphlogistic so long as the symptoms exhibit a decidedly sthenic character. But when the acme is passed, if the swelling declines, becomes soft and yielding, and the secretion of purulent material remains large, we seek for an astringent action, and the disintegration of the secretion which is endangering the cornea. For the purpose of lessening chemical decomposition of the morbid secretion, instillations of weak solutions of nitrate of silver, one to two grains to the ounce, or penciling the conjunctiva with solutions of three to five grains to the ounce of distilled water, is to be recommended. The former should be done three to five times a day, the latter once or twice, and in the intervening time cold applications and repeated cleansing the eyes with cool water should be carried on, according as the circumstances may require.

The presence of corneal ulcers by no means changes the general indications in a blennorrhœa. Yet the condition of the pupillary margin should then be carefully considered, in order to avoid a prolapse of the iris, or at least to prevent any harm resulting from it.

Authorities.—*Mackenzie*, Prakt. Abhandlung über die Krankheiten des Auges. Weimar, 1832. S. 351. 354, Traduction par Warlomont et Testelin. I. Paris. 1856. P. 758.—*Piringer*, Die Blennorrhoe am Menschenauge. 1841. Graz. S. 23 et seq.—*Arlt*, Die Krankheiten des Auges. I. Prag. 1851. S. 51 et seq.—*Stellwag*, Wiener Jahrb. f. Kinderheilkunde II. 3. S. 126. III. S. 34.—*Alf. Graefe*, kl. Monatbl. 1865. S. 370.—*Graefe*, A. f. O. I. 1. S. 168, 236 et seq.—*Delgado*, kl. Monatbl. 1866. S. 214.—*Alf. Graefe*, Berlin. klin. Wochenschrift, 1868. Nro. 6.—*Stavenhagen*, kl. Beob. Riga, 1868. S. 38.

Diphtheritic Conjunctivitis—Conjunctival Croup.

Symptoms.—*The disease is characterized by the development of a yellow, tough, and firm product of inflammation, which collects not only in the tissue of the conjunctiva, but also on the free surface. This subsequently deliquesces as the affection progresses, and thus becomes a pus-like secretion, similar to that in pyorrhœa.*

1. The inflammatory symptoms vary in degree. Sometimes they are almost entirely absent. The conjunctiva, which is at intervals covered with diphtheritic patches, appears as white as wax, or is only traversed by an open vascular net-work. It is scarcely swelled, or it is puffed out with the lids by a serous or gelatinous infiltration, but no elevation of temperature is perceived.

But generally the hyperæmia, local heat, &c., are much more decided. In the greater number of cases of conjunctival croup, we find a very severe chemosis, and the disease greatly resembles blennorrhœa. The inflammatory redness in the integument of the lids and of the surrounding parts is then marked, varying in depth of shade, inclining to a bluish color. In the conjunctiva, this redness is only apt to be great in the beginning of the affection. Subsequently it recedes, particularly in the tarsal portion and in the palpebral folds. It may disappear in a grayish-yellow shade—large and rigid inflammatory products being deposited in the conjunctival tissue, and the vessels are actually pressed together, so that only a vascular, rough net-work remains evident on the surface. Single twigs from this suddenly emerge from the deeper parts of the tissue, and after a short course sink immediately into the grayish-yellow parenchyma of the conjunctiva, which is spotted with blue extravasations.

The swelling of the lids, under such circumstances, is generally very great, and, in consequence of the rigidity of the infiltration, marked by a very great, almost wooden, hardness. The surface of the swollen conjunctiva generally appears smooth, although a fine granulation is often seen on the tarsal portion. Subsequently large trachoma-like granulations are formed on the palpebral conjunctiva, or losses of substance occur in consequence of partial death of the tissue. The heat of the parts in such cases is always very great. It is often experienced by the patient as a sensation of burning heat. The affected portions are exceedingly painful, and extremely sensitive to the touch. The whole system is generally affected at the same time, which is indicated by fever, and not unfrequently by analogous changes in other mucous tracts. (*Graefe.*)

2. The diphtheritic product collected on the surface of the conjunctiva is often only seen as a thin, gauze-like, reticulated coating, or a delicate, continuous layer of grayish-yellow, grayish-white, or pus-like color. As it is thin, the infiltrated conjunctiva, lying under, may be often seen through it. Just as often, however, it forms dense, opaque flakes of varying size, and with very irregular contours, which are occasionally continued over the inner lip of the lid, in a zigzag way, upon the free surface of

the lid-border, as it were, grasping over it. It is only exceptionally that the diphtheritic product forms a membranous coating of some density, which covers the whole of the conjunctiva. These products are firmly adherent to the conjunctiva, and an artificial separation always excites an abundant parenchymatous hemorrhage.

3. Besides this product adherent to the conjunctiva, we always find in the conjunctival sac a larger or smaller quantity of fluid secretion. This depends partly on the deliquescence and the throwing-off of the diphtheritic deposits. In the beginning this secretion is thin, on account of the quantity of tears which it contains. It is like whey, of a dirty-gray color, translucent, and contains a number of grayish or grayish-yellow shreds and flocculi. Subsequently, as the deliquescence of the diphtheritic product goes on, it becomes more like pus, of a yellowish-green color, is more consistent, and appears at times as thick as cream. It is often mingled with large rigid flakes, which have been separated here and there from the surface of the conjunctiva. It is generally quickly replaced, until the process has changed in character.

Causes.—Diphtheritis conjunctivæ is often merely the local manifestation of a general process, which occurs simultaneously upon different mucous membranes, particularly of the air-passages and larynx, and is frequently connected with exanthematous processes, as measles, small-pox, scarlatina. The disease then bears usually an endemic or epidemic character (*Graefe, Hirschberg*). Moreover, the etiology of diphtheritis conjunctivæ coincides for the most part with that of the other forms of conjunctival inflammation, since the same external noxious principles, which cause a blennorrhœa, etc., can also set up the diphtheritic process. The excessive employment of strong solutions of lunar caustic and of the mitigated stick (argent. nitr. and potass. nitr.) must be particularly considered as an important exciting cause. There is no doubt that not a few cases of croup originate from an increase in the process of luxuriant growth in consequence of the careless employment of caustic remedies. The disease is therefore more rare, where the means of treatment under consideration are only attempted in cases of extreme necessity.

Inoculation, without doubt, is also an important cause, and may particularly influence the extension of an epidemic or endemic (*Horner*). Observations and experiments show diphtheritic conjunctivitis to be decidedly contagious, and the fluid purulent secretion is proven to be the source of contagion. Introduced upon the sound conjunctiva, it generally again excites a diphtheritic conjunctivitis, more rarely a blennorrhœa of the pure form, whose inflammatory products may again excite a diphtheritic conjunctivitis. It may not be denied, however, that diphtheritic conjunctivitis occurring in children may be considerably favored by certain conditions in the constitution of the children themselves. In many cases these conditions are alone sufficient to excite the disease.

The participation of the entire organism, as manifested by febrile action, goes to support this view. It is also proved by the fact that weak children, from mothers themselves diseased, and those who are badly nourished, or are really sick, or affected with constitutional syphilis, and particularly those of two or three years of age, are more inclined to diphtheritic affections than others. In this respect the frequent combination of conjunctival croup with croup of other mucous tracts in the same persons, and the more frequent appearance of diphtheritic conjunctivitis at times, in which other diphtheritic affections, especially those of the respiratory organs, as well as puerperal fever, prevail, are all strong proofs of the correctness of this view. (*Graefe.*)

The Course is quite variable. Thus cases occur, especially in adults, in which the diphtheritic conjunctivitis only forms an episode in the course of a blennorrhœa,

the secretion at times attaining a greater consistency and adhering to the conjunctiva, but then becoming fluid; or the diphtheritic conjunctivitis is primarily developed, but immediately passes over into a blennorrhœa. These are always mild cases, really transition forms, in which the croup of the conjunctival tissue is very little developed, and, on the whole, plays a very subordinate part.

Where the characteristic changes in the conjunctival parenchyma are more prominent, as is more frequently the case in children, the disease has a more permanent form. It may then have been gradually developed from another form of conjunctival inflammation, or have appeared as such from the beginning. In the latter case the disease is generally accompanied by active symptoms, and two to three days are sufficient to bring the disease to perfection. It often reaches its highest point by this time. Here, as a rule, it remains for some days. Then the inflammatory symptoms begin to recede somewhat, without the infiltration of the tissue undergoing any considerable change. It generally requires one or more weeks, before the hardness of the infiltrated conjunctiva and its grayish-yellow fawn-color disappear. We then find the conjunctiva more or less deeply reddened, at the same time relaxed, spongy, and covered over by purulent secretion. Its surface also often appears covered by large warty excrescences, which bleed readily; the diphtheritic conjunctivitis is a trachoma changed to a blennorrhœal secretion, and proceeds in the peculiar way of this form of inflammation.

In other cases of the worst form, as soon as the disease has reached its hight, the necrotic destruction of tissue begins. The deposits are thrown off in spots, leaving behind deep losses of substance, upon the surface of which the exposed and eroded vessels not unfrequently cause severe hemorrhages. While the infiltration deliquesces to a greater or less extent, and the abundant purulent secretion, which is often ichorous, continues to increase, the tissue of the conjunctiva becomes more and more relaxed, and, as it were, more succulent, and spongy, red excrescences, which bleed readily, spring up like islands from the grayish-yellow conjunctiva. (*Graefe.*) These excrescences again dellquesce, while their surroundings also become relaxed and spongy. The result is a severe trachoma with purulent secretion. Occasionally the already-existing spongy softening is interrupted by a repetition of the diphtheritic exudation, and this latter may relapse two or three times. But generally the process, with the commencing relaxation, advances toward the end.

Results.—Diphtheritic conjunctivitis is undoubtedly one of the most destructive diseases of the eye. When the disease is severe, especially when there is sudden and great infiltration of the conjunctival tissue, and it runs its course without any injury to the eye, we may think it a piece of good fortune. In adults, evil results are more to be feared than in children. As in other epidemic diseases, the percentage of unfavorable cases is said to be greater at the commencement of the epidemic than at the decline. (*Graefe.*)

Diphtheritic conjunctivitis endangers the functions of the eye much more than blennorrhœa, so that we may consider it as a good prognostic sign when, with gradual relaxation of the conjunctiva, its color passes gradually into red, and the disease resembles blennorrhœa. Our apprehension ceases when the secretion changes to one which is principally mucous, but even here the possibility of a return of the diphtheritic secretion and deposition in the tissue of the conjunctiva should not be forgotten.

The cornea may be destroyed by extension of the inflammation upon its tissue, and by the formation of an abscess. It may also be changed, by the disorganizing influence of the secretion, into an ulcerative process extending from the surface

inward. The first danger is particularly threatening, while the process still increases or remains at its acme, with severe inflammatory symptoms. But the second danger exists as long as the fluid secretion has a purulent character. Ulcers which occur in the beginning, or during the first stages of the process, are worse than those which occur in the later stages, because the latter more frequently limit themselves, while the former very generally lead to total destruction of the cornea.

The conjunctiva may be injured by a partial or complete adhesion of one or both halves of the conjunctival sac, or by adhesion of the conjunctival portions which are in contact, that is, by the occurrence of a posterior or anterior symblepharon. It may even undergo the changes known as total or severe xerophthalmia.

A similar result arises from the degeneration of the spongy, softened proliferating tissue, from its shrinkage, shortening, and complete change into cicatritial tissue. This happens most frequently, if the proliferating conjunctival tissue, in consequence of partial ulceration or necrotic exfoliations, suffers loss of substance. Then cicatritial, tendinous net-works or patches are formed, between which the spongy proliferations appear like little islands. These excrescences gradually sink inward. The space undergoing tendinous degeneration increases, and finally those permanent results have been developed, which leave no hope for a restoration of the functions of the eye. Such a sad termination is, however, only to be feared in very severe croup. In the, happily, more frequent cases of less severity, the diffuse trachoma which remains behind may be generally subdued by appropriate treatment.

Treatment.—Together with an exact fulfilment of the indications that spring from the cause, the treatment should aim at a limitation of the tissue proliferating process, and, as far as possible, an improvement in the circulation and nutrition of the infiltrated portion. We should also attempt to guard against the dangerous effect of the secretion upon the cornea, and reduce to a minimum the injuries which can not be prevented.

1. The indication springing from the cause demands not only the removal of every thing which may maintain or increase the process, but it also aims to prevent the spread of the disease by contagion.

2. The indication from the disease naturally requires an antiphlogistic treatment, and should be more vigorous the severer is the process, and the more decidedly its sthenic character is indicated.

a. Where the conjunctival croup runs its course with the symptoms of a pure chemosis, when there is great hyperæmia, the swelling is hot and tense, the energetic use of cold, with extensive local blood-letting and the severest antiphlogistic regimen, is imperative in almost all cases.

Under such circumstances especial weight is to be laid upon the uninterrupted application of iced compresses. Leeches should be applied in great number on the temporal or angular region, and the subsequent bleeding encouraged. Some authors recommend deep incisions, passing through the infiltrated conjunctiva into the vascular layer beneath, instead of leeches. These cause profuse hemorrhage, and besides may considerably improve the circulation by relaxing the tension of the infiltrated portions. (*Jacobson.*) The great use of such an incision is disputed, however, by others, and the deposition of a diphtheritic exudation on the surface of the wound is one of the consequences feared. (*Graefe.*)

Among the pharmaceutical remedies, mercury has been most frequently used, and in large doses, often even to the extent of salivation. (*Graefe.*)

Yet those who have most faith in mercury confess that in some cases it has been of no use, and has even done harm. We naturally expect still less from the alkaline carbonates which were at one time in use. Internal remedies are therefore almost abandoned. When there is great febrile action, however, the employment of digitalis, aconite, &c., may be proper, since expe-

rience shows that they lessen the vascular excitement. Narcotics appear to be indicated especially in very restless children.

b. If the inflammation has passed beyond its hight, if the temperature of the swelling has considerably sunken, if the conjunctiva appears bloodless, perhaps on account of the great amount of the infiltration, and its nutrition is impaired to this extent, there is no good reason for the continuation of the iced compresses and local blood-letting. Gangrene of the tissue might be favored by any further lessening of temperature, and impairment of the nutrition. The therapeutical results attained up to this time, at least, suggest this idea. In respect to the local abstraction of blood, particularly in children, its effect upon the whole mass of blood is to be considered, because experience shows that it is greater on weakly, reduced subjects, who suffer from conjunctival croup, than in healthy and vigorous patients. We have become, therefore, as it were, disinclined to the incisions, with their doubtful result, and also to antiplastic internal remedies, that are absolutely and certainly inefficacious. Under such circumstances, in the helplessness of our position and the destructiveness of the affection, the results of treatment have been very lamentable indeed.

In consideration of this, the application of a pressure-bandage, with a cushion of lint, dipped in a solution of nitrate of silver, gr. x. ad ℥j aq., destillat. is to be recommended.

This method is particularly appropriate in children, who oppose every application which is at all painful, or even unpleasant, by severe crying, struggling, &c. They thus render even the use of excellent remedies dangerous, or actually injurious.

Very brilliant results have been attained by this method, not only in isolated sporadic cases, but also during two endemics of a malignant character, in one of which the method indicated under *a*, carried on by a skillful hand, was sadly inefficient. We do not mean to say that nitrate of silver, applied in this way, is an excellent or even satisfactory means of treatment. On the contrary, it is admitted that, especially in certain epidemics, it has often proved inefficacious. Therefore, in the worst cases, its value is only to be considered as relative, being compared with remedies previously employed, and it has still the advantage, that its use involves less danger in the case of children.

c. Where conjunctival croup appears with marked paleness of the conjunctiva and of the lids, with decided œdematous swelling of the parts, and in the absence of any elevation of temperature, a strict antiphlogistic treatment is not appropriate, and the use of nitrate of silver in connection with the pressure-bandage has not been justified. The strictest care of the eyes, the prevention of any irritation from reaching them, causing them to be covered with a fold of soft linen, will then be sufficient, or will at least do no harm. It is to be here remarked, that such a form of conjunctival diphtheritis often occurs in very weakly, poorly-nourished children, and, in spite of the want of local symptoms, has an exceedingly destructive course An appropriate constitutional treatment is then indicated, but has no greater effect than local treatment. The cornea generally quickly ulcerates, and the child often dies soon after.

3. In order to prevent the destructive influence of the pus-like secretion upon the cornea, the conjunctival sac should be kept as clean as possible. Unfortunately, the tension and size of the palpebral swelling, as well as its great sensitiveness, generally prevents the complete cleansing, and in case we do succeed, a few minutes are sufficient to fill the conjunctival sac again. Frequently-repeated attempts to clean the eye annoy the patient very much, and increase the inflammation. Instillation of nitrate of silver, or penciling the conjunctival surface with solution of the

same agent, as is done in blennorrhœa, have been found to be exceedingly injurious, and are almost generally recognized as pernicious. There then remains nothing more to do than to frequently cleanse the eye from secretion, by means of a bit of picked lint, or the like. If the protective bandage be used, the compression of the conjunctival sac prevents any great collections; besides, the secretion issuing from the palpebral fissure is readily absorbed by the cushion of lint, and chemically changed by the nitrate of silver.

We should particularly see to it, that pseudo-membranes, which have become partially detached, do not remain behind in the conjunctival sac, because, on the movement of the lids, they readily roll together, and cause considerable irritation. They should be carefully removed.

4. If the relaxation of the conjunctiva is already farther advanced, if the diphtheritic infiltration be entirely wanting, and if the symptoms of blennorrhœa are prominent, or if the whole tarsal conjunctiva proliferates in the form of a diffuse trachoma, then we should begin with the treatment proper for a purulent secretion from the conjunctiva, or for trachoma.

5. When the infiltrated conjunctiva has become gangrenous, any treatment may do harm. Perhaps the use of moist heat may do some good, e. g. cataplasms.

6. Ulcerations in the cornea furnish different indications according to the circumstances of the case, but they do not in any manner change those which depend on the diphtheritic process.

[The accepted general treatment in the United States, for diphtheria in any form, is the administration of iron and nutrients, e. g. beef tea, until the patient has rallied from the depression caused by the disease. We suppose that this is as applicable in diphtheritic conjunctivitis as in any other form of this blood-disease.]

Authorities.—*Graefe*, A. f. O. I. 1. S. 168, 176, et seq., X. 2. S. 196.—*Pils*, Lehrb. der Augenheilkunde. Prag. 1859. S. 322.—*Jacobson*, A. f. O. VI. 2. S. 180, 196, et seq. Königsberger med. Jahrb. III. S. 78. et seq.—*Pugenstecher* und *Sämisch*, Klin. Beobachtungen. I. Wiesbaden. 1861. S. 10.—*Stellwag*, Wiener med. Jahrbücher f. Kinderheikunde II. S. 126. III. S. 84; Weiner med. Jahrbücher. Fachbericht. 1861. S. 246, 1862. S. 74.—*Berlin*, kl. Monatbl. 1864. S. 259.—*O. Becker* und *Tetzer*, Wiener med. Jahrbücher. 1866. 4. Heft. S. 35.—*O. Becker* und *Tetzer*, Wiener Augenklinik. Ber. S. 44, 46.—*Mooren*, Ophth. Beob. S. 69, 70.—*Horner*, kl. Monatbl. 1869. S. 129.—*Hirschberg*, Berlin, kl. Wochenschrift. 1869. Nro. 3.

6. Trachoma, or Ophthalmia Granulosa—Granular Conjunctivitis.

Symptoms.—*This affection is characterized by a peculiar roughness, hyperæmia, and swelling of the conjunctiva. These changes are seen on the tarsal portion, sometimes as hypertrophied papillæ, again as diffuse, vascular excrescences, deeply rooted in the conjunctival tissue itself, like condylomata, but which are arranged in rows on the palpebral fold, and resemble roundish granules. They are sometimes of the same color as the conjunctiva, and only slightly prominent, but again are greatly elevated from its surface, and from their shape and gelatinous translucency resemble the spawn of fish or frogs.*

The appearance of the disease is considerably modified by the greater or less development of the irregularities on the conjunctiva, and according to the conditions in which the individual forms unite on this membrane. Thus, from a practical point of view, the distinction of several varieties of trachoma seems useful, since these differences affect not only the course, but the results and treatment, of the disease. The various forms are:

Pure granular.
Papillary.
Mixed.
Diffuse.

A. a. In a mild case of granular trachoma, we find the base of the palpebral fold, especially the lower half, abundantly strewn with bodies resembling the spawn of frogs, which are somewhat swelled, and are traversed by a coarse, vascular network. The tarsal portion appears somewhat more injected than normal. In the worst forms the swelling of the palpebral fold is very great. If the lids are everted, it appears like a large tumor, whose surface is thickly coated with larger or smaller spawn-like granules, and consequently has a very glandular appearance. The individual granules are sometimes greatly reddened at their base, sometimes surrounded by a pale-red confluent border, but more frequently there is a marked swelling, which is quite pale, because the granules rest on a very pale, wax-like basis, only traversed by a few little vessels. The tarsal conjunctiva is, at the same time, generally very smooth, relaxed, and more or less deeply injected. Often we find on it smaller spawn-like granules. More frequently, fine papillary granulations are seen, which indicate a transition to mixed trachoma.

b. Pure papillary trachoma is, in the nature of things, always confined to the papillary region of the conjunctiva, and is an ophthalmia granulosa of a low degree of development. The tarsal conjunctiva is a little relaxed, and its surface thickly strewn with fine granulations. These begin about one line from the inner lip of the lid, as extremely fine irregularities in the surface, of the shape of a truncated cone, gradually increasing in size posteriorly. In the region of the convex tarsal border, beyond which they pass for about a line, they are quite large, and are shaped more like papillary tubercle, having a thick pedicle. The papillary region, with the proliferating papillæ upon it, as long as the inflammatory process is active, and in gen-

eral during conditions of severe irritation, appears sometimes of a bright red color, and again darker, of a bluish tint, and, in scorbutus, it is a purple-brown. Subsequently, the hyperæmic redness becomes paler, and, in consequence of the more abundant collection of opaque cells on its surface, has more of a rose-red, violet, or dirty grayish-brown, tint.

c. Mixed trachoma, which has been described by others as catarrhal inflammatory, or blennorrhœal inflammatory, trachoma (*Seitz*), is the most frequent—indeed, it is the ordinary—form of ophthalmia granulosa. The image of the disease is made up from the symptoms of granular and papillary trachoma. The papillary region is markedly swelled, somewhat relaxed, and thickly covered by papillary excrescences, which generally far exceed the pure papillary trachoma, and often form a transition to the diffuse form of granulations by their broad base, nodular shape, and disposition to run into each other.

The palpebral fold, on eversion of the lids, is pressed forward like an elongated tumor, on whose surface the trachomatous bodies rest, arranged in rows. But they do not always have the characteristic spawn-like appearance, as in the pure granular trachoma. On the contrary, they appear, as a rule, much less developed, and are therefore readily overlooked. From their close arrangement in rows, they look like small, slightly elevated swellings or borders, of the same color with the hyperæmic basis, on whose surface shallow and oblique indentations, at equal distances from each other, indicate the individual granules. Still, very frequently, isolated granules in these swellings stand out prominently from their pale color, as well as their greater translucency and larger size. We not unfrequently find these little swellings composed almost entirely of such diaphanous and distinctly-marked granules, and interspersed with isolated, spawn-like bodies. But a predominance of these completely-developed spawn-like granules, or an exclusive formation of the swellings, from irregularities of the latter kind, is one of the most unfrequent occurrences in mixed trachoma. In the latter case, the redness, just as in pure granular trachoma, is somewhat less. In other places the palpebral fold and the tarsal conjunctiva generally appear uniformly red. The shade of color is, according to the severity of the disease, sometimes of a light-red, again of a dark blood-red, or mixed with gray, playing into a rose, violet, or bluish color.

d. Diffuse trachoma may be described as a higher grade of development than the mixed trachoma, and is distinguished by the amount of neoplastic formations in and upon the conjunctiva, as well as by the ordinary participation of the cartilage, of the integument, and the cornea. The papillary region is greatly swollen, relaxed, spongy, and covered with diffuse granulations up to a point near the inner lip of the lid. These raise up from the deeper layers of the conjunctival tissue, and are very irregular neoplastic formations. They are separated from each other by deep fossæ. They are superficially velvety, or villous, occasionally resembling a cock's comb, or broad condylomata. The palpebral fold is greatly flattened, and thickly covered with trachomatous granules, which, just as in mixed trachoma, vary in size, translucency, color, &c.

The frequent occurrence of large duplicatures in the hypertrophied palpebral folds deserves especial mention. (*Ammon.*) These folds may be found on any portion of the conjunctival sinus, although in the greater number of cases they are only an enlargement of the *plica semilunaris*. Not unfrequently they are an inch in length, with a breadth of several lines, and very generally attain a very great thickness. They cover a large portion of the anterior surface of the globe, like a third lid. In the first stages of trachoma, as long as the sub-conjunctival tissue is still very

much swelled, we scarcely ever find such folds, at least not of the size just mentioned. It appears as if the shrinkage of the sub-conjunctival tissue had something to do with these formations.

B. The picture of trachoma is completed by a number of morbid symptoms of subordinate importance, which are common to all or several forms of the disease.

The semilunar fold and caruncle are greatly swelled and reddened. In severe granular and mixed as well as in diffuse trachoma, the former is often thickly covered with spawn-like bodies.

The ocular conjunctiva in granular and pure papillary trachoma is not unfrequently quite normal during the entire course of the disease, or, at the highest, shows some evanescent vascular injection. In severe granular trachoma, sometimes in the later stages, it attains a very peculiar waxy appearance, and contains spawn-like granules in the zone near the palpebral fold. In mixed and especially in diffuse trachoma it generally appears in the beginning greatly injected, often evenly reddened, swelled by serous infiltration, frequently even really chemotic. In the decline in the disease, the swelling rapidly diminishes, the even redness is lost in an irregular vascular net-work, and this finally disappears, so that the ocular conjunctiva at times looks quite normal, and only shows the pathological condition of the vessels by its extraordinary tendency to congestion. In the diffuse form, it sometimes occurs that, after the decrease of the swelling, quite an amount of hypertrophy is recognized by the spongy relaxation and by a decided thickening of the tissue.

The secretion, generally speaking, is always increased. In the beginning, the lachrymal secretion generally predominates, the fluid is watery. In granular trachoma this often continues as long as the disease continues, although the tears are somewhat viscid, and are of a yellowish hue. In the other forms small flocculi of turbid mucus are at the same time mingled with it, and these increase rapidly, so that the secretion resembles that of a severe acute catarrh, and at times even a blennorrhœa. In the later stages, after the process has passed into the chronic course, it again decreases in quantity, becomes turbid and of a mucous character, as in a chronic catarrh. The patients then complain, at intervals, of exceedingly annoying dryness of the conjunctival sac.

The lids, when the proliferation process is severe, that is, in the beginning of the severe forms, are frequently slightly reddened and swollen more or less, not unfrequently chemotic, like the conjunctiva. If the severity of the inflammation decreases subsequently, the swelling recedes and the normal color returns. Yet the mobility remains somewhat impaired. This is particularly true of the upper lid, whose edge is always decidedly depressed, so that the palpebral fissure seems somewhat narrowed. The swelling of the palpebral fold hinders to some degree the action of the levator palpebræ.

In the severer forms of granular trachoma, as well as in the mixed form, and especially in diffuse trachoma, the inflammatory participation of the cartilage is added to this. This swells, relaxes, loses its resisting power, and is easily distended under the pressure which the conjunctival swelling causes, and is enlarged in the direction of the palpebral fissure, so that the edges of the lids are elongated. If the conjunctival swelling has been chemotic, and if it rapidly decreases, the lids do not then fit the globe. The upper lid hangs down loosely and frequently covers a portion of the lower. But the latter stands off from the globe, or sinks down from its own weight, even becomes actually everted, exposing the granulated palpebral conjunctiva—a condition which has been called *ectropium luxurians.*

In severe granular trachoma, the meibomian glands are at times affected, as is evinced by great swelling about their openings, and by their consequent appearance as granules, which perfectly resemble those of the palpebral fold, and are closely pressed together on the inner lip of the lid.

The vision is generally somewhat impaired. Cloudy vision is a very common symptom, especially in the morning. Besides, the eyes are very irritable. They are very sensitive to every external injury, especially to smoke, dust, wind, impure air, bright light. They will bear no kind of straining, reading, writing, or any kind of fine work; artificial illumination, particularly, excites the most unpleasant sensations, causes a marked increase of the hyperæmia and secretion, and even favors the proliferation of tissue.

The cloudiness of vision depends, on the one hand, on the mucous secretion of the conjunctiva, and on the other on the thickening of the epithelial layer of the cornea. The latter appears again to be dependent in part on increased formation, partly on decreased throwing-off of the epithelium as a result of the limitation of the movements of the lids.

The process is frequently continued upon the cornea, and becomes a vascular keratitis, which subsequently leads to trachomatous pannus. Occasionally a distention of the cornea occurs, with its extremely unpleasant results—staphyloma or ectasia, resulting from pannus, on account of the lessening of the resistance of the corneal tissue.

Complications.—Besides the complications, which occur where trachoma accompanies blennorrhœa, diphtheritic and membranous conjunctivitis, and which are really no complications, but only blennorrhœa, &c., in which the morbid conjunctiva is at the same time hypertrophied, the complication with herpetic or phlyctenular disease should be especially mentioned, since this very frequently affects the treatment very markedly, and to some extent the course and results.

Such a complication is always indicated by a severe injection of the episcleral and conjunctival vascular net-work, by pain and photophobia, lachrymation and spasm of the lids. These symptoms then generally continue until the herpetic process has run its course. Not unfrequently relapses of the phlyctenular disease lead to herpetic pannus of the conjunctiva and of the cornea, or extensive corneal ulcers are developed on the basis of herpetic efflorescences.

Causes.—It does not seem as if trachoma were a symptom of any constitutional disease. It seems to be a purely local affection, always caused by external injuries affecting the conjunctival sac itself. These injurious influences are the same that have been described as the exciting causes of catarrh, blennorrhœa, &c. Why it is, that in one case one form of conjunctivitis is excited, and in another a different one, is not fully explained. Still, it can scarcely be improper to assume that the frequent or even the uninterrupted effect of noxious influences may cause a tendency to hypertrophy, by the maintenance of a certain condition of irritation. Thus the proliferating process, having once broken out, may come to be trachoma in the conjunctiva, which is, as it were, prepared for it. This agrees well with the fact, that places in which a great number of people live together, and where care, cleanliness, and ventilation are insufficient, furnish the greatest number of cases (*Cunier*), while persons who are only at long intervals, and for a relatively short time, exposed to such influences, are more rarely affected with trachoma, having acquired instead of it a catarrh, a blennorrhœa, &c.

Contagion plays the most important part. The number of cases caused in this

way is at any rate in excess, especially in places in which a great number of persons live together, and come in contact, or use the same washing materials, as is apt to be the case in barracks, workhouses, hotels of the lower class, &c. If in such places a number of persons once become affected with trachoma, and if these are not carefully separated from the healthy ones, the number of those affected increases very rapidly. Thus contagion becomes an important factor in the development and extension of certain endemics and epidemics, which have become a permanent plague. In the same way may be explained, by the contagious property of trachoma, the examples of the disappearance of the disease from the place where it originated, to appear in branches of the family or in entire households who were in places completely free from the disease, and who were not exposed to the noxious influences which first excited trachoma.

The purulent and muco-purulent secretion of a trachomatous conjunctiva must alone be considered as the bearer of the contagion. The watery secretion of the pure granular trachoma, as well as the turbid mucous product of ancient papillary, mixed, and diffuse trachoma, which contains no pus-elements, is scarcely contagious, or only very slightly so.

The destructive power of the conjunctival secretion is the greater in proportion to its resemblance to pus, and the severity of the inflammation.

It should be here remarked that a trachoma by no means always results from such a transference of the trachomatous secretion. Occasionally a pure catarrh or a blennorrhœa occurs. But on the other hand, again, the secretion of a pure catarrh, or pure blennorrhœa, a urethral discharge brought in contact with the conjunctiva, may excite not only a blennorrhœa, but also a mixed or diffused trachoma.

Up to the present time there is no reasonable ground for believing that contagion is possible, except by the immediate contact of the conjunctiva with the contagious secretion itself. Contagion through the air, it being the carrier of finely-divided, dust-like particles of the contagious secretion, it is true, is not impossible; but it has not been demonstrated. Such a view has not indeed even been once made to appear probable.

If the air were the carrier of the contagious material, the number of cases among soldiers would be the same as among other classes of men. But the number is incomparably greater among the former than the latter.

It is believed that children under five years of age are not liable to trachoma. This may be true of pure granular trachoma, but papillary, mixed, and diffuse trachoma are by no means unfrequent in children. Persons also more than fifty years of age are not, as some believe, free from the danger of trachomatous disease. There is no doubt, however, that the period of life between twenty and forty years of age furnishes the largest proportion of cases, and that, not speaking of soldiers, males are much more apt to suffer from the disease than females. The reason of this is easily seen by a merely superficial examination of the causes of trachoma.

Course.—Trachoma is, in the strictest sense of the term, a chronic affection. Still, the manner of its course varies exceedingly.

1. The manner in which trachoma is developed is very different in different cases.

a. In persons who, on account of their way of living, are frequently, or even continually, exposed to irritations of the conjunctiva, it not unfrequently occurs that what are apparently very evanescent catarrhal inflammations are often repeated at short intervals, but always disappear either spontaneously or by the aid of treat

ment. But these attacks always add a few granules and granulations to those already existing, until finally the symptoms of trachoma are evident.

b. In other cases, it is thought in the beginning that we are dealing with a severe catarrhal inflammation, a herpes, or the like. These processes are protracted, however, have exacerbations and remissions, while the trachomatous excrescences gradually appear, and increase more and more, until finally the symptoms of trachoma get the upper hand.

c. Trachoma is very often developed in an acute and independent way. The conjunctiva becomes suddenly injected with troublesome sensations or pain, a rough vascular net-work may be seen on the lateral portions of the ocular conjunctiva, while at the same time it becomes œdematous. The hyperæmia of the conjunctiva increases rapidly, as also the subjective symptoms, and with them appear the secretion of a great quantity of tears, mingled with muco-purulent flocculi. Within a few hours or days it becomes general. The lids are reddened, œdematous, sensitive to pressure, especially about the borders of the lids; they are moved with difficulty, and therefore the palpebral fissure is narrowed or even closed. If we now examine the conjunctiva, its roughness will be seen to be very decided, and within a short time the trachoma has become very severe.

d. Mixed and diffuse trachoma also frequently occur during the course of a blennorrhœa, diphtheritic or membranous conjunctivitis. The trachomatous proliferation of tissue is often manifest in the first stages of these processes. The roughness of the conjunctiva, however, often first appears at the highest stage, which is then apt to last for a very long time. But the granules and granulations are first noticed when the process is already on the decrease.

2. The severity of the inflammatory symptoms subsequently diminishes, and the relaxation of the parts is very strikingly seen. Then a continual variation between exacerbations of the irritations and remissions occur, which latter are often so complete, in mild cases, that the patient scarcely notices that his eyes trouble him, and is only annoyed by the cloudiness of vision at times, as well as by the inability to bear even slight irritations. In this way trachoma may exist for months and years, without changing to any extent, until it is finally cured or arrives at a permanent form, or suddenly has an impetus given it by a new injury, and appears again in a more acute form.

Results.—1. Trachoma of any variety may get well spontaneously. The way to this is through resorption of the granules, never by suppuration. The papillary and diffuse granulations may, however, be obliterated by continual throwing-off of their superficial epithelial layers, and the retrocession and absorption of the new elements in the parenchyma of the different parts of the conjunctiva.

The prospect of spontaneous and complete cure is the greatest in children. Even a diffuse and severe trachoma often disappears within a comparatively short time; in young persons within a few weeks or months, without leaving any evil results. In adults we have less hope of this result. Recent trachoma of not a very severe form, in adults, not unfrequently gets well of itself, but months are always required for this, and it is presupposed that the patient is placed under perfectly favorable conditions, and that the causes producing trachoma have been repressed. Severer mixed and diffused trachoma, occurring in adults, only very exceptionally get well spontaneously. In by far the greatest number of cases, permanent injury of the conjunctiva occurs, if a rational treatment has not been entered upon. These

may impair the functions of the lids and of the cornea. The hypertrophied tissue hardens, becomes thicker, and finally becomes dry, bloodless, and tendinous, and at the same time lessens in size by shrinking.

a. In consequence of this the papillary granulations become very much smaller, without losing their peculiar shape. They are very pale, grayish, opaque, or even translucent and colorless, like a kind of dirty glass, but besides, at times, so hard that rubbing them with a hard body causes a distinct friction-sound.

The palpebral conjunctiva, on which they rest, then appears of a pale, yellowish-gray color, or reddish gray, only traversed by a few larger vessels, very tough and resisting. Its sensitiveness is markedly decreased, its secretory power almost entirely destroyed. As a consequence of this, such patients suffer very much from dryness of the conjunctiva.

b. In very severe mixed, and particularly in diffuse, trachoma, where the proliferation of tissue is always markedly observed in the whole thickness of the palpebral conjunctiva, the papillary portion not unfrequently entirely disappears in shriveling cicatritial tissue.

These cicatrices are generally seen as tendinous, brilliant, whitish-gray striæ, which run off in the most different directions, and thus sometimes form a coarse, again a fine, net-work, which is woven into the tissue of the conjunctiva itself, traversing this its whole thickness, and being united to the surface of the cartilage. In the meshes of this net-work we still find loose reddish or yellowish-gray tissue. It is not unfrequently elevated from the conjunctival surface in the form of fleshy growths. These striæ occur most frequently in the middle of the palpebral conjunctiva, and then generally attain the greatest size.

In other cases we meet with tendinous and whitish spots with radiate or cloudy borders, which generally indicate a fatty deposit. In consequence of this the tears flow over them, without being taken up at all. They occur alone and also in company with reticulate cicatrices, or lying either very superficially, or seizing upon the deep structures, and are then connected to the cartilage by tendinous branches. In isolated cases we meet with extensive cicatritial spots of this kind, in whose bounds the conjunctival tissue is entirely wanting, being broadly attached to the cartilage by its lower surface, and, as it were, welded to this. Occasionally the entire papillary region is destroyed in this way.

Cases are not wanting in which such cicatritial spots have been irregularly drawn together to hard cartilaginous swellings, with radiate, thick, cord or leaf like branches. These are considerably elevated above the surrounding conjunctiva, and cause irregular folds in the latter. These radiate thick cicatrices scarcely belong to the trachomatous process as such, but are generally due to too strong and deep cauterizations with solid nitrate of silver.

c. Similar changes are observable not only in the purely granular, but also in the mixed and diffuse, forms of trachoma. In consequence of the degeneration of the proliferating tissue, the granules gradually flatten, even disappear entirely, and finally the palpebral fold appears entirely smooth and markedly thicker. When there has been previous excessive proliferation it is also more rigid and very white, occasionally even tendinous, and only traversed by a few vessels forming a coarse net-work, or with no vessels at all. It has ceased to be a mucous membrane, and superficially, at least, has become fibrous.

This change often affects only individual portions of the palpebral fold. These look as if they were covered by irregularly-formed tendinous patches. In other

cases the palpebral fold is entirely changed into a tendinous non-vascular membrane, the extent of whose surface is far less than normal. In less severe forms of the disease, and when the shrunken cicatritial tissue is more irregularly distributed, this lessening of surface is often observed in a folding of the affected conjunctival portion vertically. If the lid is everted, these folds are very distinct, and we see and feel that they are thick tendinous cords and membranous structures, in which the conjunctival tissue is embedded, extending into the sub conjunctival tissue. It renders this latter tense, by reason of its shortness, and thus pushes forward the neighboring conjunctiva. We generally find several of these folds in the same lid, occasionally also single ones in the lateral portions of the palpebral fold. These are particularly prominent on any lateral motion of the globe. These are folds designated as the first degree of the so-called posterior symblepharon. In cases of the severest affection of the conjunctiva the shrinking is apt to be more even. The palpebral fold is entirely changed to a tendinous structure, is shortened, and consequently its base is pressed out more. The tarsal conjunctiva then appears immediately behind the convex tarsal border, upon the corresponding zone of the scleral surface, or springs from the tarsal surface upon the globe, being extended there as scleral conjunctiva. Under such circumstances the characteristic vertical folds are also wanting.

This condition is called a severer form of posterior symblepharon. Still this shortening of the conjunctiva is not always the result of shrinkage. It may also proceed from an adhesion of both surfaces of the palpebral fold. Such adhesions occur especially frequently in consequence of excessive cauterizations, particularly if the superficial epithelial layers are destroyed by the caustic, and thus surfaces of a wound are brought in contact.

d. It is evident that, in such a great shortening of the conjunctival sac, not only the palpebral fold but also the other parts of the conjunctiva must take part in the shrinking process. This is then plainly seen on the ocular conjunctiva, since its most anterior zone, which does not appear markedly shortened, attains a peculiar pale and rigid appearance. In the first place, it becomes less vascular by means of the degeneration of the connective tissue composing it; and, in the second place, it loses its natural elasticity, so that on the motions of the globe it is drawn in fine concentric folds.

e. The appendices of the conjunctiva, the semi-lunar fold and caruncle, under such circumstances, are apt to shrivel and gradually become obliterated, so that we recognize them with difficulty.

2. With the destruction of the corneal tissue, the trachomatous process within the bounds of the conjunctiva has found its natural termination. While this termination is being reached, as is well understood, the appearance of the trachomatous conjunctiva varies exceedingly; in quite a number of cases the subsequent development of the spawn-like bodies is quite marked. These appear singly or in greater number upon the palpebral fold, and occasionally also on the tarsal conjunctiva, again disappearing in part, giving place to others.

In patients with diffuse or mixed trachoma, where the treatment has been left off too soon, this new proliferation of tissue not unfrequently becomes very great, so that the granular trachoma appears much more prominent than before, and thus attains much the upper hand over the granulations on the palpebral conjunctiva. But in cases also in which no treatment has been ever carried on, or when the process has never been altered by remedies which directly and powerfully affected

morbid conjunctiva, proliferation of such bodies is often observed for years after during the existence of a mixed or diffuse trachoma. The tarsal conjunctiva and palpebral folds attain, under such circumstances, in consequence of the continuous liferation of tissue, a peculiar gelatinous appearance, while in some places signs a quite far-advanced degeneration are seen. Indeed, we find these gelatinous generations of the conjunctiva with the peculiar granules, as a rule, combined h granulations which have become pale and hard, and also with maculated or calated cicatrices of the palpebral conjunctiva, with posterior symblepharon, and ilar changes in the cartilage and in the cornea.

It is evident that these granulations belong to the later stages of mixed and diffuse coma. It would be unnecessary to mention this, if they had not been declared to be the pression of a very peculiar process, whose origin is to be sought for in a scrofulous or tuber-lous dyscrasia. (*Arlt.*) In consideration of this latter point, it is only to be remarked that changes in the conjunctiva in question have been observed in robust and healthy persons, that their more frequent occurrence in pale, weak, and in apparently prematurely old, persons, r the greater part dependent on the fact that the eye-affection has existed for years, and also the physical and moral depression caused by this long duration of the disease, as well as the tinuous use of powerful internal remedies.

3. Alterations in the cornea and lids, which often take part in the trachomatous cess, are frequently united to the symptoms of conjunctival shrinkage.

a. We generally find the cornea hazy, in a state of pannus, occasionally xerotic, some cases ectatic.

b. The cartilage of the lid very frequently suffers, entirely apart from its tracho-atous proliferation, from continuous recurring inflammation of the meibomian nds. In the further course of severe trachoma, it shrinks and becomes distorted various ways, or is contracted to a roundish swelling. The meibomian glands e then almost entirely destroyed, but they are in part changed into irregular vities filled with a friable or fluid mass, after their openings have been closed *lalasion.*)

c. The edges of the lids are often swollen, tylotic, affected with trichiasis or rtial madarosis.

d. Not unfrequently permanent turning in or out of the lids occurs, entropion d ectropion. The entropion is generally a consequence of tendinous degenera-ion of the conjunctiva. The palpebral fold and the tarsal conjunctiva being ortened by the continued destruction of the tissue, the surface of the lid, the inner lip being obliterated, is turned in toward the globe, and often even distended, so at some lashes protrude from the row, and appear to grow from the surface away m the outer lips of the lid. The further formation of the entropion is assisted by the spasm of the lids. This appears in the inflammatory stage and during the cerbation of the process, at times with great severity, and, when the lashes have ready been turned, it assists somewhat in maintaining them in this position. The adual thickening and shrinkage of the tissue of the cartilage is then the cause of is distortion becoming permanent. Still the shrinkage of the cartilage is sufficient f itself to cause such an entropion.

In severe mixed and particularly in diffuse trachoma, which is accompanied in e first stages by considerable swelling of the lids and conjunctiva, ptosis of the pper and ectropion of the lower lid often occur. Occasionally both lids are turned tward. The eversion of the lachrymal punctum favors the ectropion and the

deficient carrying-off of the tears. This is evident, even in slight elevations of the edges of the lids, by continuous dropping of the tears. It leads to erythematous inflammations and excoriations of the lids and cheeks, and subsequently to their shrinkage; and thus the improper position of the lid is increased, and at the same time the inflammation in the conjunctiva and cartilage maintained, and further degeneration favored.

Treatment.—We should first very assiduously attempt to remove the cause of the disease, but afterward the treatment is to be so conducted, that the proliferation of tissue shall be limited, and the already existing trachomatous new-formations removed without injury to the normal elements of the conjunctiva.

A. Among isolated collections of persons, e. g. among soldiers, in asylums, prisons, manufactories, &c., we must see, above all things, to the prevention of the disease. For this purpose all the causes of the trachoma should be carefully considered, and the proper hygienic rules be insisted upon. But if the disease has already broken out, the prevention of contagion should oppose a barrier to its extension. Separation of the affected from the healthy, and, when this is not possible, limitation of their intercourse with each other, form the chief object of attention from the medical attendant.

In individual cases the indications from the cause will demand the removal or keeping away of all injurious influences which may possibly increase or maintain the process, and therefore the eyes should be carefully protected. Besides, where one eye is affected, the transference of the secretion to the healthy one should be prevented where it is possible. For this purpose it is necessary, so long as the process remains acute and runs its course with the secretion of muco-purulent material, to protect the eye with a hermetical, or at least a protective, bandage. But if the trachoma has already become chronic, it need not be worn, in consideration of the slight contagious property of the secretion, and the annoyance of a bandage. We may then avoid contagion by the greatest care in washing the face, use of the hands, &c. Careful patients may very often prevent the affection of the other eye.

B. The direct treatment of trachoma varies exceedingly, according to the manner in which the disease is developed, according to the intensity of the tissue proliferation process, the form and extent of the trachomatous neoplastic formations, &c.

1. If the trachoma appears with the symptoms of a blennorrhœa, attention is to be directed to it rather in a prognostic than therapeutical way. Trachoma first influences the indications to any extent, when the dangerous condition of things has been removed, and the trachoma, as such, appears in the foreground.

2. If the form of the disease has changed in this way, or if the trachoma has been primarily developed, the severity of the inflammation at the time will determine the choice of methods of treatment. Wherever the sthenic character of the disease appears prominent, or a condition of severe irritation, the antiphlogistic treatment is the only proper method, whether it be in the beginning of the disease, or during an exacerbation. Every irritating procedure is to be strictly avoided. The means for this are strict care of the eyes, a general antiphlogistic regimen, the use of cold applications, instillations of a solution of atropine, &c.

3. If the relaxation of the conjunctiva is already observed, and there is no

marked injection of the vessels in the episcleral tissue, it is time to attempt the removal of the trachomatous neoplastic formations by direct treatment.

We can not conceal the fact that it is harder, in practice, to learn this point of time than in theory. There are cases in which all the above indications seem to be fulfilled, and yet direct treatment of the trachoma will not be borne, but excites exceedingly severe and even dangerous exacerbations of the inflammatory process, which make an immediate return to an antiphlogistic treatment necessary.

On the other hand, cases occur in which the inflammatory proliferation of tissue, in spite of all antiphlogistic treatment, continues, with all the symptoms of severe nervous irritation, for weeks. From a theoretic stand-point, every irritative means of treatment appears to be contra-indicated, and yet this is what it actually requires. Happily, such cases are comparatively rare, and we may easily protect ourselves from mistakes by first experimentally employing the weaker modes of direct treatment, if the condition of severe irritation be too protracted.

The scissors, nitrate of silver, and sulphate of copper, are the direct means of treatment of trachomatous neoplastic formations.

Sugar-of-lead was at one time used, and much was said of its efficacy. It was used both in concentrated solutions and in the form of a powder. (*Buys, Warlomont.*) Both preparations were placed in large quantity on the trachomatous conjunctiva, and after they had acted for a time, the excess was removed with lukewarm water. Thus a slough was formed which covered the whole penciled conjunctival surface, and enveloped the granulations. This slough was very adherent, and it was often several days before it was loosened. In the mean time it acted as a foreign body, and as such was very troublesome. It even increased the existing irritation and the proliferation of tissue, so that it was not rare to see the granulations grow instead of decrease under the slough. This occurs the more readily because the slough remaining behind prevents, or at least weakens, the effect of the lead on the neoplasia. In a similar way, tannin, tincture of opium, dilute nitric acid, &c., have been tried, but the results attained are far inferior to those from nitrate of silver or the sulphate of copper (*Cyr*).

The choice of the remedy is generally determined by the form, size, and consistency of the trachomatous new-formations.

a. Cock's-comb or cauliflower granulations, or those which are very prominent and comparatively large and pedunculated, should be cut off with the scissors. It is imperatively necessary, in doing this, to avoid any injury to the proper conjunctival tissue; otherwise cicatrices are formed which do harm. This is the reason that, in granulations with a comparatively broad base and slight elevation, the scissors are not to be recommended. Besides the granulations are not easily brought within the blades of the scissors, without at the same time getting the conjunctiva between them.

The patient is placed on a chair during the operation. An assistant, standing behind him, supports the head and the everted lids, while another restrains the hemorrhage. The granulations are cut off with scissors curved on the flat. One granulation should be cut off after the other, close to the base. The operation therefore demands much time and patience, but is not painful, provided the scissors do not cut the conjunctiva. It should be remarked, that it would cause great trouble to attempt to cut down the granulations smoothly to the conjunctiva. We should be contented with cutting off the more prominent granulations down to a slight residuum. Cauterizations with nitrate of silver should do the rest. Yet these should not be undertaken before one or two days after. Cold applications are to be made immediately after the operation, in order to restrain the hemorrhage and limit the reaction.

b. Large, very prominent, but diffuse granulations, with broad bases, are best subdued by the use of the mitigated nitrate of silver.

c. In severe mixed trachoma, as well as in the diffuse form, where the granulations were either slightly developed in the beginning, or cut off by the scissors or the mitigated stick, so that their breadth was greater than hight, pencilings of the roughened conjunctival portion with strong solutions of nitrate of silver, fifteen to thirty grains to the ounce of distilled water, are to be particularly recommended.

d. In such cases, if the smoothing out of the granulations is already far advanced, or if we are dealing with a low form of mixed trachoma, a pure papillary or granular trachoma, pencilings with a weaker solution, five to ten grains to the ounce of water, are to be advised. Then we wish the formation of very thin sloughs, because the deeper action of stronger caustics may easily endanger the proliferating conjunctiva itself, and cause the formation of cicatrices. The choice of the strength of the solution depends upon the desired effect. The caustic will be the weaker, the smaller are the neoplastic formations.

e. It not unfrequently occurs, that in some parts of the conjunctiva, especially in the vicinity of the convex tarsal border, permanent granulations of considerable size remain, while in other places the trachomatous roughness rapidly yields to the means in question. In such cases the prominent excrescences should be removed with the mitigated nitrate of silver (nitrate of silver and nitrate of potash), but the other parts of the conjunctiva penciled with the proper solution.

f. If, after the smoothing-off of the trachoma, the conjunctiva remains very much relaxed, if the catarrhal secretion appears quite abundant, and we therefore require rather a strong astringent effect than a powerful cauterization, the best means is the use of a crystal of sulphate of copper, or an ointment of five grains sulphate copper to two drams of simple cerate.

g. In secondary gelatinous trachoma, also, the sulphate of copper is to be recommended, so long as papillary or diffuse granulations of large caliber do not demand a strong caustic action.

The broad surface of the crystal has the advantage, that the greatest chemical action affects the most prominent points, and in this way remains of granulations may be cauterized, while the portions of conjunctiva lying between experience the astringent action. Sulphate of copper, with vigorous use, is indeed a caustic, and was for a long time almost exclusively used in the treatment of trachoma. It is only recently that it was displaced as a peculiar caustic by solutions of nitrate of silver, and properly so, since these latter act much more powerfully and more certainly.

The sulphate of copper ointment furnishes a very advantageous substitute for the crystal, especially when the patient can not visit the surgeon every day. The patient may easily introduce the ointment into the conjunctival sac by means of a camel's-hair brush, or allow it to be done by others.

We may also use the sulphate of copper in solution, ʒ j ad ℥ j aq. destillat., penciling it on the conjunctiva in the same way as the stronger solutions of nitrate of silver. Still, it is much inferior to the latter where we desire a powerful effect.

The object of the cauterization is to bring the conjunctiva back to a normal condition. Remembering this, we can not be sufficiently warned of the danger of deep cauterizations, especially with nitrate of silver in substance, for this always leads to the formation of extensive cicatrices. It may be considered as a rule, without exception, that at each cauterization, even in cases of very severe trachoma, we should confine ourselves to the production of a very superficial slough. A second rule requires that the caustic should not touch parts where there are no trachomatous formations.

Instillations are, therefore, to be utterly abandoned. Weak collyria do no good in a trachoma, and stronger ones act upon the ocular conjunctiva and the cornea, as well as on the trachomatous granulations. They are, therefore, dangerous in proportion to their curative action on trachoma.

Generally, we should use the caustic once a day. A more frequent repetition is not advisable. The best time for the application is the morning, two or three hours after awaking from sleep. Immediately after sleep, the conjunctiva appears hyperæmic, and the caustic irritates much more. For the same reason, cauterization immediately after a meal should be avoided. Just before a meal is also not a proper time, since the irritation caused may be easily increased by mastication, and by a full stomach.

We should not think, however, that the cauterization is to be carried on every day until the trachoma has disappeared. We should never neglect the exact examination of the conjunctiva and the neighboring parts, before we proceed to the application of the caustic. It very often occurs, that some injurious influence has temporarily increased the irritation of the eyes. This may be recognized more especially by a greater injection of the fine episcleral vessels, by sensitiveness, profuse lachrymation, and a lighter shade of the redness. If this be the case, the cauterization should be omitted, and a pure antiphlogistic treatment substituted, until these symptoms of irritation have again disappeared. If this precaution be neglected, and the cauterization continued in spite of the warning indications, the result is generally a considerable increase of the inflammation. Herpetic efflorescences then very often shoot up on the conjunctiva or cornea, which not unfrequently endanger the eye. At any rate, the patient will not tolerate the continuation of the caustic, and we are finally compelled to give up its use for weeks at a time. Then the conjunctiva has an opportunity to allow the formation of the trachomatous growths to reach the former or a greater size.

If trachoma has once become chronic, and if the irritation which is apt to accompany the first stages has yielded, we should have no object in confining the patient to his room any longer. The enjoyment of the fresh air is necessary under such circumstances. Still, the patient should be warned as to any excesses. He should take proper care of the eyes, and avoid all causes that may produce congestions of the upper half of the body.

4. Cases exceptionally occur, particularly of ancient trachoma, which offer a remarkable resistance to the means of treatment which have been named, and in which, after energetic cauterization for weeks, no change in the condition is to be observed. A marked advance in the degeneration of the conjunctival tissue has then occurred. We also here and there meet with cases of chronic and even inveterate trachoma, in which cauterizations are not borne at all. They react on every application with very severe and permanent irritation, if not by herpetic affections or other forms of keratitis. In such cases, whether with or without pannus, we may use lukewarm compresses or cataplasms. (*Graefe.*) Occasionally these are useful in relaxing the tissue, and thereby favoring resolution, besides markedly diminishing the sensitiveness. In some cases, even a spontaneous recession of the granulations has been seen. In other cases, cauterizations begun with care, and increased, are again borne, and become useful. Aqua chlori is also highly spoken of under such circumstances. (*Graefe.*) In particularly old and obstinate affections of this kind, if accompanied by pannus, we may try the inoculation of blennorrhœal secretion, and we may perhaps attain good results with it. (*Piringer, Bader.*)

5. It is time to stop the cauterizations, when the trachoma has been so far subdued that it requires oblique illumination from a lamp to show any irregularities in the conjunctiva, and if the redness remaining has a tint of yellow in it, and the swelling has lessened.

It will be best, perhaps, to gradually increase the intervals between the cauterizations, cauterizing every two days at first, and then every three or four days.

The object of these experimental cessations of cauterizations is to ascertain if the proliferation of tissue in the conjunctiva still continues, and if the slight remaining unevenness of the conjunctival surface be not merely a symptom of a hyperæmic swelling of the papillary bodies, kept up by the cauterization itself, and which immediately disappears when this influence ceases to act. It not unfrequently occurs, that inexperienced practitioners protract such slight hyperæmic swellings excessively by continuous cauterization. But, even after complete disappearance of the roughness of the conjunctiva, the patient is not to be considered as safe. In order to prevent a return of the affection, the eyes should be carefully used for a long time.

6. If, in ancient trachoma, hypertrophied conjunctival folds of some breadth are found in the palpebral fold, these should be cut off with the scissors close to their base, since they do not readily yield to cauterization, as experience teaches us, and they may with good reason be esteemed the cause of the persistence of a great irritation. In the early stages of trachoma, such large folds do not easily occur, and they are of less significance, because they are apt to disappear with the recession of the trachoma, as we may see in the semilunar fold. Under such circumstances, their removal by the scissors would not be justified.

7. If corneal pannus is combined with conjunctival trachoma, the method of treatment is to be the same as if there were no pannus. This generally disappears under treatment, or becomes a permanent corneal opacity, before the roughness of the conjunctiva is subdued. But if the trachoma is united with a pannous keratitis, or herpetic keratitis, it is generally advisable to limit ourselves to antiphlogistic treatments as long as the inflammatory symptoms, and especially the nervous symptoms, predominate to any great degree. It is only when this method of treatment remains without result, in spite of a very good condition of the patient, that we may undertake experimental cauterizations of the conjunctiva with weak solutions. Occasionally under their use the inflammation recedes very quickly. Not unfrequently, however, it increases very markedly, and may even put the eye in great danger. Occasionally the ointment of the yellow oxide of mercury does good service under such circumstances, especially when the herpetic character is a little more prominent and the severest symptoms of irritation have yielded.

In doubtful cases of this kind an elliptical piece has been cut out from the lid, and it is claimed that good results have been attained by this treatment. It is believed that the pressure of the lid is thus diminished, and the nutrition of the conjunctiva and cornea favorably acted upon. (*Graefe.*)

8. If either lid be everted, its replacement should be immediately attempted. In the first stages of acute trachoma this will often be sufficient. But if the lid again becomes everted, in consequence of the distention of the cartilage, so long as the inflammatory swelling is very great, it is better, when rigid antiphlogistic treatment is necessary, to leave it for the time in its abnormal position. If then the swelling gradually decreases, and relaxation takes place, the ectropion may be readily acted upon. If the eversion be only partial, the cauterization of the conjunctiva is generally sufficient, together with the contraction thus caused, to relieve the trouble. But

if the eversion be complete, the lids should be replaced and kept in their proper position by an appropriate bandage. As long as the bandage is used, cauterizations with nitrate of silver are not to be recommended, because the throwing off of the thick eschar is rendered very difficult, and irritation favored. Sulphate of copper is to be preferred until the lids will remain in their normal position without a bandage, when cauterizations with nitrate of silver may be undertaken. It is less useful to use the nitrate of silver from the beginning, and then to apply the bandage after each throwing off of the eschar.

Slitting up the lower canaliculus is superfluous, under such circumstances, since the ectropion may be almost always perfectly overcome.

Authorities.—*Ebl*, Ueber den Bau und die Krankheiten der Bindehaut. Wien. 1828. S. 97, 147, et seq.—Die sog. contag. oder egypt. Augenentzündung. Stuttgart. 1839. S. 1, 80, et seq.—*Piringer*, Die Blennorrhœ am Menschenauge. Graz. 1841. S. 35, 46, et seq.—*Ammon*, Zeitschrift A. f. O. III. S. 235.—*Cunier*, Ann. d'oc. XX. S. 152.—*Gule*, Die sog. egypt. Augenentzündung. Wien. 1850. S. 18, 41, et seq.—*Arlt*, Die Krankheiten des Auges. I. Prag. 1851. S. 18, 23, 39, et seq.—*Stellwag*, Zeitschrift der Wiener Aerzte. 1851. II. S. 903, et seq. Ophth. II. S. 801–846.—*Mackenzie*, Traité prat. d. mal. d. yeux. traduit p. Warlomont et Testelin. I. Paris. 1856. P. 664, et seq.—*Buys* und *Warlomont*, ibid. S. 748.—*Warlomont*, kl. Monatbl. 1863. S. 491.—*Seitz*, Handbuch der ges. Augenheilkunde. I. Erlangen. 1855. S. 45, 46, et seq.—Congress d'ophth. de Bruxelles. Compte rendu. Paris. 1858. S. 198–354.—Congress intern. d'ophth. de Paris. Compte rendu. Paris. 1863. S. 48, 81, 115, et seq.—*Quadri*, De la granulation palp. Naples. 1863. S. 12, 16. 22, 26.—*Graefe*, A. f. O. VI. S. 123, et seq. X. 2. S. 191 et seq.—*Secondi*, Clinica di Genova, Riassunto. Torino. 1865. S. 5.—*Bader*, Ophth. hosp. Rep. IV. 1.—*Snellen*, kl. Monatbl. 1866. S. 170.—*Schwalbe*, ibid. S. 276.—*Blumberg*. A. f. O. XV. 1. S. 156, 158.—*Mannhardt*, ibid. XIV. 2. S. 31, 34.—*Stavenhagen*, kl. Beob. S. 45, 48.—*Arcoleo*, Conferenze clin. S. 5.—*Cyr*, Centralbl. 1866. S. 542.

7. Herpes of the Conjunctiva—Phlyctenular Conjunctivitis.

Symptoms.—*This disease is characterized by circumscribed and roundish inflammatory points, ranging in size between a poppy and hemp seed, which are developed in the conjunctiva, with evidences of greater or less ciliary irritation and conjunctival hyperæmia.*

The original form of these inflammatory points is a roundish exudation nodule. At the summit of the nodule, as a rule, exudation of a serous fluid very soon occurs. This lifts up the epithelium, and thus causes a pellucid vesicle, which again changes to a so-called lymph or pus vesicle, by alterations in its contents. It generally ruptures very soon, and then it is seen as a roundish, sharply-defined excoriation, surrounded by shreds of epithelium. It is soon covered by an opaque, grayish, or fatty-looking coating, and heals over, or it is changed to a superficial, roundish, sharply-defined little ulcer, which either heals up or becomes a penetrating ulcer, by a gradual deliquescence of the original substance forming the nodule.

These efflorescences are most frequently seen on the limbus conjunctivalis. They are there found singly, or scattered in greater number, or thickly collected together in portions of the corneal periphery, or even on the entire edge of the cornea, surrounding it like a border. They also occur frequently in the anterior zone of the ocular conjunctiva, especially on the portion in the palpebral fissure, where they are also sometimes found singly, and again in irregular groups. It is only exceptionally that they occur in the palpebral fold, on the tarsal conjunctiva, and on the surface of the edge of the lid.

But it is quite common to find such efflorescences on the cornea and the conjunctiva at the same time. Generally they appear in the different stages of development, because they are of different age. Efflorescences which have healed, and those which are recent, nodules, vesicles, and ulcers, often stand near each other.

Herpes of the conjunctiva is always developed where hyperæmia has previously existed. Where the process is limited to the development of a single group of efflorescences or vesicles, the hyperæmia very often appears sharply bounded. The efflorescences are, at the point, of fan-like arrangement of injected conjunctival and corneal vessels. The long axis of this is always in a meridional direction, and its broad end is directed toward the palpebral fold. More frequently, however, and in the existence of a number of efflorescences scattered or grouped together, the conjunctiva and episcleral tissue are densely injected throughout their entire extent, the former being even completely and evenly reddened. A serous infiltration is generally recognized in the hyperæmic portions of the conjunctiva. Occasionally they also appear markedly swelled. The secretion is watery, as long as the nervous irritation is more prominent; subsequently, catarrhal products are mingled with the increased lachrymal secretion.

The burning or stinging pain is particularly to be mentioned among the subject-

ive symptoms. It precedes the hyperæmia and the efflorescence, and forms in general the first striking symptom of the process. After the outbreak of the characteristic inflammatory points, it disappears to a great extent, or passes into the sensations peculiar to catarrhal conjunctivitis, i. e. sensations of pressure, itching, biting, and the like. If it continues, it is because still further efflorescences arise. It is only rarely that the pain is severe; where there is severe pain, especially in combination with severe photophobia, we have good reason to believe that we are dealing with a corneal herpes.

The Causes are the same as those which may produce herpes of the cornea. Like this, conjunctival herpes is sometimes primarily developed, sometimes it appears in the form of a catarrhal inflammation, blennorrhœa, trachoma, &c., especially when it is treated in a too irritating manner, or when the eye is exposed to the action of other sources of irritation.

It should be particularly noted that, on the development of an herpes zoster in the region of the frontal or the infraorbital nerve, single vesicles or groups of efflorescences shoot up on the conjunctiva and cornea.

Course and Results.—The herpetic disease generally has a typical course, and usually passes through its cycle within eight days. Such a course is taken as a rule, particularly in cases in which, in the absence of a very decided predisposition to the affection, an accidental and temporary injurious influence has been the cause. A burning or stinging pain opens the scene. The characteristic vascular injection occurs within a few hours, and, on the second or third day, we may distinguish the peculiar efflorescences, which rapidly pass through the above-described metamorphosis, and are generally well, in the time indicated. In the mean time the swelling, and also the hyperæmia, recede somewhat, but then the symptoms of relaxation become evident, and very frequently a greater amount of catarrhal secretion occurs. The disease advances, as it were, to recovery through a catarrhal inflammation.

The typical aspect of the course is sometimes obliterated by the fact that fresh outbreaks occur from time to time. It also not unfrequently occurs that the excoriated base of a former vesicle becomes afterward infiltrated to a greater extent, and becomes a superficial or even penetrating ulcer, by deliquescence of the inflammatory product. This extends further and further, and, when it is situated on the limbus conjunctivalis, is continued upon the cornea, and may here cause very unpleasant results.

Pannus herpeticus is a very peculiar result, which is also described by the names ophthalmia varicosa, tuberculosis conjunctivæ, sclerotitis, &c. It is preceded by an eruption of herpetic efflorescences, existing for a long time on some portion of the ocular conjunctiva. It therefore almost exclusively occurs in persons who are very particularly inclined to herpetic efflorescences, or who can not be withdrawn from harmful influences which continually act upon the eyes.

The nature of pannus herpeticus is a collection of thickly-arranged herpetic efflorescences of varying age, which lie in a hypertrophied and vascular tissue, exactly as seed or fruit in its covering (the pericarpium).

The affected portion of the conjunctiva, in consequence of the proliferation of tissue and of the great hyperæmia, appears greatly swelled, often elevated a line above the base of the other conjunctiva, and forms a large and generally evenly-red,

kidney-shaped swelling, the hilus of which surrounds the cornea in a large or smaller arc, while its convex, irregular, serrated border is drawn out posteriorly, and is lost in several bundles of thick, greatly-distended vessels, which pass on in a meridional direction to the palpebral fold, where they extend into the depth of the orbit. In this swelling are found a great number of herpetic efflorescences, close together, and mingled with secondary ulcers, as well as with cicatritial elements. Some of these are recent, some are advanced in suppuration, partially calcified, or degenerated to tendinous tissue, and lying in the true conjunctiva, the episcleral tissue, and also in the superficial layers of the sclerotica.

Similar nodules exist upon and in the neighboring portions of the cornea, united to each other by a pannous or cicatrital opacity, which, at the corneal border, pass over into the hilus of the conjunctival, swelling with no marked boundary.

Herpetic pannus often remains in this form for years. The nodules generally degenerate, as well as the proliferating conjunctiva and corneal tissue. The former appears pale, dense, and dry on the affected portion, and on every motion of the globe is thrown into delicate folds, which are tendinously opaque. The nodules appear as small gravelly or cicatritial deposits.

Treatment.—This has the same objects to accomplish as in corneal herpes. Wherever that disease appears in combination with the conjunctival herpes, the treatment is the same. If the conjunctiva is alone the seat of the efflorescence, in mild cases a proper care of the eyes is sufficient to bring the process quickly to a conclusion. But if the symptoms of irritation are more prominent, the use of atropine instillations is also to be advised, and subsequently, especially in repeated relapses, dusting-in of calomel, or the use of the ointment of the yellow oxide of mercury. In a recently catarrhal relaxation of the conjunctival tissue and an abundant muco-purulent secretion, it is well to pencil the conjunctiva a few times with a weak solution of nitrate of silver, as is done in catarrhal conjunctivitis. In herpetic pannus the use of the yellow oxide of mercury ointment in the conjunctival sac, or penciling the swollen conjunctival portion with the tincture of opium, together with great care of the eyes, has generally a good effect.

In pure herpetic pannus, wearing a protective bandage is also to be recommended. If the pannus be united with conjunctival trachoma, which is frequently the case, we should do best to limit ourselves at first to a cauterization of the conjunctiva with solutions of nitrate of silver, the pannus often yielding under their use.

[We need to pay particular attention to the general condition, the diet, and mode of life, in patients affected with this disease. We should see that they get plenty of fresh air, and that they are under hygienic influences in general.]

Consequences of Conjunctivitis.

1. Pterygium.

Pathology and Symptoms.—We distinguish between true and false pterygium. Both of these forms are composed of a corneal and conjunctival portion, whose long axis is always meridional. The corneal portion is generally a thick, rigid, tendinous, more rarely a loosely-woven, vascular connective-tissue neoplastic formation. This, at times, is entirely superficial, and lies upon the outermost layer of the corneal substance, but as a rule has a deeper hold in the cornea, and fills up a loss of substance which has an uneven base. This neoplasia often includes single fibrous or calcareous herpetic nodules. Its borders are frequently indistinct from epithelial opacity of the surrounding cornea.

The conjunctival portion of the pterygium is really a hypertrophied portion of the ocular conjunctiva and the submucous tissue belonging to it. It consists mostly or exclusively of bundles of tortuous connective-tissue fibers, having chiefly a meridional direction, and is traversed by a varying number of vessels, which are in part newly formed. Woven into the loose tissue of the pterygium, isolated cords or ligamental ribbon-like striæ of rigid tendinous tissue are not unfrequently formed, which generally proceed from the thicker corneal portion, and traverse the conjunctiva in a direction nearly parallel to its axis, these again disappearing without a trace of their existence, or forming a union with the sclera, the semilunar fold, &c.

The pterygium is generally very loosely attached to the portion of sclera lying beneath, and may be often raised up with forceps from the apex to the base like a fold. Still, a certain tension may always be recognized in the direction of its axis. When the deposition of new or tendinous formations is large, this may impair the mobility of the eye, and, on lateral movements, lead to double vision. (*Hasner.*)

Pterygium is described as *pterygium tenue* or *crassum*, according to the greater or less quantity of neoplastic elements. Slighter amounts of thickening, with a scantier vascular development, which do not impair the transparency of the affected conjunctival portions, we call pterygium tenue or membranaceum. In pterygium crassum, in which we still distinguish two degrees, pterygium vasculosum and carnosum, or sarcomatosum, the increase in thickness of the hypertrophied conjunctival portion and of the episcleral tissue lying beneath is so great that it is decidedly raised above the level of the adjacent healthy conjunctiva, and gives to the finger the sensation of a muscle slightly on the stretch. Moreover, the vascular development is so great that the pterygium often appears of an even red color.

The shape of a pterygium is in general that of an isosceles triangle. Its base is always directed toward the palpebral fold, and is lost either in the ocular conjunctiva or reaches in to the reflection. The apex of the pterygium generally rests on the margin of the cornea, often going on toward the center, but rarely passing beyond this.

Particularly in true pterygium (Fig. 56) and in the various transition-forms, the

triangular form is very decided, its corneal portion running to a point, which may, however, be rounded off, toward which the sides of the neoplasia converge in their entire length.

In false pterygium (Fig. 55) and in the various intermediate forms, the triangle is somewhat irregular, occasionally quite indistinct, and only marked in the conjunctival portion. Its corneal portion is generally formed of a roundish or irregular tendinous spot, whose sides are merged in those of the conjunctival part. Occasionally it seems as if the conjunctival portion had sprung from the middle of such a tendinous corneal spot. Then a bundle of loose vascular conjunctival tissue appears from the center of a tendinous corneal opacity, surrounding the corneal margin, and either unites with the hypertrophied connective tissue entirely, or in its middle portion or that of the axis. The edges roll up, and thus form a fold lying on the conjunctiva, under which the probe may pass to a greater or less extent.

In false pterygium it often occurs that single tendinous strings or bundles of loose connective tissue are continued upon the tarsal portion of the conjunctiva, upon the semilunar fold, caruncle, or even the free border of the lid, and, on certain movements of the eye-ball, may become tense.

The most common position of a pterygium is the palpebral portion of the inner quadrant of the ocular conjunctiva. It is only very exceptionally that we find two, three, or four pterygiums on one eye. These almost always are in the direction of the recti muscles. This seems to depend on the origin of many conjunctival vessels from muscular branches (*Mannhardt.*)

Causes.—True pterygium is generally the result of a fan-shaped inflammatory collection in corneal herpes, which has become hypertrophied and shrunken. Apart from direct observations of the passage of a corneal herpes into a true pterygium, the anatomical shape of the latter is an argument for this view, and the fact that, in the greater number of cases, remains of the peculiar herpetic efflorescences may be seen on the apex of the corneal portion. Corresponding to the frequency of secondary herpetic ulcers, or entire groups of herpetic efflorescences in the cornea, we often find the corneal portion of a true pterygium extended like a tendinous opacity, or is surrounded by an epithelial one, which is interspersed with tendinous and calcareous nodules.

False pterygium, to which the last-named varieties are, as it were, the passage-way, is developed from peripheral corneal ulcers, which are grown over with granulations from the limbus conjunctivalis, while the adjacent portions of the conjunctiva also proliferate and hypertrophy. The granulations covering the corneal loss of substance, and the hypertrophied conjunctival portion, subsequently shrink, the corresponding portion of the conjunctiva is rendered tense in the direction of its meridian, and is even raised up in folds above the normal level. (*Arlt, Hasner.*) It is evident that herpetic ulcers, as well as ulcers of any sort, in case they are peripheral and permanent, may cause a pseudo-pterygium. We even see such pterygiums developing from chemical or traumatic losses of substance in the cornea. Thus it is that false pterygium occasionally occurs in combination with symblepharon, or assumes forms which make it difficult to say whether it is with this or that condition we have to deal.

Very recently a great importance has been ascribed to the peculiar relaxation of the union between the limbus of the cornea and the structure beneath. Quite a disposing cause is there found for the development of a pterygium. In old persons

this condition is said to be frequently seen, and the fact that pterygium generally appears in more advanced life is said to be connected with this. A simple proliferation of tissue on the limbus is sufficient to render possible a contraction of the conjunctiva by shrinkage. Ulcerative formations are by no means as frequent a cause of the formation of pterygium as was formerly assumed. (*Hasner.*)

From experiments on animals, the view has been also enunciated, with the acceptation of a more immediate connection between the choroidal and corneal ve sels, that pterygium, occurring spontaneously in the human eye, very probably depends on venous thrombosis, coagulations, obliterations or narrowing of a corneal vein, ultimately of a vena vorticosa, and that it is thus developed from the disturbances of circulation in the corneal portion of the ciliary arteries penetrating the recti muscles. (*Winther.*)

In blennorrhœa, which is accompanied by chemosis of the conjunctiva, and causes extensive corneal ulcers, it occasionally occurs that the overhanging tumor of the conjunctiva unites with the floor of the ulcer. After the inflammation has subsided, and the swelling lessened, we find tendinous bridges, which reach from the corneal cicatrix into the ocular conjunctiva, and look exactly like false pterygia. Yet we may pass a probe under them, for their bodies only lie on the corneal margin, without being united to it.

But pterygium by no means comes fully developed from these processes. They form, as it were, the foundation. After the inflammation has run its course, this is made evident merely by some thickening and hyperæmia of the affected portion of the conjunctiva. Such undeveloped pterygia often recede, or only a few very short tendinous threads remain behind, which diverge from the corneal portion into the periphery of the conjunctiva. It is only exceptionally that the pterygium comes to a complete development, and for this several months or years are required.

It occurs most readily in cases in which either constantly, or very frequently, injurious influences are acting upon the eye. Hence we meet it, in a markedly large percentage of cases, in persons who remain much in an atmosphere containing dust-particles, or who are exposed to ammoniacal or other acrid vapors, in stone-cutters, masons, &c. It is said to be more common in Egypt, India, Maderia, Spain, and Italy, than in the northern parts of Europe.

Results.—Pterygium, once developed and formed to a certain degree, is permanent, and its disappearance is one of the greatest rarities. It may in part undergo fatty degeneration. A transition into morbid after-growths is certainly only accidental, and is not founded in the anatomical nature of pterygium.

Treatment.—This should first aim to prevent the development of pterygium. Appropriate treatment of the original disease, the proliferation of tissue, is therefore the first and most important object to be gained. As long as the tissue proliferation advances with symptoms of severe irritation, antiphlogistic treatment is indicated. Subsequently the use of astringents is more to be recommended. In the latter respect, penciling the parts with tincture of opium accomplishes the most, especially when they are very much relaxed, when they are of a spongy appearance, or when we wish to act upon an ulcerative loss of substance of the cornea or conjunctiva, and thus limit the future shrinkage. In a fully-formed pterygium, whose tissue has already developed to perfect connective tissue, or is even shrunken in part to rigid, thick, or tendinous masses, these means will have no more effect, unless the corneal portion be surrounded by an epithelial opacity, for this is markedly cleared up

Fig 57.

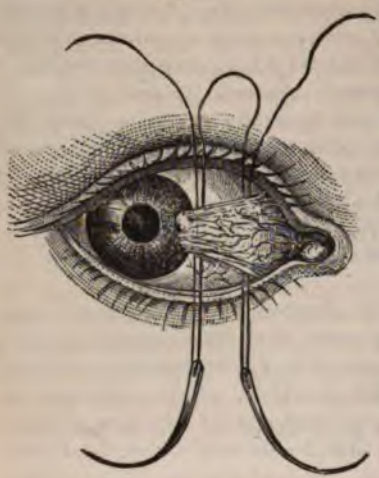

under their use, and at the same time lessened in size, which is of great importance to the functions of the eye.

The removal of such pterygia is only to be attained by an operation. The best methods are ligation and excision.

a. Ligation. (*Szokalski.*) For this purpose, each end of a silk thread is passed through a delicate, curved needle. The lids being wide open, the pterygium is then seized with the forceps, and lifted up from the sclera. Then one needle is so thrust in at the base of the pterygium, the other at the margin of the cornea, that they enter at the upper border, hugging the scleral surface, and are then emerged at the lower border of the pterygium. (Fig. 57.) The double thread now forms a noose above; by dividing one thread of this noose or loop, and cutting off the two needles, the thread falls into three parts, an outer, middle, and inner. The inner thread is first tied, then the outer, and lastly the two ends of the middle ones. In four days the ligated pterygium is seized by the forceps and removed. The cicatrization follows in a short time.

b. Excision. (*Arlt.*) The best method is probably the following: While an assistant holds open the lids, the operator seizes the pterygium near the scleral border with a pair of reliable forceps, draws it away from the globe, and separates the corneal portion from the apex with a pair of scissors curved on the flat (Fig. 58), or, what is to be preferred, enters a pointed bistoury or cataract-knife flat on the sclera, between this and the neck of the pterygium, its cutting-edge being directed toward the cornea, and cuts with a gentle course of the knife the corneal portion extending above the level of the sclerotica as evenly as possible from its substratum.

Fig. 58.

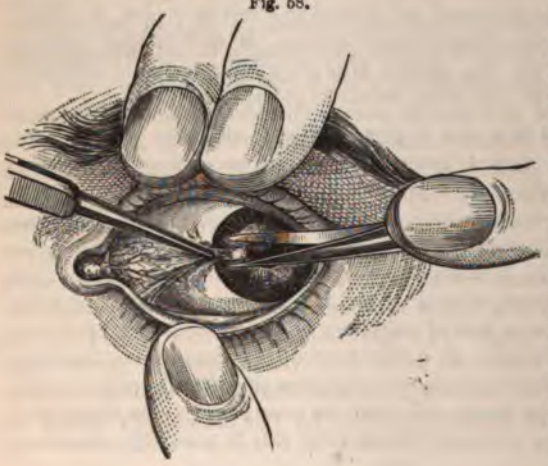

Then the separated portion of the pterygium is drawn up, and the conjunctiva dissected up with the scissors toward the palpebral fold, one to two lines distant from the corneal margin, keeping exactly to the edges of the pterygium, and close to the surface of the sclerotica. The two angles of the wound are then united by two converging incisions, which meet in front of the reflection, and thus enucleate the circumscribed pterygium. The wound is now nearly of a rhom-

boidal shape. It is not necessary, but rather harmful, to extend the incision into the reflection; still, we should as far as possible include all hypertrophying tissue. In large pterygiums, the wound will then naturally be also very extensive, and it is in such cases necessary to unite the gaping edges by some extremely fine suture, after having dissected the affected portion of the ocular conjunctiva to a sufficient extent from its base, in order to enable the edges of the wound to be drawn together without too great stretching. Besides, in order to attain the desired result, we do not need to remove completely the rhomboidal portion, or the entire pterygium. It is sufficient to simply throw back the new growth which has been dissected up, and then to close the triangular wound by a suture. The pterygium soon shrinks away, and in a short time is unnoticed. (*Pagenstecher.*)

After the operation, rest of the eye is to be secured by the application of a binocular protective bandage, in order that union of the edges be not interfered with. This bandage should be worn, according to necessity, from three to four days, when the sutures are to be removed. In the meantime a proper antiphlogistic regimen is to be carried on. If, with the secretion of pus, granulations subsequently form, pencilings of the parts with tincture of opium, having first cut off the prominent fleshy growth, is the best treatment.

A perfect cure of pterygium is by no means a frequent occurrence. If the union of the edges of the wound takes place by first intention, the neoplastic material not unfrequently thickens to a rigid tendinous string, which subsequently contracts more and more. In other cases suppuration occurs, or granulations are developed, which gradually pass over into a firm, fibrous cicatricial tissue. The further shrinkage of this new tissue is then frequently the origin of hinderance to the movements of the globe, the cicatrix is stretched in certain positions of the eye, the adjacent conjunctiva is rendered tense, and thus a condition of irritation is maintained, which leads indirectly either to hypertrophy or to the formation of a new pterygium. This evil condition of things can perhaps be lessened to a certain extent by the

c. (*Transplantation of the pterygium.*) To this end the pterygium is caught with a wide-hooked forceps at the edge of the cornea, lifted up as much as possible, and with a cataract knife separated from the cornea as far as its base. The conjunctiva is then divided with the curved scissors toward both the retro-tarsal folds in curved lines, which correspond to the upper and lower limits of the pterygium. The tendinous point of the detached pterygium is now separated, and the body of the pterygium is divided in half by an incision running in its axis. This being done, two small, quadrangular conjunctival flaps are formed, one upper and one lower, in order to cover the raw place. By the contraction of these detached conjunctival flaps the two vertical incisions widen to the base of the pterygium. In both the triangular exposed spaces thus produced the halves of the pterygium are then sewed fast, for which purpose one stitch at the apex usually suffices. Then a suture is introduced through the angle of the conjunctival flap lying on the cornea, and a second one through the two angles lying on the pterygium. This latter suture is also united simultaneously with the middle of the divided pterygium, whereby the line of union of both conjunctival flaps is somewhat stretched, and the temporal end of it is drawn away from the cornea (*Knapp*).

After the operation it is very advisable to limit the movements of the eyes by a binocular protective bandage, in order that the knots may not rub, and that the adhesion of the edges of the wound be not disturbed by tearing and displacement of the loosened parts of the conjunctiva. This bandage is to be worn two to three

days, according to necessity, after which the suture should be removed. In the mean time a corresponding antiphlogistic mode of treatment is to be carried on. If later on granulations should be formed with secretion of pus, the best means is to paint the parts with tincture of opium, of course after preliminary removal of very prominent fleshy warts.

A complete clearing up of the affected corneal portion is only rarely to be hoped for. Even if the corneal portion was very superficially situated, and was completely removed, an epithelial opacity generally remains behind. But if the corneal portion lies in a loss of substance, a return to the normal condition is still less to be expected. The loss of substance is generally filled up by turbid neoplastic tissue. In isolated cases even large ulcerations of the cornea occur.

In consideration of all this, it is scarcely possible to be a very earnest advocate of an operation in pterygium. In small ones, where it accomplishes the most, the indications are predominantly of a cosmetic nature. With the most of those affected with pterygium, these indications do not weigh very heavily. In a large pterygium we can do much less, and the danger is considerably increased. It is well, then, in these cases to avoid an operation, and in case the vision is considerably affected by covering over of the pupil, we may improve it by an iridectomy.

Authorities.—*Arlt*, Die Krankheiten des Auges I. Prag. 1851. S. 158, 160, 163.—*Hasner*, Entwurf einer anat. Begründung der Augenkrankheiten. Prag. 1847. S. 73; Klinische Vorträge, &c. Prag. 1860. S. 184, 187, 189.—*Ruete*, Lehrb. der Ophth. II. Braunschweig. 1854. S. 167, 191.—*Stellwag*, Ophth. II. S. 874, 990, 991.—*Szokalski*, Arch. f. phys. Heilkunde. 1845, Nr. 2.—*Arnold*, Die Bindehaut der Hornhaut. Heidelberg. 1860. S. 42.—*Pagenstecher* und *Sämisch*, Klin. Beobachtungen. I. Wiesbaden. 1860. S. 15.—*Winther*, Experimentalstudien über die Path. des Flügelfelles. Erlangen. S. 14, 28, 32, 40, 49, 50.—*Hippel*, Berlin. kl. Wochenschrift. 1868. Nro. 17.—*Niemetschek*, Prag. Vierteljahrschrift. 101. Bd. S. 81.—*Mannhardt*, A. f. O. XIV. 3. S. 26, 29.—*Mooren*. Ophth. Beiträge. S. 73.—*Knapp*, A. f. O. XIV. 1. S. 267.

2. Xerosis of the Conjunctiva—Xerophthalmia.

Pathology and Symptoms.—There are two varieties of the disease—xerophthalmia *glaber* and *squamosus*. The former is identical with partial cicatrization of the conjunctiva. It is characterized by extensive, tendinous white, satiny cicatrices, which invest the tarsal conjunctiva and the reflection, and shorten them considerably by their shrinkage. The ocular conjunctiva appears at the same time very dry, stiff, and tense, so that at every motion of the globe it falls into a number of fine folds, concentric to the corneal margin. Its surface, as well as that of the cornea, which is always turbid and often also in a state of pannus, has, in consequence of the dryness of the epithelium, a very peculiar, dull, straw-colored brilliancy. The secretion of the conjunctiva is very much decreased. This is not only objectively observed, but also subjectively, by an extremely troublesome sensation of dryness in the eye, especially noticed at intervals, and united with considerable hinderance to the movements of the lid.

The pathological condition in *xerophthalmus squamosus* is complete degeneration of the conjunctiva and its adnexæ into a tendinous cicatritial tissue, which is of course deprived of all secretory power. At the same time the movements of the globe and the lids are hindered by diminution of the surface of the conjunctiva. This also prevents the throwing-off of the epithelial cells, and thus favors their drying and collecting in the narrowed conjunctival sac.

On opening the lids, we find the entire conjunctiva, which is very much shrunken, together with the cornea, covered by a stratum of fatty grayish or yellowish fatty-looking mass. It is sometimes freely granulated, and is made up of dry epithelial scales, fat, grumous, organic material, mucus, and occasionally of calcareous granules.

The corneal substance is turbid from a condition of pannus, or covered by a tendinous new-formation; the conjunctival substance is entirely in a state of tendinous degeneration, thick, and rigid. The caruncle has generally disappeared, or is only present in a rudimentary condition. The semilunar folds are obliterated. The pseudo-conjunctiva is thus directly extended from the scleral surface to the angles of the lids. In the breadth of the lids, it sinks in only for a slight depth, and always proceeds from the sclera, immediately over upon the tarsal surface.

Sometimes the conjunctiva is so shortened that the vicarious, tendinous tissue passes almost immediately from the margin of the cornea to the inner lip of the edges of the lids, and the movements of the lids thus appear almost completely arrested, and the palpebral fissure stands half open. The cartilage of the lids is in the earlier stages generally thickened, but subsequently very much shrunken, distorted, and the lids in a state of en or ectropion. The meibomian and hair follicles are generally either impaired or entirely destroyed. (*Wedl.*) The lachrymal puncta are frequently obliterated, the lachrymal sac atrophied, and the lachrymal glands in many cases (but not always) are atrophied. (*Hasner.*)

On account of the destruction of the secretory structure, and of the canals of exit of the glands, weeping is impossible, and even very irritating substances, brought

in contact with the surface of the eye, excite only a slight reaction. This is recognized by injection of the vessels and unpleasant sensations of pressure, burning, etc.

Causes.—The proximate cause of xerophthalmia is generally the degenerative form of conjunctivitis, a severe diffuse or gelatinous trachoma, especially the two latter, when they have been neglected or treated with too severe caustics. Xerosis is also one of the consequences of diphtheritic conjunctivitis, and is especially to be feared here, in the case of gangrene (*Graefe*). Occasionally it results from an irritation acting upon the eye for a long time, *e. g.*, trichiasis, entropion, lagophthalmos, or in consequence of the adhesion of both lids during the course of inflammations, after cauterizations or burns, or after the rare form of *pemphigus conjunctivæ*.

The desiccations limited to the parts around the opening of the lids, which are connected with neuroparalysis, deserve special mention. Their most frequent cause is found in the diminished lachrymal secretion and in the defective closure of the lids. In this category we may also mention the drying of the parts near the opening of the lids in cholera (*Graefe*), united with lagophthalmos and venous hyperæmia (*Graefe*), as also perhaps the xerosis partialis or triangularis, which has been frequently observed in much broken-down, marasmic, or anæmic individuals, but particularly those of a scorbutic tendency, and which, united with hemeralopia, is said to occur frequently in Russia, during lent (*Bitot*, *Blessig*). The portion of the conjunctiva around the opening of the lids becomes in this disease dry, fatty, dull, dusty, absorbs no water, and in movements of the globe lies in fine folds. Its surface is covered partially, or in its entire extent, by desiccated epithelial cells, which in part are already commencing to crumble (*H. Cohn*); a great amount of irritation is also generally present. After a long time the xerotic epithelium is cast off and replaced by new, or ulcers are formed. The xerosis often attacks the cornea also and here leads to ulcerations with all their consequences, sometimes even to necrosis (*Blessig*). The ophthalmia Brasiliana occurring under similar relations, particularly among badly nourished slaves (*Gama-Lobo*), is said to produce the peculiar xerotic form of disease in its highest degree. Moreover, it is asserted that the triangular xerosis has been observed in perfectly healthy, well-nourished individuals, especially, however, as the result of an ophthalmia which leads to shrinking of the conjunctiva (*H. Cohn*). It is evident that these cases are to be strictly distinguished from those mentioned above, so much the more, as the latter as a rule are cured of the original trouble, whilst the xerosis as a consequence of degenerated conditions of the conjunctiva is permanent and incurable.

Treatment.—In *xerophthalmus squamosus*, instillations of solutions of salt, of caustic alkalies and the carbonates, of dilute acetic acid, of milk, etc., have been recommended for the purpose of getting rid of the dried epithelium, making the cornea more transparent for a time, and supplying the place of the tears.

Frequent penciling with glycerine seems to do the best service, as it remains a longer time in the conjunctival sac, lubricating it well, and markedly clearing up the opacities of the cornea.

Authorities.—*Arlt*, Die Krankheiten des Auges, I. Prag, 1851. S. 126.—*Hasner*, Entwürf einer anat. Begründung &c. Prag, 1847, S. 78; Beiträge zur Anat. und Phys. des Thränenleitungsapp. Prag, 1850, S. 101.—*Ruete*, Lehrb. der Ophth. II. Braunschweig, 1854, 172.—*W. Ch. H. Weber*, Ueber die Xerosis Conj. Giessen, 1849, S. 3, 11, 14, 23, 28, 34.—*Wedl*, Atlas, Conj. Sclera.—*Stellwag*, Ophth. S. 865. 992.—*Piringer*, Die Blennorrh. am Menschenauge, Graz, 1841, S. 224, 423.—*Graefe*, A. f. O. I. 1. S. 249.—*Graefe*, A. f. O. XII. 2. S. 202.—*Bitot*, *Blessig*, Centralbl. 1867, S. 424.—*H. Cohn*, Ueber Xerosis Conjunctivæ, Diss. Breslau, 1868, S. 32.—*Gama-Lobo*, *Ullersperger*, kl. Monatbl. 1866, S. 65.

NINTH SECTION.

INFLAMMATION OF THE LIDS—BLEPHARITIS.

Anatomy.—The two lids, palpebræ, close the entrance to the orbit, and lie immediately on the anterior convexity of the globe, being pressed upon it by muscular action, and by the force of the atmosphere. They end with a free margin at the palpebral fissure. This latter forms externally an acute, and internally an obtuse, angle (canthus).

Fig. 59.

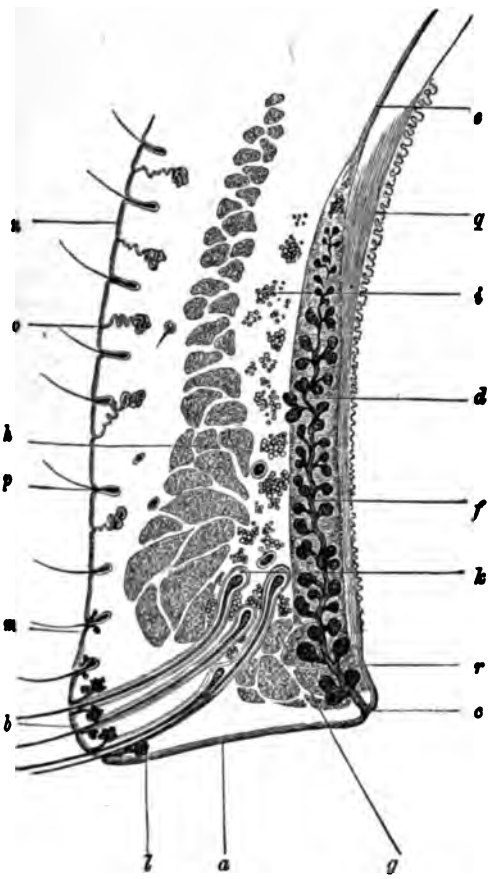

On the inner border of the lid we distinguish, besides the surface of the lid, one line in breadth (Fig. 59, *a*), an outer and inner lip. The outer lip, *b*, is very much rounded off, and is perforated by lashes or cilia of a varying length. The inner lip, *c*, on the contrary, exhibits an almost right-angled edge, on which the tarsal glands are arranged closely together. Near the inner angle of the lid, the lachrymal canaliculi open. In the composition of the lids, there are united a number of structures, which have the most different anatomical characters.

1. The cartilage of the lid, tarsal cartilages, which form the skeleton of the lids. These are properly only thickened connective tissue, interspersed with numerous elliptical nuclei, which can not be completely dissected from the submucous tissue. The upper cartilage is much thicker, broader, and more compact than the lower one, resembling a membrane. Its shape is crescentic, with an inner obtuse and an external acute angle, which both extend somewhat over the canthi of the lids. The border toward the

palpebra fissure is sharply cut off, so that it forms a surface. Toward the orbital border, the cartilages become thinned, and finally pass into a fascia, *e*, which is firmly attached to the orbital margin. The upper half of this *fascia tarso-orbitalis*, or palpebral ligament, is connected to the *levator palpebræ* muscle, whose tendon runs into a broad membrane, and is lost in this fascia.

At the inner angle of the lid, the palpebral ligament is connected to the internal palpebral ligament. This is a very firm, tendinous band or cord, two lines in breadth, lying just under the integument, and it appears very distinctly on traction being exerted on the outer commissure. This ligament, on the facial aspect of the orbital frontal process of the superior maxillary bone, passes into periosteum, and is inflected backward, almost horizontally, over the upper portion of the lachrymal sac, toward the inner commissure.

In front of this, it divides into two horns, which become lost partly in the angles of the cartilage and the surrounding parts of the palpebral ligament, and partly in connective tissue lying behind the caruncle. Its posterior surface is merged in a thick, tendinous mesh-work, which presses in posteriorly between the globe and the lachrymal sac, and is in part connected with the tendinous covering of the lachrymal sac, greatly strengthening this. (See section on *Lachrymal Organs.*)

We may consider a tendinous thickening of the orbital tissue, richly permeated with elastic elements, as the outer palpebral ligament. This proceeds from the posterior surface of the lids, in the vicinity of the outer commissure, and is connected to the orbital surface of the malar bone and the membranous sheath of the globe.

2. In the interior of the cartilage, surrounded by its tissue, lie sebaceous glands, which are commonly described as meibomian glands. These are sinuous, and sometimes quite wide tubes, on whose walls lie a number of roundish or racemose, glandular vesicles, with short pedicles. These tubes, arranged very thickly together, open on the inner lips of the lid (at *c*). The portion lying next to the margin of the lid, which is the widest, and has the largest lobuli, lies without the tarsal cartilage, surrounded by connective tissue and muscular fiber. Within the cartilage, they extend nearly in a vertical direction toward its orbital border, without, however, reaching it, ending sooner or later in a blind extremity, or uniting with the adjacent tubes. In this way, at times, they approach the anterior, at others the posterior, tarsal surface. Here and there isolated lobuli extend from the tarsus into the submuscular or submucous tissue.

Their product, the sebaceous material (*sebum palpebræ*), are chiefly cells, whose contents rapidly undergo fatty degeneration. The cell-membrane rupturing and being destroyed, is excreted in the form of fat-granules.

3. The muscles. These are partly inorganic, like the *circular muscle*, and the *levator palpebræ superioris*, partly *organic*, non-striated like the two *musculi palpebrales* or *orbito-palpebrales* (*H. Müller, Henle, Sappey, Harling*).

a. The *orbicularis palpebrarum* muscle (circular muscle of the lids), is a flat, disc-shaped muscle, which covers not only both tarsal cartilages and the palpebral ligament, but also the facial surface of the bones surrounding the orbital margin. We divide it into a palpebral and an orbital portion. To this is added a peripheral or accessory portion, which is made up of coarse and thick dark-colored bundles of fibers, and which are more or less separated from each other by fat, arising from the periosteum in the vicinity of the orbital portion. They are, however, only partially joined to this; the other part proceeds from the direction of the circular fibers, and is inserted into the adjacent integumentary portion. The lachrymal, or *Horner's muscle*, is almost universally considered as belonging to the orbicularis,

since it, with the greater part of its fibers, really unites with the orbicularis, and thus plays the part of a separate head.

a. The palpebral portion consists of delicate and pale fibers, especially in the upper half, where they are narrow and arranged closely together, covering the tarsal cartilage and the palpebral ligament, above and below, up to the orbital margin, but externally passing beyond the orbital margin, and extending seven to eight lines behind the outer commissure. The fibers lying next to the edges of the lid are almost horizontal in course. The farther they are removed from the margin the greater is the curve of the arch which they describe.

On the other side of the commissure, the bundles of the two halves meet at an angle, which is the sharper, the nearer to the commissure the fibers end. The fibers are here united to the fascia lying beneath by firm, rigid connective tissue. On more exact examination we find that the individual fibers separate, and pass partly into the other half of the muscle, but partly into the connective tissue on the boundary line of the two halves. The palpebral portion of the orbicularis is composed of fibers which rise in part from the crest of the lachrymal bone, in part from the palpebral ligament and its branches. Formerly it was generally described as consisting of two separate muscles. (*Arlt.*)

The portion arising from the crest of the lachrymal bone, the so-called posterior lachrymal muscle, or Horner's muscle, is quite a broad and thick, elliptical and quadrangular, bundle of fibers. It arises chiefly from the periosteum of the upper third of the *crista lachrymalis*, and the adjacent portion of the lachrymal bone, but sometimes partly from the aponeurosis, closing the lachrymal groove, and extends toward the inner canthus, in an arch, convex internally. (See section on *Lachrymal Organs.*) Before it reaches this the broad, smooth belly of the muscle divides into an upper and lower head, one of which passes to the upper the other to the lower margin of the lid. A few of the fibers adhere to the open-work of the posterior surface of the palpebral ligament; others weave around the canaliculi; but the principal portion of them is continued toward the edge of the lid, and through them to the outer commissure.

A portion of these muscular fibers, which is described as the *sub-tarsal muscle* (*h*), runs within and behind the cilia, separate from the palpebral portion, between the free tarsal border and the integument of the edge of the lid (*Wolfring*). It does not reach the external commissure, its fibers being before this inserted in different portions of the integument of the edge of the lid. The other extremity of the portion on the lachrymal crest lies upon the peripheral zone of the cartilage, and extends in front of the cilia. It passes beyond the outer commissure, when the fibers of the two halves meet at an angle.

The portion of the orbicularis in the palpebral ligament is divided into an upper and lower half Both arise partly from the outer ends and tendinous horns of the palpebral ligament, and in part from the tendinous mesh-work, in which the posterior surface of the ligament in question is lost, and also in part from the fibrous covering of the lachrymal sac.

The bundles next to the edges of the lids lie partly on each other (at *h*), and they, in part, cover the more peripheral bundles of the portion belonging to the lachrymal sac, and their ends extend seven or eight lines beyond the outer commissure. (*Arlt.*)

β. The orbital portion arises in part from the inner half of the palpebral ligament, and partly from the neighboring bony surfaces, but especially from the orbital process of the superior maxillary bone, as far down as the infraorbital canal, and from the frontal bone as far as the *incisura supra orbitalis.* Single bundles have a deep origin, from the tendinous superficial covering of the palpebral ligament, and from the fibrous covering of the lachrymal sac. The bundles are thick, dark-colored, pass on to the temporal side without interruption, and without any firm union to the structures beneath. Only a few bundles pass out from the circle, here and there uniting with the integument over them. (*Arlt.*)

b. The *levator muscle* has a long, narrow belly, compressed together like a ribbon. It arises by a common origin with the straight muscles of the eye at the periphery of the orbital foramen, runs forward along the roof of the orbit, and is inserted somewhat widened into the tarso-orbital fascia near the convex border of the cartilage of the upper lid.

c. The *superior palpebral muscle*, or *orbito-palpebralis*, is connected directly with the levator, and represents, as it were, a prolongation of it. Its organic fibers arise between the inorganic fibers of the levator muscle, and spread out, only traversed

by single transverse fibres, superficially between the anterior layer of the conjunctiva sack and the overlying cartilage of the lid with its aponeurosis. The muscle has the form of a truncated triangle, about 12–14 millimeters in height, the basis of which reaches over the entire breadth of the cartilage of the lid and its aponeurosis from one orbital edge to the other. Among its abundantly anastomosing longitudinal fibers, the marginal ones run along the inner and outer wall of the orbit near the anterior edge; the others, however, in an obliquely rising curved line along the superior border of the cartilage of the lid. The muscle and tarsal cartilage combined form, therefore, a quadrant of a circle which is attached on both sides to the orbital wall. The muscle can only act in a vertical direction. It is lengthened and put upon the stretch as well by opening wide the fissure of the lids as by the closure of it. It is, therefore, an *antagonist* of the *orbicularis* and *levator*, resists their action, limits the effect of their contraction, and gives to them a certain regularity (*Sappey*, *Harling*). Its paralysis produces a peculiar ptosis of the upper lid, slight in degree and accompanied usually by myosis (*Horner*).

d. The *inferior palpebral muscle* is more netlike, and its fibres have generally a horizontal direction. It lies close under the conjunctiva, and runs from the orbital tissue near the retro-tarsal fold, up to the convex border of the lower tarsal cartilage, where it ends in an elastic tendon. Combined with the superior palpebral muscle and with the organic orbital muscles, its purpose is, undoubtedly, to close exactly the lids upon the globe and the soft parts of the orbit, which, among other things, is also of the greatest importance for the conducting away of the tears. Whether it can depress the lower lid is uncertain (*Harling*).

4. Beneath the muscle we find a structure of connective tissue interspersed with fatty tissue, *i*, which adheres to the surface of the cartilage, and is connected to the subcutaneous tissue. In this stratum, near the free margin, lie the follicles of the lashes or cilia, *k*, covered by the orbicularis muscle, and surrounded by fatty tissue. Their base is a line, or even more, above the surface of the margin of the lid. A portion of the follicle rests immediately on the surface of the cartilage, and is closely united to it; another portion is somewhat more loosely connected to the submuscular layer, varying in depth and in distance from the cartilage. In each follicle, quite near the mouth, a number of racemose sebaceous glands open, *l*. Their fatty contents lubricate the cilia.

In the immediate vicinity of the cilia, numerous little hairs are found, *m*, whose follicles are also in part covered with mature sebaceous glands (*Moll*). The cilia undergo a constant change. When they have reached their normal length, which occurs within five months, their bulb becomes detached (as in *l*), while a new hair develops itself upon the papilla, which drives the old one before it until it falls out, or is loosened by rubbing, washing the face, etc. (*Donders*).

5. The integument of the lid, *n*, is a very delicate continuation of the common integument, having but very few elastic elements. It is united to the tissue beneath by loose and long-fibered connective tissue, and may be lifted up in broad folds. In the tissue beneath are numerous sweat-glands, *o*, and the delicate follicles of extremely fine little hairs, *p*, which occupy the integument of the lid (*Moll*).

The sweat-glands near the edge of the lid give up their characteristic coil-like form and become slightly contorted, relatively wide canals, which open in the excretory ducts of the hair-bulbs (*Moll*, *Stieda*).

6. On the inner surface of the tarsal cartilage, and on the fascia tarso-orbitalis, is the tarsal conjunctiva, *q*, indicated by its papillæ, and firmly united by tense submucous connective tissue.

7. The arteries of the lids proceed from the ophthalmic artery. The two principal branches run close to the cartilage near the free palpebral border, anastomosing freely with branches of the angular, lachrymal, anterior superficial, temporal, and transverse facial, and thus form two vascular arches surrounding the palpebral fissure, *arcus tarseus superior* and *inferior*.

The inferior arch runs along the convex border of the cartilage of the lower lid, in the child, removed about 2–3 millimeters from the border of the lid. The superior arch lies somewhat nearer the edge of the lid (1–2 millim.), like the inferior on the anterior surface of the tarsus. It gives off two arterial branches, each one distant about 3–4 millim. from the canthus. Both branches converge toward one another and, anastomosing, form a second arterial arch (*Henle*) which runs directly along the convex border of the tarsal cartilage. From these arches and from the vessels connected with them proceed numerous branches to the skin and muscles of the lids, to the conjunctiva and tarsal cartilage, which they partially perforate, in order to ramify upon its internal surface in the conjunctiva of the lid (*Wolfring*).

The veins empty into the upper and lower palpebral veins, and pass into the *venæ temporales mediæ* and *vena facialis antica*.

The lymphatic vessels pass into the superficial facial and sub-maxillary glands.

The tegumentary nerves are branches of the tri-facial. The orbicularis muscle is supplied by the facial, the levator palpebræ by the oculo-motorius (3d pair), and the organic muscles by the sympathetic.

Nosology.—The lids may be considered as folds of the general integument, which in their individual component parts have undergone certain modifications. In accordance with this view, the different forms of blepharitis are only repetitions of those processes which are daily observed on other regions of the common integument, and are so well known as scarcely to need a particular description.

1. Very frequently the whole structure of the lids is involved in a tissue-proliferation process. This generally occurs secondarily, by continuation of the inflammation from the adjacent parts. The inflammatory center is then sometimes in the conjunctiva, at times in the globe, in the orbit or its bony walls, or in the adjacent soft parts of the face. Under such circumstances, the participation of the lids is apt to be seen by the symptoms of inflammatory œdema. It quickly recedes as soon as the morbid process, in the inflammatory center, has passed the acme, and tends toward resolution. Occasionally, however, the inflammatory proliferation of tissue leads to hypertrophy of the constituent parts, especially when the inflammatory attacks are often repeated, or when the original disease takes on a chronic course, and keeps up a mild form of blepharitis for some time.

Permanent interruptions to the passage of lymph, and impediments in the return of venous blood, as sometimes results after caries or necrosis of the lower and outer orbital border, or of the process of the superior maxilla from deep cicatrices, often render œdema permanent. The lids are then so puffed out that the eyes are almost closed, and the face is very much distorted. The infiltration under such circumstances is somewhat gelatinous, and, since the sub-integumentary tissue is apt to be very much thickened, and hypertrophied, the swelling is quite consistent.

Blepharitis often appears more independently, and may be severe. The inflammatory product then is a rigid, firm mass, chiefly consisting of proliferating cells and nuclei. These collect especially in the loosely-woven inner layers of the lid, and generally cause very large swellings. These collections, as a rule, rapidly deliquesce into pus, while they extend more and more on the periphery by continuous proliferation of tissue (*abscess of the lid*).

Exceptionally, such abscesses bear the character of anthrax or carbuncle (*Himly, Mackenzie*), and lead, through gangrene, to large losses of substance, when death does not occur before this happens. This condition should be distinguished from malignant or gangrenous œdema [malignant pustule], which occurs especially in persons who are employed about or with decaying animal matter. In the beginning it often has the appearance of simple œdema, but rapidly extends to the neck, the breast, and abdomen, throws out gangrenous vesicles, excites necrotic sloughs, and destroys the integument quite extensively. The patient often dies from the constitutional disease. (*Mauvezin, Debrou.*)

Lupus of the lid is a peculiar form of blepharitis. It is only rarely primarily developed in the lids, but generally attacks them secondarily, passing over from the neighboring parts of the face. It generally destroys a large portion of the lid, and, in case it is limited in time, causes it to shrink into an irregular swelling. More frequently it consumes the entire lid, extending to the conjunctiva and the globe, and even eats away the bony walls of the orbit, together with its loosely-woven tissue, provided death does not sooner occur.

Secondary syphilitic ulcers at times make as great ravages in the lids. They generally extend from the surrounding soft parts, and bones of the face, to the lid. Occasionally they appear independently. They then generally result from little hard and sensitive nodules, situated in the sub-cutaneous connective tissue, and which, beginning at the surface, deliquesce, excite disagreeable ulcers, with infiltrated, uneven, funnel-shaped base, irregular edges, and containing a discolored secretion. If such a gummy tumor be developed on the free surface of the lid, it destroys at the same time the integument, the cartilage, and the conjunctiva, with the structures lying between. But if it be developed more on the surface of the lids, it rapidly takes a deep hold, completely perforates the lid, and extends over it, finally breaking through the bridge which separates it from the free palpebral border. (*Makenzie, Desmarres, Wedl, Hirschler.*)

But gummy tumors do not always precede syphilitic ulcerations. In isolated cases the process begins with the infiltration of a portion of the conjunctiva, but quickly ulcerates, and forms a conjunctival ulcer, which is very easily distinguished from the surrounding integument by its fatty-looking coating, its irregularly-eaten edges, and its uneven base, as well as by its rapid seizure of the intermarginal portions. If the constitutional disease be subdued by appropriate treatment, that is, by mercurials, if the system be saturated with mercury, and iodide of potassium, the ulcers generally cicatrize rapidly. The cicatrix itself is very characteristic, so that we may decide as to the syphilitic character of the ulcer from its appearance. It appears as a tendinous, white cord, entirely devoid of cilia, sharply defined, which extends through the entire thickness of the edge of the lid, and forms an excavation in consequence of its great shrinkage. (*Hirschler.*)

2. In other cases, which are not less frequent, the inflammation is confined to the individual component parts of the lids; the blepharitis is partial.

a. In the course of an attack of facial erysipelas, the integument of the lid and the loose connective tissue almost always participate in the erysipelas to a very marked degree. The disease often attacks deeper structures, when the conjunctiva exhibits the symptoms of inflammatory œdema, and even of true chemosis. Pustules not unfrequently occur in the course of the erysipelas, on the surface of the lids, or abscesses are formed, which may cause great destruction of the loosely-woven tissue, as well as in the integument. Dermatitis of the lids often occurs primarily after severe injuries, especially in consequence of burns and cauterizations. Extensive ulcerations of the lid then quite often result, and the loss of substance being replaced by a greatly contracting cicatrix, shortening of the palpebral integument, a lifting up of the lid from the globe, with or without distortion, is caused (*ectropion*). If the ulcerative process seizes upon the free surface of the border of the lid, an adhesion of the palpebral fissures occurs to a greater or less extent (*ankylo-blepharon*).

In case the suppuration extends to the conjunctival sac, the inner surface of the lid adheres to the surface of the globe to a greater or less extent (*anterior symblepharon*).

Ulcerations of the integument are also, in rare cases, caused by inoculation from

the pus of a chancre. They are then exactly like primary syphilitic ulcers, and often become very large. They most frequently occur on the surface of the edge of the lid, covered by a delicate integument. (*Mackenzie, Desmarres.*)

Exanthematous efflorescences often occur on the integument of the lid. There is scarcely an eruption, acute or chronic, which may not also localize itself on the lid. The pustular efflorescences and eczema and measles are of particular practical importance. These shoot up not unfrequently in very great number on the edges of the lids, and then lead to the bad consequences of a blepharitis ciliaris. Ulceration of the hair-glands, or even of the entire follicle, cicatritial misformations of the edge of the lid, &c., may result from them.

At this point *ephidrosis palpebrarum*, or the sweat-disease, deserves a description. It rarely occurs, and then generally in persons who are inclined to profuse perspiration in various parts of the body. The lids appear covered by a tenacious fluid, which on being washed off is immediately replaced by little drops which run together. In the upper portion of the upper lid, containing the most folds, the secretion is often frothy, from the movements of the lids, and thus readily causes excoriations (*Graefe*). Warm baths and cold friction are recommended for this generally very obstinate affection (*Mooren*).

b. The hair-glands are also very much disposed to inflammation. The same morbid process is repeated here, which, in other parts of the body, is called *acne.* In consequence of some injury, the cells which lie on the inner wall of the gland begin to proliferate. In the further changes which the contents undergo, fatty glandular material is secreted. The cavity of the gland thus becomes distended. The surrounding connective tissue swells, in consequence of the hyperæmia of the vascular net-work, and of the inflammatory proliferation of its elements.

In the lowest forms of the morbid process, this inflammatory swelling of the connective tissue is very slight; the affection is chiefly marked by an increase of the secretion, which in appearance does not greatly differ from the ordinary sebaceous matter of the body. In many cases a portion of the newly-formed cell becomes of a horny consistency, while it is slowly pushed forward by the cells subsequently developed, and then presents itself on the opening of the hair-follicle as a small fatty scale, or longer epidermis-like, grayish, fatty membrane, which covers the outer lip of the lid to a greater or less extent, and single cilia or bundles of them, like a sheath, for some distance, both within and without the follicle. The remainder of the secretion dries to yellowish scabs, which stick quite closely to the cilia and epidermis.

In a severe stage of the inflammation, the secretion increases greatly, becomes thinner, and more like pus. The formation of crusts on the border of the lid is exceedingly abundant. At the same time the proliferation in the connective-tissue envelop of the gland is very luxuriant; the border of the lid in the vicinity of the inflamed glands swells very much. A so-called acne-nodule is developed, or in case a greater number of acini or packets of glands participate in the process, an actual swelling is excited. The root of the hair is then generally also affected; the morbid process is also evident in the hair-follicles.

The hair-bulbs swell up greatly, are spread out, so that they rest more or less evenly upon the papillæ. At the same time they become soft from the great swelling of the cells composing them, may be easily pressed together, or even appear adhesive. Then their great richness in pigment becomes marked; the bleaching of the hair-cells is imperfect, or is delayed on account of the luxuriant neoplastic formation. The cells of the medullary canal have at times been found, but are, however, sometimes absent. The inner sheath of the root adheres delicately to the trunk, but,

on the other hand, very loosely to the external layers, so that the cilia are removed very easily without pain (*Schiess-Gemuseus, Sämisch*).

If the disease goes on still further, which often occurs secondarily, the collected glandular contents acting exactly like a foreign body on its surroundings, or if the process appears very severe from the beginning, suppuration is the ordinary result. The proliferating contents of the cells then acquire the characteristics of pus, while, at the same time, the inflamed swollen tissue surrounding the walls of the glands is destroyed, and thus the size of the abscess increased. The suppurative process is then generally continued upon the true hair-follicle, and leads to its destruction by suppuration. If the hair affected be drawn out, a grayish-white plug follows, which consists of pus-cells, lying in and between sheaths of the bulbs, affected with luxuriant cell-proliferation, and surround these from without inwards. (*Schiess-Gemuseus.*)

The pus may be subsequently evacuated through the open mouth of the hair-follicle, or makes a passage by continuous deliquescence of the infiltrated tissue, gradually reaching the surface, and breaking through externally, after the epidermis has been driven out as a vesicle. This generally happens near the mouth of the accompanying hair-follicle. The pustules of acne most frequently develop here, because the pus more easily and quickly breaks away in the direction of the canal of exit, than it perforates the rigid tissue of the true cuticle (*acne pustulosa*). With the evacuation of the pus, the process is generally on the way to resolution. Occasionally, on account of unfavorable conditions, the disease does not go on to cure. An ulcer is developed at the seat of the pustule, which goes deeper and deeper, and may be troublesome by its duration, as well as by its results.

Exactly as in other portions of the integument, acne sometimes appears on the edge of the lid as a distinct pustule, the disease confining itself to one acinus, or a single collection of glands. All the sebaceous follicles of one or all four edges of the lids are soon involved in the morbid process. The condition is then called *blepharadenitis*, or *blepharitis ciliaris*.

The disease may exhibit, in one or the other case, every degree of severity. Acne discreta occurs most frequently in the nodular and pustular form. Blepharitis ciliaris, on the contrary, runs its course with relatively less frequency as a slight affection, and is then, on account of the small amount of swelling of the hyperæmic border of the lid, a predominantly secretory disease (*blepharitis ciliaris secretoria*).

Yet severer cases of blepharitis ciliaris are quite common. They generally lead to marked hypertrophy of the connective tissue, very soon surrounding the glands and the hair-follicles, and causing with this some swelling and hardness of the edges of the lids (*blepharitis ciliaris hypertrophica*).

Ulcers are less frequently developed on the edges of the lids after partial suppuration of the inflammatory product. These extend more and more, run together, consuming the outer lip of the lid, even seizing the deeper structures, and may become very destructive from the loss of substance connected with it (*blepharitis ciliaris ulcerosa*).

Seborrhœa ciliaris is intimately connected with the secretory form of blepharadenitis. It really differs from it only in degree. It is rarely observed, and then in connection with seborrhœa of the other parts of the facial integument. The edge of the lid is then not swollen, only partially hyperæmic, and continually covered by fatty crusts of a grayish-yellow color, which resemble those of impetigo of children. The epidermis is very loosely attached. If the crusts are

removed, they are again quickly produced, and when cleansing the lids is neglected they reach a considerable size in a short time.

c. The cartilage is scarcely ever primarily and independently inflamed. But inflammation of the tarsal glands (*blepharitis tarsalis*) is frequently observed. Yet all the tarsal glands are never inflamed, or even the whole of one single gland. At least, the certain proof of such a process is as yet wanting. The inflammation is confined to single acini, or to a portion of the common tube. The pathological process is the same in its nature as in acne ciliaris. The anatomical peculiarities, however, the great distance of the acini from the mouths of the glands, the washing over of the inner lip of the lid with lachrymal fluid, the displaced position and the involution of the greater part of the gland in a firm, undistensible, fibrous tissue, cause many peculiarities. It is to be ascribed to this, that low grades of the process are not noticed. There must be quite a severe proliferation of tissue, in order to soften the cartilage which participates in it, and to cause it to be distended by the glandular contents, and also to involve the more superficial layers in the process, and thus making the redness and swelling of the inflammatory collection noticeable externally. The product of the proliferation of tissue is purulent, as is necessitated by the severity of the process; either pure pus, or a thickish gelatinous mass streaked with blood, which more exact examinations have shown to be embryonal connective tissue. This is, to a greater or less extent, mixed with true pus. The product is generally found not only in the glandular cavity, but also in the proliferating surroundings. The inflammation then forms an abscess.

It is very probable that the rigidity and resistance of the tissue of the cartilage has an influence upon purulent destruction of the inflammatory product, in so far as it exerts a certain pressure upon the proliferating glandular contents, and to such an extent renders the condition more unfavorable, as is the case in abscesses, which occur beneath tense aponeuroses.

As in acne, the proliferation of tissue is first seen in the cells of the inner glandular walls. The glandular contents, therefore, increase considerably in quantity. At the same time the cartilaginous tissue around the acinus begins to proliferate; it becomes injected and relaxed. The walls of the glandular cavity becoming more yielding, the acinus is elevated above the surface of the tarsus, and thus a tumor is formed, which we call *hordeolum*, stye. According as the inflamed glandular vesicle stands nearer the anterior or posterior wall of the cartilage, does the tumor appear more toward the integument of the lid or the tarsal conjunctiva (*hordeolum externum* or *internum*).

If the acinus lies without the cartilage, in the thickness of the border of the lid, the equal distention in all directions easily follows. It is therefore a regular distention. Peripheral hordeola have, therefore, more of a spherical shape, while external and internal ones, with a flat wall, appear to rest on the cartilage.

Authorities.—*Kölliker*, mikr. Anat. II. Leipzig. 1854. S. 720.—*Henle*, Handb. der Anat. Braunschweig. I. S. 141, II. S. 688, 697.—*Arlt*, Die Krankheiten des Auges III. Prag. 1856. S. 337, 339; A. f. O. IX. 1. S. 64, 78, 85.—*Albini*, Zeitschrift der Wien. Aerzte. 1827. S. 29.—*Moll*, A. f. O. III. 2. S. 258.—*Donders*, ibid. IV. 1. S. 286, 294.—*Henke*, ibid. IV. 2. S. 70, 133.—*Busch*, ibid. S. 109.—*A. Weber*, kl. Monatbl. 1863. S. 335, et seq.—*Wedl*, Atlas Conj. Sclera.—*Stellwag*, Ophth. II. S. 915, et seq.—*Mackenzie*, Traité d. mal. d. yeux. traduit par Warlomont et Testelin. I. Paris, 1856. P. 149, et seq.—*Desmarres*, Traité d. mal. d. yeux. Paris. 1847. P. 156, 159.—*Hirschler*, Wien. med. Wochenschrift. 1866, Nr. 72, 78, 74.—*Graefe*, A. f. O. IV. 2. S. 254.—

Himly, Krankheiten und Missbildungen, etc. I. Berlin, 1843. S. 201, 203, 204.—*Mauvezin*, gén. de méd. 1865, S. S. 421, 689.—*Debrou*, kl. Monatbl. 1866. S. 143.—*Schiess-Gemuseu* chow's Archiv. 27. Bd. S. 132.—*Wolfring*, A. f. O. XIV. 3. S. 165, 166.—*H. Müller* schrift f. wissenschaftl. Zoologie. IX. S. 541; Würzburg. Verhandlungen. IX. S. *Harling*, Zeitschrift f. rat. Med. XXIV. S. 275, 288, 295.—*Sappey*, Gaz. Méd. de 1867. S. 681.—*Lesshaft*, Arch. f. Anat. u. Phys. 1868. S. 265.—*Stieda*, Arch. f. mikr. 111. S. 363.—*Horner*, kl. Monatbl. 1869. S. 193.—*Biermann*, ibid. S. 91.—*Mooren*, (Beiträge, S. 43, 51. Sämisch. kl. Monatbl. 1869. S. 339.

1. Abscess of the Lid.

Symptoms.—*This affection is characterized by the development of a somewhat circumscribable, but not very distinctly bounded, tumor, in the loose tissue under the integument of the lid. The tumor is hard in the beginning, but subsequently yielding, and finally puffy.*

The inflammation freqnently appears with active fever, and has exactly the character of phlegmonous inflammation. The integument appears deeply and evenly reddened, hot, tense, and shining. The swelling under it is hard to the touch, is very sensitive to any contact, and painful. In other cases, the hyperæmia and heat of the parts, the sensitiveness and painfulness, are much less, the fever is entirely absent. The tumor is then more like a congestive or cold abscess. It is always in the beginning very consistent, even as hard as cartilage. But when the product of the tissue proliferation deliquesces, fluctuation is more distinct and extensive.

Abscesses occur most frequently in the upper lid, most rarely on the two lids at the same time. The affected lid is generally swollen in its entire extent, because the process easily extends in the loose sub-cutaneous tissue, and besides is apt to be surrounded by a large ring of congestion. The tumor not unfrequently reaches the size of a child's fist. It is generally pad-shaped. It rises abruptly from the lid, and slopes off in the other direction, and even extends over the bony orbital borders. The lid is, of course, immovable, and the eye is generally closed.

Abscesses occur oftener in the region of the eye-brows than in the lids. They also occur in the angular region. They are difficult to distinguish, at least in the beginning, from phlegmonous inflammation of the lachrymal sac, especially because in their farther course this part is apt to participate in the inflammation. They were formerly described under the name of *anchylops*, and, in case the pus had already made its way outward, *ægylops*.

Causes.—Occasionally, traumatic, chemical, or other injuries, which act upon the edge of the lid, are the exciting causes. But an abscess is often developed without any sufficient cause, spontaneously, as it seems. In many cases it is the result of erysipelas of the face, more rarely, of a pyæmic emboly of the vessels.

Course and Results.—Abscess of the lid almost always occurs in an acute form. When of a plegmonous character, it is apt to run a very rapid course. In the opposite kind of cases, one or more weeks may pass over before the collection of pus has been fully developed and advanced to its results.

Resolution of an abscess, without suppuration, is certainly exceedingly rare; suppuration almost always occurs. This begins while the tumor is still increasing at one or more points, extends more and more, presses against the surface, and is made known by the development of one or more points of suppuration. As a rule, the pus breaks through the integument. It more rarely perforates the fascia tarso-orbitalis, or evacuates on both sides of the lids.

After the evacuation of the pus, the tumor falls together, and the cavity of the abscess generally heals up, usually without leaving any kind of impairment of the

lid, even if the orbicular muscle has suffered from being involved in the inflammation. In not very unfrequent cases the suppuration has a worse character, and with advancing deliquescence, especially of the integument, leads to considerable losses of substance, whose consequences may be irregular cicatrices.

There may be a similar result in another way. It may occur if the abscess be evacuated at a very late period, or if only a small portion of its contents be thrown out and a great part of the integument is thinned, or even perforated by a continued deliquescence of the product of inflammation, or if the inflammation has a hypersthenic character, and a large part of the swelling becomes gangrenous. If the pus be evacuated in the conjunctival sac, it may lead to a partial symblepharon, or to a dense conjunctival cicatrix which will irritate the globe.

Treatment.—This should attempt first to limit the development of the abscess, that is, the proliferation of tissue. But in case suppuration has already occurred, the object of treatment should be to favor evacuation of the pus, and to secure a method of healing which may preserve the functions of the lid.

1. When the inflammation is of a phlegmonous character, a rigid constitutional and local antiphlogistic treatment is indicated. Iced compresses are particularly to be recommended, especially before the appearance of suppuration. They should be applied in proportion to the increase in the local temperature. Their effect may be assisted, in case of necessity, by a sufficient number of leeches placed on the temporal region.

But where the inflammation appears less violent, especially where there is less heat in the parts, covering the lid with a piece of linen cloth, or even warm applications, may better answer the requirements. For this latter purpose, the use of a wet pledget of lint, fastened by adhesive plaster, or a flannel bandage, is to be recommended.

2. If fluctuation be seen at any point, an opening should be made. The incision should open the abscess as wide as possible, but should be always parallel to the edge of the lid, and well down to the bottom of the tumor. The pus being then evacuated by pressure, a tent should be inserted, and the above-described bandage applied. Where the cavity of the abscess is quite large, it is necessary to apply the bandage more tightly, in order to keep the sides of the cavity in contact and favor their adhesion, which will considerably accelerate the cure. The bandage should be removed once or twice a day, and worn until the cavity of the abscess is completely closed, and no more pus evacuated. Of course, the wound should be cleansed, and the edges brought in contact at each application of the bandage.

3. If the abscess has already spontaneously opened, it is of advantage to enlarge the perforation, if it be very small, and unfavorably situated. If the pus has made its way out posteriorly, it is very advisable to make a counter-opening in the integument, and to introduce a tent to secure the external evacuation. When the integument has become very thin for a great distance, and gangrene is threatened, or when the skin only remains in the form of several bridges between scattered perforations, division of these seems to be required in order to leave the cicatrix as small as possible.

2. Acne Ciliaris—Solitary Pustule of the Border of the Lid.

Symptoms.—*The disease is characterized by the appearance of circumscribed inflammatory points, which push forward the outer lip of the lid, in roundish, circumscribed nodules, and generally suppurate.*

These acne nodules are connected to the sebaceous follicles, and are therefore found on the outer lip of the lid, which is occupied by the cilia, or in its immediate vicinity. They are more frequently seen on the upper, than the lower, border of the lid, because there are not so many cilia and sebaceous follicles on the latter. There is generally but a single nodule, but occasionally several are developed at once on various points of the border of the lid.

The isolated nodules generally reach the size of a pea. They lie in the subcutaneous tissue, but are intimately connected with the tense and often deeply-reddened integument of the border of the lid, which is occasionally hot to the touch. They may be somewhat pushed over on the tarsal cartilage. On the rounded summits cilia shoot up in varying number. Between the bases of the cilia, only an increased exfoliation of the epidermis is perceived in the beginning of the affection, or small crusts of dried sebaceous material are formed there. Subsequently, on the vertex of the nodule, a suppurating point, or a real pustule, is very often developed, when the pus breaks through the epidermis.

If the nodules of acne are very quickly developed, extensive inflammatory œdema is apt to occur; occasionally the lids swell throughout their whole extent, just as if a large abscess were about to be formed. The swelling is then generally very sensitive, and exceedingly painful.

Causes.—Acne ciliaris appears at every time of life, in both sexes, and under the most different conditions. It generally occurs without any evident external cause. In other cases, however, some kind of an injury of a mechanical, chemical, or physical nature, is the exciting cause. Want of cleanliness, much rubbing and wiping the lids, the formation of crusts and excoriations on the edge of the lid, when a conjunctival catarrh exists, are especially to be mentioned in this respect. It seems as if the irritated condition of the integument thus excited were continued by preference on the sebaceous glands.

Persons who are very much inclined to acne, whose skin feels very smeary, and is thickly covered with *comedones*, are most frequently affected with pustule of the lid-border. Especially in early life, during the period of puberty, such persons are very much inclined to this affection, so that they often have to contend with it for months and years. Even unapparent irritations, wind, smoke, and an abode in dusty localities, straining the eyes, slight excesses in venery, in eating and drinking, also the use of certain kinds of food and drink, e. g. of cheese, pickles, wine, &c., lead almost invariably to the development of one or more acne nodules. This predisposition, just as in acne of other portions of the integument, is probably founded in an abnormal property, or in a too great consistency of the glandular secretion. A

thick secretion is evacuated externally with difficulty, the mouth of the glands stops very readily, the sebaceous material collects in the latter, stretches its walls, and becomes rancid, and thus acts as a mechanical and chemical irritant. It then only requires a slight irritation to set up an inflammation.

Course and Results.—Each acne nodule is developed in an acute form. It reaches its hight in a few days, and then rapidly advances to its termination. The affection is not unfrequently very tedious. When the predisposition to the disease exists, one nodule shoots up after the other, and passes through all its phases. The acne nodule may recede at any stage of its development, and disappear by resorption, without the occurrence of suppuration. Exceptionally it becomes indurated (*acne indurata*), and then exists for months and years as a roundish, painless tumor, ranging between the size of a hemp-seed and that of a pea. It lies in the sub-cutaneous tissue, and is firmly united to the integument of the margin of the lid, generally suppurates, and the pus is evacuated either through the canal of exit of the gland, or breaks an opening through the lid externally, generally in the vicinity of the mouth of the hair-follicle, on which the epidermis has been previously broken by a pustule.

After the evacuation of the pus the nodule collapses, and generally all trace of it has disappeared in a few days. Yet some hypertrophy of the sub-cutaneous tissue often remains, and in case there is a particular predisposition to the disease, and the acne nodules occur often and on the different parts of the lid margin, it may become calloused. Blepharitis may in this way occur secondarily, the sebaceous glands and their surroundings being finally all involved in the affection.

In rare cases, actual ulcers occur on the situation of the acne pustule. These become deep, and when slow in healing, leave small radiate cicatrices, which may change the position of the cilia. The hair-follicle is then not generally affected. Yet their suppuration, with permanent loss of the cilia, has been observed.

It is well to remember, that secondary syphilitic nodules occur on the edges of the lids, which may simulate an efflorescence of acne, and if anti-syphilitic treatment be neglected, extensive losses of substance may be caused by gradual ulceration.

Treatment.—We should attempt first to overcome the predisposition to acne, or at least to weaken its efficacy. But if the disease has already occurred, the proliferation of tissue should be checked, and the evacuation of the morbid product favored.

The most careful cleansing of the lids, with the assiduous keeping away of all possible exciting causes, will best fulfill the first indication. When there is any tendency to the affection, the eye-lids should be washed several times a day with a piece of fine cotton cloth dipped in soft water. This prevents the collection of secretion, which favors the stoppage of the mouths of the follicle.

It is also well to draw the lashes through the fingers from time to time, to remove the cilia, which will soon fall off. In the evening, before going to sleep, the lids should be softened with simple cerate or the like.

If an acne nodule be already developed, if there is great severity of the inflammatory symptoms, deep redness, great heat, and severe pain, cold applications will do the best. In other cases we may safely do nothing, or confine ourselves to smearing the edge of the lid with fat. If the presence of pus is already manifest, and if the great tension and pain of the part demand assistance, a small incision is the best treatment. In acne indurata, a weak ointment of iodide of potassium sometimes does service. In ulceration, the remedies in use in the ulcerative form of blepharitis should be used.

3. Blepharitis Ciliaris—Confluent Pustule of the Border of the Lid.

Symptoms.—*This affection is characterized by inflammatory redness and swelling of the edge of the lid, especially of the outer lip. The border of the lid is covered with yellowish, epidermis-like scales, or true scabs, which stick the cilia together like a little brush, and adhere more or less firmly to the epidermis.*

1. The symptoms vary to some extent, according to the degree to which the affection has developed.

a. In the secretory form the redness of the edge of the lid is very striking, but the swelling is not so. The epidermis appears very thin at this point, so that the hyperæmic corion appears red through it.

Thin epidermoid scales are constantly collected between the lashes, interspersed with small granules of dried glandular secretion.

At times, also, large patches of a fatty epidermoid mass are seen, which surround the base of several lashes, and are continued like a sheath upon the hairs, uniting them in bunches. They evidently are rooted in the interior of the hair-follicle itself, coming out from this.

b. The hypertrophying form is especially characterized by a considerable increase in size of the parts making up the outer lip of the lid. There is also swelling and thickening of the integument and the loose tissue surrounding the hair-glands. The outer lip of the lid, with its immediate surroundings, appears reddened, at times having a uniform, at others an irregular, surface. The integument is infiltrated, and, as long as the inflammatory process shows some activity, it is very tense. Subsequently, as the inflammation declines, it is somewhat more relaxed, even wrinkled, and we may distinctly feel the hard or cartilaginous swelling beneath. On the surface we find extensive epidermoid patches, and crusts of dried, pus-like, sebaceous material, which cause the lashes to stick together. Very frequently we find fissures in the epidermis, and actual excoriations under these patches and crusts. These bleed readily, and are rapidly covered with fresh crusts. Points of suppuration and true acne pustules also shoot up from time to time on various parts of the border of the lid. In case such collections of pus constantly arise in great number, the affection gradually becomes an ulcerative blepharitis ciliaris.

c. A bright or dark redness, puffiness, and thickening of the border of the lid, are also constant symptoms in the ulcerative form of inflammation of the glands at the edge of the lid. When the cleansing has been neglected, the outer surface of the edge of the lid appears covered by dense yellowish-brown crusts of dried pus, which are perforated here and there by cilia, sticking to each other. Some of these are adherent, others again are loose, since fresh pus, often mixed with blood, collects under them. When there is a free secretion of pus, this is sometimes exuded through the fissures and cracks occurring in the scabs. When these scabs are removed, the outer lip and the parts adjacent are seen to be covered by an extremely

delicate membrane. In many places, however, it is excoriated and bleeds readily, and not unfrequently is traversed by little furrows. Here and there we may find suppurating points or pustules, while ulcers are found on other more numerous places. These penetrate more or less deeply, secreting thin pus, often streaked with blood. They have a very irregular, jagged base, and the same kind of edges. They are not unfrequently covered with granulations, and are generally perforated in the center by one or more cilia. These often hang loosely to the follicle, may be easily drawn out or fall out of themselves, quite an amount of pus being evacuated at the same time. In severer cases, and particularly those which have existed for a long time, these ulcers are often so numerous that they run together for some distance, while their base always sinks more deeply in the tissue of the edge of the lid, and destroys the parts there. The outer lip then appears as if gnawed, by very irregular losses of substance. At times it is even entirely wanting, and instead of it is seen a kind of groove or furrow, with jagged edges, out of which often only a few distorted cilia grow, and on whose base irregular radiated cicatrices are seen.

2. In a more acute form, as well as during exacerbations, a congestive œdema often arises. This often confines itself to the zone, next to the outer lip of the lid. The latter then appears as a dense, deep-red swelling. This œdema often extends over the whole lid, and causes this to swell greatly. Then pain, with or without photophobia, is quite a common symptom. If the severity of the process decreases, the œdema generally recedes. The subjective symptoms are also less decided. There only remains great sensitiveness to any kind of an injurious influence, and itching, burning, biting sensations in the crust-covered and excoriated edges.

These latter symptoms are frequently, however, to be referred, to a great extent, to the affections accompanying the blepharitis. There is generally also some conjunctival catarrh. In case it lasts some time, trachoma in all its phases is also a frequent accompaniment. Herpetic disease is frequently united to it, and from the frequency of the attacks becomes very troublesome and even dangerous to the eye. Besides this, the tarsal glands often participate. We often find hordeoli in connection with blepharitis ciliaris.

Sometimes spawn-like granules, similar to the trachomatous ones, are found on the mouths of the tarsal glands, in the process of proliferation. Sometimes they are so numerous that they slope off on opposite sides, and cause the inner lip to appear nodular. Exceptionally, an inflammation of the lachrymal sac is added to this.

Causes.—These, in accordance with the nature of the affection, are not different from those of acne of the general integument. In blepharitis ciliaris, also, we have reason to believe in the existence of a predisposition to the disease, but it is also caused by an abnormal glandular secretion.

Want of cleanliness, smoke, dust, wind, straining the eyes, &c., are here exciting causes, as well as in acne ciliaris discreta. In rare cases, body-lice, or the common lice, are the exciting cause of blepharitis ciliaris. (*Himly*, *Lawrence*, *Steffan*.)

Fungous growths are also said to occur in the hair-follicles, and to be an important cause of blepharitis ciliaris. These fungi are said to be very much like those of *favus*. They have, however, rarely more than one or two branches. They have been found with thick flakes of epidermis, as a rigid mass, surrounding the shortened and pointed, but not swollen, hair-bulb, within the sheath. The hair may generally be drawn out without pain. Blepharitis thus caused is said to be very obstinate, recurring frequently, accompanied by pustular and crust formations. It finally leads to atrophy and complete loss of the cilia, as well as to distortion of the edge of the

lid, with ectropion. It is undoubtedly contagious, and is generally found in several members of the same family. (*Ellinger.*) Recent examinations have not confirmed the existence of fungi. (*Schiess-Gemuseus.*)

The disease is often secondarily developed, in the course of a conjunctivitis. When there is a predisposition, the process may be continued directly upon the lid-glands; or, on the other hand, an exciting cause may be the formation of crusts on the orifices of the hair-follicles. The acute exanthemata, particularly small-pox, eczema, and impetigo, have some influence in causing the disease. In case these exanthemata localize themselves on the lids in the form of numerous efflorescences, a blepharitis ciliaris often remains, after the constitutional disease has run its course. This is the same, in all its characteristics, with acne ciliaris, and can not be distinguished from it.

Course.—Blepharitis ciliaris is a decidedly chronic affection, which may exist for months or years. In some cases it is an habitual disease, until advanced age Exacerbations are then generally interchanged with remissions. The latter are often so complete, that there is actually no inflammation while they last, and only the consequences of the preceding inflammation remain. Yet the slightest injurious influence is sufficient to set up the inflammation, and to continue it for weeks. These exacerbations often appear periodically without any recognizable exciting cause, at certain seasons of the year; for instance, in the spring.

Results.—1. When the predisposition is not too great, or when it is completely subdued in course of time, and the patient is appropriately managed, blepharitis ciliaris often gets well spontaneously. Thus, for example, we by no means unfrequently see an inflammation of the glands at the edge of the lid, which occurs during the beginning of puberty, and disappears in more advanced life without any treatment. But whoever has decided expectations of such a result will be often bitterly disappointed. We may properly assert that blepharitis ciliaris requires a careful treatment, if we do not wish it to be protracted, and to finally cause incurable and extremely unpleasant results. With a careful method of treatment, and appropriate condition of the patient, the absolute or relative cure is generally easy. Yet, in persons very much predisposed to the disease, the relapses are not unfrequent, and in some cases the disease obstinately resists all methods of treatment, or is only at intervals somewhat alleviated.

The severity of the process and the previous duration of the disease are of slight importance as to the probability of cure. Sometimes the secretory form of the disease resists all treatment, or always returns, while, on the other hand, long-existing and far-advanced cases of hypertrophying or ulcerative blepharitis often yield completely, in an astonishingly short time, to a proper treatment. Yet the severity of the disease and its previous duration greatly influence its possible consequences.

2. Thus, when hypertrophic blepharitis ciliaris has lasted for a long time, a callous thickening of the edges of the lids, *tylosis* or *pachyblepharosis*, readily occurs. The connective tissue around the hair-follicles increases in amount, in consequence of the inflammatory proliferation. It thickens at the same time, and thus forms a callus. This puffs out the edge of the lid like a pad, and rounds off, or completely obliterates the outer lip of the lid. This swelling is quite hard to the touch, often nearly cartilaginous. The surface is sometimes smooth, again irregular. The integument of the lid is stretched over it, often considerably thickened, and more or

less reddened. In consequence of the distention which the zone of exit of the cilia undergoes from the less sensitive tumor beneath, it appears broadened. Then it often seems as if there were newly-formed hair on unusual situations, especially on the distorted surface of the edge of the lid (*distichiasis.*) Between the lashes, epidermoid scales, and often rigid flakes of horny glandular secretion, are found, which cause some of the cilia to stick together.

We find, in the rigid tissue of the calloused edge of the lid, a friable and gritty substance, together with degenerated connective tissue. These are the remains of the hair-follicles, which have been distended and destroyed by proliferation. They are sometimes quite large. They then form, as it were, the nucleus of a tumor of thickened connective tissue. The irregularity of the edge of the lid is caused by such tumors. The subtarsal muscle is probably destroyed by atrophy in the tylotic edge of the lid.

3. The hair-follicles themselves often participate in severe and long-standing inflammation of the glands at the edge of the lid. They generally atrophy and are entirely destroyed. The border of the lid then appears completely bald, or is so at intervals (*partial* or *complete madarosis*). Occasionally only the hair-follicles, and with them the cilia, deteriorate, and then assume the character of the first growth of hair, become thin and devoid of pigment, are fissured in the bulb, so that two or more proceed from one follicle. They are curved in different directions, and are turned in upon the cornea (*trichiasis*).

4. The ulcerative form of blepharitis ciliaris leads at times to tylosis, more frequently to madarosis and trichiasis. Cicatrices from the ulcers are also much to be feared. They are always radiated, are irregularly drawn together, and give a false direction to the adjacent cilia. At times they unfortunately bend these inward, and thus easily cause extremely injurious effects.

5. In cases of very long existing blepharitis ciliaris, particularly the ulcerated form, not only is the edge of the lid distorted, but the external skin of the lid is also frequently shortened, since the latter on the one hand takes a direct part in the inflammatory process, on the other hand, however, is maintained in a state of irritation by the tears which constantly overflow on account of defective conducting power in the lachrymal passages, and finally shrinks. The consequence is that the zone of the tarsal conjunctiva nearest the edge of the lid is turned outwards over the edge of the cartilage, and becomes visible as a deep red, generally velvet-like, rough edge upon the border of the lid, from one to several lines wide. The inner margin of the lid, together with the punctum, is then everted and can no longer be distinguished from the external margin occupied by a few lashes. Both come together in a single, somewhat irregular line, which is formed by the edge of the external integument.

Treatment.—We should remove and keep away all injurious influences which may excite and keep up the disease, especially all impediments to the removal of the glandular secretion. We should then oppose directly the proliferation of tissue, and finally modify the character of the secretion. We should also assist the retrogression of the disease and the absorption of the newly-formed elements, which, being in the process of higher formation, may cause a degenerative hypertrophy of the edge of the lid.

1. The first indication arising from the cause requires a proper care of the eyes. Without this, all treatment is generally of no avail.

Occasionally river-bathing, and, still more, sea-bathing, has a good effect in obstinate inflam

mation of the glands at the edge of the lid, especially in persons having a very delicate skin and excitable nervous system.

2. A second indispensable requirement for any effect from treatment, is to keep away dried glandular secretion from the edges of the lids, and to prevent excoriations.

a. As soon as any kind of epidermic scales or actual crusts are seen on the edge of the lid, they should be removed. This should not be done by rubbing the lids; the patient will be easily induced to this by itching sensations, and excoriations are readily caused. These excoriations are quickly covered by lymph, which dries in a scab, and makes the matter worse. The secretion should be first softened, and then carefully removed with charpie. The remainder is either removed with a stiff camel's-hair brush, or by drawing the cilia between the thumb and fingers. It is well, at the same time, to exercise a slight traction on the lashes, in order to remove those which have become loose, because they are as irritating as foreign bodies, and they also render difficult the separation of the glandular secretion by narrowing the opening of the follicle.

Such a cleansing is particularly necessary in the morning. When insufficient care is taken, large crusts collect and completely close the lids. But cleansing is also necessary during the day. It should be repeated as often as the dried secretion is seen on the edge of the lid.

Fomentations, with clear, lukewarm water, used with clean, soft linen, forms the best method of softening the crusts. The water should contain as little of the salts as possible. For this reason distilled water is to be advised.

The use of lukewarm decoctions of marsh-mallow, &c., has been much recommended for this purpose. Cataplasms of boiled rice, of linseed-meal in mallow-tea, are not less recommended. Some pencil the edge of the lid with warm milk, in which a little piece of butter has been dissolved, and then bathe the parts with lukewarm water until the desired purpose is attained.

b. After the edge of the lid is thoroughly cleansed and dried, the new formation of crusts should be prevented or hindered, by smearing the part with fresh fat, or with a very weak ointment of the yellow oxide of mercury (one half-grain to one grain to the drachm of the vehicle). This should be done just before retiring, the crusts collecting mostly at night. In slight cases this is often sufficient to cure.

3. In the hypertrophying and ulcerative forms of blepharitis ciliaris more irritating remedies are necessary. The ointment of the yellow oxide of mercury is most to be recommended, one to two grains to the drachm of the vehicle, used morning and night.

The long well-known Scarpa's ointment is less reliable:

℞. Hydrarg. rub. oxid.
Extract. Saturni aa. gr. 1½.
Ungt. simpl. dr. 2.
M. Ft. ung.

The white precipitate has also been long esteemed, four to six grains to the drachm. Oxide of zinc and alum, in the form of an ointment, are less frequently used. The former, in an impure condition, forms one of the ingredients of the famous Janin's ointment:

℞. Tutiæ præp.
Boli. armen. aa. dr. 1.
Merc. præc. albi dr. 1-2,
Ungt. simpl. dr. 2.

This is especially recommended in very chronic cases occurring in old persons.

In the use of these remedies we should see that they come in immediate contac with the edge of the lid and the openings of the follicles, and therefore the brus should be introduced between the bases of the cilia. The irritation following th application only requires treatment when it is very great, and then we may emplo cold compresses to subdue it. If this is not sufficient to remove the irritation, i the pain continues for hours, in spite of their employment, and if, besides, grea redness remains, or if the edge of the lid swells greatly, it is well to use weake ointments.

When the ointments have little effect, or are not well borne, a strong solution of nitrate of silver often does excellent service, even in very obstinate and old cases. This is placed on the closed eyelids once a day, with a camel's-hair brush, and the excess washed off with water. Just as an ointment, it should act especially on the openings of the hair-follicles and upon any excoriated spots, the pencil being introduced between the individual cilia.

Instead of the lunar caustic, the sulphate of copper may also be employed. Painting the ulcerated edge of the lid with a flat, broad crystal is said to do good service in connection with lukewarm poultices (*Mooren*).

Suppurating points and pustules should be evacuated by the knife or pressure, before the use of the irritants. In isolated or connected ulcers, if their base be very irregular, and the secretion is of an unpleasant character, but especially when they are much granulated, we do well to use the mitigated nitrate of silver, cauterizing each ulcerated point. If the condition is improved, we should then pencil the part with strong solutions, and subsequently use ointments.

Many recommend to pull out all the lashes previous to cauterizations with nitrate of silver (*Quadri*). In case formations of fungus on the hair bulbs keep up the inflammatory process, continual depilation may be of advantage, otherwise it is generally superfluous. In some cases of very obstinate blepharitis, a cure or improvement has been obtained by cutting through the skin of the lid, along the external margin, and thus endeavoring to cause degeneration of the bulbs of the lashes (*Stavenhagen*). In a case of inveterate blepharitis ciliaris, existing for many years, and resisting all treatment, which had already led to cicatricial knotty deformity of the edge of the lid and to degeneration of most of the cilia, a rapid cure was effected by removal of the layer of hair bulbs in the manner usually employed in trichiasis.

Especial efficacy was formerly attached to the white precipitate in the form of an ointment. It was used either pure, four to six grains to the drachm of the vehicle, or combined with tar:

℞. Merc. precip. alb. gr. 4–6.
Picis. liquidis. ʒ i.
Cerat. simp. ʒ i.
M.

It is used two or three times a day. This remedy has certainly no advantage over the ointment of the yellow oxide. Penciling the ulcer with tincture of iodine seems to have no especial advantage.

4. If blepharitis be accompanied by conjunctival catarrh, besides the ointment, the remedies in use in the last-named affection should also be used. In long-existing blepharitis, any relaxation or roughness of the conjunctiva demands especial notice. These require cauterizations, as in trachoma. If caustics are not used, the blepharitis is apt to resist all treatment.

5. **In severe tylosis**, such as not unfrequently is left after ancient hypertrophic blepharitis, very excellent results are produced, in some cases, by fastening a bunch of charpie, dipped in a strong solution of nitrate of silver, on the closed lids, by means of a flannel bandage, and wearing it from eight to fourteen days.

Some authors recommend the production of a slough with nitrate of silver in substance, in the integument covering the swelling, and, at the same time, pulling out all the cilia; others expect relief from the use of cataplasms in connection with iodine or mercurial ointment. Fomentations with an ointment of the dilute iodide of mercury, one-third to one-half grain to the drachm of ointment, are also recommended.

6. **Madarosis** is incurable. The eyes should be protected by dust-spectacles, protecting spectacles, &c.

Authorities.—*Himly*, Krankheiten und Missbildungen, &c. I. Berlin. 1843. S. 241, 244.—*Stefan*, kl. Mntbl. 1866. S. 43.—*Lawrence*, *Mackenzie*, Traité d. mal. d. yeux. traduit p. Warlomont et Testelin. I. Paris. 1856. P. 322.—*Quadri*, ibid. S. 200.—*Ellinger*, Virchow's Archiv. III. Bd. S. 449.—*Schiess-Gemuseus*, ibid. 37. Bd. S. 132.—*Arlt*, Die Krankheiten des Auges. III. Prag. 1856. S. 351, 356.—*Stilling*, kl. Monatbl. 1869. S. 198.—*Sämisch*, ibid. S. 339.—*Mooren*, Ophth. Beob. S. 45.—*Stavenhagen*. kl. Beob. S. 21.

4. Blepharitis Tarsalis; Hordeolum—Stye.

Symptoms.—*Stye is a swelling of a tarsal gland. This is filled with a substance resembling pus, and occurs with inflammatory symptoms. The tumor is firmly seated in the thickness of the lid itself, and the integument may be distinctly moved over it.*

The swelling varies in size from that of a millet-seed to a bean. It is generally roundish or oval in shape, has quite a smooth surface, and is somewhat elastic. It is hard to the touch.

Styes are easily recognized on the outer surface of the lid, but on the inner it is more difficult, on account of the thickness of the cartilage. It is only when the lid is everted, and the cartilage with the conjunctiva placed on the stretch, that we may detect the tumor. The pus-like contents are seen through its coating, causing it to resemble a gray or yellow spot, plainly distinguished from the deeply-reddened conjunctiva.

Internal hordeola are only seen externally, when they are quite large. They are, however, very distinct on the inner tarsal surface, where they are easily recognized by their color, which is yellow, like pus.

When the lid is everted, they occasionally press out the palpebral conjunctiva in the form of flat, yellow vesicles, having a thin coating of roundish, oval, or even pedunculated shape.

Styes which occur in that part of the gland lying without the cartilage, push out the portion of the free border of the lid, the conjunctiva, and the intermediate piece of the inner lip, in a round projection, while the outer lip of the lid maintains its normal shape, position, and generally its mobility. The peripheral hordeolum is thus distinguished from the solitary pustule of the border of the lid. A suppurating point is generally found at the summit of the tumor. Its position generally corresponds to the opening of the affected gland. It then appears like a nipple, as it were, on the rounded-off inner lip, and, on pressure being made upon it, evacuates a portion of the purulent contents.

Causes.—These are the same as those of true acne. Hordeolum is nothing more than a pustule of the tarsal glands.

The disease is very often secondary, in consequence of the continuation of an inflammation from the conjunctiva upon the cartilage. Hordeoli are often complications of very old catarrhal conjunctivitis, but particularly of inveterate trachoma. They then appear in great numbers, one immediately after the other. They continually recur, and finally lead to degeneration of the cartilage and deformity of the lids.

Course.—Stye generally occurs with very severe inflammation, often even with decided fever. The affected lid and conjunctiva are very red, and swell so much that the glandular tumor is completely covered. Very severe pain generally occurs, and not unfrequently photophobia and lachrymation.

The affection reaches its highest point in a few days, and advances to its termination just as rapidly, or perhaps the inflammatory symptoms decrease, are limited to the immediate vicinity of the affected *acinus*, but the stye itself becomes chronic. In other cases, the hordeolum occurs with scarcely any noticeable symptoms. It grows for months, and sometimes with exacerbations and remissions, until at last it gradually proceeds to a termination.

Results.—1. Stye is not unfrequently removed by absorption. This occurs more easily in recent hordeola and those which have occurred rapidly, than in the opposite class of cases. Yet sometimes hordeola are absorbed, although very slowly, which have existed for months, and have already become *chalazia*.

2. In the greater number of cases, hordeolum evacuates its contents, and thus goes on to cure in the quickest way. The evacuation occurs often through the canal of exit of the gland, either spontaneously or by the aid of external pressure. This occurs most frequently in peripheral hordeola, less often in those which are internal or external, especially when they are situated far from the edge of the lid. The tumor sometimes opens in the conjunctival sac; one layer after the other of the inner wall of the abscess being involved in the disease, it becomes relaxed, deliquesces into pus, and finally a suppurative opening occurs. In internal hordeolum, such an opening into the conjunctival sac is the ordinary result. Peripheral styes are most frequently evacuated in this way. An internal opening is more rarely observed in external hordeoli, the tarsal cartilage being too thick to allow it. If the evacuation be nearly complete, the cavity of the abscess generally closes by a cicatrix; but in not a few cases, the disease does not terminate when evacuation occurs. The proliferation of tissue still goes on in the walls of the cavity. Yet the morbid product is not generally pus, but rather a gelatinous material, which fills the somewhat contracted cavity, and projects in little lumps from the opening, giving it the character of an unhealthy and often deep ulcer, not unlike a chancre. This is embryonal connective tissue with neoplastic vessels—an over-developed cicatritial mass, whose superficial layers still excrete pus. Occasionally this neoplasia is somewhat thicker and more vascular from the beginning. It has the appearance of exuberant granulations, which grow over the perforation. In rare instances large tumors are thus formed, which exist for weeks and months, keeping up the suppuration, but at last shrink and leave behind a small, tendinous cicatrix.

The pus rarely breaks through externally. This occurs most frequently in peripheral styes; in internal ones, scarcely ever; in external, only very exceptionally. External hordeolum has the very same tendency to evacuate itself. It becomes distended in a direction toward the integument more and more, drawing one layer after another into the process, and causing them to deliquesce. Here and there the pus may be diffused in the submuscular tissue, and then absorbed. In by far the greater number of cases the pus remains encapsuled in the manner just described, and the morbid process ceases much before the inflammation has extended to the integument.

It is of great importance, in this respect, to note that the moment when the abscess has overcome the resistance of the cartilage, and a looser tissue opposes its distention, the pressure exercised upon the contents is immediately lessened, and the conditions for resolution are much more favorable.

As soon as the inflammation recedes, the tumor also lessens. Not only the contents of the stye, but also its walls are absorbed to some extent. The absorption

COOPER MED. COLL.
SAN FRANCISCO, CAL.
This book is not to be removed from the Library by any person or under any pretext whatever.

may be even complete, and in a relatively short time no trace of the tumor be left. Again, it not unfrequently occurs that, sooner or later, there is a relapse. The hordeolum again swells out, but again recedes in part, again growing, &c., until finally, months after, the morbid process comes to a close in one way or the other. But generally, under such circumstances, the hordeolum is changed into a so-called chalazion.

3. Chalazion is distinguished from hordeolum only by the disappearance of the symptoms indicating inflammation, especially the hyperæmia and sensitiveness. It is a hordeolum in which the proliferation of tissue has somewhat receded, or at least is no longer plainly seen, and which has become, to a certain degree, permanent. There are no marked changes, except at long intervals. As has been said, this results by far the most frequently in external hordeolum, because these are evacuated with the greatest difficulty, and their complete resorption does not easily occur. Under unfavorable circumstances a peripheral, and even an internal, hordeolum, may become a chalazion. In accordance with this, not only the situation but the shape of the hordeolum varies. External hordeola often appear as longish oval elevations, which project from the anterior surface of the cartilage with a slight convexity. In other cases they are generally roundish tumors, varying in size between a pea and a bean, rising abruptly from the anterior wall of the tarsal cartilage, and resting flatly on this, or by a peduncle. They are thus, as well as by the mobility of the integument, distinguished from sebaceous tumors over them, which sometimes arise in the sub-cutaneous tissue of the lids.

Internal hordeola seldom acquire any considerable size. They always have a flat surface, from the pressure which the lid itself exerts upon them. Occasionally we find an internal chalazion, whose base appears pedunculated, the vesicular covering being curved inward, and forms a groove, on account of the lessening of the contents of the cavity. Peripheral chalazia seldom become larger than a grain of pepper or a small pea. They are generally roundish; they push the cover of the lid somewhat outward, and cause the blunted inner lip of the lid to project like an arch.

The metamorphoses, by which a hordeolum becomes a chalazion, affect not only the envelope, but also the contents of the tumor. The inflammatory swelling decreases somewhat with lessening of the hyperæmia, and with resorption of a portion of the inflammatory product, but it markedly increases in thickness, and finally changes into a tendinous capsule. This has a smooth inner and an externally rough, villous surface, by which latter it is intimately connected to the loosely-woven adjacent layer. In internal and external hordeoli, the tendinous capsule is united to the cartilage at the base of the tumor. It passes immediately over into the latter, and thus marks off a piece of cartilage, which forms the wall of the cavity on that side. This piece of cartilage is not unfrequently thinned, often so much so that, even in external hordeola, the contents of the cavity glimmer through the tarsal conjunctiva with a grayish or yellowish color.

In peripheral chalazia, the cartilage of course does not form a part of the capsule. This is completely neoplastic. It closes the canal of the affected tarsal gland, and may cause its obliteration. If the chalazion is situated near the inner angle, the lachrymal canaliculi may be endangered in the same manner.

The contents of the chalazion often maintain the consistency and appearance of pus for a long time, for weeks and months. But generally they acquire more and more the character of granulation tissue. (*Virchow.*) It is changed to a thick gelatinous mass, which is generally streaked with blood, and mixed, more or less abundantly, with cellular elements. Finally, however, it thickens to a friable, fatty, calcareous mass, in which epithelial scales, and, more rarely, larger concrements, are found (*atheroma*). This development is often united with marked decrease in size. The chalazion falls inward, and may become so small that it is only perceived on

close examination of the lid, having evidently been cured by absorption. Yet the increase in thickness of the contents of the tumor is not always accompanied by a great decrease in the size. It is replaced by a serous exudation to the same extent that the original contents are lessened, and the walls of the cavity remain distended. In old chalazia we not unfrequently find, as the contents of the large cavity, a turbid fluid, mingled with a great quantity of epithelial cells, free fat, cholestearine crystals, and calcareous granules. Occasionally the contents have become a brownish-yellow, translucent, fatty or briny fluid. The tumor has become a cyst or hydatid.

It is worthy of mention, that the cavity of old chalazia is not always a simple one, but that we not unfrequently find in the interior of the tumor a kind of connective-tissue partitions, making larger or smaller cavities, in which limpid fluid, regressive metamorphosed pus, and often embryonal connective tissue, are found. It appears, in such cases, as if there were several chalazia, which have become developed in adjacent glands, or *acini* of single glands, and which have finally run together.

Treatment.—The treatment of hordeolum is founded on the same principles as that of abscesses in general. We should first prevent the formation of the stye, by attacking the inflammatory process. If we can not accomplish this, we may somewhat retard its formation. In the second place, we should remove the pus as quickly and thoroughly as possible. We do this in order to remove a great portion of the proliferating elements, and, by lessening the tension, to favor resolution of the morbid changes as far as possible. If there are any remains of the inflammatory product, absorption should be excited. In case this proves insufficient, they should be removed with the knife.

1. If the hordeolum appears with severe and extensive symptoms of inflammation, a local antiphlogistic treatment, together with the use of cold applications, is appropriate. In the remaining cases, cold applications can only be sparingly used, and then in order to counteract attacks of pain, burning sensation, &c. An expectant treatment is then indicated. Where the inflammatory symptoms have been not very decided from the beginning, or quickly recede, but the tumor slowly increases in size, without the occurrence of suppuration, where induration is threatened, the employment of warm applications may be of advantage.

2. If a point of suppuration shows itself, the abscess should be immediately evacuated. When the pus collects at the mouth of a tarsal gland, pressure exerted upon the tumor is often sufficient to evacuate its contents. If this does not occur at the first attempt, or if the swelling is very painful, so that a more powerful pressure will not be borne, we may wait one or two days, continuing the treatment indicated under the first paragraph (1).

The evacuation then either spontaneously occurs, or is easily induced. In internal and external hordeola, situated at some distance from the edge of the lid, after the appearance of a point of suppuration, an incision is the best method of bringing the process to a speedy termination, and preventing the transition of the hordeolum to a chalazion.

It should be remembered, at the same time, that in external hordeolum the purulent contents are often perceived on the inner surface of the lid, at a very late period or not at all. It is therefore well, after the inflammation has somewhat subsided, to evert the lid, and, having made it somewhat tense, to make an incision in about the middle of the swelling, even when the pus is not seen.

Immediately after the incision, a great portion of the pus and embryonal connective tissue are generally evacuated. If the evacuation be insufficient, the lid is seized on each side of the swelling by the thumb and index-finger of each hand, drawn away from the globe, and the swelling compressed. Care should be taken that the opening of the incision be between the fingers.

The inflammation always rapidly diminishes after the opening; the pain, which is often very

severe, abates, and a further enlargement of the hordeolum is scarcely to be feared. It is therefore better to open the hordeolum too early than too late, and when the swelling is very large, we may risk the danger of not attaining an immediate evacuation.

3. If the opening has already occurred, there remains nothing for the surgeon to do but to render it more complete. If little lumps of the described gelatinous material or real fleshy growths emerge, and the cavity can not be evacuated by pressure, because it is filled by rigid neoplasia, we may cauterize it with solid nitrate of silver, after having cut off the projecting substance with the scissors. The caustic should be passed deeply into the cavity itself, and the excess be immediately washed off with water. If the granulations then grow, the daily penciling of the neoplasm with tincture of opium is generally sufficient to limit the proliferation, and finally to prepare the way for the closure of the cavity.

4. We should always attempt to evacuate a chalazion, no matter how old it may be. For this purpose a deep and long incision is made in the tumor, beginning at the inner surface of the lid, by entering a lancet or bistoury vertically in the everted lid, enlarging the wound, according to necessity, in the direction of the border. It is only when the chalazion projects very close to the integument, and this is very much thinned over the tumor, that an external opening is more advantageous.

Occasionally we are enabled in this way to evacuate the chalazion by pressure at the first attempt. It then falls together, and a few days are sufficient to cause its disappearance, partly by shrinkage of the walls, partly by resorption. In the greater number of cases the evacuation is incomplete, the chalazion only decreasing to a certain extent. If very much of it remains behind, if the chalazion only sinks in a little, and is, besides, quite extensive, the opening of the wound should be probed daily, in order that it may not close up. It is also well to irritate the inner wall of the cavity mechanically with the probe, or, if the incision was made through the integument, to place in a tent of lint, in order to excite a somewhat active proliferation of tissue, to relax the parts, and to favor evacuation of the contents. A short time is often sufficient to attain the desired end by such a procedure. If the wound does not close again, the swelling decreases markedly, and is very often reduced to a little nodule by absorption and shrinkage, which does not annoy the patient, and disfigures him still less. But when the tumor is imperfectly evacuated, weeks and even months are often necessary to attain this end. We may accelerate this somewhat by penciling one or other of the following salves on the lid once a day: viz., of iodide of potassium gr. x. ad ℥ i. ung. simp., yellow oxide of mercury gr. ½ to the drachm, deutoiodide of mercury gr. ¼ to the drachm. In very large chalazia, a pressure-bandage may be worn for some time.

Some cauterize the inside of the tumor in obstinate cases, destroying any partitions, by introducing pointed bits of nitrate of silver at intervals of several days. Formerly the removal of the chalazion was often attempted, without operation, by applying cataplasms or irritating plasters on the integument of the lid, in order to induce a deliquescence of the contents, and to favor their exit by suppuration. Some drew a silk thread, upon which the ointment had been smeared, through the tumor for this purpose. This mode of treatment certainly often caused suppuration. Yet the evacuation generally remained incomplete, the total deliquescence required weeks, and finally the tumor was found, at the end of the treatment, perhaps as large or larger than before, on account of proliferation of its walls.

5. In internal chalazia, the above-described method is almost always sufficient to remove the tumor; but this is not so in the external, especially when the walls of

the tumor are very thick in proportion to the size of the cavity, the chalazion consisting principally of rigid tissue. In such rare cases, or if the patient wishes at any cost to be free of the trouble, and if the opening leads to no result, the excision of the tumor is appropriate. The operation being very painful, it is done while the patient is under the influence of an anæsthetic.

While one assistant holds the head of the patient, and another is ready with a sponge to restrain the abundant hemorrhage, a small horn-spatula, or the index-finger of the operator, is pushed under the lid, which is tightly stretched by the aid of the thumb, and made to project as far as possible. Then an incision is made parallel with the edge of the lid, on the summit of the tumor, throughout its entire length. This incision should pass beyond the base of the tumor at both extremities. The surface of the tumor is then exposed by dissecting up the integument and the muscle, and a staphyloma-knife is entered at the base and passed through its whole length. (See Fig. 60.) The tumor is thus almost separated from the cartilage. It is then seized with the forceps and completely removed by the scissors. One or two sutures are sufficient to close the wound. The after-treatment consists in applying a pressure-bandage in order to make movements of the lids impossible, and to keep the flap of integument in contact with the surface of the wound.

Fig. 60.

If the tumor is very large, and if it rises very abruptly from the level of the cartilage, we may take out a piece of the integument covering it, by two crescentic incisions, and thus limit the dissection.

Authorities.—*Virchow*, Die Krankhaften Geschwulste. I. Berlin. 1863. S. 211, 221, 236.

Consequences of Blepharitis.

1. Adhesion of the Edges of the Lids—Ankyloblepharon an Blepharophimosis.

Pathology and Symptoms.—Abnormal adhesion of the lids is often acco plished by means of tendinous cicatritial cords or bands, of varying breadth thickness, which extend from the border of one lid to the other, and limit the ope ing of the palpebral fissure according to their length, or the obliquity of th course. These bands are sometimes situated on the inner, sometimes on the ou lip; again, they are firmly seated on the surface of the edge of the lid. They m also arise from, and be inserted in, the integument, and on the palpebral conjun tiva. Sometimes the roots of the adhesions extend even to the ocular conjunctiv in which latter case there is a combination of ankyloblepharon with symblepharo

As a rule, however, the union is effected by a membranous structure, which some cases closes the entire palpebral fissure, or the greatest part of it, but genera merely unites the outer halves of the two edges of the lids, and only exceptiona proceeds from the inner canthus. These membranous structures are usually exce ingly delicate and thin, translucent, often very distensible, and then form, as were, a continuation of the palpebral conjunctiva. In other cases they are ri tendinous, and slightly distensible, of considerable thickness, and unite the surfa of the edges of the lid in their entire extent, and so closely that the palpeb fissure is only indicated by a small furrow between the two lips, which have ci upon them.

The edges of the lid, as well as the tarsal cartilages, are not necessarily shorten in a horizontal direction. This forms the distinction between adhesion or anky blepharon, and blepharophimosis or abnormal narrowing of the palpebral fissure, which the canthi themselves appear approached to each other. This, of cour limits the opening of the palpebral fissure very much.

It is evident that the field of vision becomes narrowed by ankyloblepharon a phimosis, especially in looking in certain directions. It may even be complete covered. Certain forms of ankyloblepharon, particularly those where the bands adhesion are attached to the integument, and favor the turning in of the lids, m thus become very injurious. Blepharophimosis has the same effect.

Causes.—Partial adhesion of the edges of the lids by tendinous bands alwa results from inflammation. The common causes are burns, cauterization, injuri but especially blepharitis ciliaris, if it be accompanied by excoriations, or even ulceration, and if the exposed portions of the two edges of the lids are brought contact by a bandage, or by spasm of the lid, &c.

Membranous bridges may also occur in this way. Yet ankyloblepharon of t latter kind, especially when any great amount of adhesion exists, is generally co genital, and very often combined with other failures in development, such mikrophthalmos.

Blepharophimosis is also generally congenital. It may be secondarily developed from atrophy of the lids after severe trachoma, or extensive loss of substance in the eye-lid, from phthisical lessening in size of the globe, and furthermore, in consequence of cicatrices in the integument in the vicinity of the lids.

Treatment.—It is best to excise tendinous bands of adhesion with the scissors, close to their insertion. When this has been done, care should be taken that the surfaces of the wound do not again unite. To secure this end, we may separate the lids from the globe, and, having dried the surfaces, pencil them repeatedly with collodion. (*Walton.*) For greater certainty, in case of necessity, the patient may avoid sleep the night after the operation, or in case this is not possible, he may be waked often, in order to prevent the consolidation of any adhesions.

Where the adhesion extends into the angle of the lid, and the union is accomplished by a membranous connecting band, the removal of this does not generally effect a cure, even if the surface excised was not very broad, because re-adhesion, beginning at the angle of the wound made, can not be entirely prevented.

If the surface of the wound is very large, on account of a broad insertion of the connecting piece, re-adhesion may also prevent any result from the operation. It is therefore necessary to protect the surfaces of the wound, at least in the angles, by a sort of transplantation of the border of the conjunctival wound. The procedure for this purpose is exactly the same as the second stage of the so-called canthoplastic operation.

Canthoplasty is indicated if the connecting band has a broad insertion on the surfaces of the border of the lid, and is so short that the lips in the region of adhesion are almost in immediate contact with each other. It is, besides, appropriate, in the severer forms of blepharophimosis, especially when it threatens to lead to unpleasant results, or has already done so. It has been recently performed with very excellent results in entropion founded on or complicated with spasmodic action of the muscles.

Fig. 61.

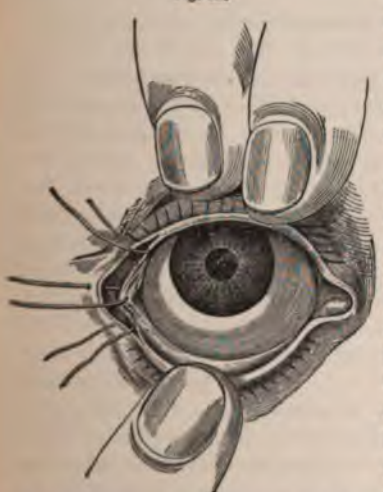

In performing the operation, one assistant holds the head of the patient, at the same time keeping the lids as wide open as possible, while another stops the bleeding. The surgeon then introduces a sharp-pointed bistoury upon a director, behind the external canthus, and causes it to emerge in the vicinity of the orbital border. He then divides the external commissure through, in the direction of the palpebral fissure, i. e. horizontally. Scissors may be used for the same purpose, one blade being laid in front of, the other behind, the commissure. The use of the scissors has the advantage, that the necessary wound is made at one cut. The first assistant now holds the lids widely apart (see Fig. 61), and the conjunctival edge is united to the integument by a suture, closing in the same way the upper and lower sides of the wound. (*Rau.*)

If the conjunctival lip can not be attached at the angle of the incision of the integument without great tension, we may content ourselves with two sutures, one above and below—if necessary, with one. The separation of the conjunctival flap from the parts beneath, or even the dissecting of a flap from the scleral conjunctiva (*Ammon*), transplanting it into the surface of the wound, is scarcely ever necessary, but has, however, been recommended.

Authorities.—*Ammon*, Zeitschrift f. Opht. II. S. 140, Angeborne chir. Krankheiten. Berlin. 1842. Taf. 4, Klin. Darstellungen der Krankheiten und Missbildungen. III. Berlin. 1841. Taf. 3, Die plastische Chirurgie, &c. Berlin. 1842. S. 229, 232.—*Himly*, Krankheiten und Missbildungen &c. I. 1843. S. 94, 100.—*Desmarres*, Traité d. mal. d. yeux. Paris. 1847. S. 29, 36.—*Stellwag*, Ophth. II. S. 896, 800.—*Rau*, A. f. O. I. 2. S. 173, 182.—*Mackenzie*, Traité d. mal. d. yeux. Traduit p. Warlomont et Testelin. II. Paris. 1857. P. 178, 181.—*Walton*, nach Mackenzie. l. c. P. 182.

2. Adhesion of the Lids to the Globe—Symblepharon.

Pathology and Symptoms.—We divide symblepharon into two classes, posterior and anterior symblepharon. In the latter, there is a neoplastic connecting band which unites the lids to the surface of the globe. These connecting bands are generally of loose, distensible, and vascular connective tissue, in which are interspersed thick, tendinous striæ and folds, thus forming a kind of frame-work. Occasionally the tendinous frame-work predominates. Cases even occur where the connecting band consists almost entirely of such rigid, fibrous tissue.

This connecting band generally proceeds from the inner surface of the lid, more rarely from the angles. The latter condition has been called *syncanthus externus* and *internus*. (*Ammon.*) It then extends obliquely upon the globe, and becomes firmly attached to the anterior scleral surface, or to the cornea, or to both at once. It generally has a broad surface at both origin and insertion. It often has cord-like processes, which may be followed for some distance in various directions.

These neoplastic growths have their origin, for the greater part, in the submucous tissue and in the integument. The latter generally becomes wrinkled in a radiate direction, or it may be drawn up like a ball. Some rigid, tendinous cords, however, adhere firmly in the greater number of cases to the cartilage and sclera. In syncanthus internus, the caruncle and semilunar fold are almost always, for the most part or entirely, involved in the neoplastic tissue, and the tendinous bands of the connecting piece are continued not only on the commissure, but also in the deeper-seated aponeurosis and the periorbital tissue.

In shape, these connecting bands often resemble cords or ligaments, which are stretched like bridges from a point on the inner surface of the lid to the globe. In other cases they are membranous, and either extend with a broad surface from the surface of the lid to the globe, or proceed from the palpebral conjunctiva. On drawing back the lid, they resemble partitions, which divide the affected conjunctival portion into pockets. In the greater number of cases, the connecting bands have more substance, and look like fleshy growths, which cover large portions of the inner surface of the lid and of the globe with their insertion. This form is called *symblepharon carnosum*, to distinguish it from *symblepharon membranosum* and *trabeculare*.

There is scarcely such a thing as total symblepharon. It seems as if the moisture from the lachrymal glands had some influence in preventing adhesions in the upper half of the conjunctival sac. Entire adhesion of the lower half of the sac are, however, not unfrequent.

Symblepharon often impairs or entirely destroys the functions of the eye by covering over the cornea. It is, besides, dangerous in all cases, because the connecting band is rendered tense on the movements of the globe, and exerts a traction on the neighboring conjunctiva which may set up a permanent condition of irritation. Finally, it not unfrequently causes changes in position of the lids, particularly ectropion. These changes are either permanent or appear at intervals, in consequence of certain directions of the axis of the globe. They always require artificial replacement.

Causes.—The cause of symblepharon is, in by far the greater number of cases a sloughing of the conjunctiva, produced by burns or the action of caustics. These sloughs generally occur accidentally, from the entrance of sparks or pieces of burning metal into the opened eye, from the explosion of gunpowder in the face, etc. It may be caused also by melted metal, quicklime, sulphuric acid, etc., which spout into the eye, or are thrown upon it.

The caustic alkalies and the acids appear to be most destructive, since they diffuse themselves in the tears, and usually occasion very extensive adhesions, while burns by fire, molten metals, and the like, generally limit their action to the parts near the fissure of the lids, and at any rate do not extend much beyond the point of contact. In burns from lime the circumstance should be taken into consideration, that portions of the cauterizing substance penetrate deeply into the tissue and here cause incrustations (*Gouvea*).

Occasionally, careless cauterizations with nitrate of silver may be the cause of symblepharon. Mechanical injuries of the conjunctiva may also produce the adhesion.

The union is almost always effected by granulations, which spring from the base of the loss of substance. It is clear that such adhesions most easily occur when two parts lying opposite are ulcerated at the same time, as is almost always the case when caustic fluids, etc., enter the eye. But a sloughing of two parts lying opposite is probably not indispensably necessary for the formation of a symblepharon. The contact of a healthy conjunctiva with granulations may render adhesion possible. The connecting bands are always formed afterward, by the movements of the globe and by the consequent stretching of the adherent portions.

Treatment.—When we see the case soon enough, we should endeavor to prevent the occurrence of symblepharon. But if it has occurred, the connecting band should be removed, and the adhesion prevented, or made as slight as possible.

1. In order to fulfill the first indication it will often be necessary to prevent the continual action of a chemical substance, not only by the most thorough cleansing of the conjunctival sac, but also by direct antidotes. This is particularly the case in burns from lime, in which, moreover, not so much acids, as rather solutions of sugar, are said to have proved the best means of treatment (*Lawson*, *Geisler*).

2. In case the adhesion threatens only to occur within a very small spot, near the edge of the lid, it will often suffice, if the patient moves the eye very frequently and vigorously, and if at short intervals of about half an hour the lid be lifted away from the globe, and if the granulating surfaces are lightly touched several times daily with the mitigated nitrate of silver, in order to produce fine sloughs, which effectually postpone the adhesion for a certain time.

But in case the adhesion threatens to involve a portion of the palpebral fold, we can not expect much from such a procedure, and least of all when the two surfaces unite at the base of the fold. The movements upon each other of the two surfaces of the palpebral fold are very slight, or none at all, and they are consequently in permanent contact. Fortunately, small circumscribed adhesions in this position do no great harm. They therefore scarcely justify very severe remedial procedures of any kind. But if the sloughing point is quite large, it is very advisable to evert the lid, and keep it in this position until the ulcer has cicatrized. There is no great difficulty in accomplishing this with the upper lid, the swelling, with the aid of a protective bandage, being generally sufficient to keep the lid

in its position. But it is very difficult to keep the lower lid everted. In consideration of the great danger in which the eye is, we should not then hesitate to cut through the outer commissure. The lower lid then readily falls down, and is easily kept in the position necessary for a cure. There is no difficulty in returning it to the normal position afterward.

This procedure avails most in the case of ulcerations which do not extend into the palpebral fold. In the opposite class of cases the result is always imperfect, but still not to be disregarded. In ulcerations of parts near the inner angle, treatment is rarely, if ever, of very great benefit.

The insertion of a wax or lead plate, somewhat like an artificial eye, may occasionally have accomplished something. But we can scarcely rely upon it, even if the eye, which is very sensitive, will tolerate it. (*Himly*). Still less is to be expected from the insertion of the skin of an egg, instillation of strong solutions of nitrate of silver, of glycerine, &c.

3. In fully-developed symblepharon, the proper method of treatment and its result depend chiefly upon the situation and extent of the connecting piece. Trabeculai and membranous symblephara, if they connect a portion of the tarsal conjunctiva near the palpebral fissure with the surface of the globe, like a bridge, may be sometimes removed. We first dissect the connecting piece only from the globe, and fasten it in the palpebral fissure by a loop of thread until the cicatrization allows the separation of the neoplastic growth from the lid without danger of re-adhesion.

In case this connecting piece is not long enough to hang away from the exposed surface of the globe, a greater tension of the loop of thread is sufficient to keep the lid from the globe. When the surface of the wound on the ball is large, it will be advisable to unite the edges by one or two delicate sutures. If the neoplasia extend upon the cornea, it should be removed with a lance-shaped knife. In this way we often succeed in causing a delicate epithelial opacity on the situation of the thick, tendinous cicatricial mass. If granulations again show themselves, they should be cut down by cauterizations with nitrate of silver, and subsequently by penciling with tincture of opium.

Membranous symblephara of the palpebral fold are sometimes made smaller by cutting them out, and limiting the subsequent reunion by cauterizations with nitrate of silver, and frequently drawing the lid away from the wound.

Fig. 62.

But if the symblepharon extends from the palpebral fold, nearly to the border of the lid, whether it be membranous or fleshy, this last-named procedure is not to be advised. Its success is very uncertain and insufficient. The surfaces always unite again. We may in some degree prevent this, by first removing the adhesion in the palpebral fold, and by securing a cicatrization of the separated surfaces. The symblepharon is thus converted into a bridge-like connecting piece before complete separation is attempted. For this purpose a lead wire is placed through the bridge in the depth of the palpebral fold. It is then left until the parts have cicatrized around it. The best method of introducing the wire is by means of a curved and grooved needle, such as is used in the harelip-suture.

In case of necessity, the wound may be made with a strongly-curved needle, and the wire introduced after it. The ends of the wire are pressed together over the edge of the lid, and twisted on the outer surface. (See Fig. 62.) It is then fastened by strips of adhesive plaster (*Himly*).

On the whole, this procedure is not very trustworthy. The wire often gradually cuts through the intermediate piece, the adhesion again occurs, and in a few weeks we are at the same point at which we began.

Cutting out the symblepharon avails the most (*Arlt*). When the connecting piece is not very broad, in the greater number of cases the result is excellent. In doing this, an assistant holds the head of the patient, and draws the lids away from the globe, so that the connecting piece is placed on the stretch. Another assistant restrains the bleeding.

The operator then carries a curved needle, armed with a silk thread, through the part of the neoplasia next to the cornea. He draws this tightly, and passes a sharp knife through, and divides the connecting piece as close as possible to the surface of the globe, toward the cornea. When a flap is thus formed, it is seized with the forceps, and the remains of the symblepharon dissected away from the globe up into the palpebral fold. When this is done, both ends of the thread are armed with needles, and these are thrust through the thickness of the lid near the orbital border, at the deepest part of the wound. Then, by drawing up the ends of the threads, the connecting piece is so turned about, that, on replacement of the lid, the cicatrized surface of the connecting piece comes in contact with the surface of the globe from which the portion has been excised. (Fig. 63.) The ends of the thread are then fastened on the outer surface of the lid by adhesive plaster, and the edges of the wound of the ocular conjunctiva are united by two or three fine sutures.

Fig. 63.

The after-treatment is the same as after other wounds. On the third day the plasters may be removed. After the cicatrization of the conjunctival wound, the connecting piece may be cut off, if it be heavy and troublesome.

When the connecting pieces are very extensive, and whenever a large part of the conjunctiva, a third or more, is involved in the neoplastic formation, it is well, after detaching the connecting piece, to cut through the ocular conjunctiva in two curvilinear incisions, proceeding from the two edges of the wound, and running upward or downward, as the case may be, and then to draw the resulting quadrangular flaps, previously dissected up, towards the raw surface, and unite them as far as possible by sutures.

The intervening piece detached from the globe can then be thrown inward, and its free border, after removal of all unnecessary cicatricial tissue, be united with the peripherical edge of both conjunctival flaps covering the raw surface by sutures (*Knapp*). Unfortunately the laceration of the conjunctival flaps in wide, raw surfaces is very unfavorable to a healing by first intention, suppuration easily occurs, and with it complete failure of the operation. If a lid be adherent to the globe

throughout the greater part of its extent, the treatment is, as a rule, unsuccessful. Such adhesions, like posterior symblepharon, are still to be regarded as incurable.

In such cases, the cornea is generally very much or entirely covered by thick cicatricial formations, and a restoration of vision is thus made impossible. Sometimes it is of advantage, for the sake of the appearance, to separate the adherent lid enough to allow an artificial eye to be inserted. If this is borne, the surface of the wound sometimes cicatrizes without any extensive reunion, although the cicatrix may become a little elevated from the palpebral fold, and thus render necessary a change in the shape of the artificial eye.

Authorities.—*Ammon*, Plast. Chirurgie. Berlin, 1842, S. 189. Klin. Darstellungen, etc. II. Berlin, 1838, Taf. 6, S. 15.—*Himly*, Krankheiten u. Missbildungen, etc. I. Berlin, 1843. S. 101, 105, 107.—*Stellwag*, Ophth. II. S. 753.—*Arlt*, Die Krankheiten des Auges. Prag, 1851, I. S. 155, III. S. 375; Prag. Vierteljahrschrift XI. S. 161.—*Pagenstecher* und *Sämisch*, kl. Beobachtungen, I. Wiesbaden, 1860. S. 7.—*Makenzie*, Traité d. mal. d. yeux. Traduit p. Warlomont et Testelin. II. Paris, 1857, 178, 182.—*Gouvea*, Arch. f. Augen u. Ohrenheilkde. I. S. 106, 120.—*Lasson*, *Geissler*, Schmidt's Jahrb. 135. Bd. S. 265.—*Knapp*. A. f. O. XIV. I. S. 270.

3. Distichiasis and Trichiasis.

Pathology and Symptoms.—*The common symptom of these two conditions, which are often seen together, is a turning inward of a number of lashes, while the surfaces of the lids are in a normal position.*

1. By distichiasis, or double growth of the lashes, we understand, strictly speaking, the growing-out from the surface, or inner lip of the lid, of scattered hairs, or of those arranged in a second row. The lid is in other respects normal. This condition occurs very rarely, and is then generally congenital. The pseudo-cilia are developed either in children, or at the time of puberty, when the growth of hair on other parts of the body is accelerated. It occurs more rarely in the later periods of life. It is said that true distichiasis is especially found in persons with a very luxuriant growth of hair. (*Vidal.*)

In by far the greater number of cases, the double growth is only *apparent*, and caused by distention of the outer lip of the lid, occupied by the cilia. When the edge of the lid is calloused, it not unfrequently occurs that the zones occupied by the hairs are distended to more than double their normal breadth, and thus isolated hairs, or entire bundles which stand more posteriorly, are separated from the others and turned toward the globe. It then often appears as if new hairs had sprouted up from the peripheral surface of the lid. Such a condition results much more frequently from shrinkage of the tarsal conjunctiva, such as is caused by severe chronic conjunctivitis, especially from diffuse and granular trachoma, old catarrhal inflammation, etc. The false double growth is in such cases united with rounding-off of the inner lip, and is confined to individual parts of the conjunctiva, according to the more or less regular or irregular degeneration of the tissue. It may, however, be extended along its entire length. Cicatricial shrinkage of the border of the lid, after ulcerative blepharitis, has sometimes caused the distortion of single bundles of cilia.

2. In trichiasis proper is comprehended the inversion of the lashes, from their degeneration and distortion.

Most authors consider the lowest degrees of entropion as a form of trichiasis. These are cases in which the inner lip of the lid is partially or wholly obliterated, on account of the tendinous degeneration of the tarsal conjunctiva, or cicatricial contraction. The outer lip, with the cilia on it, is thus brought nearer the globe, or comes in contact with it. The inverted lashes are in accordance with the cause of the affection—sometimes quite normally formed, sometimes like the first growth of hair, thin, colorless, and distorted. In trichiasis, very large cilia are generally found, and with them a great number of fine, new hairs. From two to four of these very frequently spring from a single hair-follicle, and turn in different directions.

The inverted lashes, acting like foreign bodies on the parts within the palpebral fissure, excite unbearable itching and burning sensations in the eye. They are often the cause of severe spasm of the lid, accompanied by photophobia, by which the

lashes are still more distorted, and the edges of the lids actually rolled inward. Inflammation is excited and maintained in the superficial parts of the eye by the continuous mechanical irritation. The conjunctiva, which is often partly degenerated, is very red, swollen, filled with tears and catarrhal secretion. The ocular conjunctiva is frequently hypertrophied. The cornea generally exhibits all the symptoms of partial or total *keratitis pannosa*, and is often accompanied by herpetic efflorescences in different stages, together with ulcers and opacities of the most different kinds. Occasionally the inner parts of the globe are involved in the inflammatory process. The whole globe may have lost its functions, and may even have perished by atrophy or phthisis.

Treatment.—The chief indication is, of course, to remove the anatomical cause of the inversion of the cilia. But inasmuch as in fully-developed distichiasis and trichiasis, this indication can not be perfectly fulfilled, the treatment must be limited to the following:

1. The hairs which turn inward should be removed as fast as they grow. This opposes the irritation which their presence would excite, or it leads at last to atrophy of the hair-papillæ.

2. A proper, or at least harmless, direction may be given to the cilia.

3. The hair-follicle may be destroyed if the other treatment fails.

1. The hairs are extracted by means of cilia forceps. The hair with the bulb should always be torn from the follicle itself, because this structure is most quickly induced to atrophy by repeated injury. The hair should be seized by the forceps close to the mouth of the follicle, and pulled out with slow traction. All the inverted cilia should be removed, and this operation should be repeated as long as new hairs show themselves. It is often very difficult to recognize the very fine hairs. We can generally accomplish the desired end with certainty, if a little oblique light is allowed to fall on the edge of the lid, and if we then bring each point before the illuminated pupil, and thus look the lid over.

This method of treatment accomplishes the most in partial distichiasis and trichiasis, the hair-bulbs actually undergoing atrophy, after continued depilation. We may scarcely ever expect such a result in more extensive forms of the affection. But this method is none the less applicable, in persons very much afraid of the knife, as a provisional treatment, even when there is a total double growth of the cilia, and complete inversion of the hairs on the border of the lid. After the hairs have been taken out regularly for weeks and months, they begin to grow more slowly and sparingly, and also become thinner. While in the beginning it was necessary to remove the hairs daily or every other day, it will now be sufficient to remove the isolated stumps at intervals of from one to two weeks, and finally, in case of necessity, the patient may even remove them himself.

Very recently it has been proposed, as the result of some successful experiments, to remove the cilia, without injury to the form of the lid, by causing suppuration in the follicles by a thread introduced sub-cutaneously. This method is said to have done well, both in partial and total distichiasis and trichiasis. A horn-spatula is pushed under the affected lid, and then an armed needle entered deeply into the lid, beginning at the edge, close to the improperly-turned cilia, thrust on vertically along the anterior surface of the cartilage, and then caused to diverge one and a half to two lines from the outer lip through the integument. When this is done, the needle is again introduced into the wound of the integument, and pushed forward close to the cartilage, parallel to the outer border of the lid, again being emerged in the region of the normal cilia. After the needle is again introduced into the wound of the integument, it is inclined under the muscle in a vertical direction toward the edge of the lid, and there brought out. The thread then describes three sides of a parallelogram, whose fourth side is formed by the outer lips of the lid, and which involves all the inproperly-directed cilia and their follicles. The ends of the threads

are then fastened on the forehead or cheeks by adhesive plaster, and a pressure-bandage applied After a few days the thread may be removed, and, a little later, the bandage (*Herzenstein*).

2. In order to give a proper direction to the cilia, but not to destroy them, a great number of operations have been suggested. All of them, however, accomplish their purpose imperfectly. Less severe methods may be substituted for them, with as good, or better result.

Cutting out small ovoid pieces of integument very near single inverted cilia, or bunches of cilia (*Desmarres*), is an untrustworthy method. The traction which the contracting cicatrix exerts is too little. Moreover, it acts chiefly on the portions of the lid toward the orbital border. This is much more loosely attached to the substructure than the integument of the free border of the lid.

It is certainly safer to resort to one of the methods employed in entropion. (*Fagenstecher.*) These operations, however, only have satisfactory results when our aim is especially to relieve spasmodic muscular action.

Where the lashes are turned inward, on account of smoothing-off of the inner lip of the lid, or on account of great tension exerted on the surface of the edge of the lid by shrinking conjunctival cicatrices, or where they themselves are very much distorted, and are turned irregularly in all directions, it is not sufficient, as in entropion, to place the lid in its normal position. The free border must be really placed in a condition of *ectropion*. This is difficult to accomplish. Added to this, these operations affect the position of the cilia, at the angles of the eye, very little. Trichiasis and distichiasis, however, affect the two canthi by preference.

A kind of transplantation of the outer lip of the lid, and of the hair-follicles beneath, has a great reputation. (*Jäsche, Arlt.*)

It is better to do this operation while the patient is under the influence of an anæsthetic, on account of the great pain it causes, and because of its tediousness. An assistant, who at the same time holds the head, places a horn-spatula under the lid, raises it up from the globe, and causes the edge of the lid to be somewhat everted from the spatula. Then the edge of the lid is divided into layers, for the depth of two lines, with a delicate scalpel (Fig. 62), not continuing the incision into the lachrymal puncta. The posterior layer contains the conjunctiva, with the cartilage and canals of the tarsal glands, and the anterior involves the remaining structures, with *all the hair-follicles.*

Fig. 64.

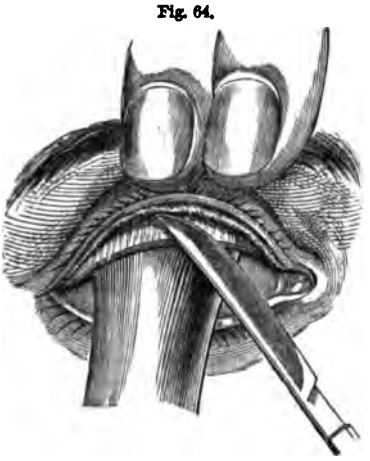

The incision should, therefore, be made close to the surface of the cartilage. Then a second incision is made, one and a half to two lines above, and parallel to the outer lip, completely through the anterior layer, down to the cartilage, and in such a manner that the two ends of the wounds extend beyond the ends of the first incision.

This layer is thus changed into a kind of bridge, to whose posterior surface the hair-follicles are attached, and which is only connected to the lids by the two extremities. When this bridge has been formed, a crescentic incision is made, beginning at the ends of the last incision, through the integument. This is seized with the forceps, and carefully dissected up, without injury to the orbicularis muscle. The size of this flap, whose boundaries are seen in Fig. 64, should be the larger, and have a greater vertical diameter, in proportion as the hairs are turned inward, and the more the skin is relaxed and wrinkled. The crescentic incision is to be closed by one or two sutures. Under the traction of these sutures the direction of the hairs becomes horizontal, or is even turned toward the orbital border. The sutures should be removed on the third day.

Instead of making the crescentic flap, a very similar effect may be attained by grasping the integument with a crutch-shaped forceps, and pushing two or three armed needles through the integument down to the muscle. The ligatures are then tied, and left until thrown off by suppuration. The border of the lid is split, as in the previous operation, but no crescentic piece of integument is cut out.

Fig. 63.

Inflammation often occurs after this operation, and not unfrequently destroys the middle portion or the whole of the bridge of integument, by suppuration or mortification. This operation is useless when, as is often the case, cilia grow inward within the canthi, because it has very little or no influence upon the direction of such lashes. (*Stavenhagen.*)

This disadvantage in the operation is now somewhat recognized, and the necessity is seen for a complete modification of the method. It has lately been recommended to begin with two vertical incisions. (See Fig. 64.) These pass through the integument and the orbicularis muscle, bounding laterally the portion to be transplanted. In complete distichiasis, one incision terminates close to the outer commissure, the other within the lachrymal punctum. Then the lid is to be divided into two layers, as in the previously-described method.

In order to exert a powerful traction on the border of the lid, and thus to separate the hair-follicles sufficiently from the inner lip, an oval piece should be cut from the integument, or ligated by several threads, with the view of causing cicatrizial adhesion. (*Graefe.*)

Fig. 64.

Of course, such a transplantation is only proper when the greater portion of the lashes is in such a condition that we may expect a sufficient protection to the eye, as well as an improvement in the appearance, when they are in a more accurate position. It is more adapted to the upper than the lower lid. There is no great stress to be laid on saving the few lashes of the latter, and the removal of the hair-follicles is a much more certain method.

Success is by no means assured, however, either by one method or the other, although they may be carried out with the greatest precision and care. In apparently very successful cases, the outer lip of the lid often again turns inward weeks or months afterward, while the cicatrix continues to shrink, and the hairs again acquire an improper direction, and irritate the globe. Such an unfavorable result often occurs, when there is progressive tendinous degeneration of the conjunctiva. (*Mannhardt*). It is, in not a few cases, almost impossible to separate all the hair-follicles from the tarsal cartilage in dividing the lid into the two layers, because they are rooted immediately *on* the catilage, or even in its most superficial layer. These folli-

cles are not easily perceived during the operation, even on the most careful observation, especially when the lashes are not of a very dark color. But if the papillæ only remain, the cilia will grow again. Unfortunately, after the displacement of the outer lip of the lid, these do not always come through the old canal; but, as experience shows, they often perforate the fresh cicatritial mass, and finally appear on the border of the incision which divides the tarsus from the hair-follicles.

Such a result can not be guarded against by cutting out or ligating a larger fold of integument. The repetition of the operation affords just as little guaranty. In fact, cases occur where the lids can not be closed in consequence of their excessive or repeated shortening. The lids are then partly open even during sleep, and nevertheless, some cilia irritate the surface of the globe.

3. The removal of the hair-follicles is certainly the most trustworthy method. It is also simpler, and more easily done. Where all four lids require the operation, this is of importance. The great objection which may be made against it, as compared with the transplantation, is the fact that the eye is deprived of its natural appearance and means of protection. But the deformity is scarcely greater in loss of the hair-follicles, than when the lids are left stiff and unwrinkled, as is necessarily the result when a large piece of the integument is cut out or ligated, and the function of the orbicularis is impaired by cicatritial tissue.

There is also not much difference with regard to the protection of the eyes, the closure of the lids being often rendered difficult or impossible, when the traction exerted on the hair-follicles is enough to correct the inversion of the cilia. Besides, it should be considered that, in partial distichiasis or trichiasis, where it seems desirable to preserve the greater number of the cilia, on account of their good condition and regular arrangement, the removal may be strictly limited to the inverted cilia, while a transplantation must, under all circumstances, extend over the greater portion, or the whole, of the border of the lid.

a. For the purpose of partial removal of the base of the cilia, a spatula is placed under the lid, putting the lid on the stretch, and the edge is split into two layers, as before described. (See Fig. 65.) This is best done with a lance-shaped knife, which is entered to the depth of two to three lines between the tarsal cartilage and the hair-follicles.

Fig. 65.

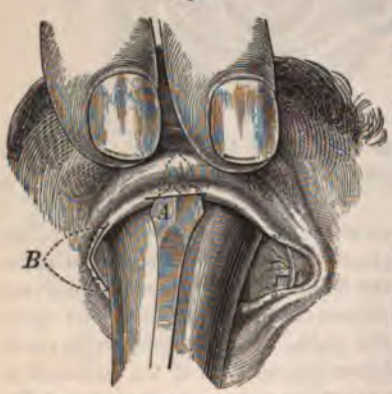

If the knife be not broad enough to include all the inverted cilia, a scalpel may be used afterward to enlarge the wound. Then two incisions are made on the outside (Fig. 65, A) of the lid, which include the affected follicles. A scalpel or scissors may be used for this.

In case the inverted cilia are in the inner or outer canthi, or near them, it is better to make the incision with the lance-shaped knife, without putting the spatula under, the wound being enlarged, if necessary, with the scalpel. (See Fig. 65, B.) The flap thus formed is completely separated with the scissors. The wound is closed by sutures.

Such a shaped incision is only sufficient, however, when the part of the hair follicle to be removed is bounded for some distance on each side by a peripheral

portion entirely devoid of lashes. It therefore answers very well as a supplementary operation, when a total removal has not been entirely successful. If the piece which is cut out be surrounded by cilia, relapses almost always occur, the hairs always being turned inward by the contracting cicatrix.

In order to prevent this, a sort of transplantation of the neighboring part of the outer lip of the lid should be combined with the excision. The incision, dividing the lid into two layers, may be continued on both sides, one and a half to two lines beyond the base of the inverted cilia, and the form given the flap may be varied according to the location and extent of the distichiasis or trichiasis. If the double-growth or inversion of the cilia affects a portion of the margin of the lid, not in the vicinity of the canthi, the incision of the integument should have the shape of a triangle with its apex cut off, its base being turned away from the edge of the lid. (See Fig. 66.) The two converging tips, *a*, separated from the structure beneath by the splitting of the lid, are then united by a suture. For this purpose we may best use delicate silk or linen thread (*fil de Florence*). These should be affixed to the base of the triangle near the angles, and at the same time some traction should be exerted.

Fig. 66.

If one side of a commissure requires the operation, one of the incisions of the flap should be made horizontally, in the direction of the palpebral fissure, down to the incision which splits the lids; but the other is to be made obliquely, upward or downward, as the case may require, through the border of the lid, and then the ends should be united by a crescentic incision (see Fig. 67). The gusset-shaped pieces thus made, *a*, are attached to the margin of the crescentic incision, after the removal of the flap. If there are inverted cilia on both sides of a commissure, there is no horizontal incision, the two boundary incisions pass obliquely upward or downward, and are united by a crescentic incision, on whose base the gusset, *a*, is fastened to the outer lip.

Fig. 67.

When necessary, the spear-shaped wound should be closed by one or two sutures.

The wound generally heals within two to three days. The cicatrix is almost always unnoticed, and its boundaries are only indicated by a slight protuberance of the zone containing the lashes. This does not disfigure the patient. Enough of such operations have been done to allow a decision as to their value. We may safely recommend them from experience.

Fig. 68.

b. The entire removal of the hair-follicles (*Fried. Jaeger, Flarer*) is in some respects the same as transplantation (described in paragraph 2). The

principal difference consists in this, that the bridge, which is formed in the same way, is entirely removed instead of being preserved. A hor is placed under the lid, and the edge split into two layers (see Fig. 62). to begin the incision at the commissure, with a lance-shaped knife, and to it with a scalpel. The integument is then divided by a horizontal incision three lines long, down to the fasci cutting-out of the hair-follicles is dertaken. The incision in the inte when the operation is done on the should ascend from the free border of in the vicinity of the lachrymal p being continued beyond the hair- parallel to the outer lip of the lid, ar ing the horizontal incision at an acu two lines beyond the commissure. right eye the incision may be mor made in the opposite direction (F When the bridge is thus defined, i is still adherent in some places, it s seized with the forceps and dissected the scissors or scalpel.

Fig. 69.

If then some follicles are still see surface of the wound, these should be most carefully dissected up from the with the scissors. Within a few days the wound is completely healed, g without suppuration, and the contracting cicatrix soon unites the integum the mucous membrane. If any hairs appear after this, they should also be as above described.

The complete removal of the hair-follicles, with all its excellent results, doubtedly some disadvantages not to be too lightly estimated. Apart from of a natural protection to the eye, it causes, especially when performe lower lid, a very unpleasant interference in the carrying-off of the tears. is suffused with tears, and these are apt to run over on the slightest irritatio unfrequently, in spite of every care in the operation, the canals of the tars become obliterated in the shrinking cicatritial tissue. Subsequently the also atrophies, and contracts to a small, thick swelling, in the interior c chalazions and cysts are developed. The mucous membrane does not alw out in consequence of the contraction of the cicatrix, and thus round of border of the lid, but in some cases the cicatrix is pulled from the inner s comes in contact with the globe. The cicatrix, being generally quite irreg rough, sometimes irritates and perhaps injures the globe. But these disad are much less than those of an unsuccessful transplantation, or those whic from the shortening of the lid, from excessive loss of substance of the inte when there have been repeated attempts at transplantation.

All these objections to removal of the hair-follicles are increased, when, as was for custom, the entire thickness of the lid is removed. (*Bartisch.*) Then shortening of th generally results, and an inability to completely close the eyes. The method in questi be discarded. Beside the unpleasant results which it may produce, it is entirely unnece

4. Where any cilia endanger the globe by an improper direction, we may attempt burn out the affected hair-follicle. For this purpose a lance-shaped knife, or a broad

rust into the lid, along the shaft of the hair. The wound thus made is cauterized r probe dipped in liquid caustic potash. Sometimes the result is excellent and per- is not advisable to simply pull out the hair and introduce the actual cautery through of the follicle, because it is more difficult and less reliable. (*Mackenzie.*)

ities.—*O. Becker*, Wien. med. Jahrb. 1866. 4. S. 80.—*Stellwag*, Ophth. II. S. 912, *nsis*, Traité d. mal. d. yeux. trad. p. Warlomont et Testelin. I. Paris. 1856. P. 142, 2.—*Desmarres*, Traité d. mal. d. yeux. Paris. 1847, P. 85, 87.—*Vidal*, nach Desmarres, —*Hünly*, Krankheiten und Missbildungen. I. Berlin. 1843. S. 140, 146.—*Arlt*, Die n des Auges. I. Prag. 1851. S. 128, 144, 146.– *Jäsche*, Med. Zeitung Russlands. 1844. *penstecher* und *Sämisch*, kl. Beobachtungen. I. Wiesbaden. 1860. S. 6.—*Graefe*, A. f. 225.—*Hirsenstein*, ibid. XIII. 1. S. 76.—*Secondi*, Clinica di Genova. Riassunto. Torino. 5.—*Burtisch*, *Fr. Jaeger*, *Flarer*, nach Arlt. l. c. S. 144.—*Stavenhagen*, klin. Beob- S. 5, 12, 18.—*Mannhardt*, A. f. O. XIV. 3. S. 40, 45.

4. Entropion.

Pathology and Symptoms.—Partial entropion very rarely occurs. We speak of partial entropion when that part only of the edge of the lids, near the outer commissure of one or both lids, is turned inward. In by far the greater number of cases the inversion is complete. The whole length of the edge of one or both lids appears turned inward, or even the lid itself is inverted. Entropion generally affects only the lower lid of one or both eyes, or is at least more fully developed there than in the upper lid.

Several degrees of inversion may be distinguished. The first is properly only a turning inward of the outer lip of the lid, and depends upon obliteration and retraction of the inner lip—a condition which is generally considered as trichiasis.

The second degree may be designated as inversion of the border of the lid. The entire thickness of the latter is turned toward the free border of the tarsal cartilage, so that the peripheral zone of the integument comes in contact with the globe.

The third degree is an inversion of the whole lid. The cartilage itself is rolled over, the affected lid forms a duplicature, and rests with the larger part of its integument on the globe.

In the highest grade the lid appears actually rolled inward, the border of the inverted lid having undergone a second turn, by which its peripheral surface has come into the original situation, and the outer lip lies in contact with the tarsal conjunctiva.

Entropion, like trichiasis, and for the same reason, is a source of very severe irritations and actual inflammation, especially in its first stages. Subsequently the eye accustoms itself, as it were, to the irritating effect of the inverted lid; the inflammation subsides, and only appears at intervals. During such exacerbations the entropion is not unfrequently temporarily or permanently increased. At last the hypertrophied conjunctiva degenerates, becomes more and more shortened; the cartilage begins to shrink, and becomes fixed in its displacement. The entropion then becomes permanent, in the true sense of the word.

Causes.—The proximate cause of true inversion of the lids may always be said to be the action of the orbicular muscle. The smoothing-off and contraction of the inner lip of the lid, as well as cicatritial degeneration of its margin, which often occur in consequence of blepharitis ciliaris and hypertrophying conjunctival inflammation, may assist in the formation of the disease, although the chief cause is as above stated. The latter are only to be regarded as disposing causes, which may be wanting.

Spasm of the muscle in question is enough of itself, when the lids are in a perfectly normal position, to produce an entropion of the edges and to make it permanent (*entropion spasticum*). Therefore all causes which may excite such spasms, and especially those which may keep it up for a time, may possibly cause entropion. Certain inflammations of the eye are prominent in this respect, especially keratitis, since this, more frequently than other eye-inflammations, is accompanied by very considerable photophobia and severe spasm of the lid.

The chief factor in this spasmodic inversion of the edges of the lids is that portion of the orbicular muscles which runs along the edges of the lids, and especially those muscular fibers which have been described as the *subtarsal muscle*. These fibers run along in the thickness of the *edges of both lids*, nearer their *inner margin*, as far as the *external commissure*, and in their course are connected at *many points* with the *integument* of the edge of the lids. If the lachrymal muscle contracts, *all* the points of insertion of the subtarsal muscle, especially the *inner margin* of the lid, are pushed toward the internal canthus and indirectly toward the *crista lachrymalis*. At the same time, because the muscle, as a whole, is extended in a great curve over the greatest convexity of the globe, the inner margin of the lid is pressed against the convexity of the globe, and endeavors to gain a vertical direction, in order to shorten the curve. Consequently the external margin of the lid approximates the surface of the eyeball, and hence the palpebral edges are no longer superficially in contact with one another, and meet at an angle which opens backward.

This effect can often be very distinctly demonstrated when, in consequence of inflammatory hypertrophy of the conjunctiva and cartilage, the latter has become loosened, soft, and yielding. It is then only necessary to hold the lids forcibly open and draw them somewhat outwards. If the patient now endeavors to close the eye, the displacement of some parts of the edge of the lid is sometimes so great that the latter is actually completely everted. The entire movement gives the impression that the edge of the lid is rotated in a very wide spiral around the free edge of the cartilage.

If the surface of the edge of the lid is once turned inward by the spasmodic action of the subtarsal muscle, the inversion is easily completed by the main body of the orbicular muscle. Its bundles describe a double curve, once in a vertical direction, and then horizontally from before backwards, and by their contractions exert a pressure upon the parts lying in their concavity, by endeavoring to shorten themselves from the arc to its chord. This pressure acts in one or the other direction, according to the respective curvature of the muscular fibers. The innermost layers of fibers, when the lids are closed, act almost horizontally across the greatest convexity. Their action in a vertical direction is then almost *nil*, while it reaches the maximum in a horizontal direction, and tends to approximate the external edge of the lid somewhat more to the globe, and therefore to increase the action of the subtarsal muscle. If, however, the external edge of the lid is brought very close to the globe, the entire palpebral portion of the orbicular muscle no longer forms a single curve, but two, one for the upper and one for the lower, and these two curves meet in the palpebral fissure at an angle opening backwards. This angle is still further diminished by the action of the more distant fibers of the orbicular muscle, since the latter press the edges of the lid more powerfully together, the greater the curvature is in the vertical direction. The subtarsal muscle, and all the fibers of the palpebral portion of the orbicular muscle, therefore, act together in causing the edges of the lid to give way backward, and it depends merely upon the power with which the muscles contract whether an entropium results or not. If then the edge of the lid once becomes inverted, the position of the two halves of the obicular muscle is so much the more favorable for the increase of the entropium, and if the lid becomes turned over, the action of the mechanically drawn subtarsal muscle suffices to turn the inversion into a complete revolution.

We thus have an explanation of why a rubbing off of the inner edge of the lid,

as well as a rounding off of the palpebral edges, favor the formation of an entropium. The backward yielding is thus facilitated, and, moreover, by the approximation of the external edge of the lid to the globe, a portion of the muscular action necessary to the formation of an entropium is rendered superfluous. It is also clear that great swelling of the conjunctiva conduces to inversion of the lids. They force the palpebral edges somewhat away from the globe, but are not sufficiently resistant to impede perceptibly their backward yielding. Besides all this, such œdema, as a rule, appears particularly in the retro-tarsal portion of the conjunctiva, and hence usually presses the surface of the two lids much farther forward than the tenser palpebral edges, and consequently diminish very much the angle at which the two halves of the orbicular muscle act upon one another.

Of course, resistance of the cartilage has a great influence on the easy or difficult occurrence of an entropion; the less the resistance, the more readily does true inversion occur. We find entropion, therefore, much more commonly on the lower lid.

It occurs especially in ophthalmia which are accompanied by great relaxation and swelling of the cartilage. It occurs, in a proportionately large number of cases, in old people with wrinkled, relaxed skin. In the latter, very slight spasm of the lid is sometimes sufficient to cause entropion of the lower lid. This is sometimes seen in an unpleasant way after cataract operations, especially if a bandage has been improperly applied, or if the corneal flap did not heal properly, and rested upon the edge of the lid.

But spasm of the lids is by no means indispensably necessary to the occurrence of entropion. The normal power of the orbicularis is sufficient to cause a true inversion of the lids, if portions or the whole of the thin edges have been brought into an improper position, with relation to each other, by shrinkage of the cartilage, from trachoma, symblepharon, cicatritial contraction of the integument or of the conjunctiva, which causes them to meet each other at an angle looking inward. Relaxation of the integument from phthisis or enucleation of the globe, without any vigorous contraction of the orbicularis, also leads, as a rule, to narrowing of the palpebral fissure, and turning inward of the edges of the lids; for then there is no resistance to the action of this muscle. (*Organic entropion.*)

Treatment.—We should in the first place oppose the occurrence and permanent formation of entropion. If the inversion has already existed for some time, and if it depends upon permanent organic changes in the lid or globe, the affected lid should be placed in a normal position, and should be permanently kept there by an operation, at the same time preserving, as far as possible, its form, size, and functions.

1. The proper treatment of the original disease is the principal requirement. As a rule, the spasm of the lid disappears under a rational treatment. When recent and slight, entropion will disappear of itself, provided changes in shape of the edge of the lid, or relaxation of the parts, do not prevent. At least, the spasm of the lid will be so far alleviated by such a treatment, that the direct treatment for the inversion of the lids may be carried out more easily and with greater hope of success. In case of necessity, in connection with the treatment of the original disease, special attention should also be paid to the spasm of the lid. (See *Blepharospasmus.*)

2. A canthoplastic operation is one of the best direct means of treatment for spasmodic entropion. Where the lids have preserved their normal shape, this operation is very frequently sufficient to effectually restrain the inversion, in spite of severe spasm of the lid. We may have more hope of this when the severity of the blepharo-spasm has already diminished, because, with the operative replacement of the

lid, an important cause for the continuance of the spasm has been removed. The result is most surely attained in senile entropion, where the spasmodic affection is less prominent, and when the inversion must be chiefly ascribed to the relaxation and looseness of the tissue of the lids.

In favorable cases of this kind, especially when the still-existing spasm of the lid depends mostly or entirely on the mechanical irritation of the lid, which is in a state of entropion, and promises to cease if the latter be removed, we may avoid the adhesion of a fold of conjunctiva in the angle of a wound, and make a simple division of the outer commissure. A horizontal incision should not be made, but an oblique one, and generally downward, because it is almost always the lower lid that is affected. A horizontal incision meets the *fascia tarso orbitalis*, the so-called external palpebral ligament, exactly in its densest portion, and may not be able to relax this. It moreover runs exactly through that part of the fibers of the orbicularis which is more lightly attached to the layer beneath. The muscle remains fixed at both extremities, and loses very little of its peculiar action. Want of observation of this anatomical condition explains the fact that the division of the outer commissure, especially the canthoplastic operation, has not been sufficiently esteemed, and has been considered as only proper in those cases where the palpebral fissure has become considerably shortened. (*Graefe.*) Where we wish a decided result, the commissure must be cut through obliquely. The more oblique the incision the greater is the relaxation of the muscle.

3. In order to increase the therapeutic effect of the canthoplastic operation, some recommend that this operation be combined with the ligation of a horizontal fold of integument, and of the muscular fibers beneath. (*Pagenstecher.*) This combined method, which is also easily substituted for transplantation and removal of the hair-follicles in distichiasis and trichiasis, is not only highly spoken of in spasmodic but also in organic entropion, where shrinkage of the conjunctiva or even of the cartilage exists at the same time. For the purpose of ligation the surgeon grasps the integument in the middle, with the thumb and finger of the left hand, and holds a piece sufficiently broad, with a crutch-shaped forceps. An assistant holds the head of the patient. The fold should run horizontally, in order that the traction on the outer lip be regular. The fold of integument should also be so broad that the outer lip of the lid appears somewhat turned out.

Fig. 70.

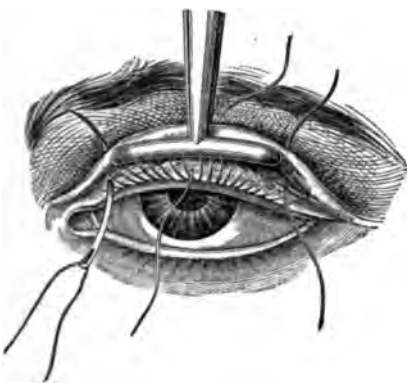

Then a curved needle, armed with a stout ligature, is introduced into the integument near the outer commissure, about a line from the lip down to the cartilage, and then emerged at a proper point. A second needle is introduced near the middle of the breadth of the lid, and a third near the inner commissure. The forceps are then removed, and each thread is tied. (*Gaillard, Rau*). This operation is very painful, but the pain disappears very soon. Inflammation then occurs. If it is not too violent we may leave it to itself. The patient should be kept in good condition, and the movement of the lid be prevented by a protective bandage. If the inflammatory symptoms are very severe, iced applications may be used. If erysipelas occurs, it is well to remove the ligatures, and choose some other method of treatment. In favorable cases the threads remain till they are thrown off by suppuration. The parts fastened by the ligature are

caused to adhere, and changed to a rigid, tendinous, cicatritial mass. This is plainly to be seen and felt a short time after the parts are healed, but subsequently it becomes somewhat softened, while the lid is generally confined in its normal position. Yet we can not count on this result with certainty, because it often becomes so much distended, under the continued action of the orbicularis, that the border of the lid again acquires an abnormal position.

4. This want of firmness of the cicatrix, together with the long duration and dangers of the inflammatory reaction, cause the simple ligation of a fold of integument to be considered as an unsatisfactory method. It is also doubtful whether the various modifications of the operation lately proposed make success sufficiently certain.

Some make an incision through the integument parallel to the free border of the lid, and about one line removed from it, down to the muscle. They then seize the orbital border of the wound, and separate the cutis from the orbicularis, so that a broad and deep pocket is formed in the integument. Then the end of a thread, armed with two needles, is entered into the outer angle of the wound thus formed, behind the fibers of the orbicularis, and along the anterior surface of the cartilage, down to the bottom of the pocket in the integument, where the needle is thrust through. The other end of the thread is entered in the pocket of the integument, in front of the muscle, and pushed through the skin near the first ligature, when the two ends are fastened by a strip of adhesive plaster. A second ligature is placed around the fibers of the orbicularis in a very similar way, and, by tying it, the muscle is drawn in a zigzag line. The result is a drawing away of the edge of the lid from the globe. (*Bowman.*)

Others ligate in the following manner: with the lid completely everted, they introduce the ends of the ligature, armed with curved needles, through the whole thickness of the lids. This is done in such a manner, that one of the threads enters at the deepest part of the palpebral fold passing through the convex border of the tarsal cartilage; but the other ligature passes through the palpebral ligament, at some distance from it. When this has been done, the two armed threads are pushed on through the outer incision, back to the anterior surface of the cartilage under the muscle, toward the border of the lid, and are brought out close to the outer lip, about two lines apart. They are then tied, and the border of the lid is thus turned out. After three days the ligature may be removed. We should be careful not to leave any portion of the thread behind. If this be done, slight ulcerations will result. The avoidance of these, and the fact that no external cicatrices are caused, are, without doubt, important advantages in this method (*Snellen, Maunhardt*).

Where we only require a temporary effect—where, for example, the ectropion is spasmodic resulting from an ophthalmia, which will evidently be subdued in a very short time—we may sometimes attain the desired end by taking a broad fold of integument from the lid, between the arms of an entropion spring-forceps. (*Bonafont.*) This forceps is on the principle of the *senes fines*, but instead of being toothed, the extremities are slightly rough, in order that they may take hold better. When the muscle contracts very much, however, they are apt, in time, to be somewhat displaced. It is well, therefore, to alter the position once or twice during the day, and, besides, not to allow the pressure to be always on the same part, changing the position of the instrument as much as possible. Senes fines (*Vidal*) press through the skin too easily, and excite too severe pain, to be useful. Folding the integument with a strip of linen, fastened on the lid by collodion, is less troublesome, and, at least, quite as efficacious. (*Bowman, Arlt.*)

Such a piece, one and a half inches long, and half an inch broad, may be fastened on the lid, with one end below the inner angle, between the furrow of the cheek and the tarsal cartilage, and then the other placed opposite, the skin having been previously drawn toward the first point of insertion. Penciling the part with collodion is said to increase the traction, by the great shrinkage caused. The tears, unfortunately, soon loosen the plaster.

5. The traction of cicatrices which have occurred on the lid is undoubtedly permanent. Caustics have been applied to the integument, in order to cause these latter, but more frequently the scissors or knife has been used. Sometimes a horizontal, sometimes a vertical, piece of integument has been said to be the proper shape for removal. In order to increase the effect, it is necessary to hold the lid in the de-

sired abducted position by strips of plaster till the final healing of the wound. If this precaution be not observed, the result is apt to fall short of our expectations. The simultaneous exsection of the denuded portion of the circular muscle (*Himly*) is scarcely necessary.

Many lay the greatest stress upon the horizontal stretching of the middle zone of the integument of the lid, since this is generally the most relaxed, particularly in entropion of the lower lid.

In order to attain the greatest amount of horizontal tension, in the zone of the greatest deviation of the lid, it has been recommended, very recently, to excise a triangular instead of an oval piece, from the integument. Its base is from three to five lines long, and runs parallel to the free margin of the lid. For this purpose (see Fig. 71) a horn-spatula is placed under the lid, one and a half lines removed from the outer lip. An incision is made parallel to it; that is, almost horizontal. The incision on either side is one to two lines distant from the commissure. When this has been done, the triangle is completed by two incisions converging toward the orbital border, and the integument is dissected up and removed. If, in old people, the relaxation extends quite regularly toward the orbital muscular arch, the flap should be shaped like a pointed arch. The sides of the wound should be united by two or three interrupted sutures. The horizontal incision is left to heal spontaneously. The cicatrix is, of course, T-shaped. The lateral shortening of the lid, in cases in which the palpebral fissure was only moderately large, is said to be of no disadvantage. But where the entropion was combined with narrowing of the palpebral fissure, this latter should be, at the same time, or previously, removed by a canthoplastic operation. (*Graefe.*)

Fig. 71.

Others, in entropion of the lower lid, place the base of the triangle to be excised without the external commissure. They first split this horizontally for a distance of four lines, and then make two incisions through the integument from the lower border of the wound, converging downward, and then dissect up the triangular flap from the muscle. The inner border of the wound is then united to the outer by sutures, and thus the lid is stretched somewhat diagonally, and also lifted up. This method is very highly spoken of where the entropion depends chiefly on shrinkage of the conjunctiva and cartilage, and is accompanied by blepharo-phimosis, such as often occurs after trachoma. (*Busch.*)

If the tarsal cartilage is shrunken in entropion of the upper lid, a triangular flap is first dissected from the middle of the integument, the base of which is turned toward the free border, as in Fig. 71. Then the exposed portion of the orbicularis is dragged away by a hook, and a triangular incision made in the surface of the cartilage, but with its base toward the orbital border, and extending with its apex close to the free border of the tarsal cartilage, without, however, dividing it. The palpebral conjunctiva is to be preserved, the cartilage being separated from it by the knife. The wound is closed by several sutures, which draw the sides of the triangle together in a vertical line. The middle ones also fasten the superficial layers of the edge of the incision in the cartilage. (*Graefe.*) Unfortunately, the closure of the incision in the cartilage, without folding its horizontal basis, is not possible. This prevents the complete healing up of the [illegible] Perhaps if a piece be cut from the cartilage, shaped like a myrtle-leaf, with a vertical [illegible] and with the sides bulged out more or less, according to requirements, it would answer [illegible]pose better.

It has recently been proposed to extirpate the cartilage of the lid completely, in case it is very much degenerated and curved. To this end we should do at first exactly as in transplantation of the hair-follicles. If the anterior surface of the cartilage is then denuded by the semilunar section from the integument of the lid, the tarsal cartilage should be detached form the conjunctiva by means of a scalpel, beginning at the wound of the edge of the lid, and be removed by means of scissors as far as its superior border, and then the resulting semilunar opening in the integument to be closed by sutures, and a suitable bandage applied (*Pope*).

6. If we do not attain the desired results with these operations, there remains nothing to be done, except to remove the hair-follicles.

7. If phthisis or extirpation of the globe is the cause of an entropion which is disturbing and dangerous to the eye, on account of the turning inward of the lashes, it will be best to insert an artificial eye. An operation is almost always superfluous.

Authorities.—*Himly*, Krankheiten und Missbildungen. I. Berlin. 1843. S. 120, 125, 129, 132. —*Mackenzie*, Traité d. mal. d. yeux. Traduit p. Warlomont et Testelin, I. Paris. 1856. P. 307, 310. —*Desmarres*, Traité d. mal. d. yeux. Paris. 1847, P. 44, 50.—*Arlt*, Die Krankheiten des Auges. III. Prag. 1856. S. 365; A. f. O. IX. 1. S. 94; Zeitschrift der Wiener Aerzte. 1861. Wochenblatt S. 87. —*Stellwag*, Ophth. II. S. 908, 922.—*Graefe*, A. f. O. X. 2. S. 221, 223, 224.—*Bonafont*, L'union méd. 1861. Nr. 27.—*Vidal*, nach Mackenzie l. c. S. 311.—*Busch*, A. f. O. IV. 2. S. 107.—*Pagenstecher* und *Sämisch*, kl. Beobachtungen. I. Wiesbaden. 1861. S. 3; Congress. intern. d'ophth. Paris. 1863. P. 241.—*Secondi*, Clinica di Genova. Riassunto. Torino. 1865. P. 122.—*Rau*, A. f. O. I. 2. S. 176, 178.—*Gaillard*, nach Rau l. c.—*Bowman*, nach Mackenzie l. c. S. 311 und Niemetschek, Prag. Vierteljahrschrift. 78. Bd. S. 97.—*Snellen*, Congress intern. d'ophth. Paris. 1863. P. 236.— *Vauquelin*, De l'applicat. de la suture enchevillée. Paris. 1853. P. 20, 26.—*Mannhardt*, A. f. O. XIV. 3. S. 42, 45.—*Pope*, Arch. f. Augen- u. Ohrenheilkde. I. S. 68.

5. Ectropion.

Pathology and Symptoms.—The eversion is sometimes confined to one part of the lid. Generally, however, ectropion is in so far complete, that the whole length of the edge of the lid is in an improper position. Ectropion affects the lower oftener than the upper lid, and is sometimes found on both lids of one or both eyes.

There are several degrees of ectropion. The lowest form is only a lifting up of the inner lip of the lid, an inexact fitting of the border of the lid on the globe. In other cases, the margin of the lid appears really turned outward. On closure of the eyes the border of the healthy lid meets the most anterior portion of the inner surface of the affected lid, and, as it were, pushes between this. In case both lids are affected in the same way, the edges meet at an acute angle, which looks anteriorly. True eversion of the whole lid may be described as the third degree. The affected lid is turned vertically upward, and the surface of the border of the lid looks downward or upward, as the case may be. On the closure of the lid, the healthy lid meets the palpebral conjunctiva where it is turned over, and its periphery remains exposed. The outer commissure generally appears distorted at the same time. In ectropion of the lower lid it sinks downward considerably, but in ectropion of the upper lid it is pushed forward. In the highest degree of ectropion the lid is totally everted. It is then placed at an obtuse angle to the surface of the globe; its posterior surface has become its anterior, so that the half of the conjunctival sac is exposed, and the globe can not be covered at all, or with difficulty.

As will be understood, these four degrees can not be accurately distinguished from each other, but are connected by numerous intermediate varieties. Eversion of the lid, moreover, not unfrequently arises from a previous turning-out of the border of the lid, and a mere lifting up of the edge of the lid often precedes this.

The increase in degree of ectropion then appears to be induced by the continuance of the existing causes, but especially by the altered action of the orbicularis, caused by the false position of the edges of the lids with relation to each other. In case the edges of the lids meet at an acute angle, looking anteriorly, the principal part of the muscular fibers push them forward with great power. The fibers of the orbicularis, next to the edge of the lid, with the subtarsal muscle, are much too weak to balance this pressure. They can, therefore, only shorten themselves by completely everting the edge of the lid, which has been before simply turned outward.

The changed position of the edges of the lid to the surface of the globe interferes with the proper carrying-off of the tears. If the lower lid is in a condition of ectropion, a very large quantity of tears collects in the deep furrow between the inner surface of the lid and the globe. The eye, therefore, seems to be suffused in tears, especially when any irritant acts upon them. An immediate consequence of this, as well as of simple lifting up of the upper border of the lid, is impairment of vision, on account of the unequal moistening of the cornea, when the lid closes. In the severe form of ectropion, especially of the lower lid, the tears collected run over in great quantity, and cause excoriation of the cheek, inflammation, and, as a further

consequence, shrinkage of the integument. This latter causes an increase in the degree of the ectropion. The effect of the atmospheric air, and of other external irritants upon exposed portions of the conjunctiva, or even of the cornea, leads, finally, although slowly, to similar morbid changes with entropion. The conjunctiva is kept in a constant state of irritation, and becomes hypertrophied. It is coated with indurated epithelium, and finally shrivels, while the cartilage, which is also affected, atrophies, and, being distorted, contracts and hardens. The greater part of the cornea then acquires a pannous condition, if it be not injured or destroyed by ulceration, from the repeated attacks of inflammation; added to all this, in the later stages of the severer forms of ectropion, shrinkage of the lachrymal sac occurs. This, if not filled up for years, becomes smaller and smaller with degeneration of its walls, and is finally incapable of fulfilling its functions. (*A. Weber.*)

Causes.—The causes of ectropion are very different.

1. In isolated cases, weakness or actual paralysis of the orbicularis muscle is the chief cause.

Thus, diseases of the brain or lesion of the facial nerve may be the cause (*paralytic ectropion*). In the lowest forms of paresis, the morbid condition is merely noticed by not quite so close a fitting of the edge of the lid to the globe, and by some hindrance to the perfect carrying-off of the tears. In the higher forms of paresis, however, the lower lid hangs down loosely, or actually turns over, while the upper lid is pulled up by the *levator palpebræ superioris*, and thus the globe is exposed (*paralytic lagophthalmia.*)

On the other hand, impairment of the function of the orbicularis may arise from changes in the fibers themselves, especially from their atrophy. It may occur from previous inflammation of the lid, abscesses, &c., also from excessive distention of the lids from orbital tumors, &c.

Weakness of the orbicularis is generally a mark of great senile change. Indeed, falling down of the lower lid, in very old people, is no very rare occurrence, especially if the person has suffered for a long time from chronic conjunctival catarrh. Then the cartilage is also generally affected. It becomes relaxed, loses its firmness, is distended, and, consequently, does not fit close to the globe. The beginning of the affection in such cases is frequently an eversion of the lower lachrymal punctum. The running over of the tears thus caused, leads to inflammation, and subsequently to shrinkage of the integument, which may cause an increase in the morbid condition (*senile ectropion*).

2. Relaxation, softening, and particularly distention of the cartilage of the lid, causes severe trachoma to be a fruitful source of ectropion. Eversion of the lid is very apt to occur under such circumstances, if for some time during the inflammation, great swelling of the ocular conjunctiva existed, or spasm of the lid from any cause whatever. The inflammatory relaxation of the cartilage is combined with some elongation of the edges of the lids, and this increases markedly, if any pressure be exerted on the lids from behind, forward. The edges of the lids do not fit accurately on the eye-ball after the swelling has subsided. They are everted under the pressure of the orbicularis. At length, the lower lid becomes completely everted, so that the swollen palpebral conjunctiva, which is roughened by trachomatous granulations, is exposed, while the upper lid hangs loosely on the globe (*ectropion luxurians* or *sarcomatosum.*)

3. Ectropion also arises in an acute form, in the course of blennorrhœa, pyor

rhœa, diphtheritis, in general in conjunctivitis which is accompanied by severe chemosis. If the lid be not immediately replaced, the cartilage becomes gradually distended, but especially the border of the lid, which is the tensest, and the lid becomes incapable of preserving its normal position. This is more apt to occur, because the exposed portion of the conjunctiva, together with the sub-conjunctival tissue, is not unfrequently hypertrophied, on account of the commencing strangulation of the conjunctival swelling, and from the mechanical hyperæmia thus induced, and remains like a puffy, hard tumor.

4. In the same way, ectropion of the lower or both lids sometimes occurs, when large morbid growths occur in the orbit, or if the globe increases much in size from any cause whatever. The lids are bulged forward, more and more distended, and their closure is even prevented. At length, either the tumor or the globe is pressed out of the palpebral fissure, and thus everts the edges of the lids (*mechanical ectropion*).

5. Wounds which entirely divide the lid in vertical or oblique direction, as well as ulcers, cancerous growths, lupus of the commissures, are also a source of mechanical ectropion. Recently, ectropion of both lids has often occurred, as a result of cutting through the inner palpebral ligament, in the treatment of some affections of the lachrymal sac.

6. Most frequently, however, a shortening of the integument of the lid, or a stretching of it by adjacent cicatrices, is the cause of ectropion (*symptomatic ectropion*). The lower lid is particularly subject to this sort of ectropion, on account of the shortness of its integument, and the want of firmness of its cartilage. Yet the upper lid is often everted, and even fully turned over, by cicatrices.

a. Chronic ophthalmia is sometimes the cause of shortening of the integument, particularly when accompanied by lachrymation, or abundant secretion of mucopurulent material, and the integument is thus kept constantly moist. The latter is then gradually covered by a layer of inflexible, often fissured, epidermis, while the corium itself becomes hypertrophied and subsequently shriveled, and is shortened, perhaps, after the cartilage is relaxed. This shortening is relatively slight, being only sufficient to produce ectropion in the lower lid.

b. Shortening of the integument is more frequently a consequence of losses of substance, with the subsequent occurrence of cicatrices. Lacerated wounds, followed by suppuration, scalds, burns, cauterizations, confluent small-pox and eczema, erysipelas, abscess of the lids with ulceration, or gangrene of the integument of the lid, are remote causes of ectropion. The greater portion, or the whole, palpebral integument is replaced by cicatritial tissue, according to the size of the loss of substance, or quite broad and thick cicatritial bands arise, which are either situated entirely in the integument, or are drawn over from one point to another, and lift up the integument in folds.

c. Caries of the bony orbital border is very important in this connection, on account of its frequency, as well as the severity and obstinacy of the ectropion caused by it. In consequence of this affection, not only is a great part of the integument which has been destroyed replaced by cicatrices, and thus considerably shortened, but the cicatrix involves the cartilage, which is generally distorted, and a portion of the tarso-orbital fascia, and is immediately connected to the bone. Caries most frequently occurs on the lower and outer portion of the bony orbit.

d. Large cicatrices in the cheek, brow, or temples, may also cause ectropion, by traction on the normal integument.

Treatment.—The same indications are to be fulfilled as in entropion. The treatment naturally varies in accordance with the cause of the affection.

1. In acute and sarcomatose ectropion, the proper treatment of the inflammation and the replacement of the lid are often sufficient to remove the affection. In the greater number of cases, however, an appropriate bandage should be applied and worn for some time. If this treatment be patiently and carefully conducted, it is often sufficient, even where the border of the lower lid is considerably elongated.

2. If, in such cases, or after attempts at relief by operation in entropion from other causes, the border of the lid remains a little lifted up from the globe, narrowing the palpebral fissure often does excellent service. For this purpose the surfaces of the borders of one or both commissures should be freshened, without injuring the cilia, and made to adhere by means of sutures.

The same method may be recommended in slight degrees of senile and in paralytic ectropion. In the latter variety it is the only means (a cure of the paralysis being impossible) to somewhat improve the condition, and to protect the exposed eye. Narrowing the fissure is also done for the sake of the appearance, in order to mask actual or apparent prominence of the eye-ball.

Where symptomatic ectropion is threatened from large losses of substance in the integument of the lids or neighboring portion of the face, from burns, or the like, it is advisable to cause nearly all of the palpebral fissure to unite, and to keep it united during the contracting of the cicatrix of the integument. For this purpose nearly the entire length of the border of the lid should be pared off or freshened, protecting the outer lips, beginning at the lachrymal punctum and continuing to a point near the outer commissure. Then they are united by five or six sutures. In order to assist in the maintenance of the cicatrices, the palpebral fissure should be frequently penciled with collodion. Some months after, when we do not fear any further contraction of the cicatrices of the integument, the edges may be easily separated upon a director. (*Debrou, Mauvezin.*)

In the same way the suture is the means of curing ectropion, caused by traumatic or ulcerative separation of continuity of the lids or commissures. If the edges of the fissure are already hardened, they should, of course, be first freshened. But when they are formed by an irregular rigid cicatrix, it is well to remove this by a curved incision before the reunion is attempted. It hardly need be said that the freshening, under such circumstances, should extend through the whole thickness of the lid. The freshening and subsequent union of the inner portions of the border of the lid also gives good results, where division of the inner palpebral ligament was the cause of the ectropion. Yet the muscular action sometimes opposes it. The integument is strongly pushed forward by the circular fibers after the freshening of the commissure, but the mucous membrane, with the caruncle, is drawn away from the portion about the lachrymal sac, the edges of the wound are stretched open, and thus suppuration often occurs at the angle of the eye. It is therefore necessary to exert some pressure upon the angular region, in order to keep the parts separated as much as possible. A firm piece of charpie, about the size of a filbert, answers for this purpose. It is laid on the inner angle of the eye, and, after carefully filling the orbit with bits of cloth or charpie, is pressed upon the structures beneath by a flannel bandage tightly drawn.

It is very good practice to prevent movements of the lids after any operation upon them, by applying a protective bandage. This should never be neglected during the first part of the healing period. The orbicularis always tears and

stretches the edges of the wound, and may thus influence the process of cicatrization very unfavorably.

A further important rule, for all cases in which an operation does not promise a complete restoration of the normal position and function of the lower lid, is to slit up the lower canaliculus, in order to assist the carrying-off of the tears. (*Bowman.*) If there be already some contraction of the lachrymal sac, we should endeavor to enlarge it by systematic probing, as is customary in the treatment of blennorrhœa of the lachrymal sac.

In operations in the lid, the interrupted suture is always to be preferred to the continuous. The latter presses greatly on the underlying parts, and almost always causes suppuration; besides, it is entirely unnecessary.

The so-called *fil de Florence*, also improperly named *sea-grass*, makes the best suture. For oculistic purposes only very fine threads should be used, and these should be softened in warm water before using. They have an advantage, not to be over-estimated, in not causing suppuration, and may therefore be left in, longer than silk or linen sutures. The wound frequently heals without suppuration. At any rate, a firmer union may be expected. (*Passavant*). However, they do not answer as sutures for the conjunctiva or globe, since they are too stiff, and cause irritation or pressure.

3. In ectropion of the lower lid, caused by elongation of the free border, with distention and relaxation of the cartilage, which can not be completely relieved, the lid must be rendered tense in a horizontal direction, and at the same time lifted up, if we hope to have it fit the eye-ball again. The simple narrowing of the palpebral fissure has almost always shown itself to be insufficient.

If it be accompanied by no very great shortening of the integument, and if the margin of the lid is in other respects normal, the excision of a triangular flap, from the outer portion of the lid, and closing the wound by sutures, is generally sufficient. For this purpose the edges of the lids in the outer commissure are split with an iridectomy-knife, the splitting being continued, if necessary, with a scalpel. Then a triangular flap of integument is made by the converging incisions, which is dissected up from the tissue beneath. The edges of the wound are then united by suture, and a protective bandage applied until adhesion has occurred. In order to lessen the stretching, it is well, before closing the wound, to separate the inner edge from the tissue beneath for a little distance, particularly if the sub-cutaneous tissue is somewhat thickened from previous irritations, and consequently resists the intended pressing out of the integument. It also seems advisable to somewhat diminish the tension by keeping the adjacent parts drawn toward the cicatrix by strips of plaster. If we wish to secure a great elevation of the lid and of the commissure, the *tarsoraphic* operation deserves the preference. (*Ammon, Graefe*). Before this operation is undertaken we should close the lids, bring the lower one into a normal position, then the border is put slightly on the stretch

Fig. 72.

in a horizontal direction. We should then mark with ink, in a vertical line, the two points of both the edges of the lids, where both lid-margins fit each other, when they are in a normal position, and there is a slight amount of tension of the lower lid. Then, the lids being kept in the position described, the integument over the outer commissure is lifted up in a horizontal fold, and as much of the integument of the lower lid very gradually fastened between the fingers as is necessary to bring the lid into its normal position, and to elevate the outer commissure to the level of the inner angle. When the breadth of this horizontal fold of integument is also indicated by two lines parallel to the margin of the lid, we begin to extirpate the portion of the integument within the described boundaries.

While one assistant holds the head of the patient, and another restrains the bleeding, the operator (see Fig. 72) pushes a small horn-spatula under the outer commissure, lifts it up from the globe, and splits it into two layers, first thrusting in a broad, lance-shaped knife immediately in front of the fascia tarso-orbitalis, and then enlarging the wound with a scalpel on both lids, up to the vertical boundary lines (Fig. 72, *a* and *b*).

When this intramarginal splitting is done sufficiently, the lower and then the upper margin of the lid are freshened in a direction inward from the vertical boundary line for about one half to three quarters of a line, by a horizontal incision. The whole breadth of this incision falls behind the lashes. The lower margin of the lid is now cut through in the vertical boundary line, and down to the cartilage, the wound elongated until the level of the horizontal line has been reached. The knife is then turned in an obtuse angle looking outward, carried on parallel to the margin of the lid, and beyond the commissure is turned upward in the shape of an arch. (See Fig. 72).

The upper lid is treated in the same way. The horizontal incision is to be made at a greater or less distance from the edge of the lid, according as the outer commissure is to be more or less elevated; but it should always be so made that the two run together at an acute angle. The integument thus circumscribed is dissected up, and the wound closed by three or four sutures. The first suture is placed close to the vertical boundary line. (Fig. 73.) When all are inserted, the curved incision is changed to a horizontal one.

Fig. 73.

In order to lessen the tension, strips of adhesive plaster, as well as the protective bandage, may be used. These are fastened on the cheeks and forehead, drawing up the integument lying between them.

When there is a very great difference in the length of the edges of the lids, the result of the operation is endangered by the bulging forward of a large fold of the cartilage and the fascia under the suture. It is, therefore, advisable, after the separation of a circumscribed flap, to cut out a piece or gusset (*zwickel*) next to the outer commissure, whose axis runs outward and somewhat downward, and whose base is about the same size as the difference in the length of the edges of the lids. The edges of the incision in the cartilage and the fascia should then be included in the suture.

Cutting out a V-shaped piece from the middle, and from the entire thickness of the lid, is no

to be recommended. (*Adams.*) There is generally some bulging inward remaining on the margin of the lid, which may affect the carrying-off of the tears. But the chief thing to be considered, in such a method, is, that the outer commissure is not elevated in the operation, and that the shortened margin of the lid, especially in prominent or projecting eyes, readily turns on the lower portion of the convexity of the globe—prevents the closing of the lids, and may become a source of irritation.

The attempt to cure an ectropion of the kind in question, by the destruction of a portion of the palpebral fold by caustics, or the actual cautery, that is, by causing a contracting conjunctival cicatrix, is entirely useless. In severe ectropion such a procedure is entirely insufficient. In slight cases, which may be removed by the traction of a conjunctival cicatrix, a very large destruction of the conjunctiva must take place, and this endangers the functions of the eye.

Some attempt to render the conjunctiva tense by a kind of transplantation, and speak highly of the results, especially in senile and sarcomatous ectropion. For this purpose the tarsal conjunctiva is entirely separated from the inner surface of the cartilage for about eight lines, and then the integument is cut through externally along the convex cartilaginous border in the breadth of the lid. As much of the conjunctiva as may be necessary is brought through this fissure as a transverse fold, and fastened by harelip needles passed in crosswise. This fold is allowed to heal there (*Dieffenbach, Küchler.*) Unfortunately, this method pays no regard to the elongation of the margin of the lid. Where this latter can be relieved without an operation, after replacement of the lid, the above procedure seems superfluous, and, where we can not expect a contraction of the distended parts, it is impossible for this operation to accomplish its object.

4. If there is a marked thickening and shrinkage of the integument, together with the eversion of the lid, we can not make the integument sufficiently tense, or lift it up, without dangerous stretching of the parts. It is necessary to take material from the adjacent integument.

It is recommended to split the lid from the lachrymal punctum to the outer commissure for this purpose, and then to carry two vertical incisions, from eight to ten lines long, through the integument. The whole quadrangular flap (see Fig. 74) is then loosened sub-cutaneously. The flap is seized with the forceps, drawn up tightly, and united in this position by sutures to the lateral incisions, beginning from below upward.

Fig. 74.

But, in order to correct the elongated margin of the lid, the flap must first be supported. This is best done by an incision, *a*, which unites the inner with the horizontal edge of the flap. Finally, the intermarginal incision is united by sutures, and a protective bandage applied until union has taken place. (*Graefe.*) This method is said to do particularly well when the free margin of the lid is very much distorted, and when, in consequence of the traction of the integument, the conjunctiva is drawn over upon the anterior surface of the tarsal cartilage. Unfortunately, its effect upon the position of the commissures is scarcely sufficient. This deficiency is felt particularly at a subsequent period, when the adherent mass begins to shrink. We shall, as a rule, therefore, be compelled to subsequently perform *tarsoraphy*.

There is an old method which is very practicable in such a combination. This is the displacement of a triangular flap of integument. (*Samson.*) But this is only to be employed, provided the margin of the lid is merely elongated, but not much changed in form. The flap is made by two straight incisions in the integument, upon

a spatula placed under the lid. They begin at the marginal surface, and converge toward the orbital border.

Fig. 75.

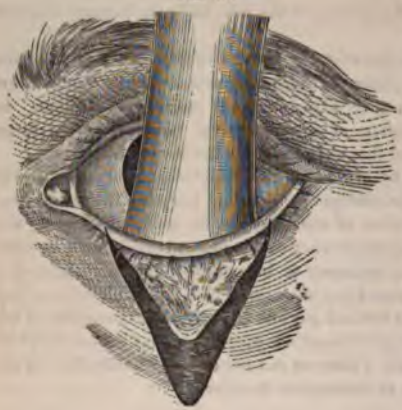

Where it is possible, all the shrunken portion of the corium should be involved in the incision. The flap is then dissected up, when the lid may be readily brought into a normal position. The flap now only partially covers the surface of the wound (Fig. 75). There remains a portion uncovered, shaped like a pointed arrow-head. This should be covered by drawing the edges of the adjacent integument together. For this purpose the converging outer borders toward the vertex of the incision should first be united to each other by suture, and then the remaining portions.

Others first cut through the integument in the vicinity of the outer lips. They separate this up to or beyond the orbital margin from the tissue beneath. The outer commissure is then divided horizontally, as far as may be necessary, and a triangular piece is taken away from the lateral portion of the lid, having first removed any puffed-out portions of the conjunctiva with the scissors. When this is done, the gap in the commissure is closed by sutures, the tarsal border is brought into proper position by two loops of thread, and fastened on the forehead or cheek by adhesive plaster. The undermined integument is to be brought at the same time as near as possible to the free margin of the lid, and an attempt made to secure adhesion (*Chelius*, *Ruete*).

Fig. 76.

A.

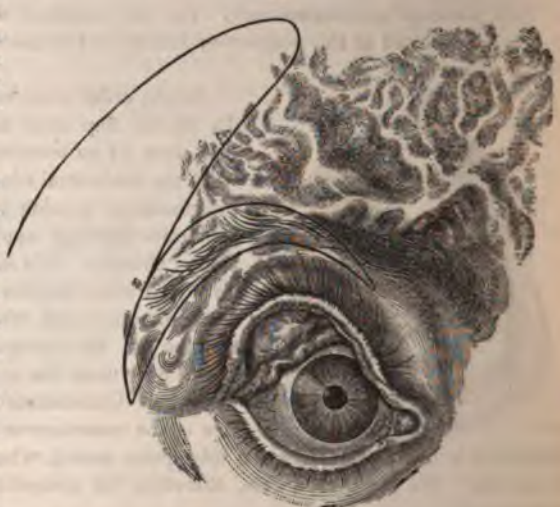

5. Ectropion which is caused by a cicatrix in the lid, and which is small and deep, may be often relieved by excising the cicatrix. For this purpose the cicatrix is involved in an arch-shaped incision, whose sides are nearly perpendicular to the free border of the lid; this is dissected up and removed, and the edges of the wound brought together by sutures. In bridge-like cicatrices it is sometimes sufficient to divide the bridge and to keep the surfaces from contact until they have healed over (*Fricke*).

6. If the greater portion of integument of the lid suffering from ectropion, and per-

nuscle also, be shriveled into a dense cicatricial mass, there is nothing to n order to overcome the eversion, but to cut out the cicatrix, and to a flap to supply its place from the adjacent integuments.

tails of a blepharoplastic operation vary exceedingly in each case. f great importance to take the flap to be transplanted from healthy skin. which nourishes it should be as broad as is possible, without impairing y very much. Generally speaking, the two following methods of opera- nswer the purpose, with slight modifications, in the majority of cases. cicatritial mass is circumscribed by two curved, oblique incisions. They e inner border of the cicatrix, at quite an acute angle, but diverge some- ard the orbital border, and at the same time sink a little downward. 76, which is from a case of Professor Arlt's.) Then the cicatritial ssected from the tissue beneath, from within outward, the lid stretched rmal position, and the gaping wound closed by a flap (*A*) shaped like newhat longer and broader. This is to be taken from the anterior temporal region, and has either a vertical or an oblique axis. The anterior boundary line of this flap should unite with the lower border of the surface of the incision in the lid, but the posterior incision should diverge outward somewhat, and end under the level of the upper border of the surface of the incision in the lid. Then the cicatritial mass is completely separated up to the inner border of the flap, which is turned upon the surface of the wound of the lid, and united by sutures. (*Fricke, Arlt*).

Fig. 77.

b. The cicatrix is circumscribe by three incisions, making a triangle, the base of which runs parallel to the lid. This is dissected up, and the wound covered by transplanting a rectangular flap, A, formed from the healthy integument, and the wound closed by sutures. (*Dieffenbach.*)

rfaces which are exposed, after the transplantation of the flap, may l or even fully covered, as far as is possible without stretching, by tion and union of the edges. That which remains uncovered must heal ation. It is necessary to wear a protective bandage at first, and the uld be kept strictly quiet, in bed, if possible, and antiphlogistic regimen The principal danger in these blepharoplastic operations is the gangrene, suppuration, of the flap. We have the best chance of avoiding these making the flap of healthy and very distensible integument, the con- ce broad, and by avoiding all severe tension. But the most appropriate ot always certain in its result. The occurrence of erysipelas is especially

unfavorable, for then partial suppuration, at least, always occurs, and cicatrices are caused, which may alter the position of the edges of the lids. Moreover, it not unfrequently occurs that the flap, although healing without suppuration, afterward shrinks up in a puffy way, the tissue beneath not being firm enough. In the most favorable cases, the new lid remains immovable, the muscle having either been previously destroyed, or having degenerated with the transplanted flap. These operations are rather designed to cover the eye, and the cosmetic interest is of less importance. It is therefore well to connect with them extensive tarsoraphic operations. These operations are also indicated from the fact that they somewhat oppose the re-opening of the palpebral fissure, on account of the shrinkage of the flap.

In the ectropion caused by cicatritial adhesion of the lids to the bony orbital border, it will be sufficient, in case the cicatrix is small, to loosen this sub-cutaneously from the bone, and to keep the lid in its position by tarsoraphy, until the union has occurred.

The following method is more certain, however, when the cicatrix is small. The cicatrix is circumscribed by two elliptical incisions, with their sides as nearly as possible perpendicular to the border of the lid. (Fig. 78, *A*.) The surface of the cicatrix is then freshened, the adjacent integument and fat sufficiently separated from the bone, so as to bring the lid into a normal position without stretching, and the edges of the elliptical wound are brought together by suture, so that the cicatrix is completely covered by the adjacent parts of integument, and united to its posterior surface. (*Ammon.*)

Fig. 78.

Fig. 79.

In broad adhesions of this kind, an incision should be made, two to three lines below the cicatrix, parallel to the orbital border (Fig. 79, *A*), down to the bone, so that the skin, with the cicatrix, can be sufficiently separated from the layer beneath sub-cutaneously, and upon which the lid may be brought in its normal position. When this has been done, the palpebral fissure is narrowed to the extent of a third and more by paring its edges, and uniting them by suture. After complete cicatrization of the edges of the wound, the danger of farther shrinkage being past, it may be again enlarged as is required. (*Ammon.*)

In both the latter-described operations, a properly-applied bandage is almost essential to success. We desire, above all things, to secure union by first intention, or at

st to limit the suppuration, in order to prevent the formation of extensive cica-ces. For this purpose the integument, with the fat, must not only be drawn over, t also pressed into the space in the bone, which is often quite deep. If there ains any unfilled space, suppuration is unavoidable. It only remains to be seen w far it will extend.

The best-performed operation may become an injury, by a slight neglect in the plication of the bandage, and may even increase the deformity. It is therefore gently advisable, to keep the integument and fat well drawn over the field of the peration, with properly-applied strips of plaster, after it has been sufficiently sep-ated from the bone. A firm bunch of charpie should be kept over the bone which as been exposed, and over the sutures, by means of a protective or roller bandage. hus the freshened surfaces of the integument are kept in immediate contact with hose of the bones. Positive experience has taught us that the suppuration may be ms limited, if not entirely restrained, and confined to a very small circumscribed pace, and, at the worst, only fine cicatritial bands are left, which may afterward e sub-cutaneously divided, and, by a gradual displacement of the integument, be tirely deprived of their influence upon the position of the lid.

Authorities.—*Chelius*, Handbuch der Augenheilkunde. II. Stuttgart. 1839. S. 148, 157.—*Am-on*, Zeitschrift f. Ophth. I. S. 36, 529, IV. S. 428, Plast. Chirurgie. Berlin. 1842. S. 192-228.—*aly*, Krankheiten und Missbildungen. I. Berlin, 1843. S. 150.—*Mackenzie*, Traité des mal. d. ux. traduit p. Warlomont et Testelin. I. Par. 1856. P. 269.—*Desmarres*, Traité d. mal. d. yeux. ris. 1847. P. 65.—*Hasner*, Entwurf einer anat. Begründung etc. Prag. 1847. S. 248.—*Arlt*, Die rankheiten des Auges. III. Prag. 1856. S. 368; A. f. O. IX. 1. T. 94.—*Ruete*, Lehrb. der Ophth. I. Braunschweig. 1854. S. 81, 84-98.—*Adams* und *Samson*, nach, Ruete S. 86, 88.—*Bowman*, nach Mackenzie l. c. P. 415.—*Fricke*, nach Ammon plast. Chir. S. 195.—*Dieffenbach*, nach Ammon l. c. S. 206 und *Chelius* l. c. S. 153, 165.—*Graefe*, A. f. O. IV. 2. S. 201, X. 2. S. 227.—*Küchler*, Deutsche Klin. 1865. Nr. 49.—*Pussavant*, Archiv. f. klin. Chirurgie. VI. S. 350.—*A. Weber*, A. f. O. VIII. 1. S. 95.—*Debrou*, Gaz. d. hopit. 1860. Nr. 133; kl. Monatbl. 1866. S. 145.—*Mauvezin*, Arch. gen. de med. 1865. S. 703.—*Graefe*, klin. Monatbl. 1868. S. 427.

TENTH SECTION.

INFLAMMATION OF THE LACHRYMAL APPARATUS.

Anatomy.—We divide the lachrymal apparatus into secreting and conducting parts. The former are the conjunctiva and lachrymal gland, the latter the canaliculi and the lachrymal duct, which again is divided into the lachrymal sac and nasal duct.

The lachrymal gland appears divided into a larger and smaller portion. The former lies in the lachrymal fossa of the roof of the orbit, and is there attached to the bone by an aponeurosis of the tarso-orbital fascia, running backward. Immediately under this aponeurosis lies the smaller portion. Its anterior border reaches to the convex edge of the upper lid. Besides this, there are a variable number of small glandular bodies lying scattered about in the sub-conjunctival tissue near the upper margin of the cartilage and the outer commissure. The lachrymal corresponds in formation with the salivary and milk glands. Its ducts, from six to twelve in number, are as fine as hairs, and open in a row at the outer third of the upper reflection of conjunctiva.

The canaliculi are canals three or four lines long, less than one third of a line in caliber, which consist of a very fine, pale, hard, smooth mucous membrane, containing a few mucous glands (*Rud. Maier*) and pavement epithelium. (*Henle.*) They begin at the prominence which the inner lip of the two lids forms next to the caruncle, in a fine opening, the *punctum lachrymalis.* The mucous membrane here contains a well-developed papilla, the lachrymal caruncle (*Thränenwärzchen*). From this, the canaliculi first run perpendicularly forward, about three fourths of a line from the inner lip of the lid, become horizontal, then converge in a convex arc toward the outer wall of the lachrymal sac. They reach this about the level of the palpebral ligament, and pierce it, either united, near each other, or far apart (*Lesshaft*). They open without valves into the lachrymal sac. The puncta are surrounded by hard, tendinous connective tissue. The perpendicular portions of the tubes are attached to the inner border of the cartilage by connective-tissue filaments, and they, as well as the horizontal portions, are well surrounded by bundles of the lachrymal portion of the orbicularis muscle, and these fibers sometimes run in arcs which turn their convexity to the caliber of the tube, and, by their contraction, open this, or at least keep it gaping (*Wedl*). In many rare cases two puncta have been seen in the same lid, which open into a blind canal (*Graefe*), or into a canal leading to the sac (*A. Weber*, *Zehender*, *Steffan*). Around the lachrymal puncta there should constantly be found a ring-shaped, funnel-like valve sunk in the tube. At the point where both tubes open by a common mouth into the sack, a single or double-lipped vertical valve is said also sometimes to partially close the opening (*Bochdalek*). The lachrymal duct has a much thicker, quite tough mucous membrane, rendered uneven by the numerous mucous fossæ, which contains a layer of ciliated epithelium, but lower down pavement epithelium, and numerous racemose mucous glands (*R. Maier*, *Henle*). Its upper part, the lachrymal sac, is five lines long and two wide. It has a kind of almond shape, as it appears flattened from anteriorly and outward to poste-

riorly and inward, and occasionally so strongly that, in the cadaver, the caliber is absent, or is only a fine fissure. The lachrymal sac lies in the so-called lachrymal canal, between the border of the lachrymal bone and the nasal process of the superior maxilla. More than half its vertical extent is below the level of the inner inferior angle of the bony orbit. The upper half of the sac is crossed by the obliquely-running tarsal ligament. The upper blind sac-like end, the fundus, extends one and a half lines above the upper edge of this ligament. The canaliculi open in the outer wall, behind the latter. The inner wall of the sac, lying next the bone, corresponding to the shape of the lachrymal canal, falls perpendicularly, and becomes the inner wall of the nasal duct. The outer wall of the lachrymal sac occasionally has a superficial recess at its lower part. In most cases this recess is absent, and then the lachrymal sac is very indistinctly, if at all, separated from the nasal duct, as the outer wall of the sac also passes into that of the duct, without any boundary. Still, cases occur where the transition from sac to canal is marked by a protrusion of the mucous membrane, and where even decided contraction exists. These prominences are caused by great development of the periosteum, or of the aponeurosis of the lachrymal sac at the point of entrance to the bony canal (*Arlt*), or represent only folds of the mucous membrane (*Bochdalek*).

The membranous nasal canal is from seven to nine lines long, cylindrical, and somewhat flattened laterally. It is inclosed in the bony lachrymal canal, whose course is curved downward, outward, and backward. The convexity, however, differs almost in every case; sometimes it is more pronounced outwardly, sometimes posteriorly. This depends partly on the perpendicular hight of the upper jaw, on the horizontal width of the nasal cavity, and the somewhat variable position of the inferior turbinated bone (*Arlt*). Besides this, decided differences are caused by the fact that the membranous nasal canal does not by any means always open immediately under the line of attachment of the inferior turbinated bone, but frequently passes still further down between the outer wall of the nasal cavity and the Schneiderian membrane covering it, before opening into the nasal cavity. Cases occur where the opening is found near the floor of the *cavum narium*, deep under the free border of the inferior turbinated bone.

The form of the lower opening of this inferior nasal duct varies exceedingly. If it is far up, close under the attachment of the turbinated bone, it is usually round, oval, or pen-shaped, and is wide open. Sometimes, however, it is much contracted by a very prominent crescentic or circular duplicature of mucous membrane, which causes the lower end of the tube to appear like a blind sac, especially if this end, as not unfrequently happens, is somewhat enlarged, in which case it is often shaped like a horse's hoof. (*Arlt.*)

But if the opening is far below the insertion of the turbinated bone, it is usually slit-shaped; for the walls of the nasal duct are not then kept apart by the bony canal, to which they are attached, but lie on each other in the space between the Schneiderian membrane and the outer wall of the nasal cavity; hence the lower part of the nasal canal appears pressed together antero-posteriorly.

In such cases, duplicatures of mucous membrane are not unfrequently found (*Hasner*), which sometimes spring from above, occasionally from before and behind, again from behind only, but always lie flat on the Schneiderian membrane. They cause the fissure to appear curved, sometimes horizontally, again obliquely or perpendicularly. The lower end of this fissure occasionally stretches out considerably, with gradual flattening, and looks as if the membranous nasal duct projected some distance into the Schneiderian membrane as a shallow trough.

The membranous lachrymal canal is enveloped throughout its entire len close network of rather firm connective tissue, mingled with elastic fibers (This network is very vascular. The vessels, which are intimately connected w of the surrounding bones, which are also very vascular, completely fill the s the mesh-work, and their walls are connected with those of the individual consequently, in the cadaver they do not collapse, but gape open. He section, with the naked eye we may recognize the open mouths of the large branches. The whole tissue acquires, to some extent, the appearance of tissue. At the lachrymal sac itself, it forms a very thin stratum. But in t passage it increases decidedly in thickness, especially inferiorly, so that t passage itself contracts, and its mucous membrane is thrown into nume prominent folds.

Externally, the connective tissue thickens to a hard, tendinous envelop incloses the lachrymal duct throughout its length like a sheath. As far as on the bone, the sheath is lightly attached to the latter, and serves as pe But at the outer wall of the lachrymal sac it forms a sort of aponeurosi clinging every where to the edges of the lachrymal passage, forms it into a inclosed space. This aponeurosis is intimately connected with the offshoo posterior surface of the ligament of the lid, as well as with the sheath of th mal portion of the orbicularis, and is thus much strengthened.

Fig. 80 represents the relative position of the parts in question, in a horizontal s frozen preparation, made through the closed lids and continued through the ligament c and the lateral walls of the nasal cavity. The outer covering of the inner third of the the lid is subsequently removed, to enable us to follow further the palpebral ligament in its relation to the neighboring parts. *a* is the nasal process of the superior maxillary. External to it lies the angular vein, and behind it, the angular artery. *b* is the crest of the lachrymal bone, and *c* the anterior end of the orbital plate of the ethmoid. The ligament of the lid, *d*, *e*, originates from *a*, and, covered by the skin, runs in an arc, convex posteriorly to the inner commissure of the lids, where it divides. The inner lips of the margins of the two lids, of which only the lower, *f*, is here shown, cling closely to the anterior surface of the globe, *g*. The inner part of the lip goes far back, and thus forms a prominence which is crowned by the lachrymal punctum, *h*. This prominence is the more marked, as the caruncle, *i*, appears on the nasal side, and gives the inner border of the conjunctival sac an S-shaped curvature. The posterior convex wall of the ligament of the lid, *d*, *e*, is not regularly bounded, but forms an indefinite number of branched an

Fig. 80.

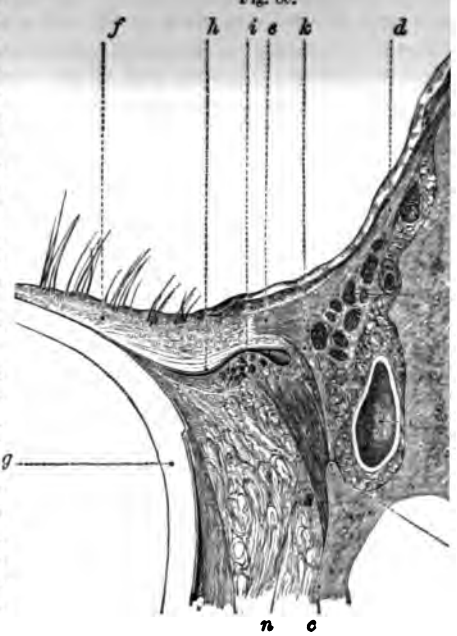

anastomosing tendinous slips and bands, which partly cling to the bone, but partly shoot out posteriorly between the bony wall and the globe. Among these, especially one, *k*, is remarkable for its density. It proceeds directly backward from the external edge of the ligament of the lid, and unites with the periosteum of the crest of the lachrymal bone. A second such process, which does not appear to be constant, however, is found inside of this, but, like the other numerous small offshoots, soon loses itself in the network which fills the relatively large space between the ligament of the lids and the lachrymal sac, *l*, and by its thickness helps to form the aponeurosis above mentioned. In this network fibers of the orbicularis palpebrarum, *m*, originate or become firmly fixed; but further back the meshes or cavities are filled with loose, partly fatty connective tissue. Outside of this network lies the lachrymal muscle, *n*.

The vessels of the lachrymal apparatus, as well as its nerves, are, for the most part, only twigs of branches destined for neighboring organs. Still, the lachrymal gland receives a special branch of the ophthalmic artery, the arteria lachrymalis, and a corresponding vein which opens into the vena ophthalmica. A particular nerve, also, the nervous lachrymalis of the first branch of the fifth pair, goes to the lachrymal gland, and governs its secretions just as certain other nerves govern the secretion of saliva (*Herzenstein*). To its influence is to be ascribed the excessive flow of tears, occurring in certain states of the mind, or when external injuries affect the eye. Under ordinary circumstances the lachrymal glands give but little secretion; the tears which moisten the eyes are mostly from the conjunctiva, and especially from the scattered acinous glands. Their secretory activity explains the trifling influence which the extirpation of the lachrymal gland usually exercises under ordinary circumstances upon the moistening and nutrition of the globe (*O. Becker*, *Lawrence*).

Tears are pure water mixed with a very small amount of salt and albumen. By winking of the lid they are regularly distributed over the convexity of the globe, and so serve to lubricate the anterior and most important surface of the dioptric apparatus. When the lids are open they sink by their specific gravity along the surface of the globe, and collect between the outer edge of the under lid and the surface of the eye in shape of a meniscus, which is described as a "tear-stream" (*Thränenbach*) and in which the upper lid is bathed each time the lids close. Toward the inner canthus the "tear-stream" widens to the so-called "tear-sea," (*Thränensee*). This is the depression between the caruncle and the lid. When the lids are open it appears bounded *above and below;* when closed, *anteriorly* bounded by the prominences of the inner lips of the lids, on which the puncta lachrymalia open. These are constantly in contact with the contents of the tear-sea.

The motive-power of the tears is the orbicularis muscle, including its lachrymal portion. By closing the lids, it presses any excess of tears in the conjunctival sac into the canaliculi, and through them into the lachrymal sac, whence their weight and the pressure from behind carry them into the nose.

As the two folds of the conjunctival sac are every where pressed closely together by the tension of the orbicularis muscle, even while it is in a state of rest, only so much fluid can remain between them as clings to the walls by molecular attraction. This is undoubtedly a very thin, even layer, which only suffices to moisten the surface and to reduce to a minimum the friction caused by the motion of the lids and eye-ball. Any excess of tears is forced by this muscular action into the fissure between the lids, and here collects in the *lacus lachrymalis*. On closure of the lids, the pressure of the orbicularis drives the fluid out. But as the edges of the lids fit closely throughout their length, the excess of fluid collected in the canthus, pressed on from all sides, must necessarily take the only way of escape, that is, through the canaliculi, and any fluid in these must be pressed into the lachrymal duct. Under ordinary circumstances, with a normal secretion of tears and quiet closure of the lids, very little or no fluid passes from the conjunctiva to the lachrymal duct. The excess of tears collecting is a minimum, and the usually excessive evaporation suffices to prevent a collection. But if, from any cause, the secretion of tears is increased, and the eye is overfilled, energetic and continued winking quickly follows, under the influence of which the excess escapes into the nose, whose walls become more moist, and the patient must blow his nose. In weeping, when the secretion of tears is excessive, part of the

product always escapes through the lids and flows over the cheeks, for, on the one hand, the edge of the lids can only retain a limited amount of tears, on the other, the capacity of the puncta and canaliculi is insufficient to take up all in as short a time as is required by the pressure of the lids. Part of the fluid is pressed out between the lids by the rapid and strong contractions of the orbicularis, while the rest streams into the nose.

The simple weight of the tear is very unimportant as a mechanical cause; when the lids are at rest, gravity causes them to run slowly into the nose only when their surface is higher than the highest point of the canaliculi.

It is improper to speak of the *siphon* action or the *suction* of the tears during inspiration, as the conduction into the sac continues unimpaired when its connection with the nares is cut off, or when it communicates freely externally. The latter circumstance, together with the well-known want of valvular apparatus, excludes the *pump* theory. In the same way the capillary action of the canaliculi might carry the tears *as far as* the sac, but not *into* it. A sort of milking action has been ascribed to the muscular filament around the canaliculi (*Arlt*), but this does not exist, and, if it did, the slitting up of the canaliculi would end the action; but this does not stop the conduction.

Nosology.—1. Inflammation of the lachrymal gland, Dacryo-adenitis, has been but rarely observed, once on both sides (*Korn*). Hypersecretion of tears occasionally precedes it for a long time (*Graefe*). It runs a slow, tedious course, and shows itself, by the gradual development of an immovable tumor, of varying hardness, glandular irregularity, usually painless, but often tender on pressure, which appears at the outer and upper portion of the orbit, and which, from its size, is apt to push the eye-ball downward and inward. On anatomical examination, this is found to be a pure proliferation of the lachrymal gland (*Gluge, Warlomont, Rothmund, Lebert, Letenneur*). Sometimes the tumor recedes spontaneously or under the use of remedies (*Heymann, Horner*), but extirpation is usually demanded to prevent injury to the eyeball. Now and then also chronic suppuration occurs, and caries of the roof of the orbit is caused. (*Ad. Schmidt.*) In other cases the inflammation appears phlegmonous, and runs a very acute course. It then appears to be a large abscess. Even in such cases the product may be removed by absorption, and the disease be cured. (*Schön, Haynes-Walton*). But the usual result is rupture and the formation of a deep excavation, which often suppurates a long while, closes repeatedly, and opens anew. (*Alf. Graefe.*) Sometimes it attacks the bone and causes caries. (*Ad. Schmidt.*) Hence the extirpation of the proliferating tissue seems advisable.

In very rare cases, so-called fistula of the lachrymal gland, opening on the outer part of the upper lid or on the conjunctiva, have been observed, as the result of disease of one of the ducts. (*Ad. Schmidt, Beer.*)

We may here mention the very rare occurrence of a tumor analogous to ranula, which is caused by ectasia of a gland-duct. It is the so-called *dacryops.* On eversion of the lids it appears as a bluish, translucent, cyst-like tumor, covered only by conjunctiva, which, by pressure, may be emptied of its watery contents (*Wecker*), but soon fills again, and when the secretion of tears is abundant, it decidedly increases in size (*Ad. Schmidt, Beer, Graefe*).

2. Inflammation of the mouth of the puncta often occurs; for this is not entirely removed from external sources of injury, and is also sometimes directly injured by probing, injections, &c. Moreover, the papillary bodies forming it participate readily in the inflammation of the edges of the lids of the tarsal conjunctiva and lachrymal duct. (*Desmarres.*) Then the same changes occur as in the papillary bodies of the inflamed conjunctiva. Under less intense but continuous change it is not unfrequently greatly hypertrophied, and later shrinks like conjunctival tracho-

mata; with its destruction, the lachrymal punctum contracts or closes. In other cases suppuration occurs, where the product is too rapidly developed. This is observed with especial frequency when neighboring ulcers spread over the mouth of the punctum, or pustules form on it. Then the result is almost always a cicatricial contraction or closure of the puncta lachrymalia. Membranous coating of the latter also occurs congenitally (*Zehender*).

3. The canaliculi also inflame occasionally, as injurious influences act on their mucous membrane from without, as foreign bodies, hair (*Hasner*, *Desmarres*, *Himly*), probes, etc.; or as the mucous membrane is sympathetically affected from the lachrymal sac or conjunctiva; or as a point of inflammation developed in the thickness of the lid, as a suppurating hordeolum (*Desmarres*, *Arlt*), extends over one or other canaliculus. This inflammation often has the character of a catarrh, and by long duration may lead to hypertrophy of the mucous membrane, which again may end with partial destruction of the tube and formation of strictures (*Stilling*). In other cases, on the contrary, the inflammation results in purulent destruction of part of the tube. The result may then be cicatricial contraction and closure, but the pus may break through and leave a lachrymal fistula opening inward or outward (*Himly*, *Desmarres*). Such fistulæ may, moreover, be caused by wounds (*Lecomte*). As a possible cause of inflammation of the lachrymal passages, we must mention the rare occurrence of fatty or chalky concrements, so-called dacryoliths (*Himly*, *Desmarres*, *Mackenzie*), as well as the development of condylomata in the canaliculi (*Graefe*).

The rare development of fungi in the caliber of the canals deserves especial mention as a possible cause of the inflammation of the lachrymal ducts (*Graefe*, *Förster*, *Narkiewicz*). These are very like the *leptothrix buccalis*, which is very common in the cavity of the mouth, and appears to occur in connection with caries of the teeth. It is supposed that this fungus is carried from the cavity of the mouth to the conjunctival sac, since many persons regard the saliva as a means of cure for all inflammatory affections of the eyes, and are accustomed to spread it upon the lids (*Förster*). The collection of such a fungus in the lower canaliculus, where up to this time it has alone been found, betrays its presence by more or less violent irritation at the internal angle of the lids, but still further by a slight rounding off and thickening of the internal portion of the lower eyelid. By palpation there is then felt an almost cylindrical, moderately compressible, firm tumor, involving the thickness of the lid and following the course of the canaliculus. The lower punctum is thus dilated, and if the disease is advanced, when pressed upon, often evacuates a small quantity of creamy matter. Slitting up the canal and cleansing it of its contents suffice to bring about a cure. The mucous membrane of the canal is seen, on being exposed, to be greatly reddened and swollen. The fungus itself appears usually as a yellow concretion varying in size, but sometimes, however, almost black, of the shape of a truncated cone. Its consistence varies very much. Sometimes it is gritty from containing large quantities of lime. In other cases pus appears on the surface. There is no doubt that the formation of abscesses and ulceration with the production of fistulæ may be the consequences. Moreover, it is very probable that the so-called dacryoliths, which have been found in the most various parts of the lachrymal canals (*Himly*, *Desmarres*, *Mackenzie*), among others in the excretory ducts of the lachrymal glands (*Williams*), are partly to be referred to masses of leptothrix with secondary formations of chalk (*Graefe*).

4. Undoubtedly the loose vascular mucous membrane, rich in glands and the granular bodies surrounding the canaliculi, is the most frequent substratum for an

inflammatory change. In most cases this process is merely a slight acute catarrh, which quickly runs its course without important results, and is rarely observed. In other cases the catarrh is severe from the commencement, and then rarely recovers spontaneously, but the process becomes chronic or even habitual. Then the mucous membrane acquires a dark-red color, bordering on blue or brown; it becomes thickened, spongy, relaxed, and tender.

It is said that, in some cases, granulations rise on the surface of the proliferating mucous membrane (*Chelius*, *A. Weber*), which much resemble those of the conjunctiva, but occasionally grow to true polypi, which decidedly distend the lachrymal sac (*Janin*, *Walther*, *Blasius*, *Graefe*, *Berlin*). In some cases, also, the mucous glands have been found much swelled and expanded (*Janin*). Here and there hemorrhages into the sac occur, the coagula gradually thicken, and undergo various changes (*Graefe*).

Muco-purulent product is thrown off from the surface of the mucous membrane lining the lachrymal sac, just as in conjunctivitis. According to the intensity of the process, this resembles cloudy mucus or fluid pus. As this product far exceeds in amount the normal secretion of the mucous membrane of the lachrymal sac, and as, on the other hand, its conduction is greatly influenced by the swelling of the walls of the tube, and the contraction of the nasal ducts combined with it, a misproportion soon arises between the contents of the sac and the amount leaving it, and this occurs the more readily as tears are continually pressed in, and the catarrhal products collect at the deepest part of the sac, thicken from resorption of their more fluid parts, and hence finally close the tube like a cork. Then the outer wall of the lachrymal sac not covered by bone is pressed outward, and the condition, named dacryocystoblennorrhœa, is produced.

But no further difficulty results from this distension; for, just as in exuberant development in the conjunctiva, the tissue of the tarsal cartilage affected becomes lax and expanded; in inflammation of the lachrymal sac, the aponeurosis covering it outwardly is affected, and made sufficiently pliable to give way to the pressure of the increasing contents. The expanded tear-sac then projects from the bony canal, like a tumor, under the ligament of the lid, and presses this forward also.

In many cases the process develops from the beginning with great intensity, and with the symptoms of phlegmon; hence the name dacryocystitis phlegmonosa. The mucous membrane and envelope of the canal then swell, on account of the excessive formation of inflammatory product in their tissue, and soon render the nasal duct and canaliculi impermeable, while large amounts of purulent secretion are poured into the cavity, and collect in the lachrymal sac, which alone is expansible. Hence, this appears as a large swelling, which, however, rarely presents itself in its true contours, as the loose tissue covering it, with the conjunctiva and outer covering, participate in the process, and swell from inflammatory infiltration. Purulent degeneration soon begins in the infiltrated walls of the canal; these are partially destroyed, and so prepared for the pus to perforate them.

Occasionally the loose tissue lying on the outer part of the aponeurosis of the lachrymal sac seems to be the starting-point of the inflammation, and the walls of the duct become affected later in the disease. Such abscesses, developing outside of the aponeurosis, have been called *anchylops*, but in case they have perforated externally, *ægilops*.

Authorities.—*Ad. Schmidt*, Ueber die Krankheiten des Thränenorganes. Wien. 1803. S. 47, 175, 181.—*Hyrtl*, Handb. der topogr. Anat. Wien. 1847. S 123, 126, 128, 130.—*Hasner*, Beiträge zur Phys. und Path. des Thränenableitungsapparates. Prag. 1850. S. 7. 18, 22, 24. Wien. med. Wochenschrift. 1865. Nr. 23.—*Arlt*, Krankheiten des Auges. III. Prag. 1856. S. 377, 386. A. f. O.

I. 2. S. 135 et seq.; IX. 1. S. 65, 67, 70, 87; Wiener med. Wochenschrift. Spitalzeitung. 1862. Nr. 22-33. 1865. Nr. 6.—*Rud. Maier*, Ueber den Bau der Thränenorgane. Freiburg. 1859. S. 6 et seq.—*Henle*, Handbuch der Anat. I. S. 139; II. S. 705, 712, 715; Zeitschrift. f. rat. Medicin. 3. R. 23. Bd. S. 263.—*Henke*, A. f. O. IV. 2. S. 70, 96; VIII. 1. S. 363, 369, 370, 383.—*Stellwag*, Ophth. II. S. 1917; Wien. med. Wochenschrift, 1864. Nr. 51, 52. 1865. Nr. 8, 9, 85, 86.—*Wedl* Wien. med. Jahrb. 1861. S. 39.—*Ross*, Oppenheims Zeitschrift f. d. ges. Medicin. 35. Bd. S. 1, 5.—*Foltz*, Journ. d'anat. et phys. V. 1862. P. 226.—*G. Becker*, Wien. med. Jahrb. 1865. Fachbericht, S. 99, 101, 103.—*Graefe*, A. f. O. I. 1. S. 288, 295; VII. 2. S. 29.—*A. Weber*, kl. Monatbl. 1863. S. 63, 107, &c.; A. f. O. VIII. 1. S. 352.—*Mackenzie*, Traité d. mal. d. yeux. Trad. p. Warlomont et Testelin. I. Paris. 1856. P. 375.—*Zehender*, kl. Monatbl. 1863. S. 394. —*Steffan*, ibid. 1866. S. 45.—*Lesshaft*, Arch. f. Anat. u. Phys. 1868. S. 265.—*Bochdalek*, Prag. Vierteljahrschrift. 1866. II. S. 122.—*Stilling*, Ueber die Heilung der Verengerung, &c. Cassel. 1868. S. 3.—*Herzenstein*, Beiträge zur Phys. u. Ther. der Thränenorgane. Berlin. 1868. S. 22, 25, 29 u. f.—*Laurence*, Congr. ophth. 1868. S. 39, 40.

Nosology.—*Ad. Schmidt*, l. c. S. 63 et seq.—*Beer*, Lehre v. d. Augenkrankheiten. II. Wien. 1817. 184, 591.—*Benedikt*, Handb. d. prakt. Augenheilkunde. III. Leipzig. 1824. S. 154, 159, 152.—*Himly*, Krankheiten u. Missbildungen, &c. I. Berlin. 1843. S. 276 et seq.—*Mackenzie*, l. c. S. 114 et seq.—*Daviel*, Med. Gaz. III. 1829. S. 523.—*Haines Walton*, nach Mackenzie, l. c. S. 117, 137.—*Hasner*, l. c. S. 9 et seq.—*Desmarres*, Traité d. mal. d. yeux. Paris. 1847. P. 854 et seq.—*Graefe*, A. f. O. I. 1. 283, 284; II. 1. S. 224; III. 2. 257; IV. 2. S. 258; VII. 2. S. 1.—*Alf. Graefe*, ibid. VIII. 1. S. 279, 286.—*Heymann*, ibid. VII. 1. S. 143.—*Horner*, kl. Monatbl. 1863. S. 257.—*Gluge*, Jena'sche Annal. f. Phys. u. Med. I. 1849. 3.—*Rothmund*, kl. Monatbl. 1863. S. 264; Jahresbericht. 1861-2. München. 1863. S. 24.—*Schön*, Beiträge zur prakt. Augenheilkunde. Hamburg. 1861. S. 185.—*Arlt*, l. c. S. 390, 392, 393; A. f. O. I. 2. S. 153, 155.—*Ammon*, kl. Darstellungen II. 1838. Taf. IX.—*Stellwag*, Ophth. II. S. 1050 et seq.—*Zander* und *Geissler*, Verletzungen des Auges. Leipzig und Heidelberg. 1864. S. 103.—*Warlomont*, ibid. S. 412 and Presse Med. Belge. 1862. Nr. 33.—*N.* klin. Monatbl. 1863. S. 405.—*Janin*, Abhandlungen u. Beobachtungen über das Auge. Berlin. 1788. S. 111. 275.—*Chelius*, Handbuch der Augenheilkunde. II. Stuttgart. 1839. S. 37 et. seq.—*A. Weber*, A. f. O. VIII. 1. 105.—*Walther*, Neiss. Diss. de fistula et polypo. saco. lacr. Bonn. 1820.—*Blasius*, nach Chelius l. c. S. 58.—*Wecker*, kl. Monatbl. 1867. S. 34.—*Graefe*, A. f. O. XV. 1. S. 324, 331.—*Korn*, kl. Monatbl. 1869. S. 181.—*Letenneur*, Prag. Vierteljahrschrift. 93. Bd. Misc. S. 82.—*O. Becker*, Wien. Augenkl. Ber. S. 162, 177.—*Zehender*, kl. Monatbl. 1867. S. 131.—*Stilling*, Ueber die Heilung der Verengerung, &c. Cassel. 1868. S. 6.—*Lecompte*, Virchow's Jahresber. 1868. S. 505.—*Williams*, Arch. für Augen- und Ohrenheilkde. 1. S. 78, 89.—*Berlin*, klin. Monatbl. 1868. S. 362.—*Förster*, A. f. O. XV. 1. S. 318.—*Narkiewicz-Jodko*, kl. Monatbl. 1870. S. 78.

Phlegmonous Inflammation of the Lachrymal Duct.

Symptoms.—*Dacryocystitis phlegmonosa* at first usually resembles an abscess developed at the inner angle of the eye. At that place, above and below the ligament of the lid, an extensive swelling, not definitely bounded, at first hard, very painful and sensitive to pressure, and subsequently fluctuating, makes its appearance. The integument, swelled by inflammation, hot, deep-red, and tense, is not movable over it. Only exceptionally, when the outer covering is but slightly swelled, we may feel the lachrymal sac expanded by inflammatory products, as a sharply-bounded, hard, sensitive swelling, of the size of a bean.

The lids are also usually much enlarged by inflammatory œdema; they often even appear erysipelatous. The same is true of the conjunctiva, especially of its inner portion, which frequently presents all the characters of chemosis. Besides this, a participation of the Schneiderian membrane is often noticed; the half of the nose affected appears to the patient dry and stopped up, while watery secretions flow from it. The whole body also often participates, with febrile action.

By pressure on the swelling, which usually increases regularly till the moment of perforation, just as in anchylops, nothing is evacuated, either through the canaliculi or nose, since the openings of the lachrymal sac are closed by the swelling of the walls. When the sac is opened, whether spontaneously or operatively, pure pus is evacuated for a long while, unmixed with tears, since, on account of the swelling of the parts and the inactivity of the muscles involved, the conduction of tears is interfered with. Only when the process is receding, and the swelling is much diminished, tears again enter the sac, and are emptied through the perforation in it, while, on the other hand, pressure on the swelling causes purulent masses to ooze out of the lachrymal puncta.

Causes.—Phlegmonous inflammation of the lachrymal sac often develops, primarily, without sufficient evident cause, rarely as a result of injury which has directly affected the sac. It occurs more frequently in the course of facial erysipelas, and it is then difficult to say which disease is to be regarded as the primary.

Quite often it is developed, secondarily, by propagation of inflammatory processes from the neighboring parts. It appears as a result of inflammation in the mucous membrane and periosteum of the nose and antrum, as a result of caries of the surrounding bones, and as a consequence of conjunctivitis. Sometimes, also, it is to be regarded as a metastasis.

Besides this, it is often one of the terminations of lachrymal blennorrhœa, and here usually causes perforation where there is any hindrance to the evacuation of the products.

Course and Results.—The disease generally develops very rapidly and with marked symptoms. It has usually passed its acme in a few days.

1. In rare cases the inflammation recedes without the occurrence of perforation, since, while the production is less, the inflammatory product, already collected, is

removed by absorption, or through the mouths of the lachrymal sac. Then a perfect cure may possibly occur, but usually blennorrhœa of the lachrymal duct remains behind.

2. Sometimes partial ulceration, and subsequently cicatritial contraction of the lachrymal duct, occur, whether a perforation has resulted or not. The upper portion of the nasal duct appears most disposed to this, for at this part we have relatively most frequently been able to observe such cicatrices, and, as their result, contractions and obliterations of the tubes. In some cases, after precedent phlegmonous inflammation of the lachrymal sac, the membranous nasal duct has been found changed, even through a great part of its extent, to a solid tendinous cord, which was placed loosely in the bony canal. (*Hasner.*)

3. As a rule, if an artificial opening is not made for it, the pus breaks through after fluctuation has gradually shown itself in the abscess. Then the inflammatory symptoms soon disappear, and the swelling subsides. After this the perforation may possibly heal up, and a perfect cure even may occur, or an ordinary blennorrhœa may remain. But usually, after the closure of the opening, the phlegmonous lachrymal inflammation soon relapses, and leads again to perforation, as long as the inflammatory process continues and pus is formed in the lachrymal sac.

In the great majority of cases the healing of the perforation is prevented by the persistent flow of muco-purulent secretion, and later by the tears. After weeks or months, the false passage becomes covered with epithelium, and then forms a true lachrymal fistula, which either evacuates pure tears or tears mixed with muco-pus, according as the mucous membrane has returned to its normal condition, or continues in a state of chronic catarrh. These fistulæ usually continue for life, if proper treatment be not instituted.

Usually the pus perforates outwardly, and a so-called external lachrymal fistula results. Several fistulous canals, running in various directions, may form simultaneously. But usually we find only one fistula, which opens under the inner ligament of the lid, and more or less obliquely perforates all the layers to the lachrymal sac. Still, these passages also sometimes run like irregular, tortuous canals, for a long way under the skin, and open at some distance from the lachrymal sac, below or external to it, occasionally even in the vicinity of the outer edge of the orbit.

In some rare cases, the abscess is evacuated into the conjunctival sac. (*Zeis.*) Quite often, also, the pus breaks through the posterior walls of the lachrymal sac, lays bare the bones, and then escapes outwardly, leaving an external fistula. The exposure of the bone in itself is not usually very serious, for, as a rule, it is again coated over after a time. Exceptionally, however, the lachrymal bone participates in the inflammation, and becomes carious. Sometimes there is perforation into the nose, and a so-called complicated external fistula is formed.

It is possible for the pus perforating the sac posteriorly to sink between the tendinous envelope of the sac and the bony wall of the canal, and escape below the inferior turbinated bone, through an ulcerated opening in the Schneiderian membrane (*internal lachrymal fistula. Hasner.*)

Caries and necrosis of the lachrymal bone are occasionally the primary disease, phlegmonous dacryocystitis the secondary. But the latter is not necessarily associated with the former. The ulceration may be limited to the envelops of the sac, and the pus may escape in its vicinity, causing an excavated ulcer, which, for a time, or even permanently, may not communicate with the interior of the sac. We

find caries and necrosis proportionately most often among scrofulous and syphilitic patients. It is then frequently one symptom of a more extensive disease of the bone, viz. ozœna. It is important to notice that, with the cicatrization, after the carious or necrosed portion of the bony canal has been thrown off, the lachrymal duct rarely retains its normal conducting power, as it is always involved in the inflammation; and, even if it does not ulcerate, it will contract.

The Treatment has the same object as in abscesses elsewhere. It is, first, to limit the inflammation, i. e. the excessive secretion, and if possible reduce it to the normal amount. If pus has already collected in or around the lachrymal sac, it is to be evacuated as soon as possible, so as to lessen the number of proliferating elements, and more especially, by relaxing the parts, to place them in a more favorable state for nutrition, and to prevent ulcerative perforations, with their evil results. If the evacuation has already occurred, we should attempt to heal up the fistula in the best manner possible.

1. Besides great attention to the causal indications, strict antiphlogistic treatment, as well local as constitutional, is to be carefully used. At first, when there is great hyperæmia, and particularly where the temperature is much elevated, cold compresses are advisable; but where the symptoms are less urgent, it is sufficient to cover the swelling with a piece of dry linen, and keep the patient on strict antiphlogistic regimen.

2. Slitting up the lower canaliculus is the best means of affording escape to the secretion collected in the lachrymal sac. This should be done as soon as we have reason to suspect that there is any fluid pus in the sac. It is usually done with ease, unless the swelling and tension of the surrounding parts is excessive, and it is not more dangerous than opening the sac from without. Then only a slight pressure from without is required for the evacuation of the contents, and this may be much assisted by introducing a probe into the sac. The result of this proceeding has hitherto proved very satisfactory. The inflammatory symptoms usually subside rapidly, and the pain entirely ceases. The perforation externally is then often aborted, even after part of the surface of the swelling has allowed the yellow pus to show through. Besides, the slitting up of the canaliculus can rarely be avoided, as a lachrymal blennorrhœa almost always remains, which subsequently requires probing of the duct.

Spontaneous perforation, as well as the operative opening of the sac from without, unfortunately almost always leaves a fistula, which is sometimes cured with great difficulty. If we, notwithstanding, choose the latter method, we can not, as in a normal state of the integument, use the middle of the palpebral ligament as the point for the puncture, because this ligament is usually hidden by the swelling. The border of the lower lid is, however, a good guide. On its prolongation, about two lines from the commissure, we place the bistoury or lancet, perpendicular to the surface of the tumor, and, with its edge downward and outward, introduce it, carefully avoiding the inner lower margin of the orbit. If the center of an abscess lying in front of the sac be not exactly in the direction of the puncture, and we fear that the opening is insufficient, we may easily remedy it while withdrawing the knife. To prevent adhesion of the edges of the wound and repeated perforations, we should insert a piece of charpie into the canal, and carefully retain it there, by fastening one end of it to the skin by a strip of adhesive plaster. This charpie must be renewed at least once daily.

If considerable hardness remains after the evacuation of the sac, it is well to use cataplasms or fomentations of warm water, or to fasten a pad of cotton over it till

inflammatory hyperæmia and the swelling of the parts, as well as the flow of , has decidedly decreased. Some recommend a tightly drawn compressive dage (*Arlt*, *Herzenstein*).

It is not well to probe the nasal duct to test its perviousness, immediately after evacuating the . At this time, probing affords us reliable evidence only after long trial, if it does so at all, use the swelled envelops of the passage usually render it impassable for the probe. Moreover, mechanical irritation produced, is not without bad effects on the future course of the disease. same is true of injections, particularly if made through an external wound. At the same there is danger of some of the water escaping into the relaxed tissue on the outer wall of the infiltrating it, and increasing the swelling, and, by intensifying the process, extending the ation beyond the original bounds.

3. If, under this treatment, the inflammatory symptoms have receded more and , and the swelling almost disappeared, and the muco-purulent product mixed tears indicates a catarrh of the mucous membrane of the sac, the treatment ld be that laid down for dacryocystoblennorrhœa.

4. If the abscess has opened spontaneously, and the fistulous orifice is not too far the palpebral ligament, the lower canaliculus may simply be slit up, and any ing tumefaction treated by warm compresses, and then the treatment of blennor- be proceeded with. But if the fistula is long and irregularly curved, or if the has escaped through several openings after undermining the skin, it is advisable it them up on the grooved director, so as to make as short and simple a fistula ible.

5. Caries and necrosis of the lachrymal bone are to be treated as directed in the ter on orbital diseases. The subsequent procedure depends on the condition of lachrymal passages.

More recently it has been recommended to perforate the carious lachrymal bone the widely-opened cavity of the sac by means of a small trephine, and to the mouth of the fistula patulous by the introduction of a rubber bougie until edges of the wound in the bone are healed (*Demarquay*).

Authorities.—*Ad. Schmidt*, Die Krankheiten des Thränenorganes. Wien. 1803. S. 227, et —*Hasner*, Beiträge zur Phys. u. Path. des Thränenableitungsapp. Prag. 1850. S. 31, et seq. *Arlt*, Krankheiten des Auges. III. Prag. S. 401, 415, 416.—*Mackenzie*, Traité d. mal d. yeux. trait par Warlomont et Testelin. I. Paris. 1856. P. 379, 408.—*Zeis*, Zeitschrift für Ophth. . 174.—*Stellwag*, Ophth. S. 1075, 1078, 1081, 1083.—*Arlt*, A. f. O. XIV. 3. S. 281.—*Zehen-*, kl. Monatbl. 1869. S. 100.—*Herzenstein*, Beiträge z. Phys. u. Ther. d. Thränenorgane. S. —*Schweigger*, Berlin. kl. Wochenschrift. 1868. Nro. 47.—*Demarquay*, Centralbl. 1868. S.

2. Blennorrhœa of the Lachrymal Passages.

Symptoms.—*This affection is characterized by a circumscribed, roundish swelling of variable size, which has a broad base, and is firmly situated behind the palpebral ligament, and causes a protrusion of the inner canthus. By pressure upon it, a muco-purulent secretion, mixed with tears, is evacuated from the canaliculi. It is not attached to the integument; hence this is movable over the tumor.*

When filled, the sac often attains the size of a bean, a hazel-nut, rarely that of a pigeon's egg, or over. According to its size it presses the ligament of the lid more or less forward, but also swells out above and below this ligament. When slightly developed, this swelling is only perceptible to touch and sight as a fullness in the angle of the orbit. Then the superjacent movable skin is not at all changed. When greatly developed, on the contrary, the swelling projects with steep walls, and is seen, even at a distance, as a roundish prominence.

The filling of the lachrymal sac varies, moreover, in the same case, according to the external circumstances, and the greater or less facility with which the contents of the swelling may be evacuated. Hence the size of the tumor, as well as its consistence, vary within wide bounds.

In fact, in dacryocysto-blennorrhœa, the lachrymal sac is sometimes found swelled out, hard, and elastic; sometimes the swelling is almost gone, and as soft as dough. When the weather is clear, dry, and warm, that is, under circumstances where the amount of tears to be conducted off is diminished, and catarrhal diseases usually improve, the swelling of the membranous walls of the tear-passages is usually less. Not unfrequently the tumor even disappears, or is much smaller. On the other hand the swelling increases decidedly, and, from the tension of its walls, causes pain, when raw, stormy, damp, cold weather increases the flow of tears and swelling, and secretive action of the mucous membrane of the lachrymal passages.

The tumor also usually diminishes during sleep, or whenever the lids are kept closed for some time, as under such circumstances the catarrhal secretion is greatly diminished, and, on account of the rest of the lids, the flow of tears is stopped. But as soon as the movement of the lids begins again, the swelling reappears, and rapidly increases to a certain point, that is, until the walls of the lachrymal sac have attained a certain tension. Then the conduction of the tears ceases, the excess flowing over the cheeks, and a dropping of the tears, very annoying to the patient, occurs. But as the catarrhal secretion of the mucous membrane of the sac does not cease simultaneously with the cessation of conduction of the tears, the contents of the tumor increase more and more, and the increasing tension of the walls of the sac sometimes shows itself by a feeling of pressure and heaviness, frequently, also, by painful tension, radiating sometimes into the nose, the brow, or the eye-ball. Then it occasionally happens that, under the pressure of the tense-walls of the sac, aided by a strong contraction of the orbicularis muscle, a portion of the contents is evacuated into the conjunctival sac through the canaliculi, and hence this is flooded with a muco-purulent fluid mixed with tears. The result is, of course, a temporary cloudiness of vision, which, returning frequently during the day, greatly annoys the patient, so that in relating his symptoms he usually places this one in the foreground. But the patient gradually becomes better acquainted with his complaint, and learns to render his condition more bearable by emptying the sac from time to time by judicious pressure, and thus as far as possible counteracting the annoyances dependent on excessive collection of catarrhal products and tears.

The evacuation usually occurs only externally, through the canaliculi, as the

nasal passage is generally closed by the swelling of the walls of the duct. Often, however, and especially in the later stages of the disease, the contents of the swelling may be pressed into the nose. Then it depends on the direction of the pressure whether the contents pass upward or downward.

The frequent combination of dacryocysto-blennorrhœa with catarrhal conjunctivitis and blepharitis ciliaris is worthy of mention. These are often secondary, from the contact of the products from the lachrymal passages with the conjunctiva, and the opportunity for the excessive formation of crusts on the edges of the lids.

Causes.—1. Blennorrhœa of the lachrymal passages is very exceptionally developed primarily as a result of external injuries, which have directly affected them. Thus, for instance, it happens that foreign bodies (*Kersten*, *Kleemann*), as snuff, &c., are driven with the air from the nose into the lachrymal passages on sudden expiration, and, remaining there, cause inflammatory irritation of the mucous membrane.

2. Apart from these cases, the disease almost constantly occurs as a *secondary* affection, in the strict sense of the word.

Frequently it is only a termination of phlegmonous inflammation of the lachrymal passages, and then counts the causes of the latter as its own. In such cases dacryocysto-blennorrhœa is usually accompanied by lachrymal fistula. We then also most frequently find strictures of the nasal passage. It is just as frequently developed by a propagation of inflammation from the neighboring parts to the lachrymal passages. Especially important in this regard are inflammations of the nasal mucous membrane, the edges of the lids, and the conjunctiva.

The inflammation of the Schneiderian membrane in these cases may be primary, or may have extended from the pharynx, the subjacent bones, &c. Thus we see catarrh of the lachrymal passages resulting from severe and long-continued nasal catarrh, from impetigo and eczema of the nasal mucous membrane, from influenza and angina, and (inasmuch as the respiratory organs suffer greatly in the acute exanthemata) from rubeola, scarlatina, but especially from variola. (*Ad. Schmidt.*) Not less important in this regard are syphilitic and scrofulous disease of the bones and mucous membrane of the nasal cavity (*Zeissl*), also tumors, polypi, cancer, etc., developing in the nares, pharynx, antrum, etc.

Of the affections of the edge of the lid, the ulcerated and variolar forms of blepharitis ciliaris are particularly to be mentioned, and, of the conjunctival inflammations, severe trachoma. However, conjunctival inflammations, accompanied by great chemosis, lead more frequently to blennorrhœa of the lachrymal sac; and then it is apparently not so much a propagation of the process, as an original sympathetic affection of the lachrymal passages. The inflammation is very extensive from the commencement, and the lachrymal sac is drawn into it.

This supposition is more probable, as chemosis is, in fact, very analogous to erysipelas, and this affection on the face presents by far the most frequent cause of blennorrhœa of the lachrymal sac. Through it the latter disease is distantly connected with pyæmia, puerperal disease, typhus fever, &c.

3. Continued impediments to the normal conduction of the tears are important causes of the disease. In fact, the affection is of very common occurrence, when the inferior opening of the nasal duct is rendered impervious by cicatrices in the mucous membrane; also, if the duct is narrowed by foreign bodies, polypi, &c., or the canaliculi or puncta are obstructed. Experience teaches that even the ever-

sion of the puncta, if it prevents for some time the entrance of the tears, causes and keeps up the disease, and finally leads to atrophy of the walls of the passages.

4. Under similar circumstances, all are not alike disposed to the disease, adults being more so than children, old people more than those in the prime of life, women more than men; and relaxed, pale, debilitated individuals more so than stronger persons. Moreover, persons with flat noses are especially inclined to the disease in question. (*Hasner.*)

Course.—In individuals predisposed to it, especially in relaxed, debilitated persons, lachrymal blennorrhœa often develops itself quite unnoticed. It has usually existed some time, when the patient is made aware of his state by the occasional dropping of tears, by the frequent overflow of the contents of the sac, and the misty vision caused by it. If, however, the disease is developed by the propagation of inflammation from the neighboring parts, it is usually marked from the commencement by slight redness, sensitiveness, and swelling at the angle of the eye.

When the protrusion of the lachrymal sac has reached a certain grade, the inflammatory symptoms soon disappear, and the blennorrhœa continues without further particular change for years, or even for life. In many cases, however, exacerbations occur from time to time, without perceptible cause, show themselves by more or less severe inflammatory symptoms, and, as a rule, result in an increase in volume of the tumor. But on the other hand, the disease occasionally recedes, and under favorable circumstances may temporarily entirely recede, subsequently to reappear suddenly.

Results.—1. Lachrymal blennorrhœa, which has not become chronic, may, under favorable circumstances, recover spontaneously; this is especially true of the disease occurring in children. It is said to go away of itself not unfrequently, at puberty, or during the first months of pregnancy. (*Mackenzie.*)

2. As a rule, however, unless the aid of art be invoked, the disease exists through life. Then, in the further course, the swelling usually increases somewhat, while the constituent parts of the lachrymal passages gradually undergo certain changes, which render a return to the normal state more difficult, and treatment more and more insufficient.

The border of the nasal process of the superior maxillary, which helps to form the lachrymal fossa, is often pressed on and absorbed; and as a similar loss occurs in the crest of the lachrymal bone, the lachrymal canal is then obliterated. (*Arlt.*) The portions of the orbicularis covering the lachrymal sac in front gradually lose their power of contraction, and atrophy, as a result of the pressure and tension to which they are exposed. The same is true of the connective-tissue mesh-work covering the aponeurosis of the lachrymal sac and connected with the ligament of the lid. This is pressed together from behind, and condenses to a more or less tendinous layer, which only becomes again relaxed with difficulty, so that the filaments grown together may separate, and their interspaces again fill with delicate loose tissue.

The mucous membrane and the cavernous tissue of the lachrymal passages hypertrophy under the continued proliferation of tissue, and the latter granulates occasionally, much like a trachomatous conjunctiva. They may remain in this state for years, or even for life. Sometimes, however, especially in high degrees of protrusion of the sac and its coverings, they gradually lose their peculiar character, and their hypertrophied tissue is destroyed. The walls of the sac then change to a slightly vascular, pale, hard, and thick tendinous membrane, which intimately unites with the fibrous envelope, and, in combination with the latter presents a homogeneous stratum of relatively slight thickness. The secretion now changes its character; it becomes a translucent yellowish or brownish glue-like substance, which, as a result of the absorption of its fluid constituents, may thicken to the consistence of half-cooled glue. This condition was formerly

described as "rupture and dropsy of the lachrymal sac, or hernia and hydrops sacci lachrymalis." (*Ad. Schmidt, Beer.*) As may be easily understood, its occurrence is much favored by impassability of the nasal duct, and, in the state in question, this is quite a frequent occurrence. Apart from the cicatricial contraction and closure, which is often caused by partial ulceration of the envelopes of the duct, we must take into consideration the shrinkage that usually succeeds hypertrophy of the mucous membrane, in the vicinity of the nasal duct; and as the collecting secretion and tears driven in by muscular action do not have the effect of dilating, as they do in the lachrymal sac, nothing prevents increasing contraction of the caliber. According to this, hydrops sacci lachrymalis ranks with the "retention cysts" of the larger canals. (*Virchow.*)

Where the flow of tears is permanently impeded by eversion or closure of the puncta or canaliculi, concentric stricture of the lachrymal sac occasionally occurs, as, with continued shrinking of its walls, the secretion also stops. (*A. Weber.*)

3. The inflammatory exacerbations that frequently occur in the course of the lachrymal blennorrhœa, have the greatest influence on the subsequent progress of the disease. These inflammations often recede, it is true, without leaving any decided traces. Frequently, however, they lead to suppurative perforation. This opening not unfrequently closes again, so that the former condition is restored; but just as often a lachrymal fistula remains. These intercurrent inflammations, with or without suppurative perforations, often cause partial ulceration of the inner wall of the sac, but particularly of the membranous nasal duct. This of course exposes part of the bone. Then the roughness felt on probing the parts may readily cause a diagnosis of caries. Such places usually coat over very soon, or are covered by the contraction of the ulcerated wall of the sac. The subsequent results are cicatricial contractions, strictures, and, exceptionally, obliteration of the nasal ducts.

4. In very rare cases dacryoliths or lachrymal calculi form in the lachrymal passages. These may excite severe inflammations, and thus prove the direct cause of the state described in paragraph 3. (*Desmarres.*)

5. Later, lachrymal blennorrhœa is also sometimes combined with emphysema of the lachrymal sac, which is characterized by air passing into and expanding the sac at every strong expiration, and particularly on blowing the nose, sneezing, &c.; or the contents of the sac may be blown in bubbles through the puncta. Impairment of the valve at the nasal end of the tube has been considered (*Hasner*) as the cause of this symptom; this is, however, a mistake. If, with this extraordinary permeability of the tube, a wound or ulceration of the wall of the sac occur, an air-tumor readily forms in the sub-cutaneous and submucous tissue of the canthus. (*Arlt, Eau, Graefe.*)

The Treatment aims at removing the existing disturbance of nutrition, and the restoration of the protruded sac to its normal size. Another indication is the removal of all impediments to conduction. Where this does not appear practicable, the suffering of the patient, caused by the disturbed conducting power, must be diminished as much as possible.

1. For fulfilling the causal indications, the constitutional and local treatment of ozœna, the removal of polypi or other outgrowths from the nose or antrum, the cure of chronic inflammation of the Schneiderian membrane, &c., are necessary. It is very rare that we have to remove foreign bodies, lachrymal calculi, polypi, &c., from the tear-passages themselves.

2. In simple blennorrhœa of the lachrymal sac, the first indication is to prevent the collection of tears and diseased secretions in the sac; for such collections directly prevent the contraction of the sac to its normal size, and thus become an immediate hindrance to the return of the normal conditions of the mucous membrane. Moreover, there is no doubt that the abnormal tension, and especially the frequent

change from tension to relaxation of the walls, must be regarded as a direct injurious influence, keeping up and increasing the inflammation. In fact, experience teaches that simple blennorrhœa of the tear-passages may be cured by permanent relaxation of the lachrymal sac.

a. The remedy most to be recommended is, undoubtedly, the slitting-up of one canaliculus, and subsequently repeatedly probing the nasal duct. (*Bowman.*) By slitting up the outer part of the canaliculus, which is thickly spun around with muscular fibers, the evacuation of the lachrymal sac upward is greatly facilitated, but by probing the nasal duct the passage downward is opened, and the conditions of nutrition are favored in every way.

To render the slitting-up more easy and certain, it is well first to dilate the punctum in question by a conical probe, or by the successive use of several probes increasing in size.

In this probing, it must be remembered that the canaliculi run about three fourths of a line nearly perpendicularly, but somewhat outward from the puncta; then, forming nearly a right angle, they become horizontal; then, respectively ascending and descending, they reach the wall of the sac, where it is covered by the palpebral ligament. Hence, after drawing the lid downward and outward, we introduce the probe perpendicularly through the punctum, then turn it horizontally and carefully push it obliquely downward. By neglect of these rules we may easily cause injury—may even perforate the canaliculi, and form false passages.

The end of the probe must be constantly held against the anterior wall of the canal and towards the fundus of the sac, and be directed relatively towards its inferior openings, whilst the convexity of the probe is applied to the surface of the globe.

If the punctum is wide enough, the blunt-pointed blade of a pair of angular or straight scissors should be carefully introduced, and, while the lid is somewhat everted, should be passed along the tube to a point behind the base of the caruncle, and the canaliculus should then be slit up from the conjunctival side by a single cut of the scissors.

If the puncta have closed from cicatrices, which very rarely happens, the opening must be restored by thrusting a blade of sharp-pointed scissors through the papilla from the inner lip of the lid, or by making a cut obliquely to the perpendicular portion of the canaliculus, about half a line from the edge of the lid. (*Bowman.*) The latter is especially necessary when the closure has occurred from extensive cicatricial growth. On the cut surface the opening of the tube may easily be accomplished by probing, and there is then no further obstacle to the slitting up.

Moreover, the canaliculi may be slit with advantage to counteract the annoying dropping of the tears when there is no blennorrhœa of the lachrymal sac, as often happens when the puncta have been cicatricially contracted or closed by precedent inflammation of the edges of the lids, or from any other cause; or if the edge of the lid does not come close to the globe, but is, however, not far enough off to render necessary or advisable a more extensive operation.

If the punctum be only somewhat contracted or covered by a layer of epidermis (as occurs not unfrequently), simply probing, as above advised, usually suffices to arrest permanently the annoying dropping of tears. [A narrow, probed-pointed knife (Weber's knife) is perhaps more conveniently used for dividing the canaliculus than the scissors.]

To gain entrance to the sac, the lower canaliculus is usually slit up. Some, however, prefer the upper. In favor of the latter choice is the fact, that continued probing, as is necessary in the treatment of lachrymal blennorrhœa, by great tension of the inner angle, readily causes cicatricial closure of the inner end of the tube, and it is most important to preserve the permeability of the lower canaliculus, as this acts the principal part in the conduction of the tears. Where an external fistula already exists, the danger of obliteration causes it to appear preferable to probe

through the lower, but at the same time to slit up one or both of the canaliculi to facilitate the evacuation of the sac. Of course, the external opening must then be maintained by the introduction of a greased tent.

This tent should not be longer than is necessary to keep it in the wound. If too long, the end curled up in the lachrymal sac acts on the mucous membrane as a foreign body. The greasing is requisite to prevent closure of the fistulous orifice by the drying secretion. To prevent the tent from falling out, we should fasten its external end to the cheek by adhesive plaster.

For probing we may use a series of graduated sounds of malleable metal, ivory, or horn, rounded at one end, bulbous, of equal thickness throughout, and of sizes varying from that of a thread to that of a moderately thick cord (*Bowman*).

[Dr. H. W. Williams, of Boston, speaks highly of probes "made with bulbous extremities, of the six sizes of Bowman's scale, but with the third of the probe nearest the end much more slender than the remaining portion." "The probes should be of alloyed silver, not too pure, that they may have an elastic flexibility without being liable to bend too readily."]

We first take a fine probe, curve it slightly, and, while drawing the lid downward and outward, pass it obliquely (nearly horizontally) through the divided canaliculus to the inner wall of the sac. When we feel it against the bone, turning the convexity backward and inward (Fig. 83), we pass it down along the wall of the sac, and very carefully through the upper opening of the nasal duct.

It is often difficult to find the opening at first, as the membrane is much puffed out, and the probe often passes into the folds surrounding the opening. Much searching around, or even roughly bearing on, or strongly pressing forward the probe, are highly injurious. The inflammation is thereby greatly encouraged, the swelling of the mucous membrane increased, so that the object of the probing is directly opposed. Occasionally the mucous membrane is even pierced, and a false passage formed, the bone partially exposed, and so a possible cause presented for cicatrices, which greatly endanger the functional power of the tear-passages. Such injuries of the mucous membrane show themselves by hemorrhage from the canaliculi, or from the nose.

Fig. 83.

As is well understood, they are most easily caused by very thin probes, since their ends are relatively sharper, and hence it is better to employ the thin medium sizes.

If we do not succeed in reaching the nasal duct without great pains, it is better to give up the attempt at once, especially when the existing inflammation requires some attention. Usually, after slitting up the canaliculus, a diminution of the inflammatory action occurs, the passage becomes more pervious each day, the lachrymal sac fills up but slightly, the difficulties of the patient diminish, and finally probes may be used without danger, and with evident advantage. In probing the nasal duct, it must be remembered that it does not pass directly down, but somewhat backward and outward. When the probe has entered

some distance into the nasal duct, its upper end (Fig. 83) should lie near the supra-orbital notch, and should remain in this position without aid from the finger.

While lying in the passages, the probe should excite no pain or disagreeable feeling of pressure. Where this does occur, it has probably caused some injury, or is not suitably curved. It should always be borne in mind that the shape of the nasal duct varies greatly, and almost every case requires a different curve of the sound. Whoever neglects this will constantly find strictures that do not exist. But, if the probe should be once forced into the nose, the patient will scarcely bear it, as the feeling of pressure extending to the teeth soon increases so as almost to cause fainting.

It is very important, also, to satisfy ourselves that the probe has been actually introduced into the nose. To this end it is not always sufficient to measure the length of the part introduced, and compare it with the distance of the opening of the lachrymal duct from the floor of the nose, since the duct, by reason of its oblique direction, is sometimes considerably longer. To prove this, we may introduce a second sound below the inferior turbinated bone, and seek to touch the end of the first.

When the probe has reached the nasal cavity, we should leave it there a few minutes before withdrawing it. The next day the operation is to be repeated, and so on, but the time the probe is left in position is to be increased by degrees to a quarter of an hour, and thicker ones are to be gradually used.

In general, however, it is scarcely ever necessary to resort to the very large probe (5–6 Bowman). On the contrary, such a large caliber might easily become dangerous from the excessive laceration of the canals.

In simple blennorrhœa of the lachrymal sac, which is not too chronic, the muco-purulent secretion usually diminishes under this treatment within a few weeks, acquires more and more the character of pure mucus, and finally dries up, while simultaneously the annoying dropping of tears ceases. If the condition approaches such a termination, it is well to undertake probing only at long intervals. It should not, however, be entirely dispensed with, even when the blennorrhœa appears perfectly cured, as closure of the internal opening of the passage easily occurs; and, for fear of this occurrence, it is well to continue the probing every other week for a long while, to prove and maintain the perviousness of the passage. For this purpose it is well for the patient to learn to probe himself, as is readily done by those who are at all dexterous.

Where the blennorrhœa is very obstinate and the discharge very free, besides probing the duct, we may use astringents, such as catgut, soaked in a weak solution of nitrate of silver (*Rau*). But we may readily use astringent injections through the divided canaliculus, or by the external fistula through which we probe. Weak solutions of sulphate of zinc or copper, one to three grains to the ounce of water, are ordinarily used. Nitrate of silver, tincture of opium, and tincture of iodine, although much recommended, are objectionable, as the passage of part of the fluid into the pharynx can not always be avoided; hence serious accidents may arise. To favor the astringent action as much as possible, it is well to precede the application of the remedy by an injection of warm water, to wash out the tear-passages. The injections are made with the lachrymal syringe, a small glass syringe with a silver nozzle, which terminates in a fine curved tube.

Instead of the syringe we may use a small bag of vulcanized caoutchouc, which terminates in a fine tube (*Jaesche*).

Actual cauterization of the wall of the sac, with nitrate of silver or with sounds of laminaria digitata impregnated with it, is scarcely necessary (*A. Weber*).

It is also said to be of advantage to fill the tear-passages several times daily with compressed air by forced expirations, with closed nose and mouth, and thus to empty the secretions contained in them upwards (*Alf. Graefe*).

Others employ an injection syringe with a very thin nozzle, in order to be able to impel the fluid into the tear-passages with greater force (*Herzenstein, Alf. Graefe*).

[The nasal duct may be syringed through a hollow Bowman's probe. The nozzle of the syringe is connected to the probe by a bit of rubber tubing. *Wecker.*]

If in consequence of continuous probings, which finally have been neglected for a long time, after complete cure of the blennorrhœa of the lachrymal sac, closures of the internal opening of the tube have occurred, which usually bring along with them a return of the blennorrhœa, the resulting cicatrix must be perforated by a boring motion with a thin metallic probe introduced into the incised canal, and we must again resort to probings, or slit up the second canal, in order to gain an opening. When both canals are closed at their internal opening, and the perforation of the cicatrix with the probe does not succeed, it is well to introduce a narrow bistoury into the lower canal, previously slit up, and thereby split the sac-wall, in order to open the way for the probe.

b. In simple blennorrhœa of the lachrymal passages, the daily injection of astringent solutions, in connection with the introduction of probes into the nasal duct, from an external fistula, or, if the latter does not exist, through an artificial sac, enjoys an old and well-deserved reputation (*Richter*).

The opening of the lachrymal sac is best accomplished by a sharp-pointed bistoury or a lancet. The instrument is to be introduced close under the middle of the palpebral ligament, and nearly perpendicular to the surface of the swelling, and the wound enlarged by withdrawing the knife outward and downward. It should not be introduced deeper than is necessary, and should only be done when the sac is full, for fear of wounding the posterior wall of the duct. That the lachrymal sac has been actually opened, is readily seen from the escape of tears and muco-pus through the opening, as well as by the collapse of the swelling.

After the opening we should prove the perviousness of the nasal duct by probes. If it is found pervious, at first fine catgut bougies, then larger ones, are passed in and left for twenty-four hours, and are then replaced by others. Each change of the gut should be preceded by injections of warm water, followed by an injection of a slightly-astringent solution. The piece of gut used must be long enough to extend into the nose, and for the other end to be fastened to the cheek by a piece of adhesive plaster. When the morbid secretion has been arrested, a piece of lead wire (Scarpa's lead probe) should be introduced and worn for a time, so as finally to close up the fistula.

The final results of this treatment, which has been recently discarded, are certainly not inferior to those of the method before described (*a*), and quite recently it has been again advocated (*Secondi*). Still, wearing a plaster for weeks or months, and a steady purulent discharge, which dries into crusts, is very annoying to many patients, and explains the preference for the use of probes through the canaliculus. Any one not having sufficient dexterity for the latter does better with the catgut; at least, he can not injure the patient as readily.

The use of filamentary bougies instead of catgut (*Ad. Schmidt*) is more troublesome and hardly so useful, as the swelling of the latter is very favorable for the dilatation of the duct.

c. There is a bloodless but less trustworthy method that can only be used at the very commencement of the disease; that is, as soon as any collection forms in the sac, to drive it into the nose by pressing on the swelling from without, and to use astringent solutions frequently during

the day. Injections of astringent solutions, as well as probing the duct through the *undivided* canaliculus, are useless. It is difficult to employ these methods without wounding or at least greatly irritating the latter.

d. Probing and injecting the duct through the nose has also been advised (*Laforest, Gensoul*). For this purpose catheter-like instruments are used. This mode, however, offers no advantage over that through the divided canaliculus or through an external fistula. Moreover, its performance is much more difficult, particularly as the inferior opening of the nasal duct varies greatly, as well in form as in position. Hence there is no great practical value in the proceeding.

e. Recently the leaden probe of Scarpa has by many been again resorted to. While, however, this was previously introduced into the nasal duct, through an opening in the external wall of the sac, the stilet now used in place of it, formed of soft silver, should be introduced into the sac through one of the incised canaliculi. The probe should be spindle-shaped, more than an inch long, and its greatest thickness should vary according to necessity between three-quarters of a line and two lines. The lower end should be knobbed, the upper end flattened, in order that after introduction into the sac it may easily be bent over upon the surface of the lid with a pair of forceps, and thus the probe be prevented from slipping down into the cavity of the nose. Many employ such probes or styles in all varieties of blennorrhœa of the lachrymal sac, after the sac has been habituated sufficiently to the irritation of a foreign body by the previous treatment by Bowman's probes, in order to dispense with the daily introduction of the probe. The style may generally remain "in situ" several days without injury, during which time the patient does not need medical interference. After the lapse of this period, however, the style should always be removed, in order to cleanse the lachrymal sac by injections of water, and bring it in contact with astringents (*Schweigger, Jaesche, Warlomont*).

Others regard such styles as particularly indicated in strictures, and begin the treatment from the start with their introduction, since they open the way for them in case of necessity by a forcible probing of the sac. The style is then allowed to remain, only being removed from time to time, in order to try the permeability of the nasal duct and to cleanse it properly.

Where, however, the secretion is very abundant the style is to be removed daily, in order to inject the sac with astringent solutions. After several weeks it is said to be always necessary to increase the caliber of the style, as it soon becomes loose (*Williams, Green*). Inasmuch as this mode of treatment likewise takes several months without insuring success, and, moreover, is begun by a very painful operation, and during the entire course must annoy the patient not a little, it can scarcely be preferred to the treatment by probes.

3. In severe and old cases, with great dilatation of the sac, restoration to the normal state requires a long time, if it be not impossible on account of the changes in the mucous membrane, but still more from the contraction and ulceration of the layer of connective tissue covering the sac externally and anteriorly. This resumes its normal state with difficulty; but often its contraction is only marginal or incomplete, if new collections of secretion be immediately prevented by opening the sac or slitting up a canaliculus. But, as long as the wall of the sac is relaxed, the amount and quality of the secretion does not become normal, and the blennorrhœa continues. It is therefore advisable to diminish the wall of the sac by an operation. For this purpose, the distended sac should be opened with a bistoury, and, starting from the puncture, we should, with the scissors, cut out a myrtle-leaf-shaped piece from the wall and the subjacent layers, skin included; the long axis of this piece should run from the middle of the tarsal ligament, outward and downward (*Bowman*). The wound rapidly closes, except a small opening, and even this will close if we probe the duct through a divided canalicus. The closure is much favored by wearing a protective bandage, which presses a small, hard charpie pad against the canthus.

Instead of cutting out, many recommend a partial destruction of the outer wall of the sac with nitrate of silver, caustic potash (*Critchett*), chloride of antimony (*Secondi*), etc. But it is too difficult to limit their action, and the opening of the duct, or the entrance to the nasal duct,

may be cicatricially contracted or even closed. Causing ectropion of the lower lid and punctum, to limit the conduction of tears into the duct (*A. Weber*), is at least superfluous. This does not prevent filling up of the sac, but rather favors it, for the withdrawal of the tears, which should dilute it, permits thickening of the muco-purulent product of the walls of the sac, and closes the exit.

4. Contractions of the nasal duct, dependent only on inflammatory swelling and hypertrophy of the mucous membrane, scarcely require special treatment, as they usually disappear rapidly under the treatment for lachrymal blennorrhœa described under 2. *a*, so that the use of probes of increasing caliber becomes easier each day, and finally fluids injected pass in a full stream through the nose. Even if the nasal duct has already begun to contract from destruction of its tissue, or if, from partial ulceration, tendinous cicatrices have formed, which contract more and more, and cause a stricture at some part, probing daily often suffices to restore the normal state, or at least to dilate the contracted part and stop further contraction. But then the probing must be continued for months in order to fulfill the purpose.

Years ago attempts were made to render permeable the lower part of the tear-passages, by healing the opening over a metallic tube (*Dupuytren*). These tubes were made of gold or silver, and of the shape of the nasal duct, and had at their upper end a small border, to give them a point of support at the upper opening of the duct, and prevent their sinking in. After the improvement of the blennorrhœa in the usual way, and a sufficient dilatation of the nasal duct, these canulæ were introduced, and the fistula caused to heal up over them. Many patients wore them for a long time (*Wecker*, *B. Ruete*). [At a meeting of the New York Ophthalmological Society, we heard Dr. Edward Delafield relate a case where a tube had been worn for thirty years.] In others, however, the bony passage wore away under the pressure, and the canula, becoming loose, sunk down. In others, again, the most troublesome diseases of the bones occurred, rendering the removal of the canula necessary. The results were never permanent, as the canula became stopped up by lachrymal calculi, and the disease of the duct returned in an increased degree. In some cases the contents of the sac made for themselves a passage alongside of the inclosed and obstructed canule (*Fried*, *Jaeger*).

It can not be too much insisted on, that an entire closure of the nasal duct is an excessively rare occurrence, and that, by repeated attempts with probes of different curvatures, we may almost always find a permeable opening in the contracted part, which will permit us to use the treatment by probes (2. *a*), and after a time the treatment by bougies (2. *b*). But these two methods accomplish all that we can reasonably hope for. The various, and sometimes very artificial, operations recently proposed were hardly announced before they were eagerly seized upon.

All attempts at dilatation by large probes (*A. Weber*, *Alf. Graefe*), by peculiarly constructed *dilators* (*Herzenstein*), by *wax bougies*, and *elastic catheters* (*A. Weber*, *Jaesche*), by *catguts* which have been saturated with nitrate of silver (*Rau*), by probes of *laminaria digitata* (*Critchett*, *A. Weber*), are especially to be avoided as entirely superfluous. They are also to some extent dangerous, as their introduction into the lachrymal sac presupposes very enormous dilatations of the internal end of the canaliculus, or the actual incision of the latter and of the sac-wall, also lacerations or incisions in the nasal duct, and therefore, on the whole, very painful procedures for the patient.

5. If we once meet with a real obliteration of the nasal duct, then the perforation of the cicatrix is to be attempted. To this end the sac is first to be incised from the outside, and then a way is to be opened by a fine-pointed knife, which is plunged into the nasal duct, in order afterwards to be able to introduce the probe and proceed towards the cure.

The introduction of the knife through an incised canaliculus is not to be recommended, since a very extensive wound at the opening of the tube into the sac, and, moreover, a violent laceration of the surrounding parts are necessarily caused.

Many regard the probing as superfluous or even injurious, and think that a complete cure can be gained simply by incising the nasal duct, when a stricture is present, by means of a narrow knife of the shape of a right-angled triangle, in several directions as far as the swollen mucosa, which they attain, by allowing the knife to slide up and down several times, at the same time rotating it upon its axis (*Stilling*, *Warlomont*, *Williams*).

If, however, the nasal duct is obliterated for a greater distance, and contracted to a firm tendinous cord, little is to be expected. The knife then never penetrates the axis of the cord, but rather passes through the wall of the sac on one side; in the most favorable case a false passage is opened close to the bone, which can only be connected with the nasal cavity by a wound in the Schneiderian membrane. The swollen mucosa of the latter offer, however, very great difficulties to the production of a permanent fistula.

This circumstance renders unreliable the operation for perforating the lachrymal bone (*Richter*), which was popular ages ago, and has again recently been advocated. (*Foltz.*) Still, it can not be denied that, if daily probing is continued long enough, a permanent communication may be obtained between the sac and the nasal cavity. In cases where the closure of the nasal duct followed caries of part of the superior maxillary, a fistulous communication between the cavity of the sac and the nose, or between the former and the antrum Highmorianii, was frequently attained, and even made permanent, as it seemed.

6. The healing up of external lachrymal fistulas, whether dependent on suppurative perforation or on an operation for making a passage to the duct, is not generally difficult, provided the conducting power of the nasal duct, or of the passage taking its place, remains, and the regurgitation of the contents of the sac through a divided canaliculus, can easily occur. In simple blennorrhœa of the sac, closing of any existing fistula frequently occurs without any treatment, when a divided canaliculus is used for probing. Those fistulas that have long been used for injections and probes are usually somewhat more obstinate. In such cases, as well as where the fistula has coated over, the walls must be freshened before a cure can be expected. For this purpose, a thin stick of nitrate of silver should be passed deeply into the sinus, and moved about till we feel certain there will be a deep slough. A day or two after, the slough should be removed by injections of tepid water or forceps, and the wound closed, as before advised.

The cure may be much favored by painting collodion over the external opening of the fistula.

Instead of cauterizations, the walls of the fistula may be dissected out (*A. Jaeger*). Still this procedure is more troublesome and more painful to the patient.

7. Destruction or obliteration of the lachrymal sac daily loses supporters in proportion as the methods of treatment of its diseases improve, and particularly as dexterity in handling the probes increases; while, quite recently, in simple lachrymal blennorrhœa that was at all obstinate, the sac was obliterated without hesitation, "because it was quicker." (*Graefe.*) At present there are many oculists who doubt if the operation should ever be done. (*Bowman*, *A. Weber*, *Jaesche.*) From the above, we may certainly suppose that this operation is only indicated in the rarest cases, and should be the last remedy resorted to, when all attempts to give a certain amount of permeability to the conducting apparatus have failed, and the existence of a constantly filling and rupturing swelling, or a constantly discharging external fistula, become unbearable to the patient. But we must be very careful about asserting that it is absolutely necessary; for there is nothing more mortifying to the attending physician, than when he has declared a disease of the

sac incurable, and when he has attempted obliteration, to have it get well with restoration of the conducting power. Such cases do occur. Even in extensive cicatrization, as a result of caries or necrosis of the neighboring bones, in hydrops sacci lachrymalis with complete closure of the upper opening of the nasal duct and of the canaliculi, that is, under circumstances which are usually considered incurable, after unsuccessful attempts at obliteration, the duct has again been rendered pervious, and even a false passage into the conjunctival sac formed, the fistula closed up under repeated probing, and a permanent conduction maintained. Of course, such occurrences were more frequent when obliteration was still fashionable. In these cases, fortunately, a suitable method of operation had not been chosen, and only apparent closures occurred, which gave a chance for the passages to open again.

The obliteration of the lachrymal sac is very difficult, as long as tears are constantly pressed through the canaliculi. These make for themselves a passage through the granulations, that shoot up after cauterization of the mucous membrane, so that a fistula always remains. Hence a considerable portion of the canaliculi must be cauterized before, or at the same time that, the sac itself is destroyed.

To close up the lachrymal sac, its inner wall must slough off entirely, to a certain depth. The best remedy for this purpose is nitrate of silver; chloride of antimony, strong mineral acids, &c., do not answer so well, as they are less easily applied, and the limitation of their action is more difficult. The actual cautery, as well as galvano-caustic, answer well; but they frighten the patient.

To use the nitrate of silver most successfully, the outer wall of the lachrymal sac must be slit up as far as possible; if an opening already exists, it should be enlarged by compressed sponge. Then a stick of nitrate of silver is to be introduced into the sac, and its walls and the external opening very thoroughly cauterized, so that we may be certain of a thick and complete eschar. The reaction is usually moderate, and is subdued in a day by cold compresses. At the end of forty-eight hours, the eschar projecting into the outer opening of the fistula is to be separated from the walls of the duct by a spatula, and removed by forceps introduced far in. Under careful traction, the whole eschar may usually be drawn out connectedly.

In order, if possible, to attain closure by the first intention, a wad of charpie, firmly pressed to the size of a bean, is to be laid over the region of the lachrymal sac, a larger and less compact wad placed over this, and the whole secured by an elastic monocular bandage, which is to be drawn tight, and kept securely in its place. The object of the bandage is not only to keep the edges of the wound in apposition, but also to prevent movements of the lid.

It is of the greatest importance that a thick and continuous eschar be produced, and that it be removed as a *whole* from the wound after forty-eight hours; for all that remains must be removed by suppuration, and this greatly interferes with healing. The neglect of this rule and of the pressure-bandage, as well as neglecting to obliterate the canaliculi, is the cause of the long time hitherto required for the cauterization of the lachrymal sac.

The lachrymal sac is not always destroyed by this operation. In spite of all care it sometimes fails, especially in cases where suppuration occurs or the canaliculi remain pervious. Then the whole proceeding must be repeated.

If granulations grow from the wound, they must be cauterized with nitrate of silver, and kept in subjection by tincture of opium. If the inflammation be too severe, it must be treated by active antiphlogistics. The occurrence of erysipelas is unfortunate; the patient's life may even be endangered by it.

Orbital abscesses have also been observed as consequences, which have involved the optic nerve and caused blindness. (*Graefe.*)

The dropping of tears, which continues after cauterization of the sac, usually diminishes, so as not to annoy the patient much, as it only becomes apparent when there is increased secretion.

It would be moreover a grievous deception to believe that in this way the lachrymal sac is always immediately destroyed. In spite of every care, this does not succeed in some cases, especially when suppuration sets in or the canaliculi remain permeable. The whole procedure must then be repeated.

More recently the extirpation of the lachrymal sac in connection with the transfixi canaliculi has been proposed instead of the destruction of the sac. To this end the the sac should be widely opened, and the sac then be dissected up from its conne round (*Berlin*). The procedure is very difficult on account of the abundant hemorr affords moreover no surety against the production of a lachrymal fistula.

The proposal, to endeavor to obtain the cure of obstinate blennorrhœa, fistula extirpation of the lachrymal gland, deserves particular mention on account of its si It is supposed that favorable results are thereby to be attained, but it is concede many cases a scarcely curable ptosis of the upper lid and even limitations of the late sions of the globe would be the consequences (*Laurence*).

Authorities.—*Ad. Schmidt*, Krankheiten des Thränenorganes. Wien. 1803. S. 248 238, 310, 323, 329, 342.—*Richter*, nach A. Schmidt, l. c. S. 301, 343.—*Beer*, Lehre v. krankheiten II. Wien. 1817. S. 151.—*Hasner*, Beiträge zur. Physiol. und Path. des Thrä ungsapp. Prag. 1850. S. 43, 53, 60, 66–88, 408, 413; A. f. O. I. 2. S. 153, 155, 157; Zeits Wien. Aerzte. 1860. Nr. 24; Verhandlungen der ophth. Versammlung zu Heidelberg. 1 Wien. med. Wochenschrift. Spitalzeitung. 1862. Nro. 22–33.—*Stellwag*, Ophth. II. S. 1 Wien. Aerzte. 1860. Nr. 24; Verhandlungen der ophth. Versammlung zu Heidelberg, 1 Wien. med. Wochenschrift. Spitalzeitung. 1862. Nro. 22–33.—*Stellwag*, Ophth. II. S. 1088, 1090; Wien. med. Jahrbrücher 1861. S. 46.—*Mackenzie*, Traité d. mal. d. yeux, Warlomont et Testelin. I. Paris, 1856. P. 384, 388, 420, 425, 429, 431.—*Desmarres*, Trait yeux, Paris 1847. P. 861, 865, 871. Ann. d'oc. VII. S. 149, VIII. P. 85; Congress inter Paris. 1863. P. 141.—*Critchett*, Lancet 1863, 1864; Ann. d'oc. 51. Bd. 2–6 Liefg.; kl 1863. S. 364.—*Kleemann*, Zeitschrift. f. Ophth. V. S. 459.—*Zander* und *Geissler*, Verlet Auges. Leipzig u. Heidelberg. 1864. S. 104.—*Kersten*, nach Zander l. c. S. 105.—*Vi* krankhaften Geschwülste I. Berlin 1863. S. 249.—*Graefe*, A. f. O. I. 1. S. 288, 291, 294 lungen der ophth. Versammlung zu Heidelberg. 1859. S. 25, 26, kl. Monatbl. 1863. S. 58 f. O. I. 2. S. 161, 166, 171, 174.—*A. Weber*, ibid. VIII. 1. S. 94, 95, 97, 100, 102, 10 Monatbl. 1865. S. 96, 98, 103, 105, 107, 108, 112.—*Jaesche*, A. f. O. X. 2. S. 166, 170, 173, *Pagenstecher* und *Sämisch*, kl. Beobachtungen. Wiesbaden 1861. I. S. 72, 74, II. S. 39.– nach Mackenzie, Arlt, Weber, Jaesche.—*Hirschler*, Wien. med. Wochenschrift. 1862. *Secondi*, Clinica oc. di Genova. Riassunto. Torino. 1865. S. 118, 120.—*Scarpa*, Tratato d'occhi. I. Pavia, 1816, P. 1. 17, 26, 29, 33, 35, 46, 52.—*Foltz*, Ann. d. oc. 1865. P. 136.– *Laforest*, nach Hasner l. c. S. 97.—*Dupuytren*, nach Mackenzie l. c. P. 402.—*Fr. Jäg* Mittheilung.—*Lacaze*, Union med. 1864. S. 130.—*E. Williams*, Congr. intern. d'ophth. P P. 137. [*H. W. Williams*, Diseases of the Eye, P. 75.—*Delafield*, verbal commun *Arlt*, Krankheiten des Auges. III. Prag. 1856. S. 392–413; A. f. O. I. 2. S. 153–157 S. 267. u. f.; Zeitschrift der Wien. Aerzte. 1860. Nr. 24; Verhandlungen der ophth. V lung zu Heidelberg. 1859. S. 28; Wien. med. Wochenschrift. Spitalzeitung. 1862. Nr *A. Weber*, kl. Monatbl. 1868. S. 362.—*Jaesche*, klin. Monatbl. 1869. S. 290.—*Willia* f. Augen. und Ohrenheilkde. I. S. 78; Transact. Amer. Ophth. Soc. 1869. S. 30.—*G* S. 31.—*Laurence*, Congres. Ophth. 1868. S. 35, 41.—*Cervera*, *Delgado*, *Sperino*, il 47.—*Delgado*, Centralbl. 1866. S. 575.—*A. Jaeger*, ibid. S. 295.—*Wecker*, ibid. *Schweigger*, kl. Monatbl. 1869. S. 56.—*B. Ruete*, ibid. 1868. S. 236.—*Alf. Graefe*, ibi *Berlin*, ibid. S. 355, 362.—*Zeissl*, Wochenbl. d. Wien. Aerzte. 1861. Nr. 11.—*Stillin* d. Heilung. d. Verengerung. etc. Cassel, 1868. S. 7 u. f.; kl. Monatbl. 1869. S. 57.– ophth. Beiträge, S. 79, 82.—*Herzenstein*, Beiträge zur Phys. u. Therapeu. d. Thräne lin, 1868. S. 35, 39, 47.—*Warlomont*, Centralbl. 1869. S. 111.

ELEVENTH SECTION.

INFLAMMATION OF THE TISSUES OF THE ORBIT.

Anatomy.—The two orbital cavities (a horizontal median section of the left one is given in Fig. 84) resemble in form oblique, four-sided pyramids with rounded angles. Their axes are about an inch and a half long, horizontal, and so directed that, prolonged posteriorly, they would meet behind the sella turcica, and at an angle of about forty-five degrees.

The entrance, which forms the base of the pyramid, is a square with rounded angles, whose plane is inclined somewhat outwardly, so that extended, it would meet that of the opposite side in an obtuse angle at the nasal spine. Its wall projects as a strong, thick rim of bone, especially at the upper outer angle.

The inner wall of the orbit is nearly perpendicular. Antero-posteriorly it runs parallel to the diameter of the skull, and is formed of the os planum of the ethmoid, *a*, and anteriorly of the lachrymal bone, *b*. The latter articulates anteriorly with the nasal process of the superior maxillary, *c*. The upper wall has the greatest extent of surface. It is curved like a roof, and posteriorly sinks down very much. Its outer anterior part is hollowed out and forms the fossa lachrymalis. It is mostly composed of the horizontal part of the frontal bone; it is very thin, sometimes even perforated, and separates the orbit from the cranial cavity, but anteriorly and internally from the frontal sinus. The inferior wall is rather level, is somewhat more elevated posteriorly than anteriorly, and divides the orbit from the antrum. It is formed mostly of the superior maxillary, is quite thick, and contains the infraorbital canal, with the nerves and arteries of the same name. The outer wall is the firmest and most resisting; its surface is nearly perpendicular, and much inclined to the axis. It is mostly formed of the great wing of the sphenoid, *d*; anteriorly, however, the malar process of the frontal and the malar bone, *e*, combine to form it. Behind this bone lies the musc. temporalis, *f*.

At the inner upper angle of the pyramidal orbit is attached the pulley for the trochlearis (superior oblique) muscle. The outer upper

Fig. 84.

angle has a posterior opening three-fourths of an inch long, and one to two lines broad; the sphenoidal fissure, through which the vena ophthalmica cerebralis passes back to the cavernous sinus, and the oculomotor, trochlearis, abducens, and first branch of the fifth pair of cerebral nerves pass out into the orbit. The lower outer angle is perforated posteriorly by the spheno-maxillary sinus, which connects the orbit with the temporal and pteregoid fossæ. Through this fissure pass the vena ophthalmica facialis, and the infraorbital and a sub-cutaneous nerve.

At the apex of the orbit is the foramen opticum, bounded by the two roots of the small wings of the sphenoid (at *g*), through which the optic nerve and ophthalmic artery, *h*, escape from the cranium.

The bony walls of the orbit are everywhere covered with periosteum or periorbita. This is less firmly attached to the surface of the bones than to the sutures and edges of the fissures. At the latter, it is continuous with the dura mater and the periosteum of the neighboring bones of the face, while at the same time it forms sheaths for the nerves and vessels. At the edge of the optic foramen, the periorbita thickens to a firm tendinous ring, from which the four recti and the superior oblique muscles, as well as the elevator of the upper lid arise.

The space between the eyeball, *i*, and the walls of the orbit, is filled by a very loose connective tissue, *k*, richly strewn with fat. This connective tissue is thickened in some places, and thus forms sheaths for the muscles, vessels, and nerves of the orbit; and also forms fascia-like layers which unite the different parts of the orbit with each other and with the periorbita.

Such a fascia is the suspensory ligament of the eyelids, fascia tarso-orbitalis, which runs from the border of the orbit to the convexity of the cartilages of both lids, is connected with the ligaments of the lids, and helps to close the anterior opening of the cavity of the orbit. It is in places very thin and even perforated—that is, replaced by loose connective tissue (*Arlt*).

Another fascia extends from the convex border of the tarsal cartilage over the retro-tarsal portion of the conjunctiva as far as the surface of the globe, where it blends with the capsule of the eye, and is connected by this with a fascia which surrounds the four straight muscles of the eye and unites their edges with one another, so that the entire muscular funnel appears limited on all sides by a delicate sheath (*Magni*). Another fold goes from the posterior surface of the palpebral ligament to the lachrymal gland, insinuates itself between the superior and inferior portions of the latter, supports the first, and unites with the periorbital fascia.

The tunica vaginalis bulbi, the sheath of the eye, is of this kind. It begins at the circumference of the optic foramen, loosely incloses the optic nerve, at whose anterior end it widens out into a goblet-shape for the reception of the eyeball. It envelops this beyond its equator like a capsule (Bonnet's capsule), and is only united to the surface of the sclera by scanty loose connective tissue, and is so smooth that the globe can rotate in it. Beyond the equator it is pierced by the tendons of the oblique muscles, and is connected with their sheath. More anteriorly, it gives passage to the tendons of the recti muscles in an oblique direction, is connected with them, and finally with them disappears in the sclerotic. This anterior part of the sheath of the eyeball, from the part where the muscles pierce it to its union with the sclera, is also described as Tenon's capsule.

The space between the capsule and the globe, together with the optic nerve, is regarded as a lymphatic space, which is connected posteriorly with the arachnoideal space, but anteriorly with the suprachoroidal space by lymph canals which pass through the sclerotic near the orbital veins (*Schwalbe*).

In the cavity of the orbit, besides the inorganic muscles of the globe there are found a number of bundles of smooth organic muscular fibers.

The largest of these, the inferior orbital muscle, covers the inclosing membrane of the inferior orbital fissure, is about a millimeter in thickness, and consists mostly of fibers having a longitudinal direction, with which only a few bundles, running less perpendicularly to them, are interwoven (*H. Müller*, *Harling*). This muscle, the elements of which in part pass into the periorbital fascia, but are connected anteriorly with the palpebral ligament (*Sappey*), is a rudiment of the extremely powerful muscle which, in the higher animals, in connection with the orbital membrane, closes in the cavity of the orbit externally. Besides this there exist also small short bundles, which arise close behind the insertion of the palpebral ligament upon the internal and external wall of the orbit, and appear to be attached to the fascia tarso-orbitalis (*musculus orbitalis internus et externus*, *Sappey*). A very similar bundle, which has its place upon the roof of the orbit near the palpebral ligament (*H. Müller*), has not been found by others (*Henle*, *Harling*), which is in part explained by all these muscles being very slender and very frequently the subjects of fatty degeneration. It is probable that these, together with the organic muscles of the lids, strengthen the union of the fascia tarso-orbitalis and the lids on the anterior surface of the globe and the orbital cushion of fat, and therefore also aid in the carrying away of the tears.

The *arteries of the orbit* are all branches of the *ophthalmic artery*, which arises at almost a right angle from the carotid and passes through the optic foramen on the inner side of the optic nerve.

The trunk of the orbital artery, shortly after its entrance into the orbit, passes in an oblique direction under the optic nerve, and runs from here in a slight curve forwards, in order then to reach the inner side of the nerve, and then to run forward near the internal wall of the orbit. Where it lies external to the optic nerve, it gives off numerous muscular branches, the central artery of the retina, the short posterior ciliary arteries, and, finally, the lachrymal branch, the terminal branches of which reach to the external portion of the conjunctiva and the lids. In its course upon the inner wall of the orbit, besides the long internal ciliary artery, it gives off muscular branches, both the ethmoidal arteries and the anterior meningeal artery. Finally, as supraorbital artery, it divides itself into the frontal branch and into branches for the two lids.

The *veins* of the orbit form a rich network, which is intimately connected anteriorly with the *vena facialis anterior*, posteriorly with the *sinus cavernosus* and the pterygoid plexus, so that the venous blood can flow out as easily forward as backward, and obstructions in the region of the orbit cannot easily make themselves manifest when hindrances to the circulation exist in the trunk of the vena facialis or in the sinus cavernosus (*Sesemann*).

The two main venous trunks of the orbit are the vena ophthalmica superior, or cerebralis, *a* (Fig. 85, after *Sesemann*), and the vena ophthalmica inferior, *b*, called also externa or facialis. The first, which corresponds in its course to the arteria supraorbitalis, is composed of frontal branches and palpebral branches, and communicates in the region of the inner angle by large connecting branches, partly directly, partly by palpebral branches, with the vena angularis, *g*, and the facialis anterior, *c*. It then passes backward beneath the superior rectus muscle, and empties, after having perforated the superior orbital fissure, into the sinus cavernosus, *d*. In this course it anastomoses by numerous connecting branches with the ciliary veins, *e*, with the vena centralis retinæ, *f*, and with the vena ophthalmica inferior. This last proceeds from a plexus which is found at the anterior part of the bottom of the orbit, between the inferior and internal recti muscles, takes up all the inferior conjunctival veins, as well as some veins from the lower lid, but besides, is connected with the vena ophthalmica superior and facialis anterior. The trunk runs backward over the inferior rect. muscle, and empties either into the sinus cavernosus, or into the vena ophthalmomeningea (*Hyrtl*), the trunk of which passes out of the fissure of Sylvius, along the side of the sella turcica, through the superior orbital fissure into the orbit. The inferior orbital vein anastomoses in this way very freely with the vena ophthalmica superior, and with the vena facialis, with the vena lachrymalis, which, increased by the

conjunctival veins, runs towards the vena ophthalmica superior, or empties directly into the sinus cavernosus, and is, moreover, connected with the ciliary veins and with the plexus in the pterygo-palatine fossa (*Sesemann*).

The globe of the eye is embedded in the tissue of the orbit as in a cushion. The resistance of the latter is, however, sufficiently great in order to maintain the globe immovable in its normal position, opposed to the united force of the four straight muscles of the eye. Deviations from this position (Statopathien, *Hasner*) are always the sign of affections of the muscles, or of the orbital tissue, or of the globe itself.

Fig. 85.

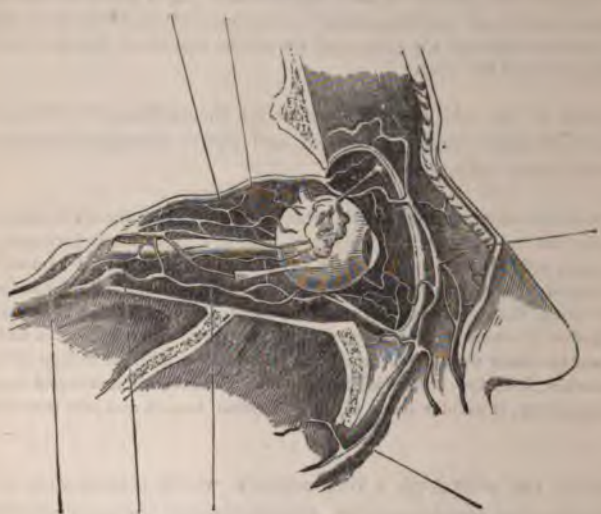

More recently great interest has been aroused and active endeavors have been made to find some means of measuring these deviations exactly, and of expressing them in figures. To this end peculiar instruments have been devised (Exophthalmometer, Ophthalmoprostatometer, *H. Cohn*, *Zehender*, *Emmert;* Orthometer, *Hasner*). By means of these the longitudinal distance of the apex of the cornea from the middle of the external (*Hasner*), or of the superior orbital border (*H. Cohn*), can be very easily measured, and thus also an approximate change in the relative position of the globe be ascertained, and its size also estimated. Still the instruments just mentioned and the points chosen are not suited for the estimation of normal values, since the prominence of the orbital border varies within wide limits, not only in different individuals, but also in the same individual on both sides (*H. Cohn*); moreover, the very changeable cushion of fat comes into account in the superior orbital margin, and besides the relative position of the summit of the cornea is very much influenced by the length of the antero-posterior diameter of the eye in otherwise perfectly similar conditions.

Nosology.—Inflammations of the orbit occur, on the whole, not unfrequently. The change of tissue is often confined to the soft parts lying between the eyeball and periorbita, while, in other cases, the periosteum or the bone itself is the seat of inflammation. It also happens quite frequently that all the parts mentioned are drawn into the process primarily or secondarily, as a result of propagation from one part to another.

1. It is said that, in rare cases, the ocular capsule is the sole or principal seat of an inflammation that is accompanied by excessive pain, and the formation of extensive morbid products between the sclera and Bonnet's capsule, so that the eyeball is protruded and its motion impaired (*O. Ferral*). The ocular conjunctiva is said to be, at the same time, much swelled and dark red, but to secrete little. The interior of the eye has sometimes been found normal (*Wecker*), sometimes undoubted choroiditis and hyalitis accompany or precede the affection (*Rydl, O. Becker*). Erysipelas and "cold" are given as causes of it. The disease is said to always end in a cure.

2. Inflammations of the fatty and connective tissue of the orbit are often seen. They may cause hypertrophy, and, as a result of this, permanent exophthalmos.

Thus from the action of traumatic, physical, or other causes of disease, in the course of an erysipelas of the face, of an inflammation of the bony walls of the orbit, of a suppurative panophthalmitis or severe conjunctivitis, we occasionally see the eye-ball protrude from the orbit, since the loose connective tissue enveloping it has participated in an inflammatory change, and has undergone a decided increase in size. On more careful examination the swelling usually shows itself to be composed of excessive serous or gelatinous infiltration; the process bears more the character of an inflammatory œdema. This usually recedes as the inflammation approaches its termination. In some exceptional cases, however, the connective tissue increases in amount, partially thickens to a hard, tendinous framework, in whose interspaces a somewhat consistent gelatinous product appears inclosed. This happens only when the inflammation of the orbital tissue is often repeated, or continues for a long time. (*Himly, Sichel, Duval.*)

Hypertrophy of the cushion in the orbit is relatively most frequently seen, along with an analogous overnutrition of the thyroid body, as a symptom of a constitutional disease, which is probably caused by some affection of the sympathetic nerve, and is usually accompanied by great disturbance of the blood and of the system generally. (*Exophthalmos with disease of the thyroid and heart, exophthalmos cachecticus, Basedow's disease.*)

In by far the greater number of cases, the inflammation of the soft parts of the orbit is of a suppurative character.

Usually most of the orbital tissue, muscular sheaths, and even of the muscles, are included in the process. Then, either small scattered abscesses, which are not always connected with each other, and are surrounded by hard, infiltrated tissue, are formed, or one large abscess with cavities and lateral chambers, whose walls, when not formed of the periorbita, appear hardened to a greater or less thickness by inflammatory proliferation of tissue.

3. Periostitis is often seen on the walls of the orbit. The vascular periorbita is at the same time closely injected, and swells more or less, occasionally so much that, when the affected portion of bone is superficial, elevations of some consistence may be felt.

When the inflammation has run its course, these tumors often disappear. Sometimes, however, they leave a perceptible thickening of the periosteum. In some cases, however, the tumor grows, gradually thickens to a filamentary cartilaginous tissue, or even ossifies and becomes permanent.

More frequently, however, the product of periostitis is purulent, whether because the process began with greater intensity, or account of unfavorable circumstances (especially the pressure to which the proliferating elements are exposed between the periosteum and bone), higher development of the new-formation was prevented. [illegible] the periosteum is rapidly raised from the bone to a greater or less extent, and [illegible] conduction of blood to the subjacent bones interfered with, and hence they [illegible]me necrosed.

4. As a rule, the periostitis is accompanied from the beginning by inflammation of the subjacent bone. Occasionally only the cortical substance lying next to the periosteum participates in the process. More frequently, however, the corresponding parts of the bony walls suffer throughout its thickness, and then the periosteum of the second surface, with the soft parts next to it, is usually affected. The inflamed bone appears reddened, swelled, and loses more or less of its consistence.

The chalky salts near the seat of inflammation are partially or entirely absorbed, while the hyperæmic connective-tissue covering of the medullary canal and cells is much swelled by the proliferation of its elements.

Where the process is less intense, and the conditions otherwise favorable, the cure may be perfect. Often, however, the bone near the seat of inflammation does not recover its former state; it remains somewhat enlarged and porous, or hardened. Occasionally, as a result of propagated change of tissue, large swellings originate from the bone, which are exactly like those arising from periostitis.

In most cases, however, and in higher grades of inflammation almost always, suppuration results from ostitis. Then the loose, spongy, reddened bone, at the center of the inflamed part, appears soaked in pus, which fills the medullary canals and cells like small drops, and enlarges them; but, as the developing connective tissue and cartilaginous basis of the bone deliquesce, the chalky parts are gradually absorbed. At last we find only a bony net-work, whose meshes are filled with soft, exuberant, vascular connective tissue and small drops of pus, and which render the surface of the bone decidedly rough.

Where the process is more intense, it also happens quite frequently that a part of the inflamed bone dies.

Just as in abscesses of the soft parts, suppuration only occurs in the center of the inflamed part, but the abscess appears inclosed by parts in which the inflammation is less intense, and elements are produced which are capable of higher development and of replacing the parts lost. In the same way, the carious or partially necrosed bone is always bounded by bony tissue, in which the exuberant elements strive for higher development, and form granulations, which gradually detach and throw off the part that has become incapable of living, and, as they subsequently change to bone or cicatricial tissue, they partially or entirely fill the cavity in the bone.

5. Orbital hemorrhages deserve particular mention. In most cases these depend on the spontaneous or traumatic rupture of vessels ramifying in the orbit. When extensive, they displace the eye-ball anteriorly or laterally. They usually sink and become diffused, so that, although originally situated deeply, they finally appear under the conjunctiva, which they may bulge out and discolor. They are usually absorbed. But they may thicken, and by repeated apoplexies become so extensive as to cause excessive exophthalmos, and give the impression of a luxuriantly proliferating new-formation. (*Fischer.*)

In other cases a fissure of the bone is the source of the extravasation, or the blood reaches the fatty cushion of the orbit, through a rupture communicating with some of the neighboring cavities. If the lower or inner wall of the orbit is torn, emphysema sometimes occurs. Exophthalmos is developed and increased by sneezing, &c., and shows its nature by crackling on pressure. The wound usually heals quickly, and the extravasation and emphysema usually disappear without leaving a trace. But if the upper wall is fractured, death usually results. Some think that the blood coming from the roof of the orbit always sinks, and appears under the upper half of the conjunctiva, so that from such conjunctival ecchymoses, appearing several hours after an injury to the skull, we may diagnosticate a fracture of the roof of the orbit. Careful observation and experiments on the cadaver have not entirely confirmed this. They showed that a large amount of blood must be effused, and the periosteum torn, for a fissure in the roof of the orbit to cause conjunctival ecchymoses; moreover, that blood and exudations escape from the cranium without

fracture through the foramen opticum, and through the anterior part of the upper orbital fissure get under the periorbita, and, if this be ruptured, may make for themselves a passage into the soft parts of the orbit. They also proved that such conjunctival ecchymoses might just as well originate from the vessels of the fatty cushion of the orbit, and that the tarso-orbital fascia prevented an escape of the extravasation under the skin of the lid (*Friedberg*).

Authorities.—*Mackenzie*, Traité d. mal. d. yeux. Traduit. p. Warlomont et Testelin. I. Paris, 1865. S. 433, 434, 440, 441, 450.—*O. Ferral*, ibid. S. 450.—*Himly*, Krankheiten u. Missbildungen, etc. I Berlin, 1843. S. 365.—*S chel*, Bull. de ther. 1846. Mai.—*Duval*, Ann. d'oc. 17. Bd. S. 201. —*Wecker*, Etudes ophth. I. Paris, 1864. S. 696.—*Stellwag*, Ophth. II. S. 880, 882, 884, 1262, 1287, 1288.—*Rydel*, *O. Becker*, Wien. med. Wochenschrift. 1866. Nr. 65, 66, 77; Wien. Augenklinik. Ber. S. 118.—*Graefe*, A. f. O. I. 1. S. 424.—*Fischer*, Lehrbuch d. ges. Entzündungen, etc. Prag. 1846. S. 359.—*Knapp*, kl. Monatbl. 1863. S. 162.—*Seitz*, Handbuch d. ges. Augenheilkd. I. Erlangen, 1855. S. 85.—*J. Meyr*, Beiträge zur Augenheilkunde. Wien. 1850. S. 10.—*Friedberg*, Virchow's Arch. 31. Bd. S. 344, 349, 362, 366, 369.—*Manz*, A. f. O. XII. 1. S. 1, 5.—*Arlt*, Krankheiten des Auges. III. 339.—*Magni*, Rivista clinica. 1868.—*H. Müller*, Zeitschrift f. wiss. Zoologie. IX. S. 541; Würzburg. Verhandl. IX. S. 244.—*Harling*, Zeitsch. f. rat. Med. XXIV. S. 275, 288, 293.—*Henle*, Eingeweidelehre. 1866. S. 696.—*Sappey*, Gaz. med. de Paris. 1867. S. 681.—*Winther*, Experimentalstudien. Erlangen, 1866. S. 4.—*Schwalbe*, Arch. f. mikr. Anat. VI. S. 28.—*H. Cohn*, kl. Monatbl. 1867. S. 439.—*Hasner*, Die Statopathien d. Aug. Prag. 1869.—*Sesemann*, Arch. f. Anat. u. Phys. 1869. S. 154–162, u. f.—*Henke*, kl. Monatbl. 1869. S. 220.—*Emmert*, Zwei Fälle von Sarkom der orbit. Bern, 1870. S. 24; kl. Monatbl. 1870, S. 33.—*Zehender*, ibid. S. 42.—*Lawson*, Schmidt's Jahrb. 135. Bd. S. 264.—*Pepper*, ibid. S. 201.—*Hulke*, ibid. 140. Bd. S. 203.—*Küchler*, Deutsche Klinik. 1866. Nr. 28.—*Becker*, A. f. O. XII. 2. S. 289.—*Langenbeck*, ibid. XIII. 2. S. 447.

1. Basedow's, Graves', or Parry's Disease. Exophthalmic Goitre.

[*Historical Notice.*—Emmert shows, from an extract of a work by Parry, that this author, as early as 1825, reported eight cases of morbus Basedowii, under the title of "Enlargement of the Thyroid Gland," with hypertrophy, or palpitation of the heart. The description pictures the disease pretty well, although exophthalmos was noticed in only one of the cases, and no special weight given to that symptom. Besides this, Parry gives five more cases where enlargement of the thyroid gland occurred in connection with affections of the head, epilepsy, headache, dizziness, deafness, etc. Emmert, therefore, proposes to call the disease after neither Basedow nor Graves, but after Parry. In conclusion, the author reports twenty cases of his own observation. Of these, ten per cent. occurred in men and fifty per cent. in women. Exophthalmus was constantly present; in one case, on one side only, while the thyroid gland was enlarged on both sides. In every case there was a diminution of sensibility in the cornea and conjunctiva, and also diminished reflex action of the lids. At times there occurred a slight impairment of the sight without any apparent ophthalmoscopic cause; in two cases atrophy of the optic nerve, and more often enlargement of the retinal veins, with simultaneous constriction of the arteries. In about six cases peculiar disorder of the speech occurred. When the individual attempted to speak, and the mouth was widely opened, there set in a spasmodic movement of the jaw, and only after some exertion was he master of his speech, which was somewhat hasty and often indistinct. (*Emmert.*)]

Symptoms.—*The characteristics of the disease are decided disturbances of innervation of the muscles of the lid and of the heart, exophthalmos and goitre.*

1. The disturbed action of the heart shows itself by accelerated, strengthened, and often irregular contractions, and by systolic murmurs in the heart and great vessels of the neck. The palpitations are often, especially at intervals, so strong that the thoracic walls are greatly shaken, and we may perceive, at a distance, the pulsation in the carotids, facial arteries, and even in the orbit. But it is said that the pulsation is less than normal in the brachial and radial arteries (*Trousseau*). These palpitations are usually accompanied by dyspnœa. Actual diseases of the heart sometimes accompany it, but are usually absent, and at all events are only accidental complications.

The palpitations appear particularly during bodily and mental exertions, sometimes, however, they are paroxysmal without cause, and then are usually accompanied by extreme dyspnœa, and often also by increase of the exophthalmus as well as by perceptible increase of the goitre. Actual cardiac affections occur with them, are, however, as a rule, wanting, and are at any rate only accidental complications.

2. Like the exophthalmos, the goitre also varies greatly in size, but never becomes so great as to cause decided functional disturbance.

3. The exophthalmus is with few exceptions binocular, but not always uniformly

developed in both eyes. It appears often very early, but usually not until after long continuance of the cardiac symptoms and the formation of the goitre. It is sometimes scarcely perceptible, or appears at times to disappear completely, particularly in the first stages of the affection, where, like the goitre, it is very apt to vary. In other cases it is very considerable, without ever coming to an actual protrusion from the orbit. The bulging forward of the globe usually occurs in the direction of the orbital axis; only rarely does an oblique position of the eye occur, owing to an asymmetrical increase of volume of the orbital cushion (*Graefe*).

The exophthalmus, as well as the swelling of the thyroid gland, as has been demonstrated, depends upon a dilatation of the vessels, particularly of the veins. It therefore usually increases a good deal temporarily, if, on account of increased activity of the heart, the pressure of blood in the orbit increases, or in consequence of obstructions in the region of the superior vena cava; but, on the other hand, it disappears in death almost entirely. Only by long continuance of the superfluity of blood does secondary hypertrophy of the connective tissue occur, and in the thyroid gland also it leads to the development of colloid cysts (*Virchow*).

4. The disturbances of innervation are seen as well in the domain of reflex activity as in that of the arbitrary movements of coördination, and manifest themselves, moreover, not uncommonly in the form of real paralysis.

a. To the first category belongs one of the most constant symptoms usually present from the beginning, namely, the wide opening of the inter-palpebral fissure and the incompleteness and rarity of the rhythmical movements of the lids. The gaping of the palpebral fissure is usually so large, that quite a wide zone of sclera is exposed above and below the corneal margin. The rhythmical movement of the lids is often entirely absent for several minutes, is also generally very incomplete, and is replaced by a slight drawing inwards, and by a weak, screw-like rotation of the edge of the lid. This symptom, in connection with the wide opening of the palpebral fissure, gives to the physiognomy of the patient the peculiar hardness and staring appearance which is mentioned by so many authors.

These disturbances of mobility can not well be explained by the exophthalmus, since, as a rule, they precede for a long time the protrusion of the globe, and fall and rise independently of its variations. The exophthalmus increases the disturbances of mobility already present only by an increase of the resistance in higher degrees of development, sometimes to such an extent that the palpebral fissure remains open up to a certain width even during sleep, whereby much irritation is caused. The disturbances of mobility in question can not, moreover, be deduced from a tonic spasm of the *levator palpebræ superioris* or of the organic muscle of the upper lid, since voluntary innervations of the circular muscle are sufficient to overcome powerful contractions, whose actual power is scarcely less than the normal. The freedom of the voluntary movements distinguishes, however, the condition thoroughly from paralysis, in the narrowest sense of the word. It can, therefore, well be said, that in these appearances it is merely an obstruction of those reflex currents which are conducted during the waking hours by the sensory nerves of the surface of the globe and by the retina continually to the ocular portion of the seventh pair of cranial nerves, and in the circular muscle maintain on the one side a certain degree of tonic tension, on the other, however, excite the rhythmical movement of the lids.

The most important factor of the conducting away of the tears is coincident with the cessation of the movements of the lids; hence the patients, particularly in the beginning, suffer frequently from lachrymation, and this indeed so much the more as the wide opening of the palpebral fissure increases the irritating influence of the atmospheric air, etc., and thus the secretion of the tears also. In the later stages of

the process, however, the irritability of the sensory nerves is considerably blunted, the palpebral fissure is only more flooded by tears when severe irritants act upon the eye, in rough stormy weather, in a smoky, dusty atmosphere, etc. In ordinary circumstances, however, scarcely more than the normal are secreted. From their insignificance, and from the great evaporation upon the surface of the globe, which is always exposed, desiccation of the epithelial layers easily occurs. These are then found actually, in the later stages of the affection and in exophthalmus of a higher degree of development, to be very frequently perceptibly opaque, dry, and flaky. Along with this the resistance of the orbicular muscle naturally increases, whilst the irritating action of the atmospheric air and of external injuries simultaneously perceptibly decrease. The disturbances of mobility in question increase with the xerosis, and the latter sometimes reaches such a high degree that the touching of the surface of the globe with a feather is felt, but it excites no pain and still less reflex spasms.

The xerosis, according to all this, cannot be regarded as the cause, but only as the effect of the disturbances of innervation, so much the more as the latter, as a rule, precede for a long time the former, and the xerosis, moreover, is frequently absent during the whole course of the affection.

b. There is only one very common disturbance of the voluntary movements of co-ordination. It is manifested by the upper lid following the globe only slightly or not at all, when the visual plane is depressed (*Graefe*). This symptom is found, as a rule, from the earliest stages of the disease on, along with the above-described disturbances of reflex activity. Still it is in general less frequent than the latter. It varies like these in degree, and during the course of the disease often disappears entirely for a time.

In one case a temporary complete cessation of the lateral movements was observed. The visual lines of both eyes stood perfectly parallel. The visual plane could be raised or depressed voluntarily. The movements of convergence were also entirely free. Still the power to direct both eyes simultaneously to the one or the other side was completely absent. Whilst therefore the lateral straight muscles of the eyes followed unhindered the impulses to convergence, they were absolutely paralyzed for innervations for lateral vision. The same condition occurs here as in action of the circular muscle, which under a voluntary direct impulse contracts with normal power, whilst it remains completely inactive under opposite impulses which aim at depression of the visual axis.

c. True paralysis is, on the whole, not uncommon, and generally very variable and transitory. It affects the muscles of the eye with relatively greater frequency, more rarely the respiratory muscles of the face, the trigeminus and the opticus.

Oblique positions of the eye are mentioned, in fact, by various observers, as quite frequent complications of Basedow's disease, and according to present experience are dependent in the majority of cases, without doubt, upon obstructions to the conducting power of the motor nerves of the eye, and resemble these in every particular. Such oblique positions may have been caused in many cases by an excessive fatty degeneration of one or more muscles of the eye (*Recklinghausen*). It also is a fixed fact, that the exophthalmus in itself causes a squint in a purely mechanical way, and, moreover, in proportion to its development, causes limitations of the movements of the eye in every direction.

In this class certainly belongs the not very uncommon mydriasis (*Mooren*, *Demme*, *Heymann*). It not only occurs in connection with the characteristic disturbances of the paralysis of the oculo-motorius, but independently, and in the latter case may possibly be dependent upon the stretching of the ciliary nerves caused by the exophthalmus. It appears more frequently, however, to indicate a central impediment to the conducting power. The paralysis of the respiratory muscles of the face is usually incomplete, and manifests itself by a peculiar rigidity

and immobility of the corresponding halves of the face in whistling, blowing, etc., and in emotion.

Attacks of anæsthesia of the trigeminus are more frequent. They are often limited to the anterior surface of the globe, and may then often be explained like the mydriasis from the stretching of the ciliary nerves. In other cases they extend over a larger surface, and must then be considered as hindrances in the conducting power of the branches, or central portions of the fifth nerve. With such a degree of extent they are in general very variable and occur also in paroxysms.

There is no doubt that the ulceration of the cornea, which is sometimes observed in Basedow's disease, is partly connected with it, pathogenetically, and that also the sometimes very considerable drying of the surface of the globe (*Mackenzie*) is in many cases actually caused by it. Still it would be a great error to ascribe a neuroparalytic origin to all ulcerations of the cornea in Basedow's disease. Ulcerations of the cornea also occur with a scarcely diminished sensibility, with great ciliary irritation and very profuse lachrymation. They are then caused probably by external irritations, and are especially favored by the wide gaping of the palpebral fissure.

Disturbances of vision are also observed, but are usually caused by the mydriasis, by the drying of the corneal surface, etc. Cases of real amblyopia also show themselves here and there, and in one case, perhaps accidental, a real amaurosis, with complete atrophy of the optic nerve, was found.

5. The disease is frequently complicated with anæmia or chlorosis, with great disturbance of the general nutrition, producing extreme emaciation, and in women, suppression of the menses. This condition of things is met with very frequently, especially in the later stages, or it may never occur. In connection with it we sometimes meet with digestive troubles, dyspepsia, watery or bloody vomiting, bloody stools; exhausting sweats, hypersecretion of urine; extreme weakness with a tendency to vertigo, tinnitus aurium, headache, and frequent attacks of syncope; finally general nervous prostration and great irritability. These symptoms are, however, not constant, but may occur or be absent in an apparently normal condition of the blood (*Trousseau*).

Pathology.—There is good reason for supposing that all these complex symptoms of Basedow's disease come from a common source, and this is to be sought in affections of the central parts of the sympathetic nerve (*Geigel*, *Friedrich*). The pathognomonic triad, exophthalmus, goitre, and cardiac affection, bears plainly upon its face the angioneurotic character, and may be regarded as directly connected with functional disturbances of the vaso-motor centers. The many very inconstant additional symptoms, however, which give a true protean form to the disease, may be regarded partly as direct, partly as indirect consequences of that central affection. The manifold disturbances of innervation, in particular of the motor and sensory nerves, point, like the frequent psychical alterations, to multiple sources of disease, which appear disseminated in the most various points of the brain, in its cortex, in the separate reflex and co-ordinative centers, in the nuclei of origin of individual nerves, etc., and their changeableness and transient nature are only to be ascribed to circumscribed paralytic dilatations of the vessels, which, although secondary in the brain, as elsewhere, by favoring infiltration and inflammatory exudation, lead to actual vitiation of the nervous tissue, and may, to a certain extent, determine the functional disturbances dependent upon them.

By many the cervical cord has been regarded as necessarily the point of origin of the disease (*Aran*, *Kæben*). Very remarkable changes in it have actually been demonstrated in a number of cases (*Trousseau*, *Reith*, *Cruise*, *M'Donnel*, *Traube*, *Biermer*, *Virchow*, *Geigel*). In other cases, however, no disease of the cervical cord could be recognized (*Recklinghausen*,

Paul, *Fournier*, *Ollivier*). The characteristic symptoms, moreover, do not correspond to those which are caused by operative or accidental interruptions of conduction in the sympathetic nerve of the neck (*Eulenburg*, *Guttmann*). The suspicion arises, therefore, that the above-mentioned changes of the cervical cord are merely accidental, and perhaps only to be regarded as local neuro-paralytic foci. Moreover, adhesions of the central canal of the spina cord and of the medulla oblongata, together with distinct signs of hyperæmia and inflammation in the surrounding tissue, have been demonstrated as probable sources of Basedow's disease in at least one case (*Geigel*). With the slight attention which has hitherto been given to the central portions of the sympathetic, it can be, however, easily supposed that morbid changes may often exist in them, even if they may not always be very perceptible to the naked eye. The tendency of Basedow's disease to the formation of multiple morbid foci in the most diverse regions of the sympathetic nerve is illustrated by a case (*Praël*) in which numerous foci of softening were demonstrated in the brain. It manifests itself, however, very unequivocally in the frequent occurrence of circumscribed paralysis of the vessels in the periphery of the body, partly pure, partly combined with inflammatory exudations and œdema. Here belong also the deep reddening of larger cutaneous surfaces, accompanied by great development of heat, sometimes one-sided, appearing paroxysmally or with psychical excitement; the constant enormous dilatation of the vessels, which are not uncommonly found on the cheeks and nose; the so-called "taches cérébrales" (*Trousseau*, *Paul*, *Dusch*) and certain ephemeral formations of tumors, entirely analogous to them, in the region of the eyebrows and on the lids, which are sometimes accompanied by enormous swelling of the venous trunks running in the neighborhood, or of single arteries (*Decés*). Diffuse, tolerably firm swellings, traceable to inflammatory exudations, were observed on the cheeks and lips. One case may also be adduced as an example of a secondary inflammatory, circumscribed, morbid focus, in which great swelling and reddening of the conjunctiva, with exudation of a membranous product during the course of Basedow's disease, repeatedly occurred in paroxysms (*Heymann*).

The **causes** of the affection have as yet been but little investigated. It appears that violent mental emotions play an important part in the etiology. The disease has been observed exceptionally in children (*Rosenberg*, *Trousseau*, *Deval*). As a rule it attacks young individuals or those of middle age, particularly those with delicate constitution, clear complexion, blue eyes, blonde or reddish hair and irritable nervous temperament. Chronic diseases, hemorrhages, etc. increase the predisposition. Women are liable to the disease about four times as often as men (*Dusch*).

Course.—The development of the disease in all its phases is occasionally very rapid; a few weeks, or even a few days, accomplish it. As a rule, however, the symptoms come on gradually; months and years pass, during which the heart-disease has more or less frequent and severe paroxysms. Then the goitre and exophthalmus, finally faulty hæmatosis, indigestion, etc., appear. Sometimes, however, the latter symptoms open the series; the heart-affection occurs later, and, after it, the goitre and exophthalmus.

Once developed, the disease often exists for years, with more or less variation, so that while there is slight change in the exophthalmus and goitre, the other symptoms vary individually or in their totality. This is especially true of the heart-disease, which often wholly disappears for a considerable time, so that it looks as if the disease was actually stopped, till it finally appears again, with the former or even greater severity.

The retraction and immobility of the lids may also disappear, although the exophthalmus remains.

Termination.—The patient may recover completely, or at least be so far improved that there are only traces left of the goitre and exophthalmus, or of either of them. This presupposes that the heart-affection has been permanently removed; where it continues, experience teaches that we can not count on such favorable

results, even when the other symptoms entirely disappear, as relapses usually occur. We can count the least on improvement in the digestive power and hæmatosis; and on the other hand, total failure of the functions does not necessarily involve a bad prognosis, as rapid recovery of the patient has been frequently observed under such circumstances, when the heart has been quieted. Rapid increase of the anæmia, and disturbance of digestion, are always injurious, as the patient finally dies of exhaustion (*Graefe*).

In general, death is not a frequent termination. Out of 56 cases, 7 died. But permanent cures are also not usual (20 out of 56). Considerable and permanent improvement was observed in 30 out of 56 cases (*Dusch*).

Sometimes in great exophthalmus the cornea is destroyed by partial ulceration, and then the globe is destroyed by phthisis.

Treatment.—The recognized angioneurotic character of the disease has in later times led to attempts at galvanization of the cervical cord, and, so far as experience has hitherto gone, this seems a valuable means of treatment. In fact the frequency and force of the pulse often diminishes by appropriate treatment, the heart becomes quiet, and the difficulties of respiration connected with violent movements disappear; the nutrition of the individual is also improved. Moreover, the goitre and the exophthalmus usually rapidly diminish in new cases, and the manifold disturbances of innervation of the lids, etc., are usually entirely stopped within a brief period. Favorable conditions of life, sojourn in the country, cheerful rest, appear to promote permanent cures.

Some persons praise systematic water-cure treatment, which is to be combined with the use of digitalis in cases of highly developed cardiac affection (*Trousseau*). Tonic remedies and iron, which are antagonistic to disturbances of digestion and defective blood development, have not proved of service. Men especially bear them badly, and it seems that ergotine and quinine are better adapted to them (*Graefe*). Iodine, which has been very often employed for the purpose of producing absorption in the region of the thyroid gland and orbit, also leaves us in the lurch. In some cases it is said to have caused even dangerous accidents. Local depletion is said to have checked the development of the goitre and exophthalmus in a remarkable manner (*Trousseau*). In order to protect the partially denuded globe, tarsoraphy has been recommended (*Graefe*). This, however, usually fails in the desired effect. Hence the tenotomy of the levator muscle has been recently proposed in place of it, in so far as a slight ptosis of the upper lid is obtained with certainty (*Graefe*).

Authorities.—*Basedow*, Caspers Wochenschrift, 1840.—*Helfft*, ibid. 1849, Nr. 48, 49.—*Praël*, A. f. O. III. 2, S. 199, 205.—*Graefe*, ibid. S. 278, et seq.; Med. Neuigkeiten, 1864, Nr. 14; Deutsche Klinik, 1864, Nr. 16.—*Remak*, *Bezold*, ibid.—*Mackenzie*, Traité d. mal. d. yeux. Traduit p. Warlomont et Testelin, I. Paris, 1856, S. 458.—*Wecker*, Etudes ophth. I. Paris, 1864, P. 704.—*Trousseau*, Archiv. gén. de méd. XX. P. 244-248, 488.—*Guyon*, u. A. ibid. P. 116, 359, 362, 365.—*Aran*, nach Trousseau.—*Reith*, kl. Mntbl. 1866, P. 138, 140.—*Recklinghausen*, ibid. S. 141.—*Gros*, ibid. 1865, S. 298.—*Gros* und *Charcot*, Gaz. méd. de Paris, 1856, Nr. 38, 29, 1867, Nr. 14.—*Geigel*, Centralbl. d. m. Wiss. 1866, Nr. 48.—*Graefe*, Centralbl. 1867, S. 650; Congrès ophth. 1868, S. 58.—*Mackenzie*, Traité d. mal. d. yeux. Traduit p. Warlomont et Testelin, III. Paris, 1856, S. 146, 149.—*Geigel*, Würzbg. med. Zeitschrift, VII. S. 84, u. f.—*Friedreich*, Lehrb. d. Herzkrankheiten, Erlangen, 1867, S. 317.—*Eulenburg*, *Guttmann*, Arch. f. Psychiatrie, I. S. 420, 447, u. f.—*Paul*, ibid. S. 452.—*Aran*, *Koeben*, ibid. S. 434, 435.—Decôs, ibid. S. 443.—*Deval*, ibid. S. 432.—*Traube*, *Recklinghausen*, Deutsche Klinik, 1863, S. 286.—*Heymann*, Ophth. Leipzig, 1868, S. 9.—*Stellwag*, Wien. Jahrbücher, 1869, S. 25, 33, 44, u. f.—*Dusch*, Lehrb. d. Herzkhtn. Leipzig, 1868, S. 349, 353, u. f.—*Baeumler*, Deutsch. Arch. IV. S. 59. 5.—*Virchow*, Die Krankheiten Geschwülste, III. S. 73, u. f.—*Cheadle*, Lancet, 1869, I. S. 845.—*Rosenberg*, Centralbl. 1866, S. 76.—*Fournier*, *Ollivier*, Centralbl. 1868, S. 124.—*Mooren*, Ophth. Beiträge, S. 32.—[*Emmert*, Archiv f. Ophth. XVII. S. 203.]

2. Abscess of the Orbit.

Symptoms.—*This disease is characterized by exophthalmos, and swelling of the conjunctiva and lids, that have appeared with symptoms of inflammation.*

The latter vary with the intensity and extent of the process. This is usually accompanied by an active or even continuous fever. In simple inflammation of the orbital tissue—that is, when there is no periostitis—the pain is usually dull, and only becomes excessive when the eye-ball is greatly protruded. It is increased by pressure on the globe, but not by pressure on the wall of the orbit. (*Graefe.*) At the same time, the conjunctiva and lids show their participation by swelling greatly. Not unfrequently the former covers a considerable part of the cornea, in the shape of a large cushion.

Where the orbital inflammation is deeply seated and not very intense, this swelling of the conjunctiva and lids frequently bears the character of pure or inflammatory œdema. When it is intense or superficial, however, it often appears chemotic or erysipelatous, is hot, tense, and deep red. In the latter case, the secretion from the conjunctiva is usually stopped, and, where exposed to the air, this appears dry. On the other hand, when the swelling is more œdematous, the secretion usually appears increased, and may foretell a blennorrhœa.

The exophthalmos is usually in proportion to the extent of the inflammation. When the abscess is deeply situated, the protrusion of the eye-ball is usually regular, while a *periosteal* swelling usually pushes it to one side. (*Graefe.*)

At first the exophthalmos is often slight, and can only be recognized by a careful comparison of the corneæ of the two eyes. But in other cases, the eye-ball protrudes so far from the orbit, that the lids can not be closed, and the gaping fissure left between them is filled with a pad of conjunctiva. The movements of the eye are much impaired, painful, or even impossible.

At first the cornea appears quite clear and brilliant; the pupil is generally contracted, immovable, and quite black. Ophthalmoscopically, we often find the central veins greatly dilated.

Subjective affections of vision are rarely absent. The visual field is usually misty, often contracted; in many cases even sensitiveness to light is lost.

Causes.—The disease rarely occurs without a perceptible cause. Sometimes rapid change of temperature is blamed as the immediate cause. The most important of the causes, however, are injuries, particularly concussions, penetrating and perforating, and most of all, infectious wounds. The actual cautery or strong caustics used for destroying the lachrymal sac, as well as the injection of irritating solutions into the lachrymal duct, and their escape into the surrounding loose tissue through an opening in the walls, have caused very injurious orbital abscesses. (*Mackenzie, Zander, Geissler, Hulke, Graefe.*)

Orbital abscess is frequently a secondary disease, caused by a propagation of inflammation from neighboring parts. It not unfrequently occurs in the course of a purulent meningitis, from the inflammation passing through the orbital fissures to the loose connective tissue of the orbit. Then it usually occurs on both sides, and

consists of a number of small hemorrhagic abscesses scattered around, and occurring particularly in the œdematous fatty cushion and muscles. Then externally it appears like facial erysipelas, and seems to have been often confounded with it. (*Leyden.*) Moreover it can not be denied that erysipelas of the head and scalp often enters the orbit, and causes similar abscesses. (*Mackenzie.*) The same is true of phlebitis, which is directly or indirectly propagated to the orbital veins, and may become a cause of suppurative inflammation of the orbit. (*Mackenzie.*) Moreover, suppurative panophthalmitis rarely runs its course without extensive infiltration of the fatty cushion, which sometimes results in partial ulceration. In purulent periostitis of the orbital walls, the formation of abscesses in parts anterior to it is an almost unexceptional rule. Finally, experience teaches that the orbital connective tissue is a very favorable seat for metastatic abscesses, which not unfrequently occur in the course of pyæmia, puerperal fever, exanthema, &c. In some cases the orbital abscess may be a local deposition of tubercle. (*Fischer.*)

The Course is often very violent. It usually passes its hight by the eighth or fourteenth day, and then terminates with gradual decrease of the inflammatory symptoms. The complete removal of the injuries caused by the process then not unfrequently requires weeks and months, if not years.

Sometimes the disease is more subacute, or inclines from the beginning to a chronic form. Then it usually commences with less decided inflammatory symptoms, or these soon diminish, if they have shown great intensity at first. The eye, meanwhile, is slowly pressed forward to a certain extent, while the conjunctiva and lids swell with œdema. Thus some weeks pass without material change, except slight exacerbations and remissions of the inflammation, till finally, art interferes, or in some other way a certain termination is arrived at.

Very exceptionally also, so-called cold abscesses have been observed. During months and years, pus had gradually assembled in the orbit and pressed the eye a little forward, without any decided signs of inflammation having shown themselves. But finally the process took a sudden start, and, with the usual symptoms of *acute* abscess of the orbit, went on to its termination. (*Mackenzie, Carron du Villards.*)

Termination.—1. The process may end in resolution. This occurs most easily before abscesses have actually formed, that is, in the commencement of the inflammation, when this has not begun with too great intensity.

2. If a considerable amount of pus has once been developed, it almost always perforates. While this is occurring, the fever usually diminishes, pain is less intense, the swelling becomes softer, and a point of fluctuation usually appears. If, even now, we do not evacuate it artificially, a point of pus appears behind the conjunctiva or on the lid, sometimes even at a considerable distance from the margin of the orbit, it gradually enlarges and finally breaks through. Then the eye-ball recedes in proportion to the completeness of the evacuation of the abscess. It is some time before it attains the normal position, as the suppuration generally lasts a long while, and the induration of the walls of the orbit and the surrounding œdema only recede gradually. The perforation finally closes by granulation. In most cases the abscess opens at one point; sometimes, however, at several simultaneously, or at intervals. Occasionally, even a number of sinuses form, which extend into the orbital tissue in the most varied directions, and open at some distance from each other.

Sometimes it happens that the sinus is closed by granulation near its external orifice, before the termination of the suppuration of the walls of the abscess. Then the pus collects again, and the result is a repetition of the entire process.

3. The eye-ball is frequently much injured. But sometimes it bears a great deal. Cases are known where it has been protruded through the lids, and kept in that position for weeks, and, after the disappearance of the inflammatory symptoms, has perfectly regained its functional power. Still, this is not by any means the rule. Not unfrequently the process extends to the neurilemma of the optic nerve, a neuritis or neuro-retinitis is developed, with a more or less extensive exudation, which finally leaves a gray atrophy; or as a result of the pressure on it, and the disturbance of circulation, the optic nerve is attacked by gray atrophy, the eye becomes blind, and this may occur not only in severe cases, but also where the eye-ball has been but slightly protruded; indeed, it has even been seen after simple erysipelas of the parts about the eye. (*Graefe.*) Retinal detachments also occur as a result of orbital abscess. The eye-ball often participates under the form of irido-choroiditis, and atrophies (*Tetzer*), or it is destroyed by suppurative panophthalmitis. When the process is very intense, and the exophthalmos extreme, the cornea is often necrosed, or else abscess or ulcers develop in it, which cause perforation, and finally phthisis of the globe.

But, apart from this, the mobility of the eye is not always restored after it has returned to its normal position; a more or less decided luscitas remains. For, not unfrequently, especially in extensive abscesses, some muscle or nerve suffers, either directly from inflammation and partial suppuration, or indirectly from the formation of thick, hard, and extensive cicatrices in the orbital tissue. As a result of cicatritial contraction of the conjunctiva and lids, the mobility of the eye-ball is not unfrequently much limited, or it is even *fixed* in a false position.

4. It is a very important point, as regards the prognosis, that not unfrequently the bony walls of the orbit become sympathetically affected, under the form of periostitis or ostitis. The subsequent result is then usually caries or necrosis. Through an opening thus formed, the orbital abscess may, exceptionally, evacuate itself into the nose or antrum, the pteregoid fossa, or even into the skull.

5. In the latter case, death is the usual but not constant result. Death may also be caused by direct propagation of the inflammation to the brain and its membranes. Occasionally the patient dies early, before there is any great collection of pus in the orbit. The fatal result is most to be feared when the process begins very fiercely, or when it depends on phlebitis, as this extends very readily to the brain, as well from contiguity as by thrombus. As phlebitis not unfrequently runs its course with the outward symptoms of erysipelas, it is very advisable, in the latter disease, to carefully examine the state of the veins in order to avoid errors of prognosis.

The Treatment is, on the whole, the same as that of abscesses in other parts of the body. Still, the indications are more urgent, on account of the great danger that accompanies the process. The first indication is to oppose the excessive proliferation of tissue, to limit it as far as possible in intensity and extent, or even to suppress it. If the existence of pus be once suspected, the abscess should be opened as soon as possible, and subsequent care taken for easy escape of the pus, as well as for the favorable healing up of the abscess.

1. When there is a probability or certainty that a wound caused the affection, we attend carefully to the fact that possibly a foreign body may have been driven

into the orbit, and may remain there. We should therefore examine the conjunctiva carefully to discover any existing wounds or cicatrices. Frequently shot, pieces of metal, even broken pipe-stems, &c., have been found behind quite unnoticeable wounds or scars. These were driven into the orbital tissue, and occasionally incapsulated. If the probe shows the presence of such a body, it must be cut down upon and removed.

If the orbital abscess be developed secondarily, the primary disease must be treated properly, and the special indications of any existing constitutional disease attended to.

2. The indication of the disease aims first at an antiphlogistic treatment, answering to the existing intensity of the process. Perfect rest of mind and body, as a rule keeping in bed, a small amount of easily-digested food, &c., are always required.

Where the inflammation is very intense, and severe fever exists, internal antiphlogistic remedies, cooling drinks, and when there is great excitement of the circulation, digitalis, aconite, and similar remedies, are to be used. Local applications of ice are to be energetically and uninterruptedly made, and seconded by repeated applications of leeches.

The leeches are best applied to the temples; but in case the skin, in the immediate vicinity of the orbit, be erysipelatous, or if the brain show evident signs of sympathy, it is better to apply the leeches over the mastoid process. If the tension be great and the pain severe, and the eye is threatened with panophthalmitis or destruction by ulceration or gangrene of the cornea, we must no longer delay incision, to diminish, at least, the existing pressure.

For this purpose a sharp-pointed bistoury is to be introduced to the depth of one inch, between the wall of the orbit and the globe, on the side where the latter appears pressed furthest from the wall. While making the incision, it is necessary to remember the positions of the walls of the orbit. At the inner side of the globe the knife is to be introduced horizontally, somewhat obliquely backward and outward from the median line of the head, but on the external side obliquely inward and backward.

If the symptoms of inflammation remain moderate, occasional applications of ice, with strictly antiphlogistic regimen, will be sufficient. In the subacute form, when no local elevation of temperature is perceptible, a bandage with a pad is advisable.

3. As soon as we have cause to suspect the existence of pus in the orbit, we must attempt its immediate evacuation by the means above mentioned; otherwise we run the danger of the purulent destruction going further and further, of sinuses forming in various directions, of the bones and eye becoming sympathetically affected, and, finally, unsightly cicatrices occurring, which may also be highly injurious to the functions of the eye.

It is better to puncture too early than too late. If we wait until fluctuation, or until the presence of pus becomes evident at some point, we will often have to regret the results above detailed, or even worse. But if we operate early, and very little or no pus be evacuated, no harm is done; on the contrary, it often happens that all the symptoms are rapidly diminished, and the process is arrested; for the pressure to which the proliferating tissue is exposed has itself a bad influence on the nutritive conditions. But this pressure is greatly diminished by the partial division of the fascia, as well as by the loss of blood and the evacuation of small abscesses. Moreover, small abscesses break into the wound more readily than they perforate anteriorly. Hence, in case nothing is evacuated immediately after the opening, we may hope with some

reason that something will be evacuated after a time, and thus the object be attained. At the worst, we have only to repeat the operation after a while.

After the puncture, we should favor the exit of the pus by only a very moderate pressure. Injections into the wound for the purpose of washing out the pus are to be avoided, as the water may diffuse itself in the loose tissue, and cause a decided increase of the inflammation and suppuration. Immediately after the operation, it is well, by careful probing, to detect any existing disease of the bone. If caries or necrosis exist, it is to be treated in the manner hereafter given. The wound must be always kept open, till no more pus is evacuated, and the abscess cavity has had time to fill up with granulations. This is best done by an india-rubber tube, with small perforations to permit the escape of the pus.

If the granulations become exuberant, and protrude beyond the conjunctiva, they are to be kept down by applications of tincture of opium, and if necessary, snipped off with the scissors. If, after closure of the opening, the globe remains somewhat prominent, and there is œdema of the conjunctiva, a pressure-bandage is to be applied. It usually answers the purpose quickly.

If in the course of the disease the eye-ball appears very hard and tense, or a hypopion occurs, paracentesis corneæ is urgently required, and must be repeated if necessary. If pus has collected in the posterior chamber, the eye is lost. But we must not neglect evacuating the pus, as soon as possible, by a puncture through the sclera, to ease the pain of the patient, and save as much of the eye as possible.

Attempts to prevent, by bandages, &c., the anomalies of position of the eye-ball and lids, which are often caused by contraction of cicatrices, are almost always fruitless. Where circumstances render a favorable result possible, of course such attempts should not be neglected.

Special therapeutics gives the rules for treatment of the disease of the brain.

Authorities.—*Mackenzie*, Traité d. mal. d. yeux. Traduit p. Warlomont et Testelin. I. Paris. 1865. P. 168 et seq.—*Himly*, Krankheiten und Missbildungen. I. Berlin. 1843. S. 363.—*Carron du Villards*, nach Arlt, Krankheiten des Auges. III. Prag. 1856. S. 425.—*Fischer*, Lehrb. der ges. Entzündungen. Prag. 1846. S. 359.—*Stellwag*, Ophth. II. S. 1257, 1261, 1263.—*Leyden*, Virchow's Archiv. 29. Bd. S. 199.—*Graefe*, kl. Mntbl. 1863. S. 49, et seq.—*Berlin*, ibid. 1866. S. 77.—*Tetzer*, *Rydel*, Wien. med. Jahrb. 1866. 4. S. 75, 77.—*O. Becher*, Wien. med. Wochenschrift 1866. Nr. 65.—*Küchler*, Deutsche Klinik. 1866. Nr. 21.—*Graefe*, Virchow's Jahresber. 1868. II. S. 510. —*Mooren*, Ophth. Beitr. S. 26.—*Biermann*, klin. Monatbl. 1869. S. 71.—*Knapp*, A. f. O. XIV. 2. S. 234.—*Hulke*, Lancet, 1867. II. S. 395; Schmidt's Jahrb. 133. Bd. S. 328.—*Zander*, *Geissler*, Verletzungen d. Auges. 1864. S. 219, 291, 335, 399.

3. Periostitis with Caries and Necrosis of the Orbital Walls.

Symptoms and Course.—At the commencement, the disease usually resembles a simple abscess, and often can not be distinguished from it, with absolute certainty, till the pus has been evacuated and a probe passed through the passage thus formed. Still, from the first, there is usually excessive pain, which is often extensive, and is generally increased by pressing or tapping on the orbital walls. The superjacent conjunctiva and skin ordinarily participate, subsequently, in the inflammation. Moreover, when the affection is deeply situated, and its center is not at the apex of the pyramid, the eye-ball is not pressed forward and surrounded by the swelling so regularly as in a simple orbital abscess, but is pressed to one side or the other, and its movements interfered with, according to the seat of the affected part. (*Graefe.*)

The process is often acute, with high fever and intense symptoms of inflammation, which rapidly increase till suppuration occurs, and perforation follows. In other cases the intensity of the process is moderate from the first. Then it is less rapidly developed, or even inclines to a subacute course, and weeks may pass before suppurative perforation occurs. Fever is altogether absent, or occurs only occasionally. The inflammatory swelling of the soft parts bears more the character of simple œdema. There is usually, however, considerable pain. Sometimes, as when it is of syphilitic origin, this occurs only periodically at certain times of day; but as a rule it is continued, and vibrates between exacerbation and remission. It is usually described as tense or tearing. If the margin of the bony orbit, or its immediate vicinity, be affected, we may occasionally perceive the protrusion of the bone, or the detachment of the periosteum; the latter shows itself by the occurrence of an indistinctly fluctuating, hard tumor.

Finally, the disease of the bone often develops itself very slowly and gradually, with such undecided symptoms, that it may long remain unobserved, till, after weeks or months, the process takes a new start, and the pus breaks through. Especially where the inflammation is deep, is it easily overlooked, as there are scarcely any objective symptoms, and at most a more or less severe, occasionally exacerbating pain points to the existing disease. However, when the affected bone is more superficial, the œdematous swelling of the surrounding soft parts, occasionally also the decided thickening of the bone, or the vesicular protrusion of the periosteum, together with the pain, increased by pressure, prevent errors of diagnosis.

As a rule, perforation takes place outwardly through the conjunctiva or lid; the former occurs when pus lies behind the tarso-orbital fascia, the latter when the disease originates in the margin of the bone. Usually only one sinus occurs; rarely the pus makes a road through several at a distance from each other. Exceptionally, however, it happens that, after partial destruction of the bony walls, the abscess opens into the nose, frontal sinus, antrum, or the cranial cavity.

The pus evacuated is usually unhealthy; it blackens silver probes, or shows by its discoloration and bad smell that it is much decomposed. Only when the disease of the bone is advancing toward a cure does the pus become thicker and benign.

Corresponding to this, the walls of the abscess have the characters of true ulceration, which is especially evident at the mouth of the cavity. This usually appears surrounded to a greater or less extent by swelled, but relaxed, not unfrequently granular tissue of a bluish or brownish red color.

Then a probe introduced through the sinus proves the roughness of the bone, as well as the exuberant granulations. We rarely find loose pieces of bone at first; for it usually requires some time to throw off necrosed splinters. Exceptionally, we pass the sound through a rough opening, bordered with bone, into a neighboring cavity. Still, this rarely happens, as caries and necrosis are usually superficial.

The sinus closes permanently only when the caries is actually stopped, or the piece of dead bone has been thrown off. If it closes earlier, whether by exuberant granulations or by actual cicatrization, the pus collects again, and the process is repeated. Then the destruction of the soft parts and bones is sadly increased. Frequently months, and even years, pass before the termination of the process.

Causes.—The disease is not unfrequently developed primarily, as a result of concussions and injuries of the orbit, although weeks and months may often pass before its symptoms are perceived. Recently, it has often been caused by carelessness in operating for destruction of the lachrymal sac. It also frequently occurs as a local manifestation of constitutional syphilis, and then usually runs a subacute course. Mercurial poisoning and gout are also considered as causes. Most frequently, however, scrofula is the cause of caries and necrosis; hence a very great percentage of the cases is found among badly-nourished children. It then often appears in several bones simultaneously, or at short intervals, and is usually characterized by great torpidity and a very slow course. Its favorite seat is the bony margin of the orbit, and especially the outer lower part. Often also there is no apparent cause. The disease seems to develop spontaneously in otherwise healthy individuals.

Secondarily, caries and necrosis occur quite often as a result of orbital abscesses, of phlegmonous dacryocystitis, sometimes also of facial erysipelas and embolis. In some cases the orbital walls are affected by a propagation of the process from the neighboring bones of the face. Swellings which develop in the neighboring cavities and push their walls apart, not unfrequently also cause caries and necrosis. Finally, suppurative meningitis and abscesses of the brain are to be mentioned as possible causes. In fact, not a few cases show that abscesses forming in the brain primarily may, by carious destruction of the orbit, make a way out, and thus be evacuated.

Termination.—As a rule, the process ends in recovery, after the carious portion of the bone has lost its roughness, and perhaps some part has been necrosed and thrown off, which usually occurs gradually, and in small, often microscopic, splinters, rarely in large fragments. Then, on the site of the former roughness, or on the edge of the bony cavity, granulations develop; the pus, escaping from the sinus, becomes diminished, and is healthier looking; the sinus itself contracts, the parts around its opening become lighter red; finally it closes up, not again to break out.

Sometimes recovery occurs in this way without serious injury having occurred. Much oftener, however, the cicatritial formation leads to unfortunate, permanent results, which may render doubtful the continued existence of the function, or even of the eye itself. This of course depends greatly on the locality and extent of the abscess.

Caries and necrosis occur most frequently at the margin of the orbit, and destroy

larger or smaller portions of the marginal ring, which is partially explained by the fact, that this part is most exposed to injury, and that in individuals predisposed, especially in scrofulous children, even apparently slight injuries suffice to occasion inflammation of a bad nature in the bones. The result is a deep, funnel-shaped cicatritial contraction of the external skin, which, in most cases, causes more or less ectropion.

The process is also often observed in the anterior third of the orbital walls. In scrofulous children, the fossa for the lachrymal gland is especially liable to the disease, the result of which is usually cicatritial eversion of the upper lid, or a lagophthalmos caused by its shortening; for under such circumstances the lid around the mouth of the sinus usually ulcerates, and draws together from cicatritial contraction. At the same time, the granulations sprouting up from the surface of the bone and the tissue surrounding the abscess cavity, change to thick cicatritial tissue, which contracts more and more, and thus often draws the cicatrix of the lid close to that of the bone. If the inner portion of the anterior wall be the seat of the disease, the lachrymal sac will usually be affected and injured.

Less frequently the caries and necrosis occur on the posterior portion of the orbital wall. These are the worst cases; for they always cause extensive suppuration of the orbital tissue and its sequences. The optic nerve is not unfrequently affected, and its function destroyed by inflammation, or it is compressed in the foramen opticum by the swelling of the bone and periorbita till it atrophies. (*Horner.*) Moreover, under such circumstances, fatal results are quite possible, for the excessive and long-continued secretion of pus is alone sufficient to completely exhaust debilitated patients. If the walls of the orbit are affected secondarily, for instance, from a progressive ozœna, or if, as occurs occasionally in disease of *syphilitic* origin, a caries of the orbital walls, at first limited, gradually spreads over a large portion of the bones of the face, even strong persons will finally be brought down.

Besides this, the vicinity of the brain is of the greatest importance. In caries of the roof of the orbit, the meninges and even the brain itself suffer sooner or later, and usually betray this by very marked symptoms. In many cases death is thus caused very early. Occasionally it occurs suddenly with apoplectic symptoms, because the abscess has perforated into the cranium through the necrosed portion of the roof of the orbit. Frequently, however, death occurs late, and after long suffering. It is remarkable how much the organism can bear in this respect. Not a few cases are known in which the orbital abscess was connected (through an opening in the bone, caused by caries or by simple pressure), with an abscess of the brain, as large as a hen's egg, so that the pus, from the brain abscess, was conducted off by the canal passing outward. Such abscesses of the brain existed for months or years without peculiarly marked symptoms indicating them, and finally arrived at a permanent cure, by cicatrization.

Treatment.—As in caries and necrosis of other parts of the skeleton, the first indication aims at removing or limiting as much as possible the inflammatory change of tissue. The second care is to evacuate, as soon as possible, the pus that has already collected, and to maintain a free escape, as well as to favor the removal of dead bone. Finally, the treatment should influence the process of cicatrization to reduce the evil results as much as possible.

1. The causal indications are especially strong when the disease arises from some dyscrasia, and often demand constitutional treatment; without this, little can be

expected in syphilitic or scrofulous cases. When, as a result of disease of the bone, the entire organism is much affected, constitutional treatment must not be neglected, since a bad state of the nutrition of the body reacts very unfavorably on the local disease. Of course, where the caries is a secondary disease, the primary affection requires a proper treatment.

2. The direct treatment is nearly the same as that of orbital abscess. In the first stage, antiphlogistics are to be used according to the intensity of the process. Where the process is very chronic, local antiphlogistic treatment is of little account, and must usually be limited to the doubtful benefits of mercurial friction, or the application of a padded bandage. Still, such processes arise from dyscrasiæ, and if we can remove the cause, local antiphlogistics are usually unnecessary.

3. As soon as the formation of an abscess is evident, it should be opened. The rules for this were given, p. 529. If, at the same time, the periosteum appears much thickened, or pressed out by pus, it is very important that the incision should go down to the bone, on the one hand to remove the tension, and on the other to prevent the further detachment of the periosteum from the bone. Where the abscess is superficial, this is not difficult; when deeper, it is often impracticable. But then, it is often scarcely possible to recognize the condition with certainty; hence spontaneous perforation is usually awaited.

4. If the abscess has been evacuated externally, the closure of the opening must be prevented. This is done by introducing charpie, smeared with fat, which must be renewed daily, or by the use of gutta-percha tubes. Frequent probing must not be neglected, to test the condition of the diseased bone, and to discover early any splinters lying in the sinus, so that they may be removed. If the process goes on very slowly, and all symptoms of irritation are gone, and the pus becomes very thin, the charpie may with benefit be smeared with some irritating salve, or cauterizations with nitrate of silver, or the hot iron may be required to terminate the process. Exuberant granulations are to be kept down by nitrate of silver or tincture of opium. Not until the bones have lost all roughness, and all the necrosed part has been thrown off, and only a little healthy pus is evacuated, dare we permit the closure of the sinus.

5. To prevent shortening of the lid, or ectropion, in caries or necrosis of the margin of the orbit, tarsoraphy may be very useful. Where the disease of the bone is situated more deeply, all attempts to prevent the evils, resulting from cicatrization, fail.

Authorities.—*Mackenzie*, Traité d. mal. d. yeux. Traduit p. Warlomont et Testelin, I. Paris 1856. P. 37, 40.—*Stellwag*, Ophth. II. S. 1343. Nota 301.—*Graefe*, A. f. O. I. 1. S. 430, 436, IV. 2. S. 162; kl. Mntbl. 1863. S. 50.—*Horner*, kl. Mntbl. 1863. S. 71, 74-77.—*Heymann*, A. f. O. VII. 1. S. 144.—*Pagenstecher* und *Sämisch*, kl. Beobachtungen. I. Wiesbaden. 1861. S. 75.—*Demarquay*, Centralbl. 1868. S. 862.—*Hulke*, Lancet. 1867. II. S. 395.

PART II.

TUMORS.

Tumors.

Nosology, Symptoms, and Course.—Morbid growths of every description occur both in the eye-ball and its appendages. Some are rarely met with; others are of more frequent occurrence. We find that certain of them affect only particular organs, while others attack any part where blood-vessels exist.

They were formerly distinguished as malignant or benign; the former term being applied to such as spread, with more or less rapid growth, into tissues of varied character, and destroyed them; were liable to extend by means of the lymphatics and blood-vessels, setting up new foci in different parts of the body; hence, were difficult to remove, relapsed as a rule, at last became general, and assumed a constitutional habit.

These peculiarities do not, however, depend on certain specific elements, whose presence or absence determines the benign or malignant character of the tumor. On the contrary, the typical forms of normal tissues, of epithelium, and of muscle-cells, of connective tissue in its various forms, of cartilage, and bone-cells, &c., are repeated in the structure of tumors of the most varied nature. Moreover, the benign or malignant character is not determined by the elementary forms alone, but by their correspondence with the mother-cells from which they originate. The same elements have a different prognostic indication according to the tissue from which they sprung; that is, as they appear homologous or heterologous. They are dangerous when they depart from the type of the mother-tissue, or even differ from it in histological character; for instance, in having an epithelial character when located in connective tissue, or cartilage. Their malignancy increases when they are very succulent, and when they have a large amount of fluid in the intercellular substance; or, when they are very perishable, readily breaking down, and undergoing rapid regeneration by means of luxuriant granulations; or again, when the basis from which they arise is thickly permeated with lymph and blood-vessels. For the conditions favoring absorption of morbid material into the blood, and its dispersion through the system, are multiplied in proportion to the amount of soft or recrementitial matter in the tumor, or as the number of its lymphatics or blood-vessels increases. Then the immediate results are irritation in the various parts, the formation of new foci in the most varied localities, and finally, the not unfrequent saturation of the blood with foreign materials, the lowering of the entire nutritive conditions, in short, the occurrence of *cachexia.* (*Virchow.*)

Tumors can only be correctly classified on the basis of their anatomical origin. From this point of view there are three chief groups, to which might be added, as a fourth, tumors caused by hydatids.

The *first class* comprises tumors composed of blood, or materials coming directly from the blood, contained in natural or mechanically-formed spaces, such as *extravasations*, *transudation* and *exudation* tumors.

The *second class* comprises tumors due to collections of secretions proper, in existing cavities, such as *retention* and *dilatation* tumors.

The *third class* represents growths, the true new-formations or pseudoplasms,

which grow immediately from the structure of the organs, originating in actual formative processes, or a true proliferation of tissue. (*Virchow.*)

A. Tumors of the first variety are rare in the parts about the eye.

Besides some cysts observed deep in the orbit, those orbital and sub choroidal tumors, formed from hemorrhages by thickening and partial organization of clots, belong in this class.

B. From the richness of the ocular region in glandular organs, tumors of the second class are frequent.

1. The integument of the eye-lids and neighboring parts of the face, is often thickly strewn with comedones and miliary nodules. Exceptionally, from the hardening and deposit in concentric layers of the secretory cells of the sebaceous follicles, the latter reach the size of a hemp-seed. Thus, whitish-yellow nodules, hard as cartilage, are formed, which are very prominent, and much resemble "pearl-tumors." In former times, these appear to have been described as *lithiasis* (*Himly*), or, judging from some old wax preparations, as *grando*. In a case recently observed, a zone, two lines broad along the free edges of both lids of the left eye, was covered by such nodules, so as to present the appearance of a section of a fig. In some places, the tumors collected into racemose clusters. An umbilication could be distinguished on the surface of most of the nodules. The eye-lashes were well preserved, and grew out from between the nodules. On the lower lid were numerous hordeoli. The skin of the entire face appeared richly strewn with similar tumors, together with miliary eruption, comedones, and numerous acne pustules.

Sometimes, in this region, as well as over the brows, we meet with true sebaceous tumors, with fatty, gelatinous, or even honey-like contents (*atherom, meliceris*). Hairs occasionally grow from their inner walls. (*Himly, Kerst,* [*Hackley*].) Sometimes they attain considerable size, press into the orbit (*Schwarz, Testelin*), and may cause exophthalmos. Occurring near the lachrymal sac, they may be mistaken for an affection of this organ. (*Himly, Hasner.*) Some cases of molluscum, observed on the lids (*Mackenzie*), may have been modified sebacous tumors. Chalazia ("hail-granules") may also be regarded as cysts.

2. Acne also occurs in the caruncle, which is rich in sebaceous glands. It sometimes originates spontaneously (*Mackenzie*), sometimes as a result of mechanical irritation from foreign bodies, inverted cilia, or stiff and distorted caruncle hairs. (*Himly.*) Ulceration of one or more sebaceous glands is the usual result. Sometimes, however, the retention of the secretion causes inflammatory hypertrophy of the stroma; the caruncle swells to a considerable tumor, and the distended follicle appears on, or projects from, its surface as a yellowish, round nodule. (*Himly, Graefe.*) Its contents readily condense into a fatty atheromatous mass. (*Benedict, Weller.*) As an exception, extensive concrements form (*encanthis calculosa*), which occasionally attain considerable magnitude. (*Blasius, Sandifort, Schmucher, Riberi.*) Now-and-then, as a result of luxuriant proliferation, the caruncle protrudes as a large, spongy tumor (*encanthis fungosa*); it granulates, and forms fleshy, warty outgrowths. Probably, also, some of the mucous polypi (*Mackenzie*), which have been seen on the caruncle, are to be regarded as *retention* tumors.

3. In the same way the glands of the conjunctiva and lachrymal passages are subject to dilatation from collected secretion. The tumor occasionally develops as a mucous polypus, more frequently however as a cyst. These are occasionally found at different parts of the conjunctiva, as thin-walled vesicles, with clear, serous contents, about the size of a hemp-seed, pea, or bean, projecting perpendicularly from the surface of the membrane. If the thin mucous covering be divided, the cyst often rolls out. It is only loosely connected with the surrounding parts. In other cases these cysts are quite large, attaining the size of a hen's egg, or more. Then they often grow into the orbit, causing exophthalmos. In such cases their walls are usually very thick, aponeurosis-like, and are but loosely attached to the orbital connective tissue, which is thickened into a strong, tendinous membrane. The contents are mostly fluid, serous, often yellowish or brownish, rarely hemorrhagic, exceptionally milky or gelatinous. They are most usually situated to the inner side of the globe, and in the course of years not unfrequently destroy the cribriform plate, penetrate into the nose, and expand throughout its cavity. (*Ressel, Caratheodori, Fano.*) In one case such a cyst forced its way through the optic foramen into the skull, and caused pressure on the brain. (*Delpech.*)

4. The mucous polypi and cysts, which occur in the nasal and frontal cavities and in the antrum, and sometimes attain such enormous size as to contract the orbit, or even the cranial cavity, by pressing on the bony walls (*Mackenzie*), originate mostly from the glands of the mucous membrane, and are originally caused by collections of secretion (*Virchow*). Like orbital cysts, they are often multicellular.

5. Swelling of the lachrymal sac, which accompanies blennorrhœa, particularly the so-called *hydrops sacci lachrymalis*, should also, strictly speaking, be classed among dilatation tumors, as well as *dacryops*, and the watery vesicle of the lachrymal gland (*Ad. Schmidt*, *Beer*). The latter is by some, however, attributed to hydatids (*Himly*). It sometimes develops rapidly, sometimes more slowly, causes marked exophthalmos, and, by displacement of the roof the orbit, may cause pressure of the brain, or even the symptoms of apoplexy. Sometimes it suppurates, and a cure or a fistula results.

6. The cysts of the iris, moreover, deserve mention, although their reference to folding and sagging of a section of the iris (*Wecker*) will scarcely suffice for the great majority of cases, and the structures in question most probably have very little in common with "retention tumors." According to what has been shown (*Hulke*, *Wecker*), they contain, as a rule, a serous-like contents, exceptionally however fatty and grumous, and even hairs (*Graefe*). Their cavity is lined with epithelium, and their wall is connected directly with the tissue of the iris, or is rather nothing more than rarified iris tissue itself. Such cysts are situated most frequently in the inferior part of the iris, and sometimes attain a very considerable size, so that they almost entirely fill the anterior chamber. In almost two-thirds of the cases they are said to have been caused by wounds, particularly by perforating injuries of the cornea (*Hulke*).

In one case a congenital cyst, with clear, serous contents, was found in the anterior inferior part of sclerotic, and referred to a dilatation of the canal of Sclemm (*Waldhauer*).

[A case of cyst of the iris is described (*Althof*) as a structureless membrane believed to be the membrane of Zinn, which had been lifted up from its base and served as the anterior wall of the cyst, the posterior wall being formed of the atrophied tissue proper of the cyst.]

C. The growths proper, occurring in the eye and its adjuncts, are sometimes *histoid*, composed of a single tissue, and are then often simply hyperplasia of any histological constituent; again they are *orgagoid*, composed of several tissues, which not unfrequently show a distinct typical arrangement, and thus give the tumor a resemblance to some parts of the body; finally sometimes several parts unite, and in their union correspond to a whole system of the body (*teratoid tumors*). Besides these, there are the *combination* tumors, in which several forms have united.

The power of combination in tumors is very extensive. Not only do the most varied forms unite among themselves, but tumors of all three of the above-mentioned varieties unite together. Indeed, it occasionally happens that, in one growth, cavities are formed by extravasations, transudations, and exudations, around which the compressed and inflamed tissue is bulged out into a cyst. Then, again, we not unfrequently meet with tumors of the first or second class, in whose cyst or bed tumors grow, that gradually envelop the cyst, or even grow into its cavity and fill it up. Pseudoplasmata occasionally form also in glandular organs, and, by mechanical obstruction of excretory ducts, cause retention of the secretion and the formation of cysts.

This change of type in tumors is very important practically, as tumors originally benign may gradually become malignant. In general, a tumor can only be considered as benign as long as it is strictly homogeneous. As soon as it ceases to be so, it must at least be regarded as suspicious (*Virchow*), especially in the region of the eye.

The very considerable richness in lympathics and blood vessels of these parts, as well as the circumstance that the orbit is surronnded by cavities very difficult or impossible of access, are to be especially regarded as rendering even the continuous progress of a tumor injurious, and still more so its dissemination.

1. Fibromata contain, as sole or chief constituents, connective tissue, in the ordinary sense of the word. They proceed mostly from the stroma of the part, and especially from the thick, hard expansions of which the membranes are composed. Rarely they originate in other analogous tissues, as the bones, and are then heterologous. They frequently are *histoid*, and then represent simple hyperplasia. Often, however, their formation is complex; the tumor is somewhat organized. Moreover, fibroma is often found as a *combination* tumor, either because adjacent parts of a structure have, from the outset, produced different elements, or because a tumor, purely fibrous, has in places changed its type occasionally, and developed mucous or cellular elements or vessels, or become cartilaginous or bony, or even by alveolar structure, and the characteristic deposits of epithelial tissue indicated the transformation into cancer. They are generally divided into diffuse, papillary, or warty, and tuberose.

a. First in this series stands elephantiasis, which has, in rare instances, been observed on the lids (*Carron du Villards, Graefe*), as well as some forms of molluscum. (*Virchow.*)

b. In the second class may be placed *pinguecula*. This is only found in the ocular conjunctiva, lying in the palpebral fissure. Often, however, its base extends into the episcleral tissue, or even into the sclera. It is about the size of a hemp-seed, in rare instances, a large, flat, roundish, sometimes pendant, yellowish-white body, which externally much resembles fat, but, on close examination, is found to be embryonic, connective tissue. These bodies are usually covered by dilated vessels, are painless, and, once developed, usually persist unchanged during life. They are more frequently found in old than in young persons. It appears that exposure of this portion of the conjunctiva to external injuries is to be regarded as the cause of the very frequent occurrence of this sort of hypertrophy. At all events, frequently recurring irritation of the conjunctiva favors the establishment of pinguecula. (*Seitz.*)

c. The papillary, warty, ragged fibromata are occasionally developed on the skin, conjunctiva, and caruncle. Exceptionally, they have been seen growing in the form of a fringe from a follicle of the latter. (*Carron du Villards.*) Their starting-point is the connective-tissue stroma. They here form as small, amorphous, granular, or homogeneous bodies, in which cells are only subsequently developed. (*Virchow.*) Their further growth results from increase of the cellular parts, or that of the intercellular substance. The first often preponderates so much that an actual state of granulation results, and the overgrowth acquires a fleshy, warty, or spongy look, such as occasionally occurs on ulcers of the conjunctiva and cornea, prolapsed iris, &c., and is often even pedunculated. They may contain few or no vessels. Usually, however, such tumors are traversed by an exceedingly dense net-work of vessels, and may then, if covered merely by a thin, superficial layer of soft epithelium, be liable to spontaneous hemorrhage (*Seitz*), which sometimes proves dangerous from its magnitude. Papillary fibromata often lie flat on their substratum, and appear as isolated or grouped, pale or deep-red nodules, more or less hard, which are usually without sensation, although in exceptional cases they itch excessively. (*Beer.*) Sometimes these nodules unite to tumors of the size of a raspberry (*Himly, Chelius, Ammon*), which usually are very vascular, but at times may be of quite a dark hue, from the pigment which they contain. (*Travers.*) They are often found elevated by a pedicle above the surface. (*Mackenzie, Arlt, Hasner.*) This pedicle is formed of very hard connective tissue, and usually contains large vessels, which cause profuse hemorrhage, if the tumor be cut off. In some cases these growths have returned. (*Arlt.*)

d. Tuberous fibromata comprise, among others, those tumors which were formerly described as fibroid, steatomata, fibrous polypi, and, when situated on the skin, as molluscous tumors. They consist of radiated and fasciculate connective tissue, which occasionally solidifies to a cartilaginous hardness, but frequently are much less consistent, and often contain a large amount of mucous tissue. They may even be soft, or almost fluid. (*Virchow.*) Besides the skin, the fascia, and periosteum are the usual starting-points. The hard, firm nodules, which occur in the orbit, lie usually about its edge, and are often attached by a broad base to the bony walls. As a rule, they grow slowly, sometimes ossify (*Graefe*), or calcify (*Bader*), and rarely attain a great size. (*Schuh, Weinlechner, Zehender.*) If large, such a tumor is almost always a case of combination tumor, e. g., a secondary cyst (*Mackenzie*), a transformation into cancer, &c. The softer tuberous fibromata are often pedunculated, and project far above the surface, push the mucous covering

before them, and are covered by it as far as the pedicle. The latter is usually hard, and originates by one or more roots from the periosteum. The body of the tumor may be of cartilaginous hardness (*Lawrence*), but usually it is very soft. These pedunculated fibromata, or fibrous polypi, have been found in the conjunctiva (*Graefe*), in the lachrymal duct, and in other cavities lined with mucous membrane. On the conjunctiva it is exceptional for them to exceed the size of a hazel-nut (*Jüngken*). The depth to which their roots extend causes them readily to return after extirpation.

2. Dermoid tumors, with some others, were formerly classed together as "warts." They occur quite often on the outside of the lid, and on its free margin. Exceptionally, they are found at the superior reflection of the conjunctiva, whence they bulge out between the superior and external recti muscles (*Graefe*), and, as they are connected with sub-conjunctival fat, they are mistaken for lipomata. There are also numerous cases where they have been developed on the corneal border, one part of them being on the cornea, the other originating in the conjunctiva or sclera, and often entering deeply into their tissue.

These warts are of the size of a grain of pepper, a bean, or larger. They are usually roundish or oval, and more or less projecting. They are often as soft as sponge, but frequently, too, are quite hard, or even cartilaginous. Their color varies exceedingly; they are sometimes of a tendinous whiteness, fatty yellow, red, brownish red, or even dark brown. The surface of the tumor is sometimes smooth, sometimes granular, like a raspberry, and sometimes bears upon it a number of delicate short and pale, or stiff, long, dark hairs (*trichosis bulbi*). These tumors consist of a pad of connective tissue and elastic filaments, covered by a thick layer of epithelium, in which are situated the hair-follicles, either with or without accompanying sebaceous glands (*Virchow*). They are usually congenital, and increase gradually with the growth of the body (*Ryba, Fischer, E. Müller, Graefe, Lainati, Visconti, Achilli, and others*).

It is thought that these must be connected with the congenital fissures of the lids, in which at least indications of them are found. It is believed that that part of the integument which, in the growing forward of the lids over the globe is changed into conjunctiva, preserves the character of the external skin on the place in question, and thus represents the dermoid tumor (*Wecker*).

3. Lipomata. These contain an oleaginous fat in nucleated cells, which are usually somewhat larger than normal, are always ragged, and depend on new formations, on hyperplasia of existing fatty deposits. Sometimes the fat preponderates in them, and they are very soft; sometimes the connective tissue, when they may possess considerable consistence. According to some, they occur most frequently in the orbit (*Demarquay*). Other experienced authors have never seen them there, and believe lipomata observed in such portions to have been vascular tumors, which often resemble the former so much as to be mistaken for them (*Schuh*).

In one case a lipoma is said to have been found in the subconjunctival tissue (*O. Becker*), and in another case even in the iris (*Mooren*).

4. Myxomata.—The chief constituent of these is mucous tissue, which is normally represented by the vitreous, the jelly of the umbilical cord, and the neuroglia of the nervous system. It is intimately related to fatty tissue, the one being directly convertible into the other by increase or decrease of fat. They are very soft, often fluctuating like a cyst. From their cut surface exudes a filamentous fluid, which exactly resembles mucus. There is also found a filamentary basis, with elements much resembling connective-tissue fibrillæ, but very loose, and filled with mucilaginous fluid. The intercellular substance contains cellular elements in variable amount and of different forms (*Virchow*).

In recent myoxmata the round cells (mucous bodies) are in excess; in old, the spindle-shaped and stellate preponderate. The latter sometimes anastomose and exhibit an areolar formation. In

proportion as the cells disappear or are more abundant, or by increase of fat change to fat-cells, the tumor appears hyaline, medullary, or lipomatous. It frequently happens, also, that the intercellular substance becomes fluid, and cystoid excavations form, or that the framework solidifies into a hard mesh-work of connective tissue, or even becomes cartilaginous, or contains numerous vessels, which in some places seem of a talangiectetic nature; the myxoma partly changes to a cystoid, fibrous, cartilaginous, or talangiectatic form. (*Virchow.*)

On the whole, myxomata do not occur frequently. They usually develop as homologous tumors, and then are usually benign. Still, they are capable of the most varied combination with other tumors, not unfrequently transforming into very different tissues, becoming hetero'ogous and decidedly malignant in character. (*Virchow.*)

Indeed, it seems as if certain growths described as colloid cancer, which have affected the entire eye-ball and the surrounding orbital tissues, should be regarded as myxoma. It has been observed in the optic nerve, where it forms tumors more or less extensive, which are encapsulated by the sheath of the optic nerve, push the eye regularly forward, and limit, without entirely arresting, its motions, rapidly cause blindness, and run their course without pain. In one such case the eye was already evacuated as a result of ulceration of the cornea, and flattened antero-posteriorly. (*Rothmund.*) In another case the globe still retained its shape, and by the ophthalmoscope the pressure of the growth on the papilla could be made out from the bulging forward and cloudiness of the latter, as well as from the congestion of the retinal vessels. (*Graefe.*) In a third case the myxoma in the papilla had developed in company with a number of analogous small tumors in the fatty tissue of the orbit. (*Jacobson.*)

In a fourth case the myxoma filled the entire orbit as a recurrent tumor, after the globe had been extirpated on account of a tumor of the posterior part of the eyeball, which reflected a yellowish-white light, and had existed for two years (*Lebrun*).

5. Chondromata, whose basis is cartilaginous tissue, may now-and-then have been observed in the orbit, and are mentioned in literature under the names osteo steatomata, osteo-sarcomata, &c. (*Mackenzie, Chelius.*) But it is difficult to determine strictly what cases belong in this category. At all events, oculists very rarely meet with chondroma. (*Schuh.*) Once a bit of cartilage has been found in a warty growth on the edge of the cornea (*Schweigger.*) Chondroma have also been seen in the lachrymal gland. (*Busch.*) They sometimes develop from normal cartilage, sometimes from other tissue; hence they are either homologous or heterologous, and in the latter case may be very malignant. They may be very soft, or ossify, undergo amyloid degeneration, and ulcerate. They often come in combination with other tumors, as myxoma, cancer, &c. Their comparative frequency is greatest in young persons. (*Virchow.*)

6. Osteomata are developed from connective tissue or from a cartilaginous base, but are distinguished from ossifying fibroma, chondroma, &c., by the fact that, in them, the whole process is from the first directed to formation of bone. They are often as hard as ivory, consisting of compact bony substance, with vessels, and a periosteal or cartilaginous covering. In other cases the tissue is spongy, and even contains medullary substance in its canals or greater cavities. Osteomata are usually mere hyperplasia, but they also occur as heterologous growths, and are frequently combined with other tumors, especially myxoma, cysts, &c. (*Virchow.*) Homologous osteoma occasionally appears as an excessive development of certain bones or of entire portions of the skeleton, which are then enlarged into shapeless masses, *leontiasis.* (*Virchow, Acrel.*) More frequently, however, they form circumscribed tumors, which project more or less above the surface from which they originate. Sometimes they grow immediately from the substance of the latter, sometimes they depend on a proliferation of the periosteum. A connective tissue tumor forms first, this gradually ossifies and unites with the subjacent bone. The osteomata occurring in the orbit are usually as hard as ivory. They frequently originate in the diploe of the bone affected, and readily break through to both sides, so that the tumor appearing in the orbit is only part of a growth, which projects into various neighboring cavities. (*Mackenzie, Knapp.*) This should be borne in mind, especially when there is a question of removing the growth by an operation. An osteoma can usually be removed without danger from the orbital plate of the ethmoid (*Maisonneuve*), and from the floor of the orbit. (*Mackenzie.*) But if seated on or near its roof, such an operation would be very hazardous, for the simultaneous projection of the tumor into the

cranium is never betrayed by marked symptoms (*Knapp*). Nevertheless, even osteomata originating here have been successfully operated on (*Mackenzie*, *Knapp*), for they do not all grow in both directions. Exceptionally also, we encounter cases where bony tumors originate from bones in the vicinity of the orbit, press against its walls (*Mackenzie*), and even perforate them (*Baillie*). Orbital osteomata may be small or large. Now-and-then they have been met with in both orbits at the same time (*Frank*, *H. Walton*, *Howship*). Young persons suffer from them more frequently than old, females more so than males (*Virchow*). They often proceed from wounds; their development and increase is usually very slow, sometimes painless, at others very painful. In some cases osteomata are said to have receded (*Mackenzie*), or to have broken off from the basis, or to have been thrown off by suppuration (*Stanley*), or, after operative procedures, they have broken down and become obliterated through carries (*Brassant*, *Spöring*).

7. Melanomata, whose characteristic constituents are cells, heavily loaded with pigment, such as occurs in the uvea, are found as extensive brown or black discolorations of the integument of the lids, or of the conjunctiva. Sometimes, however, they occur as spongy tumors from the conjunctiva or orbital tissue (*Lisfranc*, *Cunnier*), again as warty growths from the margin of the cornea (*Travers*, *Ed. Jaeger*, *Heedäus*). Occasionally they are seated on the iris (*Graefe*).

8. Myoma. This form has only been once demonstrated, in combination with sarcoma in the region of the eye. It was situated in the inner quadrant of the ciliary body and choroid, ran its course with violent pain, and two years after the enucleation there was no recurrence. The tumor occupied the entire inner portion of the ciliary body, appeared in section whitish, fibrous, pigmented in its anterior periphery, and was tolerably sharply limited on all sides from the neighboring normal parts. The portion situated in the region of the ciliary body consisted of spindle-shaped cells, with elongated nucleus, which were arranged in bundles running meridionally, and resembled in their appearance the non-striated muscular fibers. A nuclear division could be nowhere perceived in them. The intervening spaces were filled with circular and stellate connective-tissue cells and finely-fibrillated intercellular substance. The most external periphery of the tumor consisted of round cells, between which were situated here and there deeply pigmented stellate and spindle-shaped cells, sometimes also connective-tissue fibers. Capillary vessels were also found there. In the neighboring portion of the corpus ciliare the muscular fibers were entirely unchanged, and between them lay neoplastic embryonic cells; yet at a distance of from 2-3 millm. beyond the limits of the tumor the entire tissues appeared normal (*Iwanoff*).

9. Glioma, or medullary fungus, proceeds from the neuroglia to the interstitial connective tissue of the retina, and is composed of a basis analogous to the latter, and of cellular elements (*Virchow*).

The cellular elements form the mass of the tumor. They are generally finely granular, delicate, circular, very small, and contain a relatively very large, round nucleus, which is closely surrounded by the cell-wall. In other cases they appear somewhat larger, likewise with very moderate-sized cell-body, which as a rule takes on a circular, but sometimes very regular form, provided with fine processes. Here and there longer fiber cells are seen isolated, with very long processes and a very slender and short cell-body. Sometimes also several of these are connected together.

The intercellular substance is sometimes quite soft, almost fluid, and after being artificially hardened, shows the fine fibrillary network peculiar to the neuroglia; occasionally, at least, in places, it is hard, and arranged in layers which have a more or less parallel filamentary striation. According to the preponderance of the one or other sort of intercellular substance, the glioma is called soft or hard.

Pure soft glioma contains moderate quantities of homogeneous granular intercellular substance, with various amounts of fibrillæ arranged in regular network, and containing nuclei and cells at their points of juncture. If the size of the meshes increases, and mucus collects in them, as often happens, the tumor is transformed to a myxoma. But often the cellular elements preponderate, so that the intercellular substance nearly disappears, and ramifications of greatly enlarged vessels becomes a prominent feature in the structure, which may be easily mistaken for an alveolar formation. This is called a true *medullary glioma*. This, again,

may change to a *medullary sarcoma* by a further development in size and contents. All these stages of transformation are often found in the same tumor; moreover, by excessive development of its vessels, part of the growth may furnish a typical picture of fungous hematodes. Hard gliomata are more like fibromata, and in some cases we may speak of combinations as fibro-glioma. In these growths the nervous elements always perish (*Virchow*).

Glioma may occasionally deposit its first germs in each individual layer of the retina (*Iwanoff*). As a rule, it appears to proceed from the neuroglia of the inner granular layer (*Robin, Hirschberg*), more rarely from the external granular layer (*Knapp*), or from the framework of the internal retinal layers, particularly of the layer of nerve fibers (*Manfredi, Iwanoff*). It is sometimes under the form of small white or gray points, which increase in size and grow to one or several larger nodules; sometimes it appears in the shape of a superficial, diffusely extended infiltration, which gradually thickens in one or more spots, and thus becomes a lenticular or cake-like tumor.

If the glioma appear primarily in the external layers of the retina, it usually soon perforates externally (*glioma exophytum*). It then appears usually as a circumscribed nodule of soft consistence, whitish or reddish-white, vascular appearance, and ragged, cauliflower-like seamed surface, which overlies the retina already generally detached throughout a wide extent. The elements of the retina are thereby as a rule entirely destroyed, as far as the gliomatous infiltration extends, whilst the overlying internal layers usually remain for some time in a state of integrity. Later the gliomatous infiltration continues to extend in all directions, while new nodules are ever forming, which run together. Finally the retina appears as a thick-walled funnel, infiltrated with large nodules, the pointed end of which is connected with the entrance of the optic nerve, and which by progressive growth may finally fill up completely the vitreous space.

If the glioma is developed from the internal layers of the retina, it often appears at first as a diffuse infiltration of the layer of nerve-fibers with a collection of gliomatous masses upon the inner surface of the limitans interna. This exudation appears at first as a tolerably uniform layer, fibrillated in hardened preparations, in which processes of the retinal supporting fibers enter in many places. Later this becomes thickened into little points and nodules of different size, which can be distinctly seen with the naked eye. The majority of these nodules are formed of glioma cells, which by space in the limitans interna are directly connected with the glioma layer of the nerve-fiber layer, and have evidently from this latter reached the free surface of the retina. Larger nodules, moreover, appear also to be traversed by vessels, which take their origin from the retinal trunks. In other cases the glioma in the internal layers of the retina is developed in the form of circumscribed nodules, which by increasing size gradually extend into the internal granular layer. They are, when of large extent, always very vascular, and their small cellular elements appear in sections to be collected in concentric rings around the walls of the vessels. With advanced growth these nodules usually perforate the limiting membrane, whereupon the secondary growth with its vessels increases further upon the inner walls of the retina, and in the form of a large tumor gradually displaces the vitreous humor (*glioma endophytum, Iwanoff*). The gliomatous growths, proceeding from the internal layers of the retina, do not so readily cause detachments of the retina. It is moreover uncertain whether those cases in which the infiltrated retina was found lying upon the choroid in the form of a spherical shell (*Sichel, Pokels*) or of a fig (*Horner*), should be counted among the endophytic gliomata.

The process encroaches as a rule very early upon the optic nerve and choroid, partly by direct propagation, partly by the dissemination of new germs.

In the optic nerve the glioma forms at first circular or elongated masses. These represent in longitudinal sections strings of small round cells, which extend more or less backward between the bundles of nerve-fibers. By progressive growth the nerve-fibers gradually become degenerated and the orbital part of the optic-nerve swells more and more. It then appears

cylindrical, sometimes spindle-shaped, sometimes it is pushed forward like the calyx of a rose, with considerable increase in surface of the lamina cribrosa. The process hereby frequently propagates itself step by step, or leap by leap, that is, by dissemination of germs, to the intracranial portion, which then not uncommonly forms extensive tumors, which generally end fatally within a short space of time (*Mackenzie*, *Joffroy*). Only exceptionally does the optic nerve remain unimpaired in advanced gliomatous affections of the retina, or undergoes atrophy (*Virchow*, *Knapp*, *Schiess-Gemuseus*).

The extension to the choroid takes place most frequently at the entrance of the optic nerve, where the stroma and the vessels of the retina and choroid are directly connected. In other cases the process encroaches upon places in which the retinal tumor touches the surface of the choroid, and then cord-like connections are sometimes found consisting of vessels, the adventitia of which is covered by a thick layer of gliomatous elements (*Schweigger*, *Hirschberg*). Secondary choroidal foci, however, are not uncommonly found in places which are separated from the retinal tumor by subretinal fluid. The extension then takes place, either by the vessels or by some portions of the retinal tumor becoming detached, falling upon the choroid and here growing luxuriantly in the stroma (*Knapp*). Such secondary choroidal foci appear in the beginning as thin, soft, whitish membranous deposits upon the tapetum, later as round foci of cells under the choroidal epithelium, and finally as smooth, disc-like nests of small round cells in the otherwise completely normal, true choroidal tissue (*Knapp*). Since the growth advances farther and farther from this focus, there is gradually developed a lenticular or cake-like, or bulbous choroidal tumor, which is usually more firm and compact than the retinal glioma, and in its stroma a more distinct fibrillation can generally be recognized. It then sometimes happens that the choroidal tumor remains somewhat behind in its growth, while the retinal tumor fills finally the entire disposable space in the vitreous chamber, even causes dislocation or destruction of the lens, and thus grows through the pupil into the anterior chamber (*Weller*, *Ammon*, *Chelius*). More frequently, however, the choroidal tumor extends more superficially, surrounds the funnel-shaped retina like a shell, and finally incloses it either entirely or throughout its greatest extent in the form of a more or less thick shell, in places bulging forward like knobs. The choroidal glioma is under such circumstances usually connected with the region of the entrance of the optic nerve, but elsewhere is very distinctly defined in its limits, as the limiting membrane with the remains of the tapetum, and even the choriocapillaris remains intact usually for a tolerably long time. The latter appear in meridional sections (Fig. 84), as a dark line, which, beginning at the ciliary processes, stretches in a winding course toward the entrance of the optic nerve. The choroidal glioma not uncommonly encroaches in its anterior border upon the connective tissue uniting the ciliary body with the sclera, pushes the corpus ciliare to one side, or destroys it, and thus reaches the anterior chamber, which it soon entirely fills.

Fig. 86.

Arrived at this point and frequently sooner, detached parts of the secondary growth commence to take on retrogressive metamorphosis, to undergo fatty degeneration, to calcify or to disintegrate.

The circumscribed fatty degeneration always proceeds with a considerable enlargement of the glioma cells, and causes the transformation of the secondary growths into caseous lumps, or into a soft, dirty whitish-yellow, deliquescent purulent substance, the chief constituents of which are fat cells, fat globules and fatty

detritus, and which frequently contain large quantities of salts.—Real cystoid degenerations (*Sichel*) are however rare. Sometimes the concretions attain a considerable size (*Robin*). They generally consist chiefly of phosphate and carborate of lime. In disintegration some parts of the tumor show a yellow, caseous property, and allow the shrunken cell-elements and nuclei to appear within them. The more compact constituents of the tumor attain by these processes sometimes a tendinous or even cartilaginous appearance, and form plates or framework, in which the fatty, sandy or caseous remains of the disintegrated masses lie, and which may in the course of time become ossified in part.

Upon the basis of more recent observations we may conclude that the gliomatous process is in this way scarcely ever really and permanently to be stopped, although some older experiences appear to indicate this. This much is settled, that partial recessions of the glioma, as a rule, usually bring with them either no stand-still in the growth of the tumor, or else only a very transient one. The tumors cease to grow sometimes for months, and even years. They may often be connected with inflammatory attacks, which are usually manifested under the form of irido-choroiditis. The globe, then, after a lull in the inflammatory attack, often becomes soft in a marked degree, and shrinks together perceptibly, and, in case the opportunity offers, we can demonstrate in its interior the inflammatory products, such as posterior synechiæ, irido-cyclitic membranous patches, ossified plates, upon the surface of the choroid, etc. (*Schiess-Gemuseus, Hirschberg, Knapp*).

In some cases, such instances of transitory atrophy of the globe have been seen to reappear repeatedly, that is, alternate with periods in which the shrunken globe again became filled up and attained a higher degree of tension, while the after-growth increases (*Knapp*).

In the majority of cases, however, there is no period at which the process is at a stand-still, the intra-ocular glioma increases more and more, disseminates its germs, and finally perforates. The perforation takes place usually through the cornea, more rarely through the sclerotic, or through the sheath of the already infiltrated optic nerve (*Hulke, Hirschberg, Neumann*).

Fig. 87.

The destruction of the cornea is brought about sometimes by neuro-paralytic ulcerations, usually, however, by the advancement of a panophthalmitis to the cornea, or the gliomatous mass already filling the anterior chamber grows into the corneal tissue (*Hirschberg*), and destroys it to the last remains. If the secondary growth has in such a manner projected from the anterior scleral opening, the growth is usually extremely rapid, within a very short time the glioma becomes swollen into a very large tumor, which projects from the anterior scleral opening, with a neck-like constricted base (Fig. 87), assumes a dark-red color, bleeds easily, and generally soon destroys the strength of the patient with its progressive increase in size. The globe often preserves its natural external form under these processes for a long time. Often, however, the elements from each other, not uncommonly excavate pocket-like spaces in the thickness of the scleral, and finally perforate outwards.

often appear very early, penetrate sometimes very deeply into the thickness of the d sheath of the optic nerve, cause in places an attenuation of the latter to a mini- it according to numerous observations scarcely ever actually perforate inwards, and w into the interior of the globe or of the optic nerve. There is sometimes a single sometimes a number of them. The orbital portion of the optic nerve has been found sed with numerous gliomatous nodules throughout its entire length (*Bader*). Such ular nodules manifest in the majority of cases a preference to extend superficially surface of the sclera and sheath of the optic-nerve, by not uncommonly enclosing and optic nerve for a considerable distance like a shell.

ndary gliomatous foci often develop themselves in the orbital tissue. pear at first nodular, but soon spread rapidly and destroy heteroplastically ividual structrues, nerves, muscles and lachrymal glands. They here appear cells and thus assume the appearance of gliosarcoma. In case they meet dules in their progress, which lie upon the episclera or in the sheath of the erve, or have penetrated through these from within, they usually blend with them. The orbital glioma finally forms not uncommonly an actual the cavity of the globe, separates its walls from each other, or by pressure al losses of substance in them, leads to their carious disintegration (*Hasse*, or passes directly to the bones (*Brodowski*), and thus opens for itself a o the neighboring cavities. The glioma often encroaches upon the lids ough the fascia tarso-orbitalis or develops in them new secondary foci.

ecurrent gliomatous orbital tumors also follow the same course; they proceed as a the stump of the optic nerve, causing the latter to bulge very much, finally per- and pass into the surrounding orbital tissue, but often take their rise from the ster of the orbit, even from the bony walls and lymphatic glands, not uncommonly ci in the lids, and as a rule grow very rapidly to a considerable size. They also ly of the small cell variety, sometimes even when the primary tumor was of the variety, and therefore belonged to the category of gliosarcoma (*Hirschberg*).

e orbital glioma penetrates through the roof of the orbit, it may be from fect being formed, or that the bony walls themselves formed the point rture of secondary gliomatous foci; death as a rule soon follows, since the sually increases very rapidly in size inside the skull, forms new secondary d thus presses upon the brain more and more. This is however not the ay in which the glioma presses into the cavity of the cranium; this leads

commonly occur in distant parts of the body, and testify unmistakably to the malignity of the glioma. Such metastases are occasionally found in every part of the body, not excepting the most distant parts of the bony skeleton.

The lymph glands in the region of the parotid gland, and of the angle of the lower jaw (*Knapp*) in particular, which are connected by lymphatic vessels with the globe, are to be regarded as a frequent seat of secondary deposits. The lymphatic glands in the neck, in the mesentery, etc., participate less frequently. Among the viscera, the liver appears to be the most disposed according to past experience. Gliomatous deposits have, however, exceptionally been found in the kidneys, in the ovaries (*Heymann*, *Fiedler*), in the uterus (*Mackenzie*), etc.

The retinal glioma encroaches upon the second eye in about a fifth of the cases (*Hirschberg*). The chiasm then very exceptionally forms the bridge (*Hjort*, *Heiberg*, *Greeve*), or the secondary growth breaks from the brain into the other orbit, and here pushes forward the globe (*Lawrence*). As a rule it is a new deposit, which develops itself by dissemination in the other eye and passes through its usual course. The glioma retinæ is on the whole a not very uncommon affection, for it is observed in 0.05 % of eye patients (*Hirschberg*). It can be called a disease of childhood in the narrowest sense of the word (*Mackenzie*), at least an undoubted case of retinal glioma has not up to the present time been observed in a person beyond the twelfth year of life (*Hirschberg*). The age at which glioma begins embraces the entire period from birth to the twelfth year. It has already been repeatedly found in the new-born (*Sichel*, *Virchow*, *Knapp*, *u. A.*), so that we must assume its development during fœtal life. In several cases it was seen in several children of the same parents (*Lerche*, *Sichel*, *Graefe*). As regards sex, a trifling preponderance has been found in boys (*Hirschberg*). Special causes are unknown. An objectively perceptible kakochymia, or otherwise defective diathesis is certainly not the cause. On the contrary, the great majority of the children attacked, by their blooming appearance and perfectly satisfactory general health, show that their nutrition is normal. External injuries, wounds, etc., can just as little be charged with exerting an influence upon the occurrence of retinal glioma (*Hirschberg*).

10. Sarcoma varies exceedingly in its appearance, and hence is described under the most varied titles, as fibro-plastic, medullary, melanotic sarcoma or carcinoma, fatty tumors, medullary fungus, fibrous polypi, etc. Its structure sometimes approaches the type of one, again of another, group of connective tissue, occasionally assumes a transition form, so that we have to distinguish it as fibrous, mucous, gliose, melanotic, cartilaginous, or bony sarcoma. Still, the preponderance of *cellular* elements remains its peculiar feature. These cells still present the recognized form of connective-tissue cells, but they are, as it were, in a state of hypertrophy. They also persist in this condition without further development into perfect connective tissue. On the other hand, they combine with the intercellular substance to form a relatively firm, coherent structure, containing vessels, and are intimately connected with the neighboring connective tissue, thus presenting a decided difference from epithelial formations, and especially from cancerous or cysticercous tumors. Moreover, the intercellular substance often recedes, while the cells preponderate, and almost hide the former. The sarcoma thus acquires a medullary or (if the cells are rich in pigment) a melanotic appearance. (*Virchow.*)

The cellular elements are sometimes stellate, spindle-shaped, or roundish. The latter often become very large, and then contain numerous nuclei. According to the predominance of this or that kind of cell, the distinctions into reticulate, spindle, round, and giant-celled sarcoma are made. The former most resemble growths of connective tissue, and would be difficult to distinguish from them if we did not frequently find in them transformations into spindle and round-celled sarcoma, and the cells more developed, and so preponderating in number as to render the intercellular substance only recognizable on careful examination. Besides, pigmented stellate cells not unfrequently develop in such masses and to such an extent, that nothing but masses of dark-brown pigment can be seen. Spindle-celled sarcomata (*fibro-plastic tumors*) are very distinctly characterized by the peculiar form of the cells, which are elongated, and at both ends terminate in filamentary or branched processes, and have long oval nuclei. They are often heavily laden with pigment, and usually very friable, so that free nuclei are often scattered in their tissue. Sometimes these cells lie in a large amount of intercellular substance, sometimes so close together that the latter is invisible.

By approximation and parallelism of their axes, they often form prolongations in the shape of a leaf, fasciculus, or band, which sometimes cross, and, on the whole, have a decided influence on the general appearance of the growth. The round-celled sarcomata are almost always confounded with medullary cancer, and, if they contain much pigment, with melanotic cancer. This resemblance is also very great, if closely-branched vessels or remains of the basement-structure simulate the appearance of alveolar formation. Still, the cells in sarcoma have not the epithelial character; they are not flat, but round, oval, or at most disc-shaped, nor are they grouped cell against cell, in cavities in the intercellular substance, but lie imbedded upon all sides in the matrix, although but a minimum quantity exists. Their destructibility is excessive, so that an abundance of free nuclei are seen in the preparation. These nuclei are proportionately large, and have large nucleoli. These round cells are found in all varieties of sarcoma. They are often very small, particularly in *gliosarcoma*. In other cases they appear larger, are multinuclear, and by numerous transformations (often alongside of each other in the same preparation) they attain very great size. If these giant-cells fall out of the stroma, an alveolar appearance may be caused; still, only one, not several large cells or a group of them, lies in each cavity. (*Virchow.*)

The intercellular substance is rarely pure connective tissue capable of producing gelatin. It usually contains albuminous, caseous, or mucous constituents. Where it occurs in greater proportion, it assists in the distinction of the variety of sarcoma. It is occasionally fibrilated, and stamps the tumor as fibro-sarcomatous. In other cases it is granular. This occurs most frequently in gliosarcomata, and some small-celled myxosarcomata. Finally, it frequently appears as a homogeneous, hyaline, gelatinous mass, traversed by broad, dark filaments (in some myxosarcomata); or, it may be very dense and firm, almost cartilaginous. It either may have the latter peculiarity from the first, or may acquire it by a sort of sclerosis of the fibrous or mucous masses. Such a condensation usually precedes calcification or ossification, and forms the ordinary course of development of osteo-sarcoma. (*Virchow.*)

All sarcomata contain vessels. These grow from the basis into the tumor, and branch out, sometimes forming loose, sometimes close, net-works. (*Wedl.*) In some cases the vessels are so numerous as to form the chief part of the mass, and, from their size, give the tumor the appearance of fungous hæmatodes (*sarcoma talangiectodes*). Of course the presence of numerous vessels favors the rapid growth of the tumor, and increases its fluid contents, and, consequently, its infecting power. Hemorrhages occur either outwardly or inwardly. In the latter case, they may cause rapid increase of the tumor, and, by the gradual transformation of the extravasation to pigment-granules, may give it a melanotic color.

Sarcoma usually develops in the form of nodules, which, under some circumstances may become quite large, and by the formation of new foci may readily acquire an irregular appearance. If such tumors grow on surfaces, they readily project, and if on membrane, often have a polypoid or fungoid shape. More rarely, sarcoma appears diffusely on the interior of an organ, like an infiltration or a hypertrophy. If seated in glandular organs, the natural canals and cavities may be dilated mechanically, and the symptoms of a cysto-sarcoma created. (*Virchow.*)

This state must be carefully distinguished from that where a sarcoma has formed in the wall of an already-existing cyst, and grown into it; or where, by partial softening and breaking down of its tissue, a sarcoma has cavities formed in it; or becomes covered with a hard envelope, and is, as it were, incapsulated.

Sarcoma has a peculiar predilection for connective tissue proper. It may, however, originate from any structure belonging to the connective-tissue series. Then the peculiarities of the matrix are usually repeated, to some extent, in the tumor, so that the sarcoma, according to its origin, is fibrous, mucous, glious, cartilaginous, osseous, or melanotic. However, this tendency to the type of the mother-tissue is not absolute. Besides, the combination-power of sarcoma is very great, and not unfrequently a variety of different kinds of growths may be seen in the same tumor, which do not always even belong to the connective-tissue series. Still more frequently do we see the elements of sarcoma, along with those of cancer, growing from the cells of the matrix. (*Virchow.*) The first are then sometimes arranged inside the sarcomatous tumor in the form of sack-like fibres, anastomosing richly with one another, and provided with conoid or club-like outgrowths, and thus present a cancroid structure, which has been often described under the name of *adenoid* growth. (*Hirchberg, Recklinghausen.*) In other cases we find hyaline cords of cartilaginous tissue ramifying and anastomosing, plexus-like, richly with one another, the groundwork of which is evidently formed by vessels, and which recently have been regarded as the characteristic constituent of plexiform tumors. (*Billroth, Czerny.*)

Sarcomata are not, by any means, benign tumors, that only return locally. Indeed, their infecting power is very decided. Their vicinity is almost always affected, the proliferation proceeding first in homologous tissues, and then in the heterologous tissues which are organically connected with the part affected. The cartilages alone, and in a less degree the fibrous membranes, resist for a long period, and form a sort of barrier. Subsequently, infection of unconnected parts occurs. New foci first develop in the vicinity, or, as in metastasis, nodules develop in the lungs, liver, kidneys, brain, &c. Then the peculiarities of the original tumors are propagated to the descendants. Primary, melanotic, medullary, osteoid sarcomata, by infection, usually excite melanotic, medullary, or osteoid products. (*Virchow.*)

The fact that, during this dissemination, the lymphatic glands remain unaffected, distinguishes sarcoma, to some extent, from other malignant growths, and moreover permits the suspicion that the conduction of the germs is accomplished through the blood, rather than the lymphatics.

The malignant character of sarcoma does not, however, show itself from the first. Most of them have a period of innocuousness, during which they are limited to the place of origin, and grow very slowly, often with long intermissions; many remain in situ from youth up, or are even congenital, and do not become malignant until maturity or old age, when they rapidly begin to increase in size. All kinds of sarcomata are not infectious to the same extent. Very hard, fibrous sarcoma appear to be least so. Large-celled, especially the spindle or giant-celled, sarcoma, even when soft, are less fatal than those containing small cells. The worst of all is the melanotic class, which is usually merely a pigmented medullary form. The position of the tumor, and its relations to the vascular and lymphatic systems, are very important. Experience teaches that orbital sarcomata excite new foci, and are more rapidly disseminated than similar intraocular tumors, which often remain inclosed in the eye for a long while. The perceptible implication of heterogeneous tissues, and still more the perforation of a hard, resisting membrane, such as the cornea or sclera, are very bad symptoms, for, under such circumstances, infection, even of distant parts, has almost always already occurred.

Sarcoma does not always proceed regularly to its termination. It often recedes, especially within the eye-ball. Not unfrequently, only part of the tumor recedes, the rest proliferating more luxuriantly; but, even if the entire tumor retrocedes, there is often merely a temporary arrest of the process, for sooner or later it again develops, and then usually advances with great malignancy. Retrogressive metamorphosis is caused by fatty degeneration of the cellular elements, which are gradually transformed into fat-granules or globules, and finally to an emulsive, fatty detritus.

This fatty degeneration is occasionally observed in all species of sarcoma-cells; but those forms that are rich in cells, and particularly those that grow rapidly, are most inclined to it. In the hard forms, especially in fibro-sarcoma, progressive resorption of the disintegrated material causes the tumor to shrink and atrophy into a hard, cicatritial tissue, poor in cells. In the soft varieties of sarcomata, however, the mass becomes more pulpy, and finally thickens to a cheesy substance containing much fat, and often also calcareous salts.

In other cases the fatty degeneration causes softening; cavities form in the tumor, which with progressive resorption do not collapse, but supply the loss of tissue by fluid, and finally resemble cysts. Erosion of vessels is often caused by this softening; then extensive parenchymatous hemorrhage occurs, which usually changes the softening into ulceration.

Sarcomata are generally but little inclined to ulcerate. But there is no form that can not finally break open and form an ulcer. The hard forms, which grow slowly, remain longest as unbroken tumors, and hence occasionally attain a large size. On the contrary, in soft sarcomata, especially when rich in cells, ulceration usually occurs early and progresses rapidly, whence the secretion is usually abundant, often bloody, or even ichorous, and oligæmia, marasmus, or inanition of the patient, may soon be brought about. A true cachexia, as in cancer, is not easily developed in sarcoma. There is simply a disturbance of nutrition.

Sarcoma is much more frequent in adults than in children. Sarcoma occurs primarily in all parts of the eye and its surroundings. It often begins without perceptible cause. In other cases, continuous or frequently repeated irritation or inflammation may be regarded as its cause. Occasionally it proceeds from shrinking of cicatrices, and is then called *keloid*.

a. In the integument of the lids, sarcoma is not unfrequently developed from warts or macula, which were congenital or observed in early childhood. These growths usually have very small cells, and may be regarded as the commencement of sarcoma. They generally remain unchanged till old age; then, with or without external cause, such as injuries, they suddenly become very sensitive, occasionally even very painful, swell up, and change to uneven tumors. There are also cutaneous sarcomata that originate deep in the subcutaneous tissues. They appear as smooth swellings, push the integument before them, without affecting it, sometimes become very large, and may occasionally be very painful (*Mackenzie*, *Wedl*).

Here belongs also a peculiar tumor, which was observed on all four lids of an old man. This was situated in loose connective-tissue, and could be easily separated from its surroundings. It gave to the lids the appearance of great œdema, was firmly elastic, somewhat lobulated, of a yellowish-white color like wax, and proved to be a sarcoma of the small cell variety (*Schirmer*). This case calls to remembrance another one, where, in the upper eyelid of a boy, a similar tumor was found, but of a plexiform character (*Billroth*). In the East analogous tumors in the upper lid are very frequent, and were regarded even by Celsus as *hydatis* or *vesica pinguis*. They occur usually in children, render the elevation of the upper eyelid difficult, and may be easily evacuated with the fingers through a horizontal wound in the skin (*J. E. Polak*). In an old shrunken alcoholic preparation the composition of the tumor of cellular elements and a groundwork of connective-tissue could be inferred.

b. The same condition obtains in the conjunctiva. Here also warty, polypous, and fungous

growths, melanotic tumors, &c., form the basis for sarcoma; indeed, not a few of the growths described under these heads are sarcomatous from the first. Quite as frequently, the growth in question originates, primarily, in tissue before healthy, or, secondarily, by infection from intra-ocular or orbital growths. It first appears as one or several scattered, reddish, or strongly pigmented nodules, which usually lie in the submucous tissue; these soon unite, and occasionally grow to quite large tumors. If seated on the anterior surface of the globe, they readily spread laterally, occasionally attack the cornea (*Iris*), pass backward in the episcleral tissue, and occasionally form shells, which envelop the most of the globe, and push it from its normal position.

c. Sarcomata are frequently found in the orbit. They are usually small-celled glio- or myxo-sarcomata, or are very malignant melano-sarcomata, rarely cysto-sarcomata. (*Singer.*) They usually proceed from fatty tissue (*Virchow*), and soon pass to other parts; hence they are ordinarily attached to the fascia, and sometimes to the periorbita. If the growth be situated far forward, it is apt soon to protrude between the lids, and sometimes to form a large tumor (*Chelius*), before it perforates the conjunctiva and begins to ulcerate. It usually grows backward at the same time, and causes exophthalmos. If the starting-point of the sarcoma be behind the equator of the eye-ball, of course the eye is sooner protruded from the orbit. A frequent result of this is suppuration, or slough of the cornea, and subsequently phthisis oculi. A direct entrance of the growth into the protruded globe occurs very rarely, but seemed most probably to have occurred in one case. (*Virchow.*) On the other hand, orbital sarcomata, particularly melanotic, not unfrequently perforate the bony walls of the orbit, destroying them by caries, pressure, or necrosis, attacking the periosteum and bone-tissue directly. When the pseudoplasm has thus entered a neighboring cavity, its progress within the orbit is usually slower. Thus it sometimes happens that a growth may appear to us moderate in size, and sharply defined in its limits, while it has, in reality, already developed into a large tumor in the adjacent inaccessible cavities. In some cases, no doubt, the disease has taken the opposite course, and has pressed from the antrum (*Pagenstecher*), the nares (*Graefe*), frontal sinus, &c., into the orbit. But the formation of *new foci* in the bones and soft parts of the neighboring cavities is more frequent than the direct passage. In this way the contents of the skull, and, above all, the arachnoid and pia mater, are particularly endangered. (*Virchow.*) These disseminations and actual metastases to which orbital sarcomata (and especially the melanotic forms) are liable, and which often occur early, are not only very unfavorable to operation, but, by interfering with the vital functions, they often cause death before the primary disease is very extensively developed.

d. Sarcomata probably occur in the lachrymal gland, more frequently than they are diagnosticated. (*Stengel.*) Some diseases that are considered as simple hardening or hypertrophy, and some cysts (*Knapp*), may come under this head. In many cases the variety distinguished for its green color, *chloroma*, has been observed in the lachrymal gland. (*Paget, Burns, Balfour, Durand, Furdel.*)

e. Primary sarcomata in the cornea are great rarities. Both melanotic and fleshy growths, originating in the cornea (*Cooper, Nelaton, Steffan*), have been seen however, which had almost or even entirely destroyed it and attained a considerable size, without perforating Descemet's membrane, and without affecting the limbus conjunctivalis and sclera. Secondary corneal sarcomata are much more frequent. They start from conjunctival sarcomata, that have gradually spread over the cornea, or from fleshy or melanotic warts (*Virchow*) seated on its margin, and gradually developed into true sarcomata. The course of a melanotic sarcoma resembles that of a pannus crassus, which develops more and more under the epithelium from the primary focus, and forms jagged protuberances on its surface. The medullary form, on the contrary, first appears as a

have a broad base, and by
enlargement generally soon
anterior chamber, often en-
upon the ciliary processes
d destroy the latter as well
iris in great part, or even
as far as the ora serrata
). In the ciliary body they
nes appear as diffuse infil-
s (*Graefe*). As a rule, how-
hey appear here also in the
f nodules, and gradually in-
ortions of the ciliary pro-
They sometimes push the
one side (*Knapp*), fre-
grow into it, and then
ill the anterior chamber.

ometimes also encroach backward upon the choroid. In the great majority of cases, r, the sarcoma of the ciliary body and iris is a secondary one, coming from the choroid *Graefe, Demarquay, Hirschberg*). Such sarcomata often excite violent inflammations ciliary body and iris, which may sympathetically endanger the second eye (*Mooren*), but lead to detachment of the retina (*Knapp*).

etimes scleral ectasiæ occur, which rupture afterward, and allow an exit to the tumor. case the wound, which was made in the corneal margin for the purpose of excising a f iris involved by a nodule, was the point where the tumor emerged (*Lebrun*). As a e sarcoma really grows through the cornea and sclera. After the perforation has oc- the aftergrowth grows rapidly to a very considerable tumor (Fig. 88), which is attached globe by a constricted neck. In some cases, after such a course, retrocession of the tu- ith atrophy of the eye-ball, has been observed (*Saunders, Lawrence, Maitre-Jean,*). But there is a possibility that the affection was *granuloma.*

Sarcoma is by far most frequently found in the choroid. Here the growth occurs with severe symptoms of irritation; hence it is regarded as an inflam- n, and the disease is described as choroiditis hyperplastica and sarcomatosa.

choroidal sarcoma is often very deeply pigmented; just as often, however it is, merely treaked, spotted, striped, or marbled. On the contrary, unpigmented, so-called leuco- ata are more rare (*Virchow, Graefe, Hirschberg, Knapp, Hutchinson, Hulke*).

variable pigmentation of the mother-tissue perhaps has an influence upon the quantity coloring contents (*Haase, Berthold*). The spindle-shaped cells usually preponderate,

nermost vascular layer; this begins to granulate, numerous formative cells here appear, which gradually assume the character of the sarcoma cells (*Knapp*). They are often mingled with *myeloplaxi*, that is, masses of protoplasma of a very irregular changeable form, which are filled with round and oval nuclei, and are situated in a distinctly finely-fibrillated intercellular substance (*Iwanoff*). In many cases it appears to end in an exudation upon the surface of the choroid. Yellow spots appear, which gradually become confluent and appear to be closely covered by the vessels of the retina. Deeper in, near these vessels, appears a second vascular network, which has grown from the choroidal tumor into the adherent retina, and often causes hemorrhages. Finally the aftergrowth grows through the retina also, and spreads out into the vitreous chamber (*Knapp*). The texture of the retinal infiltration is then often of the very small-cell variety, and bears entirely the character of glioma or gliosarcoma. Thus glioma and sarcoma are then combined in one and the same tumor (*Virchow, Horner, Rindfleisch, Graefe, Hirschberg, Berthold*).

The growth at first appears as a disc-shaped patch, which, lying between choroid and sclera, projects into the back part of the eye (Fig. 89, *a*). As the neoplasm grows, the protrusion increases, forming a roundish swelling, *b*, whose zenith gradually approaches or passes beyond the optic axis, while the base constantly extends, so that finally half or more of the posterior part of the eye appears filled.

Fig. 89.

The sarcoma, however, exceptionally spreads in a diffuse manner, and finally surrounds the posterior chamber of the globe in the form of a more or less thick shell (*Hirschberg*).

The elastic membrane, *c*, of the choroid, is usually preserved, in spite of the increase in size of the tumor, which it completely covers as a tense membrane, continuing uninterruptedly from its base to the surrounding choroid, *d*, which is usually somewhat prominent. In such cases the surface of the tumor is, as a rule, quite smooth.

The part of the retina lying upon this is generally soon lifted up from the tumor by a more or less abundant quantity of fluid in the form of a sac, *e*, and appears lying in folds and floating; the tumor is, as it were, marked by a detachment of the retina. Later, the usually very opaque retina sometimes lies again closely upon the surface of the tumor, becomes adherent to it, and finally is actually penetrated by it (*Mooren, Knapp*).

Cases occur where the tumor has filled the greater part of the posterior portion of the eye, and has pushed one half of the retina into the concavity of the other half, so that the retina appears inverted, and its two surfaces are only separated by a thin layer of cloudy vitreous. We also find the retina constricted to the shape of a long-nozzled funnel, and almost surrounded by the sarcomatous mass. In two cases these growths were pedunculated. The tough vascular peduncle originated in the choroid, and the body of the growth was adherent to the funnel-shaped retina (*Knapp, Klebs, Landesberg*).

extends by rapid growth into the orbit, so that frequently the globe is within a short time pushed forward out of the palpebral opening and becomes immovable.

Perforation may occur at any point; but places where many vessels pass, as the anterior and the equatorial zones (Fig. 90), and the posterior part of the sclera, are favorite localities. The perforation is brought about rather by a transition of the disease to the sclera than from mechanical causes. In the scleral tissue, we see the cellular elements increase (*Virchow*), but the fibrous tissue is finally entirely destroyed. Not unfrequently irregular collections of material form pocket-like spaces in the thickness of the sclera, before the perforation occurs. When this has taken place, the edges of the opening are often protruded like a funnel, by the tumor pressing outward. In such cases the tumor usually ceases to increase materially within the eye, but expands outwardly, the cornea long remaining intact.

Fig. 90.

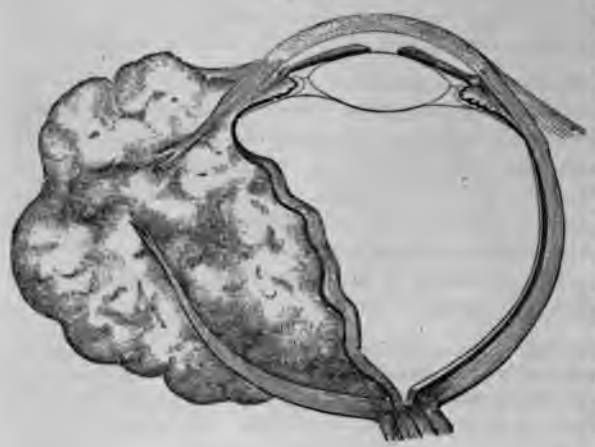

Secondary deposits very often develop themselves in the loose episcleral tissue even before the perforation, and so much the more after it, which are often entirely disconnected with the main deposit (*Knapp*), but in other cases communicate with them by cords of neoplastic cells (*Hirschberg*). Secondary deposits are just as often found in the orbit. These, like the episcleral secondary deposits usually grow tolerably quickly to considerable size, and otherwise behave very similarly to the primary sarcomata of the orbit. Metastatic deposits in more distant parts, particularly in the brain, lungs, liver, etc., are something very usual in advanced stages of the process. Sometimes these manifest themselves very early, or at least deposit germs, which, after the extirpation of the primary tumor, rapidly develop, even when this was done soon after their first appearance, and appear as local returns or distant metastases (*Alf. Graefe*).

10. Granulation tumors, or granulomata, are intimately related to the connective-tissue growths, but do not, at their period of maturity, contain any developed connective-tissue, consisting mainly of perishable elements, with the decay of which the tumor also usually declines. Their chosen seat is in connective tissue.

Their chief constituents are small, round cells with proportionately large nuclei, which greatly resemble lymph or exudation corpuscles, but which do not always develop fully, as the mother-cells often undergo fatty degeneration even during the period of their growth and the division of their nuclei. At the edges of the swelling we often meet with elements of true connective tissue, anastomosing stellate and spindle-shaped cells. Sometimes the intercellular substance is filamentary, and the whole structure corresponds to connective tissue; sometimes it is soft, mucous, or fluid and pus-like (*Virchow*).

:h granulomata have been found in the iris (*Lincke, Graefe*). They appeared there rily as a partial thickening of the iris, which developed itself under inflammatory oma, and grew rapidly to a pale swelling, which then became vascularized, filled a art of the anterior chamber, but also encroached upon the ciliary body, and destroyed r some distance. Such tumors have been seen to remain stationary for a long time. r, however, they usually perforate the cornea, spread out like a sponge upon the free e of the globe, but then always lead to permanent atrophy of the globe, either by al interference, as excision, cauterization, etc., or spontaneously.

ge swellings of the choroid may possibly here be included, which in regard to extension ı very like sarcomata, entirely filled the globe, perforated the cornea anteriorly, and by fatty degeneration and contraction, together with partial calcification and ossifica- the connective-tissue framework, shrunk to a dense, compact, partially crumbling, mass; in one case they perforated the sclerotic also, filled the greater part of the orbit, rmed several considerable secondary deposits in the region of the forehead and mastoid s, but after a very incomplete extirpation of the orbital tumor, underwent suppurative gration, and healed permanently by the formation of a cicatrix. Lupus and gummy s are also to be reckoned in this category. The latter are found very commonly in the nay, however, exceptionally extend to all the envelopes of the eye, and cause destruction globe under the appearances of panophthalmitis (*Hippel*). In several cases they have bserved upon the lids, in the bony walls of the orbit (*Chelius*), often at the base of the (*Graefe*), and once in the chiasm (*Arcoles*).

obably certain growths, originating in the submucous tissue, which are said to have l *exophthalmia fungosa*, should be regarded as granulomata. They are occasionally umerous in the tarsal conjunctiva, and particularly in the semilunar fold. They are y round, from the size of a grain of pepper to that of a bean. They originate in the stroma, and protrude the superjacent conjunctiva before them. By collecting together ometimes attain great size, so as even to hinder the closure of the lids and to change their on. At the same time transverse tumors usually occur in the palpebral fold. They om a broad base, and may be several lines in diameter, so as to protrude the eyelid them, or, by pushing out between the eyeball and lid, cause ectropion. These tumors ually accompanied by trachoma. Then the conjunctiva covering them is usually granular, dinously degenerated. The tumors are quite hard, elastic, and are but little diminished ssure. They often remain unchanged for years. Their tissue consists of a more or less framework of fibrous cords and membranes, whose interspaces are filled by gelatinous ctive tissue.

this class also belong the granulations which occasionally develop on corneal ulcers com- with prolapse of the iris, and which occasionally form long pedunculated tumors of the f a grain of pepper or a pea.

pillomata must also here be considered, which in high degrees of pannus grow out from ıbepithelial formative layer (*Iwanoff*), and, exceptionally completely covering the cornea, each so considerable a size that they push the lids apart (*Businelli*). Spongy growths g no less to this category, which often spring up around foreign bodies lying in the arsal fold or in the conjunctiva of the globe, sometimes actually inclose them, and al them from observation. Cauliflower-like excrescences must also be mentioned, which sprung up from suppurating conjunctival wounds, and are most often observed after otomy, especially when a part of the tendon of the muscle has remained attached to the . The chalazion must also be regarded as a granuloma, so long as it contains in its y much undeveloped connective tissue.

view of the not unfrequent transformation of corneal granulation to epithelial cicatrices, n iris-tumors may here be mentioned, which consist mainly of epidermoid cells, and which, thickening of their outer envelope, have acquired a strong resemblance to sebaceous tumors. contain one or more eye-lashes, which have entered the aqueous chamber through a wound, re to be regarded as a sort of incapsulation. (*Pamard, Graefe, Langenbeck, Stober.*)

1. Carcinoma, or cancer, is recognized by the alveolar formation of its stroma, and epithelial character of its cellular elements. The latter lie without intercellular tance, closely packed in groups, in peculiar interspaces in the mesh-work. They

do not act as parenchyma-cells, but may be separated from the alveolar basis and pressed out from cut surfaces. They often contain much pigment, and then stamp the cancer as melanotic. (*Virchow.*)

Not unfrequently they appear spindle-shaped, with filamentary processes at their poles, and so cause the tumor to resemble spindle-celled sarcoma. Still, especially on cross sections, the flattening and horny consistency of the cell-membranes, as well as their aggregation in the meshes of the stroma, usually appear very distinctly. In other cases they are small and round, giving the cancer a medullary appearance. Giant cells, with six to twelve or more nuclei, also occur; these, however, never grow as large as in sarcoma, are never isolated, but always in groups, and mixed with large cells containing only one nucleus, which is, however, disproportionately large. (*Virchow.*)

Externally, carcinoma sometimes resembles one or other forms of the growths already described, so that only a careful examination of the intimate structure can determine its cancerous nature. Hence there is no doubt that some of the cases above cited are to be referred to cancer, and this is the more likely to be true, as a great variety of tumors are combined with carcinoma from the outset or during their progress, assuming its character more and more, as the elements peculiar to cancer are grouped together in spots in the form of nests or of plexus-like fibres, and by continuous growth gradually attain the preponderance.

In general terms, we may say that no other tumor is so malignant as carcinoma. As a rule, the infection spreads early from the original focus, without offering any marked change of tissue perceptible to the naked eye. Cancer attacks heterologous tissue more readily than other growths do, and even hard, tendinous, or bony partitions offer but weak obstacles, which are soon overcome, so that it bursts through from the eye to the orbit, and hence to the neighboring cavities. Moreover, the infection of distant parts, the formation of new foci, and the occurrence of actual metastasis, usually takes place much earlier in cancer than in other more histoid tumors. In contradistinction from sarcoma, the means of transfer here are the lymphatics; hence swellings of the lymphatic glands usually occur early. Moreover, the occasional occurrence of a cachexia in cancer indicates that there is a large amount of free morphological constituents in the blood. In diagnosis it is also important to remember that in carcinoma the pain is usually very severe from the commencement.

Carcinoma may occur in any part and in any tissue about the eye; still, the internal tissues, on the whole, appear less inclined to the formation of cancer, at least no case of primary intraocular carcinoma has as yet been completely proven to exist, and where cancerous elements have been found they were always mingled with sarcomata, etc. Finally, carcinomata have been found as more or less vascularized, sometimes pigmented, superficially lobulated tumors, with abrupt edges upon the cornea (*Langhans*) on the corneal border, and partly in the scleral tissue (*Berthold*, *Steffan*, *Classen*) in the external skin, in the conjunctiva (*Althof*) and in the orbit (*Graefe*, *Sichel*, *Rothmund*). In a few cases the aftergrowth proceeded from the neighboring parts of the skeleton, the sphenoid bone (*Graefe*), the bones of the face (*Hulke*), and by extensive destruction of the intervening structures grew into the orbit. The cancroid growths observed in the lachrymal gland must probably be included in the class of plexiform tumors.

Cutaneous carcinoma, long known as *epithelial* cancer, deserves particular mention. This rarely occurs in young persons, but rather often late in life, and in the latter case is much more malignant, as, even under favorable circumstances, operations are very unsatisfactory, the cancer almost always returning. Epithelial

carcinoma is always superficial, and never attacks the viscera. It rarely appears primarily on the lids, conjunctiva, or cornea, but advances from the skin of the cheeks, forehead, or nose, to the eye-lids, thence to the orbital tissue. It is almost always the flat, rarely the glandular or alveolar, variety, that is observed in this region.

a. Flat epithelial cancer appears in the skin as small, round, hard nodules, which are variously grouped, and later are spun over with numerous blood-vessels, thus acquiring a marbled or triped appearance. They next become covered with yellow crusts under which we at first find a mere excoriation, but subsequently an ulcerated surface, with hard edges, secreting a thin, purulent fluid. It may close temporarily, soon to break out again, however, and may continue in this condition for months or years without materially increasing in extent or depth. The disease is almost painless, or only occasional attacks of pain occur. It is not till the lapse of considerable time, perhaps several years, that the cancer begins to extend deeper and farther out, and, by the union of newly-forming nodules, destroys not only the skin, but all the subjacent parts of one or both lids. It then progresses to the fatty orbital connective tissue, attacks the eye-ball, and, by continuous inflammation of its component parts, causes its atrophy. Exceptionally, however, it may advance to the cornea itself, and by its destruction cause phthisis of the globe. As the cancer gradually dies on the surface, but at the same time penetrates deeper, the orbit is constantly more opened, and the atrophying bulb more exposed. Sooner or later it attacks the *bony* walls of the orbit, destroys them progressively, thus causing communication between the orbit and the surrounding cavities, and may finally destroy the or other half of the bones of the face. As soon as the cancer has attacked the upper parts, and especially when it has affected the eye-ball, pain occurs, which may be explained by the pressure of the tumor on the nerves. The pain is especially severe at night, and by its severity robs the patient of his sleep. Then the lymphatic glands in the vicinity of the parotid usually become enlarged. Finally, the patient emaciates from the constant pain, hectic fever sets in, and he dies. (*Schuh.*)

b. Glandular or alveolar epithelioma is developed primarily as well in the skin as in the sub-cutaneous connective tissue, the muscles, the palpebral and ocular conjunctiva. Sometimes it appears as a circumscribed swelling, sometimes as an induration. Then, within or under the skin, one or several hard nodules form, which are painful on pressure, and which may swell to the size of a pea or walnut before breaking. This usually occurs after a few weeks. The exposed surface of the growth now looks dark, and occasionally brownish-red, and level. It throws off dirty-white, purulent secretion, which soon becomes fetid, and dries into crusts. Sometimes thin strias of cicatrix form, sometimes actual depressed scars. The edges of the ulcer are quite prominent, more or less everted, presenting roundish elevations and notches. The further course of glandular epithelioma, is similar to that of the flat form. Still, in the glandular variety, the neighboring lymphatics become sympathetically affected quite early. This greatly diminishes the prospect of a successful operation. (*Schuh.*)

12. Angiomata. These are tumors formed by the expansion of normal or the formation and dilatation of pathological vessels. This origin from vessels distinguishes it from the telangiectoid forms of the growths previously described, which incidentally, and often but partially, from excessive vascularity, assume the appearance of fungous hæmatodes, without, however, losing its original character of myxoma, fibroma, carcinoma, &c. Both in their histological relations and in their external

appearances, they present great variety; hence they are to be separated into several classes.

Angioma cavernosum. a. Cavernous tumors. These do not properly belong to the vascular tumors, as they are composed not so much of vessels as of connective tissue or its allies, and form a framework with roundish or membranous striæ, whose interspaces are filled with blood, thus giving the growth some appearance to erectile tissue (*Schwellkörpern.*) The striæ consist of a hyaline, finely fibrillated, or loose filamentary intercellular substance, with numerous elongated nuclei, and sometimes form a delicate, felty, sometimes a coarse, framework. They often grow in hollow-round bosses, occasionally, also, in dentated branched tubes, which also contain blood. (*Rokitansky.*)

Cavernous tumors not unfrequently develop in the deeper layers of the sub-cutaneous tissue of the lids and the immediate vicinity; occasionally, also, they start from the orbital tissue, at variable depths. They usually unite with the tissue, without decided boundary; more rarely they are enveloped by a cellular-tissue envelope, and hence may be enucleated. Occasionally, also, they are pedunculated, and are then attached at one point. When they are superficial, and can grow freely in all directions, they usually appear roundish, somewhat lobulated, show considerable elasticity, and occasionally even indistinct fluctuation. Then their tendency to swell becomes very evident. They increase on crying, coughing, straining, &c., and by any congestion in the upper part of the body, but may be easily compressed, and return at once to their former size, when the mechanical hyperæmia is removed. By their growth and temporary swelling, they press the skin of the lid outward, and appear blue through it. But this is not always the case. Sometimes the tumor appears quite pale, and is then easily mistaken for a lipoma till an incision shows its character. The meshes of the frame-work are not always filled with blood from the first, but sometimes remain for a time unconnected with the veins, and appear as solid tumors. Subsequently the tumors readily become attached to the integument, and break through externally as small, reddish-brown, berry-like growths, after the venous net-work of the skin has been greatly distended. They often press back into the orbit at the same time, cause absorption of the bones, and so pass into the neighboring cavities and spread out there. If developed further back, as in the space between the muscles (*Graefe*), or, outside of these, in the fatty tissue (*Bowman*), their peculiarities are not so perceptible, on account of the pressure to which they are subjected from all sides; they then seem more consistent, less elastic, and their disposition to swell is scarcely observable. They are generally congenital, and often seem quite large in very young children, and grow very rapidly. In other cases their increase is very slow; the tumor is only perceived late in childhood, or in adult age. The fungus may attain very great size; if in the orbit, they may fill it, and cause protrusion of the eyeball. At the same time, similar tumors are often found in other parts of the body. They are painless, and usually exercise no injurious influence on the nutrition of the body generally. Their bad effects are due to mechanical causes. (*Schuh.*)

b. Plexiform Tumors. These, on the whole, occur but seldom, and are then generally mixed with other growths, especially with myxoma and sarcoma. Their characteristic constituents are often nodular tubes of firm consistency, richly anastomosing with one another, ending in culs-de-sac. The histological properties of these structures vary in the several cases, and compel us to make a preliminary distinction into several groups, which, however, agree in this, that they all proceed from the lymphatic vessels, and seem to owe their origin to a growth

of the epithelium of the latter, (*Koester*). In the one group, which has also been described as cylindroma, the firm tubes and culs-de-sac show themselves to have been originally composed of formative cells, and of their various transformations into spindle-shaped and stellate cells, which are embedded in an intercellular substance of fibrillated connective tissue. Later on these elements in part undergo fatty degeneration, but usually they degenerate to a hyaline, structureless mass, at first soft, later more firm and becoming even bony hard, which gives to the plexiform structures the appearance of a cartilaginous structure. In many cases the texture of the tubes and culs-de-sac, however, agrees really with that of true cartilage, and leads to that peculiar cell of considerable size and large nucleus (*Bœttcher*), and hence it has been found necessary to reckon this group as belonging to the enchondromata, and to include it in the system as chondroma telangiektodes. In a third group, to which the so-called adenoid growths may also in part belong, the elements forming the tubes bear throughout the epithelial character, lie close to one another without intervening substance, and thus stamp the growth as cancroid (*Hirschberg*), while by their tendency to gelatinous degeneration, and by the development of numerous alveoli with colloid contents, as well as by their plexiform nature, they betray their intimate connection with the two groups previously mentioned. The tubes of the first and second group are frequently united to the course of the nerves and especially of the small vessels, and seem to proceed from the network of lymphatic vessels surrounding these. They then only represent ramified tubes, in the calibre of which the vessels and nerves are inclosed for a certain distance. Sometimes, however, these tumors also develop themselves independently upon a fibro-cartilaginous basis, and grow out of this in the form of cylinders, knobs or dentrites. They appear in their first position to be congenital, and later to grow independently, and generally painlessly, to exert but little influence upon the nutrition of the individual, and, if they could be completely extirpated and appeared in a pure form, not easily to recur. They generally represent larger or smaller lobulated tumors, softly elastic, sometimes lipoma-like, in which the denser nodulated cords, sometimes also large knobs, may be distinctly felt. They are situated most frequently very superficially. They are found in the subcutaneous connective tissue of the upper lid. From here filaments were sent into the orbit (*Knapp*), or were spread out in the region of the eyebrows and forehead (*Billroth*). In other cases they were situated in the anterior part of the orbit near the roof and pushed the lid forward (*Czerny*, *Graefe*), or had developed themselves behind the lachrymal sac, and had pushed this forward and outward (*Graefe*). Often, however, they proceed from the rear of the orbit and push the globe forward (*Graefe*). In one case such a tumor had perforated the bones of the orbit toward the cavity of the skull (*Bœttcher*), in another downward (*Koester*). The cancroid form has been proved to occur in the anterior part of the orbit (*Hirschberg*), and in all probability many of the adenoid tumors observed in the lachrymal gland are to be referred to it (*O. Becker*).

c. *Telangiectasiæ* occur as circumscribed flat swellings. They probably result not only from a simple dilatation, but also from a new formation of capillaries. The latter appear tortuous, twisted into knots, often with sac-like dilatations, and in some cases (from absorption of the partitions) a number of such dilatations coalesce, and impart to the growth some resemblance to a cavernous tumor (*Rokitansky*). The neighboring small vessels are always in a state of dilatation, the arteries being more affected in one case, in another the veins, according to the direction in which the process within the capillaries may tend (active and passive telangiectasis). The more *arterial* tumors are usually characterized by a somewhat brighter color. They may also pulsate, and closely resemble an aneurism by anastomosis.

All telangiectasiæ are liable to swell. This becomes evident in hyperæmia, and particularly in obstruction of the circulation in the superior vena cava. On the slightest injury they bleed profusely and are inclined to partial ulceration (*Mackenzie*). They are usually congenital, or at least appear very early; later in life they often disappear, but commonly exist for life, and sometimes attain an extraordinary size (*Pauli*). They are most frequently found in and under the skin; more rarely they attack the conjunctiva, or develop there primarily. Sometimes they go deep into the orbit (*Wardrop*). In such a case great dilatation and tortuosity of the retinal veins have been observed (*Schirmer*). It is doubtful whether the tumors described as telangiectasiæ or *nævi venosi*, growing from the sub-conjunctival tissue and caruncle (*Ammon*), or that protruded from the anterior part of the fatty tissue of the orbit (*Barns*, *Abernethy*, *Schön*), or which were deeply seated, and caused exophthalmus (*Kempf*, *Soler*), belong to the

telangiectasiæ, or if they were not rather cavernous tumors, cylindromata or phlebectasia. This doubt is particularly pertinent where they seem to have been caused by a wound.

d. Pulsating tumors. These sometimes lie very superficially and appear as tolerably circumscribed tuberculated convolutions of vessels (*Bell, Wardrop*), which are very similar to the telangiectasiæ, and may be regarded an *aneurysma anastomoticum.* In the great majority of cases, however, they are situated deeper in the orbit and occasion an exophthalmus, which is usually accompanied by very considerable disturbances of vision, and frequently causes destruction of the globe by atrophy. The most prominent symptoms are aneurismal murmurs, and the very marked pulsations. The first may be heard in the globe as well as in its neighborhood, on the temples, the forehead, and even throughout a still greater extent. The pulsations may not only be felt, but frequently also distinctly seen. The patient also hear and feel the murmurs sometimes in a very troublesome, even unbearable manner. Violent pains in the head and eye are not uncommonly co-existent. By passing in the finger between the edge of the orbit and the globe, the tumor may be felt generally as a very soft, easily compressible, elastic mass, as a rule not very distinctly circumscribed. The pressure of the globe backward is not as a rule very painful, and usually meets with no particular resistance. Impediments to circulation in the region of the superior vena cava usually increase the exophthalmus and the somewhat visible tumor, whereas compression or even ligation of the carotid artery of that side diminishes the tumor, stops the pulsation and buzzing, or at least essentially diminishes them (*Travers, Dalrymple, Walton, Brainard, Freeman, Morton, Bell, Lawrence, Collard, Williams, Demarquay, Mackenzie, Poland, Zander, Geissler, Zehender, Schiess-Gemuseus*).

In not a few cases the tumor also projects forward out of the orbit, and pushes the lids as well as the conjunctiva forward. It is then sometimes connected with very dilated vessels, which can be followed upon the lids, forehead and region of the nose, etc. (*Wecker, Bourget, Bell, Schiess-Gemuseus*), and then sometimes make the pulsation and buzzing evident. In some cases a very extensive dilatation of the veins and arteries of the globe has been also observed (*Wecker, Schiess-Gemuseus*). In one case the tumor seemed to have penetrated into the frontal sinus (*Jobert*), and in another, very similar pulsating tumors were found in the brain, lungs, and calves of the legs (*Lenoir*). The tumor exceptionally showed itself bilaterally (*Velpeau, Herpin, Desormeaux*).

In the larger half of the cases belonging in this category, an injury was the exciting cause. The exophthalmus sometimes appeared directly afterward, generally, however, not until later, often after weeks, months, and even years. The development of the tumor was then frequently accompanied by great pain in the head, with the feelings of cracking, knocking, and roaring in the ear. In some cases it appeared during pregnancy, during delivery (*Nunneley*), in consequence of violent fits of coughing, etc.

According to anatomical investigations, such pulsating orbital tumors are often found in combination with impediments to the circulation in the sinus cavernosus, and it has been suggested that the stasis in both ophthalmic veins should be recognized as the pathological source of the exophthalmus (*Nunneley*). These hindrances to circulation have been shown to be caused: by enormous extravasations, which were situated in the sinus cavernosus around the carotid artery (*Gendrin*); by inflammatory products (*Hulke*), and by growing tumors (*Nunneley, Lenoir*), which stopped up the sinus cavernosus; by a true carotid aneurism which was situated exactly upon the point of origin of the arteria ophthalmica, and compressed the corresponding vein (*Nunneley*); finally, by a *varix aneurysmaticus* of the carotid artery which had been lacerated by a splinter of bone at its point of exit from the carotid canal, and mingled its contents with those of the sinus cavernosus (*Nélaton*). The recession of pulsating orbital tumors by obstructions in the sinus cavernosus is, however, on the one hand conceivable through the wide communication of the ophthalmic vein with the vena facialis anterior

on the other hand are cases in which the very same appearances existed during life, and after death either nothing at all abnormal was found (*Bowman*), or at least every hindrance to circulation in the sinus cavernosus could be excluded; but on the other hand a very considerable dilatation of the orbital veins and an inflammatory thickening of their walls were demonstrated (*Wecker*). From these results it can scarcely be doubted, that not so much the venous stasis in itself, as rather the inflammatory dilatation of the orbital network of vessels, has been the cause of the exophthalmus also in those cases in which the sinus cavernosus had been found obstructed on the cadaver, and that the phenomenon of pulsation must be explained by the propagation of the systolic cardiac pressure upon the dilated vessels. True aneurisms have been but seldom anatomically demonstrated.

These affected usually the trunk of the arteria ophthalmica (*Guthrie*, *Carron du Villards*, *Paswavant*). In one case the tumor was situated in the cavity of the skull at that portion of the carotid artery from which the arteria ophthalmica is given off (*Giraudet*). In other cases aneurisms existed in the terminal branches of the arteria ophthalmica (*Parish*, *Hart*, *Skokalski*). The pulsating dilatation of a main branch of the arteria centralis retinæ has been ophthalmoscopically observed (*Sous*), and, according to old accounts, has even been met with in the cadaver (*Himly*, *Graefe*, *Sen.*, *Scultet*).

e. Simple Phlebectasiæ.—To this category belongs a tumor found in the most anterior part of the orbital connective-tissue, of the size of a pea, accompanied by great dilatation of the veins of the lid, only projecting temporarily above the external commissure of the lids, and containing a phlebolith (*Graefe*). Moreover, it has been said that such phlebectasiæ have been found in the conjunctiva in the form of large varices (*K. Jaeger*, *Roosbræck*). Once a venous tumor had been formed in the lower lid after an injury, which completely disappeared when the body was in the erect position, but swelled to the size of an almond when the head was bent forward (*Foucher*). Certain cases of exophthalmus, with very similar contents, may also possibly belong in this category. The eyes projected forward considerably when the upper part of the body was much bent forward, but sunk back into their normal position under opposite conditions (*Andrae*, *Mackenzie*), or were elevated or depressed with the change of the respiratory pressure (*Ad. Schmidt*).

D. Hydatids. The *echinococcus hominis*, and the *cysticercus cellulosæ*, are the only ones which have hitherto been observed about the eye. The first presents a large, spreading tumor, of cystoid character, containing a variable number of limpid vesicles in a serous or gummy fluid. On opening the sac of the tumor, these vesicles escape. A cysticercus does not usually become larger than a cherry-stone, and appears as a cloudy, delicate vesicle, which is located on the very contractile neck and head of the animal.

1. The echinococcus has been found in the frontal bones (*Keate*), in the subcutaneous tissue of the temporal and malar region (*Mackenzie*), and in the orbit (*Lawrence*, *Bowman*, *Waldhauer*). In the orbit it seems to prefer the upper inner angle, but usually expands considerably, and so causes great exophthalmus, with its results. It is always inclosed by a capsule of dense connective tissue, which is formed of the compressed stroma, and is only loosely attached to the animal vesicle, so that the latter can be separated from the former.

In Northern Germany the cysticercus is met with quite commonly, but in the South, as also in Austria, France, and Switzerland, it is very rare. The youngest child that was attacked was in the eighth year, the oldest person was in the seventieth year. Hydatids are but rarely found with them in other parts of the body, or the tape-worm in the intestines. In two cases brain symptoms pointed to the simultaneous presence of a cysticercus in the brain.

Cystercus has been observed in the anterior part of the orbital tissue (*Graefe*), between the lamellæ of the cornea (*Appia*), in the submucous tissue on the margin of the cornea (*Estlin*), and repeatedly under the conjunctiva, near the palpebral fold. (*Bowman*, *Höring*, *Sichel*, *Graefe*.)

When the hydatid is superficial, especially when under the conjunctiva, it is not difficult to diagnosticate it from a simple cyst; for the contents of the latter are very clear and shine through, as the conjunctiva over them is usually very thin and non-vascular. The hydatid, however, is generally more opaque, and not unfrequently its head and neck can be distinguished as a dense white mass. The deposition of the hydatid generally causes great irritation, as a result of which, hyperæmia and subsequently inflammatory products occur, which cause thickening of the neighboring tissue (*Graefe*).

Cysticercus occurs far more frequently within the eye. Centuries ago it was discovered in the anterior chamber (*Schott, Logan*), and since then numerous cases of it have been observed. (*Mackenzie, Canton, Graefe, Hirschler, Mende.*) Its favorite seat, however, is the posterior part of the eye-ball. Although it was not discovered here till the ophthalmoscope came into use (*Coccius, Graefe*), there is already a long list of ophthalmoscopic observations upon this subject. Opportunity for the anatomical examination of eyes in which the cysticercus was developed in or under the retina has often occurred (*Schweigger, Soelberg, Jacobson, Alf. Graefe*); or where a subretinal cyst (*A. Weber*) or a hydatid adherent to the choroid (*E. Jaeger*) could be considered as probably a cysticercus.

There is good reason to suppose that all cysticerci, that take up their abode in the eye, begin to develop in the *vascular* parts, but soon readily bore through and get into the transparent media.

Those found in the anterior chamber seem to proceed from the iris. Part, at least, of the vesicle usually remains attached to the iris, although some portions are found free in the aqueous.

Cysticerci occurring in the posterior part of the eye, with rare exceptions, originate in the retina. In a number of the cases observed, the animal still lay under the retina and was immediately connected with its tissue, while the corresponding portion of the choroid was proportionately little changed. Often, also, the animal became attached to this point, and incapsulated, without, however, perforating the retina. In some cases the perforation or its results could be seen. The head of the animal was seen to protrude from an opening in the cloudy retina, and subsequently the scar which closed the opening was to be seen. (*Graefe, Schweigger.*) But where the cysticercus had already entered the vitreous, it was usually attached by a cord or tube-like process to some part of the retina (*Graefe*).

The first appearance of cysticercus is almost always accompanied by severe irritation, which usually causes a large deposit of inflammatory product about the animal. Hence the latter is usually hidden, and is not immediately perceived. But the inflammation usually subsides soon, and the opacities clear up. If the violent attacks accompanying the entrance, and somewhat later perforation have subsided, the eye becomes gradually quiet and bears the presence of the worm for weeks and months without any particular trouble. Finally, however, the globe is destroyed as a rule by iridochoroiditis. This may lead to suppuration and acute panophthalmitis (*Schweigger, Jacobson*); usually, however, it moves more insidiously, and finally causes, sometimes with exacerbations, shrinking of the globe with total detachment of the retina. Only very exceptionally does a worm, situated in the vitreous humor, become encapsuled and later on dies, in which case the globe and even some vision may be preserved.

The signs of iridochoroiditis usually manifest themselves between the third and the fifteenth month after the commencement of the visual disturbance. In some cases the reactive inflammation has endangered the other eye by sympathetic irritation (*Schweigger*).

Dead cysticerci, moreover, seem to be well born in shrunken eyes. The duration of life of the worm is unknown. It certainly amounts to two, perhaps to three or four years. Suppurative inflammations of the globe, and still more calcification and shrinking of the exudations surrounding it appear to be injurious to it (*Graefe*).

E. Filaria.—It is said that these have been seen twice living in the vitreous humor (*Fano, Quadri*), and once dead (*Mauthner*).

Authorities.—*Virchow*, Die krankhaften Geschwülste, Berlin, 1863, 1-10 Vorlesg.

Cysts: Virchow, l. c. S. 211, 219, 221, 224, 231, 238, 344, 249, 286.—*Mackenzie*, Traité d. mal. d. yeux. Traduit p. Warlomont et Testelin, I. Paris, 1856, P. 70, 72, 74, 76, 81-107, 213, 214, 219, 363, 369, 371, 372, 432, 462, II. P. 261.—*Chelius*, Handb. der Aughelke. II. Stuttgart, 1839, S. 424, 434, 443, 446, 447, 472, 482.—*Himly*, Kraknheiten u. Missbildungen, &c., Berlin, 1843, S. 194, 232, 233, 237, 263, 266, 267, 294, 327, 370.—[*Hackley*, Amer. Jour. Med. Sciences, Oct., 1865.]—*Ammon*, kl. Darstellgn. II. Berlin, 1838, Taf. 9, 10, 11.—*Stellwag*, Ophth. II. S. 862, 877, 880, 906, 997, 1086, 1221, 1280.—*Zandler* und *Geissler*, Verletzungen des Auges. Leipzig und Heidelberg, 1864, S. 416, 418, 420, 422.—*Ressel*, Allg. Wiener med. Zeitung, 1860, Nr. 8-10.—*Caratheodori*, *Fano*, Schmidt's Jahrb. 112. Bd. S. 260, 261.—*Benedikt*, *Weller*, nach Himly l. c. I. S. 263.—*Blasius*, *Sandifort*, *Schmucker*, *Riberi*, *Quadri*, ibid. S. 266, 267 — *Testelin*, Mackenzie l. c. I. P. 471.—*Delpech*, ibid. P. 468.—*Seitz*, Handb. der gesammten Augenheilkunde. Erlangen, 1855, S. 89, 90, 96, 100.—*Graefe*, A. f. O. I. 1. S. 290.—*Hasner*, Beiträge zur Phys. u. Path. des Thränenableitungsapp. Praeg, 1850, S. 44.—*Schuh*, Wien. med. Wochenschft. 1861, Nr. 1-5.—*Schmidt*, Krankh. des Thränenorganes. Wien. 1803, S. 73, 90, 94.—*Beer*, Lehre v. d. Augenkrankheiten. 11. Wien. 1817, S. 597.—*Secondi*, Clinica oc. di Genova. Torino. 1865, P. 114.—*Graefe*, A. f. O. III. 2 S. 412; VII. 2 S. 39; XII. 2 S. 228.—*Hirschberg*, ibid. XIV. 3 S. 295.—*Hulke*, Ophth. Hosp. Rep. VI. S. 13.—*Wecker*, Etudes Ophth. I. 1863, S. 397; Arch. f. Augen u. Ohrenheilkde. I. S. 122.—*Mooren*, Ophth. Beiträge. S. 129.—*Bourdillat*. Gaz. hebd. 1868. Nr. 13.—*Stavenhagen*, kl. Beob. S. 22.—*Sichel*, Centralbl. 1867 S. 557.—*Waldhauer*, ibid. 1866, S. 667.

Fibroma: Virchow, l. c. 13. Vorlesg.—*Mackenzie*, l. c. I. P. 207, 357, 358, 478.—*Travers*, ibid. P. 366.—*Carron du Villards*, ibid. P. 220, Ann. d'oc. 32. Bd. P. 253 nach Himly l. c. S. 264.—*Graefe*, kl. Montbl. 1863, S. 21, 23, A. f. O. I. 1. S. 289.—*Himly*, l. c. I. S. 217, 257, 260, 264, II. S. 15, 19.—*Stellwag*, Ophth. I. S. 227, 354. Nota 224, II. S. 875, 877, 906. Nota 83, S. 1224, 1226, 1229.—*Mooren*, Ophth. Beiträge. S. 40.—*Borelli*, Schmidt's Jahrb. 142 Bd. S. 83.—*Schiess-Gemuseus*, A. f. O. XIV. 1 S. 87.—*Lawson*, Ophth. Hosp. Rep. VI. 3. S. 206.—*Seitz*, l. c. S. 86, 99.—*Magne*, Ann. d'oc. 19. Bd. S. 218.—*Beer*, l. c. II. S. 678, 679.—*Arlt*, Krankheiten des Auges I. Prag. 1853. S. 166.—*Hasner*, Entwurf einer anat. Begründung, &c. Prag. 1847. S. 79.—*Chelius*, l. c. II. S. 426, 439, 477.—*Ammon*, l. c. II. Taf. 9.—*Pagenstecher* und *Sämisch*, kl. Beobachtgn. II. Wiesbaden, 1861, S. 41.—*Jüngken*, Lehre v. d. Augkhtn. Berlin, 1836, 628.—*Schuh*, l. c.—*Weinlechner*, Zeitschft. d. Wien. Aerzte. 1865, Wochenbl. S. 263.—*Bader*, Schmidt's Jahrb. 112. Bd. S. 261.—*Zehender*, A. f. O. IV. 2. S. 55, 62.—*Heymann*, ibid. VII. 1. S. 135, 142.

Dermoid: Virchow, dessen Archiv. VI. S. 225.—*Ryba*, Dusensy's Diss. Prag. 1833, S. 63. —*Fischer*, Lehrb. der ges. Entzündungen, &c. Prag. 1846, S. 303.—*Wardrop*, Morb. anat. of the eye. I. London, 1819, S. 31.—*Mackenzie*, l. c. I. P. 362.—*Chelius*, l. c. II. S. 483.—*Himly*, l. c. II. S. 15, 19; Ophth. Biblioth. II. S. 700.—*Ammon*, l. c. II. Taf. 3.—*Arlt*, l. c. I. S. 171. —*Stellwag*, Ophth. I. S. 227, 355, Nota 228, II. S. 877, 963.—*Schön*, Path. Anat. des Auges. Hambg. 1828, S. 167; Beiträge z. prakt. Augenheilkunde. Hamb. 1861, S. 198.—*Graefe*, A. f. O. I. 2. S. 287, II. 2. S. 334, VII. 2. S. 3. 7, X. 1. S. 214.—*E. Müller*, ibid. II. 2. S. 158.—*Heyfelder*, Deutsche Klinik, 1850, Nr. 28.—*Hock*, Wien. Zeitschft. f. prakt. Heilk. 1865, Nr. 26.—*Graefe*, A. f. O. XII. 2. S. 226.—*Visconti Achilli*, Centralbl. 1867, S. 111.—*Hildige*, Schmidt's Jahrb. 142 Bd. S. 82.—*Wecker*, Arch. f. Aug-u. Ohrenheilkde. I. S. 126.—*Lainati*, Arch. gen. de med. 1867, II. S. 350.

Lipoma: Virchow, l. c. 14. Vorlesg.—*Demarquay*, ibid. S. 374.—*Schuh*, l. c.—*O. Becker*, Wiener Augenklinik. Ber. S. 119.—*Mooren*, Ophth. Beiträge S. 128.

Myxoma: Virchow, l. c. 15. Vorles. S. 425.—*Mackenzie*, l. c. I. P. 360.—*Graefe*, A. f. O. X. I. S. 193, 197, 201.—*Jacobson*, A. f. O. X. 2. S. 55, 62.—*Rothmund*, Jahresbericht 1861-2. München. S. 21; klin. Monatbl. 1863, S. 261.—*Szokalski*, Congress. int. d'ophth. Paris, 1863, P. 245.—*Stellwag*, Ophth. I. S. 342. Nota 178.—*Lebrun*, Schmidt's Jahrb. 141 Bd. S. 211.

Chondroma: Virchow, l. c. 16. Vorlesg.—*Mackenzie*, l. c. I. P. 67.—*Graefe*, A. f. O. I. 1. S. 415, VII. 2. S. 5.—*Schweigger*, ibid. VII. 2. S. 6.—*Busch*, nach Virchow l. c. I. S. 515.—*Schuh*, l. c.—*Chelius*, l. c. S. 455.—*Travers*, nach Mackenzie l. c. I. P. 61.

Osteoma: *Virchow*, l. c. 17. Vorlesg. II. S. 22, 25, 27, 28, 37, 43–52, 99.—*Mackenzie*, l. c. I. P. 54, 56, 61, 73, 98, 481.—*Chelius*, l. c. II. S. 453.—*Knapp*, A. f. O. VIII. 1. S. 239, kl. Mntbl. 1865, S. 376.—*Zander* und *Geissler*, l. c. S. 414.—*Stellwag*, Ophth. II. S. 1285.—*Acrel*, nach Mackenzie l. c. I. P. 65.—*Baillie*, Ibid. p. 59.—*H. Walton*, ibid. P. 63.—*Brassnat*, *Spöring*, ibid. P. 64.—*Stanley*, ibid. P. 73.—*Maissonneuve*, ibid. P. 65.—*Howship*, ibid. S. 90.—*Frank*, ibid. P. 59.—*Bowman*, Verhandlgn. der Heidelbg. Versammlung. Berlin, 1860, S. 18.—*Textor*, Constatt's Jahresber. 1865, III. S. 34.—*Hasner*, Statopathien, 1869, S. 17.

Melanoma: *Virchow*, l. c. 18. Vorlesg. S. 119, 122.—*Mackenzie*, l. c. I. P. 366, 486.—*Cunier*, ibid. P. 367.—*Lesmaires*, Traité d. mal. d. yeux. Paris, 1847, P. 353.—*Stellwag*, Ophth. II. S. 879.—*Lisfranc*, nach Himly l. c. I. S. 233.—*Ed. Jaeger*, Staar und Staaroperat. Wien. 1854, S. 63.—*Hedäus*, A. f. O. VIII. 1. S. 314.—*Graefe*, ibid. I. 1. S. 414, VII. 2. S. 35. *Schön*, Beiträge, &c. 200.—*Hirschberg*, A. f. O. XIV. 3. S. 293, 296.—*Haase*, ibid. XIV. 1. S. 63.—*Langhaus*, Virchow's Arch. 49. Bd. S. 117.

Myoma: *Iwanoff*, Congrès ophth. 1868, S. 118.

Glioma: *Virchow*, l. c. 18, Vorlesg. II. S. 123, 151–169.—*Mackenzie*, l. c. II. P. 267, et seq.—*Chelius*, l. c. S. 491, 496, 506.—*Schweigger*, A. f. O. VI. 2. S. 324, 327; VII. 2. S. 47.—*Robin*, ibid. VI. 2. S. 330.—*Graefe*, ibid. VII. 2. S. 42, 45, 46, X. 1. S. 216, 219.—*Iwanoff*, ibid. XI. 1. S. 135, et seq.—*Metaxa*, nach Mackenzie, l. c. P. 273.—*Horner*, *Rindfleisch*, kl. Monatbl. 1863. S. 341, et seq.—*Szokalski*, ibid. 1865. S. 396. 398.—*Stellwag*, ophth. II. S. 443, Nota 142, S. 611. 613.—*Lincke*, *Sichel*, nach Virchow, l. c. S. 152, 167.—*Travers*, nach Mackenzie, l. c. II. P. 268, 269, 271.—*Saunders*, *Stevenson*, ibid. P. 284.—*Lerche*, Verm. Abhandlg. a. d. Gebiete der Heilkd. Petersbg. 1830. S. 202.—*Knapp*, Die intraocularen Geschwülste. Carlsruhe, 1868; Congrès ophth. S. 25; kl. Monatbl. 1868. S. 316, 428; 1869. S. 106.—*Hirschberg*, Der Markschwamm d. Netzhaut. Berlin, 1869; A. f. O. XIV. 2. S. 30.—*Graefe*, ibid. XIV. 2. S. 103, 128 u. f.—*Iwanoff*, ibid. XV. 2. S. 69, 73, 77, 88.—*Neumann*, ibid. XVI. 2. S. 278.—*Schiess-Gemuseus*, ibid. XIV. 1. S. 73; Virchow's Arch. 46. Bd. S. 286.—*Joffroy*, Gaz. méd. de Paris. 1869. S. 35.—*Manfredi*, Centralbl. 1869. S. 602.—*Lebrun*, Schmidt's Jahrb. 141. Bd. S. 211.—*Betz*, kl. Monatbl. 1868. S. 274.—*Alf. Graefe*, ibid. 1869. S. 161.—*Hjont Heiberg*, A. f. O. XV. 1. S. 184.—*Heymann*, *Fiedler*, ibid. XV. 2. S. 173.—*Kulke*, Ophth. Hosp. Rep. V. S. 173.—*Pockels*, nach Hirschberg, S. 94.—*Weller*, *Ammon*, ibid. S. 123.—*Hasse*, ibid. S. 58, 116.—*Brodowski*, ibid. S. 40.—*Recklinghausen*, ibid. S. 121, 122.—*Lawrence*, ibid. S. 67.—*Bader*, ibid. S. 111.—*Greeve*, VII. Jaarl. Verslag. Utrecht. S. 1. u. f.

Sarcoma: *Virchow*, l. c. 19, Vorlesg. II. S. 222, et seq.—*Wedl*, Sitzungsberichte d. Wien. k. Akad. 1. Abthlg. 53. Bd. S. 343, Grundzüge der path. Histolog. Wien. 1854. S. 469.—*Mackenzie*, l. c. I. P. 67, et seq. II. P. 259, et seq.—*Paget*, *Burns*, *Balfour*, *Durand-Fardel*, ibid. I. P. 122.—*Saunders*, *Lawrence*, *Maitre-Jean*, ibid. II. P. 265.—*Chelius*, l. c. II. S. 439, et seq.—*Schuh*, l. c.—*Stellwag*, Ophth. I. 182, 186, 344 Nota 183, S. 346 Nota 184, II. S. 306, et seq.—*Steffan*, *Cooper*, *Nelaton*, kl. Mntbl. 1864. S. 81, 83.—*Dixon*, ibid. 1863. S. 405.—*Stengel*, Aerzt. Intelligenzblatt. 1866. Juli.—*Ressel*, l.c.—*Singer*, Wien. allg. med. Zeitung. 1860. Nr. 46.—*His*, Beiträge zur norm. u. path. Histologie der Cornea. Basel, 1846. S. 134.—*Pagenstecher* und *Sämisch*, l. c. I. S. 78, II. S. 91, 93.—*Graefe*, A. f. O. I. 1. S. 413, 417, II. 1. S. 214. 221. IV. 2. S. 220, VII. 2. S. 36, 40. X. 1. S. 177, et seq.—*Dor*, ibid. VI. 3. S. 244. 248.—*Schiess-Gemuseus*, ibid. X. 2. S. 109, et seq.—*Landsberg*, ibid. XI. 1. S. 58, 66.—*Klebs*, ibid. XI. 2. S. 253.—*Jacobi*, ibid. XI. 3. S. 165, kl. Monatbl. 1863. S. 121.—*Knapp*, ibid. 1865. S. 378, 383.—*Küchler*, Deutsche Klinik. 1866. Nro. 17, et seq.—*Sichel*, Gaz. med. de Paris. 1867. Nr. 27.—*Hirschberg*, A. f. O. XIV. 2. S. 71; 3. S. 285; kl. Monatbl. 1868. S. 153, 175; 1869. S. 65–83.—*Schirmer*, ibid. 1867. S. 124.—*Alf. Graefe*, ibid. 1869. S. 161, 169.—*Iwanoff*, A. f. O. XV. 2. S. 28.—*Haase*, ibid. XIV. 1. S. 63.—*Leber*, ibid. XIV. 2. S. 221.—*Berthold*, ibid. XIV. 3. S. 149; XV. 1. S. 159, 176; kl. Monatbl. 1870. S. 19, 23.—*Recklinghausen*, A. f. O. X. 1. S. 189; X. 2. S. 62.—*Billroth*, Arch. f. Chirurgie. XI. S. 230.—*Czerny*, ibid. S. 234.—*Demarquay*, Schmidt's Jahrb. 141. Bd. S. 210.—*Lebrun*, ibid.—*Hulke*, Ophth. Hosp. Rep. IV. S. 82.—*Hutchinson*, ibid. V. S. 90.—*Cowell*, *Warren*, ibid. S. 188, 230.—*J. E. Polak*, brieff. Mittheilg.—*Graefe*, A. f. O. XII. 2. S. 233, 237, 239; XIV. 2. S. 106.—*Schiess-Gemuseus*, ibid. XIV. 1. S. 87.—*Landsberg*, ibid. XV. 1. S. 210.—*Knapp*, kl. Monatbl. 1868. S. 318; 1869. S. 108; Die intraocularen Geschwülste. Karlsruhe, 1868; Centralbl. 1866. S. 726.—*Rothmund*, Deutsche Klinik. 1865. S. 86.—*Mooren*, Ophth. Beob. S. 35; Ueber Symp. Ophth. S. 41.—*Eimert*, zwe Falle von Sarcom der Orbita. Bern, 1870.

Granuloma: Virchow, l. c. 30. Vorlesg. II. S. 390, 462.—*Chelius*, l. c. II. S. 452.—*Desmarres*, l. c. S. 352.—*Pamard*, Ann. d'oc. V. P. 157.—*Graefe*, A. f. O. III. 2. S. 412; VII. 2. S. 24, 33, 39, X. 1. S. 211.—*Stoeber*, kl. Monatbl. 1864. S. 362, 364.—*Stellwag*, Ophth. II. S. 877. —*Graefe*, A. f. O. XII. 2. S. 231.—*Lincke*, *Hirschberg*, ibid. XIV. 3. S. 296.—*Iwanoff*, Pagenstecher's kl. Beob. III. S. 135.—*Businelli*, Schmidt's Jahrb. 141. Bd. S. 324.—*Colsman*, kl. Monatbl. 1869. S. 53.—*Arcoleo*, Congrès Ophth. 1868. S. 183, 186.—*Hippel*, A. f. O. XIII. 1. S. 65.

Carcinoma: Virchow, l. c. II. S. 196, et seq.—*Schuh*, l. c.—*Graefe*, A. f. O. I. 1. S. 417, X. 1. S. 184, 206.—*Althof*, ibid. VIII. 1. S. 137.—*Knapp*, kl. Monatbl. 1865. S. 378.—*Steffan*, ibid. 1864. S. 83, 85.—*Hock*, l. c.—*Pagenstecher* und *Sämisch*, l. c. II. S. 40.—*Graefe*, A. f. O. XII. 2. S. 244; XIV. 2. S. 106, 114.—*Berthold*, ibid. XIV. 3. S. 149.—*Iwanoff*, Pagenstecher's kl. Beob. III. S. 135.—*Hulke*, Schmidt's Jahrb. 135. Bd. S. 203.—*Mooren*, ophth. Beob. S. 50. —*Classen*, Centralblatt, 1868. S. 39; Virchow's Arch. 50. Bd. S. 56.—*Sichel*, Gaz. méd. de Paris. 1867. Nr. 27.—*Rothmund*, Deutsche Klinik. 1865. S. 86.

Angioma: Rokitansky, Lehrb. der path. Anat. I. Wien, 1855. S. 202–209; II. S. 315. et seq. —*Schuh*, l. c.—*Demarquay*, Schmidt's Jahrb. 112. Bd. S. 259–264.—*Geissler*, ibid. 102. Bd. S. 52–54. 114. Bd. S. 346.—*Zander* und *Geissler*, l. c. S. 423–436.—*Mackenzie*, l. c. I. P. 223–242, 455. 487–504.—*Himly*, l. c. I. S. 220–224. 376–380; II. S. 417.—*Chelius*, l. c. II. S. 428, 456.—*Stellwag*, Ophth. II. S. 964, et seq.—*Graefe*, A. f. O. I. 1. S. 420; VII. 2. S. 11. 19; X. 1. S. 184.—*Schirmer*, ibid. VII. 1. S. 119.—*Szokalski*, kl. Monatbl. 1864. S. 326, 427.—*Ammon*, l. c. II. Taf. 9. Fig. 10.—*Schön*, Beiträge etc. S. 204; Handb. S. 159.—*Abernethy*, nach Mackenzie I. P. 227.—*Wardrop*, ibid. P. 239, 240.—*Pauli*, ibid. P. 226.—*Burns*, ibid. P. 238.—*K. Jaeger*, *Roosbroeck*, ibid. P. 358.—*Foucher*, Schmidt's Jahrb. 102. Bd. S. 52.—*Soler*, nach Zander und Geissler l. c. S. 435.—*Kempf*, Canstatt's Jahresber. 1864. III. S. 164.—*Nunneley*, kl. Monatbl. 1865. S. 244, Schmidt's Jahrb. 112. Bd. S. 263.—*Andrae*, nach Fischer's Lehrb. S. 361.—*Ad. Schmidt*, Ophth. Bibliothek. III. S. 174.—*Bowman*, Schmidt's Jahrb. 112. Bd. S. 262.—*Gendrin*, *Hulke*, *Nelaton*, ibid. S. 259.—*Bell*, nach Mackenzie l. c. I. P. 237.—*Bourguet*, ibid. P. 490.—*Travers*, ibid. P. 495.—*Dalrymple*, ibid.—497.—*Jobert*, ibid. P. 499.—*Velpeau*, *Walton*, ibid. P. 500.—*Brainard*, ibid. P. 501.—*Guthrie*, ibid. P. 488.—*Carron du Villards*, nach Himly I. S. 376.—*Parish*, Americ. Journ. of Med. Science. 1841.—*Sous*, Ann. d'oc. 53. Bd. P. 241.—*Poland*, nach Zander und Geissler, l. c. S. 427.—*Hart*, ibid. S. 431.—*Küchler*, deutsche Klinik. 1866. Nr. 28.—*Graefe*, A. f. O. X. 2. S. 55; XII. 2. S. 222, 223.—*Recklinghausen*, ibid. X. 1. S. 189; X. 2. S. 62.—*Knapp*, Arch. f. Aug. u. Ohrenheilk. I. S. 1, 14; A. f. O. XIV. 1. S. 213.—*Czerny*, *Billroth*, Arch. f. klin. Chirurgie. XI. S. 230, 234.—*Burns*, Virchow's Archiv. 50. Bd. S. 80.—*M'Clelland*, Schmidt's Jahrb. 142. Bd. S. 320.—*De Ricci*, Centralbl. 1866. S. 45.—*Borelli*, Congrès Ophth. 1868. S. 149.—*Mooren*, Ophth. Beob. S. 119, 125.—*Freeman*, Centralbl. 1866. S. 798.—*Boettcher*, Virchow's Archiv. 28. Bd. S. 400.—*Koester*, ibid. 40. Bd. S. 468.—*Blessig*, Centralbl. 1868. S. 87.—*Williams*, Med. Record. New York, 1868. III. Nr. 52.—*Wecker*, kl. Monatbl. 1868. S. 47, 406.—*Zehender*, ibid. S. 99.—*Lawrence*, ibid. 126.—*Herpin*, *Desormeaux*, *Passavant*, *Giraudet*, *Lenori*, nach Zehender l. c. —*Hirschberg*, kl. Monatbl. 1868. S. 153, 157.—*Schiess-Gemuseus*, ibid. 1870. S. 56.—*Collard*, Gaz. méd. de Paris. 1866. Nr. 39.—*Morton*, Prager Vierteljahrschrift. 93. Bd. Misc. S. 81.—*Manz*, kl. Monatsbl. 1868. S. 182.—*O. Becker*, Wien. Augenkl. Ber. S. 162.

Hydatids: Mackenzie, l. c. II. P. 860–871.—*Stellwag*, Ophth. II. S. 1229, 1356.—*Keate*, nach Mackenzie I. P. 70.—*Lawrence*, *Bowman*, ibid. II. P. 861.—*Waldhauer*, kl. Monatbl. 1865. S. 385, 388.—*Zehender*, Seitz Handb. etc. S. 552–558.—*Hirschler*, A. f. O. IV. 2. S. 113.—*O. Becker*, Zeitschrift der Wien. Aerzte. 1865; Wochenbl. S. 385.—*Graefe*, I. 1. S. 453, et seq. I. 2. S. 326; II. 2. S. 334, 339; III. 2. S. 308, et seq.; IV. 2. S. 171; VII. 2. S. 48, 49. 52; X. 1. S. 205.—*Appia*, nach Mackenzie l. c. II. P. 868.—*Estlin*, ibid. P. 862.—*Bowman*, ibid. P. 803. Anmkg.—*Sichel*, *Höring*, nach Zander und Geissler l. c. S. 417.—*Schott*, nach Mackenzie l. c. II. P. 863.—*Logan*, ibid. P. 864.—*Canton*, ibid. P. 868. *Mende*, A. f. O. VII. 1. S. 123.—*Coccius*, über die Anwendung des Augenspiegels. Leipzig. 1853. S. 93.—*Schweigger*, A. f. O. VII. 2. S. 53; Vorlesgn. über den Gebrauch des Augenspiegels. Berlin. 1864. S. 54.—*Soelberg-Wells*, Ophth. Hosp. Rep. III. P. 324.—*Jacobson*, A. f. O. XI. 2. S. 148, et seq.—*Alf. Graefe*, kl. Monatbl. 1863. S. 232–242.—*A. Weber*, ibid. 1864. S. 223.—*E. Jaeger*, nach Mackenzie l. c. II. P. 869.—*Liebreich*, A. f. O. I. 2. S. 343; Atlas der Ophth. Berlin. 1863. Taf. 7.—*Busch*, A. f. O. IV. 2. S. 99, 102.—*Nagel*, ibid. V. 2. S. 183.—*Graefe*, A. f. O. XII. 2. S. 174.—*Hirschberg*, Virchow's Archiv. 45. Bd. S. 509.—*Krüger*, kl. Monatbl. 1867. S. 59.—*Mauthner*, Lehrb. d.

Ophthscop. 1868. S. 461, 468.—*Teale*, Med. Record. 1868. III. 52. S. 83.—*Merkel*, Cent
1867. S. 560.—*Arlt*, Wochenschr. d. Wien. Aerzte. 1867. S. 252.—*Wharton Jones*, Cans
Jahresber. 1865. III. S. 36.—*Mooren*, Ueber Symp. Ophth. S. 41.—*Fano*, *Quadri*, L'
méd. 1868. Nr. 31.

1. Extraocular Tumors.

Accompanying Symptoms.—According to their position and extent, these tumors cause a variety of disturbances, which greatly modify their symptoms. When on the eye-lid, if of any size, they may interfere with or entirely prevent the movements of the parts; if, on the contrary, in or under the conjunctiva, they readily protrude between the lids as they grow, prevent their closure, interfere with the conduction of the tears, often displace the eye-lids, or actually evert them, and limit the movements of the eye. If they grow to one side, they cause deviation of the optic axis and diplopia, or they impair vision by partly or entirely covering the pupil. If they grow behind the tarso-orbital fascia, in the anterior part of the orbit, they often push the eye-ball to one side. Growths deep in the orbit behind the eye-ball always cause exophthalmos. If they lie in the space between the muscles, and the latter be unaffected, the eye is usually pushed directly forward, and its movements limited in all directions. If the tumor be not connected with the eye-ball, but separated from it by a cushion of fat, the rotation of the eye is still around its center. But if the tumor be attached to the ocular capsule, the point of rotation becomes eccentric, or may even be thrown outside of the eye. If the growths have developed between the muscles and the orbit, the protrusion is always more oblique, and power of motion seems mainly diminished toward the side of the tumors. If motion be entirely stopped in one direction, we may suspect that the corresponding muscle has been affected by the growth, and this would show the inclination to affect different tissues, and indicate a malignant nature. (*Graefe.*)

The exophthalmus may exist for a long time, without the globe necessarily suffering any permanent injury. Frequently, however, the inability of the lids to sufficiently protect the eye, or the laceration and compression of the vessels and nerves impair the nutrition of the globe; they lead to intraocular inflammations, often with signs of stasis in the retinal veins; to *hydrops subretinalis*, and exceptionally to detachments of the choroid, by which the globe finally becomes atrophic with signs of iridochoroiditis; or the cornea ulcerates in consequence of neuroparalysis or of intercurrent violent inflammations, and the result is phthisis of the globe. Not very uncommonly there is developed an atrophy of the optic nerve, either primary or dependent upon retrobulbar neuritis; sometimes the optic nerve is even attacked by the secondary growth itself and destroyed.

The extent of the exophthalmos is not necessarily in proportion to the size of the orbital tumor at the time. Not unfrequently one or other wall of the orbit is worn away, destroyed by caries or necrosis, or drawn into and affected by the process of proliferation. Thus the tumor may, even quite early, find its way into the nasal, frontal, or maxillary sinus, into the pteregoid fossa, or even into the cranium. It then enlarges, presses aside organs lying in its way, causes their atrophy, or attacks their tissue. During this time the orbital portion increases but little.

Very exceptionally tumors grow from neighboring cavities into the orbit. On the other hand, tumors that have developed in the surrounding cavities often injure the eye-ball by pressure on the walls of the orbit; they contract this cavity more and more, and finally reduc

it to a fissure, and destroy the protruded eye-ball by interference with its nutrition, or by inflammation. (*Mackenzie.*)

Treatment.—The first indication is the removal of the tumor. The means for this is generally the knife.

In small cysts the oft-repeated puncture and emptying of the cavity suffices, particularly when the internal wall is subsequently cauterized. In larger cysts, repeated injections with irritating remedies have been regarded as useful, especially with tincture of iodine accompanied by drainage.

Circumscribed, superficial angiomata have been in some cases removed by passing in needles cross-wise and heating them to a red heat (*Mackenzie*). Of the more deeply situated pulsating orbital tumors, one case is said to have disappeared spontaneously (*Virchow*), others are said to have been cured by the use of ergotine and veratrum, cold applications; a larger number by injection of coagulating fluids, particularly the sesquichloride of iron (*Zehender*). Digital compression, according to Vanzetti, has rendered good service in some cases, in others has produced no effect. The most cures, or at least satisfactory results (23 in 31 cases, *Zehender*) have been obtained by the ligation of the carotid artery. Still this is in any case a very hazardous operation. Out of a collection of 586 cases (*O. Pilz*) there results, that in consequence of the ligation of the carotid artery about 43 per cent. of the patients die and 53 per cent. recover; that 30 per cent. of the patients suffer brain-disturbances, and that in about 8 per cent. paralyses are developed.

Secondary growths may be removed sometimes by cauterizing pastes, if they are superficial. The Vienna paste or chloride of zinc may be employed. Some do not limit their employment to superficial tumors, but use these caustics also to thoroughly destroy the suspiciously infiltrated raw surface even down to the bones after extirpation of the orbital tumor (*Sichel, Robin, Lawson*). More recently the internal and external use of chloride of potassium has been well spoken of, especially in epithelioma of the lids. Pledgets of lint, impregnated with a solution of chloride of potassium in water (1:15), should be laid upon the luxuriant surface, and renewed three to four times a day. In addition seven grains of the drug should be taken inwardly daily in a watery solution (1:180) (*Magni, Stavenhagen*). The remedy seems to need several months to effect a cure.

Tumors of a benignant character, which are situated with a pedicle very superficially, may sometimes also be cured by ligation.

Generally, extirpation should be undertaken as soon as possible, especially in true tumors, which continue to grow; for it is not simply a question of avoiding or removing injuries that are being inflicted mechanically upon neighboring organs. The great danger lies in the often rapid infection of the surrounding parts, in the scattering of germs of the disease, and their development to new foci. The apparently benign aspect of a tumor, which is perceptibly growing, should not cause delay, for it is certain that benign tumors that have long remained unchanged and uninjurious, often change their character suddenly, and become exceedingly infectious. But it is impossible to decide the time when this unfortunate change will occur, and if infection of the neighboring parts, or dissemination of the germs, has once set in, the operation is usually without benefit, as the new foci hardly betray themselves at first, and hence are readily overlooked, or may even arise in places where they can not be reached. Hence relapses readily occur, which progress very rapidly, and usually kill the patient in a short time.

If the malignancy of a tumor becomes certain by its affecting a *variety* of tissues lying near each other, or if it has already attacked and perforated hard, tendinous or bony walls, there are most probably scattered secondary foci, and the success of an operation becomes mere chance; if a number of foci already be well developed, or if the lymphatic glands be swelled; should the original tumor have attained considerable size, and should ulceration have set in; or if cachexia have shown itself

an operation should be declined, for it will hasten the process, and the probably short life of the patient will be still further curtailed.

A chief rule in operating, especially upon suspicious or manifestly malignant growths, is to remove all the affected parts, not leaving even a trace of the growth. Hence the incisions must always be made outside of the tumor, and must be carried beyond the parts evidently affected. Where the growth has extended into cavities, so as not to permit a complete removal, we should not operate. Of course, the incision must depend on the position and extent of the roots of the tumor. We may prescribe, as a general rule, that each stroke of the knife should be made with the view of causing as slight a scar as possible; especially in operating upon pseudoplasms of the skin and conjunctiva should every incision be so made that the opening left may be covered by contraction of the neighboring parts without much straining so as to afford the most favorable conditions for union without suppuration.

a. Dermoid tumors, seated on the margin of the cornea, should be seized and drawn forward with the forceps, and cut off by a cataract-knife. (*Graefe.*) Any part remaining above the surface of the cornea may be removed by the curved scissors. If the wound should granulate too much, we may cauterize it with nitrate of silver, and subsequently apply tincture of opium.

b. In cancroids of the scleral margin it is advisable to incise the conjunctiva at a distance of at least a line from the border of the secondary growth, then to draw the latter forward with the forceps, and to remove it by long incisions with a cataract-knife in such a way that the incised surface lies in healthy corneal and scleral tissue throughout its entire extent. In order to cover up the loss of substance of the conjunctiva and to avoid the excessive formation of granulations, two four-cornered flaps, proceeding from the edges of the wound, must be separated in the conjunctiva, of which one is directed obliquely upwards and outwards, the other obliquely downwards and inwards, and which, after they have been dissected up from the subjacent layer, are drawn together over the raw surface of the sclera and united by sutures, (*Knapp.*)

c. Epitheliomata, which grow in the skin of the lids, demand extirpation together with their roots. As long as these do not extend very far, it will as a rule be easy to cover the raw surface by drawing together the neighboring parts without causing essential deformities and disturbances in function of the lid. If, however, the growth has reached a certain extent and has gone somewhat deeper, the covering of the loss of substance will then generally be difficult. To this end many ingenious methods of *blepharoplasty* have been recommended. (*Hasner, Knapp.*) Still it is very doubtful, whether they answer the purpose and are worth the trouble, as the epithelial cancer, if it involves a large extent of the lid, always returns, and then usually advances very rapidly.

d. Tumors lying close under the skin or conjunctiva must be exposed before extirpation. A linear incision is often sufficient for this purpose. This is best made by lifting a fold of skin from over the tumor, and cutting it through in the proper direction with a bistoury or scissors. If the tumor is large, a cross or T-shaped incision may be required. But if the tumor be anywhere adherent to the covering, it is best to include the adherent integument between two elliptical incisions. Then the rest of the covering is to be dissected off from the tumor; this is to be seized with toothed forceps, drawn forward, and the whole of it carefully removed.

In *angiomata* of the lids in which great bleeding is to be feared, the ring-forceps of Desmarres may be used, which by compression of the vessels renders the operation essentially easier. (*Stavenhagen.*) If the growth has been removed, the edges of the wound are to be united by strips of plaster or better by fine sutures, in case the operation was commenced from the external covering, and a light pledget of cotton bound upon them, in order where possible to bring about union of the cavity of the

wound by first intention. Where, however, such a favorable result is from the beginning not to be hoped for, the introduction of a tent of charpie must not be forgotten. As for the rest the bandage remains the same. If the secondary growth was extirpated from the conjunctival surface, sutures are only indicated in very long or crucial incised wounds, and must be made by the finest silk-thread and also removed as soon as possible. The protective bandage then has the effect of impeding the movements of the lids, the displacement of the edges of the conjunctival wound, etc., and consequently of favoring the cure. Introductions of tents are to be avoided under such conditions.

Cysts, lying under the conjunctiva, often spring out spontaneously from the envelope as soon as the membrane over them has been divided. The wound heals up very quickly. If the cyst ruptures during the operation, and if, on account of the delicacy of the cyst-wall it be difficult to remove it, we may rest satisfied with a partial removal, without apprehension of its return. But, for greater certainty, we may cauterize the remains of the sac with nitrate of silver.

e. In growths originating deeper in the orbit, extirpation is more difficult, but more imperative, particularly when the tumors are growing rapidly. If possible, the extirpation should be made through the skin of the lid, as, when made through the conjunctiva, it is more difficult and objectionable from the resulting cicatrix. An incision should be made over the most prominent part of the swelling, parallel to one of the bony walls of the orbit, and exposing the surface of the tumor. When the latter is large, a second incision should be made, perpendicular to the first, forming a T-shaped wound. The coverings should be sufficiently removed, the tumor seized with toothed forceps, drawn forward, and freed from its attachments by the knife or scissors.

If the pseudoplasm be attached to the periosteum, and this be much swelled, it seems advisable to shave off the affected portion of it. If the bone seem much diseased, part of it should be chipped out with a chisel. This is absolutely required in growths of a suspicious or manifestly malignant character. In cysts, on the contrary, it makes no difference if part of the sac remains, as this is removed by subsequent suppuration.

Many employ the paste of chloride of zinc as a substitute under such conditions. (*Sichel, Lawson.*) Still it is doubtful whether this answers the purpose.

During the operation the eye must be carefully handled, and protected from injury. Its extirpation is not required as long as its constituents have undergone no material change, and is only justifiable when the pseudoplasm cannot be removed without it. But in far the greater number of cases, especially when the tumor lies outside of the intermuscular space, the eye-ball can and should be preserved. The necessity of laying bare a large part of the globe does not render this less imperative, for experience teaches that, even under such circumstances, the eye not only retains its shape, but part of its functional power may again return and be retained. (*Berlin.*) (*Zehender, Graefe, Schiess-Gemuseus.*)

When the tumor has been removed, and the hemorrhage checked, the wound in the skin should be united by sutures, except a small space. Through the latter, a piece of lint should be passed to the bottom of the wound, to insure an escape for the pus. Otherwise the treatment is the same as for other deep wounds. Usually, granulations soon form, which fill up the cavity, and appear at the outer opening, till cicatrization terminates the process. Not unfrequently sinuses remain for years, which constantly secrete pus, and will not close. This often happens without the

, and other foci of the disease can be found in the orbital cellular tissue, it is
risable to remove the globe and the whole of the degenerated fatty cushion.
extirpation of the eye-ball and its fatty cushion is always to be done under
ics, because of its painfulness. One assistant must attend to the anæsthetic,
holds the head of the patient, and keeps the lids as far apart as possible; while
undertakes the arrest of the hemorrhage, which is usually great. To widen
as possible the approach to the orbit, and to facilitate the manipulation, in
ses it appears advisable to divide the external commissure of the lids by a
al incision, as far as the edge of the bone. Then, with his left hand, the
seizes the globe, or the protruding tumor, with toothed forceps, and draws
rd and upward. When this has been done, a strong knife, slightly curved
the edge and flat, is to be introduced to a depth of more than an inch, close
one, near the inner or outer canthus, and cut around below the eye, to the
the other canthus. Then the forceps are to be depressed, and the mass
by them drawn forward and downward, to enable the operator to cut
ne angle to the other above the eye-ball. Then it may be drawn forward
rably with its attachments, and scissors, strongly curved on the flat, passed
nto the lateral part of the wound, opened, and the optic nerve divided at one
some attachments still remain, they are readily divided by repeated cuts of
sors, and thus the growth and globe are to be removed. Then the lachry-
nd is to be seized with the forceps, drawn out, and separated with the knife
ors. When this has been done, the surface of the wound is to be most care-
examined with the finger. Where any diseased tissue is found, it should be
down to the bone, and, if necessary, the periosteum scraped off, and even a
the bony wall cut out. If the cancer presses through one wall, we may
to draw it forward with the forceps, and extirpate it.

hemorrhage, profuse as it generally is, is usually easily stopped by injections
water. The orbit is then to be tamponed, to prevent the secondary hemor-
which not unfrequently occurs. This is best done by filling in small wads of
, carefully pressed against each other, over which the lids are closed, and a
ad of charpie laid on, and a bandage applied tightly to keep the compress in
and press against the orbital tampon.

and occasions the formation of plugs, which might readily prove injurious when in the vessels at the base of the brain.

The bandage should not be removed for two or three days, that is, until suppuration begins. Usually it is to be worn till the orbit is covered with a layer of granulations. Meantime the patient is to be treated as if severely wounded, and we must especially endeavor to moderate the local inflammation and any severe fever that may occur.

In some rare cases, traumatic meningitis occurs after extirpation. From its suppurative character, it inclines to assume a very active course, in which the typical stages are lost sight of. The pulse is very rapid, the local temperature increased, the headache very severe, and the mind cloudy. Then symptoms of paralysis, general collapse, and death, soon occur. It is rarely possible to master the process, at its very commencement, by strong antiphlogistics. Nevertheless, the occurrence of suppuration at the edges of the orbital wound seems to have a beneficial effect. (*Graefe.*)

When the danger of secondary hemorrhage is over, and the orbit covered with a layer of granulations, the bandage may be omitted, and the treatment limited to syringing out the cavity several times daily, till cicatrization is complete. This often occurs in a short time (within fourteen days), especially when large portions of conjunctiva have been preserved, which contract and close the orbit anteriorly, like a curtain, thus greatly diminishing the extent of the wound.

Should the process of granulation be retarded, or should it become too luxuriant, accompanied by profuse proliferation, or if the granulations themselves appear flabby, pale, very soft, etc., local irritating remedies, such as tincture of opium, nitrate of silver, etc., should be used.

g. If the operation be given up as useless, we must render the painful condition of the patient as bearable as possible, and lengthen, as much as may be, his miserable existence. The local treatment then required consists in guarding against injurious influences, carefully cleansing the part, by washing it frequently during the day with lukewarm water, and wearing a suitable bandage, partly for protection, partly to hide the horrible condition. If hemorrhages occur later, compresses, wet with dilute chlorine water, may be used. When pieces of the cancer have begun to fall off, it is customary to use powdered charcoal to absorb the bad gases. Moreover, the avoidance of bodily and mental excitement is to be recommended. Cold compresses are used with advantage for local inflammations, especially when a decided increase of temperature is perceptible. Narcotics are occasionally serviceable against severe pain. Where there is much fever, digitalis, aconite, and sometimes quinine, are useful. If exhaustion of the body shows itself, preparations of quinine, easily digested nutritious food, and a moderate amount of beer, may be used.

Authorities.—*Himly*, Krankheiten u. Missbildungen. etc. I. Berlin. 1843. S. 505.—*Mackenzie*, Traité des mal. d. yeux. Traduit p. Warlomont et Testelin. I. Paris. 1856. P. 70–107—242, 487–504.—*Küchler*, Deutsche Klinik. 1866. Nr. 18, 19, 20.—*Stellwag*, Ophth. II. S. 1230.—*Graefe*, A. f. O. I. 2. S. 288; X. 1. S. 193, 194, 200, 205.—*Jacobson*, ibid. X. 2. 5—*Zander* und *Geissler*, Die Verletzungen des Auges. Leipzig u. Heidelberg, 1864. S. 424—435.—*Schuh*, Wien. med. Wochenschrift. 1861. Nr. 1–5.—*Chelius*, Handbuch der Augenkunde. II. Stuttgart. 1869. S. 515.—*Berlin*, kl. Monatbl. 1866. S. 81.—*Graefe*, A. f. O. S. 197.—*Schiess-Gemuseus*, ibid. XIV. 1. S. 73.—*Zehender*, ibid. IV. 2. S. 55; kl. Mon— 1868. S. 108.—*Knapp*, A. f. O. XIII. 1. S. 183; XIV. 1. S. 278, 283; Arch. f. Aug- u. O— heilkde. I. S. 1, 3.—*Hasner*, Entwurf einer anat. Begründg. Prag. 1847. S. 248.—*Hirsch*— kl. Monatbl. 1869. S. 76.—*Sichel*, *Robin*, ibid. 1868. S. 275.—*Lawson*, Lancet. 1869. I. S. *Magni*, Rivista clinica. 1869.—*Stavenhagen*, kl. Beob. S. 23.—*Berthold*, A. f. O. XIV. 107.—*O. Pilz*, Arch. f. kl. Chirurgie. IX. S. 257.

2. Intraocular Tumors.

Accompanying Symptoms.—Growths occurring in the posterior part of the eye always cause disturbance of vision very early. All perception of light is often lost quite soon, or indistinct perceptions remain at some points, and disappear as the disease progresses. In many cases it is the monocular blindness that calls the patient's attention to the disease, for the tumor may develop and attain considerable size, without causing any other difficulty or changing the appearance of the eye. Frequently, even careful examination with a dilated pupil and the ophthalmoscope is necessary to perceive the growth.

Retinal glioma in its commencement appears under the form of an opacity, either diffuse (*Knapp*) or separated into numerous large and small deposits, tolerably sharply defined, from a bluish white to a deep white color, destitute of any admixture of yellow, which is interspersed usually very early with a few denser nodules projecting distinctly forward, leaves the retinal vessels free in spots, but veils them or entirely conceals them in spots, and not uncommonly becomes vascularized, so as exceptionally to resemble red granulations. The prevailing white, saturated tint, the opacity of the infiltration, the smoothness of the surface of the tumor, and the absence of all appearances pointing to inflammation, particularly the absence of striking opacities in the vitreous humor, then combine to cause us on the one hand to doubt the existence of exudative or hyperplastic forms of neuro-retinitis, on the other hand to render a strong reflex possible, which is obtained particularly with a widely dilated pupil and by a position favorable to the light, and causes a shining of the fundus of the eye with an intense, brilliant white, metallic glistening. It is usually this very remarkable symptom which calls the attention of the persons around the affected child to the existence of the affection and excites an investigation, which almost always proves the existence of almost complete blindness of the eye in question. With progressive growth the tumor presses closer upon the optical axis and can then always be distinctly seen with the naked eye. As a rule, the portion of the retina in question is very early lifted up to a wide extent from the choroid, and in some cases advances as far even as the posterior surface of the lens; the detachment of the retina is often even total. The unusual situation and form of the detached portion of the retina, the eccentricity of the funnel-axis in total detachment, the intensely white color and the opacity, as well as the superficial smoothness of the detached retina, projecting in places like nodules, then give sufficient proofs, in connection with the peculiar arrangement of the choroidal structure perceptible upon it, for distinguishing the condition from a primary hydrops subretinalis. In addition to these we have, as diagnostic aids, the continuance of the normal or even the demonstrable increase of the intraocular pressure, not uncommonly the development of an actual glaucoma with all its characteristic signs, that is to say, a combination of symptoms such as is scarcely ever observed in children. Further on in the course of the disease intercurrent inflammations then appear in the form of iridochoroiditis, which, when they do not lead to suppuration and perforation, sometimes cause a temporary shrinking of the globe.

This temporary phthisis is not always connected with a sinking-in of the globe, there sometimes even found rather a slight bulging forward, which then, in connection with sli excursive limitations, betrays the transmission of the glioma to the retrobulbar structure, o least an enormous infiltration of the anterior section of the optic nerve. (*Graefe.*)

Sarcoma appears in the iris in the form of brownish or black nodules, more less vascularized, which, having their roots in the parenchyma of the iris, pro into the anterior chamber. Choroidal sarcoma presents itself in the commencem usually as a lenticular, flatly lying tumor of a reddish-gray or brownish-red co upon the generally smooth surface of which a rich vascular network and hemorrhages are often seen. (*Knapp.*) This is frequently spotted or studded vi the remains of the disintegrated epithelium, and even dull black, if the pig en were very abundant. In so far as it always reflects more light than the no mal choroid, the fundus appears very smoky, shimmering into green, or in bright color- ing, reddish or whitish gray, and under favorable conditions glistening dimly.

Where the choroidal sarcoma quickly leads to adhesion of the retina with the choroid, and, being transformed into gliosarcoma, grows through the retina, the appearances are very similar to those of pure retinal glioma, unless we attempt to make a distinction in the fact that in some cases, irregular light-colored, non-elevated spots have been observed under the veil-like opaque retina in the neighborhood of the clear white tumor (*Graefe*), which are without doubt to be referred to partial destruction of the choroidal tapetum.

On the whole, it is merely an exceptional case when the choroidal sarcoma in its commencement is perceived as such. As a rule, the retina becomes detached and opaque throughout a wide extent very early in the disease, so that the tumor is completely concealed. Only when the latter increases in size does it again come to lie against the retina, and may shine through with its reddish-gray, brownish or black color, in case the retina is not too opaque and thickened by inflammatory processes. Before this is the case, the unusual situation and form of the detachment of the retina furnish grounds of supposition for the existence of an intraocular pseudoplasm.

In addition, moreover, there is often found a considerable, and at the same time irregular dilatation of the pupil, which is not the case in simple detachment of the retina. Moreover, a peculiar kind of vascular injection is sometimes observed in the region of the episclera and conjunctiva, a single quadrant, a half of the sclera appears covered with coarse, contorted veins, freely anastomosing with one another, whilst on the remaining portions of the external surface of the globe the congestion is but slightly or not at all pronounced.

More decided points on which to base a differential diagnosis are given in the increase of the intraocular pressure, which is, as a rule, present, and in pure hydrops subretinalis is very unusually large, upon which the other symptoms of chronic glaucoma usually supervene. The globe remains often for a long time in this glaucomatous condition when it does not result in perforation by the growth. The lens then usually grows opaque pretty quickly, and the eye resembles one affected by absolute glaucoma which has run its course. The development of these complex symptoms is also not uncommonly very much hastened by inflammatory attacks with very violent signs of irritation, which bear the stamp of acute glaucoma. The globe degenerated in such a degree does not, however, become perfectly quiet, as is usually the case in pure glaucoma; on the contrary, the inflammatory attacks are usually repeated, and are ordinarily accompanied by very violent, often unbearable pain to the patient, particularly when intraocular hemorrhages appear, as very easily happens. Finally, scleral staphylomata are developed, which usually prepare

the way for perforation, or else the eye begins gradually to shrink. In many cases the inflammatory attacks resemble a suppurative iridochoroiditis or a real panophthalmitis, and by destruction of the cornea or by perforation of the sclerotic give exit to the tumor, or else lead to temporary phthisis of the eye.

The tendency to inflammatory attacks continues to exist in the atrophic or phthisical stumps, which distinguishes the latter from those which find their starting point in pure inflammations of the globe and suffer from a chronic, insidious cyclitis. The inflammatory attacks are also distinguished by being accompanied by very violent paroxysms of spontaneous pain, while the ciliary region manifests a slight sensibility to palpitation. Such stumps, moreover, have the peculiarity that in them the shrinking occurs mainly from before backwards, the equatorial diameter being, on the contrary, relatively but little shortened. The flattened shape of the stump naturally brings with it a considerable receding of the anterior surface of the globe. Where this is very trifling or even amounts to nothing, there is reason for supposing the existence of a retro-bulbar secondary deposit, or that a perforation of the intraocular tumor has already occurred posteriorly. (*Graefe.*)

Cysticerci, which lie in the anterior chamber, may always be distinctly seen with the naked eye. If, however, one is situated in the vitreous humor, we need the opthalmoscope to enable us to recognize it. It presents itself as a circular, cloudy vesicle of bluish tint, which sometimes makes marked vermicular movements, while the head is sometimes projected, sometimes drawn back. The circlet of hooks has often been distinctly perceived. (*Liebreich.*) Moreover, under such conditions the animal makes itself also subjectively felt, as the portion of retina overshadowed by it appears as a dark spot in the field of vision, which in one case rendered even the movements of the head of the animal visible, it being sometimes lengthened and then shortened. If the worm is still underneath the retina then it appears at first, ophthalmoscopically, as a bluish-gray opacity of about double the size of the papilla, which grows rapidly in all directions, pushes the retina before it and seems to penetrate it, since the vessels become more and more concealed and even entirely unrecognizable. If the worm does not now penetrate into the vitreous humor, a rounded bright spot is often seen in the fundus near this bluish opacity, which in time is not uncommonly lengthened like a band, which depends upon the cysticercus moving itself along beneath the retina, leaving behind it a decolorized portion of choroid. Where a detachment of the retina has early appeared, and hence the worm was from the beginning freely movable, the spots and lines are absent, as they are also in cases where the worm has penetrated within a short time into the vitreous humor.

The accompanying inflammatory symptoms are varying in intensity, sometimes very violent and extensive, sometimes very slight. Later on in the disease very dense opacities of the vitreous humor almost always occur, which render the diagnosis not a little difficult. These are of a membranous nature and resemble veil-like curtains lying upon one another, which pass diagonally through the eye, and frequently show folds, but rarely interruptions. If iridochoroiditis has already appeared, the fundus cannot be distinguished, and there is an end of the possibility of a diagnosis of cysticercus without a history. (*Graefe.*)

Treatment.—The first indication is of course the removal of the neoplasm, and when this cannot be effected without destroying the eye, the extirpation of the latter is demanded, in order to prevent the threatened infection of neighboring parts and constitutional contamination.

If such a tumor have a small base and be attached to the iris, a linear incision may be made through the cornea, as for iridectomy, and the tumor, with the iris attached, drawn through the wound and cut off.

Hydatids may be removed from the anterior chamber in the same way. But a *flap*-wound seems preferable here, as the animal is more apt to be spontaneously evacuated. At all events, it can be more certainly seized and extracted, or freed from its attachments, if necessary.

Cysticerci which still lie beneath the retina, or are connected with it by neoplastic membranous formations, are without a doubt best extracted through a meridional wound in the sclera. In case, however, the worm has penetrated into the vitreous, and is here still pretty freely movable, it seems best to open a way for its removal by the peripherical linear incision.

To this end a broad piece of iris must be cut off in the region of the scleral wound, and the lens extracted as completely as possible. This being done, the blunt hook formerly used for the extraction of the cataract should be introduced in the direction in which the animal had been seen with the ophthalmoscope. It is then either immediately extracted, or opacities of the vitreous humor are brought out which envelop the worm. Here we must continue to proceed until the cysticercus becomes visible. Then, in order to avoid the wounding of it as much as possible, we should no longer proceed directly toward the animal, but by removal of the vitreous humor endeavor to cause it to slip out of the wound by moderate pressure. (*Graefe.*) It is said that this not only usually succeeds, but that in several cases a certain degree of visual power has been preserved, which is to be very highly valued, since by the methods formerly employed phthisis bulbi was almost always the result.

The extraction of the cysticerci seems to be urgently indicated when inflammatory attacks occur, which in many cases torment the patient from the commencement, and finally always cause destruction of the eye-ball; once excited they also continue for a very indefinite time, or return as exacerbations, and finally even endanger, in a sympathetic manner, the other eye (*Alf. Graefe, Jacobson*). In order to avoid as much as possible these inflammations, and the hindrances or difficulties of the operation dependent upon them, it appears, therefore, the most prudent not to delay the operation, as soon as we are certain of the presence of a cysticercus inside the globe.

When the cysticercus is firmly adherent to its surroundings by means of extensive dense membranes, and hence cannot probably be removed without destruction of the globe, we may endeavor to cause suppuration of the eyeball by the introduction of a thread. (*Graefe.*) If an iridocyclitis is developed, which threatens to attack the other eye sympathetically, it appears more advisable to enucleate.

Growths which are attached to the iris by a broad base, and grow into the ciliary body or into the deeper tissues of the globe, require the enucleation of the eyeball as early as possible, even when they at the time betray a benign character. This is pre-eminently the case of gliomata. In fact, but extremely few cases are known, where the existence of an intraocular glioma has been proved, in which the enucleation has produced a cure, or even retarded the process of growth; and all these were cases in which the affection had been taken in hand in the first stages. If the glioma had already existed a long time, and had only involved the retina to a limited extent, the enucleation always proved futile, and the return of the disease was rarely protracted beyond two months (*Hirschberg*); usually it appeared earlier and induced death, usually much more quickly, according to the previous course of the affection, than would have probably been the case if the operation had not been performed. As patients only very exceptionally apply for the physician's help in the commencement of the disease, and only have their attention called to it when, by the brightly-glancing reflex of the fundus, an advanced period of development

naps permanent, was obtained by enucleation of the diseased eye, even when
wth had extended for months and longer into the cavities of the eye; and
rgeon who has a large material at his disposal might bring forward one or
ch cases. In consideration of this, the operation seems here, under favor-
nditions, not only justifiable, but even indicated, although we must heartily
ith those who consider the sarcomata as the most malignant pseudoplasmata,
s not to be denied, that frequently, perhaps even as a rule, recurrences take
ithin a short time, which may possibly shorten the life of the patient con-
ly.

e the pseudoplasm has already perforated the cornea or sclera, little or
can be expected from the removal of the eye-ball, as the infection has prob-
read to the neighboring parts, and produced new foci. Where the opera-
postponed, or given up as hopeless, the treatment is limited to avoidance of
g injurious, allaying irritation, pain, etc., for there are no remedies that
uence the growth itself.

rities.—*Graefe*, A. f. O. II. S. 219, III. 2. S. 312, 321, 327, IV. 2. S. 171, et seq. VII. 2.
. 2. S. 105, 110.—*Liebreich*, Atlas der Ophth. Berlin. 1863. S. 19.—*Jacobi*, kl. Monatbl.
121.—*Busch*, A. f. O. IV. 2. S. 99, 102.—*Guersant*, Bulletin thérap. 1865, 30 Sept.—
te, Traité d. mal. d. yeux. Traduit par Worlomont et Testelin. II. Paris. 1857. P. 285.—
, Wien. med. Wochenschrift. 1864. Nr. 10-12.—*Himly*, Krankheiten und Missbildungen,
erlin. 1848. S. 516.—*Chelius*, Handb. d. Augenheilkunde. II. Stuttgart. 1837. S. 508. A.
I. S. 176; XII. 2. S. 174, 178, 189, 237, 239; XIV. 2. S. 103-137; Congrès Ophth.
59; Virchow's Jahresber. 1868. II. S. 512.—*Knapp*, Congrès Ophth. 1868. S. 29; kl.
. 1869. S. 112.—*Mooren*, Ueber symp. Ophth. Berlin. 1869. S. 41.—*Alf. Graefe*, kl.
. 1863. S. 242.—*Jacobson*, A. f. O. XI. 2. S. 147.—*Hirschberg*, Der Markschwamen in
haut. Berlin. 1869. S. 169, 247, 250, 261.

Enucleation of the Eye-Ball.

Indications.—The enucleation of the eye (*O. Ferral, Bonnet, Arlt*) is proper in cases of intraocular tumors, as well as of growths adherent to the surface of the eye which but slightly involve the orbital tissue, and which can, therefore, be easily and completely removed.

It is, moreover, indicated in blind eyes, which are painful to the patient from continual inflammatory exacerbations and violent ciliary neuroses, or from intense subjective photopsia, when the affection cannot be cured by a less severe method of treatment; especially, however, when a sympathetic affection of the second eye is to be feared on account of chronic iridocyclitis.

Enucleation of the globe has been recommended, purely for its cosmetic effect, in extensive, permanent, and irritating sclero-choroidal staphyloma and total staphyloma of the globe, as an artificial eye can be worn after the operation, and the deformity hidden to some extent. At the same time, it must not be forgotten that in decided staphyloma the orbital fatty tissue shrinks, on account of the pressure on it, and that after the operation, the conjunctiva is strongly drawn backward; hence it is difficult to keep the artificial eye in place, and it always remains immovable.

The advantages offered by a stump for the application of a glass eye have induced many to avoid enucleation. They take away the anterior half of the eye, which is done by passing a cataract-knife through the globe, and completing the section with the scissors. (*Hondy, Williams*). In degenerative processes such a proceeding is dangerous, as the choroidal and retinal vessels often bleed excessively, and the hemorrhage cannot be checked; so that the immediate or subsequent enucleation of the eye is required.

As a general rule the operation should not be performed unless imperatively demanded. For, apart from the deformity, it is well to remember that enucleation is not at all a guarantee that the nutrition of the other eye will improve. The contrary often occurs in spite of the early performance of the operation. Besides, it may prove dangerous. Indeed, meningitis and death have been observed as its results. (*Mannhardt, Horner.*) This unfortunate termination seems to threaten particularly when the operation is performed during the existence of suppurative panophthalmitis. (*Graefe.*)

Operation.—The operation should be performed while the patient is under the influence of anæsthetics, of which *one* assistant should have the care. A *second* assistant holds the head of the patient, and opens the lids as far as possible; a *third* attends to the hemorrhage. If the eye be much enlarged, or if it be connected with an extensive growth, so that it will evidently be difficult to draw it out between the lids, the outer commissure should be divided by a horizontal incision as far as the outer bony margin of the orbit. Then the conjunctiva should be taken up, in a horizontal fold, with forceps, over the point of insertion of the left rectus, cut through with the scissors; then the tendon of the muscle is seized with the forceps, drawn forward through the vertical wound in the conjunctiva, and divided at some distance from the line of insertion. When this has been done, one blade of a pair of scissors, curved on the flat, is to be passed from one angle of the wound.

under the conjunctiva, to the attachment of the next rectus-muscle, the conjunctiva divided, and the exposed tendon of the second muscle seized with the forceps and divided, and so on, till all four recti-muscles have been separated from the globe. Then, if we do not fear that the eye will rupture, and lose its contents too soon—that is, *collapse*—Museaux' forceps may be employed; otherwise it is better to seize the tendinous stump of the left rectus with strong, trustworthy forceps (Fig. 91), in order to turn the globe strongly outward, and at the same time draw it forward. Scissors, strongly curved on the flat, are then to be introduced, closed, into the wound close to the left side of the eye, opened to receive the optic nerve between its blades, and to cut it as far back as possible. Then the eyeball can readily be brought out of the orbit, and its remaining attachments divided. (*Arlt.*)

Fig. 91.

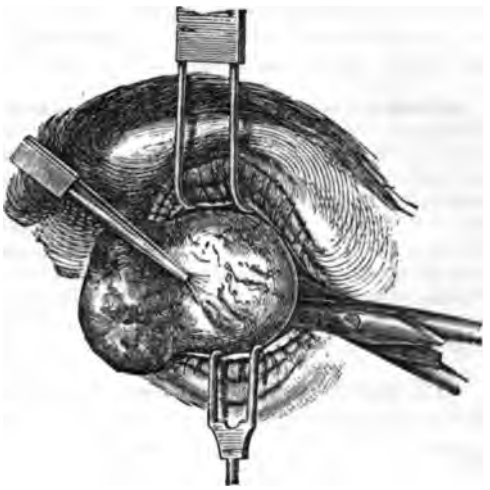

If the enucleation has been determined upon on account of the existence of intraocular tumors, particularly of a retinal glioma, it seems advisable, in view of the early encroachment of the growth upon the optic nerve, to divide the latter as near as possible to the optic foramen. To this end, it is recommended to plunge a neurotomy knife along the external wall into the posterior part of the orbit immediately before the enucleation and with this divide the nerve. There is no difficulty in this, if, after the detachment of the muscles of the globe, the latter be drawn as far forward as possible with the forceps. This subcutaneous neurotomy may, moreover, also be performed in the manner designated without previous section of the muscles of the eye, and has been employed with success in several cases, where intense photopsia lasted for a long time in amaurotic eyes and became unbearable to the patient. (*Graefe.*)

If the enucleation of the blind eye is undertaken on account of sympathetic endangerment of the other, and the subsequent introduction of an artificial eye is proposed, it seems more advantageous to divide the optic nerve close to the globe. If a larger piece of the trunk of the optic nerve be taken away, the sheath of the eye at the point of entrance of the optic nerve is laid open, the trunk retracts somewhat, and the round opening of the sheath is no longer kept separated by the optic nerve, but heals by the formation of a stellate cicatrix, in consequence of which the posterior half of the conjunctival sac is pulled far backward, and thus an obstacle may be created to the wearing of an artificial eye, which cannot be corrected. (*Mooren.*)

If the globe which is to be enucleated is adherent by tendinous bands to the orbital tissues, as exceptionally occurs, then a simple enucleation is naturally impossible, and the globe must be dissected out from its attachments. (*Sichel*).

The hemorrhage is usually stopped by injections of ice-water. If it continues, the coagula are to be removed, the lids closed, the outer commissure, if divided, is to be united by adhesive plaster, and a well-padded bandage applied over the lids. If it be difficult to control the bleeding, or secondary hemorrhage occur, we shall often be obliged to use the tampon, as after *extirpation* of the eye. (P. 573.)

However, where the tampon is not necessary, it should be avoided, as it increases the *suppuration*, and delays the healing of the parts.

Cicatrization usually occurs in a few days. The lids sink backward, and thus diminish the wound considerably. The edges of the round conjunctival opening contract and unite, forming a cicatrix which posteriorly is connected with the stump formed by the anterior ends of the muscles and the optic nerve. The conjunctival sac is again closed, and after a time an artificial eye may be readily applied.

Authorities.—*Bonnet*, Ann. d'oc. VII. P. 30.—*Mackenzie*, Traité d. mal. d. yeux. Traduit p. Warlomont et Testelin, II. Paris. 1857. P. 302.—*O. Ferral*, ibid.—*Arlt*, Zeitscrift der Wien. Aerzte. 1859. S. 145 et seq.—*Blodig*, ibid, 1860. S. 293, 451.—*Critchett*, Lancet. 1851. P. 386. kl. Mntbl. 1863. S. 440, 442, 446. Allg. Wien. med. Zeitung. 1860. S. 50, 83.—*Pagenstecher* und *Sämisch*, kl. Beobachtungen. II. Wiesbaden. 1862. S. 44.—*Graefe*, A. f. O. III. 2. S. 442, 444; VI. I. S. 122 et seq.; kl. Mntbl. 1863. S. 448, 456.—*Mannhardt*, *Horner*, ibid. 1863. S. 456.—*Höring*, ibid. 1863. S. 219, 222.—*Himly*, Krankhtn. and Missbildungen, etc. Berlin. 1843. I. S. 506; II. S. 365.—*Williams*, Congress intern. d'ophth. Paris. 1863. P. 139.—*Maats*, Zesde Jaarl. Verslag. Utrecht. 1865. S. 25, 66, 68.—*Graefe*, Congrès ophth. 1868. S. 59.—*Sichel*, Gaz. méd. de Paris. 1867. Nr. 27.—*Berlin*, A. f. O. XIV. 2. S. 279.—*Mooren*, Ueber symp. ophth. Berlin. 1869. S. 149.

[The makers of artificial eyes strongly insist upon fitting the porcelain substitute in the orbit within a short time after the operation, say a week; and there is no good objection to this, if the reaction be not excessive.]

Insertion of an Artificial Eye—Prothesis Ocularis.

Indications.—The object of the insertion of an artificial eye is to lessen, as much as possible, the unpleasant appearance caused by deformity or absence of the eye. This is important, not only as regards the feelings of the patient, but often also for his success in business. Where the eye-ball is absent, or even decidedly small, prothesis is a true *remedy*, if used soon enough; for it prevents the orbit from contracting and causing distortion of the bones of the face. It also prevents the contraction and inversion of the lids, which sometimes excite continued irritation of the stump or conjunctiva; finally, by causing a correct position of the lids and restoration of the power of winking, it renders possible the normal conduction of tears, and so removes the annoying running-over of the tears and its results.

In order that a well-chosen artificial eye may fulfil its purpose, it is necessary not only that it be sufficiently fixed anteriorly by the lids, but also that its posterior concave surface have as many points of support as possible, and that, through these supports, the recti-muscles may have an influence on its position.

Hence, prothesis is of the least service where the eye, with a considerable portion of the fatty cushion, has been removed. Even when a great portion of the conjunctiva has been preserved, the circumstances are unfavorable; for then the posterior half of the conjunctiva sinks deeply in, and, to preserve the position of the lids, it is necessary to use a large artificial eye, which is supported only by its edges on the conjunctival fold and bones, but whose posterior surface is empty; hence is either insecure, or presses too much, and, apart from its weight, remains immovable, from the absence of the muscles.

The circumstances are somewhat more favorable when the eye has been enucleated, or still exists as a small button, unless the fatty cushion be atrophied, and the lids appear decidedly retracted. The loss of substance is then less, and a smaller artificial eye suffices, which does not stand firmly based on the bony walls, but permits slight motions. The conjunctival sac is then also of sufficient size; its posterior part, with the fatty cushion, presses against the concave portion of the artificial eye, by which means the points of motion are multiplied. Moreover, the muscles still exist, and they, with the lids and conjunctiva, give the artificial eye a certain amount of motion.

Prothesis answers best when an existing deformed globe is only a little smaller than the normal one; for then a very small artificial eye suffices to hide the deformity, and has a very decided lateral motion. It fits closely on the stump, and follows all its motions. Such eyes are not unfrequently as movable as normal ones, the arc by which the muscles encompass the stump not appearing materially shortened.

If the deformed eye be of normal size, or if it have somewhat increased from disease, no room remains for a sufficiently large and thick artificial eye, which would protrude the lids disproportionately, and press on the stump, thus becoming unsightly, and insupportable to the wearer. If, on the other hand, it were made very thin, it would be too friable, and if made too *small*, there would be danger of its falling out of the conjunctival sac. Hence, in such cases, the eye-ball must first be made smaller by operation, but of course only so much as is necessary for the application of a small artificial eye without mechanical irritation of the part, all further diminution taking place at the expense of the mobility.

The artificial eye is not to be employed till all trace of inflammation and sensibility have disappeared from the conjunctiva and stump; otherwise it is not borne

well, exciting severe inflammation, with insupportable pain, and it may even ca
further shrinking of the stump. Still, we must not delay *too* long, if the stump
very small, or the entire globe has been removed: otherwise the conjunctival
and even the lids, shrink, the opening of the lids contracts, and, finally, even
orbit itself diminishes in size.

Method of Insertion.—We must first carefully determine the size and form
the eye to be applied to any particular case.

In general terms, artificial eyes are sections of the surfaces of spheres, made of enam
which are added an enameled cornea and iris.

In adults, the convexity must differ from that in children, as in the former the eye is some
larger than in the latter. Still, in either case, the radius does not vary much from a half

The size of the section of the sphere, which the artificial eye must represent, varies of c
with the size of the stump. If this be but little smaller than a normal eye, the artificial ey
must be small; otherwise it would press and resist all movements of the stump. St
should not be so small that, by an outward motion of the eye, its under edge will rise abo
lower lid, because, when looking down, it would press against the latter, and so be throw
Fig. 92, *a* (*Ritterich*), represents an artificial eye suitable for such cases. The greater the
ence in size between the normal eye and the stump, the greater the section of sphere req
(Fig. 92, *b*, *c*.) If the stump be very small, or the eye be entirely gone, the artificial eye
represent a hemisphere. (Fig. 92, *d*.)

Fig. 92.

The *posterior* surface of the artificial eye must always be hollow. If the stump be so
that the former lies on the surface of the latter, the artificial iris should not project backv
otherwise an insupportable pressure will be exerted on the stump. But if it be *small*, or
be no stump, the iris may project; otherwise the posterior surface of the artificial eye re
vacant. To make the eye so thick that even in such cases it will lie closely on the parts be
would render it too heavy.

On account of the weight, the artificial eye must not be made larger than is absolutely n
sary in order to give it a certain amount of security. Generally a thickness of quarter of
for the scleral part, and of half a line for the corneal part, is to be recommended.

The edge of the artificial eye must be very smooth. Simple *polishing* is not
ficient. In order that it may not make impressions or wounds in the conjunc
the edge must be turned under. If there be prominences in the reflected por
of conjunctiva, tendinous bands, &c., it is necessary to make openings for then
the border, so that the artificial eye may admit them (Fig. 92, *e*). Of course
interferes with the mobility.

s best to have a collection of artificial eyes, so that from them a suitable one chosen. However, the most extensive collection will not always suffice, and often obliged to have one made for a particular case.

introduction of the eye requires great care, on account of its fragility. It is ne by holding it by the outer angle, and introducing the inner angle under er lid, which is to be somewhat drawn out; then the lower edge of the l eye is to be held by the index and middle finger of the other hand, while er lid is drawn downward and over it. If we then let go of the lids, they e eye into its proper place. If, on the other hand, we wish to remove the l eye, the under lid should be depressed, so that the head of a pin may be behind the eye; the latter may be easily drawn forward until it can be seized ingers and removed.

artificial eye should always be removed and properly cleaned before going This is best done by wiping it with clean lint, and occasionally dipping it s or cologne-water.

ld not be placed in water, as this contains acids and salts, that attack the enamel and ough; and besides, water does not dissolve and remove the fats that adhere to the artifi- When cold water is used there is also the sudden change of temperature, and if the eye in with the fingers, the *uneven* cooling may affect it. These causes suffice to produce s on its surface, which may subsequently enlarge. The lint used for cleaning it must lly preserved from dust, &c. It is said that the fewest artificial eyes break in England, France, and most in Germany. This has been said to depend on the general use, in , of sand on the floors; this adheres to every thing, and if it be on the cloth used for the artificial eye, it causes fine cracks. (*Boissonneau père.*)

care, an artificial eye may be preserved for years. Finally, it becomes nd even rough. It should then be cleaned with rouge, as metal-buttons hile this is being done, the eye should be fixed on a wad of lint covered with At last, cleaning no longer answers the purpose, and a new artificial eye must ured.

orities.—*Chelius*, Hdbch. d. Aughkd. II. Stuttgart. 1839. S. 549.—*Himly*, Krkht. u. n. I. Berlin. 1843. S. 533.—*Ritterich*, Das künstl. Auge. Leipzig. 1852.—*Mackenzie*, Traité mal. d. yeux, trad. p. Warlomont et Testelin. II. Paris. 1857. P. 223.—*Boissonneau fils*, Sur artif. Paris. 1862.—*Boissonneau père*, Verbal Communications.—*Schauenburg*, Ueber rauch künstl. Augen. Lahr. 1862.—*Hasner*, Sitzungsbericht der k. böhm. Gesellschaft. f. schaften, 1861, 21. Oct.—*Arlt*, Zeitschrift der Wien. Aerzte. 1869, S. 147.—*Burow*, A. I. 1. S. 111.—*Mooren*, Ueber symp. ophth. Berlin. 1869. S. 52, 124, 125. 130.—*Lawson*, Hosp. Rep. VI. 2. S. 123—*Graefe*, A. f. O. XIV. 2. S. 138.

PART III.

CATARACT.

Cataract.

:omy.—The crystalline lens is a disk-shaped, perfectly transparent and ›dy, which is so held by the ciliary body that its axis (measuring about two ırly corresponds with the optic axis. Its anterior surface, which is the ex, projects at its center somewhat beyond the plane of the iris, which ntly appears bulged forward, and fixed by the lens. The posterior surface › more curved) is embedded in the lenticular fossa of the vitreous, and, the peripheral zone, is intimately connected with the hyaloid. The lens sed of two distinct parts, an outer envelope or *capsule* of the lens, and the ›er.

apsule is a sac-like, closed, transparent, elastic and permeable membrane, nder the microscope, appears homogeneous, structureless, but when diseased, s shows a lamellar formation. Its anterior half (the anterior capsule) is ck, but thins off quite rapidly as soon as it unites with the zonula. The portion and the posterior capsule are very delicate. The capsule is firm o offer considerable resistance to the action of blunt instruments, but is n, cut up, or pierced. If wounded, it usually tears beyond the wound from lasticity; occasionally the rent extends to the insertion of the zonula, and may even escape. The edges of the wound then retract, by rolling up or together, as far as the position of the wound permits. The great elasticity tact crystalline depends on the capsule. The lens proper, without its hyaline , is soft, and easily broken.

capsule is destitute of an epithelium. In the middle part of the posterior of the anterior capsule, a single layer of beautiful, clear polygonal cells, nd nuclei, are found, however, which was formerly regarded as epithelium. se belong, undoubtedly, to the lens itself, and stand in the most intimate to the conditions of nutrition and to the growth of the lens. From them loped new lenticular elements, which, by their apposition to those already bring about the enlargement of the lens after birth in the equatorial ı. In the antero-posterior, an increase in volume of the lens can scarcely ce after birth. (*Sappy, Ed. Jæger*).

ıct, the so-called epithelial cells of the anterior capsule pass over at the one into nucleated fibers, which increase in length more and more, enter into tissue of the lens proper, and are to be regarded as true lens fibers.

lens fibers appear, generally, as long, band-shaped tubes, appearing in a icular section as flattened and hexagonal, of very considerable transparency, y and toughness, which, exceptionally, are pointed at both ends, but as a pe away and spread out very much. Each of them bears, at least in its te, the nucleus which indicates its cellular origin.

uclei are situated together in nearly the same portion of the lens fibers, but yet at heights, hence they cause no particular swelling of the part of the lens in question. of their being collected together in a comparatively narrow belt of the periphery of ıstifies the anatomical description of a nuclear zone (*H. Meyer*).

The lens fibers run closely pressed upon one another, without interven cement-like substance. A section carried perpendicularly to their course give appearance of a delicate mosaic, consisting of six-sided plates, arranged altern Their lateral edges are dentated, and encroach upon one another, are ther more firmly connected together than the flat surfaces, the two widest of w always run parallel to the surface of the lens. By this peculiarity is explaine property of the lens of splitting up into layers, situated parallel to their su not entirely homogeneous, by which means the lens gains the appearance of composed of completely closed shells, fitting into one another like the layers onion, which surround a small round nucleus.

Every individual fiber belongs, as a rule, to both halves of one and the layer, since it runs around the equator in a course shaped like the letter S. main direction is, in general, a radiating one; still only a few reach the anter posterior pole of the stratum in question, but terminate at a distance from since their broad, more coarsely toothed end meets that of another fiber at an angle. By the meeting of two fibers at an acute angle, linear seams are fo which radiate in a stellate manner from the pole, and, since they are situate one upon the other in all the layers of the anterior and posterior halves of the divide this like perpendicular septa into a number of triangles. In the new infant three such triangles are found, almost constantly, as well on the anter on the posterior halves of the lens, which enclose between them a stellate figure three rays. With advancing age, however, these figures increase by cont apposition of new layers of fibers, and correspondingly also the rays of the st figure. Finally, secondary figures are also developed, the vertices of w removed from the poles, unite in a main ray, representing, as it were, a forkin the latter.

The lens fibers meet each other directly in the seams or rays of the stellate fi The supposition of the existence here of a thickly-fluid, homogeneous, cement substance (*Henle*), appears, according to later investigations, to be an illu (*Zernoff*). In the same way the interfibrillary passages, which are said to between the deeper layers of fibers (*F. Becker*), have become more than doul by later investigations (*C. Ritter*, *Zernoff*).

In the center of the lens the stratification ceases, and here we meet wi number of short, very irregularly-formed processes, pointed at both ends and fi into each other by their dentated lateral edges. They are, generally, withc nucleus, but sometimes contain one situated very peripherically. They are situ parallel to the axis of the lens. (*C. Ritter*, *Zernoff*).

The lens-filaments of the newly born or of children are very delicate. They tubes, which consist of a very fine and delicate, clear envelope, and watery contents, which stream out in large drops on separation of the elements. Lat peculiar protein body, *globulin* or *crystallin*, has been observed. As the indivi increases in age, the amount of this material increases in the lens; hence the elen acquire greater *consistence*, while on the surface of the lens new tubes, with contents, are formed. As the growth of the body ceases, the apposition of superficial strata of tubes appears to cease also; on the contrary, the thickenin the contents of the tubes progresses from the center toward the surface Sim neously the central elements appear to increase somewhat in size, and at the time to become rough. They also lose their nuclei. Finally, at maturity we distinguish a quite firm, rather hard, and almost dry nucleus and superficial cor substance, formed of soft tubes. The older the individual the larger the nuc

reater its firmness and hardness, while of course the still soft cortical is diminished.

nents of this latter layer are very destructible. After death they soon deliquesce into id, which has long been described as *Humor Morgagni*, but does not exist during life. ar epithelium does not furnish anything toward this, for it is often found intact s after death. (*F. Becker*).

the contents, which has become free by destruction of the lens-tubes, thickens to ated balls (*Myelinkugeln*), which greatly resemble the coloid deposits on the cho- y are found in lenses that were placed in hardening fluids, or examined when not ; they often also lie in numbers between the different strata of the filaments that rfect.

rystalline lens has no blood-vessels or nerves; but, even shortly before capsule is surrounded by a vascular sac, which lines the lenticular fossa, r the equator, and covers the anterior capsule, is united with the margin , and closes the pupil (*membrana capsulo-pupillaris*). After the disappear- is sac the crystalline receives its nourishment from the aqueous humor and us by transfusion. Hence its normal condition depends on the integrity nedia, and ultimately on that of the tunica uvea and retina. The ciliary seem to have a great deal to do with the nutrition of the lens.

Changes.—These occur in some cases earlier than in others. In general, y that they are usually the more decided, the more marked the marasmus her parts of the body. They are especially evident in eyes with well- arcus senilis. They consist of a deposition of hyaline substance on the wall of the anterior capsule, and more particularly of increased density of

mer correspond exactly in chemical and physical properties with the posits on the membrane of Descemet and choroid. Like these, they appear as hemispherical bodies with broad bases, rarely pedunculated, as if spread out, and have the appearance of thickenings of the hyaline. are often full of holes. Their surface is frequently uneven, so that they nolten glass. They usually adhere immediately to the inner wall of the psule, so that, on a section, the boundary between them appears as a fine In other cases there is between them a granular layer, which probably from the destruction of the superficial layer of cells. (*H. Müller, Wedl.*) s becomes, as a rule, dryer, more brittle, and more scissile. This is, how- cularly the case of the nucleus of the lens, which assumes, as a rule, a deli- yellow or amber tint, sometimes even running into a brownish hue. In cases we then meet with molecular opacities in the edges of the cortical ediately around the nucleus, which appear particularly distinct when the lecting mirror is employed.

diness is at first confined to a small portion of the anterior and posterior equatorial layer in question, and is of very varied form. Most frequently we meet radiated h usually follow the course of the lens-filaments, and depend on cloudiness of the ts themselves, and on depositions of molecular masses in the interspaces. They found accompanied with delicate, thin, sometimes sharply-bounded, whitish ch consist of various-sized granules, and spread out on one or both halves of the equa- ce of the nucleus. Frequently, also, the equator of the nucleus appears hidden by a ay, misty girdle, without decided contours. This more or less broad equatorial ys extends through several layers, and is caused by a throwing-off of fat-granules,

which collect particularly near the equator, and there even unite to large drops. Rar
and fine white lines form a circle around the equator of the nucleus, and they here
separating line. They give the impression that clefts have formed between the c
layers of filaments, which have been filled with molecular substance (*Förster*). These
combining forms of the layer-like opacities have been considered with the arcus se
described as *gerontoxon lentis*. (*Ammon.*)

On account of these alterations, the reflection of light from the crystalli
course, increased. Hence the pupil of an old person's eye is no longer pur
but smoky, and often very cloudy, especially when seen by bright *diffuse*
by *oblique* illumination. Then the cloudiness is usually so great that we
tarily think of a cataract far advanced.

The deception becomes still more complete when *artificial* illumination and a conve
used. Then, as a rule, the surface of the crystalline appears covered with a thi
slightly striated, grayish veil, which occasionally has a satin gloss. The border of th
also, is marked by a dull-grayish or grayish-yellow glitter. But the cloudiness on th
of the lens-surface is especially seen. The part of the lens-border turned from the
light has the appearance of being inserted in a groove, formed of two surfaces, mee
angle, which are internally smooth and brilliant, indistinct toward the pole, occasional
or marked with striæ. The width of this girdle varies greatly. The color is sometime
white, sometimes yellowish.

This cloudiness is explained by many as the commencement of a true
In most cases, however, it exists for years without decided change, and ev
age does not necessarily, or even frequently, lead to formation of cataract.

The senile thickening of the lens is marked by increasing difficulty of the
of form necessary for accommodation. With progressive thickening of th
volume diminishes somewhat also—at least the two surfaces of the lens *fla*
the refraction consequently diminishes.

Nosology.—*Cataract* and *atrophy of the lens* are synonymous expressions.
lens, as in other organs, atrophy sometimes occurs from diminution or othe
of nutrition; sometimes this process is prepared, and even caused by *infla*
change of the cellular elements of the lens. Corresponding to this, we occa
find cataract *solely* the result of atrophy; again, this is combined with th
of proliferation of elements.

Inflammation in the lens is characterized by very similar symptoms as el
Varying quantities of formation-cells collect on both surfaces, especially in t
torial zone of the lens, and in part penetrate into the deeper portions, wh
then appear arranged in rows between the fibers of the lens or in superficia
between the separate layers of the lens. The superficial polygonal c
especially the young lens fibers lying in the limiting zone take on a process
liferation, their nuclei become surrounded with granular protoplasm, swel
finally divide, while the remaining cellular contents become opaque. In co
developed lens fibers, in which the cellular contents have already been co
changed to globuline, a real division of the nucleus never occurs; w
observe an inflation and molecular opacity, which can only be referred to
processes (*Iwanoff*).

Since the inflammatory products are chiefly grouped together in the mo
ficial cellular layer of the lens, the process was also formerly described as
and phakohymenitis. Still in consideration of the evident inflammatory
encroaching deeply upon the lenticular structure, the name inflammati

kitis, is indisputably a much more suitable one, particularly as the real sub- the capsule takes but a very slight, and, as a rule, undemonstrable part in ss.

ne cases, especially when the phakitis appears as a symptom of suppurative almitis, or as result of injury to the lens, as from a wound, the neoplastic sometimes proliferate rapidly, and acquire the character of pus-corpuscles, the mother-cells undergo fatty degeneration, and the inflammatory cata- mes a *cataracta purulenta.* (*Moers, C. O. Weber, Lohmeyer, Knapp.*)

ule, however, particularly in the more chronic forms of the inflammation, a tendency to a higher development, to transformation into lens elements elf in the wandering cells, newly produced by endogenesis.

ne anterior and posterior surface of the lens, besides formation-cells, seen a large number of young growing cells, which often lie in several upon the other, or are pressed together into irregular groups, and seem he formative elements of the lens away from the capsule towards its center. mble in part the polygonal cells of the anterior pole of the lens, and in me lengthened and assume transition forms into nuclear fibers. Still they rs very irregularly formed, their contents become easily cloudy, their s surrounded by a thick layer of protoplasm, and divisions of the nuclei and ells themselves may frequently be seen in them. At the same time they y degenerate into colloid and mucous masses, at least near them there are uently found considerable quantities of a homogeneous, slightly opaque of varying consistency, in which globular kernels of a colloid appear- also frequently found. In the deeper cortical layers we often meet with arying extent, even of colossal size, which are often circular and carry one l nuclei in the slightly opaque contents; sometimes approach rather the orm and contain a fine molecular mass with coarser and larger granules, uclei; and finally they have sometimes degenerated into dark, fatty groups les without nuclei. The very opaque lens fibers, the nuclei of which appear h swollen and darkly granular, are pressed out of relative position by the c elements poured out between them, and sometimes are actually bent as ted. Their expanded ends appear swollen up and acquire a very changed ce by precipitation and a net-like arrangement of an opaque mass in their (*Wedl, Iwanoff*). The further changes are on the whole very variable. ess often soon recedes, the growing cells with their nuclei clear up, and ture gradually gains its former normal appearance. More frequently, , the inflammation leads to atrophy of the lens, the elements of which lecomposed, disintegrated and undergo secondary metamorphosis; the result rmation of cataract in the narrow sense of the word. More frequently still n occurs a development of connective tissue and its derivatives, a large of neoplastic elements spring up, gradually assume the character of con- issue cells, whilst the intervening intercellular substance becomes fibrously and finally splits up into the peculiar fine, wavy, loose bundles of fibers. plastic connective tissue is not uncommonly found in more or less thick read out superficially between the capsule and the cataractous nucleus of

More rarely we meet with wart-like, strictly defined, circular outgrowths posterior wall of the anterior capsule, which sometimes are situated flatly, s display a circular head and a distinct pedicle. They consist of a kind

of shell of concentrically stratified, oblong cells and of a nucleus of smaller circ lar cells. These cells appear very soon to become disintegrated and pass into a fine molecular, dirty brownish-yellow mass, unchangeable in hydrochloric acid. Som times the nucleus of small cells is also found entirely concealed by a glassy substan (*Wedl*). In some few cases circumscribed masses of pus appear inclosed in a envelope of connective tissue (*Moers*).

The filaments, which have become denser, and have lost their cell-nuclei, usuall participate in the inflammation only by becoming cloudy and swelled. They ofte remain unchanged, or only undergo atrophy as the affection advances.

Inasmuch as phakitis is rarely idiopathic, but occurs as a result of inflammatio in the anterior part of the uvea, its products are usually found in connection wit others, which proceed from the iris and ciliary processes, and form a covering o variable thickness on the anterior portion of the crystalline.

2. Atrophy proper shows itself first as a chemical separation or breaking-up o the lens-elements into materials of different kinds, which are partly fluid, and ma be absorbed, but are partly solid, and may remain, or be gradually absorbed, afte further chemical changes. The immediate perceptible result of the breaking-up is optical dissimilarity of the elements—that is, their cloudiness. Subsequently, however, the changes dependent on this show themselves very differently, according to the *consistence* of the atrophying part, *i.e.*, according to the greater or less density attained by it in a given time.

a. In the hard lenses of old persons, in whose elements the *solid* parts are greatly in excess, while the watery fluids are greatly diminished, the chemical process of separation goes on very *slowly*, and is also less marked, as even the escape of the fluid constituents can alter but little the original form of the elements. In accordance with this, the lens remains to a certain extent *diaphanous*. The diminution of optical homogeneousness is shown by the increase of the reflection, in the evident *coloring* of the above-mentioned part of the organ; for the lens appears brownish-yellow, or, where the process is far advanced, dirty grayish-brown, rarely red-, purple-, or black-brown. If deprived of the external layers, and exposed to the air, the darkness of the coloring increases rapidly, and it clears up very little on being placed in water. The lens *freshly* taken from the eye appears dry, hard and friable. It readily divides into concentric layers, each of which is almost transparent, and borders on yellow or red. We almost always find the *convexity* of the two surfaces *less* than normal. On the whole, we may say the flattening increases with the equatorial extent of the cataractous lens. But the extent of the latter appears to increase in proportion to the age of the individual; at least, in very aged persons we almost constantly find *large* and *flat*, but in younger persons *small* and *strongly-convex*, lenses.

Under the microscope, the individual layers, which are easily separated, appear as very translucent, yellowish or brownish plates, with rough, dark edges of unequal length, and smooth surfaces, which, with more or less dark, very fine, molecular masses, are also often strewn with rusty or brown granules of larger size, or with fat-globules. In these plates the union of the individual elements is often so intimate that their boundaries can no longer be distinguished. In other plates, however, the sides of the individual filaments, occasionally evidently shrunken, may be clearly recognized as more or less dark, rough, and parallel lines. In hard lenses affected with senile cataract we often see the lateral *edges* of the filaments very dark, and, as it were, gnawed, while their *sides* appear sown with dark points, which, on more careful examination, are seen to be small *holes*.

thinner layers of the lens, the cataractous process usually goes on more nd completely, and also shows itself by great opacity of some layers, or the ns. At the same time, the opaque layers often maintain their connection g time, and even with the naked eye we may frequently recognize the radiathem. Finally, however, the elements break up, and then present a whitishp, whose consistence changes somewhat with the degree of development of of the lens in question, but is usually curd like.

clouded filaments, and their usually somewhat swelled nuclei, appears a brighter or olecular mass, and, at the same time, a greater or less amount of fat in granules and th numerous myeline bodies. The myeline also appears frequently in the form of that the lens fibers actually fall together, and, like flat bands, float about, heaped in bundles, in the products of disintegration, which always appear deposited in : less quantity between the remains of the layers of fibers. Here and there, also, as ıclens, we find the above-described homogeneous, friable plates. Still, these here ntain a large number of myeline globules, which become isolated in the breaking-up, the plates the appearance of a network, with large openings (*Wedl*).

lements of the capsular epithelium, during this time, often remain unchanged, or, at w a fine molecular or fatty opacity of the contents. In some cases the cell-walls are ıtly destroyed, and we only find the cloudy, swelled, and variously-sprouted cells; someo, nuclei which are being destroyed or atrophied, between which is deposited a more or molecular mass. Not unfrequently the nuclei themselves are destroyed, the epithelium ated into fatty granular plaques, which have occasionally preserved the polygonal s of the cells. At the same time, we not unfrequently find striæ, in which certain roups of cells, have undergone a peculiar process of thickening. A yellowish, transm mass, has formed around the nucleus, which increases more and more, finally fills cell, and changes it to a solid, hard, opalescent disc, insusceptible to chemical changes. es subsequently unite to form quite irregular glandular groups, or stand alone, between as of other cells. (*H. Müller, Wedl.*)

ft lens-elements, under the advance of the cataractous process, usually break quickly into a cloudy, paste-like mass, or they dissolve into a whey-like which swim opaque, formless, fatty, granular flocculi.

ıe physical properties of the cataractous mass depend chiefly on the stage of nent of the elements in question, at the time, and this changes not only d to the lens as a whole, but as to the individual layers, according to the ıe person. Moreover, as the lens rarely hardens throughout at once, but ractous change proceeds sometimes from the nucleus, sometimes from the al strata of the crystalline, and only gradually extends over the rest of the is clear that the coarser anatomical conditions of the cataract must greatly But these are particularly important practically; hence they are worthy ial consideration.

mature and old age, if peculiar external circumstances do not influence the he cataract proceeds from the nucleus. This separates, as it were, from the portion, becomes hard, friable, dry, cloudy, and colored, the superficial ten long maintaining, at the same time, an almost normal transparency, and the immediate vicinity of the nucleus a fully-developed *arcus senilis of the* rs, from the disturbance of the filaments. This is called *hard nuclear* or cataract, also *phacosclerosa*. In time, the *superficial* strata also become They first become cloudy without change of form in the elements; finally, , they dissolve into a more or less consistent pulp, rarely becoming more he nuclear cataract sometimes appears with the cortical—a state called taract.

early manhood and youth, cataract more frequently commences on the han in the nucleus, but often is not limited to any part, in a short time

PART III.

CATARACT.

Cataract.

Anatomy.—The crystalline lens is a disk-shaped, perfectly transparent and elastic body, which is so held by the ciliary body that its axis (measuring about two lines) nearly corresponds with the optic axis. Its anterior surface, which is the less convex, projects at its center somewhat beyond the plane of the iris, which consequently appears bulged forward, and fixed by the lens. The posterior surface (which is more curved) is embedded in the lenticular fossa of the vitreous, and, except at the peripheral zone, is intimately connected with the hyaloid. The lens is composed of two distinct parts, an outer envelope or *capsule* of the lens, and the lens proper.

The capsule is a sac-like, closed, transparent, elastic and permeable membrane, which, under the microscope, appears homogeneous, structureless, but when diseased, sometimes shows a lamellar formation. Its anterior half (the anterior capsule) is quite thick, but thins off quite rapidly as soon as it unites with the zonula. The marginal portion and the posterior capsule are very delicate. The capsule is firm enough to offer considerable resistance to the action of blunt instruments, but is easily torn, cut up, or pierced. If wounded, it usually tears beyond the wound from its own elasticity; occasionally the rent extends to the insertion of the zonula, and the lens may even escape. The edges of the wound then retract, by rolling up or folding together, as far as the position of the wound permits. The great elasticity of the intact crystalline depends on the capsule. The lens proper, without its hyaline envelope, is soft, and easily broken.

The capsule is destitute of an epithelium. In the middle part of the posterior surface of the anterior capsule, a single layer of beautiful, clear polygonal cells, with round nuclei, are found, however, which was formerly regarded as epithelium. Still these belong, undoubtedly, to the lens itself, and stand in the most intimate relations to the conditions of nutrition and to the growth of the lens. From them are developed new lenticular elements, which, by their apposition to those already existing, bring about the enlargement of the lens after birth in the equatorial direction. In the antero-posterior, an increase in volume of the lens can scarcely take place after birth. (*Sappy, Ed. Jæger*).

In fact, the so-called epithelial cells of the anterior capsule pass over at the border zone into nucleated fibers, which increase in length more and more, enter into the real tissue of the lens proper, and are to be regarded as true lens fibers.

The lens fibers appear, generally, as long, band-shaped tubes, appearing in a perpendicular section as flattened and hexagonal, of very considerable transparency, flexibility and toughness, which, exceptionally, are pointed at both ends, but as a rule, slope away and spread out very much. Each of them bears, at least in its early state, the nucleus which indicates its cellular origin.

The nuclei are situated together in nearly the same portion of the lens fibers, but yet at different heights, hence they cause no particular swelling of the part of the lens in question. The fact of their being collected together in a comparatively narrow belt of the periphery of the lens justifies the anatomical description of a nuclear zone (*H. Meyer*).

The lens fibers run closely pressed upon one another, without intervenin cement-like substance. A section carried perpendicularly to their course gives t appearance of a delicate mosaic, consisting of six-sided plates, arranged alternat Their lateral edges are dentated, and encroach upon one another, are theref more firmly connected together than the flat surfaces, the two widest of w always run parallel to the surface of the lens. By this peculiarity is explained property of the lens of splitting up into layers, situated parallel to their surf not entirely homogeneous, by which means the lens gains the appearance of b composed of completely closed shells, fitting into one another like the layers o onion, which surround a small round nucleus.

Every individual fiber belongs, as a rule, to both halves of one and the layer, since it runs around the equator in a course shaped like the letter **S**. main direction is, in general, a radiating one; still only a few reach the ante posterior pole of the stratum in question, but terminate at a distance from since their broad, more coarsely toothed end meets that of another fiber at a angle. By the meeting of two fibers at an acute angle, linear seams are f which radiate in a stellate manner from the pole, and, since they are situ one upon the other in all the layers of the anterior and posterior halves of t divide this like perpendicular septa into a number of triangles. In the n infant three such triangles are found, almost constantly, as well on the an on the posterior halves of the lens, which enclose between them a stellate fig three rays. With advancing age, however, these figures increase by c apposition of new layers of fibers, and correspondingly also the rays of th figure. Finally, secondary figures are also developed, the vertices o removed from the poles, unite in a main ray, representing, as it were, a fo the latter.

The lens fibers meet each other directly in the seams or rays of the stella The supposition of the existence here of a thickly-fluid, homogeneous, ce substance (*Henle*), appears, according to later investigations, to be a (*Zernoff*). In the same way the interfibrillary passages, which are said between the deeper layers of fibers (*F. Becker*), have become more than by later investigations (*C. Ritter, Zernoff*).

In the center of the lens the stratification ceases, and here we me number of short, very irregularly formed processes, pointed at both ends a into each other by their dentated lateral edges. They are, generally, v nucleus, but sometimes contain one situated very peripherically. They ar parallel to the axis of the lens. (*C. Ritter, Zernoff*).

The lens-filaments of the newly born or of children are very delicate. T tubes, which consist of a very fine and delicate, clear envelope, and wat contents, which stream out in large drops on separation of the elements. peculiar protein body, *globulin* or *crystallin*, has been observed. As the i increases in age, the amount of this material increases in the lens; hence th acquire greater *consistence*, while on the surface of the lens new tubes, w contents, are formed. As the growth of the body ceases, the appositio superficial strata of tubes appears to cease also; on the contrary, the thic the contents of the tubes progresses from the center toward the surface neously the central elements appear to increase somewhat in size, and at time to become rough. They also lose their nuclei. Finally, at maturit distinguish a quite firm, rather hard, and almost dry nucleus and superfici substance, formed of soft tubes. The older the individual the larger th

r its firmness and hardness, while of course the still soft cortical minished.

of this latter layer are very destructible. After death they soon deliquesce into ıich has long been described as *Humor Morgagni*, but does not exist during life. thelium does not furnish anything toward this, for it is often found intact r death. (*F. Becker*).
ıntents, which has become free by destruction of the lens-tubes, thickens to alls (*Myelinkugeln*), which greatly resemble the coloid deposits on the cho- ound in lenses that were placed in hardening fluids, or examined when not often also lie in numbers between the different strata of the filaments that

line lens has no blood-vessels or nerves; but, even shortly before ıle is surrounded by a vascular sac, which lines the lenticular fossa, equator, and covers the anterior capsule, is united with the margin closes the pupil (*membrana capsulo-pupillaris*). After the disappear- : the crystalline receives its nourishment from the aqueous humor and transfusion. Hence its normal condition depends on the integrity , and ultimately on that of the tunica uvea and retina. The ciliary to have a great deal to do with the nutrition of the lens.

ges.—These occur in some cases earlier than in others. In general, t they are usually the more decided, the more marked the marasmus arts of the body. They are especially evident in eyes with well- s senilis. They consist of a deposition of hyaline substance on the f the anterior capsule, and more particularly of increased density of

correspond exactly in chemical and physical properties with the on the membrane of Descemet and choroid. Like these, they ar as hemispherical bodies with broad bases, rarely pedunculated, spread out, and have the appearance of thickenings of the hyaline. ften full of holes. Their surface is frequently uneven, so that they ı glass. They usually adhere immediately to the inner wall of the , so that, on a section, the boundary between them appears as a fine ɔther cases there is between them a granular layer, which probably the destruction of the superficial layer of cells. (*H. Müller, Wedl.*) ɔmes, as a rule, dryer, more brittle, and more scissile. This is, how- ly the case of the nucleus of the lens, which assumes, as a rule, a deli- w or amber tint, sometimes even running into a brownish hue. In s we then meet with molecular opacities in the edges of the cortical ely around the nucleus, which appear particularly distinct when the g mirror is employed.

, is at first confined to a small portion of the anterior and posterior equatorial in question, and is of very varied form. Most frequently we meet radiated lly follow the course of the lens-filaments, and depend on cloudiness of the mselves, and on depositions of molecular masses in the interspaces. They d accompanied with delicate, thin, sometimes sharply-bounded, whitish sist of various-sized granules, and spread out on one or both halves of the equa- he nucleus. Frequently, also, the equator of the nucleus appears hidden by a sty girdle, without decided contours. This more or less broad equatorial ends through several layers, and is caused by a throwing-off of fat-granules,

by oblique illumination. Then the cloudiness is usually so gre
tarily think of a cataract far advanced.

The deception becomes still more complete when *artificial* illumination
used. Then, as a rule, the surface of the crystalline appears covered
slightly striated, grayish veil, which occasionally has a satin gloss. The
also, is marked by a dull-grayish or grayish-yellow glitter. But the clou
of the lens-surface is especially seen. The part of the lens-border turne
light has the appearance of being inserted in a groove, formed of two su
angle, which are internally smooth and brilliant, indistinct toward the pol
or marked with striæ. The width of this girdle varies greatly. The color i
white, sometimes yellowish.

This cloudiness is explained by many as the commencement
In most cases, however, it exists for years without decided chang
age does not necessarily, or even frequently, lead to formation of

The senile thickening of the lens is marked by increasing diffic
of form necessary for accommodation. With progressive thicke
volume diminishes somewhat also—at least the two surfaces of t
the refraction consequently diminishes.

Nosology.—*Cataract* and *atrophy of the lens* are synonymous c
lens, as in other organs, atrophy sometimes occurs from diminuti
of nutrition; sometimes this process is prepared, and even cause
change of the cellular elements of the lens. Corresponding to th
find cataract *solely* the result of atrophy; again, this is combin
of proliferation of elements.

Inflammation in the lens is characterized by very similar sym
Varying quantities of formation-cells collect on both surfaces, es
torial zone of the lens, and in part penetrate into the deeper p
then appear arranged in rows between the fibers of the lens or i
between the separate layers of the lens. The superficial p
especially the young lens fibers lying in the limiting zone take o
liferation, their nuclei become surrounded with granular proto
finally divide, while the remaining cellular contents become opa
developed lens fibers, in which the cellular contents have alrea
changed to globuline, a real division of the nucleus never

ne, however, particularly in the more chronic forms of the inflammation, a
endency to a higher development, to transformation into lens elements
f in the wandering cells, newly produced by endogenesis.
e anterior and posterior surface of the lens, besides formation-cells,
en a large number of young growing cells, which often lie in several
upon the other, or are pressed together into irregular groups, and seem
e formative elements of the lens away from the capsule towards its center.
ible in part the polygonal cells of the anterior pole of the lens, and in
e lengthened and assume transition forms into nuclear fibers. Still they
very irregularly formed, their contents become easily cloudy, their
surrounded by a thick layer of protoplasm, and divisions of the nuclei and
ls themselves may frequently be seen in them. At the same time they
degenerate into colloid and mucous masses, at least near them there are
ently found considerable quantities of a homogeneous, slightly opaque
of varying consistency, in which globular kernels of a colloid appear-
so frequently found. In the deeper cortical layers we often meet with
rying extent, even of colossal size, which are often circular and carry one
nuclei in the slightly opaque contents; sometimes approach rather the
rm and contain a fine molecular mass with coarser and larger granules,
lei; and finally they have sometimes degenerated into dark, fatty groups
s without nuclei. The very opaque lens fibers, the nuclei of which appear
swollen and darkly granular, are pressed out of relative position by the
elements poured out between them, and sometimes are actually bent as
d. Their expanded ends appear swollen up and acquire a very changed
e by precipitation and a net-like arrangement of an opaque mass in their
Vedl, Iwanoff). The further changes are on the whole very variable.
s often soon recedes, the growing cells with their nuclei clear up, and
are gradually gains its former normal appearance. More frequently,
the inflammation leads to atrophy of the lens, the elements of which
composed, disintegrated and undergo secondary metamorphosis; the result
ation of cataract in the narrow sense of the word. More frequently still
occurs a development of connective tissue and its derivatives, a large
neoplastic elements spring up, gradually assume the character of con-
ue cells, whilst the intervening intercellular substance becomes fibrously
d finally splits up into the peculiar fine, wavy, loose bundles of fibers.
lastic connective tissue is not uncommonly found in more or less thick
ad out superficially between the capsule and the cataractous nucleus of
More rarely we meet with wart-like, strictly defined, circular outgrowths
osterior wall of the anterior capsule, which sometimes are situated flatly,
display a circular head and a distinct pedicle. They consist of a kind

of shell of concentrically stratified, oblong cells and of a nucleus of smaller ci lar cells. These cells appear very soon to become disintegrated and pass into a fi molecular, dirty brownish-yellow mass, unchangeable in hydrochloric acid. S times the nucleus of small cells is also found entirely concealed by a glassy subst (*Wedl*). In some few cases circumscribed masses of pus appear inclosed i envelope of connective tissue (*Moers*).

The filaments, which have become denser, and have lost their cell-nuclei, n participate in the inflammation only by becoming cloudy and swelled. They remain unchanged, or only undergo atrophy as the affection advances.

Inasmuch as phakitis is rarely idiopathic, but occurs as a result of inflamm in the anterior part of the uvea, its products are usually found in connectio others, which proceed from the iris and ciliary processes, and form a cover variable thickness on the anterior portion of the crystalline.

2. Atrophy proper shows itself first as a chemical separation or breaking the lens-elements into materials of different kinds, which are partly fluid, a be absorbed, but are partly solid, and may remain, or be gradually absorbe further chemical changes. The immediate perceptible result of the breakin optical dissimilarity of the elements—that is, their cloudiness. Subseq however, the changes dependent on this show themselves very differently, ac to the *consistence* of the atrophying part, *i.e.*, according to the greater or less attained by it in a given time.

a. In the hard lenses of old persons, in whose elements the *solid* p greatly in excess, while the watery fluids are greatly diminished, the chemi cess of separation goes on very *slowly*, and is also less marked, as even the e the fluid constituents can alter but little the original form of the eleme accordance with this, the lens remains to a certain extent *diaphanous*. The tion of optical homogeneousness is shown by the increase of the reflection evident *coloring* of the above-mentioned part of the organ; for the lens brownish-yellow, or, where the process is far advanced, dirty grayish-brow red-, purple-, or black-brown. If deprived of the external layers, and ex the air, the darkness of the coloring increases rapidly, and it clears up very being placed in water. The lens *freshly* taken from the eye appears dry, h friable. It readily divides into concentric layers, each of which is almost rent, and borders on yellow or red. We almost always find the *convexity* of surfaces *less* than normal. On the whole, we may say the flattening increa the equatorial extent of the cataractous lens. But the extent of the latter to increase in proportion to the age of the individual; at least, in very aged we almost constantly find *large* and *flat*, but in younger persons *small* and *convex*, lenses.

Under the microscope, the individual layers, which are easily separated, appear translucent, yellowish or brownish plates, with rough, dark edges of unequal length, an surfaces, which, with more or less dark, very fine, molecular masses, are also often str rusty or brown granules of larger size, or with fat-globules. In these plates the uni individual elements is often so intimate that their boundaries can no longer be disti In other plates, however, the sides of the individual filaments, occasionally evidently s may be clearly recognized as more or less dark, rough, and parallel lines. In hard lens with senile cataract we often see the lateral *edges* of the filaments very dark, and, a gnawed, while their *sides* appear sown with dark points, which, on more careful exa are seen to be small *holes*.

ular mass, and, at the same time, a greater or less amount of fat in granules and umerous myeline bodies. The myeline also appears frequently in the form of the lens fibers actually fall together, and, like flat bands, float about, heaped undles, in the products of disintegration, which always appear deposited in quantity between the remains of the layers of fibers. Here and there, also, as s, we find the above-described homogeneous, friable plates. Still, these here n a large number of myeline globules, which become isolated in the breaking-up, lates the appearance of a network, with large openings (*Wedl*).

nts of the capsular epithelium, during this time, often remain unchanged, or, at ine molecular or fatty opacity of the contents. In some cases the cell-walls are lestroyed, and we only find the cloudy, swelled, and variously-sprouted cells; some-clei which are being destroyed or atrophied, between which is deposited a more or cular mass. Not unfrequently the nuclei themselves are destroyed, the epithelium into fatty granular plaques, which have occasionally preserved the polygonal the cells. At the same time, we not unfrequently find striæ, in which certain s of cells, have undergone a peculiar process of thickening. A yellowish, trans-ass, has formed around the nucleus, which increases more and more, finally fills and changes it to a solid, hard, opalescent disc, insusceptible to chemical changes. bsequently unite to form quite irregular glandular groups, or stand alone, between other cells. (*H. Müller, Wedl.*)

ns-elements, under the advance of the cataractous process, usually break kly into a cloudy, paste-like mass, or they dissolve into a whey-like ch swim opaque, formless, fatty, granular flocculi.

hysical properties of the cataractous mass depend chiefly on the stage of of the elements in question, at the time, and this changes not only the lens as a whole, but as to the individual layers, according to the erson. Moreover, as the lens rarely hardens throughout at once, but us change proceeds sometimes from the nucleus, sometimes from the rata of the crystalline, and only gradually extends over the rest of the lear that the coarser anatomical conditions of the cataract must greatly these are particularly important practically; hence they are worthy onsideration.

ure and old age, if peculiar external circumstances do not influence the ataract proceeds from the nucleus. This separates, as it were, from the ion, becomes hard, friable, dry, cloudy, and colored, the superficial ong maintaining, at the same time, an almost normal transparency, and immediate vicinity of the nucleus a fully-developed *arcus senilis of the* rom the disturbance of the filaments. This is called *hard nuclear* or ract, also *phacoscleroma*. In time, the *superficial* strata also become ey first become cloudy without change of form in the elements; finally, y dissolve into a more or less consistent pulp, rarely becoming more nuclear cataract sometimes appears with the cortical—a state called st.

ly manhood and youth, cataract more frequently commences on the in the nucleus, but often is not limited to any part, in a short time

The lens fibers run closely pressed upon one another, without intervening cement-like substance. A section carried perpendicularly to their course gives the appearance of a delicate mosaic, consisting of six-sided plates, arranged alternately. Their lateral edges are dentated, and encroach upon one another, are therefore more firmly connected together than the flat surfaces, the two widest of which always run parallel to the surface of the lens. By this peculiarity is explained the property of the lens of splitting up into layers, situated parallel to their surface, not entirely homogeneous, by which means the lens gains the appearance of being composed of completely closed shells, fitting into one another like the layers of an onion, which surround a small round nucleus.

Every individual fiber belongs, as a rule, to both halves of one and the same layer, since it runs around the equator in a course shaped like the letter **S**. The main direction is, in general, a radiating one; still only a few reach the anterior or posterior pole of the stratum in question, but terminate at a distance from them, since their broad, more coarsely toothed end meets that of another fiber at an acute angle. By the meeting of two fibers at an acute angle, linear seams are formed, which radiate in a stellate manner from the pole, and, since they are situated the one upon the other in all the layers of the anterior and posterior halves of the lens, divide this like perpendicular septa into a number of triangles. In the new-born infant three such triangles are found, almost constantly, as well on the anterior as on the posterior halves of the lens, which enclose between them a stellate figure with three rays. With advancing age, however, these figures increase by continued apposition of new layers of fibers, and correspondingly also the rays of the stellate figure. Finally, secondary figures are also developed, the vertices of which, removed from the poles, unite in a main ray, representing, as it were, a forking of the latter.

The lens fibers meet each other directly in the seams or rays of the stellate figure. The supposition of the existence here of a thickly-fluid, homogeneous, cement-like substance (*Henle*), appears, according to later investigations, to be an illusion (*Zernoff*). In the same way the interfibrillary passages, which are said to exist between the deeper layers of fibers (*F. Becker*), have become more than doubtful by later investigations (*C. Ritter, Zernoff*).

In the center of the lens the stratification ceases, and here we meet with a number of short, very irregularly-formed processes, pointed at both ends and fitting into each other by their dentated lateral edges. They are, generally, without a nucleus, but sometimes contain one situated very peripherically. They are situated parallel to the axis of the lens. (*C. Ritter, Zernoff*).

The lens-filaments of the newly born or of children are very delicate. They form tubes, which consist of a very fine and delicate, clear envelope, and watery fluid contents, which stream out in large drops on separation of the elements. Lately a peculiar protein body, *globulin* or *crystallin*, has been observed. As the individual increases in age, the amount of this material increases in the lens; hence the elements acquire greater *consistence*, while on the surface of the lens new tubes, with fluid contents, are formed. As the growth of the body ceases, the apposition of new superficial strata of tubes appears to cease also; on the contrary, the thickening of the contents of the tubes progresses from the center toward the surface. Simultaneously the central elements appear to increase somewhat in size, and at the same time to become rough. They also lose their nuclei. Finally, at maturity we may distinguish a quite firm, rather hard, and almost dry nucleus and superficial cortical substance, formed of soft tubes. The older the individual the larger the nucleus,

nated balls (*Myelinkugeln*), which greatly resemble the colloid deposits on the cho-
ey are found in lenses that were placed in hardening fluids, or examined when not
n; they often also lie in numbers between the different strata of the filaments that
erfect.

crystalline lens has no blood-vessels or nerves; but, even shortly before
e capsule is surrounded by a vascular sac, which lines the lenticular fossa,
er the equator, and covers the anterior capsule, is united with the margin
s, and closes the pupil (*membrana capsulo-pupillaris*). After the disappear-
this sac the crystalline receives its nourishment from the aqueous humor and
ous by transfusion. Hence its normal condition depends on the integrity
media, and ultimately on that of the tunica uvea and retina. The ciliary
seem to have a great deal to do with the nutrition of the lens.

Changes.—These occur in some cases earlier than in others. In general,
say that they are usually the more decided, the more marked the marasmus
ther parts of the body. They are especially evident in eyes with well-
d arcus senilis. They consist of a deposition of hyaline substance on the
wall of the anterior capsule, and more particularly of increased density of

ormer correspond exactly in chemical and physical properties with the
eposits on the membrane of Descemet and choroid. Like these, they
es appear as hemispherical bodies with broad bases, rarely pedunculated,
s as if spread out, and have the appearance of thickenings of the hyaline.
y are often full of holes. Their surface is frequently uneven, so that they
molten glass. They usually adhere immediately to the inner wall of the
capsule, so that, on a section, the boundary between them appears as a fine
e. In other cases there is between them a granular layer, which probably
s from the destruction of the superficial layer of cells. (*H. Müller*, *Wedl.*)
ns becomes, as a rule, dryer, more brittle, and more scissile. This is, how-
ticularly the case of the nucleus of the lens, which assumes, as a rule, a deli-
e-yellow or amber tint, sometimes even running into a brownish hue. In
y cases we then meet with molecular opacities in the edges of the cortical
mediately around the nucleus, which appear particularly distinct when the

which collect particularly near the equator, and there even unite to large drops. Rarely, short and fine white lines form a circle around the equator of the nucleus, and they here form the separating line. They give the impression that clefts have formed between the concentric layers of filaments, which have been filled with molecular substance (*Förster*). These variously combining forms of the layer-like opacities have been considered with the arcus senilis, and described as *gerontoxon lentis*. (*Ammon.*)

On account of these alterations, the reflection of light from the crystalline is, of course, increased. Hence the pupil of an old person's eye is no longer pure black, but smoky, and often very cloudy, especially when seen by bright *diffuse* light, or by *oblique* illumination. Then the cloudiness is usually so great that we involuntarily think of a cataract far advanced.

The deception becomes still more complete when *artificial* illumination and a convex lens are used. Then, as a rule, the surface of the crystalline appears covered with a thick, often slightly striated, grayish veil, which occasionally has a satin gloss. The border of the nucleus, also, is marked by a dull-grayish or grayish-yellow glitter. But the cloudiness on the equator of the lens-surface is especially seen. The part of the lens-border turned from the source of light has the appearance of being inserted in a groove, formed of two surfaces, meeting at an angle, which are internally smooth and brilliant, indistinct toward the pole, occasionally cloudy or marked with striæ. The width of this girdle varies greatly. The color is sometimes grayish-white, sometimes yellowish.

This cloudiness is explained by many as the commencement of a true cataract. In most cases, however, it exists for years without decided change, and even in *old* age does not necessarily, or even frequently, lead to formation of cataract.

The senile thickening of the lens is marked by increasing difficulty of the changes of form necessary for accommodation. With progressive thickening of the lens its volume diminishes somewhat also—at least the two surfaces of the lens *flatten*, and the refraction consequently diminishes.

Nosology.—*Cataract* and *atrophy of the lens* are synonymous expressions. In the lens, as in other organs, atrophy sometimes occurs from diminution or other change of nutrition; sometimes this process is prepared, and even caused by *inflammatory* change of the cellular elements of the lens. Corresponding to this, we occasionally find cataract *solely* the result of atrophy; again, this is combined with the results of proliferation of elements.

Inflammation in the lens is characterized by very similar symptoms as elsewhere. Varying quantities of formation-cells collect on both surfaces, especially in the equatorial zone of the lens, and in part penetrate into the deeper portions, where they then appear arranged in rows between the fibers of the lens or in superficial groups between the separate layers of the lens. The superficial polygonal cells and especially the young lens fibers lying in the limiting zone take on a process of proliferation, their nuclei become surrounded with granular protoplasm, swell up and finally divide, while the remaining cellular contents become opaque. In completely developed lens fibers, in which the cellular contents have already been completely changed to globuline, a real division of the nucleus never occurs; we simply observe an inflation and molecular opacity, which can only be referred to osmotic processes (*Iwanoff*).

Since the inflammatory products are chiefly grouped together in the most superficial cellular layer of the lens, the process was also formerly described as capsulitis and phakohymenitis. Still in consideration of the evident inflammatory changes encroaching deeply upon the lenticular structure, the name inflammation of the

akitis, is indisputably a much more suitable one, particularly as the real sub- of the capsule takes but a very slight, and, as a rule, undemonstrable part in cess.

ome cases, especially when the phakitis appears as a symptom of suppurative thalmitis, or as result of injury to the lens, as from a wound, the neoplastic s sometimes proliferate rapidly, and acquire the character of pus-corpuscles, th the mother-cells undergo fatty degeneration, and the inflammatory cata- comes a *cataracta purulenta*. (*Moers, C. O. Weber, Lohmeyer, Knapp.*)

rule, however, particularly in the more chronic forms of the inflammation, a l tendency to a higher development, to transformation into lens elements tself in the wandering cells, newly produced by endogenesis.

the anterior and posterior surface of the lens, besides formation-cells, s seen a large number of young growing cells, which often lie in several me upon the other, or are pressed together into irregular groups, and seem the formative elements of the lens away from the capsule towards its center. semble in part the polygonal cells of the anterior pole of the lens, and in come lengthened and assume transition forms into nuclear fibers. Still they rays very irregularly formed, their contents become easily cloudy, their is surrounded by a thick layer of protoplasm, and divisions of the nuclei and cells themselves may frequently be seen in them. At the same time they sily degenerate into colloid and mucous masses, at least near them there are equently found considerable quantities of a homogeneous, slightly opaque ce of varying consistency, in which globular kernels of a colloid appear- e also frequently found. In the deeper cortical layers we often meet with f varying extent, even of colossal size, which are often circular and carry one ral nuclei in the slightly opaque contents; sometimes approach rather the form and contain a fine molecular mass with coarser and larger granules, nuclei; and finally they have sometimes degenerated into dark, fatty groups ules without nuclei. The very opaque lens fibers, the nuclei of which appear uch swollen and darkly granular, are pressed out of relative position by the stic elements poured out between them, and sometimes are actually bent as orted. Their expanded ends appear swollen up and acquire a very changed ance by precipitation and a net-like arrangement of an opaque mass in their r (*Wedl, Iwanoff*). The further changes are on the whole very variable. ocess often soon recedes, the growing cells with their nuclei clear up, and ucture gradually gains its former normal appearance. More frequently, er, the inflammation leads to atrophy of the lens, the elements of which decomposed, disintegrated and undergo secondary metamorphosis; the result formation of cataract in the narrow sense of the word. More frequently still hen occurs a development of connective tissue and its derivatives, a large t of neoplastic elements spring up, gradually assume the character of con- -tissue cells, whilst the intervening intercellular substance becomes fibrously d and finally splits up into the peculiar fine, wavy, loose bundles of fibers. eoplastic connective tissue is not uncommonly found in more or less thick spread out superficially between the capsule and the cataractous nucleus of s. More rarely we meet with wart-like, strictly defined, circular outgrowths he posterior wall of the anterior capsule, which sometimes are situated flatly, mes display a circular head and a distinct pedicle. They consist of a kind

of shell of concentrically stratified, oblong cells and of a nucleus of smaller circular cells. These cells appear very soon to become disintegrated and pass into a finely molecular, dirty brownish-yellow mass, unchangeable in hydrochloric acid. Sometimes the nucleus of small cells is also found entirely concealed by a glassy substance (*Wedl*). In some few cases circumscribed masses of pus appear inclosed in an envelope of connective tissue (*Moers*).

The filaments, which have become denser, and have lost their cell-nuclei, usually participate in the inflammation only by becoming cloudy and swelled. They often remain unchanged, or only undergo atrophy as the affection advances.

Inasmuch as phakitis is rarely idiopathic, but occurs as a result of inflammation in the anterior part of the uvea, its products are usually found in connection with others, which proceed from the iris and ciliary processes, and form a covering of variable thickness on the anterior portion of the crystalline.

2. Atrophy proper shows itself first as a chemical separation or breaking-up of the lens-elements into materials of different kinds, which are partly fluid, and may be absorbed, but are partly solid, and may remain, or be gradually absorbed, after further chemical changes. The immediate perceptible result of the breaking-up is optical dissimilarity of the elements—that is, their cloudiness. Subsequently, however, the changes dependent on this show themselves very differently, according to the *consistence* of the atrophying part, *i.e.*, according to the greater or less density attained by it in a given time.

a. In the hard lenses of old persons, in whose elements the *solid* parts are greatly in excess, while the watery fluids are greatly diminished, the chemical process of separation goes on very *slowly*, and is also less marked, as even the escape of the fluid constituents can alter but little the original form of the elements. In accordance with this, the lens remains to a certain extent *diaphanous*. The diminution of optical homogeneousness is shown by the increase of the reflection, in the evident *coloring* of the above-mentioned part of the organ; for the lens appears brownish-yellow, or, where the process is far advanced, dirty grayish-brown, rarely red-, purple-, or black-brown. If deprived of the external layers, and exposed to the air, the darkness of the coloring increases rapidly, and it clears up very little on being placed in water. The lens *freshly* taken from the eye appears dry, hard and friable. It readily divides into concentric layers, each of which is almost transparent, and borders on yellow or red. We almost always find the *convexity* of the two surfaces *less* than normal. On the whole, we may say the flattening increases with the equatorial extent of the cataractous lens. But the extent of the latter appears to increase in proportion to the age of the individual; at least, in very aged persons we almost constantly find *large* and *flat*, but in younger persons *small* and *strongly-convex*, lenses.

Under the microscope, the individual layers, which are easily separated, appear as very translucent, yellowish or brownish plates, with rough, dark edges of unequal length, and smooth surfaces, which, with more or less dark, very fine, molecular masses, are also often strewn with rusty or brown granules of larger size, or with fat-globules. In these plates the union of the individual elements is often so intimate that their boundaries can no longer be distinguished. In other plates, however, the sides of the individual filaments, occasionally evidently shrunken, may be clearly recognized as more or less dark, rough, and parallel lines. In hard lenses affected with senile cataract we often see the lateral *edges* of the filaments very dark, and, as it were, gnawed, while their *sides* appear sown with dark points, which, on more careful examination, are seen to be small *holes*.

ı thinner layers of the lens, the cataractous process usually goes on more and completely, and also shows itself by great opacity of some layers, or the ·ns. At the same time, the opaque layers often maintain their connection ıg time, and even with the naked eye we may frequently recognize the radia- them. Finally, however, the elements break up, and then present a whitish- lp, whose consistence changes somewhat with the degree of development of of the lens in question, but is usually curd like.

ı clouded filaments, and their usually somewhat swelled nuclei, appears a brighter or ıolecular mass, and, at the same time, a greater or less amount of fat in granules and ith numerous myeline bodies. The myeline also appears frequently in the form of that the lens fibers actually fall together, and, like flat bands, float about, heaped in bundles, in the products of disintegration, which always appear deposited in r less quantity between the remains of the layers of fibers. Here and there, also, as nclens, we find the above-described homogeneous, friable plates. Still, these here ontain a large number of myeline globules, which become isolated in the breaking-up, the plates the appearance of a network, with large openings (*Wedl*).

lements of the capsular epithelium, during this time, often remain unchanged, or, at ıw a fine molecular or fatty opacity of the contents. In some cases the cell-walls are ntly destroyed, and we only find the cloudy, swelled, and variously-sprouted cells; some- ıo, nuclei which are being destroyed or atrophied, between which is deposited a more or molecular mass. Not unfrequently the nuclei themselves are destroyed, the epithelium rated into fatty granular plaques, which have occasionally preserved the polygonal es of the cells. At the same time, we not unfrequently find striæ, in which certain roups of cells, have undergone a peculiar process of thickening. A yellowish, trans- m mass, has formed around the nucleus, which increases more and more, finally fills cell, and changes it to a solid, hard, opalescent disc, insusceptible to chemical changes. es subsequently unite to form quite irregular glandular groups, or stand alone, between ns of other cells. (*H. Müller, Wedl.*)

ıft lens-elements, under the advance of the cataractous process, usually break quickly into a cloudy, paste-like mass, or they dissolve into a whey-like which swim opaque, formless, fatty, granular flocculi.

he physical properties of the cataractous mass depend chiefly on the stage of nent of the elements in question, at the time, and this changes not only d to the lens as a whole, but as to the individual layers, according to the ıe person. Moreover, as the lens rarely hardens throughout at once, but ractous change proceeds sometimes from the nucleus, sometimes from the al strata of the crystalline, and only gradually extends over the rest of the is clear that the coarser anatomical conditions of the cataract must greatly But these are particularly important practically; hence they are worthy ial consideration.

mature and old age, if peculiar external circumstances do not influence the he cataract proceeds from the nucleus. This separates, as it were, from the portion, becomes hard, friable, dry, cloudy, and colored, the superficial ten long maintaining, at the same time, an almost normal transparency, and the immediate vicinity of the nucleus a fully-developed *arcus senilis of the* ırs. from the disturbance of the filaments. This is called *hard nuclear* or cataract, also *phacoscleroma*. In time, the *superficial* strata also become They first become cloudy without change of form in the elements; finally, they dissolve into a more or less consistent pulp, rarely becoming more he nuclear cataract sometimes appears with the cortical—a state called ıtaract.

early manhood and youth, cataract more frequently commences on the han in the nucleus, but often is not limited to any part, in a short time

spreading through the whole lens. The result is a *soft* cataract (phacomalacia). As long as the process is confined to the *nucleus*, while the cortical layers preserve their transparency, we speak of a *soft* nuclear or *soft* central lenticular cataract. But, the process begins in the *peripheral* layers, and thence progresses gradually to the nucleus, we are accustomed to diagnosticate a *cortical cataract*, as long as the nucleus remains transparent.

c. In *children*, also, the cortical portions of the lens are usually first clouded, more rarely the nucleus. Still here the process progresses so rapidly, that we rarely find a pure cortical or a soft nuclear cataract, but in most cases the cataract spreads through the *entire* lens. The disintegration is at the same time almost *complete;* the entire lens appears dissolved into a pasty or milky fluid. Exceptionally, however, even in childhood, in spite of long existence of the process and complete fluidity of the exterior portions, we meet half soft, cloudy, or even sclerosed nuclei.

4. The cataractous process does not by any means terminate with the above-described "primary" changes in the lens. In yellow, hard nuclei, secondary metamorphoses are, it is true, rendered difficult, by the slight amount of fluid present; we only see an increase of dryness, friability, and hardness, as well as a darkening of the hue. In softer layers of the lens, however, secondary changes are very marked. They occasionally begin quite early, long before the cataract has spread over the *whole* of the lens, and before the parts affected by it have been wholly destroyed. Usually, however, the secondary changes only occur after the parts of the lens affected have been reduced to a formless mass. At the same time the cataractous lens-substance thickens more and more, as a consequence of the absorption of the separate soluble constituents, and, finally decreasing in size, changes to a more consistent, solid mass, or a fatty, sandy pulp, whose chief constituents are fat, lime-salts, and myeline substance in variable quantities, together with an organic base.

The fat is in minute particles, scattered through the mass, or in granules or globules of larger size, which are often grouped irregularly. A large part of them are usually metamorphosed into cholesterin and crystalize in the well-known beautiful plates. These crystals are often heaped up in nests, so that, with the naked eye, they may be recognized by their peculiar brilliancy. Fatty acids also seem to occur occasionally in the form of needle-shaped crystals. In rare cases, the free fat flows together to form oil-globules.

Lime usually occurs as carbonate, more rarely as phosphate. Like fat, it is separated in the form of dust-like molecules, which subsequently unite and form large grains, which are recognizable as well by the naked eye as by the touch. Very often, especially where the cataract originates from inflammation, large concrements occur. These often have the appearance of irregular, chalky masses, and then lie free in the fatty, sandy mass. Often, however, they form scales or cups of greater or less thickness, which are attached to the inner surface of the anterior, or of both capsules. On polishing such concrements, we often find the chalk strewn through the organic basis in a granular form, but often also collected together into masses, which have the most varied size and arrangement, and sometimes also give the impression of incompletely developed bone-corpuscles; hence, these concrements are sometimes mistaken for ossification of the lens. Exceptionally, the chalk is also seen in the form of crystals, especially near the capsule.

In the stage of secondary metamorphosis, in rare cases, we find the organic basis to be fluid; so that the cataractous mass has some similarity to lime-water. In most cases, it appears as an entirely formless, smeary, opaque substance, which unites the fat, salts of lime, and hyaline bodies to a more or less consistent, fatty, sandy pulp. More rarely it appears changed to a semi-transparent or entirely opaque, finely-granulated or homogeneous, consistent and dry substance which appears in the form of plates, even in primary cataract, and is caused by the breaking down of the lens-filaments. In the nuclear layers of soft or half-soft cataracts, as well as in the immediate vicinity of sclerosed nuclei, however, in spite of the occurrence of secondary metamor

phoses, the elements occasionally preserve their original form and coherence; and on sections we often may even see the characteristic parallel boundary lines of the lens-filaments.

The peripheral parts of the cataractous mass first undergo secondary metamorphoses. This is particularly true of the part of the anterior external layers lying behind the pupil; hence this part appears most changed. The thickened masses cling to the capsule, rendering it stiff and unyielding, and after detachment they retract from their inherent elasticity. Often, even quite early, we find the inner wall of the anterior or posterior capsules, or of both, covered with a cloudy substance, which, in some places, collects to smaller or larger spots, or to variously figured and grouped clumps, and not unfrequently even thickens to crust-like, irregular plates. In other cases this deposit is quite thick, and presents itself as a fibro-granular mesh-work or cloudy membrane, with irregular or indistinct borders. Occasionally the capsule is adherent to large shells of calcareous cataract-substance. These are called capsular cataracts, capsulo-lenticular cataracts.

The hyaline membrane itself is only exceptionally altered by these changes in its tissue. Apparent thickenings by deposit of hyaline layers are certainly not rare; but the capsule proper usually maintains its integrity. The possibility of its becoming cloudy is not disproved, although it has not been observed. Portions of it, inclosed by iritic deposits on the outside, and inflammatory products on the inside, are occasionally found thinned, perhaps by pressure. According to some recent observations, it appears as if, under such circumstances, the capsule may be entirely destroyed, as far as the deposits extend. (*Wedl, H. Müller.*)

Where there was no precedent inflammation, the cloudy masses clinging to the inner wall of the capsule are not usually extensive, and show themselves mostly as thickened cataractous substances. They consist of a granular, often clearly fatty, chalky basis, brown from the pigment in it, in which groups of lime-salts, and cholesterin crystals, and exceptionally of brittle, white plates of muriate of lime, and very rarely black (melanin?) crystals, &c., scattered about, or conglomerated to groups. Between them usually appear choloid bodies, and groups of thickened epithelium cells, which, by the addition of chalky salts, have acquired a dark, granular appearance. In places the epithelium still exists as such on the anterior capsule, even if far advanced in regressive metamorphosis. (*Wedl, H. Müller, Schweigger.*)

Where, on the other hand, inflammation has influenced the cataractous process, we usually find a more or less thick stratum thrust between the capsule and the secondarily metamorphosed cataractous mass, in which the disintegrated remains of lens-substance mingle with well-formed elements, that have undoubtedly originated from proliferation. The latter usually appear already altered by retrogressive metamorphosis, shrunken and strewn with fat and chalky salts. Sometimes the chalky salts are in such excess that the new formation has the character of a concrement.

On the posterior capsule these deposits are usually much less extensive than on the anterior, and are even absent in cases where very considerable deposits exist on the latter. Cases also occur where the anterior capsule is free, and the posterior largely covered by these deposits. Posterior capsular cataracts are occasionally combined with polar or vitreous cataract. As a rule, however, the deposit is intracapsular, and depends on the lens-substance. It then often appears as a simple retrogressive, thickened substance; but, much more frequently, no traces of cellular formation can be found in it, and it must be considered as a result of pure phakitis. (*Schweigger, Wedl.*)

The secondary cataractous changes are always accompanied by atrophy, as a result of which the capsule wrinkles, loosens from the lenticular fossa, so that the lens, with its envelope, may be easily removed from the vitreous. The extent of the diminution of size depends chiefly on the proportion of the constituents that have become soluble to those remaining insoluble, and thus ultimately on the density of the primary cataract. But the firm material of secondarily metamorphosed cataract must not be regarded as detritus. The process of resorption is not a pure removal, but a change of substance, in which the gain and loss of firm constituents

may incline to one side or the other. In fact, cataracts are met where the sum of the firm constituents is much greater than normal; that is, in which the secondary metamorphosis was evidently accompanied by an addition of firm material. But the process is also greatly influenced by the nutritive condition of the eye, and particularly of the lens.

a. Where the secondary metamorphoses are simply the expression of progressive atrophy of the original lens-elements, the insoluble remains are usually proportionately less; consequently the shrinking of the lens is very decided.

The secondary changes are least prominent, as may be readily understood in "overripe," mixed cataracts, especially when the sclerosed nucleus is extensive. The external layers are then deficient. Then the lens only flattens somewhat, and the capsule, thickened by newly-formed hyaline layers, and clouded by depositions of cataract masses, incloses the nucleus more tightly, being separated from it only by a comparatively thin stratum of fatty, sandy pulp, in which usually the chalk, rarely the fat, preponderates.

Occasionally this residue is so slight that it no longer forms a *continued* layer, but heaps, striæ, &c., between which the nucleus is almost in contact with the capsule, whose two halves approach so near, at the margin of the scleroma, that the cataract acquires the appearance of an alated seed.

Soft cataracts shrink very decidedly, as a result of secondary metamorphoses, so that finally they resemble discs, with irregular wrinkled surfaces, whose thickness is often less than a half or third of a line. These disc-like cataracts are usually quite flat, like a kind of partition-wall between the ciliary processes. Not unfrequently, however, they appear bulged forward like a cupola; the normal convexity of the anterior capsule is changed but little, and hence its relation to the pupil has altered but slightly. On the contrary, the posterior capsule, with the gradual diminution of the cataractous mass, has changed its curvature, and turned into the concavity of the anterior capsule, as the anterior wall of the vitreous has advanced on account of the corresponding increase of the vitreous (Fig. 17). In such cataracts, even with the naked eye, we may recognize the two halves of the capsule, thickened and clouded by newly-formed hyaline layers, and by deposits of secondarily metamorphosed lens-substance. The cataractous mass itself is usually a fatty, chalky pulp, with or without great concretions, in which sometimes cholesterin, sometimes lime, predominates in spots, and which, collecting here and there, sometimes causes irregular elevations on the surface of the cataract. Often, however, in disc-shaped cataracts, we find, as chief constituents, a half-transparent, yellowish or brownish, dry and friable (myeline?) substance, which causes these cataracts, when operated on, to split in all directions, and to be removed with difficulty, if at all.

Sometimes soft total cataracts become fluid, breaking up into chalky liquid, in which numerous very fine chalk-granules and fat are suspended, or deposited on the inner wall of the capsule as a delicate gauzy layer. This form is called *cataracta lactea*, *phakohydropsie*, or milk-cataract. It also appears to have been formerly described as cataracta cystica. (*Hasner.*)

Frequently these fluid cataracts, as well as the very soft cataracts of childhood, are, in the course of the secondary changes, absorbed, except a few fatty, chalky remains, so that the greater part of the two capsules is very nearly in contact. The cataract then appears as a more or less firm, tenacious, opaque membrane, which is stretched behind the pupil with its surface either flat or projecting anteriorly. It

consists of the two halves of the capsule, between which is inclosed a thin, irregular layer of retrogressive cataract-substance. From their resemblance to dried seed-shells these cataracts have been called *cataractæ siliquatæ*, and have been distinguished from the above-described disc-like cataract by the term membranous.

It is evident that the three described forms are only the representatives of a series of differently composed cataracts, which must be considered as transitions from one kind to another. Thus, disc-like cataracts occur, which contain a small sclerosed nucleus; membranous cataracts, in which the cataractous substance so collects that they resemble the disc like form, &c. Moreover, the development of the forms of cataract in question presupposes that the zonula has retained its integrity. If this has been considerably torn before the commencement of the cataractous process, or during the secondary changes, the shrinking of the cataract no longer occurs exclusively in an *antero-posterior* direction, but also *laterally*, and the shape of the cataract is thus greatly modified.

b. If the development and the secondary metamorphoses of the cataract have been influenced by inflammation, a *diminution* of size, and a corresponding wrinkling of the capsule, may occur, on account of the great addition of firm constituents, but the decrease is never so decided as in the forms of cataract described under *a*. Usually the two surfaces of the cataract simply *flatten*, while the equatorial diameter somewhat shortens, without the lens-form being entirely lost. (See Fig. 34.)

On the contrary, with shortening of the equator, and corresponding tension of the zonula, the two convexities of the crystaline are often increased, and the edges of the lens rounded; the cataract acquires a more spherical form. If, however, the zonula be ruptured, the cataract not unfrequently shrinks to a quite irregular mass.

In these cases, also, the chief mass of the cataract appears to be fat and chalk. Exceptionally, the fat predominates, the cholesterin crystals heap up, especially on the surface, and unite even to a continuous layer, which glistens through the thickened and opaque capsule with a peculiar mother-of-pearl or silvery-like lustre (*cataracta argentea seu cholesterinica*). As a rule, however, the chalky salts greatly predominate. They frequently form shell-like concrements, whose extent and thickness vary greatly, and which are attached to the inner wall of the capsule. These shells are found sometimes on the anterior, sometimes on the posterior half, but usually on both halves of the capsule. In the latter case they usually unite at the edge of the lens, and thus form a sort of case, inclosing a more or less irregular cavity, which is filled either with a fatty, chalky pulp, with or without concrements, or with a sclerosed nucleus (chalky cataract, *cataracta calcarea*). Sometimes, however, it stops at simple thickening and cloudiness of the capsule; no actual shell is formed, at most, there are only small chalky masses, which partly cling to the capsule. Then the cavity is found filled with a dry, fatty, sandy pulp, which either envelops a nuclear cataract or a number of smaller and larger, or one large concrement (fatty, chalky cataract).

Under such circumstances it is not at all rare for a thick layer of hard, firm connective tissue to develop on the inner wall of the capsule. Under the influence of the developing cell-layer, the whole cataract may undergo a change. Then the cataract, which is always flattened, looks as if formed of coagulated albumen or cartilage (*cataracta fibrosa*). Usually, however, the connective tissue forms a sort of closed capsule, which usually contains fatty, chalky, cataract pulp, with several large stone-like concrements or sclerosed nucleus (*cataracta fibroso-calcarea*).

In very rare cases, an oily fluid, of penetrating, rancid odor, has been found in the cavity (*cataracta cum bursa ichorem tenente, cataracta putrida. A. Schmidt, Beer, Himly.*)

Subsequently, especially when bony strata have formed on the surface of the choroid, and in the hardened vitreous, the fibrous cataractous mass ossifies (*cataracta ossea*).

Then, along with chalk-granules, bone-corpuscles appear in the tissue. Strange to say, the ossification does not begin on the periphery. The layers next to the capsule preserve their original character, so that the bony case remains separated from the capsule by a connective-tissue layer. Only where the outer surface of the capsule touches directly on the newly-formed bone, the osteoid cataractous mass reaches to and unites with it, while the interjacent capsule is destroyed.

In the face of actual observations, the doubts which have been raised of the possibility of an ossification of the lens (*Virchow, Pagenstecher*), are of no great importance (*R. Wagner*).

5. The entire lens is not always drawn into the cataractous process, but this is often limited to certain parts of the crystaline. These degenerate, and, by secondary metamorphosis of the cataractous mass, assume permanent forms, while the rest of the lens remains normal, preserves its transparency, or at least does not join in the process for years. Such cataracts are called partial, and are divided into various classes, according to their position, shape, and size.

a. A very characteristic variety is the so-called central capsular cataract. It is occasionally congenital. As a rule, however, it is developed after birth, when, as a result of a corneal perforation (*Piringer, Arlt*), or of an iritis (*Hasner*), clumps of exudation have remained attached to a part of the anterior capsule behind the pupil, and have become permanent there. The portion of cell-layer behind the deposition and the superficial layers of the lens then become clouded to a corresponding or greater extent, from pure atrophy, or from actual change of tissue, and, shrinking greatly, are changed by secondary metamorphosis to a cartilaginous or chalky nodule, as large as a poppy or millet seed, which is firmly attached to the inner wall of the anterior capsule, and lies embedded, as it were, in an excavation in the surface of the crystaline.

Under such circumstances, instead of a roundish *nodule*, an irregularly-shaped cone is often formed, whose posterior, often bulbous, end, extends more or less deeply, sometimes even beyond the level of the equator, into the transparent lens. The anterior end usually projects beyond the anterior curve of the crystaline, and so elevates the anterior capsule, to which it adheres almost inseparably. As a consequence of this, and of the circumstance that the lens has often greatly decreased in size, the anterior capsule, in the vicinity of the cone, usually appears arranged in small, mostly radiated, *folds*. This variety of central capsular cataract is called pyramidal cataract (*cataracta pyramidalis*, or *pyramidata*).

In examining such a plug, which has been unfortunately detached from the capsule, it has been found that it was devoid of a capsular covering upon its anterior surface, and was composed entirely of plates of neoplastic, opaque lens substance, stratified in a parallel direction upon each other. It had exactly the appearance as if the plug had grown forth from the lens substance through a hole in the capsule (*Singer, Wedl*). This is probably an exceptional case, and the plug perhaps the remains of the neck of the fœtal lenticular sac. This case might then be connected with certain others, in which the pyramid projected into the anterior chamber far beyond the anterior surface of the capsule, or was even already united to the cornea (*Steffan*), and in which the reference to that arrest of development cannot for the present be disputed. As a rule, however, the plug is situated upon the posterior wall of the anterior capsule, and consists, as was mentioned, of retrogressive products of inflammatory growths and of the simple process of cataractous development, which also, as a whole, explains the usually accompanying increase of volume and change of form of the lens.

Cases are also worthy of mention on account of the widely deviating pathogenetic relations,

in which, with complete transparency of the posterior half of the lens, the anterior half has almost completely disappeared, so that only a number of sharply-defined calcareous nodules remained, which, embedded in the pellucid mass of the lens, were attached to the greatly-flattened anterior capsule, and, as far as they lay in the region of the pupil, gave exactly the impression of central capsular cataracts. In a similar manner, the recently observed case of a double pyramidal cataract is perhaps to be explained (*Mauthner*).

b. Frequently in young persons we meet lenses, in which one deep layer in both halves, or very exceptionally only in the anterior or posterior half, has become cloudy, and has, perhaps, already undergone secondary metamorphosis, while the rest of the lens preserves its transparency, or only becomes engaged in the process after years. Occasionally, in otherwise pellucid lenses, we find two or three different and distinct deep bundles of filaments in a state of cataractous degeneration. (*D. E. Müller*, *Graefe.*) Such partial cataracts have been called laminated cataracts. They almost always occur simultaneously in both eyes, rarely in one eye only, and corresponding layers in both lenses are usually affected in an analogous manner. (*Ed. Jaeger*, *Graefe.*) In most cases, the opacity is throughout almost regular; with favorable illumination we may at most recognize the radiated arrangement of the fibres by a delicate striation. The cataractous stratum is usually sharply bounded on the one hand from the superficial layers (remaining pellucid) which cover it, and on the other from the transparent and usually yellowish nucleus. In other cases only the parts near the equator show the cataractous degeneration. Then the border of the transparent lens appears, as well anteriorly as posteriorly, girdled by a more or less broad, opaque zone, which runs out on each side in zigzags toward the pole of the layer, more rarely ends in an indistinct cloudy or finely-striated border. There is scarcely a doubt that the latter form represents an incompletely-developed laminated cataract, and that, as a rule, the entire layer is cataractously degenerated before the secondary changes become marked.

But when this has once occurred, the anatomical appearances greatly change. As the soluble constituents are absorbed, while the fatty, chalky remains are more and more thickened and contracted, the former regular opacity becomes pitted, the cataractous layer is full of cavities. At the same time the lens, as a whole, flattens decidedly. Besides, the equatorial diameter shortens, while the zonula stretch, so that the distance of the margin of the lens from the heads of the ciliary processes is evidently increased. (*Graefe.*)

Cases exceptionally occur, in which the affection proceeds from the cataractous strata to the structureless axis-substance of the lens, thus forming, as it were, an opaque cone, which reaches through the lens from one half of the layer to the other. More frequently the whole nucleus is destroyed and absorbed, except some fatty, chalky lumps; these remain in the middle of the flattened lens (*Ammon*, *Pilz*, *D. E. Müller*, *O. Becker*).

c. Frequently, also, in young persons, a great part of the lens is cataractously degenerated and secondarily metamorphosed, while the rest remains transparent. The anterior half of the lens is often destroyed to a thin, fatty, chalky stratum, without the posterior half participating in the process. Seen from before, the cataract then has the appearance of a cataracta siliquata, and only on closer examination do we find the extensive stratum of transparent, but usually yellowish and gelatinous, lens-substance, which clings to the opaque, wrinkled, and flattened anterior capsule, and separates it from the posterior. In the same way the posterior half of the crystaline may be destroyed, while the anterior remains apparently normal. It also occasionally happens that a lateral half of the lens becomes cataractous, and, with secondary changes of the substance, shrinks to a small body, while the other lateral half maintains its integrity. The lens then usually acquires the shape of a kidney. On the hilus side the wrinkled capsule appears clouded with

fatty, chalky cataractous residue. The zonula, corresponding to the sinking of the hilus, is decidedly widened, and usually opaque from depositions.

Rarely, quite irregular portions from the body of the lens are affected in the process, and, by partial resorption, changed to fatty, chalky, or tendinous masses, which appear encased in the flattened, but otherwise pellucid, lens. (*Graefe, O. Becker.*) Posterior capsular cataracts belong in this class.

Symptoms.—*Cataract is characterized by a more or less complete opacity, seen a short distance behind or in the pupil, which more or less impairs vision according to its thickness and extent.*

A. In the opacity, the various changes that the cataractous lens-elements undergo are quite clearly reflected by peculiar tones of color, of brilliancy, varying degrees of translucency, &c., so that, from the special variety of the opacity, the particular anatomical form of a given cataract may be decided with some certainty.

1. *a.* Nuclear cataract shows itself by a diffuse cloudiness, which, following the anterior surface of the nucleus, spreads out behind the pupil with a greater or less curvature. This opacity is thickest at the center, and diminishes toward the edge, where much of the incident light is allowed to pass. The color of the opacity is usually grayish-yellow or dirty brownish-gray; sometimes reddish-brown or green, rarely bronze-like, dark brown or blackish. The distance of the opacity from the plane of the pupil is always considerable, and is greater in proportion to the stratum remaining pellucid—that is, the smaller the sclerosed *nucleus*. This distance permits us to see between the opacity and the pupillary margin, and, by good illumination, to see the shade cast by the iris in the shape of a dark crescent.

On weak illumination by the ophthalmoscope, the nuclear cataract appears as a roundish, dark cloud with indistinct borders; on stronger illumination, the red of the fundus shows through, but its individual parts can not be distinguished; the fundus appears enveloped in a more or less thick mist, which, in the middle of the visual field, often concentrates to a dark cloud. The color, convexity, boundaries, relative position to the pupillary margin, &c., appear most distinctly by oblique illumination, when the pupil is dilated. By this means we may easily recognize the border of the hard portion, and can estimate its distance from the heads of the ciliary processes; hence also we may see the extent of the cataract. Then a more or less pronounced arcus senilis of the lens usually appears at the margin.

b. If, by oblique illumination, we find the outer periphery of the lens cloudy or striated, if the distance between the opacity and the heads of the ciliary processes be reduced to almost nothing, a pure nuclear cataract no longer exists, but the cortical layers are involved; there is a mixed cataract. On further development the cloudiness continually passes from the edges toward the pole of the superficial strata, till, finally, these appear cloudy throughout.

As long as the elements have not entirely lost their original form, the cortical substance remains translucent, bluish-white. With the naked eye, but still better by oblique illumination with a lens, we may then recognize in the diffuse opacity a radiated striation, corresponding to the course of the filaments, or a number of points and cloudy, indistinct spots.

If the striæ (which often unite to triangular zigzag figures) are very small, line-like, whether clear white and opaque or diaphanous and bluish, we may consider it probable that the cortical layers have maintained a nearly normal consistence. This is also true if there be none of these striæ and the opacity is undecided, and the points and spots not very prominent. Broad, blue, sparkling striæ under the capsule, which are not entirely opaque, and have between them translucent sectors, or parts of lens sprinkled with coarse gray spots, as well as great opacity with thick points and spots, are considered as signs of a more gelatinous or starchy consistence of the cortical strata (*Graefe*).

If the opacity becomes thicker, the outlines become more blurred, so that, to the naked eye, the cataract finally appears regularly white, or yellowish and opaque. If, moreover, the opacity extends to the pupillary margin, so that the shadow cast by the iris entirely disappears, we may diagnosticate a very probable decomposition of the cortical layers into pulpy or fluid substance. Then the nucleus generally loses its influence on the coloring of the cataract. It requires focal illumination and a very small angle of incidence for the concentrated light to cause the nucleus to shine through.

In some cases, where the cortical layers are very rapidly destroyed, a sort of swelling up, an increase of size as a result of extensive additions from without, appears to take place. We decide that this is the case, from the fact that, under such circumstances, the anterior convexity of the lens is uncommonly great, and it drives the iris before it, as it were, thereby greatly contracting the anterior chamber.

c. If secondary metamorphoses occur in the cortical part of the cataract, the products attached to the inner wall of the capsule immediately show themselves on the surface of the cataract. Scattered, bright, opaque, chalk-like spots of variable size occur, which subsequently heap up, unite to clumps, striæ, &c., and give the cataract a spotted, marbled, net-like, or striated appearance. Not unfrequently cholesterin crystals glisten from between them. Besides, we often find, especially in the pupillary region, tendinous-gray or yellowish-gray, dull, glistening, somewhat translucent, striæ and spots of irregular form, with sharp, fringed, or cloudy borders. These products are more clearly seen, especially by oblique illumination, as their formation is usually accompanied by a very decided decrease of the cortical substance, and hence by a returning transparency of the lens.

Indeed, when the secondary metamorphosis is far advanced, we may often perceive the nucleus very clearly, or bring it into view, by having the patient bow his head forward for a few minutes. Then it is not always found exactly in the middle, where the cortex is very soft; it is rather apt to sink downward. In some cases the resorption of the cortical layers is so complete, that the sclerosed nucleus appears to be covered only by a very thin veil strewn with chalk-points and cholesterin groups.

The decrease in size of the crystalline shows itself, moreover, by the withdrawal of the slightly-wrinkled surface of the cataract behind the plane of the pupil, and by the return of the shadow which depends on this state. As the iris is deprived of its natural support by the flattening of the cataract, we have that very characteristic tremulousness (irido-donesis), which is especially evident when the eye is rapidly moved laterally.

d. If severe inflammations have participated in the process, we often find, on the outer walls of the anterior capsule, extensive depositions of new-formations which completely cover the cataract. At the least, the capsule appears united with the pupillary margin to a great extent, so that only the middle part of the cataract can be seen.

This usually appears chalky-white, opaque, with a dull luster; it gives the impression of a solid chalky concrement, with a glass covering. More rarely, it resembles tendinous tissue, with or without chalky depositions. Exceptionally, its surface glistens like a mother-of-pearl button, from predominance of cholesterin.

2. If possible, the appearance of *soft* cataract varies still more, according to the course and stage of the process.

a. If the cataractous degeneration begins in the nucleus, we find, at some distance

behind the pupil, a diffuse or spotted, rarely striated, whitish-blue opacity, convex anteriorly. This opacity is thickest in the center of the "soft cataract;" toward the periphery, however, the translucency, and hence also the bluish color, increases. The boundary is nowhere quite sharp; as well on the convex surface as at the border, the opacity becomes a delicate cloud. The cloudiness increases in proportion to the progress of the process; it becomes clear white or yellowish-white, and almost opaque, while its bluish borders continually approach the capsule and diminish the shadows from the iris. Then the cortical layers commence to degenerate at the equator, the nucleus is gradually hidden by diffuse or broadly-striated opacities, which extend from the outer margin of the lens toward the pole, and a total soft cataract now exists.

b. But if the soft cataract begins as a cortical cataract, a bluish-white, slightly glistening, often interrupted, zone, usually first appears at the periphery of the surface of the lens; of course, a dilated pupil is necessary for its recognition. This more or less wide zone often appears indistinct. More frequently, however, as well on the anterior as on the posterior surface of the lens, it runs out in bluish, glistening projections, which gradually widen and elongate in a meridional direction, so that they finally appear in the plane of the pupil. Sometimes the substance between the filaments appears transparent, and the stellated figure of the superficial lens layers are, at least in places, clearly perceptible. Usually, however, the cortical portions between the projections are also cloudy, and parts of the projections shade off into clouds and spots. Finally, the entire lens-surface loses its transparency. As long as the nucleus preserves its pellucidity, the opacity appears thinner at the center, and bluish; at the edge, however, very white or whitish yellow, and almost opaque.

In some cases the equatorial parts of the external layers remain for a long while transparent. We find on the anterior, but more frequently on the posterior half, or both halves of the cortical strata, some spots, points, or radiated striæ, which gradually increase in number and extent, and subsequently unite at the poles, and especially at the margin of the lens.

In rare cases, the opacity of the cortical layers begins in the middle; some or all of the rays of the star shaped figure become bluish-white, and hence become distinct from the still transparent surrounding parts. Occasionally the process goes on first in the deeper layers of the stellate figure, so that it appears as if the lens were divided into a number of sectors, which unite near the axis and are perpendicular to the surface (*cataracta stellata*). The process does not attack the superficial bundles of filaments and the nucleus until later.

c. In soft total cataract, the symptoms of the cortical cataract are combined with those of soft nuclear cataract. The opacity is densest at the center; on the periphery it is more diaphanous. On the one hand it extends to the heads of the ciliary processes, on the other to the plane of the pupil; occasionally it even projects beyond it. Where cataract of this kind develops rapidly, a sort of inflation, an increase in size, occurs, showing itself by greater anterior curvature of the iris, and consequent diminution of the anterior chamber.

Total soft cataract often retains a certain amount of transparency until the stage of secondary metamorphosis, or even after this; and, with oblique illumination, we may still quite clearly make out the filament bundles as radiated striæ. These are the cases where the lens-elements do not lose their form entirely, but the cataractous layers rather preserve a nearly normal consistence, or, when operated upon, appear pasty.

But if the destruction goes further, at least in the cortical portions, if the lens-

substance dissolves to actual pulp, or to a fluid, these different shades of color gradually disappear; we at most recognize, by oblique illumination, thick, white points and small flocculi; to the naked eye the opacity appears almost regularly white or yellowish-white. The shade of this color depends principally on the greater or less thickness of the cataractous remains, and the variable amount of the fatty contents.

The color is also influenced by the circumstance that, while the eye is quiet, the denser flocculi suspended in the fluid occasionally sink; consequently the lower part of the cataract appears almost opaque and pure white, but the *upper* part whey-like, bluish-white and translucent.

The possible existence of a still undisturbed pellucid, or already cloudy, or even sclerosed, nucleus, is then usually betrayed by no outward symptoms; it can only be suspected, with some probability, from the age of the individual, but can not be diagnosticated with any certainty, as quite fluid cataracts do occur after puberty.

d. The occurrence of secondary metamorphoses in soft total cataract shows itself by the same symptoms as in mixed cataract. The various appearances which the fatty, chalky, or tendinous products cause by their disposition on the inner wall, are important here. In soft total cataract these depositions are usually somewhat more extensive than in mixed cataract, as they are mostly composed of broken-down cataractous substance. But this very fact is the reason for their being at first less prominent, and only being noticed when the cataractous pulp has been so much diminished by resorption that the dark fundus can again show through. A second important diagnostic factor is the removal of the lens-surface behind the plane of the pupil, the recurrence of a shadow, and the tremulous iris. Where these symptoms are very evident, we may be certain that the cataract is much shrunken. In the opposite class of cases, where the surface of the cataract is decidedly convex, and shows very slight wrinkles, or none at all, the existence of a shrunken cataract is not impossible, as even disc-like and dry capsular (*trockenhülsige*) cataracts are not unfrequently pressed forward by the vitreous. Then, for a correct diagnosis, besides these appearances on the surface, we must consider the age of the patient, the time the cataract has existed, and its translucency.

When the pupil is dilated, disc-shaped cataracts often show a very irregular, dentated, or angular border, and, therefore, are at some points quite distant from the ciliary body. They are frequently regularly chalky-white, and entirely opaque. Just as often, however, they have a tendinous, cartilaginous appearance, and, corresponding to this, are but slightly diaphanous, so that the fatty, chalky depositions on the inner wall of the capsule are quite noticeable from their bright color and opacity. Finally, the disc-shaped cataract is not unfrequently transparent when of a peculiar dirty, yellowish-gray, bordering on greenish or brownish. Then we usually find on the surface bluish-gray spots, with a dull tendinous brilliancy. Such cataracts are usually very friable.

Dry capsular cataracts are always, from their thinness, rather transparent. Their chief color is bluish-white, and the blue or white appears more prominent according to the amount of cataractous remains. The various figures which the chalky concretions, cholesterin groups, and fibrous masses attached to the inner wall of the capsule produce, appear very distinctly on the cloudy, bluish-white ground. It is an important fact, that the cataract usually reaches to the ciliary processes, and the opacity is often thickest at the outer border of the flattened cataract, since the fatty, chalky products collect, as it were, in the fold of the capsule, and give it the appearance of a roundish cushion, which surrounds the cataract like a wreath. In partial

cataract, such a chalky border rarely occurs. It is peculiar to the cataracts siliquata.

c. Where soft total cataract is developed, and undergoes further changes under the influence of severe inflammation, its symptoms are the same as those of mixed cataract, occurring under similar circumstances. The portion of cataract behind the usually distorted pupil, if not covered by iritic products, generally appears evenly chalky-white and opaque, more rarely tendinous or cartilaginous, exceptionally of a mother-of-pearl luster, in which case we are restricted to the diagnosis of a cataracta calcarea, fibrosa, argenta, &c. If the iris be drawn backward (perhaps even to a funnel-shape), we may decide with considerable certainty on a shrunken cataract. If, however, the iris has lost but little of its normal convexity, or if it be pressed against the cornea, we must draw our conclusions, as to the size of the cataract, mostly from the age of the patient.

3. *a.* Of the partial cataracts, the most difficult to recognize are those in which the anterior cortical layers, or the entire anterior half of the lens, has been destroyed in the process; for in the first stages they have exactly the symptoms of cortical cataract, but later they nearly resemble a dry capsular cataract. In diagnosis we may remember the circumstance that, in such partial cataracts, the outer border is usually less clouded, and at all events lacks the chalky cushion of a cataracta siliquata. Where a lateral half or an irregular piece from the body of the lens becomes cataractous, the diagnosis is not difficult, as the anatomical changes are perfectly evident.

b. When fully formed, the laminated cataract very much resembles soft nuclear cataract. Still, when pure, it is easily distinguished by the fact that the usually delicate and bluish-transparent, often, however, thick and white opacity does not increase toward the pole, but is apportioned almost regularly, and is indeed rather more dense at the margin. A second important difference is, that the opaque layers, as well on their anterior surface as at the equator, are sharply bounded from the superjacent pellucid strata, as long as the cataract remains stationary; thence, from a cloudy or striated opacity of the superficial layers, we may conclude that there is a progress of the process, a change from a laminated to a soft total cataract.

These circumstances are especially evident on ophthalmoscopic examination. When the light falls perpendicularly, the cataractous stratum appears as a circular, sharply-bounded, dark spot, through whose center the fundus appears red, and past the edges of which the retinal vessels, &c., may be distinctly seen. But the peculiarities of laminated cataract are best seen by oblique illumination. The margins of the superficial pellucid strata then present themselves as a broad, dark, ring-shaped zone, which is placed between the heads of the ciliary processes and the equator of the cataractous layer, and is very distinctly defined by its black color.

If all this has been carefully noted, there is no difficulty in recognizing laminated cataract as such, at its very commencement—that is, when it is still a diffuse, cloudy zone, striated, and pointed in a radiated direction, which, from its sharp, peripheral margin, extends more and more toward the two poles of the layer.

There can be just as little doubt, in diagnosis, when the cataract is already affected with secondary changes, when the opaque laminæ begin gradually to separate, and the pellucid lens again appears through the fissures and interstices. Then we usually find at the anterior pole of the affected stratum a number of chalk-like points, which are variously grouped, sometimes forming a star-shaped figure. They lie in the midst of a delicate, bluish, web-like zone, strewn with irregular striæ and

white points, which thickens gradually toward the edge of the laminæ, so as only to show small openings, and finally is sharply bounded. As a rule, the diameter of the lens is diminished under such circumstances. The outer pellucid border appears distorted at some places, and is at a considerable distance from the heads of the ciliary processes, while the diminution in size of the crystaline is also shown by the tremulous iris, and by the retrocession of the anterior capsule behind the plane of the pupil.

c. Central capsular cataract presents itself as a chalky white or cartilaginous-looking nodule, as large as a poppy or hemp-seed, rarely larger, which lies in the plane of the pupil, and strongly contrasts with its blackness. Sometimes it is quite sharply bounded, sometimes surrounded by a cloudy, indistinct, bluish halo. This halo may be distinctly perceived by oblique illumination, often even when, to the naked eye, it appears to be absent. Frequently we see a small spot of iris-pigment on the summit of the nodule, and around it a radiated wrinkling of the capsule.

Rarely there are two or more such deposits in the pupil, and then the central capsular cataract is often only the remains of partial cataract, spread over the whole anterior surface of the lens, and secondarily metamorphosed.

If the nodule be elongated posteriorly, like a cone (*cataracta pyramidalis*), it is, of course, the more marked. Then it often projects beyond the plane of the pupil, or even extends like a horn into the anterior chamber.

B. The disturbances of vision accompanying cataract result partly from the diffusion and absorption of the light in the lens-substance, which has become irregularly refractive, and partly from the varied curvatures which the two surfaces of the crystaline so frequently undergo.

The disturbance of vision, dependent on diffusion and absorption, are nearly the same in cataract and corneal opacities.

Still, other things being equal, much less dispersed light will be thrown on the central portions of retina from cataractous opacities. This difference is especially evident in slight obscurations, and particularly in those confined to individual laminæ. This is not only because peripheral opacities of this class (as in commencing cortical cataract), are entirely covered by iris; for *central* opacities, also, interfere with vision far less than equally thick and extensive corneal opacities.

It must here be remembered, that much of the diffuse light falling on the eye from the side is thrown off by the reflecting and strongly-convex surface of the cornea, so that it does not reach the lens; but especially that, under ordinary circumstances, the larger half of the crystaline is covered by the iris, which acts as a perforated diaphragm, as well as that the surface of the lens has a much less curvature than the cornea. The diffuse light, passing the lateral portions of the cornea, and already weakened, strikes the middle of the anterior surface of the lens at a great angle, hence loses much of its intensity by reflection, and can only throw a weak spectrum of light on the anterior zone of the retina. But light coming from directly in front, falling nearly perpendicularly on the lens, undergoes a proportionately slight dispersion, and passes through, almost without being weakened; hence it can form sharp images of great apparent brilliancy on the retina.

Indeed, patients affected with unripe nuclear or laminated cataracts make out large objects at a moderate distance quite well, and usually read large type without hesitation (although not for a long while), especially when faulty adjustment of the dioptric apparatus is neutralized by suitable spectacles, and diffuse light avoided as

much as possible, and when the pupil is enlarged, on account of slight illumination of the visual field. Even cortical cataracts, extending beyond the pole of the lens, do not necessarily render it impossible for the patient to go alone, and in iritic depositions on the anterior capsule, even when the pupil is entirely closed, and the portion of the lens-surface bounded by it is entirely covered, we are often astonished at the sharpness of vision. The disturbance of vision is particularly slight, when the natural diffuse light is cut off, and the object is well illuminated. Hence, patients shade the eyes as much as possible, and try to bring the object in a good light; they usually carry the head down, find dark glasses and broad eye-shades advantageous, and greatly prefer twilight and cloudy days.

In thick and extensive cataractous opacities, but especially where a number of laminæ are affected, these advantages are more than balanced by the increased absorption of light, that is, by the diminution of the apparent brilliancy of the retinal images. In cataracts limited to the nucleus, in ripe, hard, and soft nuclear cataracts, in certain partial cataracts, this loss may be annulled, to a certain extent, by dilatation of the pupil, that is, by exposing the pellucid periphery of the lens to the direct light. Thus, at least the lateral portions of the visual field will be clearly perceived; but when the cloudiness has advanced near to the edge of the lens, as is the rule in ripe cataracts, external objects are no longer distinctly presented on the retina, and the diameter of the pupil only influences the greater or less illumination of the spectrum. Under ordinary circumstances, this usually appears to the patient as a whitish or yellowish mist, which, in pure, highly-colored nuclear cataracts, is sometimes brown, spread regularly over the whole visual field. If there be only direct light, if the patient look from a dark place at a bright candle-flame, the moon, &c., he sees a bordered spectrum of roundish or oval form, with bright edges and dark center, on account of the thickness of the lens increasing toward the pole. The weakening of the light falling on the retina, thus caused, is really very decided. This is most clearly explained by the dark shadows which partial cataractous opacities, i. e. small sclerosed nuclei, central capsular cataracts, striæ of commencing cortical cataracts, &c., under favorable circumstances, throw on the retina, and which the patients perceive, as scotomata. These are most distinctly perceived by the entoptic method of examination. (See *Scotoma.*)

In view of this symptom, the fact that cataractous opacities, lying in the region of the pupil, cut the already convergent rays of light in a smaller diameter, is of great importance, since, with an equal extent, it will weaken them far more than a corresponding corneal opacity. To this must be added the fact, that the formation of cataract is almost always accompanied by a diminution of accommodation, and by a false state of refraction of the dioptric apparatus, so that the shadows caused by the opacities of the lens have a considerable diameter when they fall on the retina.

Hence, in nuclear cataract, not only is the accommodation influenced, but a high degree of hypermetropia occurs from flattening of the lens. In soft cataracts, on the contrary, a myopic condition may occur. Indeed, this is frequently observed in laminated cataract (*Donders*), and depends sometimes on congenital malformation of the globe; sometimes it is developed, and is explained by the circumstance, that the object must be held unproportionately near to the eye for sake of clear vision. In shrunken cataracts of all sorts, the dioptric apparatus is, of course, adjusted for negative distances; but the wrinkling of the capsule, dependent on the decrease of the lens, shows itself by decided distortion of the spectra.

In central capsular cataract, besides the frequent diminution in size of the crystaline, the wrinkling of the portion of capsule covering the nodule is a source of decided visual disturbance.

Complications.—The most important are the material changes in the deep, vasco-

ation of the ciliary vessels in the episcleral tissue, decided increase of the anterior chamber, atrophy of the iris, immovability or slug-raction or dilatation of the pupil, &c. Still, one or more of these r be present without amblyopia, amaurosis, or other incurable alteration sensitive to light existing, and *vice versa*. Very often, morbid pro-affecting the organization of the parts in question (for instance, pure mation, detached retina, inflammation of the optic nerve, exudative .), occur without changes in the external parts of the globe during eir course. Moreover, such disturbances of function often result from ors of development, among which congenital cataract is particularly to . In monocular cataracts, developed in childhood, the complicating not unfrequently simply the result of continued disuse of the eye. ny of these complications are of great, even of all-important, influence osis, it is imperative, in a case of cataract, and particularly before examine not only all objective symptoms, suggesting changes in the of the eye, but also the subjective symptoms, especially the amount the sensitiveness to light. This is particularly necessary where an ped capsular cataract exists.

judge the functional activity of the parts sensitive to light solely by the action should be in danger of error of diagnosis in not a few cases; for not unfre-liary margin is fixed by posterior synechia, and, on the other hand, the sensitive-y be considerably diminished, without the reaction of the pupil appearing much ange of light.

stworthy conclusions on this point are to be drawn from the distance at which a an perceive the light of a small lamp in a darkened room. As a general rule, in otal cataracts, where the diffusion of the incident light is complete, the light of clearly perceived at a distance of fifteen feet or more. We may easily satisfy point, by alternately shading and exposing the light. In unripe cataracts, fully-ataracts, laminated cataracts, as well as in cataracta discoidea and siliquata, the arse greater, if the other parts of the eye be normal; for in these, more direct ough, and concentrates to a spectrum of greater apparent brilliancy. If the rrors of dioptric adjustment be removed by proper glasses, and the spectrum the distance at which the lamp is perceived may be considerably increased. If, amblyopia exist, this distance is much less, and it is the shorter, the higher the nal disturbance.

retrogressive fluid cataracts, even prompt quantitative perception of light does t ground for a favorable prognosis; for such cataracts are very thin and translu-re interrupt but little light. The patient should be able to distinguish large can exclude functional disorder of the retina. Indeed, such patients can occa-sh even small objects. (*Graefe.*)

lored spectacles is serviceable in such cases. They are to be held before the eye on. From the power of distinguishing various colors, and particularly various me color, very certain conclusions can be drawn as to the grade of functional tina and optic nerve.

9

We will occasionally discover limitations and interruptions of the visual field, if we move a lighted candle or wax taper to and fro near the eye, and note the point at which the light is feebly, or not at all, perceived.

It is also well to observe the *subjective* symptoms which often accompany inflammatory processes of the deeper parts of the eye. But we must bear in mind that cholesterin crystals existing in cataract remains, under suitable illumination may cause similar phenomena—sparks, colored rings, &c. The circumstance that such subjective symptoms only occur in bright light, and are independent of the circulation of the blood, easily distinguishes them from the symptoms of morbid retinal excitement.

Causes.—1. Cataract is usually developed without apparent local cause.

a. The process often begins before the commencement of involution of the body, in manhood, youth, or childhood. Not unfrequently it is even congenital (cataracta adnata), and is then often accompanied by some malformation of the eye-ball, myopia, mikrophthalmia, &c., and the consequent functional disturbances of the deeper parts of the eye, particularly of the retina. In many cases it is seen to be hereditary; still, parents without cataract sometimes have children, all or most of whom have cataract either occurring in early life, or congenital. (*Hasner, Froebelius, Schön.*)

The immediate cause is supposed to be a faulty development of the lens, which prevents the elements from long maintaining themselves at the hight of evolution, and causes their premature destruction; a proceeding that is analogous to the early fall of the hair and decay of the teeth.

The most common form of cataract during youth is the laminated. It occurs more frequently than all the other forms together. Next to it in frequency are soft and fluid total cataracts, with their various secondary changes. Spontaneous soft nuclear cataracts, and other partial cataracts, are very rare.

In a very large percent. of cases, laminated cataract is encountered along with disease of the brain and its membrane, with rachitis, Hutchinson's teeth, hydrocephalic shape of the skull, and often also with imperfect mental development. Hence, many think it depends on functional disturbance of the brain, as it is thought that by temporarily changing the general nutrition, this affects secondarily the development of the lens-filaments and the enamel of the teeth. (*Horner, Davidson.*) Others maintain that laminated cataract always comes after birth, and that great agitation of the lens in convulsions, whooping-cough, &c., are the immediate cause. (*Arlt.*)

On these hypotheses it is difficult to understand why the cause should act solely on the layers next to the nucleus, while the others remain unaffected. For the supposition that the filament layers composing the laminated cataract form after birth, and at the time the cataract is developed, is false; since, in extra-uterine life the lens increases in an equatorial, not in a sagittal, direction. But there is no doubt about the perinuclear strata alone becoming cloudy; this is shown objectively in the development of arcus senilis of the lens. This last fact has been used to prove the relationship of laminated and nuclear cataract. (*Förster.*) The formation of perinuclear cataract has also been observed as a result of iritis or of dislocation of the lens. (*Graefe, Hirschmann.*) The connection between laminated cataract and brain-disease, which is clearly proved by statistics, may originate in fœtal life, and only the incipient stage of the former may exist at birth, and may be developed by any thing affecting the nutrition of the lens. The decided frequency with which laminated cataract occurs in congenital and spontaneous luxation of the lens, as well as its always affecting both sides, incline to this view.

b. In the great majority of cases, however, cataract does not occur till after the forty-fifth year, after the commencement of general involution; hence it is considered as especially a disease of old age. Men are affected in a larger per cent. than women. It seems, that atheromatous degeneration of the vessels in the anterior portions of the retina and in the choroid (*Mooren*) here play a very important part.

At any rate it is very worthy of notice, that senile cataracts and œdema of the retina are so very frequently found united. The latter, however, chiefly originates from those degenerations of the vessels (*Iwanoff*).

c. It is possible, that a dissolute life, excessive anxiety lasting for a long time, the cachexia of drunkenness and intermittent fever, poverty of the blood (*Mooren*), etc., should be reckoned with the more remote causes of cataract, or, at least, hasten and favor the appearance of the cataractous process. It has also been observed, which agrees with this view, that cataractous individuals below the fiftieth year of life are very frequently weakened, wretched, decayed, sickly people.

Such an etiological connection certainly exists between cataract and diabetes. A remarkable percentage of diabetic patients are cataractous, and this takes place at a time of life when the occurrence of cataract is, under other circumstances, very unusual (*Lecorché*).

It is not the presence of sugar (*Carius*), or the acidity which has been asserted to occur, in the dioptric apparatus, that chemically causes the destruction of the lens, but the great affection of the whole body, which, like the premature senility, shows itself also in the lens. This cataract, therefore, is only seen in high degrees of diabetes and in the advanced stages, when the body is much debilitated, and it often occurs when the production of sugar is much diminished (*Lecorché*).

Cataract in diabetes has no anatomical peculiarities. It is usually soft, and develops rapidly, as diabetes usually affects persons in youth or early life. If diabetes occurs in advanced age, the cataract dependent on it is mixed, with a large sclerosed nucleus.

The proportionately greater frequency of its complication with amblyopia is peculiar, and is to be remembered before commencing treatment. The amblyopia usually proceeds from an affection of the brain or of one of the nerve-trunks, and, like cerebral amaurosis, is characterized by darkening in the visual field, and symptoms of atrophy in the optic-nerve entrance, its bright white color, greater opacity, decided contraction of the central vessels, &c. (*Lecorché.*)

It is unnecessary to mention that this amblyopia may occur in diabetic patients, without cataract, and the disturbance of vision must, under all circumstances, be greater, as, with the general affection of the nervous and muscular systems, a true paresis or paralysis of the apparatus of accommodation usually accompanies high degrees of diabetes.

Latterly, raphania (ergotism) has been observed as a cause of the formation of cataract. (*J. Meyr.*) This variety develops slowly, and inasmuch as the original disease usually affects young persons, it is ordinarily soft.

It is not yet decided whether the poison, by its specific action on the ciliary system, impairs the nutrition of the crystaline, or if the cramps, which form the chief symptom of the disease, produce the cataract mechanically.

In a valley of the forest of Bregenz, the probable hereditary development of a peculiar disease of the skin and of cataract constantly united with it was observed in three families. The cutaneous affection always appears in the first months of life, and is characterized by a marble-like redness, which later leads to net-like cicatrices, and seems to consist in a fatty degeneration of the papillary body and of the rete Malpighi. From the fourth to the sixth year of life the cataract is always developed, and this in both eyes quickly one after the other (*Rothmund*).

2. In another series of cases the immediate cause of cataract lies in inflammation of the deeper parts of the eye, especially the anterior parts of the choroid. The inflammation may, in various ways, disturb the nutrition of the lens, and thus in *different* ways cause cataract.

Frequently the cellular layer of the capsule, or even the lens, is drawn into the inflammation, its organization is changed, and an indispensable condition to the normal existence of the lens removed.

In other cases, the cataract is caused by the inflammatory process ending with atrophy of the vascular organs of the eye, and thus destroying the chief source of nutrition for the lens.

Frequently the immediate cause of cataract lies in the impairment of free exchange of material, on account of depositions on the anterior capsule. When such products cover a large part of the capsule, the whole lens usually becomes cataractous; but if the depositions are confined to a small portion of the surface of the capsule, the cataract remains partial.

Of course, in many cases the pathogenetic causes act together in the production and further development of the cataract. It is not fully decided whether a mixture of the aqueous humor with extravasated blood, &c., can alone cause cataract. It is probable that the accompanying inflammation, and the deposition of clots on the anterior capsule, may be the cause.

Sometimes, moderate extravasations of blood in the aqueous chambers have a peculiar and lasting influence on the further formation of a developing cataract; for the hematin dissolved in the aqueous humor passes through the capsule, and reddens the superficial layers of the gradually decomposing lens.

Subsequently, in the disintegrated remains, it again separates, and we then find it collected under the form of dark, pigment-like granules deposited in the cataractous pulp. (*Beger.*) More rarely, we meet groups of beautiful dark-purple hematin crystals. In secondary metamorphoses the cataractous mass becomes very dense, almost cartilaginous, without much diminution in volume; hence such cataracts usually appear very large. But at the same time, from the resorption of the soluble constituents, the transformed hematin acquires the preponderance, and at last gives the surface of the cataract a purple-brown or ink-black color. As the hematin does not penetrate to the nucleus, the changes in it are the same as usual, except that it appears to sclerose more frequently. Such cataracts have been particularly described under the name of *cataracta nigra*, and have been correctly distinguished from black *nuclear cataracts*, which are only a far-advanced sclerosis. By using oblique illumination and the ophthalmoscope, they are easily recognized. The former shows very distinctly the brown or grayish-black color, the dull hue and the inequalities on the lens-surface caused by the remains of the clots, and by the ophthalmoscope the complete obstruction of the pupil is shown. On examination with the naked eye, however, the cataract may be easily overlooked on account of the dark color of the pupil, especially when this is much contracted. Then the condition may be readily mistaken for a high degree of amblyopia. This is, moreover, a usual complication, firstly, because extravasations in the chamber are often accompanied by hemorrhages in the choroid and retina; secondly, because extensive hemorrhages easily give rise to functional disturbances of the eye, by atrophy of the part.

3. Wounds of the lens and its appendages play an important part in the etiology of cataract.

a. Very fine punctures, which do not penetrate deeply, heal, in some rare cases, without leaving the least trace. Then, shortly after the injury, a superficial cloudiness usually occurs around the wound, which is caused by exuberance of the neighboring cells, and later disappears again, as the proliferating cells become normal. More frequently, however, this exuberance leads to a permanent opacity, in whose midst, at the point of the capsular wound, we find thick, cicatritial, fatty, chalky masses. There is a partial traumatic cataract.

As the parts of the lens surrounding the puncture disintegrate and swell up, they enter the wound in the capsule, or elevate themselves somewhat above its edges; subsequently they are partially absorbed, but partially become calcareous, especially when there is any severe inflammation. Thus a sort of plug is formed, which closes the capsular wound like a cicatrix, but often penetrates the lens-substance, and, according to late researches, is usually covered with a neoplastic hyaline layer, a continuation of the capsule-walls.

Exceptionally, extensive opacities of the lens, even such as have been caused by severe wounds, such as the entrance of an arrow, clear up with very slight remains, and leave only a proportionally slight disturbance of vision. (*Ressl*, *Rydl*, *Colsmann.*)

But, in most cases, even a small wound of the capsule suffices to cause cataractous degeneration of the entire lens. This process always begins with some, often with very decided, swelling of the lens-substance. As a result of this swelling, the capsule not unfrequently tears from the edge of the wound, a portion of the cataractous mass protrudes, and is absorbed, while the edges of the capsule retract and are fastened together by the calcifying remains of the cataract. The result is a secondary traumatic cataract. But where the capsule is not further torn, its wound is soon closed by the secondary metamorphoses, and the cataract, by these secondary metamorphoses, becomes (according to the density of the crystaline) a nuclear cataract, with a fatty, chalky surface, a disc-like or dry capsular cataract.

Moreover, since the injury often directly causes severe inflammation of the vascular deep parts of the eye, or excites it indirectly by swelling of the cataractous mass, causing irritation of the iris, true calcareous or fibrous cataracts occur, which as a rule are connected with extensive or total posterior synechia of the pupillary border. Then we often find the iris and lens also adherent to the corneal wound by tendinous bands. Moreover, the globe is usually atrophied by participation of all its parts in the inflammation. In not a few cases this is even so intense, that a true phthisis of the globe results.

b. The larger the wound in the capsule, the more certainly do total cataract and the last-mentioned results of inflammation occur, for then the edges of the capsular wound can retract further, a larger piece of lens is exposed, hence the aqueous has far greater effect, consequently the cataractous disintegration is more rapid and the swelling greater. Wounds of the capsule are particularly dangerous in individuals beyond puberty, where the lens has already attained a certain degree of density. In children, swelled lenses irritate less, perhaps, because they have less consistence, and as the absorption is very rapid, the injurious influence lasts a shorter time. Indeed, in children a wounded lens is much more frequently absorbed, without the eye being endangered by inflammation, than it is in grown persons.

Moreover, cases do occur, although rarely, where the capsule has been divided extensively, or even by a great number of crossing cuts or rents, and the lens deeply cut into, and only a partial cataract has resulted. In this the individual wounds are recognized as leaf-like, thick, tendinous, partly fatty chalky depositions, perpendicular to the surface, which are surrounded by cloudy, opaque masses, and are easily distinguished from the usually yellowish and soft remains of the lens which continue transparent.

c. Lacerated wounds are the most liable to produce cataract; such as are often caused when small chips of metal, pieces of exploded copper-caps (*Mackenzie*), etc., strike forcibly on the anterior surface of the globe, and after penetrating the cornea and iris, lodge in the lens. These bodies sometimes lie quite superficially in the wound of the capsule. Then, when the neighboring parts of the lens become cataractous, they are pressed out of the wound, fall to the floor of the aqueous chamber, and, as they are not easily found, they cause atrophy or phthisis of the globe, with severe pain. Often, however, they press deeper into the lens, and are enveloped by the cataractous substance. Then, in very rare cases, there is a clearing-up of the turbid lens-substance, except that in the immediate vicinity of the foreign body (*Ressl*, *Wagner*, *Wecker*). Total cataract usually results; generally there is even severe inflammation, which may totally destroy the eye, or is at least accompanied by extensive posterior synechia of the pupillary margin, and causes the transformation of a total to a calcareous or fibrous cataract. An important

symptom in the subsequent course of this cataract is the deep orange-yellow or rusty color of the capsular cicatrix and its surroundings. When this coloration occurs we may reckon with great probability on the existence of a metallic body in the cataract. This is of the more service in diagnosis, as the corneal wound often leaves no perceptible cicatrix, and the patient may not know of any precedent injury, as the latter is often unattended by pain, and is consequently overlooked.

4. In some very rare cases entozoa have been found as causes of cataract. These had perforated the capsule and entered the lens. They were sometimes round, sometimes flat worms, and were described as *filaria oculi humani*, *monostoma lentis*, and *distoma oculi humani* (*Nordmann*, *Gescheidt*). Quite recently a cysticercus has been found in the crystalline also (*Graefe*).

5. A further source of cataract is central perforation of the cornea. If the posterior opening be small, the anterior capsule becomes attached to only a small extent of cornea, and the union is easily broken up by the renewal of the aqueous, whereupon the plug remaining attached to the capsule is either absorbed or causes a central capsular cataract. But if the diameter of the perforation exceeds half a line, the separation of the capsule becomes more difficult; in many cases the lens remains connected by the cicatricial plug to the cornea, and often even with the pupil (Fig. 6). Then, as a rule, it soon becomes cataractous, and goes through its secondary metamorphosis under the influence of the inflammatory process causing the adhesion. It usually becomes a chalky or fibrous cataract, whose decided shrinking is shown by deep folds in the capsule. These often radiate from the plug, and there is always considerable tension and widening of the zonula.

It often happens, in large perforations, that the part of the capsule pressed into the opening bursts under the pressure of momentary muscular contraction, and that a part, or almost the whole, of the lens is evacuated, while the capsule remains. Occasionally even the posterior capsule is torn, and a greater or less amount of vitreous is lost. Under such circumstances it may exceptionally happen that only a part of the lens-matter remaining becomes cataractous, the rest remaining transparent. A partial cataract is the result. As a rule, however, the entire remains of the lens become cataractous, and are mostly absorbed. Then we at last find the cataract, as an irregularly-formed, chalky, or cartilaginous nodule, as large as a grain of hemp or pepper, attached to the pupillary margin at the corneal cicatrix. If, after adhesion of the lens has occurred, the cornea or cicatrix itself protrudes (on account of the firmness of the plug uniting them), the lens must naturally follow, the zonula is more and more stretched, and finally tears, so that the cataract is at last attached only to the concavity of the staphyloma (Figs. 47, 48, 50).

6. Finally, violent solutions of continuity of the ciliary processes are to be mentioned among the causes of cataract. These may be produced by concussions propagated from the bones to the eye, which shake the zonula and dioptric media. Most frequently, however, they are caused by direct force to the eye, as the cut of a whip, a blow, or kick, which compresses the globe in one direction, and, on account of the incompressibility of the dioptric media, causes a compensating expansion of the other parts not immediately acted on by the mechanical force; hence a momentary expansion of the circle of origin of the ciliary processes occurs.

a. In some cases the rupture is partial. It may then remain hidden for years, as it does not necessarily produce cataract in a short time. On more careful examination, however, we notice it from the tremulousness of the iris on rapid motions of the eye, from the protrusion of one and retraction of the other half of the iris; from the impairment of vision resulting from the oblique position and mobility of the lens; from the strongly-myopic adjustment of the eye, which is a consequence of the constantly-increasing convexity of the lens, resulting from the solution of continuity of the zonula; finally, from the entire absence of accommodation. On dilatation of the pupil, also, the faulty position, inclination, or sinking of the lens is directly perceived. If the formation of cataract has begun, there is no difficulty in diagnosis, and this is the easier the further the secondary metamorphosis has progressed, since

the cataract is then quite irregular from shrinkage, and the zonula is torn further out from the angle of the wound; moreover, the motion of the iris and cataract increases (*cataracta tremulans*), till, finally, the latter becomes free, and falls into the anterior chamber, or, if the vitreous has become fluid, it floats around freely in the eye (*cataracta natans*), and, as a mechanical cause, constantly or at intervals gives rise to inflammation.

b. In other cases, the crystalline is completely separated all around at first, and is thrust into the anterior chamber, where it lies wedged in between the iris and the cornea. The iris then appears much pressed back; its curvature altered; the pupil is usually dilated and immovable. As its diameter shortens, the lens acquires a more spherical form, and is recognized, as long as it remains transparent, by its peculiar reflex, and especially by the shadowy ring which appears behind its free border, and contrasts strongly with the brilliancy of the latter.

More frequently intense inflammations occur, which often destroy the eye by suppuration or atrophy. But, on the contrary, the crystalline inclosed in its capsule may remain for years lying in the anterior chamber, without causing particular inconvenience. Most commonly, however, iritis occurs, sometimes acute, but occasionally originally chronic. Frequently it may be easily cured, often, however, not till after the formation of an amount of morbid product, which becomes permanent, and secures the prolapsed crystalline permanently in its new position. As a rule, this iritis relapses sooner or later, and the relapses occur frequently, so that, even with the greatest care, the patient can not avoid them. If the lens be not removed, the choroid and retina finally participate in the inflammation, the eye becomes amaurotic and atrophied, without, however, becoming quiet; the sensitiveness is rather apt to continue, and then, under new attacks of inflammation, the eye is lost by phthisis. Moreover, it is not rare for irido-choroiditis to occur in the *other* eye, and injure its functions.

The crystalline itself may remain transparent for years, or may become cataractous only where it is attached by iritic deposits. In the course of time, however, it decidedly decreases in size, especially in its diameter, and subsequently also in the axis, while the lens-substance itself becomes more of a dirty yellow. Finally, although occasionally after years, a cataractous change begins on the surface, and progresses slowly toward the nucleus. The atrophy is then more extensive, and is the more decided the smaller the sclerosed nucleus, which may already exist, and the less intense the inflammation caused and maintained by the prolapse.

A complete disintegration and absorption of the prolapsed lens has been exceptionally observed (*Davis*).

c. If very intense mechanical force has acted on the eye, the crystalline, torn from its attachments, is driven into the vitreous (*Hasner*). Then severe inflammation of the inner parts of the eye almost always quickly occurs, and this is the more likely, as they usually have also been torn, or there has at least been hemorrhage from their tissues. If phthisis of the globe does not result, the functional power of the eye is usually lost by degenerative atrophy of the choroid and retina. The vitreous then usually becomes fluid, and the crystalline gradually becomes an atrophied cataracta natans, which, during motion, swims freely in the cavity of the eye, and keeps up irritation, if it has not been previously encapsulated and attached to some part in the back of the eye.

d. Occasionally, also, the sclerotica is ruptured near its anterior margin, and, as the dioptric media seek to escape at the point of rupture, the crystalline, torn from the zonula, with or without a part of the iris, is dislocated into the wound, or even under the conjunctiva. The rupture is almost always upwards, very rarely inwards, and most rarely downwards or outwards (*Lawson*). It always runs concentrically to the corneal margin (*Manz*). Phthisis, or at least degenerative atrophy of the globe, is then, of course, a probable result. Still, under these circumstances, a relative cure may exceptionally occur, and a certain amount of function of the eye may be preserved. Then we find the crystalline as a hard, at first transparent, but subsequently opaque, disk-like tumor, under the more or less hyperæmic conjunctiva, which is protruded by it. If the crystalline be not removed by an operation, or by suppuration, it is encapsulated or calcified. It is worth mentioning here, that such ruptures of the sclera are not necessarily accompanied by dislocation of the lens under the conjunctiva, for similar protrusions of this membrane are sometimes caused by prolapsed portions of vitreous, and they spontaneously disappear after a time.

e. The slighter resistance of the zonula explains why, under the influence of a blow, the

capsule rarely bursts and permits the escape of the lens, but is dislocated *as a whole*. Still, cases of the former variety are exceptionally observed. They lead to results analogous to those produced by change of place of the lens without injury of the capsule; but if the eye-ball does not suppurate, they leave a secondary cataract. (*Mackenzie, Graefe.*)

f. There are also congenital dislocations of the lens, or, at least, cases where it occurs very soon after birth, without any apparently sufficient external cause. These generally binocular dislocations are called "spontaneous," in contradistinction to the "traumatic," which are usually monocular. They are divided into *ectopia* and *spontaneous dislocations*. (*Sippell.*)

By *ectopia* is understood a slight degree of displacement of the lens, within the ciliary processes, with a continuance of the normal attachment. *Spontaneous luxation*, on the contrary, is a total removal of the crystaline from the optic axis, by destruction or excessive tension of the zonula, and separation of the attachment between the posterior capsule and the hyaloid.

Ectopia is always congenital, often hereditary, and frequently accompanied by decided myopic formation of the eye. The lens is usually displaced upward and inward. Its lower border pushes the iris forward, while the lower half of the latter deviates backward, and trembles greatly. When the pupil is dilated, the interval between the lower border of the lens and the ciliary processes appears as a black crescent, contrasting with the bright border of the lens. On ophthalmoscopic examination, on the contrary, the edge of the lens appears as a dark, crescentic shadow in a red field, sharply bounded below, indistinct above. If, with a moderately dilated pupil, the patient "fixes" objects, they often appear to have colored borders, and, on account of the prismatic deviation caused by the exposed margin of the lens, they often seem doubled. But they usually appear broken, and also much confused, on account of the partial coincidence of the rays passing to the retina through the lens, and below it. With a contracted pupil, when the lower border of the dislocated lens is covered by the iris, the adjustment of the eye is usually myopic and astigmatic. But, if the upper part of the dilated pupil be covered, and rays pass only under the edge of the lens, the adjustment is hypermetropic. (*Donders.*) This condition usually exists for life, without causing further changes; but it gives an inclination to laminated cataract, and occasionally to deviations of the optic axes, during fixation. (*Graefe.*)

Spontaneous luxations are scarcely ever congenital, but develop, sooner or later, after birth. The immediate cause often remains unknown. In other cases, slight concussion, sneezing, vomiting, &c., are given as causes. A decided diminution of resistance of the zonula, and a weakening of the union between the posterior capsule and hyaloid, are evidently indispensable to the occurrence of a spontaneous luxation.

This cause occasionally depends on precedent inflammation, on the staphyloma of the anterior half of the globe that it produces, and on the accompanying excessive tension of the ciliary processes. (*Ryba, Heymann.*) Usually, however, all symptoms of such processes are absent; the diminished resistance of the zonula is probably congenital. The occurrence of the affection on both sides is another proof of this, and it depends on the elongation of the eye, that may be always observed. In some cases there is not so much tearing, as tension or stretching of the zonula. (*D. E. Müller.*) More frequently, only part of the ciliary processes is ruptured; the lens waves about, attached to the remainder.

When the head is quiet and upright, the lens appears sunken more or less downward, and often also to the side, or to the floor of the posterior chamber, so that its upper edge is perceived in or under the horizontal diameter of the pupil. It is also oblique, without being exactly reversed, as the hyaloid and vitreous are almost always preserved. On motion of the eye and head, the lens also moves (*Höring, Ed. Meyer*); either in the posterior chamber, or by certain motions of the head, the lens may voluntarily be thrown through the pupil into the anterior chamber, and brought back again. This condition has been called "spontaneous free motion" of the lens (*Heymann*).

The symptoms of spontaneous luxation require no special distinction from those given for ectopia. As long as the lens lies on the floor of the posterior chamber, the adjustment of the eye is the same as in aphakia—that is, hypermetropic; but if it approaches the pupil, or enters the anterior chamber, the eye becomes myopic, for then the spherical shape of the lens, and its displacement forward, correspond with the myopic form of the eye.

The characteristic point, however, is the *rapid change* from one to the other of these opposite conditions, when the vertical axis is inclined in certain directions. In spontaneous luxation, vision is, as a rule, much more indistinct than in simple ectopia, as the lens is set in motion, and kept moving, by the slightest movement of the head and eye, as in following the lines in reading. When the lens lies in the anterior chamber, this condition is less felt, on account of the greater stability of the crystaline. But the strong refraction of the light at the rounded edges is a source of disturbance, greater in proportion to the dilatation of the pupil. In addition to these circumstances, convex and concave glasses, which might neutralize any temporary error of adjustment, are of little service to the patient, and of course the entire absence of the power of accommodation increases the difficulty. The luxated lens and its capsule usually remain transparent for years, but it becomes smaller and almost spherical. Finally, however, it always becomes cataractous. At first, by its movements through mechanical irritation of the iris, it may lead to the same results as a traumatic dislocation. But if the spontaneous dislocation has existed for some time, and the lens has become smaller and spherical, so far as has been observed, inflammations rarely occur.

Course.—In general, we may say that, where there are no peculiar local causes for the formation of cataract, it progresses more slowly the older the individual—that is, the harder and firmer the lens has already become.

a. Hard nuclear cataracts often require years, before they are so far advanced as to render it impossible for the patient to go about alone, and months often pass without noticeable increase of the opacity. But a progressive (even if *gradual*) increasing density of the sclerosed nucleus, and an increase of its diameter, with a corresponding flattening of surface, occurs. Where the cataract has existed for years, we may expect a large nucleus, and must remember this when undertaking an operation. Even the softening of the superficial layers takes place very slowly in old persons. The progress is particularly slow where a fine, delicate striation is observable in the cortical layers, while broad striæ, with marked diminution of consistence of the layers affected, usually indicate a rapid progress of the process. Where softening of the cortical portion has once begun, the progress is always more rapid than in sclerosis of the nucleus, and it occasionally occurs that, in a few weeks or even days, the cataract becomes complete, after the nucleus had required years to attain a high degree of opacity. The secondary changes of the cataractous cortical layers ordinarily proceed very slowly, especially when the circumstances are unfavorable, to a complete softening. In fact, we not unfrequently find mixed cataracts, that have existed for years, in whose cortical layers the secondary metamorphosis appears scarcely to have commenced. For actual atrophy, several years are required.

b. Soft cataracts, on the contrary, are formed in several months, at most in one or two years, and go through the secondary changes also in a proportionately shorter time. They advance with peculiar rapidity when arising from external causes, especially wounds.

c. In more advanced years of life we often meet with very irregular or radiating opacities in the anterior or posterior halves of the cortical portion, usually finely granular, whilst the nucleus can, as yet, show no marked signs of sclerosis. Such undeveloped, partial cortical cataracts frequently exist for many years, without there becoming perceptible any increase or superficial expansion of the opacities apparently situated upon the capsule. The sclerosis of the nucleus then gradually shows itself, or the cataractous process in the periphery of the lens suddenly increases and then leads within a short time to complete degeneration of the cortical

Still, numerous exceptions occur to this rule. Cases are known, where, in individuals beyond thirty, they have fully developed in a few weeks or even days, and, on the contrary, where in children an existing cataract has steadily or interruptedly gone on for years before complete development.

d. Partial, like soft cataracts, usually develop rapidly, and then become stationary, as the atrophied elements, by their secondary metamorphoses, gradually pass into permanent forms, without the process proceeding further. This is particularly true of central capsular cataract and its varieties. As a rule, these exist till advanced age without any very decided change occurring, or a transformation into total cataract threatening. More extensive partial cataracts are less stable, for in them, after several years or in advanced age, a continuance of the process and a consequent formation of total cataract often occurs.

Laminated cataract is almost always developed in childhood or youth, and extends rapidly, then becomes stationary for a longer or shorter period, usually for years, but rarely continues as such far into maturity. After it has existed for some time, secondary metamorphoses gradually show themselves in the cataractous laminæ, and in the course of time somewhat change the appearance of the cataract. All at once, and without perceptible cause, the process sooner or later goes on, the diffuse spotted or striated opacities peculiar to cortical cataracts show themselves in the superficial strata; these sometimes quickly, sometimes gradually extend, with or without interruption, and, arrived at a certain point, again stop to take on another form from secondary metamorphosis. Then we have a cataract whose cortical portion is much atrophied, partly transformed to a fatty, chalky mass, partly to a tendinous net-work or to large flakes attached to the capsule, while the nucleus preserves its normal consistence and transparency, but appears very yellow. Finally, however, this becomes cataractous or sclerosed; the cataract becomes total.

Here also the appearance of broad opaque stripes, with coarse points and spots lying between them, indicates a rapid progress of the disease, while very fine striæ in small numbers, as well as a diffuse or finely-punctated cloudiness, lead us to expect a slow advance.

It is, of course, understood that an increase of the cloudiness is accompanied by a decrease of vision. This usually causes the patient to apply to the surgeon, and hence, clinically, we meet far more of such imperfect and progressive laminated cataracts than of pure ones.

e. Cataracts dependent on purely local causes usually remain limited to the affected eye, and there is no proof for the assumption that they cause an inclination to cataract in the other eye. Cataracts which have appeared without any demonstrable cause, when they affect young people, and are therefore soft, exceptionally remain monocular for years, and even to old age. On the other hand, cataracts which depend on constitutional, senile, or pathological involution of the body, or originate in faults of development, almost always occur in both eyes. This occurrence is often simultaneous in both eyes, and then the process usually goes on more rapidly in one eye than in the other. In most cases, however, cataract appears first in one eye, and, after developing there to a certain extent, the morbid process begins in the other eye.

Results.—These regard first the condition of the crystaline and the disturbance of vision associated with it; but secondly the functions of the other parts of the eye; for experience teaches that, under certain circumstances, these are endangered by cataract.

A. Under favorable circumstances, inflamed lens-elements may again become normal. Indeed, we not unfrequently see the delicate cloudiness of the superficial layers of the lens, which occurs in iritis, and which is undoubtedly to be regarded as phakitis (capsulitis), completely disappear after the termination of the

process of proliferation. Then the unchanged refractive condition of the eye is a proof that the clearing-up has not occurred at the expense of the portion of lens that was inflamed. But this occurs not only with delicate opacities; sometimes, under the same circumstances, dense opacities of the external layers occur, and give the appearance of fully-formed cortical cataracts. Even these sometimes disappear, and the former power of adjustment is restored.

It is different with cataractous opacities in the strict sense, i. e. those dependent on destruction or atrophy of the parts. It is doubtful if a perfect cure is possible in these cases, but it is maintained that it has occurred spontaneously (*Himly*, *Ed. Jaeger*), and as a result of various methods of treatment.

It is said that there is most probability of a spontaneous cure in incompletely developed cataract of the superficial layers, especially in striated opacities of the middle layers of the posterior cortical strata, which either exist alone or with short processes running over the equator of the lens into the anterior cortical layers, and which have long remained stationary. (*Ed. Jaeger.*)

On the other hand, a relative cure, or at least a diminution of the disturbance of vision, is not unfrequently accomplished by a complete absorption of the cataractous portion of the lens, as well as by a displacement of the entire crystaline.

1. For resorption alone to fulfill such an aim, presupposes softened lens-matter. In sclerosed, calcareous, fibrous, &c., lenses, resorption is far too slow and incomplete for us to expect a favorable result from it.

a. Where the capsule is uninjured, the resorption of even soft lens-matter is difficult, and it rarely disappears from the *closed* capsule as a result of absorption.

It occurs most readily in partial cataracts in young persons, but particularly in incompletely developed cortical cataracts. The clearing-up always takes place at the expense of the extent and shape of the crystaline, whose surfaces flatten out correspondingly, and usually become irregular, while a shrinking usually begins from the equator. This is accompanied by a hypermetropic adjustment of the eye, and an indistinctness of the circles of dispersion, as well as by an almost complete absence of the power of accommodation.

In most cases, under such circumstances, the absorption is incomplete; the existing opacities diminish only with corresponding diminution and change of form in the lens; they break, split up; cavities form in the thickening opacity, which finally present only heaps of points, spots, striæ, &c. These are formed of fatty, chalky, white, opaque masses, and appear scattered in the transparent lens-substance, and leave larger or smaller intervals for the passage of direct rays of light.

Thus occasionally, in extensive cortical opacities, which have remained stationary for a long while, in partial cataracts of all kinds (traumatic included), and particularly in laminated cataracts, the vision, which has been much affected, or entirely lost, is improved to a considerable extent, and retained at the same point, if the cataract does not progress.

In total cataract, resorption alone is insufficient to cause a decided improvement of vision. Still, sometimes, fluid total cataracts, as a result of progressive resorption, shrink together to a thin dry membrane, which may acquire a high degree of translucency, and permit the patient to go alone with difficulty. By almost complete absorption of the affected portion of lens, such a cataract may, exceptionally, become so transparent, that the patients can see sharply, or even read small print, with the aid of suitable glasses, or possibly without them. The same thing may possibly occur in mixed cataracts with fluid surfaces, as the cortical portions are almost entirely absorbed, so that a certain amount of direct light passes not only through, but by the side of the diaphanous nucleus.

b. If the capsule be opened by an external injury, or by an operation, and th dioptric fluids thus permitted to act directly on the cataractous lens, resorption is

more effective, and, under otherwise normal circumstances, is seconded by the powe of the edges of the capsule to fold up and retract toward the equator.

In these cases it is usually indifferent whether the injury of the capsule ha caused the cataract, or has occurred after the cataract has begun, and progresse more or less in its development. The result depends more on the length and depth the number and direction, of the individual wounds of the capsule, on the consistenc of the different layers of the lens, and on the intensity with which the vascula parts of the eye react after the injury.

a. Of course, a simple linear wound of the capsule produces no decided gaping of the opening. Hence it gives but little opportunity to the fluids to act on the lens-matter; consequently the disintegration and resorption of the cataract is usually slight. If the wound is very short, it often closes again, with or without leaving a fatty, chalky cicatrix; but, if longer, it becomes lance-shaped. In either case the resorption is incomplete, no matter how favorable the conditions may be otherwise. At most, the two halves of the capsule approach each other, and become attached by the secondary metamorphoses of the cataract. The result is a secondary cataract, which is distinguished from the ordinary cataracta siliquata or discoidea, by the appearance on its anterior wall of a fatty, chalky cicatrix, or a lance-shaped slit with elevated edges, which is covered posteriorly by the usually opaque posterior capsule. But if the posterior capsule was also wounded, the vitreous may lie in the wound, and, by aid of suitable glasses, distinct and sharp vision may be obtained.

β. If the capsule be opened by a flap-wound, or by a series of intersecting cuts, the circumstances may be more favorable, because the edges of the wound or flap retract by rolling up and folding together. The dioptric fluids then act on a greater portion of the lens; hence the disintegration is usually very rapid, and when it occurs with great swelling, is not unfrequently accompanied by a further tearing of the capsule from the angle of the wound, which favors the retraction of the edges to the margin of the lens. The part of the crystaline lying in the capsular opening is then usually completely absorbed, if particular circumstances do not prevent. The portions covered by the remains of the capsule, however, always leave a detritus, which becomes at least partially calcareous, and renders adherent the halves of the capsule lying next to each other.

If both the anterior and posterior capsule have been extensively divided, the cataract presents a sort of ring-shaped cushion, which contains disintegrating cataract substance, and has an envelope, formed of the peripheral parts of the two halves of the capsule. The inner border of this ring is formed by the calcareous remains of the lens, and at the outer side is united with the ciliary body by the zonula. If the wound of the capsule extend to the equator, or if pieces have been torn out from the periphery of the capsule, this ring-shaped cushion appears to have gaps in it; it borders only portions of the ciliary body; at others, all trace of it is absent, or only a few cloudy shreds appear. This cushion is completely covered by the iris, the pupil appears clear, and direct rays pass, as in a normal one.

But if the posterior capsule has remained uninjured, it subsequently appears stretched in the opening of the crystalline cushion, as in a frame. Sometimes it appears bulged forward; this is to be explained by the increase of the vitreous. It may always retain its transparency, but not unfrequently it becomes cloudy, or subsequently loses its pellucidity by a more or less thick deposit consisting of cells or their derivatives, which form, by proliferation, on the anterior surface of the posterior capsule, and subsequently change in various ways (*Schiess-Gemuseus*).

If the splitting of the anterior capsule were incomplete, and thus only short ...s formed, which, on account of the position of the wound, could retract but ..., the inclosure of the peripheral portions of the lens occasionally forms a ...ion-like frame, it is true, but its opening is generally covered by cloudy mem-...ous offshoots, which consist of the middle portions of the two capsules glued ... each other by a fatty, chalky cataractous layer, and as they only leave a portion ...e pupil free, they always cause a decided limitation of the visual power.

... In order that the edges of the capsule may retract, it is absolutely necessary ... it should not be deprived of its elasticity by iritic depositions, products of cap-..., or fatty, chalky deposits on the inner wall. Even very thin deposits, whether ...e inner or outer wall, offer decided obstacles to the reaction. When of a cer-... thickness, they suffice to hold even small and long, almost linear, shreds in their ...al position. Thus the reunion of capsular shreds, lying near each other, is ... favored, and the direct action of the dioptric fluids on the cataractous lens-...r is greatly limited. Hence, under such circumstances, resorption usually ac-...plishes less, but, on the contrary, the calcareous formation is usually extensive.

... The condition of the individual layers of the lens—that is, the form and ...e of development of the existing cataract—have a great influence on the ...omical appearance. In general, under otherwise similar circumstances, the ...rption of the disintegrating lens, and the retraction of the capsular shreds, are ...ly the more rapid and complete, the softer the individual constituents of the ... In this regard fluid cataracts stand first, if secondary changes have not begun ... early in them, and the capsule has not been robbed of its natural elasticity ...tty, chalky deposits. Soft cataracts, in which the softening has advanced to ...center, especially those of starchy consistency, are therefore regarded as the ... favorable. Moreover, in the partial and incomplete cataract of children or ...g persons, resorption usually goes on very rapidly, and often very small wounds ...e to render the pupil almost or entirely free. After puberty, however, the ...tence of the nucleus opposes a rapid and complete absorption.

But the difficulties increase in proportion as, with advancing age, the density and ...nt of the nucleus increase. Hard nuclear and mixed cataracts (when the ...osed part is of considerable size) are not much affected by simple division, even ...is extends to the nucleus. But this is true, to a still higher degree, of cataracts ... advanced in secondary metamorphosis, as the cataracta siliquata, discoidea, ...rea, fibrosa. Here, in order that a part of the pupil may be passable for direct ..., large portions must be torn out of the anterior, or both capsules, and, with the ...ens (if sclerosed), removed from the optic axis.

... The condition of individual lens-strata influences very much the amount of ... swelling dependent on the cataractous disintegration, and thus, also, to a certain ...nt, the amount of danger from inflammatory reaction. (*Graefe.*) In pultaceous ...tegration, and particularly in parts of the lens far advanced in secondary ...morphosis, there is little or no swelling. Even large pieces of sclerosed nuclei ...ll but little, as they are only slowly affected by the dioptric fluids. Mechanical ...tation of the vascular parts of the eye are, therefore, only to be feared from such ...ract when they protrude from the capsule, or even fall to the floor of the ...mber, and come in direct contact with the iris. Small portions of sclerosed ...leus, on the contrary, under favorable circumstances, swell more. As they present

a relatively greater surface to the dioptric fluids, the disintegration may result mo rapidly. Under otherwise similar circumstances, transparent, or even cloudy len matter, having a normal or nearly normal consistence, swells most, and does so ti more rapidly, the more extensively the capsule and lens have been divided.

Other things being equal, the mechanical irritation of the vascular parts o the eye, accompanying the swelling, is the greater and more dangerous, the great the density of the swelled parts coming in contact with the iris. Indeed, in childre enormous swelling of the lens is often borne without severe inflammation occur ring, while even at puberty comparatively slight swelling usually excites inten reaction. But from this point the bad results increase, and in advanced age small piece of lens, projecting from a slight puncture, will often suffice to exci very injurious inflammation. Here comes into question the difficulty of resorpti (which increases with the density of the swelled part), that is, the duration of th mechanical irritation. Independent of this, however, the age itself is of great im portance, as experience shows that the eyes of children suffer less from injuries than those of grown persons.

These dangers from swelling depend greatly on the extent and duration of the action of atro pine, so that, under otherwise similar circumstances, the swelling may be considered less dangerou when the iris dilates rapidly and permanently under atropine, and can be kept out of the way of the pieces of cataract. (*Graefe.*) Of course also individual inexplicable peculiarities have a influence. These sometimes cause quite unproportionate reaction, or even purulent destructio of the globe, where it was least expected; while, on the other hand, in exceptional cases the lessen the danger of the most serious injuries to the vascular parts of the eye.

The amount of influence exercised by the chemical effect of the disintegration of the cataract is undetermined. The vital influence of the process of proliferation, which occurs in the living elements of the lens adherent to the capsule, are certainly very important (*Graefe, Pagenstecher*).

If inflammations thus excited run their course without noteworthy injury of th vascular parts of the eye, they are nevertheless injurious, for they not only delay but often prevent resorption, and favor the transformation of the exposed parts o the cataract to permanent forms. On the one hand, as a result of the iritis, po terior synechia readily forms; this prevents the retraction of the capsular shreds and, on the other hand, the process easily affects the capsular epithelium, and hence goes to the lens-elements proper. At least, under such circumstances, the parts o the lens lying in the capsular opening often thicken decidedly, and, after a whil present actual membranes of fibrous appearance, or chalky masses, which close th capsular opening anteriorly, and often even form over it a neoplastic hyaline mem brane, while the contents of the capsule, transforming to chalk or cholesterin, becom permanent, and the cataract acquires the appearance of one developed under seve inflammation.

2. Another way for the relative cure of cataract is rupture of the zonula, whi permits displacement of the crystaline. It is of course understood that the caus of such a loosening from the ciliary body are the same, whether the lens be catara tous or transparent. However, circumstances are always more favorable for partial or total detachment of the crystaline in cataracts, especially such as are f advanced in regressive metamorphosis. Apart from the fact that the zonula rare remains undisturbed in atrophy of the lens, an irregular traction on the zonula often caused by shrinking of the lens; hence this is unproportionately stretche

Then, only a slight external force, often only a strong contraction of the recti muscles, is required to cause a rupture of the zonula. If the vitreous be fluid, as not unfrequently happens where the cataract has been developed under severe inflammation, the strong vibrations in which the fluid is thrown, by rapid movements of the eye, often suffice to cause a rupture of the zonula.

If the zonula be torn to only a slight extent, on account of its weight, the cataract sinks, sometimes to one side, sometimes to the other, and so, perhaps, exposes parts of the pupil. To this is to be added the fact that, after separation of the zonula, the impediment to a shortening of the diameter of the lens is removed. But, if the lens be diminished in all its dimensions, a large part, or perhaps the whole of it, will remain permanently free.

So long as a cataract that has thus shrunk continues attached to the ciliary body, by the zonula, it can not, it is true, remove from its position, but it follows all the vibrations of the vitreous and aqueous, and appears as a tremulous cataract. From these oscillations and the mechanical irritation of the iris, it readily causes acute, and often very injurious, inflammation. More frequently, however, it causes chronic irido-choroiditis, which easily ruins the eye, and may even sympathetically affect and endanger the other eye. But sometimes the cataract is gradually fixed in its position by these inflammations, and rendered harmless, or the motions are tolerated, and do not produce any great reaction.

If the tremulous cataract does not become attached to the vascular parts around it, the separation of the zonula usually progresses, on account of the tension caused by the oscillation, and finally becomes a floating cataract—a condition which may also occur originally, as a result of an external mechanical force, producing total rupture of the ciliary processes.

A cataract, torn entirely loose from its normal attachments, occasionally sinks, and becomes attached, by inflammatory products, to the floor of the posterior chamber, and is thus possibly rendered permanently harmless. More frequently, however (whether irido-choroiditis occurs or not), it remains free for a long time, and sometimes comes into the anterior chamber, and again goes back. If it remains long in the anterior chamber, it usually excites severe inflammation by its mechanical influence on the iris. This is rarely confined to the iris, but is more apt to extend to the entire globe, and destroy it by atrophy or phthisis. If the vitreous were fluid when the lens became detached, or if it became fluid as a result of the inflammation excited by the movable cataract, the latter may float about the whole interior of the eye. Sometimes it appears in the anterior chamber, again sinks to the bottom of the eye, till finally it becomes attached somewhere by the inflammation, or the globe shrinks from atrophy or phthisis.

B. The disturbances of vision caused by cataract may, under certain circumstances, have a secondary influence on the functional power of the parts sensitive to light, and the muscles.

If the cataract does not develop till after puberty, or in mature age, these secondary lesions rarely threaten. Such cataracts, it is true, appear not unfrequently accompanied by amblyopia, and occasionally, also, by disturbance of movement; but these are accidental complications, or they come from the same cause as the cataract. Where the cataract has existed for several years, particularly if only on one side, the greatest misfortune, at this age, usually is that, after a successful operation, the patient can not make out quite well the impressions received by him, and requires long practice to gain the full benefit of the reacquired visual power.

The circumstances are more unfavorable, when the cataract has been developed in early childhood, or during fœtal life; and this is the more important, as a considerable extent of such cataracts is accompanied by incomplete development in the other parts, and by visual disturbances dependent on them. If the cataract be double, nystagmus usually occurs early. This increases in intensity with time, and soon causes a strabismus of one of the eyes. Besides this, experience shows us that the functional activity of the retina often diminishes at the same time; this diminution increases if the operation be postponed, and often becomes an actual binocular amblyopia before the commencement of puberty, and renders fruitless all attempts at cure. If the cataract be and remain monocular for years, amblyopia and strabismus of the cataractous eye is a very usual result. It is true, however, that cases have occurred where cataracts developed in early life have been operated on at an advanced age, with the best results, and the eye has retained its general position and mobility. (*Graefe*, *Knapp*.)

Treatment.—By this we attempt to cause incipient cataracts to recede, or at least impede their course. Where the cataractous cloudiness is solely the expression of a recent inflammation, which is running its course, we may often fulfill this indication by proper antiphlogistic treatment; otherwise we must attempt to diminish, as much as possible, the disturbance of vision accompanying the formation of the cataract, until its removal from the axis of vision can be most easily and safely accomplished.

A. 1. It is at least doubtful if cataracts can be caused to recede by therapeutic measures.

It is true, several credible authors say they have seen existing cataractous opacities clear up under the systematic use of mercury, and after frictions of iodide of potassium ointment about the eyes for months, after the internal and external use of phosphorus (*Tavignot*), after treatment with electricity (*Faye*), after hydropathic treatment at Karlsbad, Eger, &c. (*Himly*, *Arlt*). These cases, however, are such rare exceptions, that they scarcely encourage the commencement of such treatment of diabetic cataract (*Melchoir*) have been destroyed. The methodically-repeated paracentesis of the cornea is also shown to be inefficacious. (*Rivaud*, *Landray*, *and others*.) Still, some claim to have temporarily arrested the progress of cataract by this procedure. (*Secondi*.) The extent to which the use of concentrated sunlight may be serviceable in clearing up the cataractous opacities (*H. Langenbeck*) has not yet been satisfactorily decided.

Medical treatment may, however, be of service in so far as it is suited to remove direct or indirect causes of cataract.

It can scarcely be denied that, with the removal of the cause, the development of the cataract may be easily impeded, and its progress restricted. But if this succeeds, it is evidently possible that the already cloudy portion may be caused to disappear by regressive metamorphosis and absorption, and a relative cure thus brought about. The indications for such treatment are clearest, when certain diseases exercise an injurious influence on the nutritive conditions of the whole body, and originate a pathological involution, as well as where local inflammations endanger the normal nutrition of the lens.

2. But if the causes of cataract escape recognition, or if they lie beyond the reach of therapeutic means in unripe cataracts, it is best patiently to await their ripening, and direct our whole care to keeping off injurious influences, which may hasten the growth of the cataract, or place the other parts of the eye in a condition to endanger or prevent success in future operations.

For this purpose it is sufficient to live moderately, and it is quite unnecessary to

forbid customary habits that do not injure the general health. Still, it is wise, if not absolutely necessary, to insist on great care of the eyes, and particularly to forbid continuous employment which requires acute vision at short distances, that is, long-continued reading, writing, sewing, &c.

3. In binocular cataracts that have attained a certain grade of development, employments requiring sharp vision usually become impossible. As long as the cataract is not ripe in either eye, the indication is temporarily to diminish as much as possible the impairment of vision, and so render the condition of the patient less annoying, until an operation can be undertaken under the most favorable circumstances. Shading of the eyes answers all these purposes, and hence is instinctively used by most cataract patients, if a more distinct view of objects is desired. The surgeon may recommend broad-brimmed hats, eye-shades, &c., if it is desired to keep off direct sun or lamp light; but dark glasses, if bright, diffuse light is to be subdued.

Mydriatics are much used in such cases. Their action is not under perfect control, however. If solutions of atropia, &c., be dropped in, the pupil ordinarily dilates considerably, and vision is often interfered with. The gain, therefore, only becomes evident, where the dilatation attained by shading the eye no longer suffices to improve vision considerably. Here the mydriatics remain, at least temporarily, a valuable palliative. In other cases, simply shading the eye is preferable.

4. Of course, these remedies suffice only when the cataract is progressive, and there is a reasonable hope that, at no very distant time, a successful operation may be performed with comparatively little danger on at least one eye. In partial cataracts, which have become stationary, and, as experience teaches, may remain so for years, or for life, but where a decided preponderance of the still normally-transparent part of the lens renders a cataract operation dangerous, other more effective means must be employed, if we would not, for an indefinite time, leave the half-blind patient in his pitiable condition, or give him the alternative of a recognizedly dangerous operation.

In such cases, the object is, by exposing transparent parts of the lens, to increase the apparent brightness of the retinal images, and, at the same time, by keeping off superfluous light, to lessen the intensity of illumination of the spectrum from the cloudy portions of lens. The first end may often be attained by an iridectomy (*Graefe*, *Steffan*), the other by shading the eyes, or, if necessary, by dark glasses. The desired end is more surely attained, however, by a successful displacement of the pupil, since, in this way, we simultaneously enlarge the passage for direct rays, and partially cover the opacity, causing the dispersion of light, without the activity of the pupil or the accommodation of the eye suffering (*Pagenstecher*, *Berlin*).

In fact, after such a proceeding, vision is almost always very much increased, and it requires at most relatively weak glasses to correct sufficiently the existing errors of adjustment in the eye. Still, the dangers of the operation are also of very great moment, and on the whole it seems more advisable to content ourselves with the slighter but always very satisfactory results of iridectomy. Of course, it is presupposed that the laminated cataract is pure and stationary, and also that a zone of the border of the lens, about a line broad, remains free.

If the equator of the cloudy stratum approaches nearer to the equator of the lens, the open-

ing gained by the operation for direct rays is much too small to enable retinal images to receive a sufficient apparent brightness in moderate illumination. If the laminated cataract be impure, if other and particularly superficial strata begin to cloud up, the operation is not worth while, as the exposed pellucid borders of the lens, as a rule, soon become impassable again for direct rays, and the temporary gain is outweighed by the cosmetic injuries, and by the objections that a dilated or displaced pupil subsequently offer to undertaking an operation for cataract.

With similar reservations, displacement of the pupil may, as we know from experience, be serviceable in other forms of partial cataract, and particularly, also, in ectopia of the lens. In the latter case, the pupil must, of course, be displaced toward the part of the lens-border which is connected to the ciliary body, so that the portion of the lens that was exposed in the pupil may be covered by the iris. (*Pagenstecher, Wecker, Knapp.*)

B. When the cataract is ripe, the indications are for its removal by operation, and only circumstances, independent of it, can render advisable or necessary the postponement or entire neglect of the operation.

The idea of a ripe cataract is not very exact. It depends chiefly on the amount of difficulty and danger which arises in a cataract operation from the state of the lens itself. It therefore varies, also, with the different methods of operation that may be used in any case, and is usually the more extended the more numerous the means these offer for removing the entire cataract safely from the eye.

In this regard the condition of the margin of the lens is of the utmost importance. Where the exterior strata are pulpy or fluid, the evacuation of even a large transparent and normally consistent nucleus is not difficult; hence such cataracts are ripe for operation. The existence of a thin, perfectly normal, cortical layer, does not imply any peculiar dangers if the rest of the lens be sclerosed, for then the connection between cortex and nucleus is very intimate, and the crystalline is readily separated from the capsule, or only leaves some scanty remains in it. If the peripheral layers have preserved their transparency, or at least their normal consistency, to only a moderate depth, they are firmly attached to the capsule, and their evacuation can not be attained without energetic, and therefore dangerous, manipulation. The flaps of the capsule formed by the operation may retract with difficulty, readily adhere together again, and exclude the subjacent lens-tissue from the aqueous humor, and prevent its absorption. Moreover, the portions of lens that are slightly clouded and of normal consistence, swell up under the influence of the aqueous and irritate the iris mechanically, perhaps also chemically. (*Pagenstecher.*) And so far as they have maintained their organic connection with the capsule, they proliferate, and may possibly cause increased disease of the neighboring parts of the eye. (*Graefe.*) The result of the operation is, therefore, at least a secondary cataract; but there is often an inflammation that seriously threatens the existence of the eye. Even if this be successfully treated, it greatly hinders the subsequent removal of the secondary cataract, by forming posterior synechia, membranous formations on the posterior surface of the iris, chalky deposits in the capsule, &c. In short, such cataracts are unripe for operation.

In order to hasten the proper period for operation in such cases, and at the same time to avoid the above-mentioned dangers, the artificial ripening of the cataract, by opening of the anterior capsule, has again been recently attempted, and with favorable results. For this purpose an iridectomy was first made, and after five weeks at least, a cataract-needle was passed through the cornea and a crucial incision made in the capsule, or even the lens-substance proper broken up. A few days afterward the cataract was removed. (*Graefe.*) Others wounded the capsule

ce-shaped knife at the time of the iridectomy, or punctured it with a needle, and, lays, operated for cataract and iridectomy at the same time. (*Mannhardt.*) But it d that this operation was not by any means a safe one, but that, in spite of all care, g might occur, and the inflammatory reaction could not always be limited, and the n lost. (*Arlt.*) Hence forced ripening must be regarded as a very doubtful under- haps the danger may be somewhat avoided by opening the posterior capsule with a d through the sclera, thus escaping the action of the swelled portions of lens on the

taracts, where all the constituents are far advanced in cataractous degene- most favorable for operation. But the advantages of ripeness do not ncrease, if the cataract continues to change more and more. On the he secondary metamorphoses have certain disadvantages, which may not r more difficult the performance of the operation, but may have a bad n the result. A cataract may be *overripe*, in a bad sense of the word. taracts whose cortex or entire structure is broken down into a chalky, , full of small sandy granules, or thickened to a fatty, chalky pulp; but r cataracts whose cortical strata are transformed to a dry, friable mass the capsule, can not be removed without the greatest danger, as it is remove all the hard chalky fragments from the eye; they are apt to ind the iris and act as foreign bodies.

re the cataract is ripe or overripe, the urgency of the operation greatly whether the function of one or both eyes be greatly impaired or entirely

e eye is cataractous, while the functions of the other are normally per- only slightly impaired, the operation should only be undertaken when le results may be regarded as nearly certain; of course, this does not es in which the long retention of the cataract in the eye is itself inju- traumatic cataracts which swell greatly, prolapsed lenses and parts of

ntages accruing to the patient, in case the operation is successful, are indeed not t, we have the cosmetic interest, and in young persons this is often important, so may indicate the operation, even if want of functional power in the parts sensitive er restoration of vision out of the question. Besides this, both eyes are enabled to , the visual field is enlarged, the intensity of optical impressions and the correct small distances and dimensions increased. Another important point is, that, in the ormation of cataract in the other eye, the patient is not at any time quite blind.

nt should be told, before operation, that the unequal refraction of the two eyes will y felt in sharp fixation, since the circles of dispersion of the lensless eye, and the l images of the sound eye, unite to a common *indistinct* perception, and that this evil revented by the use of a suitable convex glass, on account of the unavoidable ine- e images and of the loss of accommodation in the lensless eye. It is true that, in , the patients learn to avoid the circles of dispersion, and so all disturbance disappears. atly, however, they overcome the latter by entirely suppressing the perceptions of eye, which finally causes dullness of the retina, and, in young patients, amblyopia. ther hand, the objections in case of failure are not unfrequently important, and are ause operation on one eye to appear unadvisable, as long as the other is serviceable. perated on is quickly destroyed and soon becomes quiet, we may at least console hat, besides the loss of the eye, which was blind at any rate, the patient has only the operation and after-treatment to complain of. But the inflammation may r months, with severe pain; then relapses continually occur, and do not cease till e has become cataractous, or perhaps sympathetically inflamed, and during the is time the patient has been prevented from using the sound eye

b. If the cataract is fully formed in one eye, and so far advanced in the other as to cause decided impairment of vision; or if the second eye has, from any cause, become affected in its functional power, or if both eyes are affected with ripe cataract, the operation is to be immediately undertaken, if other circumstances, which can not be removed, do not require its postponement.

The question, whether both eyes shall be operated on at one sitting (where there is binocular ripe, or overripe cataract), may be answered affirmatively in those cases where, after carefully weighing all circumstances, the result appears quite certain. But in proportion as the guarantees for the success of the operation diminish, the considerations against it increase. The most skillful and experienced ophthalmic surgeons contradict each other on this point, and contend with reasons that can not be refuted, but only weigh more or less heavily. (*Ritterich.*)

2. Before operating on a ripe or unripe cataract, there are many other circumstances to be weighed.

a. The condition of the eye itself. In general, it is a rule only to operate when no diseased changes exist in the eye or surrounding parts, which will unfavorably influence the cure after operation, or which, in case the operation succeeds, will diminish the patient's gain to the lowest point.

Thus, inflammations of the globe or its surroundings serve as temporary contraindications except when, after wounds of the capsule, a swelling or dislocated lens gives a mechanical cause for the existence and progress of the inflammation; then, in proportion to the danger connected with the inflammation, the indications become more urgent. Chronic inflammation of the surrounding parts, habitual blepharitis ciliaris, senile conjunctivitis, chronic trachoma, lachrymal blennorrhœa of several years' duration, &c., sometimes, however, form an exception, though they may be troublesome during the after-treatment; for their perfect cure is not unfrequently very difficult, or takes a long time, which is occasionally an important consideration in old persons.

In the same way changes of position in the lids (entropion and ectropion), trichiasis, &c., which expose the eye to external injury, or are even accompanied by direct mechanical irritation, are to be regarded as temporary obstacles to the operation. During their existence, cataractous operation is only justifiable under the most urgent circumstances, and, if it is possible, they should be cured before the operation is undertaken.

If the retina and optic nerve have already lost part of their functional power, the operation is, in most cases, fruitless, or even injurious. Hence, before operating, we should not neglect to examine most carefully the state of the sensitiveness to light and the extent of the visual field, especially when there is passive hyperæmia of the ciliary vessels, traces of precedent inflammation in the deeper parts of the eye, or a decided myopic formation, which disposes to sclerectasia and choroiditis posterior; or, if a conjunctival or diabetic cataract, or an already-developed capsular cataract, or a partly or entirely fluid senile cataract exist, as these are more frequently accompanied by amblyopia than other forms. If decided signs of functional disturbance of the retina are found, the operation is best avoided, unless the patient insist on it, in spite of all representations, or unless the cosmetic effect is of importance, and a slightly dangerous operation promises success. A further exception occurs in cases where existing obtuseness of the retina or the amblyopia may be explained by the long disuse of the eye, as, under such circumstances, suitable use not unfrequently increases the functional power of the retina to a satisfactory extent.

Extensive corneal opacity and pupillary attachments are not contraindications; they only require modifications of the proceeding, and influence the prognosis; for the former threaten a cicatritial keratitis, or at least an increase of the existing corneal opacity; the latter obstruct the escape of the cataract, and the retraction of the divided edges of the capsule.

b. We must also consider the health of the patient, as far as it can influence the removal of the local disturbance caused by the operation, or in any way endanger the result.

Experience teaches that the operation is more dangerous in individuals much depressed by hunger, bad living, affections of the mind; in marasmatic old people, with flabby skin or extensive sclerosis of the arteries; in persons inclined to suppuration and ulceration, and who may,

perhaps, have already lost one eye after a well-performed operation. The prognosis is the worse the severer the operation. Well-pronounced gout, secondary syphilis, tuberculosis or developed scrofula, are also injurious, and render the operation dangerous, particularly at the time of fresh attacks. In drunkards, also, we sometimes have the worst results, especially if delirium tremens occur during the after-treatment. (*Sichel.*) Moreover, experienced surgeons avoid the periods of menstruation or pregnancy; the latter, on account of the danger caused by the frequent vomiting, inability of preserving certain positions of the body, &c., accompanying this condition. On similar grounds, urinary troubles, asthma, chronic bronchial catarrh, &c., are much feared during the after-treatment. Habitual headaches, and especially severe and frequent toothache, nasal catarrh, and inclination to spasms, are to be considered as very disagreeable and even dangerous complications.

c. The age of the patient influences more the choice of the method than the indications for operation.

Childhood is not, as was formerly supposed, a temporary obstacle to the operation. On the contrary, it is at present urged on all sides, that the operation should be done as soon as possible after the cataract is ripe, to anticipate the evil results of a long disuse of the child's eyes. In congenital cataract, the operation may be performed without particular danger in the first months of life; still, between the second and fourth years is considered the most suitable time, as the child is then usually past the most changeable period, while the evil results of the cataract-blindness have not usually attained an incurable grade at that time (*Schön*). Subsequently, in females, the commencement of menstruation, or of the change of life, would seem to indicate delay. Advanced age alone is no contraindication, as more than one centenarian has been operated on with the best results It is only less favorable, because more often accompanied by marasmus and other difficulties (*b*), and also with diminished powers of endurance. Moreover, very old and particularly marasmatic persons suffer from lying quiet, and incline to hypostatic pneumonia, which may even prove fatal.

d. The surroundings of the patient during the after-treatment. A quiet, well-ventilated, dry chamber, which may, as required, be darkened or illuminated; a comfortable, not too warm, bed, with mechanism enabling the patient to sit up without muscular exertion; a well-constructed easy-chair, a bed-pan and urinal; a practised and careful nurse, and suitable diet, are necessary requirements, and if any or all of them are wanting, we had better postpone the operation, especially if it is a severe one. Hence persons not well off should be directed to a hospital, where all these requirements are more easily obtained. Unfortunately, however, in such institutions, the crowding of the patients and other well-known evils most frequently interfere with the otherwise favorable conditions, and actually diminish the percentage of cures.

e. The time of year. In general we may operate at any time of the year with an expectation of success; still, it is better to avoid extensive operations during the hot Summer months, as, during great heat, wounds do not so readily heal by the first intention; moreover, the requisite rest in bed becomes very tiresome, or even unbearable, to the patient; hence the success of the operation is endangered. On the other hand, Winter is objectionable, because patients are confined to their chamber longer and convalescence is greatly protracted.

f. When epidemics, such as cholera, are raging, we should not operate, as depressing affections of the mind, especially great anxiety, impede the cure. The occurrence of hospital gangrene and of diphtheria (*Horner*) forms a direct contraindication to extensive cataract operations, especially in hospitals.

8. Having once determined on operating, the condition of the cataract and the neighboring parts must be carefully determined; for on this depends the choice of the proceeding by which the cataract may be removed from the axis of vision with the greatest ease and least danger.

a. Fluid and pulpy as well as pasty total cataracts, without consistent nuclei, may be easily removed by cutting or tearing the capsule (*division* or *discission*). After such an operation, the cataractous substance usually absorbs quickly and entirely. At the same time the edges of the capsule, which have remained in contact with the margin of the lens, retract, and, if the capsule has been sufficiently divided, the pupil is usually exposed. Under such circumstances the reaction is usually slight, or not difficult to suppress, and this is more apt to be the case as such cataracts usually occur in young persons, where the iris is less sensitive to mechanical irritation, and may easily be kept away from the dislocated fragments of lens by the use of mydriatics.

Resorption does not always go on as we would wish. In cataracts that are not entirely fluid, it not unfrequently happens that, in spite of extensive division of the capsule, while the disintegrated portions are absorbed, the cataractous substance thickens, cakes together, and may remain unchanged for a long while. Then weeks and even months pass before rents appear. These gradually increase in length and breadth, and finally the different pieces fall apart. If the capsule were not sufficiently divided, the edges of the wound unite and protect part or all of the contents from the aqueous, and the operation must be repeated. It is often necessary to operate several times at suitable intervals in order to attain our object. Discission is a very imperfect operation.

Very soft and fluid cataracts may now be removed directly from the eye. It only requires a linear corneal wound (which readily heals), and the opening of the capsule; for the pressure that the recti muscles exercise on the vitreous is propagated to the contents of the capsule, and evacuates it. If any portions remain, they may partly, at least, be removed by a delicate spoon. (*Linear extraction, Paluzzi, Graefe.*)

Compared with division, this operation has the advantage of making no demands on the resorbent powers of the interior parts of the eye, and when perfectly successful, it escapes the dangers arising from the contact of portions of lens with the iris, and the linear incision in the cornea permits the removal by the forceps of any portions of capsule that, from depositions on them, have lost the power of retracting. But along with these advantages are certain dangers. In unruly patients, who strain during the operation, and particularly in children, a portion of the iris is often protruded through the wound with the cataract, and becomes attached there, causing a displacement of the pupil, or the prolapse may become the starting-point for severe inflammation. Frequently, spasmodic contraction of the ocular muscles causes rupture of the anterior wall of the vitreous, the latter escapes through the corneal wound, and pushes the cataract to one side; the operation must be stopped, before its completion. These disadvantages may be escaped by deep anæsthesia, but at the expense of certain advantages, for, if the muscles of the eye are relaxed, the cataract can not escape unaided. Pressure from without, or the frequent introduction of the spoon, are necessary for the removal of the pulp. Notwithstanding these irritating procedures, the scooping-out is often incomplete, for, in spite of instillations of strong solutions of atropine, at the moment the aqueous escapes, the pupil always contracts, and a large part of the interior of the capsule remains inaccessible for the spoon. Moreover, the nausea and vomiting caused by the anæsthetic is unfortunate, as it often induces secondary prolapse of the iris and vitreous.

In olden times, it was thought that very soft and fluid cataracts could be sucked out through a fine tube introduced through the opened capsule. (*Siebel.*) Later, this almost forgotten "*suction method*" was again brought up (*Laugier*), and is said to still have adherents in England. (*Knapp.*) It is evident, however, that cataracts suited for suction will be evacuated on opening the capsule, and still more by passing in a fine tube, and hence there will not be much left to suck up; consequently the operation may well be considered as a *linear extraction with artificial hindrance*. It appears void of all practical value, even if with it there be more attention paid to dividing the capsule extensively, and thus avoiding a secondary cataract.

b. If the lens is not completely softened throughout, if a soft nuclear or a cortical cataract with a cheesy or waxy nucleus, or more especially an unripe or partial cataract, exist, there is no difficulty in the performance of the operation. Its results, however, are often dangerous, as from the swelling of the pieces of cataract, intense iritis is often produced, which occasions extensive posterior synechia or entire closure of the pupil and secondary cataract; it often also progresses to the ciliary body and the choroid, and interferes with the functions of the eye, or eve goes on to suppuration and destroys the globe, under the form of suppurative pan-ophthalmitis or phthisis.

In division, the action of the aqueous on a large surface of the divided lens causes great swelling; but in linear extraction, the shape, direction, and position of the incision, as well as the escape of the aqueous, which causes contraction of the pupil, greatly hinder the spontaneous evacuation of the denser portions of cataract, and, moreover, do not permit a complete breaking up, and subsequent scooping out, as a large part of the interior of the capsule is inaccessible for instruments. If the cataractous remains adhere to the capsule, they can not be detached without employing too much force, even at the places that can be reached by the spoon; so that the diminution in size caused by the division is more than balanced by the irritation following the operation, and by the bad effects of the so frequently-occurring prolapses of the iris, &c.

The dangers from division and simple linear extraction of partly-disintegrated cataracts may, it is true, be lessened by combining these operations with a preliminary or coincident iridectomy. (*Graefe.*) Still, this combination is but an imperfect protection, especially in discission, where the whole cataract remains in the eye, and some of its fragments may be displaced, fall into the anterior chamber, &c. On the other hand, in linear extraction, iridectomy has the advantage of increasing the accessibility to the capsule, and thus favoring the complete evacuation of the lens. Still, the size of the linear corneal wound is always too small to fully answer its purpose. A linear, slightly gaping wound of the cornea, can never permit the spontaneous escape of a consistent cataract: a *spoon* is required. But, from the position of the wound, the spoon must act at a great angle; it can only seize the lens-matter by pressing against the cornea and iris. The less firm parts of the cataracts are always crushed at the first touch of the spoon, and a considerable portion of that in the instrument is carried off by the edge of the contracted corneal opening. At the same time, the parts left behind are scattered in all directions through the aqueous chamber, by the pressure of the scoop and the vitreous. They can only be removed by its frequent introduction, which is very irritating, and rarely perfectly successful, as the pellucidity of the particles prevents their recognition; and, moreover, the danger of a prolapse of the vitreous urges a speedy termination of the operation.

These objections are only partly overcome by making the section at the outermost border of the cornea, or even a little beyond it, and making it a little longer by using a broader, lance-shaped knife. Experience shows that, even then, the angle at which the scoop acts on the lens, as well as the pressure, is still so great, that the lens breaks on being seized. But even if it is brought to the mouth of the wound, it can not pass until its size is diminished. If, however, the nucleus is too firm to break up, the stretching of the angles of the wound becomes dangerous. Moreover, we have the lever-like action of the instrument causing contusion, and often prolapses, as well as inflammatory cloudiness of the vitreous; the latter does not always recede. In consideration of these points, we can ascribe no true practical value to the operation, which has lately been described as spooning out of the cataract, and has been advised even for hard, nuclear cataract. (*Schuft.*) It has indeed found but few friends, as the experiments made with it have not been very satisfactory. (*Mooren, Rothmund, Graefe, Steffan, Dantone.*) Even the more suitable shape of the spoon (*Critchett, Bowman*), or the substitution of a single (*Graefe*) or double hook (*A. Weber*), which have rendered possible a more safe and certain seizure of the cataract, have not rendered the spoon-operation more popular.

If we wish to remove cataracts from the eye which have a half-soft or normally-consistent nucleus, without leaving any remains behind, and without injurious handling of the eye, the wound must be made much longer and must gape wider than can be effected with the lance-shaped knife, and the desired end can only be attained by the methods employed for the removal of senile cataracts.

c. In cataracts with sclerosed nucleus, discision is in itself very difficult of execution, since the nucleus constantly turns aside from the needle, on account of the lack of a resistant substratum, and on account of its hardness. In the best case we only succeed in breaking up the lens into large pieces, which then usually excite very intense inflammation and thus become destructive to the globe in the great majority of cases. Depression was formerly, and for a long time, used to displace hard cataracts of this kind, and to depress them in the lower and outer part of the vitreous humor (depression or reclination).

To this end a straight cataract needle is thrust through the sclera, into the anterior chamber, close to the temporal portion of the ciliary processes and past the pupillary margin, through the periphery of the lens, pushed along as far as the upper and inner edge of the optic foramen, then turned flat over the center of the cataract, and then a gentle, gradually increasing pressure is exerted upon the latter, so that the lens may be loosened from its connection with the zonula throughout as great an extent as possible. This being done, the handle of the needle is raised in the meridian plane of the point of entrance, and thus the cataract with the capsule is depressed into the lower and outer part of the vitreous humor. By a slight turning of the needle upon its axis, the point, which easily catches in the depressed portions of the cataract, becomes free, and can be drawn flatly from the wound without danger that in this maneuver the cataract will follow, and reach a spot in which it may cleave less closely, or could even endanger the vascular tissues of the globe.

This procedure is still applicable in cases of a very large sclerosed nucleus, and proportionately thin but tough cortex. In a very thick cortical layer, especially if it is soft, depression has the disadvantage, that the largest part of the cortex is stripped off in its entrance into the wound of the vitreous, that is to say, remains behind in the posterior chamber and there causes the same dangers which make us fear the discision of senile cataract. The chief danger, however, lies in chronic inflammations of the choroid of manifold character, which are excited by the dislocated nucleus as a foreign body, often do not appear until weeks, months, and even years have elapsed, and destroy the globe, usually with very great and tedious sufferings, and even often affect the second eye sympathetically.

In view of all this, extraction appears as the only justifiable method for such cataracts. If this method, however, is to be less dangerous than discision and depression, the extraction of the cataract must be effected by the muscular pressure, and can only be assisted by careful manipulation. It is further necessary that the stripping off of the disintegrated, or still normally consistent cortex, be as little as possible, and that all laceration of the parts, particularly of the angles of the wound, be avoided. These demands can only be satisfied by a wound in the peripherical zone of the cornea, or in the most anterior scleral margin, a wound the plane of which cuts the corneal axis far in front of the center of curvature of both surfaces of the cornea, at almost a right angle, and thus fixes the limits of a flap, the base of which at least corresponds to the equatorial diameter of the nucleus of the cataract, and which, at the vertex, allows of a gaping, corresponding to the axis of the cataractous nucleus.

The tranverse diameter of the crystalline lens is at most 10 millm., the axis, 4 millms. long (*Henle*). The horizontal perimeter of the lens should hence be reckoned, in the maximum, at less than 23 millms. If it were a question of removing completely every cataract from the eyes, without laceration of the angles of the wound, and without stripping off the cortical layers, the length of the section must at least equal more than half the axis of the transverse diameter of the lens, and

therefore, for the largest cataracts, reach 12 millms. In practice, however, this demand is modified by the quality of the cortical layers. In fact, a cataract inclosed in the uninjured capsule may be evacuated through a much smaller opening without any dangerous laceration of the edges of the wound, since the soft cortex yields easily, and the cataract stretches thus somewhat in length. If, however, the capsule remains behind in the eye, the cataract does not reach, in its entirety, the wound in the sclera; a part of the superficial soft cortical layer is rather always stripped off at the edges of the wound in the opening of the capsule and at the border of the natural or artificial pupil. If the cortical layers are still of normal consistency, a large portion of them remains adherent, in the form of a shell, to the inner half of the capsule, and only the nucleus comes out. In every case, therefore, the cataract is rendered considerably smaller in the relative dimensions before its exit, which admits of a diminution in the length of the wound. Among about three hundred and fifty extracted cataracts, preserved in a weak solution of alcohol, were only two deep coffee-brown nuclei divested of the cortex, the equatorial diameter of which measured 7.6 and 7.4 millm., the axis 3.5 and 3.2 millm. Only a few of the remaining nuclei approached these dimensions, the rest were much smaller. If, therefore, we wish to avoid the laceration of the angles and edges of the wound, the length of the wound must, in all cases, be a little more than 9.4 millm. If, however, we wish to extract the cataract easily, and diminish the stripping off of the cortex to the minimum, an enlargement of the length of the wound is urgently demanded on account of the stiffness of the cornea; the wound should not measure less than 10 millm., in order that a sufficient gaping in the middle of the flap may be rendered possible.

The opening in the posterior corneal surface now measures in the middle about 11 millm. (*Ed. Jaeger.*) With a radius of curvature of 6.7 millm., the length of a meridian of the posterior corneal surface would be estimated at about 13 millm. A section running in the horizontal meridian of the eye, bisecting the internal surface of the cornea, must therefore create a wound whose circumference measures about 26 millm. Such an opening, however, so far exceeds the horizontal circumference of the lens, that from the side of the cornea no serious hindrance can result to the exit even of very large cataracts.

In fact, such a section, for the purpose of an extraction of cataracts, has been proposed, and with it also satisfactory results have been obtained in a number of cases (Tranverse extraction, *Küchler*).

It is, however, evident that the cicatrix of a wound passing transversely across the pupil, must very considerably diminish the power of vision in the operated eye. In addition, it happens that the power of gaping of an incision running in one of the greatest circles of the ideal corneal globe is very small, on account of the stiffness of the corneal substance. Hence only a very small zone of the iris is laid bare in the wound, and as the remainder is at the same time pinned between the cataract and posterior corneal surface, must experience, relatively, a very considerable stretching, in order that the cataract may come out through the pupil.

An extraction of the cataract in this way cannot be effected without stripping off a good deal of the cortical layers. Furthermore, it is to be considered that the cataractous nucleus, in order to reach the wound, must complete an almost right-angled rotation around its tranverse diameter, which, with the greatness of the resistance opposing such a movement, is only possible by the aid of violent manipulations, and must usually bring along with it a crumbling of the superficial

cataractous layers. This drawback can, of course, be a little lessened by removing somewhat the plane of the incision from the greatest diameter of the cornea. In order, however, that the cataract may be removed from the eye without very excessive rotation, the section must fall, in its entire length, between the scleral border and the equator of the nucleus. The length of an incision passing through the middle point of curvature which is so far distant from the vertex of the cornea, would, however, be considerably less than is required. A peripherical corneal incision which should admit of the lens coming out with a very small rotation, cannot hence lie in one of the largest segments of an ideal corneal globe, but must cut the axis of the cornea at almost a right angle, far in front of the center of curvature of the posterior surface of the cornea, and therefore form the arc of a section of a circle.

A curved incision running in the circle of origin of the ligamentum pectinatum and bisecting it, reaches, with a radius of the whole circle of origin of 5.5 millm., the length of about 17 millm., therefore gives us a wound with a circumference far exceeding the horizontal circumference of the largest lens. The resistance which is opposed in such a curved incision to the exit of the cataract is very small, since the already limited flap, by reason of its height and breadth, can easily yield to the pressure of the cataract pressing forward from the vitreous; and as half of the iris is already deprived of its support, hence a corresponding dilatation of the pupil may occur without any considerable laceration of the iris. Such an incision is, however, rendered very difficult by the anatomical relations. The middle portion of the iris and lens projects considerably beyond the plane of origin of the ligamentum pectinatum. The knife must hence be introduced in the curve through the anterior chamber, and must push back the vertex of the lens in making its exit, by which means the peripherical portion of the iris is easily carried under the edge of the knife. Moreover, an incision running in the circle of origin of the ligamentum pectinatum presupposes an uncommonly broad wound; the external edge of the wound must fall for about 1 millm. in the sclera and limbus conjunctivalis, since the scleral border reaches perceptibly farther forward on the anterior surface of the cornea than on the posterior. Moreover, positive disadvantages are also attached to such a maximum flap incision. Its position and enormous power of gaping take away every support from the anterior portion of the zonula, the latter ruptures, as it is exposed to the entire pressure of the vitreous, and leads to serious losses of the latter fluid; often enough, a portion of the corpus vitreum is even evacuated before the cataract, and then makes the extraction of the latter extremely difficult, sometimes almost impossible. Besides this, the iris, after the operation, is pushed into the wound by the vitreous humor pressing forward, and thus a generally very extensive prolapse of the iris is occasioned, which not only hinders the healing of the wound, but is in a position to endanger, in a high degree, the success of the operation, by exciting violent inflammation, and by distortion and displacement of the pupil. We can only partially obviate these drawbacks by undertaking the operation under deep anæsthesia of the patient, and by excision of a broad piece of iris (*Jacobson*).

Hence it appears more advisable to limit the height and breadth of the flap, to the oft-tried, established measure.

At any rate, a flap whose internal edge is distant about half a millm. from the circle of origin of the ligamentum pectinatum, and in which both angles of the wound are situated in the horizontal meridian of the cornea, is sufficient to extract

even very large cataracts under slight resistance, as a rule, even by the pressure of the vitreous humor alone. In cataracts with smaller nuclei, and pulpy or fluid cortex, the points of entrance and exit should fall at some distance from the horizontal diameter of the cornea, and thus the height of the flap be shortened. Such a flap, of slighter breadth and height, affords the important advantage of an easier adjustment and surer healing. Besides this, the support which the iris and zonula find in the broad peripherical border of the wound is usually sufficient to prevent prolapses of the iris and vitreous humor during and after the operation, therefore makes it unnecessary to excise the iris, which, especially in young persons, not only is of cosmetic importance, but also increases somewhat the functional activity of the eye.

The flap extraction, with the curved section of the cornea, as has long been practiced, is a tolerably dangerous undertaking, and demands a very sure and practiced hand, as well as an exact knowledge of all possible accidents, and the means necessary to avert them; therefore a rich experience, if a satisfactory result is to be expected.

Iritis occurs much more frequently than suppuration of the cornea, after flap extractions. Slight iritis almost always occurs. In most cases it leaves behind partial cicatricial retractions of the pupillary margin, and partial attachments of this to the remains of the capsule, which, however, usually cause but slight impairment of vision. Quite often, however, the proliferating process is very intense, and causes extensive posterior synechia or complete closure of the pupil; not unfrequently it extends to the ciliary processes and the choroid, and impairs the functional activity of the eye, or even causes atrophy. Sometimes the process assumes a suppurative character, and the eye-ball quickly atrophies, or is destroyed by phthisis after suppuration of the cornea.

This destructive iritis rarely appears till after the second day; it is usually first discovered from the fourth to the tenth day, or later. It is much to be feared when the nucleus is hard and large, as well as when the evacuation of the cataract is difficult on account of insufficient size of the corneal wound, or from cicatricial or spastic contraction of the pupil, and causes tension or bruising of the iris, and also where the manipulation was rough, or repeated introduction of the spoon was necessary for the removal of the cortical masses. The usual cause, however, is the retention of large pieces of cataract, or, still more, of a thick layer of normally consistent cortical substance attached to the capsule, and capable of swelling. These usually proliferate luxuriantly, and to the *mechanical* irritation of the swollen particles add the *vital* irritation of inflammation (*Graefe*), thus in a double manner exciting the iris to reaction. Beside the results of uveitis, there are extensive secondary cataracts. Sometimes the immediate and chief causes of iritis is a prolapse through the flap-wound, and consequent adhesion and bruising of the iris. Then the process quickly becomes chronic. Exceptionally, it is accompanied by severe ciliary irritation, and it may then endanger the second eye sympathetically. (*Critchett.*)

The dangers resulting from mechanical irritation in flap extractions, as in other cataract operations, may be lessened by performing an iridectomy several weeks previously, or at the same time. (*Wenzel, Richter, Graefe.*)

For we thus considerably increase the space for the escape of the cataract, and avoid bruising the iris and stripping off the cortical substance. If the pupillary margin has been already

bruised by the escaping cataract, we may remove the injured portion, and prevent its affecting the healing process. Moreover, we facilitate the access to any retained portions of cataract, and are often enabled to remove them with the scoop without injury to the parts. But if portions of the cataract must still be left, the diminution of the points of contact with the iris, and its relaxation, decidedly decrease the irritation. Besides all this, extensive prolapse of the iris is avoided, and in a wide pupil a partial cicatricial contraction of the borders or a partial posterior synechia cannot cause so much injury as if the pupil is of normal size; and after a large iridectomy, a complete closure of the pupil does not occur so readily as if the central zone of the iris is entire.

According to the above, the combined operation is urgently indicated in cataracts with pulpy, chalky, or normally consistent cortices, which are adherent to the capsule, when the pupil dilates but slightly on the use of atropine, and hence threatens to offer great opposition to the escape of the cataract; when the corneal wound is too small, and the escape of the lens is difficult, or the iris has been bruised; but particularly when, from any cause, portions of the cataract are left in the eye. (*Arlt.*) It is also well to perform an iridectomy, when the general state of the patient or of the eye is not favorable to the healing of the wound.

It is, however, going too far to say, as some do (*Mooren*), that iridectomy should be performed in *all* cases of flap extraction. Under favorable general and local conditions and successful termination of the operation, the dangers of flap extraction are not sufficient to counterbalance the disadvantages to vision from a broad artificial pupil; for with strong illumination the latter causes painful dazzling, and, in proportion to its size, increases the circles of dispersion that fall on the retina, which is, of course, doubly felt from the entire absence of accommodation. The clearness of eccentric vision, and the capacity of the patient for seeing around him, when he wears spectacles (*Graefe*), are much impaired, for the deviation of marginal rays becomes very evident, on account of the deficient arrest of the rays by the iris.

Quite recently, *tapping the vitreous* has been recommended as a substitute for iridectomy. The results attained by it entitle it at least to trial. It is thought that the dangers of secondary cataract, iritis, closure of the pupil, choroiditis, and even unfavorable healing of the cornea may be greatly lessened by it, and that the optical effect is much better than by any other operation. Immediately after the escape of the cataract, the puncture should be made with a needle, by passing it through the posterior capsule at the center of the lenticular fossa. The immediate result is the escape of some vitreous into the anterior chamber, a slight dilatation of the pupil, and a bulging forward of the previously relaxed cornea. At the same time the capsule changes to a ring-shaped pad, and is removed from the region of the pupil, which then appears quite clear, and permits considerable sharpness of vision. (*Hasner.*)

The size of the artificially produced prolapse of the vitreous does not, however, lie entirely in the hands of the operator, and as a large prolapse easily occasions injury to the eye, the method seems hazardous.

Others, who consider the retention of portions of cataract as the source of all danger, advise the extraction of the cataract and capsule entire. (*Pagenstecher.*) This sometimes succeeds very readily in cataracts far advanced in retrogressive metamorphosis, whose capsules have become tough and hard from calcareous deposits, and are but slightly attached to the lenticular fossa. In primary cataracts, on the contrary, such attempts are difficult, as may be readily conceived from the rules of operation above given. We first require a large incision downward, to comprise half the circumference, and to make it longer; this should be beyond the margin of the cornea. To facilitate still more the access to the lens, a large portion of iris should be excised, and any existing adhesions of the pupillary margin to the anterior capsule should be broken up with a hook. If the lens cannot now be luxated by a slight pressure on the anterior scleral zone, a spoon should be passed behind it, and it, with its capsule, should be thus extracted. If, however, the zonula is too firmly attached, it should be first loosened with a hook, so as to free the capsule. Since the danger of large prolapse of the vitreous is increased by this manipulation, perfect anæsthesia is considered indispensable, in spite of

which this accident cannot be wholly avoided, and may prove very injurious. If by this method we do escape secondary cataracts, this advantage is fully balanced by the frequent occurrence of inflammatory cloudiness of the vitreous, which requires months to clear up, or may never pass away. Attempts have not in fact proved very inviting. (*Knapp, Bergmann, Wecker, Steffan.*)

The chief danger of the flap extraction with the corneal section lies, however, in suppuration of the cornea. This is caused sometimes by awkwardness of the operator, but chiefly by too small and too oblique an incision. An incision which is too oblique, splits the cornea for a distance into two very thin laminæ, and the conditions for their nutrition are very unfavorable. Moreover, the inner edge of the wound under such circumstances narrows the opening very considerably, and is put very much on the stretch during the exit of the cataract, and is not uncommonly torn, which renders an immediate healing very difficult, without regarding the mechanical irritation of the wound. In other cases, the suppurative inflammation is caused by restlessness of the patient after the operation, particularly by forcible opening of the already adherent flap, in consequence of accidental wounds or momentary increase of the intraocular pressure in coughing, sneezing, etc. The patient's constitution also exerts an influence. According to experience, phthisis of the cornea is more threatening in persons in whom wounds of other parts of the body easily take on a suppurative action; further, in people with a rigid sclera and atheromatous vessels, and in individuals of a marasmatic tendency, who have been weakened by age, disease, misery, depressing mental affections, etc., and who have a toneless, withered, faded skin, covered by dry, cracked epidermis. (*Graefe, Mooren.*)

In the majority of cases, however, the operation itself is the cause of the suppuration, since it makes its appearance after the best executed flap extractions, with the best behavior on the part of the patient, and under apparently the most favorable conditions.

Its principal source is then, without doubt, to be sought in the incomplete adaptation of the edge of the flap to the peripherical border of the wound. As elsewhere, so also with the cornea, an exact coaptation of the raw surfaces is the indispensable condition for their direct reunion. The danger of suppuration is relatively so much the greater, the more unfavorable the conditions are for the correct position of the flap, the more the vitreous humor is evacuated in the operation, and the greater the change of curvature of the anterior surface of the globe caused by it becomes; further, the more extensive but especially the higher the flap thus formed is, and therefore the easier this can yield to the pressure of the contents of the globe acting on it from behind. Furthermore, the direct reunion of the flap is often hindered by the intervening of parts of iris, of vitreous humor, of remains of capsule or of cataract, and thus the phthisis of the cornea favored.

It is considered by many observers, that the suppuration of the cornea is always secondary, and connected with the existence of a suppurative irido-choroiditis, and that the latter is always caused by the remains of cortical lens matter which have swollen. (*Arlt, Mooren.*) A careful observation of the changes occurring in the eye after extraction (*Jacobson, Sichel, Pagenstecher*), has, however, proved the opposite to be the rule. Moreover, suppuration of the cornea, with complete integrity of the uveal tract, has been seen in the cadaver (*Schweigger*), and the still unclouded condition of the power of perceiving light, when the infiltration of the cornea has already rapidly advanced, renders the assumption of a suppurative affection of the deeper tissues of the globe not to be thought of (*Graefe*). In regard to the second part of this opinion, it must be considered that the phthisis of the cornea occurs even after com-

plete evacuation of the lens, and even after extractions in which the cataract was removed together with the capsule from the eye. It has also been observed once in an eye which was destitute of iris (*Graefe*).

The suppuration of the cornea begins in the margins of the wound, which soon become cloudy, and swell with purulent products. The infiltration then proceeds from the angles of the wound to the peripherical portions of that segment of the cornea which has not been incised, so that a circular band of purulent infiltration appears, within which the corneal tissue seems at first only slightly cloudy and swollen, but rapidly assumes the yellow color of pus and dissolves with considerable swelling. It then comes away in shreds, or else shrinks to a sort of slough, which drops off as a whole. The globe is then destroyed by suppurative panophthalmitis.

Still the suppuration is sometimes limited to the margins of the wound, or at most a circumscribed band of pus may be developed. In favorable cases the process may then again recede, so that the edges of the wound may heal by a cicatrix of varying extent. Much more often, however, the inflammation soon advances under such conditions to the iris, and then to the deeper tissues of the eye. Atrophy of the globe is then frequently the result, and in case large quantities of pus exist in the interior of the eye, a subsequent suppuration of the cornea, partial or entire, occurs, with consecutive phthisis bulbi. (*Graefe, Jacobson.*)

In very rare cases, a dense, purulent, yellow infiltration is said to be met with at the end of the second or third week at one point in the wound, and soon destroys the cornea by its rapid extension to the entire flap. This affection is said to begin with increasing sensibility and swelling of the conjunctiva and soon becomes involved by a suppurative iritis. (*Graefe.*)

In order to prevent the suppuration of the cornea occasioned by the incomplete coaptation of the flap, an iridectomy does not suffice. We should expect just as little from a union of the two edges of the wound by sutures. (*Williams.*)

The indication is rather towards lessening the gaping, that is to say, the incision should be as short and linear as possible. The necessary length of the wound is, however, determined by the horizontal diameter of the nucleus of the cararact, and cannot be shortened without causing other important drawbacks. The incision in the scleral border is therefore justified from one point of view. The circumference of the anterior scleral border is at any rate larger than that of the peripherica corneal zone, and a curved incision made in the first will with the same length represent a so much smaller part of the whole circumference, and will therefore approach its chord so much the more, the further the plane of incision is removed from the cornea. Still this advantage is not obtained without a sacrifice. The slight power of gaping of a flap-wound removed outwards into the anterior scleral margin, in connection with the anatomical position of the iris and cataract, necessarily occasion the excision of a corresponding piece of iris.

If by these means, as well as by the thorough incision of the anterior capsule, every impediment to the free exit of the cataract is done away with, then a slight pressure exerted upon the portion of the corneal margin opposite the wound as a rule suffices for the evacuation of the cataract. As the vitreous humor presses at the same time from behind forward, and the cataract is therefore affected by two forces acting in an obliquely opposite direction to each other, it must advance towards the wound in the direction of the resulting force, and pass through the latter with a very inconsiderable rotation. If this maneuver does not at once succeed in causing the exit, the cataract may be extracted without difficulty with the spoon without injury to the iris. The instrument may be easily passed in a straight direc-

tion from the wound towards the equator of the lens and behind it, and then pushed forward to its opposite margin. The cataract then lies in the hollow of the instrument, and its somewhat projecting anterior angle embraces the equator of the lens firmly enough to cause it to follow its course outward. The lever movement is here very slight; the cataract glides away behind the iris without injuring it to any considerable degree. Even the more compact cortical layers adherent to the capsule may be detached by the edge of the spoon, without any dangerous pressure upon the iris, and extracted, and hence flakes already loosened so much the more easily.

The curved incision in the scleral margin and the expulsion of the cataract through the peripherical wound renders necessary a number of instruments and manipulations, which are very different from those employed in the flap extraction, and hence force us to regard and describe the method as a peculiar one. It has been proposed to call it the "modified linear extraction," "extraction by the peripherical linear incision," and "extraction by the scleral incision." All these names are, however, but little appropriate. In the absence of a better designation, however, the name "extraction by the peripherical linear incision," which the inventor (*Graefe*) regards as most appropriate, may for the present remain in use.

Strictly speaking, from the reasons above mentioned, this is not really a *linear* wound, even when we consider merely the external edge of the wound and entirely disregard the position of the surface of the wound to the corneal axis. The mistake in the name is seen in a still more glaring manner, when we observe the internal opening of the wound more closely. According to anatomical requirements, and to those mechanical conditions which admit of the easiest possible extraction of a cataract, this should be connected with the circle of origin of the ligamentum pectinatum. The radius of this circle measures in the middle 5.5 millm. The minimum length of wound for the largest senile cataract amounts to 10 millm. The name "scleral incision" is just as little appropriate, since the surface of the wound, accordig to anatomical investigations, only falls in the scleral tissue with its most external zone, and by far the greater part lies in the cornea. At the same time there is hence explained the mistake of those who suppose that the main advantage of the peripherical linear incision is to be found in making the surface of the wound in the sclerotic.

The results which have hitherto been obtained, in a large number of cases, with the peripherical linear incision, are incontestably very satisfactory, and entirely qualified to maintain the supposition of a causal connection between phthisis of the cornea and a greater gaping of the wound. If we include together everything that we ourselves have observed, read and heard, as it were, in private conversation, we may conclude that the proportion per centum of suppuration of the cornea is less in the peripherical linear incision than in the curved incision of the cornea; that this advantage, however, is again counterbalanced by the greater frequency of destructive inflammations in the uveal tract, especially of iridocyclitis and iridochoroiditis with the formation of membraniform obstructions. This state of things is explained in great part because it is more difficult to split the anterior capsule which presses forwards against the posterior surface of the cornea, and because of the unavoidable healing of the edges of the iris in the angles of the curved wound, because of the more frequent and not uncommonly late effusions of blood into the anterior chamber, and because of the somewhat increased frequency of the very dangerous losses of vitreous humor. It is very difficult to express this proportion in definite numbers. According to careful statistical reports (*Dantone*), the unconcealed total losses of the eye vary between 2% (*Knapp*), and 6.4% (*Hoering*), even 28% (*Ed. Jaeger*). Incomplete successes, in which the

acuteness of vision sank to $\frac{1}{4}$, yielded from 2% (*Horner*), to 20% (*Knapp*). Complete successes were numbered from 74% (*Hoering*), to 90% (*Graefe*). The view which is taken of results is influenced very much by the temperament, the more or less dependent position of the statistician, and several other motives. But the old flap extraction is looked at very unfavorably, while the peripherical linear incision is regarded with great favor. In addition comes a very important circumstance, namely, that the great advances of recent times, which have been made in the knowledge of the causes of bad success and in the after-treatment, have come to the aid of the extraction with the peripherical linear incision, but not of the flap-extraction, since nearly all of the ophthalmologists, at the first instant, have thrown overboard the older method and have followed the new banner with enthusiasm, in order perhaps to forsake it at the very next instant. The old flap-extraction is really far better than its present reputation, even when we entirely disregard the fact that with the marginal flap section, to which all the faults to be avoided by the peripherical linear incision cling most decidedly, results hitherto unsurpassed were obtained. This method gave, namely, in 78.5% a visual acuteness of $\frac{1}{4}$–$\frac{1}{1}$, in 19.6% a visual acuteness of $\frac{1}{10}$–$\frac{1}{20}$, and in 1.9%, phthisis of the globe. (*Jacobson.*)

Among 287 recorded cases the simple flap extraction gave 71.77% direct complete successes, that is, the patients left the clinic with normally wide pupil, entirely or in great part movable, and a normally acting retina, so that with the corresponding glasses they could either read medium type, at about 12″ distance, or might expect to after the lapse of a few weeks; although it might then be that the posterior capsule had subsequently become opaque and made a secondary operation necessary. Incomplete successes, which in the best cases admitted of the recognition of large type at 12″ distance, and of going about alone, numbered 21.60%; still the half of these could be brought to a complete success by a subsequent operation. 2.09% of the eyes became atrophic in consequence of iridochoroiditis, 4.52% were destroyed by suppuration. Among the 47 cases last operated on were 5 in which the one eye, after extraction with the peripherical linear incision, had been, under another surgeon, destroyed by suppuration. [Probably Stellwag's own cases.] In 4 of these cases complete success was obtained by the flap-extraction, in one iridocyclitis, with closure of the pupil, occurred, and here an iridectomy, with rupture of the false membranes, restored the power of vision so that the patient could move about alone.

By the peripherical linear incision there were in 44 cases 70.45% of complete success; 20.45% incomplete results were obtained, of which about half, perhaps, might be essentially improved; in 4.54% phthisis of the cornea appeared, and in the same number atrophy of the globe. Among these cases there were 25 in which both eyes were operated upon at one and the same sitting, the right one always by the peripherical linear incision, the left one by the curved corneal section. The success was 13 times complete in both eyes, 6 times incomplete in the left and once complete in the right; 4 times the opposite proportion occurred; twice, the success in both eyes was incomplete at the time of the patients' discharge. A loss of an eye did not occur in any case.

[There seems to be a want of uniformity now existing among operators, in regard to testing the vision of cataract patients, which has a tendency, to say the least, to create confusion, not only as to the results of different operators, which is of comparatively small importance, but also as to the merits of the method of operating itself, which is of vast importance.]

[The ideas of American ophthalmologists have materially changed of late as regards the method of operation to be in general employed. The peripherical linear incision of *Von Graefe* has undoubtedly received a fair trial in this country where manual dexterity in operating is very marked, and from the results gained experience has led many of our surgeons to abandon it as unsatisfactory. Many of the American operators now evince a predilection for the old corneal flap operation, but the use of Beer's knife has generally been given up, and the corneal incision is now made with the narrow knife of *von Graefe*. The discussion between Drs. Loring and Hasket Derby, in regard to the results obtained from the two operations, at least shows that the difference in these results is of no material importance, while the greater difficulty of the peripherical incision is still admitted (*Boston Medical and Surgical Journal*, 1872).

The discussion in this country of the subject of cataract and its treatment being an almost every-day occurrence, American surgeons have been led to modify materially the after-treatment. The patients are not confined to their beds as long as formerly, and surgeons are not as particular in excluding every ray of light. A few turns of a flannel roller bandage, or even a piece of black silk placed over the eyes and retained in position by strips of adhesive plaster, is all that is ever used, and then the room is moderately darkened for several days.]

On the whole, the results of both methods seem to be tolerably equally balanced. He who regards the greater difficulty and duration of the operation, as well as the excision of the iris, as insignificant, and strives to obtain the largest possible number of medium successes, will be, perhaps, best satisfied with the peripherical linear incision. He, however, who sees important advantages in the elegance, simplicity and rapidity of the operative act, in the ease and safety of the extraction of the cataract, and wishes to obtain faultless results approaching the ideal, and will, of course, comprise in the bargain one or more losses, will always return to the flap-extraction, and seek to moderate its drawbacks as much as possible, without, however, rejecting entirely the peripherical linear incision. Where the predominant conditions seem to favor corneal suppuration; where extensive cicatrices occupy the space for the flap incision, and at the same time render it necessary to make an artificial pupil; where all the conditions for the development of an acute glaucoma are present, or one eye is even suffering from this affection, and therefore an iridectomy would be necessary at no distant period: here it is in fact advisable to choose the peripherical linear incision. The same holds good in those cases in which the strict regimen, indispensable after the flap-extraction, should become unbearable and even dangerous to the bodily condition of the patient; for in the peripherical linear incision the separation of the already united raw edges is much less threatening than in the flap incision, and hence essential alleviations in the position and diet of the patient might be allowed even in the first days after the operation.

Some have also claimed that the peripherical incision heals in a shorter time. Still, this can only be recognized for those cases which run a normal course. Those in which the course towards a cure is abnormal, and their number is not small (41.5%, *Dantone*), again outweigh this advantage, in so far as the chronic iridocyclitis and iridochoroiditis with their consequences are somewhat more frequent, and the not uncommon cystoid cicatrices often trouble the patient for a long time.

A more cogent reason for the superiority of the peripherical linear incision over the flap incision appears to lie in the slighter astigmatic difference, which the eyes

operated upon by the first method show (*Reuss, Woinow*). Still we should here consider that the astigmatism, which usually follows the extraction of a cataract, grows less some time after the operation, and that, in case it remained somewhat greater after the flap incision, the difference would scarcely ever be so great, that cylindrical glasses could not equalize it. It is, however, particularly to be borne in mind, that even a greater and more irregular astigmatism after a regular flap extraction must become subjectively less perceptible by reason of the slighter width and central position of the pupil, than after the peripherical linear incision when combined with iridectomy.

There have also been attempts made to moderate or even to do away with the drawbacks attached to extraction with the peripherical linear incision. Thus, the extraction of the lens in the uninjured capsule has been recommended, just as in the flap extraction, in order to avoid leaving behind any remains of the cataract, and it is even believed that this can be accomplished without excising the iris. To this end, after the peripherical linear incision has been made, a cataract spoon is to be introduced into the pupil, with its convexity turned towards the lens, the edge of the lens is to be pushed aside, and the zonula separated with the edge of the spoon; then the instrument is to be pushed behind the lens into the lenticular fossa, and the lens drawn out as a whole through the wound. The ease, safety and excellence of the result is praised (*Gioppi, Hasner*). It will be well to wait for further trials of this operation before deciding.

The chief danger, however, lies in chronic choroidal inflammations, which are excited by the dislocated lens acting as a foreign body. These occur after weeks, months, or even years, and after severe and tedious suffering they destroy the eye, and may even sympathetically affect the other one. The percentage of bad results from this accident is quite large; hence, at present, depression is almost abandoned.

d. In overripe cataract the calcareous deposits on the inner wall of the capsule require the utmost care. They prevent the retraction of the flaps of capsule formed by the operation; therefore, even when the capsule has been freely divided, cloudy remnants of it are left in the pupil, and are difficult to remove, and greatly impair vision.

Simple discission is then less serviceable, even when the lens is disintegrated, and forms a fatty, chalky pulp. If the latter contain granular, chalky matter, this may enter the anterior chamber and prove the more irritating, as it is dissolved slowly and is not readily removed. In some rare cases the chalky masses have been seen to adhere to the rough surface of the iris, and also to form a deposit on the posterior wall of the cornea, which greatly impaired vision.

In retrogressive fluid total cataracts, linear extraction answers best. In such cases, however, the aqueous should be allowed to escape before the capsule is opened, so that, the crystalline being pressed against the iris and cornea by the vitreous, the aqueous chamber may be reduced to nothing, while the milky fluid is escaping. It is also well to make the incision nearer the center of the cornea than usual, so that the opening may not be covered when the pupil contracts during the escape of the aqueous. Of course, in such cases, the capsule cannot be very freely divided; sometimes we can draw most of it out; most frequently, however, the attempt is unsuccessful. Then a secondary cataract remains, which must be subsequently removed.

In consideration of this, it has been advised not to open the cornea with a lance-shaped knife, but with a large cataract-needle, whose neck closes the wound and prevents the escape

of the aqueous, thus keeping the capsule at such a distance from Descemet's membrane that it may be divided. (*Graefe.*) But then, of course, the cataractous remains will escape into the aqueous chamber, and there prove injurious. Hence the method is unsatisfactory.

In dry capsular cataracts, as well as in all shrunken cataracts with tough capsules, thickened by firm deposits, and having pulpy nuclei, simple linear extraction is to be preferred to all other operations, and has been employed for many years, (*Friedr. Jaeger*). Such cataracts are readily drawn out whole, by a hook or forceps, and may easily be removed through a linear incision. For, in such cases, the zonula is atrophied and is easily torn, and the posterior capsule is not very adherent to the lenticular fossa.

Dry capsular and secondary cataracts may also be removed through a scleral wound. Formerly this operation was quite popular, but it has long been neglected, and it offers no peculiar advantages over linear extraction through the corneal wound. A meridional incision, about three lines long, is made on the temporal side of the sclera, about two lines below the horizontal diameter, with its anterior end about the same distance from the margin of the cornea. Then a delicate-toothed forceps or iris-hook is introduced and passed through the vitreous to the cataract, which is then seized and withdrawn. (*Sichel, Desmarres.*)

Overripe cataracts, with sclerosed or normally consistent nuclei, should be removed by flap or modified linear extraction. But we should always attempt to remove them entire, before dividing the capsule. This attempt often succeeds, and when it does, it is very advantageous, for there are no chalky portions of lens left in the anterior chamber, and no secondary cataract results. But if the cataract does not follow the traction of the hook or forceps, the capsule must be freely divided and the lens removed piecemeal.

To prevent the bad results that follow the retention of small chalky granules in the aqueous chamber, it has been recommended to drop, or even gently to inject, lukewarm water, about 90° F., in order to wash out the remnants, as it were. (*Arlt.*)

e. In posterior synechia, also, the edges of the capsule cannot retract, as they are partially attached to the iris, and, from the precedent inflammation, somewhat extensive (subsequently calcifying) products have been deposited on the inner wall of the capsule, and the stiffness caused by the external deposits is thus increased. Besides this, the entire cataractous pulp frequently thickens under the influence of the inflammation, and chalky conglomerations develop in it. The exposure of the cortical portion, and its exit from the capsule, then becomes more dangerous, as, on account of the formation of new product on the margin of the pupil, it cannot dilate, and as the inclination to the recurrence of iritis is kept up by the synechia. Under such circumstances, the cataract operation should always be combined with iridectomy; and where the state of the cataract renders an extraction advisable, we should always attempt to draw out the capsule without dividing it. So we should only divide the latter, and remove it subsequently, when we can not remove the lens and capsule entire. Some advise the commencement of the operation with iridectomy. (*Hasner.*)

f. In *traumatic* cataracts, which are developed without dangerous irritation, we may use the treatment proper after division, especially the frequent instillation of atropine, and await the natural termination. Especially in children, it is well not to operate too quickly, as a spontaneous cure is not unfrequently caused by resorption. But if the lens swells up, and an iritis develops, and the inflammation cannot be quickly checked in the usual way, it is advisable to perform a linear extraction and

an iridectomy. If, however, the lens is not fully softened, or if the injury has occurred in an old person, with a hard nucleus, we should perform a flap extraction with an iridectomy, or, still better, a modified linear extraction. Unfortunately the means are frequently entirely insufficient, and the eye is rapidly destroyed by phthisis or atrophy. In view of this no reproach should be cast on any one who regards the operation as justifiable as a last resort only in the most urgent necessity and in desperate cases.

g. Flap extraction answers for lenses that have fallen into the anterior chamber and become attached there, as well as for lenses that have become partly or entirely dislocated, and irritate the eye by moving around. It is immaterial whether they be still transparent, or have already become cataractous.

Calcified lenses, which have lain for a long time in the anterior chamber, have generally very much involved the globe by iridochoroiditis, and have destroyed the sight. Hence, in case frequent conditions of irritation, and particularly iridocyclitis, demand operation, or even if the second eye were in danger of being sympathetically affected, it seems prudent to enucleate the eye, since the operation might easily fan the inflammatory process still more to a flame, and might transmit it to the other eye. (*Graefe.*) In order to avoid as much as possible greater losses of vitreous in the extraction of lenses lying in the anterior chamber, the previous contraction of the pupil by preparations of calabar has been recommended. (*Pagenstecher*).

In true floating cataract it is often difficult to seize the lens with the spoon, as it moves freely in the fluids filling the eye-ball, and readily gets out of the way. Hence it is advisable to first transfix the cataract with a needle passed through the sclera, to push it through the pupil and hold it against the cornea, and then remove it by flap extraction. (*Graefe, Hasner.*) [The same operation has been successfully done in an ordinary case of senile cataract. (*Hackley.*)]

If we cannot transfix the floating cataract on the needle, we must do a so-called scleral extraction. (*Quadri.*) For this purpose, at the equator of the eye-ball we divide the sclera, parallel to the corneal margin, to about one-sixth to one-fifth of its circumference; then the fluid vitreous is evacuated, and the lens drawn out. It is true, the eye then frequently suppurates, but this does not make much difference, as in floating cataract the functional power is usually destroyed at any rate, and the cataract is often a source of recurring inflammations, that never give the patient any rest, and often injure the general health, so that a quick destruction of the eye-ball is often an actual gain; in view of which, artificial suppuration of the globe has been induced by passing a thread through it, when the lens could not be extracted. If sympathetic affection of the other eye threatens, or already exists, it is considered proper to enucleate. (*Graefe.*)

In ectopia and slight degrees of congenital luxation of the lens, whether the crystalline be transparent or cararactous, displacement of the pupil often suffices. Of course, extraction is not then advisable. But, if the first-named operation does not give good sight, or if the motions of the luxated lens endanger the eye, modified linear extraction is indicated.

If the lens has been dislocated under the conjunctiva, it is advisable not to extract it till the opening in the sclera has closed, so as to avoid evacuating the vitreous.

h. Secondary cataracts may be broken up and partially depressed by scleronyxis. This procedure is especially to be recommended in opacities of the posterior capsule, as are often formed after flap and linear extraction. Here it is well to illuminate the field of operation obliquely with a convex lens, in order to perceive distinctly the finest opacities. (*Knapp.*) Large secondary cataracts are best removed

by the simple linear extraction. When, however, they are firmly connected with iridocylitic false membranes, as is often the case, the traction necessary to the extraction is very dangerous, and may lead to destructive inflammations. Where such adhesions exist, it is then perhaps better to cut up the secondary cataract with two needles. These needles are introduced through the cornea from two opposite sides, are pushed into the same opening in the center of the secondary cataract, and then by moving them in opposite directions a free pupillary space is produced. (*Bowman*, *Pagenstecher.*)

[For removing secondary cataracts or other membraniform obstructions from the pupil, the following operation is performed: The pupil having been dilated by atropine, the patient (lying on his back) is etherized; a spring speculum is inserted into the eye to be operated on. The operator, seated behind the head of the patient, passes a "stop-needle" through the cornea, about one line from its nasal border, and transfixes the membraniform obstruction. Then, while holding this steady, he makes an opening in the cornea, about half a line from the temporal border, with a Beer's knife, a lance-shaped knife, or a broad needle. Through this opening a sharp hook is introduced, and its point entered in the opening made in the membrane by the "stop-needle." If possible, the hook is now to be rotated, and the membrane rolled up around it and brought out of the anterior chamber. If it cannot be drawn out, it should be torn. After the operation, a solution of atropine (two grs. to the ounce) should be again used. The patient should remain two or three days in bed in a darkened chamber, then gradually accustomed to the light. The great advantage of the "stop-needle" is, that it prevents traction on the iris, and the consequent detachment of its border. It may also be used in performing an iridectomy, when the pupil is closed by posterior synechia. *C. R. Agnew.*]

4. Special preliminary treatment is quite superfluous, and is rather inclined to cause injury, by increasing the anxiety of the patient. It is, however, advisable to administer a *purgative* the day previous to the operation, because, after a complete evacuation of the bowels, the patient usually goes several days without a stool, which in flap extraction is very desirable, on account of the motion attending the effort. If a needle operation, or a linear extraction, is to be done, *repeated* instillation of atropine is advisable, to insure its effect.

If it be designed to make a flap-extraction, the artificial dilatation of the pupil seems scarcely advantageous. Still, many believe that by weakening the sphincter pupillæ the passage of the cataract is rendered easier, and thus the dangerous consequences of some lacerations of the iris may be to a certain extent obviated. The mydriasis is also said to disappear rapidly after closure of the corneal wound, and thus the influence upon the iris of the remains of cataract which are left behind is limited. (*Sämisch.*)

5. The operation is best done in the morning, an hour or two after the patient has taken a bowl of soup or a cup of coffee. When the stomach is empty, vomiting readily occurs, which may prove dangerous; when it is full, the patient does not easily retain the position on the back which is usually necessary, and inclines to congestion of the head.

Recently the recumbent position is generally considered the most favorable for the operation. Hence the patient is brought in his night-dress to a suitably prepared bed, which is so placed that the light from one or two windows falls obliquely on the head of the patient, and the eye is sufficiently illuminated, while direct sunlight is excluded.

The advantage of this proceeding is, that the patient, in order to get comfortably to bed after the operation, is not obliged to move about in a way that may be dangerous; fainting during the operation is not so serious; the head of the patient may be more easily held, and the operator, while manipulating *above* the patient, can himself hold the *upper* lid of the cataractous eye, and thus the more readily dispense with an experienced assistant.

Where, however, disease renders lying in bed tedious or unbearable, and a sitting posture is necessary during the greater part of the after-treatment, the patient had better be operated on in an easy-chair, and, properly clothed and well propped up, left for the day sitting up, but at night placed in bed, with the head well supported.

Children should be operated on under anæsthesia, or else they should be enveloped in a cloth, so that the arms and legs shall be held immovable, in an extended position; one assistant, seated, holds the child in his lap, while the operator, sitting opposite, clasps the enveloped legs of the patient between his knees, and a second assistant, from over the patient's head, separates the lids and holds the head.

In adults, and generally where an extraction by the flap or peripherical linear incision is to be performed, anæsthesia is best avoided, as the excitement of the patient in the semi-intoxication during and after the operation may endanger the success, and the frequent vomiting also acts in a very disturbing manner. In very anxious persons, however, who throw themselves about during the operation and react in the most violent manner during the separate manipulations, profound anæsthesia, as in children, can scarcely be dispensed with.

The dangers attached to anæsthesia by chloroform may perhaps be very much diminished or entirely done away with by the use of the hydrate of chloral. To this end, the patient is recommended to take a dose of 30–60 grains of the drug, in case he is a drinker even 75 grains, according to necessity, and after he has fallen asleep, to complete the anæsthetic effect by inhalation of chloroform. It is then hoped that very small doses of chloroform will answer the purpose, the stage of anæsthesia will very quickly disappear after the operation, and the patient will enjoy a good sleep. (*O. Liebreich.*) Local anæsthesia, according to the method of Richardson, is, according to direct experiments, not applicable. (*Weber.*)

In this country, sulphuric ether is almost always employed; chloroform but very rarely.

If possible, we should also avoid fixation of the eye. This is especially true in flap extraction. For we must remember that fixation excites considerable pain, and is apt to cause unruly patients to strain more, which may much interfere with the operation, cause prolapse of the vitreous, &c. If the flap extraction is done in the upper half of the cornea, or a modified linear extraction be made upward, we are sometimes unable to avoid using the forceps to draw down the upturned eye, and bring the field of operation into the opening of the lids.

It is of the utmost importance that the eye-lids should be properly held. This requires a skilled assistant, for it is not easy to open the lids widely and keep them apart with certainty, without getting in the way of the operator, and without in the least encroaching on the globe, and thus causing discomfort to the patient. Usually the operator holds one lid, and this is the upper or lower according to his position behind the head or at the breast of the patient; the assistant holds the other. The two hands used for this purpose are laid (with the ring and little finger closed) flat on the forehead and face, and, while the patient opens his eye, the ends of the extended index and middle fingers are brought over the eye-lashes on to the edges of the lids, whereupon the latter slide back along the globe, and may be easily held fast without at all interfering with the eye. It is at the same time very important that the inner lip of the lid be not for a moment raised from the eye-ball, as otherwise, by some straining of the patient, an eversion may readily occur, which renders the operation much more difficult.

Lid-holders, that are strong enough to oppose the spasmodic contraction of the orbicularis muscle, annoy the patient, increase his restlessness, and hence should generally be avoided. In modified linear extraction, however, during the second step of the operation, viz. the making of an artificial pupil, it is often difficult to do without them, as the fixation of the lids by an assistant leaves too little room for a second assistant to fix the eye-ball with the forceps.

6. Immediately after the operation the patient is directed to close the lids gently, as in falling asleep, the escaped fluid is to be carefully wiped away with soft charpie, and then a protective bandage applied over both eyes.

The application of the protective bandage requires the greatest attention. The charpie must be finely picked, soft, and clear; it must not ravel out, for then some threads might get between the lids and prove very injurious. The two cushions formed of it should not be too large; they should be of a regular density and thickness throughout; the bandage should be of fine and new flannel, so that it may stretch regularly, for only thus can it be equally applied to the surface of the closed lids, which is one of the chief requirements for a good bandage.

We can not sufficiently warn against strong traction on the bandage, especially after flap extraction, for the flap is easily displaced; in this case, however, there is a disagreeable feeling of pressure which renders the patient uneasy, and may lead directly to bad results. As a rule, the bandage should exercise no pressure, but simply keep the parts in their natural position. There are some, however, who recommend strong pressure, and even advise the laced bandage, under some circumstances, especially in prolapse of the iris or vitreous, in hemorrhage, commencing suppuration of the cornea, &c. (*Graefe.*) But it is well not to follow this advice.

Fastening the lids with strips of isinglass plaster, beside using the protective bandage, is only advisable where the patient is very unquiet and thoughtless, as well as in childish old persons, as in such there is great danger that they may lift the bandage (at a moment when they are not watched) to prove the effect of the operation, which may cause the worst results.

[In this country the plasters are frequently used, and with excellent results. Instead of ichthyocolla plaster, strips of fine gauze may be laid over the lids, and retained in their position by painting collodion over them. The collodion not being soluble in watery fluids, the plasters remain well in position. They are, however, liable to objections, on account of the contraction caused by the collodion.]

Children will frequently suffer no bandage, and then, if we would avoid the injuries caused by their crying and struggling, we must leave them with open eyes in a dark room. This is the more easily done, as we usually perform *needle* operations on them.

When the bandage has been applied, the patient should be placed in the proper position, and made as comfortable as possible; for he will not long retain an uncomfortable position—pains in the head, hips, &c., occur; he becomes restless, tosses about, and may thus endanger the success of the operation. Usually, lying on the back, with the head more or less elevated, is the best position. If, however, only one eye has been operated on, the patient may, if necessary, lie on the other side, and only occasionally on the back.

When the patient has been carefully laid down, the bed should be moved to the chosen part of the chamber, where it will be protected from draughts, furnace-heat, rays of light, &c. The chamber should then be regularly darkened, but not so much so as to render the features indistinguishable after having been a little while in the room.

7. For the first couple of days the patient should preserve the greatest bodily and mental quiet; he should speak as little as possible; muscular exertion, snoring, coughing, sneezing, are to be carefully avoided; visits and exciting news are to be forbidden; diet must be limited to warm soup, and, at most, steamed vegetables. If the patient longs for them, acid drinks are not injurious, but rather beneficial.

[It is desirable to have the food soft, to avoid exertion of the masticatory

muscles; but it should, at the same time, be nutritious. Beef-tea and various nutrient soups are suited for the use of patients who have just been operated on.]

Quite recently some have declaimed against the absolute rest of the patient after operation. This is said to be opposed to all the rules of medicine, and to be apt to cause cerebral congestion, as it arrests the muscular actions that are absolutely necessary to normal circulation. (*Coursserant.*)

Some hours after the operation, the charpie of the dressing should be changed, as, at first, a good deal of aqueous escapes, and the conjunctival secretion is also much increased, and thus the pad covering the eyes becomes soiled, cakes together, presses unevenly, and readily causes irritation, and, at all events, is annoying to the patient. The conjunctival secretion also renders it necessary to change the dressing once or more daily, for the following days. Almost all patients find this a relief. While making the change we must most carefully guard the eye from mechanical injury and strong light on the closed lids, and prevent the patient from opening them. Severe irritation often follows the neglect of these rules.

The above includes the urgent warning not to examine the eye too soon. Many, however, advise this (*Desmarres, Zehender, Küchler*), and, where the symptoms are threatening, recommend an examination with oblique concentrated light, within ten hours after the operation, as well as on subsequent days (*Jacobson*); but we can only explain this advice by their desire for a more thorough knowledge of the process of cure. It is true that much valuable information has been gained in this way (*Sichel, Jacobson, Graefe*); but this gain to our knowledge is made at great risk to the patient. Besides, we can not expect to draw any hints for true and practicable therapeutics from the state of the different parts of the eye at the time. The careful surgeon would not be easily induced to perform a second operation within the first couple of days. Hence we could only expect to determine if any inflammation existed, and its grade. But the objective and subjective symptoms that we find, while the lids are closed, suffice to show us this. We must not forget that rest of a diseased part is the best antiphlogistic, and answers better than all others together.

When we wish to use atropine soon after the operation, we should advise the patient to look upward, keeping the lids closed; we then draw down the lower lid, and drop one or more drops of the solution into the fissure. Generally, we should avoid much manipulation with this remedy; one, or at most two, daily instillations of it are sufficient even in the most urgent cases, and these should be made at the time the dressing is changed.

It seems that by these means compensatory hyperæmiæ in the posterior portion of the uveal tract are very much favored. At any rate the curative action of the atropine in iridocyclitis and iridochoroiditis after cataract extractions is very problematical.

a. If no reaction has occurred after the second day, if the recumbent position becomes very tiresome to the patient, he may alternate it with a sitting one, and may be supported in an easy-chair with pillows. If the patient is very hungry, there is no objection to his then using meat-broth, easily digestible vegetables, &c., in small quantities; in much debilitated persons this is even necessary.

On the fifth or sixth day the bandage may be raised and the patient's vision tested, at the same time being most careful that dazzling light, rays of light or reflection from a white or dazzling object, do not reach the eye; otherwise the success of the operation may, even yet, be prevented, as the retina, which for years may have been protected from dazzling light behind an opaque lens, at first reacts strongly to even moderate light. This is the more apt to occur, because since the operation it has been kept in entire darkness. Careless exposure of it may readily cause incurable amaurosis. For the same reason the eye must not be strained in the trials of vision. Where the pupil is closed by remains of cataract, the trials are useless, or can only determine the amount of sensitiveness to light. After this the patient may be allowed to sit up for an hour or two at a time, in an easy-chair, and be better nourished; still, however, avoiding all food that requires chewing.

From this time on a simple shade suffices during the day. At night it is well to apply the protective bandage. The patient may now pass the time out of bed in a comfortable arm-chair, and may be better nourished, yet with the exclusion of all articles of food requiring efforts at mastication.

After nine or ten days, there is no objection to removing the bandage from time to time and permitting the patient to use the operated eye. It is wisest to do this only in the evening at first, as the patient is then most certain to escape dazzling light. After fourteen days the patient may use the operated eyes the whole day, being careful, however, to lessen direct bright and diffuse light by the use of shades and dark glasses. In summer-time it is well at this period to let the patient be led about in a quiet place out of doors at twilight, as fresh air greatly shortens convalescence. If eighteen or twenty days have passed without bad results, the patient may be regarded as well, and it is sufficient to warn him against possible injuries, such as straining the eyes too soon, bright light, intemperance in food or drink, &c. It is well to choose suitable cataract-glasses for the patient at this time. They should not be used, however, for a month or two.

It is, of course, understood that these are only general rules, and that many deviations from them are necessary, according to circumstances, especially in regard to the periods given.

b. The cure does not always go on so quietly, however. It is interfered with by various accidents which require treatment and delay convalescence for a long time. Quite often feelings of pressure, foreign bodies, heat, even flying stitches and temporary severe pain, occur immediately after the operation, or a few hours subsequently, but soon depart after a few tears have escaped between the lids, or the charpie has been changed. We may almost always calculate on this accident when fixation forceps have been used. If, however, they increase after a few hours, if the flow of hot tears becomes more copious, if the margin of the upper lid becomes red and swelled, or the entire lid congested and œdematous, we may know there is severe inflammatory reaction. Then active antiphlogistic treatment becomes necessary. Usually we attempt to meet the indications by leeches applied to the temporal region or behind the ear. But if the local temperature appears much increased, it is well to apply cold compresses to the brow and temples. If the pain is unbearable, we should use solutions of morphia hypodermically, or some of the narcotics internally. [The sixtieth of a grain of atropiæ sulph. and one sixth of a grain of morph. sulph. in solution, given hypodermically, are very satisfactory.]

In order to secure sleep for the patient, a dose of from 1½-2 scruples of hydrate of chloral, with five times the weight of mucilage, with the same quantity of orange syrup and about an ounce of water, may be given. (*Graefe.*) We should be careful with our instillations of atropine. They are of little use at this period.

More recently, doubts have been raised against leeches, particularly when they are applied upon the region of the temple, and it is advised rather to replace them by a venesection of 4-6 ounces. (*Graefe.*) The ineffectiveness of the latter is, however, sufficiently determined by the experience of former years, hence it had better be discontinued. The excitement of the patient, which we cause by the leeches, is, moreover, scarcely less in the venesection. Purgatives, among which calomel together with rhubarb is particularly praised, should still less answer the purpose. At least they disturb in the most dangerous manner the quiet of the patient while in bed. To do away with the protective bandage and to make cold applications directly to the region of the eye, is seldom of service; the changing of compresses becomes troublesome to the patient, and often increases the condition of irritation. Irrigations with cold water are objectionable on account of their irritating action. Still they have been very recently recommended. (*Laurence.*)

If, with these remedies and careful antiphlogistic diet, we do not succeed in mastering the inflammation, or if this even increases, the eye is seriously affected. There is usually a severe iritis, which is excited and kept up by retained portions of cataract. But at this time these are rarely so much softened as to be removed without rough, and therefore dangerous, manipulation. In children only, the consistency of the lens allows us to hope for speedy disintegration after discission and the consequently safe removal through a linear corneal wound. In adults, even an iridectomy, during severe irritation, is dangerous. Hence, as experience teaches, it is almost always better to continue the antiphlogistic treatment, and patiently await the termination. Often only extensive synechia and secondary cataracts result. After the inflammation has run its course, or, still better, after several weeks or months, these may be corrected by an iridectomy, without much danger. After flap extraction, great attention must be paid to symptoms of corneal suppuration. This most unfortunate of all the accidents often appears even in the course of twelve or twenty-four hours, but often, also, not till after the second day. It shows itself by rapidly-increasing œdematous swelling of the inner angle of the eye, as well as by a profuse discharge of purulent conjunctival secretion. The pain may vary to any extent. In old, decrepit persons, after flap extractions, the cornea not unfrequently becomes infiltrated, or the whole globe filled with pus, without the occurrence of severe pain, or even with its entire absence. In such cases it is well to assure ourselves of the state of the eye by inspecting it. If we find that a diffuse infiltration of the cornea has already occurred, all hope of restitution of vision is gone. The treatment is best directed to the existing symptoms and the comfort of the patient. If the globe appears very tense and painful, or if a rupture is threatening, it is advisable to lift the flap or tap the eye. Cataplasms are often soothing.

[Astigmatism often occurs as a disturbing element in the vision of patients who have been operated upon for cataract. Thus Dr. Knapp, in Graefe's Archives for 1867, observes that "we should not neglect to test eyes which have been operated on for cataract, with cylindrical glasses, to see if vision is not thereby improved. This is found to be the case in a marked degree, where the result has been a good one, in about one-fourth of the cases. Thus I have found where $V = \frac{1}{4}$, corrected it will be $\frac{1}{2}$, and $V\ \frac{1}{8}$ will become $\frac{3}{8}$ and so on."

But notwithstanding this knowledge of its existence, very little has been done by the majority of operators in determining the degree of this error in refraction when making out their statistics of vision, and still less has the attempt been made to remedy the defect by prescribing suitable glasses.

This latter is no doubt due to the fact that the necessary sphero-cylindric glass is so heavy and of so awkward a shape as only to be worn with great discomfort to the patient. Thus if we wished to give a spherical glass, for example $+\frac{1}{4}$ combined with a cylindric glass, the spherical surface, inasmuch as it would have to be put all on one side, would have to be ground on a radius of 2 inches. This degree of curvature would, in order to fill the eye of the spectacle frame, require the glass to be very thick in the center, the apex of which would consequently project a good deal from the plane of the rim of the spectacle, while the slight curvature of the cylindric surface would hardly project at all. Such a glass as this is necessarily very heavy, and very clumsy and uncomfortable.

With the hope of remedying these objections so as to allow us to give astigmatic glasses to cataract patients, I have contrived the glass which I now present to the Society, and which is made in the following manner:—

A simple cylindric glass of the required strength is first set in the spectacle frame in the usual way, the axis of the glass of course running in the required direction. A thin plano-convex glass is then ground, and, taking advantage of the fact that lenses can be cemented together by Canada balsam, this is firmly fixed by its plane surface to the back or plane surface of the cylindric glass.

As the diameter of the plano-convex is made only equal to the vertical diameter of the spectacle frame, and not to the longitudinal one, it follows that a large quantity of glass is thus dispensed with, and the weight of the glass is thereby much reduced—the two combined lenses being, in fact, when nicely made, only one-fourth of the weight of the common spherical cataract glass as found in the shops.

In the figure, *A* gives a longitudinal section of the glass, the dotted line making the line of union between the two lenses, while *B* shows the front view of the glass as it appears in the frame, the dotted line showing the circumference of the plano-convex glass.

Fig. 98.

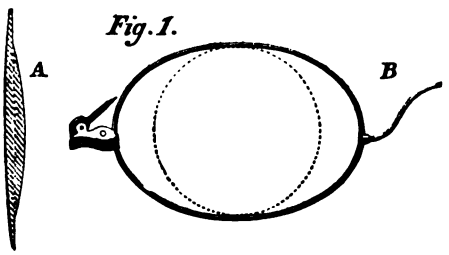

As you will observe, the edge of the convex lens is so delicately ground and so perfectly fitted to the cylindric glass, that the point of union is barely perceptible when the glass is worn, and the peculiarity of its construction would escape the notice of any but a very observant eye.

The pair which I now offer as a sample has a spherical surface of + ¼ (really equal to a biconvex + ½) and a cylindric surface + $\frac{1}{12}$ c, the patient being astigmatic to that degree in the vertical meridian. With the best correction with spherical glasses vision equalled ⅓. With this glass it rose to ½.

The chief objection which would be raised against glasses made in this manner would, in all probability, be on account of their liability to come apart. Whether this is a valid objection remains to be proved. I would say that this pair has been in constant use for four months, and in that time they have dropped twice, once in a crowd, from which they were only rescued after the frames had been considerably bent. They certainly show no signs of separation between the two lenses, and we know that the lenses of telescopes and opera glasses are subjected, oftentimes for years, to the extremes of temperature and hard usage without showing such a tendency; and even if the glasses should occasionally separate, it is certainly a simple matter to re-cement them. This slight inconvenience would be more than compensated, it seems to me, by the increased amount of vision, especially when, as in the present case, it is doubled. *Loring.*]

If, however, phthisis first threatens, then powerful cauterizations of the external integument of the lids with nitrate of silver in connection with the tight bandage are said to have

produced favorable results. To this end the lid is to be cleansed, and its entire surface touched with the mitigated stick, with the requisite neutralization and careful drying, this procedure repeated according to necessity, and united with the above-mentioned antiphlogistic means, especially with venesection, purgatives, etc. (*Graefe*). The warm aromatic poultices, formerly so much recommended, are now pretty well neglected. In one case, an already diffusely suppurating, infiltrated cornea has been seen to clear up completely a few hours after the powerful local action of a solution of quinine, and the case to end in a complete cure (*Nagel*).

While the bandage is still used, conjunctival catarrh is not unfrequently developed. It occurs particularly in old people with relaxed skin, and often runs its course with great œdematous swelling of the parts. Then compresses wet with lead-water are advisable. Strong astringents should only be used subsequently, when an irritation of the eye does not appear dangerous.

Authorities.—*Anatomy: Brücke*, Anat. Beschreibung des menschl. Augapfels. Berlin. 1847. S. 27.—*Kölliker*, mikrosk. Anat. II. Braunschweig. 1854. S. 703.—*Henle*, Handbuch der Anat. II. Braunschweig. 1866. S. 678.—*Sappey*, ibid. S. 685.—*Ed. Jaeger*, Einstellungen des diopt Apparat. Wien. 1861. S. 11.—*F. Becker*, A. f. O. IX. 2. S. 1, et seq.—*H. Meyer*, ibid. S. 8.—*C. Ritter*, ibid. XII. 1, 17, 19, 23, Etudes ophth. p. Wecker. II. Paris. 1866. P. 1, 10, 11.—*Iwanoff*, Klin. Beobachtgn. von Pagenstecher. III. Wiesbaden. 1866. S. 141.—*Moers*, Virchow's Archiv. 32. Bd. S. 64.—*Babuchin*, Würzbgr. naturw. Zeitg. IV. S. 85.—*Valentin*, A. f. O. IV. 1. S. 227, VIII. 1. S. 88.—*Kunde*, ibid. III. 2. S. 275.—*Graefe*, ibid. I. 1. S. 323.

Senile Changes, Nosology: H. Müller, A. f. O. II. 2. S. 53, 56, 58, III. 1. S. 55, 56, 86-92, IV. 1. S. 385, 387; Verhandlgn. der Würzburg. phys. med. Ges. 1856. 13. Dec., 1859. 26. März.—*Wedl*, Zeitschft. der Wien. Aerzte. 1858. S. 463, Atlas. Lens-Corp. vitreum.—*Stellwag*, Ophth. I. S. 451, et seq.—*Ammon*, klin. Darstell. I. Berlin. 1837. Taf. II, III. Taf. 14. S. 67.—*Förster*, A. f. O. III. 2. S. 187, 189, 196.—*Schweigger*, ibid. V. 2. S. 225, VI. 1. S. 142, VIII. 1. S. 227, et seq.—*C. Ritter*, ibid. VIII. 1. S. 81; Etudes ophth. p. Wecker, II. Paris. 1866. P. 13, 17.—*Iwanoff*, l. c. P. 143, et seq.—*Schiess-Gemuseus*, Virchow's Archiv. 24. Bd. S. 557.—*Moers*, ibid, 32. Bd. S. 48, 53, 56, 59.—*C. O. Weber*, ibid. 19. Bd. S. 412.—*Lohmeyer*, Zeitschft. f. rat. Medicin V. 1854. S. 79, 81, 88.—*Hasner*, kl. Vorträge. Prag. 1865. S. 235, et seq.; Entwurf einer anat. Begründung, etc. Prag. 1847. S. 185.—*Graefe*, A. f. O. I. 1. S. 330, 332, I. 2. S. 234, II. 1. 203, 204, 272, III. 2. S. 372, et seq.—*Ad. Schmidt*, Zeitschft. f. Ophth. I. S. 364.—*Beer*, Lehr von den Augenkrankheiten. II. Wien. 1817. S. 301.—*Himly*, Krankheiten u. Missbildungen. II. Berlin. 1843. S. 233.—*R. Wagner*, Nachrichten von der G. A. Universität in Göttingen. 1851. S. 109.—*Pagenstecher*, A. f. O. VII. 1. S. 115, 117.—*Virchow*, Die krankhaften Geschwülste. II. Berlin. 1864. S. 101.—*Rusta*, Lehrb. der Ophth. Braunschweig. 1845. S. 694, 762.—*Piringer*, Die Blennorrhœ am Menschenauge. Graz. 1841. S. 207.—*Arlt*, Krankheiten des Auges. I. Prag. 1851. S. 232, II. S. 260, 264.—*Bauer*, Zeitschft. f. Ophth. III. S. 79.—*Singer*, *Wedl*, Wien. med. Wochenschft. 1864. No. 14-20.—*Ed. Jaeger*, Staar und Staaroperat. Wien. 1854. S. 17, 20, Zeitschft. der Wien. Aerzte. 1859. S. 491.—*D. E. Müller*, A. f. O. II. 2. S. 164, et seq.—*Pilz*, Lehrbuch der Augenheilkunde, Prag. 1859, S. 726.—*O. Becker*, Wien med. Jahrb. 1866. 4. S. 55, 58.—*Businelli*, Zeitschft. der Wien. Aerzte. 1859. S. 410, 425.

Symptoms, Complications: Graefe, A. f. O. I. 2. S. 231, et seq.; IX. 2. S. 46.—*A. Weber*, ibid. VII. 1. S. 7-11.—*Donders*, ibid. S. 160.

Causes: Hasner, klin. Vorträge, &c. S. 259, et seq.—*Arlt*, Zeitschft. der Wien. Aerzte. 1854. Wochenbl. S. 777, Krankheiten des Auges. II. S. 290.—*Schön*, Beiträge zur pr. Augenheilkunde. Hamburg. 1861. S. 157, et seq.—*Froebelius*, kl. Mntbl. 1864. S. 38.—*Horner*, *Davidson*, ibid. 1865. S. 180.—*O. Becker*, Wiener. m. Jahrb. 1866. 4. S. 56.—*Förster*, A. f. O. III. 2. S. 197.—*Ammon*, kl. Darstellgn. III. S. 67.—*Lecorché*, Arch. gén de med. 1861. I. P. 572, 577, 583, 725, II. S. 64, 65.—*Knapp*, *Carius*, kl. Mntbl. 1863. S. 168, 171.—*Melchior*, ibid. S. 499.—*Graefe*, Deutsche Klinik. 1859. Nor. 10, A. f. O. I. 1. S. 333, II. 1. S. 229, 273, III. 2. S. 372, V. 1. S. 170; VI. 1. S. 134, 141, 143. XII. 1. S. 213. XII. 2. S. 191.—*Hirschmann*, kl. Montbl. 1866. S. 94.—*J. Meyr*, A. f. O. VIII. 2. S. 120.—*A. Weber*, ibid. VII. 1. S. 21.—*Hutchinson*, A clinical memoir, &c. London. 1863. P. 150.—*Stellwag*, Ophth. I. S. 466, et seq.—*Beger*, Zeitschft. f. Ophth. III. S. 145.—*Petrequin*, Canstatt's Jahresber. 1857. III. S. 108.—*Rau*, A. f. O. I. 2. S. 197.—*Ressl*, Zeitschrift der Wiener Aerzte. 1860. S. 639.—*Rydl*, Wien. med. Jahrbücher. 1866. 4. S. 46, 50, 61.—*Ruste*, Lehrbuch der Ophth. II. 1854. S. 680.—*Coccius*, Ueber die Neubildung von Glashäuten, &c. Festrede Leipsig. 1858. S. 1, 7.—*A. Pagenstecher*, kl. Beobachtungen. Wiesbaden II. 1862. S. 122, III. S. 1, 3, 6, 7.

—*Mackenzie*, Prakt. Abhdlg. &c., Weimar. 1832. S. 307; Traité d. mal. d. yeux, traduit p. Warlomont et Testelin. I. Paris. 1856. P. 596.—*Sichel*, Annal. d'oc. XIII. P. 193.—*Zander* und *Geissler*, Verletz. d. Auges. Leipzig und Heidelb. 1864. S. 27, 276.—*Schweigger*, A. f. O. VIII. 1. S. 237.—*C. Ritter*, ibid. S. 1, 16, 81, Etudes. ophth. p. Wecker II. Paris. 1866. P. 19.—*C. Pagenstecher*. kl. Montbl. 1865. S. 11.—*Nordman*, Mikrograf. Beiträge, &c. Berlin. 1832, 1. Heft. S. 7, 2. Heft. S. 9. —*Gescheidt*, Zeitschft. Ophth. III. S. 405.—*Leuckart*, kl. Montbl. 1864. S. 86.

Dislocation of the Lens: Zander und *Geissler*, l. c. S. 358–385.—*Geissler*, Schmidt's Jahrb. 107. Bd. S. 72–74.—*Mackenzie*, Traité, &c., I. P. 599–607.—*Stellwag*, Ophth. I. S. 438, et seq.—*Hasner* kl. Vorträge, &c., S. 231–238.—*Arlt*, Zeitschft. der Wien. Aerzte, 1861. Wochenblatt. S. 203. Krankheiten des Auges. &c., II. S. 16, 271–276.—*Sichel*, ibid. S. 275.—*Ryba*, ibid. S. 273.—*Heymann*, Ein Fall von spontaner Freibeweglichkeit der Linse. Denkschrift an G. R. Carus. S. 21.—*Schön*, Beiträge, &c., S. 111, 116; Handb. der path. Anat. Hamb. 1823. S. 121.—*Ed. Jaeger*, Zeitschrift der Wien. Aerzte. 1853. II. S. 551. Staar und Staaroperat. &c. S. 57, 59.—*Ammon*, A. f. O. I. S. 119, 126.—*Pagenstecher* und *Sämisch*, kl. Beobachtungen. II. S. 33; III. S. 5.—*Graefe*, A. f. O. I. 1. 336, et seq. I. 2. S. 291, II. 1. S. 195, 197, III. 2. S. 365, 371, 372; IV. 2. S. 311, 316. —*Donders*, ibid. VII. 1. S. 201.—*D. E. Müller*, ibid. VIII. 1. S. 166.—*Sippel*, ibid. S. 170.—*Mans*, kl. Montbl. 1865. S. 176.—*C. Pagenstecher*, ibid. S. 1.—*Wecker*, ibid. 1863. S. 114.—*Steffan*, ibid. 1865. S. 164.—*Hirschmann*, ibid. 1866. S. 94, 99.—*Bowman*, ibid. S. 267.

Course, Results: Himly, l. c. II. S. 247.—*Ed. Jaeger*, Wien. Zeitschrift f. prakt. Heilkunde 1861, Nr. 31, 32.—*Schön*, Beiträge, etc. S. 162.—*Graefe*, A. f. O. I. 1. S. 326, III. 2. S. 376, V. 1. S. 173–177; IX. 2. S. 46; XI. 3. S. 36.—*Knapp*, Dritter Jahresbericht 1864-5. Heidelberg, 1865. S. 19.

Treatment: Arlt, Lehrb. II. S. 294, 338; Zeitschrift der Wien. Aerzte, 1859. S. 412, 1866. Wochenbl. Nro. 38; Prag. Vierteljahrsch. 76. Bd. Misc. S. 16; kl. Monatbl. 1864. S. 337, et seq.—*Hasner*, Prag. med. Wochenschrift, 1864. Nro. 42, kl. Vorträge, etc. S. 235, et seq.—*Iils*, Lehrb. S. 729.—*Melchoir*, kl. Monatbl. 1863. S. 499.—*Zehender*, ibid. S. 87, 186, 274, 1766. S. 122.—*Rivaud-Landrau*, and others, Congress intern. d' ophth. Paris, 1863. S. 155–171.—*Secondi*, ibid. S. 164, 217, Clinica oc. di Genova, Riassunto Torino, 1865. P. 91, 130.—*M. Langenbeck*, die Insolation d. m. Auges. Hanover, 1859. S. 8.—*Ed. u. Fr. Jaeger*, Ueber die Behandlg. ds gr. Staares, Wien. 1844, S. 19, et seq.; Staar und Staaroperat. Wien. 1854. S. 33–48.—*Ritterich*, Deutsche Klinik, 1855.—*Stellwag*, Zeitschrift der Wien. Aerzte, 1852, 1. S. 321, 481, 570; ophth. I. S. 570–654.—*Graefe*, A. f. O. I. 2. S. 219, et seq. II. 1. S. 195, et seq. II. 2. S. 177, et seq. IV. 2. S. 211, 214, V. 1. S. 158, et seq.; VI. 2. S. 155, et seq.; IX. 2. S. 43, et seq.; X. 2. S. 209, et seq.; XI. 3. S. 1 et seq.; XII. 1. S. 150, et seq.; kl. Monatbl. 1863. S. 141, et seq.; 1865. S. 306, 341, 345.—*Gibson*, nach Graefe, A. f. O. I. 2. S. 221; X. 2. S. 216.—*Schweigger*, nach Graefe kl. Monatbl. 1863. S. 198.—*Palucci*, nach Himly l. c. II. S. 285.—*Pagenstecher*, A. f. O. VIII. 1. S. 192, et seq.; kl. Beobacht. 1. S. 41, et seq.; II. S. 28–34, III. S. 3, et seq.; kl. Monatbl. 1865. S. 316.—*Berlin*, A. f. O. VI. 2. S. 73, 76, 78.—*Steffan*, ibid. X. 1. S. 123, 126, 131.—*Wecker*, kl. Monatbl. 1863. S. 114, 119.—*Mannhardt*, ibid. 1864. S. 403.—*Knapp*, ibid. 1863. S. 165, 168, dritter Jahresbericht, etc. S. 19, Canstatt's Jahresbericht, 1864, III. S. 155.—*Sichel*, kl. Monatbl. 1863, S. 125, Ann. d'oc. XVII. P. 106, A. f. O. IX. 2. S. 117.—*Schön*, Beiträge, etc. S. 170, 175.—*Laugier*, Ann. d'oc. XVII. P. 29, XX. P. 28.—*Desmarres*, Clin. europ. 1859. Nr. 8. Traité d. mal. d. yeux, Paris, 1847. P. 651.—*Schuft*, die Auslöffelg des gr. Staares, Berlin, 1860. S. 1. 11.—*Stöber*, De l'extract de la cat. p. incis. lin. Strasbourg, 1857.—*C. Ritter*, A. f. O. VIII. 1. S. 1, et seq.—*Mooren*, Die Verminderter Gefahren einer Hornhautvereiterung, etc. Berlin, 1862. S. 5, et seq.—*Rothmund*, Jahresbericht, 1861-2. München, 1863. S. 15, 17.—*Workman*, *Carter*, kl. Monatbl. 1864. S. 41, 42.—*Critchett*, ibid. 1864. S. 349, et seq.; 1866. S. 127.—*Bowman*, ibid. 1866. S. 128.—*A. Weber*, ibid. 1865. S. 309.—*Quadri*, nach Himly l. c. II. S. 289, 291.—*Küchler*, Deutsche Klinik, 1865. Nr. 41, 32, 1866. Nr. 37, u. d. f. Wien. med. Wochenschrift, 1866. Nr. 86.—*Sämisch*, Wurzb. med. Zeitschrift, II. 4, 1861.—*Jacobson*, Ein neues. gefahrloses operat. Verfahren etc. Berlin, 1863, kl. Monatbl. 1864. S. 330, A. f. O. X. 2. S. 78, XI. 1. S. 114, et seq.; XI. 2. S. 166, et seq.—*Braun*, A. f. O. XI. 1. S. 200.—*Ullersperger*, XI. 2. S. 266.—*Rossander*, kl. Monatbl. 1864. S. 118.—*Roeder*, ibid. 1865. S. 307.—*Agnew*, ibid. 1865. S. 389.—*Laurence*, ibid. 1868. S. 416.—*Courserant*, Wien. med. Wochenschrift, 1865. Nr. 88. [*Loring*, Boston Medical and Surgical Journal, Oct. 12, 1871.] *F. Becker*, A. f. O. XIII. 1. S. 75.—*C. Ritter*, ibid. XIII. 2. S. 451.—*Zernoff*, ibid. XIII. 2. S. 521, 527, 533, 545.—*M. Schultze*, ibid. XIII. 1. S. 83.—*Woinow*, Kl. Monatbl. 1869, S. 411.—*Barkan*, Sitzungsber. d. Wien. k. Akad. d. Wiss. 54. Bd.

Senile changes, Nosology: Knapp, A. f. O. XIII. 1. S. 158, 176.—*Mauthner*, Lehrb. d. Ophthscop. S. 139, 144, 147.—*Steffan*, Kl. Monatsbl. 1867, S. 209, 216.—*Mooren*, Ophth. Beob. S. 207, 209.—*Kruse*, Zeitschft. f. rat. Med. 24. Bd. S. 261.

Symptoms, Complications: Mauthner, Lehrb. d. Ophthscop. S, 138.

Causes: Iwanoff, A. f. O. XV. 2. S. 59, 89.—*Mooren*, Ophth. Beob. S. 208, 211.—*Rothmund*, A. f. O. XIV. 1. S. 109.—*Berlin*, ibid. XIII. 2. S. 282.—*Wecker*, Kl. Monatbl. 1867. S. 36.—*Colsman*, ibid. 1869. S. 105.—*Wagner*, ibid. S. 15.—*Stavenhagen*, kl. Beob. S. 86. *Dyer*, kl. Monatbl. 1867. S. 241.

Dislocation of the Lens: Noyes, Arch. f. Aug. u. Ohrenheilkde. 1. S. 154.—*Lawson*, ibid. S. 21.—*Mooren*, Ophth. Beob. S. 255.—*Colsman*, kl. Monathl. 1869, S. 104.—*Wagner*, ibid. S. 18.—*Davis*, ibid. S. 191.—*Hoering*, ibid. S. 347.—*Ed. Meyer*, ibid. S. 351.—*Horner*, ibid. S. 353.

Course, results: Mooren, Ophth. Beob. S. 214.—*Mauthner*, Lehrb. d. ophthscop. S. 142.—*Steffan*, Erfahrung. u. Studien. Erlangen. 1867, S. 40.—*Schless-Gemusens*, A. f. O. XIV. 1. S. 95.—*Pagenstecher*, kl. Beob. III. S. 17. 32.—*Milliot*, Centralbl. 1867, S. 250.

Treatment: Hasner, Prag. Vierteljahrschrft. 96. Bd. Annal. S. 85, 88; 98, Bd. Annal. S. 85; 102. Bd. Ref. S. 77; Neueste Phase der Staaroperation. Prag. 1868; Phakolg. Studien. Prag. 1868.—*Faye*, Congrès Ophth. 1868. S. 141.—*Horner*, kl. Monatbl. 1869, S. 134.—*Gioppi*, Sulle ultime ricerche, etc., Padova, 1869, S. C.—*Tavignot*, ibid. S. 1.—*Dantone*, Beiträge zur Extraction des grauen Staaers. Erlangen. 1869. S. 42, et seq. *Mooren*, Die verminderten Gefahren einer Hornhautvereiterung etc., Berlin. 1862. S. 5–40; Ophth. Beob. S. 219–246; Ueber Sympathische Ophth. S. 44, 50, 79; kl. Monatbl. 1868. S. 335.—*Steffan*, A. f. O. X. 1. S. 123; Klin. Erfahrungen. Erlangen. 1869. S. 4; Erfahrungen und Studien über d. Staaroperat. S. 15, 23, 44, 48, 50; kl. Monatbl. 1870, S. 90.—*Graefe*, A. f. O. XIV. 3. S. 106–126; Congrès Ophth. 1868. S. 61, 95; kl. Monatbl. 1868. S. 1. 259; 1870. S. 1, 10, 14 u. f.—*Henle*, Eingeweidelehre. 1866. S. 587, 678.—*Mannhardt*, A. f. O. XIV. 3. S. 49.—*Knapp*, kl. Monatbl. 1868. S. 431, 341; A. f. O. XIII. 1. S. 85, 98, 124; XIV. 1. S. 262, 285; Arch. f. Aug- u. Ohrenheilkde. S. 44, 58.—*Sichel*, A. f. O. XIV. 3. S. 1. *Rothmund*, kl. Monatbl. 1868. S. 328; A. f. O. XIV. 1. S. 178.—*O. Leibreich*, kl. Monatbl. 1869. S. 353, 456.—*Adamük*, ibid. S. 383.—*Nagel*, ibid. S. 430.—*Esslingen*, ibid. 1868, S. 26.—*Paulsen*, ibid. S. 288.—*Hoering*, ibid. S. 131; Congrès Ophth. 1868. S. 84.—*Heymann*, kl. Monatbl. 1868, S. 327; Ophth. Leipzig, 1868, S. 38.—*O. Becker*, Congrès Ophth. 1868, S. 72.—*Ed. Meyer*, *Quaglino*, *Kanka*, ibid. S. 82–93.—*Critchett*, ibid. S. 80; kl. Monatbl. 1864. S. 349, 353, 357; 1866, S. 127.—*Küchler*, Congrès Ophth. 1868, S. 89; Die Querextraction des gr. Staares, Erlangen, 1868.—*Jacobson*, A. f. O. XIV. 2. S. 247.—*Reuss*, *Woinow*, Ophth. Studien, Wien. 1869, S. 1–26.—*Bergmann*, A. f. O. XIII. 2. S. 383.—*Gouvea*, ibid. XV. 1. S. 244, 257.—*Williams*, Arch. f. Aug- u. Ohrenhlkde 1. S. 91.—*Hirsch*, kl. Monatbl. 1869. S. 282.

1. Discission.

cations.—Simple breaking up of a cataract is indicated:
the various forms of cataract occurring in childhood, except in siliculose

opacities of the posterior capsule, such as occur after linear and flap ex-

ation.—The discission may be done as well through the cornea as through
. Scleroticonyxis is advisable in fluid and pasty total cataracts, especially
re is ground for suspicion that depositions of changed cataract-substance
ent the retraction of the capsule, as in this operation, by using the needle
the anterior capsule may, if necessary, be depressed; the same is true in
of the posterior capsule, which often remain after extraction.
s cataract-needle is almost always used for *scleroticonyxis*. It is not suited
onyxis, however, for, as the spear-pointed end enters the anterior chamber,
ous escapes; hence the lens approaches the posterior wall of the cornea, and
le passes out of the reach of the needle. The formation of secondary cata-
hus favored. Hence, Dalrymple's needle, or the round stop-needle, is used
antage, as it prevents the escape of the aqueous humor.
breaking up a cataract by scleroticonyxis, after dilating the pupil as fully as
the needle is passed perpendicularly through the sclera, on the temporal
ut a line and a half behind the margin of the cornea, and from one to two
ow the horizontal meridian of the eye, the cutting edges of the needle being
antero-posteriorly, the better to avoid the chief vascular trunks of the
Then the point of the needle should be turned forward, so that the end
side shall look toward the cornea; then past the temporal part of the
rocesses and the pupillary margin, through the periphery of the lens into
the anterior chamber as far as the upper inner margin of the pupil (Fig. 94.)

Fig. 94.

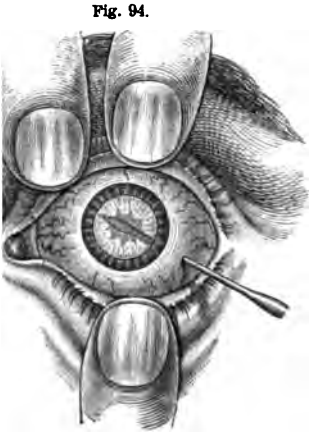

In order to tear as large a piece as possible from the middle of the anterior capsule, and sink it in the vitreous, the end of the needle is to be laid flat over the center of the capsule, and moved slowly, with increasing pressure, toward the vitreous. The needle is to be used as a two-armed lever, whose fulcrum is in the scleral wound, and in its excursions should not go out of the plane of the meridian of the wound. When this has been done, the needle is to be again passed into the anterior chamber, in order to tear loose the remaining parts of the anterior capsule, or

to cut them up as much as required, as well as still further to break up the remains of the cataract.

It is not advisable to push the fragments of cataract into the anterior chamber, as they collect at the bottom of the chamber and irritate the iris. Their sinking in the vitreous is not attended with peculiar danger, as they are there readily absorbed, and only a small portion of them reach there, for, on account of their softness, they are usually stripped off, and remain in the posterior chamber.

b. In breaking up the cataract by keratonyxis, after dilating the pupil as far as possible (Fig. 95), the stop-needle is passed through the cornea at the middle of the lower outer quadrant, its point pushed through the anterior chamber to the inner upper border of the pupil, and the capsule and lens divided in various directions.

Fig. 95.

The needle should be passed through the cornea perpendicularly, so that the track of the wound may be shorter. If the needle be introduced obliquely, the opposition to its advance, which is always great, is increased, and then the patient is restless while the operation is being completed. Such an oblique canal is also dangerous, as the parts around the points of entrance and exit of the cornea are strained and bruised by the forcible excursions of the shank of the needle. Inflammation, or even suppuration, then readily occurs, and opacities of the cornea usually result. Moreover, these opacities are not certainly avoided by puncturing the cornea perpendicularly, hence the advice of many ophthalmic surgeons, to enter the needle through the *center* of the cornea, is to be rejected.

Authorities.—*Himly*, Krankh. u. Missbild. II. Berlin. 1843. S. 330–339.—*Arlt*, Krankh des Auges. II. Prag. S. 335.—*Stellwag*, Ophth. I. S. 570, 575, 583.

2. Linear Extraction.

Indications.—This operation is particularly indicated:

1. In fluid and pulpy, as well as in pasty, total cataracts.

2. After the division of cataract, and after wounds of the globe, when the fragments of the lens, pressing forward out of the wounded capsule, excite severe irritation, and the crystaline has become pulpy throughout its extent.

3. In regressive and shrunken cataracts without nuclei, especially in siliculose cataracts, and secondary cataracts related to it.

The Operation varies considerably, according as we have a fully softened or a shrunken leathery cataract. A division into two distinct methods is, however, untenable, as soft cataract is often transformed to siliculose cataract, and an operation combined of the sub-varieties is required.

The necessary instruments are a straight lance-shaped knife, and either a sickle-shaped needle or an iris-hook, a Fischer's forceps, and a Daviel's spoon.

First, the pupil being fully dilated by atropine, the chamber is to be opened with the lance-shaped knife. The opening is always made on the temporal side of the cornea, in the horizontal meridian or somewhat below it, about one line from the scleral border. The knife should be so placed that its surfaces shall stand perpendicular to the meridian of the point of entrance, and its point press obliquely through the cornea. When the point has entered the chamber, it is to be advanced in the same meridian plane, between Descemet's membrane and the capsule, until the corneal wound is about two lines long, and then slowly withdrawn, while the aqueous escapes.

a. If the cataract be fluid or pulpy, and the capsule clear, as soon as the patient becomes quiet, a sickle-shaped needle is passed flat through the wound as far as the opposite margin of the lens, and the capsule divided as far as possible with long strokes in various directions. Fluid and starchy cataracts are usually, for the most part, evacuated during this manipulation; on the other hand, pulpy cataracts only approach the wound, and a little of them escapes.

Fig. 96.

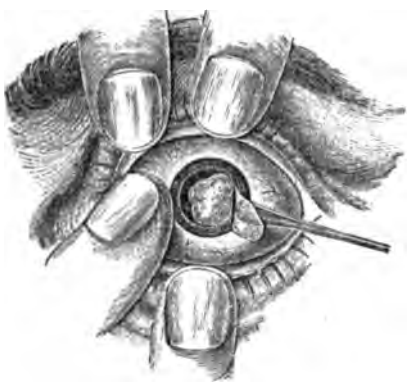

To complete the evacuation, the convex surface of Daviel's spoon is pressed against the posterior lip of the corneal wound, until the opening gapes. At the same time, one finger of the hand fixing the lid is laid on the inner margin of the cornea (Fig. 96), and slight, increasing pressure made toward the center of the pupil, to drive the cataractous substance in the inner part of the fold of the capsule toward the opening of the capsule and cornea. If this be not sufficient to

remove the cataract entirely, the lids are to be kept closed for a while, to allow some aqueous to collect; then, by laying the ends of the fingers flat on the lids, and moving them in a *circular* direction, the remaining fragments of cataract will be pressed toward the middle of the pupil. And it will only be necessary to let the corneal wound gape again for the cataract pulp to escape. If the pupil can not be cleared in this way, the spoon is to be passed into the anterior chamber, and the fragments brought out with it. If remains of the capsule then appear in the pupil (they may be detected by the irregular reflection of their folds or their veil-like cloudiness), they should be extracted with the iris-hook or forceps.

b. If the capsule be clouded by regressive cataractous depositions, and be more or less stiff and tenacious, it is best to introduce an iris-hook flatwise, instead of the sickle-shaped needle, to hook the capsule near its inner edge, to rotate the instrument slowly on its axis so as to gain more points of attachment, and envelop its sharp point in the folds of the capsule, and then, with gradually increasing careful traction, move it toward the corneal opening. If the anterior capsule has already become very tenacious by the deposition, we not unfrequently succeed in bringing it out of the wound entire. But, if the hook pulls out, the opening in the capsule is at least sufficiently large to permit the evacuation of the cataract by aid of Daviel's spoon, as above described; then the remains of the capsule should be again seized with the hook, and extracted.

c. If it is a dry capsular or secondary cataract, the operation is still more simple; for such cataracts, as a rule, follow entire the careful traction of the hook (Fig. 97), and the Daviel's spoon is unnecessary. If the hook tears out, or if the cataract has already a free margin to seize, it is better to introduce the forceps, and complete the extraction with these, as they have more points for attachment than a hook, and hence are more certain.

The puncture must be made a line or more from the scleral border; for, if the inner opening of the wound be peripheral, a prolapse of the iris may readily occur, as the pupillary margin will be driven into the wound by the escaping aqueous and the fragments of cataract, especially when the pupil contracts on account of the diminution of intraocular pressure. Moreover, when the puncture is made near the edge of the cornea, the iris is endangered by the instruments introduced, and often is much injured mechanically.

The lance-shaped knife should be passed obliquely through the cornea, because instruments can be more easily introduced and withdrawn through an oblique wound, without stretching or bruising its inner lip; and the cataract may also be brought out more readily in a straight direction than in one bent almost at a right angle.

Fig. 97.

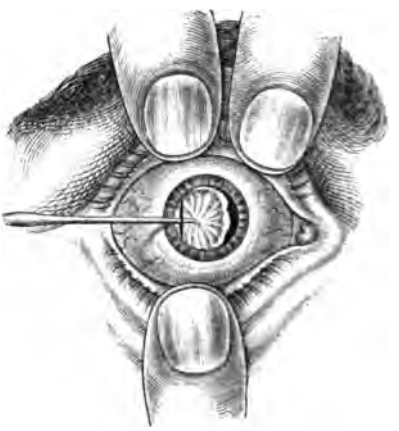

Accidents.—1. The pupil occasionally contracts very much at the moment the aqueous escapes, and the intraocular pressure ceases. This greatly impedes the division of the capsule, as well as the exit of the cataract. In such an event, nothing more can be done; hence it is to be avoided by careful and repeated use of mydriatics.

2. Prolapse of the iris frequently occurs during the operation. If only a little is prolapsed

after removing the capsule and fragments of cataract, we may sometimes replace the iris by closing the lids and lightly rubbing the surface of the eye at intervals, in a circular direction, and thus exciting the sphincter to strong contraction. This maneuver is especially successful in prolapse of the pupillary margin. In such a case, we may also attempt to reduce the prolapse with a Daviel's spoon; but we should avoid excessive manipulation, as the mechanical irritation to the prolapsed iris, caused by this process, easily leads to severe inflammations, which are far more injurious than the prolapse itself. If the reduction is not readily accomplished, it is best to seize the prolapsed portion with the forceps, and cut it off close to the cornea. In any case, if part of the pupillary margin has been in the wound, whether it has been replaced or excised, a strong solution of atropine should be dropped in the eye before the pressure-bandage is applied, so that the pupil may dilate after adhesion of the wound, and its border be removed as much as possible from the latter. This is also advisable where the pupil is much contracted during the operation, without a prolapse occurring, as this sometimes does not take place till after the application of the bandage, when the patient strains on account of pain, and the aqueous that has collected escapes from the wound.

3. Incomplete evacuation of the cataract. Where the operation has been successfully done, this danger only threatens, when we have been mistaken in the consistence of the cataract, and have used linear extraction at a wrong time; when, instead of a fluid or pulpy total cataract, there was one with a normally consistent exterior or a hard nucleus; or, instead of a leathery, tough, capsular cataract, there was a friable cataract breaking to pieces on being touched, or one that was partially retrogressive. In such a case, it would be unwise to try to effect the complete evacuation by frequent use of the Daviel's spoon, as severe inflammation almost always results, and, in spite of all our care, a considerable part of the cataract usually remains behind. In such cases it is best to satisfy ourselves with breaking up the cataract, and excising a piece of the iris, and then, as well as frequently during the after-treatment, to use a strong solution of atropine.

4. Prolapse of the vitreous, from bursting or instrumental injury of the hyaloid, requires the immediate interruption of the operation, and the application of a protective bandage, as continued attempts to remove the remaining portions of lens are fruitless, on account of their lateral displacement; on the contrary, they cause further prolapse of the vitreous, and thus increase the danger of intraocular hemorrhage, retinal detachment, severe reaction, &c.

Authorities.—*Himly*, Krankheiten und Missbildungen. II. Berlin. 1843. S. 285.—*Fr. Jaeger*, nach Ed. Jaeger, Die Behandlung des gr. Staares, Wien. 1844. S. 51. S. und Staaroperat. Wien. 1845. S. 45.—*Graefe*, A. f. O. I. 2. S. 219, 278–286.

3. Flap Extraction.

Indications.—Flap extraction is only suited for cataracts with nuclei whose density exceeds that of the layers around them, especially—

1. In cortical and total cataracts of young or mature individuals, when the cortical layers have softened, but the nucleus retains a normal consistence, or is even more dense, and is large.

2. In all senile cataracts, and especially where there is a sclerosed nucleus of only moderate size, whether the exterior be of normal consistence, softened, or retrogressive.

The Operation requires great practice on the part of the operator and assistants. It is done in several stages, after each of which the lids are gently closed, to give the patient time to collect himself.

The instruments required, are: a cataract-knife, a sickle-shaped needle, an iris-hook, a Daviel's spoon, and fine scissors curved on the flat; perhaps, also, a Fischer's forceps.

It is better not to use ophthalmostats in flap extractions, for they give the patient pain, and so cause him to strain the muscles of the eye.

Of all the cataract-knives that have been recommended (*Himly*), "Beer's" answers best, and is by far the most frequently used. Quite recently, however, keratomes, with bellied edges, such as were formerly used (*Himly*), have been recommended by some. (*Zehender*, *Küchler*.) Graefe's cystotome is not a good substitute for the sickle-shaped needle, as, on account of its shape, it is difficult to sharpen, and it is apt to catch in the iris and wound it, while being passed in or withdrawn from the corneal wound.

The length of the flap should be in proportion to the size of the nucleus. If too large, it is not so readily adjusted, and the danger of suppuration is increased; but if too small, the cataract does not escape, or only does so by stretching the angle of the wound; the section has to be enlarged subsequently, otherwise very injurious results may arise from forced delivery of the lens. A section of half the circumference of the cornea is never necessary; even with large nuclei it is sufficient to make the knife enter and come out a little below (in the lower section) the horizontal diameter of the eye, and to cut so that the outer lip of the flap may be near the limbus conjunctivalis. For a small nucleus and soft cortical substance, a somewhat smaller flap suffices.

To make the flap, while the patient turns the eye outward, the point of the cataract-knife is to be entered perpendicularly, just below the horizontal diameter of the cornea, near the limbus conjunctivalis; passed through the cornea, then turned, passed across the anterior chamber as quickly as possible (without too much haste, however), and, at a point of equal hight, passed out close to the margin of the conjunctiva, and without delay pushed on till the edge of the knife is against the posterior wall of the lower segment of the cornea, or has already passed into its posterior lamellæ. Then we are to stop, give the patient a little time to recover

himself, and finally cut through very slowly and carefully by moving the knife forward and backward without making any pressure.

After the patient (with his eye-lids lightly closed) has again become calm, we proceed to open the capsule. For this purpose the capsule-needle is to be held horizontally, and passed, with its back anteriorly, up under the flap without lifting it. When the cutting part has reached the pupil, the point is turned toward the capsule, which is to be divided as extensively as possible, and in various directions; but at the same time we must carefully avoid injuring the iris. When this has been done, the needle is to be again turned horizontally, and drawn out with the back looking anteriorly.

If the flap is large enough, or larger than is necessary, if the muscles of the eye contract moderately, the nucleus follows at once, and is evacuated without aid. If this is not the case, the lids are to be again closed, till the patient has recovered himself; then we are to evacuate the cataract. This is to be done by holding the lids apart (Fig. 98) and pressing the convex side of the Daviel's spoon gently against the upper margin of the cornea. The pressure is propagated to the upper border of the lens, and, as this turns backward and downward, the lower border of the nucleus turns forward and upward, presses the inferior half of the iris and the corneal flap forward, finally overcomes the opposition of the pupil, and, with the aid of the vitreous, pressed forward by the recti muscles, it passes through the gaping corneal wound. If the exit of the nucleus is long delayed, it is best to interrupt the operation, and permit the patient to keep his eye-lids gently closed, and recover himself, then to renew the attempt. Where the muscles of the eye are not very active, it is sometimes necessary to renew the trial two or three times, as a strong pressure with the Daviel's spoon might readily prove dangerous, especially by causing a rupture of the zonula, and a prolapse of the vitreous.

Fig. 98.

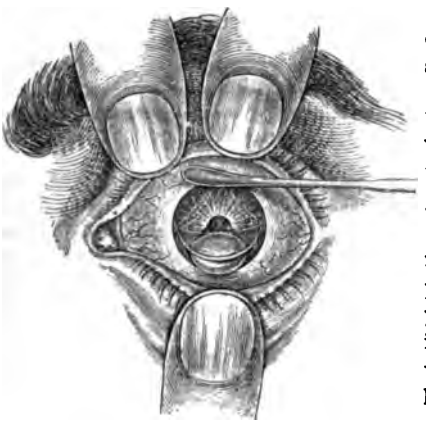

When the nucleus has escaped, the lids are to be again closed for a time. Then it is well to rub the surface of the eye in a circular direction, with the index and middle fingers gently applied over the lid, to excite the sphincter pupillæ to contract, and thus most gently to remove any folds or displacements of the iris, and also to bring into the pupil any fragments of cataract remaining in the folds of the capsule. Then we have the patient open the eye carefully, and observe whether the pupil is quite black and regular; if so, we apply the bandage immediately. If there be still any fragments of cataract in the pupil, a Daviel's spoon should be passed under the flap, and the remaining masses scooped out. Particular attention is to be paid to any flocculi between the iris and cornea, or lying in the wound, also to any protrusion of the iris between the edges of the wound, as this impedes the adhesion. The bandage should not be applied till all the fragments of cataract have been removed from the wound, and prolapsed portions of iris have been replaced.

1. The flap may also be made upward. Formerly this was only done when it was desired to avoid cicatritial opacities in the lower half of the cornea (*Himly*), but later it has been done as a rule. (*Fr. Jaeger.*) It has the advantage of hiding the deformity better, when the section leaves an opaque cicatrix, if a sector of the iris comes under the knife, and is cut off, or if the pupil is distorted on account of a prolapse of the iris. But the chief advantage is, that if the flap does not adjust perfectly, but the upper lip projects, it does not so readily strike against the upper lid and become loosened on motions of the eye, or subsequently keep up irritation, and thus, in various ways, injure the effects of the operation. But the operation is more difficult to perform, especially in restless patients, whose eyes often turn up under the upper lid, and do not obey the will. It is true, the globe may be brought back to its position by the fixation forceps; but if much traction is made, they readily cause pain, and thus increase the restlessness and the straining of the patient.

2. As the flap is being formed, the eye should look outward, as in this position it is much easier to complete the section without entering the knife into the bridge of the nose, which renders the patient uneasy, and often obliges the operator to stop before the edge of the knife has reached the inferior segment of the cornea, whereupon the aqueous rapidly escapes, and a large portion of iris comes under the knife. This is the more threatening, if, as often happens at the moment of puncture, the patient seeks to evade the knife, and rolls the eye inward. If the optic axis were directed slightly outward, the excursion would have to be considerable to interfere with the operation, and it would also require more time; hence, when the axes are directed outward, it is easier to pass through the chamber and get the globe fully in our power before the point of the knife touches. But this maneuver is not always certain; hence, when making the puncture, we should be prepared for the movement of the eye. We should never start with the idea that we *must* go through. If the eye moves, it is better to withdraw the instrument and repeat the attempt, when a moment of rest permits the section to be made.

3. The point of the knife is to be introduced perpendicularly; if it be held too flat, it passes through the cornea. The perpendicular canal is very long, and holds the knife fast in the original position; hence its point passes through the chamber very near to the posterior wall of the cornea, and passes out just as obliquely. The extent of the arc cut is, therefore, large, and the opening proportionally small; hence the cataract is not evacuated, or its escape is difficult, and the sharp, inner wall of the posterior lip of the wound is easily stretched or bruised, and severe inflammations may be caused.

4. The cutting should be done very slowly and carefully, no pressure being made on the cutting edge of the knife; otherwise, bringing out the knife suddenly, the patient is frightened, the muscles of the eye contract spasmodically, and evacuate not only the lens, but part of the vitreous. Hence, the force should always act in the axis of the instrument.

5. The manipulation of the Daviel's spoon, also, requires the greatest care; it is to be lightly placed on the upper border of the cornea, and the pressure gradually increased. In proceeding hastily, there is no time for the pressure to be distributed; the under part of the zonula may be torn, and the vitreous evacuated. The pressure should never be great.

6. Of late, some have altogether thrown aside Daviel's spoon, and evacuated the cataract with the finger, which may, if necessary to prevent slipping, be wrapped in a piece of fine cloth. (*Arlt.*) The patient is told to look upward, and the operator places the palmar surface of his two thumbs, or of the thumb of one hand and the index-finger of the other, on the upper and lower lids, so that he can move them as he chooses over the eye-ball. Then, pressing the upper lid downward, he gently presses on the upper margin of the cornea, and thus rotates the lower margin of the lens forward toward the wound. The lower lid is, at the same time, pressed forward with the other hand, and, by slight pressure on the anterior part of the eye, the cataract is induced to escape through the incision and the slightly-opened eye-lids. The retained cortical portions are to be removed by gently rubbing the upper lid over the cornea.

Accidents.—1. *Wounds of the iris.* *a.* If the iris is pierced as the cornea is opened, it is best to withdraw the knife, and not undertake the operation again till after the healing of the cornea, as, by further advance of the instrument, the iris would be extensively divided, which would interfere with the continuance of the operation, and might also prove dangerous.

b. Most frequently a sector of the iris is excised during the completion of the section. This happens particularly if the chamber is very small, the pupil contracted, and the iris bulged for-

ward, for then the knife can with difficulty be passed by it. But, when there is a *large* chamber, the iris falls under the knife, if this passes through slowly or interruptedly. Then we may often press the iris away from the edge of the knife by turning this forward, and with the end of the finger making moderate pressure on the lower section of the cornea, so as to flatten it somewhat, or by stroking downward the part of the cornea lying in front of the knife, with the ends of the fingers lightly laid on. But this attempt often fails, and there is nothing left but to sacrifice the portion of iris in question. Sometimes, however, the corresponding part of the pupillary margin remains, and a *hole* is left in the iris. It is then necessary to divide the bridge with the needle, so that the cataract may not catch, strain the iris, and even rupture the bridge.

2. *Difficulty in the escape of the cataract.* In spite of strong contractions of the muscles of the eye and of aid from the operator, the lens pushes the lower half of the iris between the edges of the wound of the cornea, but recedes again, or finally passes through the pupil with difficulty, causing stretching and straining of the iris. This is often caused by the large size of the sclerosed lens, or an extensive synechia and callous transformation of the pupillary border, rarely by a spasmodic contraction of the sphincter of the pupil.

In such cases we should make an iridectomy immediately after the flap is made, to prepare the way; if the cataract has already escaped, to follow it by an iridectomy, so as to remove the injured portions of iris and prevent the results of mechanical irritation. The most usual cause of the difficulty of exit of the lens is, that the flap is too small or the section through the cornea has been too flat. If we recognize this condition, we should avoid forcibly pressing out the cataract, as the angle of the wound would be strongly pressed, and nevertheless the evacuation often would not be effected, as the vitreous would escape first; we should rather enlarge the section as much as necessary, by introducing the scissors between the flap and the iris, and enlarging one or other angle of the wound. The traditional fear of the scissors is groundless, as the part of the wound formed by the scissors, as a rule, heals as readily as that made with the knife, and usually does not even leave a cloudy cicatrix—provided, of course, that the eye, and especially the angle of the wound, have not been too much injured before the scissors were used. If this has happened, an iridectomy should be performed.

3. *The incomplete evacuation of the cataract.* A large part of the cortex has from the first remained attached to the capsule, or has stripped off during the passage of the cataract through the pupil, and can not be removed by the Daviel's spoon without danger of a prolapse of the vitreous, or great irritation of the iris. Where the passage of the cataract through the pupil is difficult, as well as in the extraction of cataracts with normally consistent cortex—that is, particularly in unripe cataracts—this accident is very common, and the more difficult to avoid if the parts of cataract remaining in the eye be still transparent, and thus escape observation. Where we are certain, or tolerably confident, that large quantities of fragments capable of swelling have been left behind, we should perform an iridectomy immediately after the extraction.

4. *Escape of the vitreous before the cataract.* This very unfortunate accident occurs particularly if a part of the section is in the sclera, or when, on opening the capsule, the needle comes too near the margin of the lens, or if, during the evacuation of the cataract, the spoon has been too quickly or too firmly pressed on it, that is, under circumstances causing a bursting or wounding of the zonula with the needle. Straining on the part of the patient greatly favors the rupture. In such cases it is often necessary to stop the operation and apply the bandage; for, with continued attempts to evacuate the cataract, more and more vitreous escapes, the lens sinks further back, and finally we must cease, after having very greatly increased the danger of intraocular hemorrhage, detachment of the retina, imperfect adjustment of the flap, severe inflammation, &c. Still, in quiet patients we may sometimes succeed by cutting out a broad sector of the iris, passing the spoon behind the cataract, pressing it forward against the posterior wall of the cornea, and withdrawing it.

5. *The lens, with a portion of vitreous, advance.* This accident is especially apt to occur in restless patients, who strain violently, if the corneal flap is too large, or the Daviel's spoon is carelessly used. We should then give up the operation and apply the bandage, otherwise the vitreous will be mostly evacuated, which, as above shown, may prove a serious accident. Fluidity of the vitreous is also given as a cause of this accident. In eyes which otherwise appear normal, actual fluidity of the vitreous, or even a diminution of its consistency, is, however, very rare, and can scarcely be recognized beforehand. Where, however, choroiditis or irido-choroid-

itis has preceded, or there is extensive posterior staphyloma, synchesis occurs more frequently, and must be taken into consideration.

6. *Incorrect opposition of the flap*, with stair-like projections of its edges. Then, on motion of the eye-ball, the latter strikes against the lower lid, and this causes great irritation, which is often the source of very injurious inflammation. The danger is the greater, since, on motion of the eye, before the cicatrix has become sufficiently strong, the badly-applied flap is often partially loosened, and the intraocular pressure is thus often entirely removed. Unfortunately, little can be done for this, particularly shortly after the operation, when it is most necessary. Neither plasters nor collodion suffice to keep the lower lid away from the eye, as, on account of the irritation caused by the artificial ectropion, tears flow abundantly and soften every thing; moreover, the necessary manipulations are dangerous shortly after the operation. We should avoid all sources of irritation, and quietly await the gradual, spontaneous smoothing-off of the prominence. This is usually accomplished in a few weeks.

[It is proposed to avoid such accidents by applying a suture of a single strand of silk or very fine thread by means of a needle, which is straight or only slightly curved at its point, "only a quarter of an inch long, and having its point flattened to a cutting edge and carefully sharpened. The needle is held and passed through by means of a pair of firm forceps." The suture "is allowed to remain until it cuts itself out, which is sometimes not for several days or even weeks; or it may be removed after the wound has become consolidated, say at the end of a week or ten days." *H. W. Williams.*]

7. *Prolapse of the iris.* This is often a secondary result of incorrect apposition of the flap, and may be produced by carelessness of the patient several weeks after the operation. Most frequently, however, the prolapse occurs immediately after the escape of the lens, as a part of the iris has been torn out with it, and the operator has neglected to replace it, or has been obliged to neglect the reposition on account of prolapse of the vitreous or restlessness of the patient. At all events, a decided *distortion*, or even a *closure* of the pupil, results, especially when severe iritis occurs, as is not unfrequently the case. It may also happen that the flap becomes very irregularly curved and interferes with vision, as the cicatrix contracts, but still maintains a certain breadth, so that the edge of the flap stands off more or less from the inferior lip of the wound. (Fig. 20.) To obviate such evil results, it is best to have the bandage worn longer than would otherwise be necessary, that is, until the cicatrix is thick and strong. If the pupillary margin has become adherent, atropine should be used to keep its upper part as far as possible from the point of adhesion. Excision or repeated punctures are only indicated in very large and constantly-increasing prolapse of the breadth of the iris, especially when there is danger that the pupillary margin will finally be drawn into the wound.

8. *The occurrence of entropion.* This accident is not unfrequent in very relaxed, elderly persons, particularly during the after-treatment. If the protective bandage is still in use, it should be at once removed, as it greatly favors the inversion of the lids. Among the positive remedies, the canthoplastic operation is particularly to be recommended.

Authorities.—*Beer*, Lehre v. d. Augenkrankh. II. Wien. 1817, S. 366, 372.—*Himly*, Krankh. u. Missbild. II. Berlin, 1843. S. 255 et seq.—*Arlt*, Krankh. des Auges. II. Prag. 1853, S. 298, 300.—*Hasner*, Kl. Vorträge Prag. 1860. S. 289, 293, 301.—*Stellwag*, Ophth. I. S. 635, 637, 642.—*Zehender*, Kl. Monatbl. 1863. S. 73.—*Küchler*, Deutsche Klinik. 1865. Nr. 39.—*Hüring*, Kl. Monatbl. 1863. S. 217.—[*H. W. Williams*, Diseases of the Eye, P. 193.]

4. Peripherical Linear Extraction. (*Graefe.*)

The Indications for this operation are the same as those for flap extraction. But it has also certain special indications:

1. For the removal of cataracts whose cortical portion is quite adherent, and whose capsules are of normal consistency.

2. Where general or local conditions render suppuration of the cornea imminent.

3. Where the condition of the patient renders a less strict regimen advisable, or, more particularly, a shortening of the time of his confinement to bed.

The Operation is much like flap extraction, and, like this, is done with several pauses for the patient to rest and recover himself.

The instruments required are a narrow, pointed knife (*Graefe*), iris-forceps, and a fine Louis' scissors; a delicate sickle-shaped needle with rounded, blunt back; a sharp and a blunt hook, a thin and very flat spoon (*Bowman*), or better, a scoop with projecting anterior edge (*Critchett*), a toothed forceps, and a spring speculum.

The sickle-shaped needle and the hooks should have malleable necks, so that we may alter the curvature; for if the neck of the instrument is straight and stiff, and the eye is deeply set, the instrument can not be readily introduced flat into the wound and moved in various directions in the plane of the iris. For the same reason, the spoon is more convenient, if its concavity is at an angle to the neck.

Snowden's spring speculum, which has long been in use, does not answer well here, because the part uniting the two arms interferes with the introduction of the different instruments. Hence this part has been much elongated, so that, when in use, it rests on the temporal region. (*Graefe.*) But the elongation of the arms causes a loss of power in the spring; hence the instrument must be made heavier, or furnished with an adjusting screw, which is somewhat objectionable. It would seem best, therefore, to have a small Snowden's speculum with an *anterior* curve, so made that the part uniting the arms should lie on the side of the nose, when the instrument is placed in the conjunctival sac.

More recently several spring elevators have been constructed on this principle (*Stilling. Schrader*).

Fig. 99.

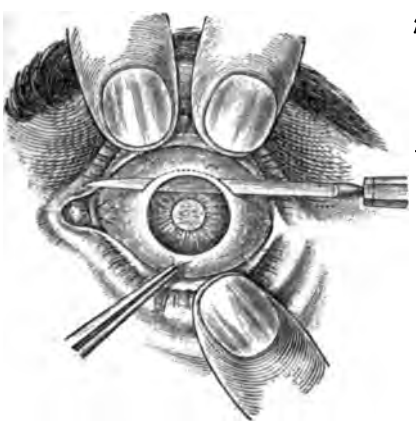

In modified linear extraction, the *upper* part of the anterior scleral zone is usually opened. In order to make the requisite linear section at this place with one or a few strokes of the knife, the upper eye-lid should be held well back by the operator or an assistant; and to prevent rolling of the globe, this is seized with toothed forceps, placed exactly under the lowest point of the corneal margin, drawn downward, and held in this position. (Fig. 99.)

The incision should vary in length according to the supposed size of the nucleus; but four to four and a half lines may be considered as the medium length.

For this purpose the knife should be entered about one third to half a line from the anterior margin of the cornea, and two thirds of a line to a line below a tangent to the highest point of the cornea, in the outer part of the anterior scleral zone. The knife is to be held with the cutting edge inward and upward, and its point directed toward the middle point of the anterior chamber. It is entered obliquely in this position, so that it appears in the anterior chamber, close to the origin of the iris; it is advanced about three lines, and then turned horizontally, so as to be passed through the corresponding inner portion of the anterior scleral zone at the same hight, and at an equal distance from the cornea as the point of entrance. When this has been done, the instrument should be passed on horizontally with its back downward and anteriorly (Fig. 99), and if the point comes near the nose it should be drawn back till its edge has severed the attachment of the upper sector of the iris, as far as the margin of Descemet's membrane, and rests against the inner wall of the sclera. Now the knife should be turned so that its back shall be toward the ideal center of the corneal curvature, so that the capsule of the globe may be divided by long strokes almost perpendicularly to its surface. Then the knife lies between the sclera and conjunctiva, and the latter appears raised in a broad fold. As the conjunctiva is very distensible and gives way, the cutting edge should be turned forward, and the membrane divided by a sawing motion. The wound in the latter thus forms an anterior convex arc, whose summit reaches nearly to the limbus conjunctivalis.

The second step of the operation, the excision of the portion of iris presenting at the wound, is facilitated by the use of the spring speculum. In order to manipulate readily, it is necessary to lay the conjunctival flap back on the cornea. The piece of iris is then seized with the forceps, pulled out and cut off close to the scleral wound, so that no tags may remain in the wound.

In order to take the second step in the operation without disturbance, namely, the excision of the portion of iris bulging into the wound, it is very necessary to strip off the conjunctival flap from the wound, and to lay it back upon the cornea. The sector of the iris in question must be fully embraced with the forceps, put upon the stretch and cut off close to the edge of the scleral incision, in order that no ragged edge may remain behind which may be crowded into the wound. With the length of the wound it is, however, very difficult to embrace between the forceps the entire portion of iris corresponding to it; hence, it appears advantageous to complete the excision of the iris with several cuts, at first, therefore, to embrace the central portion and pull it out, and afterwards to do the same to the internal and external portions, and cut them off. At the same time it is necessary to put the iris firmly upon the stretch, so that as much of it may be brought forward as possible. Afterwards the position of the lower half of the pupillary margin is to be carefully observed, and often it will be already found in its normal situation. If this is not the case, and if it appears drawn somewhat towards the wound, then a portion of the incised edge of the iris is firmly engaged in the angles of the corneal incision, and this usually occurs on the temporal side. In order to get rid of this we make use of the india-rubber spoon. The surface of the globe must be gently stroked with its convex surface, beginning somewhat on the scleral side of the corners of the wound in question, and directed from this point towards the centre of the cornea.

These manœuvers may be executed also alternately in a direction corresponding more to the length of the wound, always proceeding from the corresponding corner, or even in a circular direction over the part in question. If only the nasal edge of the iris is adherent, we frequently gain our end by the introduction of the cystotome, by carefully smoothing the iris with its back introduced into the anterior chamber, before proceeding to open the capsule.

The opening of the capsule is best done in four movements, in order to be able to cut out as large a piece as possible, and to allow of the extraction of the cataract, which may push the piece forward into the wound like a curtain. The necessary instrument for this, the lancet-formed cystotome or Sichel's needle, the neck of which is bent at a corresponding angle, is pushed flat-wise through the wound as far as the lower portion of the pupillary margin, then turned with the edge towards the capsule, and the latter split at first along the two lateral edges of the pupil and coloboma throughout the entire pupillary space, after this especially in a transverse direction, once close to the inferior periphery of the pupil, and then about a millimeter below the superior equator of the lens. (*A. Weber.*)

If the capsule has been sufficiently opened, the nucleus of the lens frequently appears of itself at the opening in the sclera, and it needs but slight assistance to cause it to come out. To this end the india-rubber spoon is to be slightly pressed with the convex back upon the lower border of the cornea, by which means the scleral wound is made to gape somewhat. After this the spoon must be somewhat turned so that its upper edge presses a little into the cornea. Then by pressing the instrument in this position upon the surface of the cornea gently upwards, the cataract will be lightly pushed out of the wound, and may be easily lifted up with the spoon, after it has passed with a great part of its circumference through the wound.

Whatever part of soft, broken-up lens-matter has remained behind in the capsule during this process, may be pushed towards the wound as in the flap-extraction by stroking the cornea from below upwards slightly with the back of a spoon. If the lens-matter is not completely evacuated there remains nothing to be done but to go in with the spoon and bring it out.

Just as in flap extraction, we should make it a rule to clear out the cataractous lens as completely as possible; to draw out portions of capsule that have become stiff from deposits; clean the wound properly, and remove any pieces of iris that may be caught in it; and, finally, to replace the conjunctival flap in its natural position. When all this has been done, it seems advisable to open the eye again in a minute or so, and let out the aqueous that has collected; for this not unfrequently washes out with it some small pieces of cataract and effused blood.

The after-treatment and dressing are to be regulated as in flap extraction. But in modified linear extraction, after the first couple of days, the patient requires less restriction, and may be allowed more freedom, as the detachment of the flap is here less to be feared. After the second day, instillations of solution of atropine should be made with proper care once or twice daily, so as to diminish, as much as possible, the irritating influence of any retained portions of cataract.

1. A very perpendicular corneal incision, as was formerly employed, and is still preferred by many, has the disadvantage, that it takes away every support from the zonula in the region of the wound, and thus so much the more favors prolapse of the vitreous, as the cataract, in order to enter the opening, must make a considerable rotation forwards; hence the spoon for the extraction has to exert a greater pressure in a perpendicular direction upon the lower border of the cataract, which necessarily brings with it a bulging of the vitreous humor towards the opening of the wound. In a more oblique incision the rotation of the cataract does not occur, and the latter may move outwards in the direction of its equatorial plane. In addition to this, the posterior edge of the wound is pushed under the anterior edge of the wound, and pressed upon by the intraocular pressure, closes the opening like a valve, and hence no portion of the zonula appears exposed.

The corneal incision may also be made, of course, at the inferior margin of the cornea.

This is even an easier operation. Still the patient is readily dazzled by reason of the excision of the iris, which troubles him very much. The lower incision is therefore only justifiable when the state of the eye and its surroundings or the unruliness of the patient render the incision upwards very difficult.

2. The use of the spring speculum in the second stage of the operation has the advantage of enabling us to do without a second assistant; for, while both hands of the operator are engaged with the iris-forceps and scissors, and those of the assistant with the two eye-lids of the patient, a fifth hand is required for the fixation forceps. This, apart from the other inconveniences, diminishes the space that was already very limited. In the other steps of the operation, the operator always has one hand free to use the fixation forceps, or to hold one of the lids; hence the speculum may then be dispensed with, and should be removed, as it inconveniences the patient, and causes straining, which may interfere with the operation, and induce prolapse of the vitreous.

3. It is not advisable to make very large conjunctival flaps, as they readily roll up, infiltrate, and may thus unfavorably influence the healing of the scleral wound. Cutting them off is also bad, as a large wound is the result, and it does not always cicatrize and harden without causing serious irritation. These circumstances cause us to turn the knife forward, after it has divided the sclera, and appears under the conjunctiva. For the same reasons, we should be careful of the conjunctival flap, and keep it off the cornea during the subsequent steps of the operation, so that it may not be injured by the instruments.

4. The iris must be excised close to the anterior edge of the scleral wound. If portions of the iris remain caught in the wound, they easily become the origin of destructive inflammations, by reason of the laceration to which they are exposed. In some cases they subsequently bulge forward, like vesicles, and require subsequent excision. Aside from this, such adhesions of the iris have the unpleasant effect of pulling up very much the lower part of the pupillary margin, sometimes even above the horizontal diameter of the eye, and thus, when the upper lid hangs down, a large portion of the pupil is concealed. The vision then suffers so much the more, as through such a displaced pupil no central rays, but only marginal rays, reach the retina, and hence less distinct images are here produced. It is believed that the complete excision of the iris throughout the whole region of the corneal incision may be done more easily and safely by straight or knee-shaped scissors, than by those curved on the flat. (*Graefe.*)

5. A great difficulty lies in this operation in the fact that the anterior capsule, after evacuation of the aqueous humor, is pressed close to the posterior surface of the cornea by the pressure of the vitreous humor, that its central portion falls exactly into the greatest concavity of the cornea and is thus with difficulty reached by the edge of the instrument. Hence it also happens, that very often a more or less broad crescentic-shaped edge of capsule remains behind in the lower portion of the pupillary space. This afterwards becomes opaque, conceals the pupil partially covered by the upper lid, and injures the acuteness of vision very much. By the manifold changes in the form of the cystitome (*Ed. Meyer*, *A. Weber*, and others), this drawback cannot be remedied: we should rather aim at carrying the point of the instrument over the convexity of the anterior capsule beneath the level of the inferior margin of the pupil, without previously pressing into the cavity of the capsule.

6. It is difficult to divide the capsule sufficiently, if it has become hard and tough from deposits. Then, instead of using a sickle-shaped needle, it is best to enter a sharp hook and seize it deeply. Not unfrequently we may tear loose the anterior half, and bring it out entire. In retrogressive and atrophied cataracts, the entire lens and capsule often respond to the traction, and may be removed from the eye without difficulty.

7. Formerly it was recommended to this end to exert more pressure upon the globe with the fixation forceps, and thus to render the lower portion of the capsule of the globe more tense, but besides this to press the posterior edge of the wound of the sclera somewhat downward with the convex back of a spoon, and thus allow the instrument to glide to and fro in the horizontal direction. The so-called sliding maneuver has also been employed by many, that is, while the finger fixing the edge of the upper lid exerted a slight pressure upon the superior circumference of the globe, the back of the spoon was repeatedly placed against the inferior margin of the cornea and by delicate pressure rubbed up towards its center. More recently, all pressure upon the peripherical edge of the wound and upon the superior circum-

ference of the globe has been considered inadvisable or at least superfluous. Some, however, still advocate this maneuver, and believe that the slight downward pressure of the peripherical edge of the wound may promote the gaping of the wound, and therefore the exit of the cataract also, but that, moreover, the pressure of the back of the spoon may give support to the zonula and hinder prolapse of the vitreous. (*Knapp.*)

Accidents.—1. *Too small a linear wound.* With some care and practice, this cannot readily occur, as the section is, on the whole, very easy; for the knife closes the wound with considerable certainty, and so prevents the too early evacuation of the aqueous humor. Hence, if the point of entrance has been made too high, we have time enough to make the point of exit correspondingly lower, so as to compensate for the deficiency. The knife may even be partly drawn back into the chamber and thrust out elsewhere. But if, in spite of all this, an error has been committed, there is nothing left but to enlarge the wound with the scissors.

2. *Hemorrhage into the chamber.* This accident sometimes occurs, even during the division of the conjunctiva, but is more frequently seen as a result of the iridectomy. It is not very serious. It is only necessary to suspend the operation for a time, and gently stroke the cornea with the back of the spoon, in order to press the blood out of the wound. If the aqueous has again collected, it is often sufficient to lightly depress the posterior lip of the wound, to cause the escape of the blood, and keep the field of operation clear during the opening of the capsule.

Sometimes, however, the anterior chamber becomes refilled, as often as it is emptied. Then the extravasation is in a high degree hazardous for the further steps of the operation, and not uncommonly endangers very much the success of the operation. This accident points to a far advanced degeneration of the vessels, particularly when the extravasated blood shows a very dark color. The hemorrhages then easily occur repeatedly after the operation, while the absorption remains very incomplete; the coagula increase, become in part organized in connection with the products of reactive inflammation, and occasion, at least, the reclosure of the pupil. Iridochoroiditis and iridocyclitis also frequently occur with their extremely deleterious consequences. In not a few cases extravasations of blood do not appear until several days after the operation, in the anterior chamber, or even in the cornea. They are then, for the same reasons, very serious.

Difficult Extraction of the Cataract.—It is generally caused by too small, sometimes, however, by too oblique a section of the cornea. In such a case the wound must be enlarged with the scissors. Often, however, the cataract cannot be extracted even when the corneal section is large enough, and the anterior capsule is opened sufficiently, and the manœuvers well performed. Under such circumstances, it is certainly not imprudent to make use of the so-called traction instruments, no matter how much it may be by many opposed. Their careful and delicate employment surely carries fewer dangers with it, than a prolonged general bruising of the globe, which perhaps in the end does not produce the desired effect, or even draws after it a prolapse of the vitreous. If the nucleus be large and sclerosed, we shall do best with a blunt hook, which, like Sichel's needle, is to be pushed with its angular bent neck flat through the wound and the posterior cortical layers of the cataract to the other side of the equator of the nucleus, and then is to be turned with the point forwards in order to embrace the nucleus and draw it outwards. The latter almost always follows readily, even when the superior marginal portion of the capsule has not been sufficiently cut through, as the latter is easily turned over outwards by the pressure of the advancing cataract. In cataracts with normally consistent nuclei the hook still cuts easily through, breaks up the lens, and leaves the pieces behind, as the latter easily avoid it. Under such conditions, as well as in cases where a normally consistent cortex must be separated from the capsule, the hook is best replaced by a suitably-constructed spoon.

4. *Prolapse of the vitreous* is the most frequent accident. It is especially to be feared in persons that strain greatly, or where the vitreous is fluid, as a result of precedent disease of the eye-ball. Under such circumstances it may occur at any stage of the operation, and greatly interfere with the subsequent steps. It usually occurs when the linear incision has been made too far back in the sclera, and has exposed a portion of the zonula; or if the latter has been injured by the needle or the hook; or, finally, if the ciliary processes, or the hyaline covering of the lenticular fossa have been too much stretched in the attempt to evacuate the

cataract, or have been pierced by instruments, or ruptured in any other way. If part of the vitreous escapes *before* the cataract, the hook or spoon should be instantly used to seize the lens and draw it out. But if the vitreous escapes with or after the cataract, it is best to close the lids at once, and apply a tight bandage for the first couple of hours, so as, if possible, to prevent intraocular hemorrhage and detachment of the retina. Prolapse of the vitreous is always a misfortune, as it readily causes inflammatory cloudiness of the part remaining in the eye. This often does not pass away for some time, and in some cases clears up very incompletely, so that it greatly impairs vision. We fear such opacities particularly when the fragments of the cataract cannot be completely removed, and come in immediate contact with the vitreous.

5. *If part of the vitreous protrudes into the scleral wound*, without the hyaloid being wounded, it is advisable to leave it there and simply apply a bandage; for it is not apt to cause much injury, and the prolapse readily absorbs; while cutting it off involves the danger of a more extensive evacuation.

6. Portions of lens-matter often remain behind in the pupillary space, particularly when the cortex was not completely disintegrated by softening, which subsequently swell up and by setting up violent inflammation become very dangerous. It has been recommended to expose the wound upon the 3d or 4th day, in order to remove the remaining portions of lens with a spoon. (*Küchler.*) Other attempts to remove them have in every case resulted in prolapse of the vitreous, and the fragments had to be left behind. (*Knapp.*) Moreover, the danger of such an undertaking is evident, and hence it is opposed energetically by the best authorities.

7. *The Development of a Capsular Cataract.*—It is frequently attributed to an insufficient splitting open of the anterior capsule. Frequently, however, the opacity results from a subsequent proliferation of the cataractous fragments remaining attached to the posterior capsule, or from the new formation of permanent products, and cannot then be avoided. Such opacities require discission. Still it is very advisable to allow several weeks to elapse, in order that the globe may recover from the extraction. Many recommend not to discharge any patient from treatment, before the posterior capsule has been thoroughly split by a new operation. (*Critchett.*) Still we shall do well to limit this operation, painful for the patient, to those cases in which it is a real necessity.

8. We often meet with a cystoid cicatrization. The rules before given should be followed in treating it.

Authorities.—*Graefe*, A. f. O. XI. 3. S. 24—80; XII. 1. S. 156—181, 198, 202 bis 210; XIII. 1. S. 273; XIII. 2. S. 549, 559; XIV. 3. S. 106, 119, 134 u. f.; kl. Monatbl. 1870. S. 1, 8 u. f.; Congrès ophth. 1868. S. 61, 95.—*O. Becker*, ibid. S. 72.—*Critchett*, ibid. S. 80; nach Knapp. A. f. O. XIV. 1. S. 305.—*Heymann*, Ophthalmologisches. Leipzig. 1868. S. 38, 45 u. f.—*Knapp*, A. f. O. XIII. 1. S. 58—103; XIV. 1. S. 287, 291, 293; Arch. f. Aug. u. Ohrenhlkde. I. S. 47.—*Weber*, A. f. O. XIII. 1. S. 250, 256; kl. Monatbl. 1868. S. 384.—*Ed. Meyer*, ibid, S. 382.—*Stilling*, ibid. S. 289.—*Nagle*, ibid. S. 340.—*Schröter* ibid. 1869. S. 126.—*Küchler*, Die Querextraction. Erlangen. 1868. S. 24.—*Dantone*, Beiträge zur Extraction etc. Erlangen. 1869. S. 66.

5. Streatfeild's Peripherical Extraction.

This method is merely a modification of the preceding operation of Von Graefe. The patient being placed well under the influence of an anæsthetic, a spring speculum is introduced between the lids, and the eye itself steadied by grasping a considerable fold of conjunctiva at some distance below the lower margin of the cornea, with the toothed forceps. Mr. Streatfeild prefers a Sichel's knife, as in iridectomy, because with it a section of the cornea can be made less obliquely in all its extent than by puncture and counter-puncture, which, in iridectomy for glaucoma, is also an advantage. The point of the knife being directed towards the center of the pupil, the cornea is transfixed at its upper margin at the right-hand extremity of the intended incision; the point of the knife is then carried on between the cornea and iris along the upper circumference of the anterior chamber. No counter-puncture is made, but the knife is quickly brought into a more vertical position, and with a firm hand and quickly, by little to-and-fro movements, the section is continued as far as need be to the left extremity of the intended opening. That this extremity may be square like the other, and not at all oblique, the knife should be either drawn out at the end of the section, held quite vertically; or, the knife being held horizontally, the edge is brought upwards and forwards, and its point is made so to cut its way out suddenly at one stroke. The corneal opening should be as large as one-third of the circumference of the cornea; it had much better be unnecessarily large than a little too small in any case; it is easily extended at either end, if it should seem to be necessary, by reintroduction of the point of the knife into the anterior chamber, and cutting right or left. No conjunctival flap is left to cover the wound. A considerable iridectomy is as usual made, and the lens-capsule opened. To evacuate the lens, the back of the curette, held horizontally, is now pressed on the globe between the lower margin of the cornea and the point below it, at which the globe is held with the fixation-forceps. By moderate pressure backwards, gradually increasing, and by a succession of little sliding movements from below upwards, the upper margin of the lens will begin to protrude at the corneal opening. As soon as the largest part of the lens has been evacuated, care must be taken to remove completely all the softer cortical matter, by continuing the sliding movements with the curette, until the cortical matter exudes through the wound and the area of the pupil looks clear and black. A drop of atropine may be then instilled. A piece of fine linen (about 6 × 3 inches), is placed over both eyes, a little pad of fine wool is placed in each orbital space, and over this is fitted a Liebreich's bandage of elastic knitted cotton, and tied comfortably tight.

Liebreich's Corneal Extraction.

In this operation, the entire line of incision is included in the cornea, with the exception of the puncture and counter-puncture, which are situated about a milli-

Fig. 100.

meter from the corneal margin. Liebreich at first did a simultaneous iridectomy, but gradually excised a smaller and smaller portion of iris, until he finally abandoned it altogether.

Fig. 101.

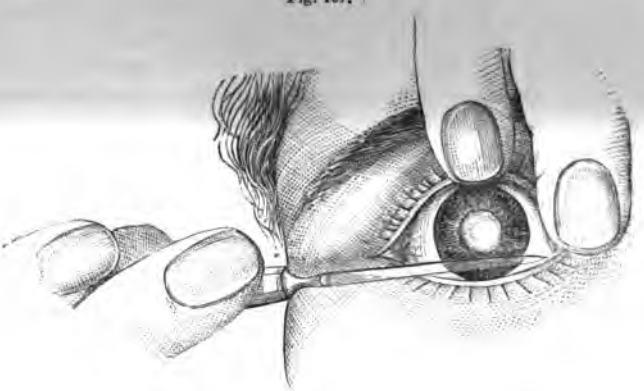

The operation has the immense advantage of dispensing with the spring speculum and fixation forceps; and but two instruments are necessary, the narrow knife and the cystotome, which may even be combined in one. It is better, when possible, to dispense with an anæsthetic. The pupil should be dilated completely with atropine, and if the operator is ambidextrous, he may stand behind the head of the patient. An assistant is not indispensable. The upper lid is elevated by the forefinger of the one hand, while the narrow knife of Von Graefe, with the back of the blade directed slightly backwards, is held horizontally with the other hand, and its blade so inclined as to form with the horizontal meridian of the eye an angle of about 45°. The point is introduced in the sclerotic about a millimeter from the external border of the cornea, without changing its direction; the knife glides

across the anterior chamber to the opposite point of exit, which should be about a millimeter beyond the corneal margin. The knife is then pushed far enough along to admit of completing the incision by withdrawing it. As the incision is completed, the upper lid is allowed to fall over the eye. The second step in the operation consists in opening the capsule carefully and thoroughly. The third step is the delivery of the cataract, and here the spoon of Daviel comes into play. It is pressed lightly against the inferior part of the cornea, while the index-finger of the other hand exerts a slight counter pressure upon the upper portion of the cornea. By these means a slight rotation is given to the lens; its inferior border advances towards the posterior surface of the iris, pushes the latter forward, glides along the

Fig. 102.

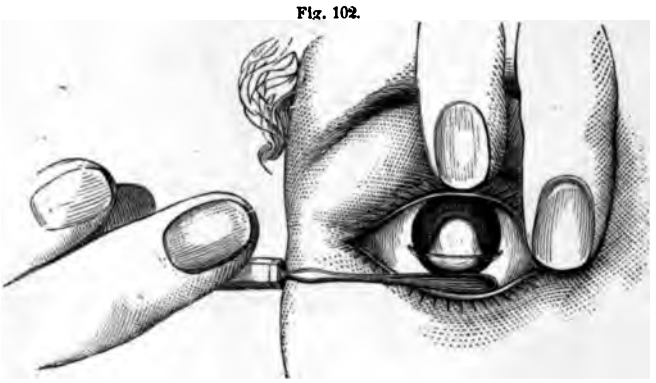

iris towards the pupil, overcomes the resistance of the sphincter, and is finally engaged in the wound which is already gaping to receive it. A slight pressure, produced by the movement of the index-finger of the left hand upon the upper lid over the superior portion of the cornea, is sufficient to cause its extrusion. This gliding movement of the lid is to be kept up until all the cortical matter has been expelled. Atropine is then to be instilled, and the eyes are closed with a bandage. Liebreich claims that this method is applicable for all cataracts, except zonular cataracts, soft cataracts of childhood, liquid cataracts, or partial cataracts without nucleus.

PART IV.

FUNCTIONAL DISEASES.

FIRST SECTION.

DISEASES OF REFRACTION AND ACCOMMODATION.

Preliminary Remarks.—The chief component parts of the dioptric or refractive apparatus of the eye are the cornea and crystaline lens, which together act as a convex lens. They are separated from each other by the aqueous humor, and from the retina by the vitreous body. Their surfaces, which are the most important surfaces of the dioptric apparatus, represent sections of ellipses, whose eccentricities, however, under normal circumstances, are so slight, that their central portions, lying within the bounds of the pupil, may be considered as segments of a sphere.

1. The anterior surface of the cornea is the vertical segment of an ellipsoid with three axes, of which the longest extends antero-posteriorly, while the two shorter ones are perpendicular to this, and, with rare exceptions (*Donders*), to each other. (*Knapp.*) The chief sections—that is, the planes passed through the long axis and each of the shorter ones—may fall in any meridian of the cornea (*Javal*, *Donders*); but usually the meridian corresponding to the smaller axis (the greater curvature) is nearer the vertical, and the minimum of convexity, on the contrary, nearer the horizontal meridian of the cornea (*Knapp*, *Donders*, *Reuss*, *Woinow*, *Snellen*). It is rare to find the opposite, or to find the curvature the same in all meridians, as it would be, if the corneal surface represented a surface formed by the rotation of an ellipse.

The same is true of the curvatures of the two surfaces of the lens (*Helmholtz*, *Knapp*, *Rosow*); they also are non-symmetrical, with meridians of greatest and least curvature, which are, as a rule, perpendicular to each other. But, contrary to what obtains in the cornea, the maximum of curvature in the lens is usually nearer horizontal, and the minimum nearer vertical. (*Knapp*, *Donders.*) But these diameters of the cornea and lens do not usually come in the *same planes.* The convexity of the lens-surfaces is often much less regular than that of the cornea. The length of radii of adjacent meridians is often very unequal, and frequently varies even in the same meridian. (*Donders.*)

2. The principal surfaces of the dioptric apparatus have not exactly the same axis, but the summit of the cornea is usually to the nasal side of the axis of the lens. (*Helmholtz.*) Frequently the plane of the equator of the lens is placed obliquely to that of the base of the cornea (*Knapp*); but, under normal circumstances, these deviations are too slight to perceptibly impair the retinal images.

3. The axis of the cornea does not necessarily correspond with the axis of vision; that is, with the line passing from the object fixed to the point of direct vision. But generally the visual axis cuts the cornea within its zenith, and usually below, rarely above, the horizontal meridian. (*Young*, *Helmholtz*, *Knapp.*) The horizontal deviation varies from two to eight degrees (*Schuerman*), the vertical from one to three degrees (*Mandelstamm*).

Still, this angle α is not a constant one, as it is to be measured from the nodal point, and the latter changes its place during the change of accommodation of the eye. Therefore, even in one and the same individual, it must be different according to the various degrees of convergence of the visual lines (*Reuss*, *Woinow*, *Mauthner*).

4. The most important of the four surfaces is the anterior corneal surface. In it the incident rays are most diverted from their course, because here the light enters from a slightly refractive medium—the atmosphere—to one of a relatively high re-

fractive power. In fact, a simple calculation shows that parallel rays of light, falling on the anterior surface of the cornea, will be so affected as to come to a focus about five lines behind the retina. Hence we can say that the posterior focal distance of the anterior corneal surface only exceeds the optic axis of the eye by a few lines.

The posterior surface of the cornea, although having a greater curvature, comes but little into consideration, in respect to the dioptric conditions. The traversing rays of light may almost be regarded as passing through the same medium, as the refractive power of the cornea and aqueous humor differ but little.

In consequence of the slight difference of refractive power of the neighboring media, the two surfaces of the lens have also but slight influence on the progress of the rays. That the crystaline lens, nevertheless, acts as quite a powerful refractive medium, is explained by the fact, that it is composed of a great number of layers, whose refractive power increases from the surface to the center, and thus inside of the lens a number of surfaces exist, whose dioptric effect is all summed up together. Indeed, the rays passing through the lens are deflected more from their original direction, by this formation, than they would be if the entire lens were formed of homogeneous layers of equal refractive power with the nucleus. Hence, under normal circumstances, parallel rays falling on the cornea unite on the sensitive layer of the retina.

5. A complete union of the rays of light emanating from single points does not occur, however. Besides, this very slight, and, under normal circumstances, unnoticed, *chromatic* aberration (*Helmholtz, Freck, Pope*), the asymmetrical form of the dioptric apparatus, also, occasions an aberration of rays of the same color, i. e. *monochromatic* aberration. (*Helmholtz.*) This is described as *astigmatism.* (*Young, Airy.*)

6. The ellipsoidal form of the chief surfaces causes the homocentric light, in the different meridians of the dioptric apparatus, to be unequally deviated, hence to be focused at different distances. This species of monochromatic deviation, when confined to rays that are refracted in different meridians, shows a regularity and unity corresponding to the original curvature of the corneal surfaces, and is called *regular astigmatism.* Its chief cause is the ellipsoidal curvature of the anterior surface of the cornea, whose refractive power far exceeds that of all the other surfaces. The want of symmetry in the surfaces of the lens is also important, and particularly in a *corrective* point of view, as the maximum and minimum of their curvatures are usually in the opposite direction to those of the cornea. But, as this opposition of position is rarely exact, the equalization is not so complete as the refraction of the different meridians of the lens would otherwise render it. We may say that the astigmatism of the cornea *alone* is usually greater than that of the dioptric apparatus, as a whole. But we can not say that the latter corresponds to the *difference* between the astigmatism of the cornea and that of the lens. (*Middleburg, Donders.*) Cases occur where the maximum and minimum of convexity of the cornea and lens approximate or correspond, and hence the sum of the two forms the total astigmatism (*Knapp*).

The corrective action of the lens does not seem to remain the same in different conditions of accommodation of the same eye, but to change according to the change of form of the lens (*Dobrowolsky, Woinow*).

Hence the general rule is, that the maximum and minimum of refraction of the dioptric apparatus are determined by the anterior corneal surface, and, consequently, that those rays which fall on the cornea, in a meridian near the vertical, are united at the shortest distance, while divergent rays, falling horizontally, are united at the greatest distance.

In order to correctly understand this form of astigmatism, it is well to undertake a closer examination of the course of the rays of light in passing through the dioptric apparatus. If the

refraction is a maximum in the vertical meridian, and a minimum in the horizontal, rays striking on the cornea from a point in the extension of the optic axis, after passing through the pupil and lens, will no longer give a section of a circle, on a screen crossing the optic axis at right angles, but will form an ellipse, whose long axis is horizontal, and whose eccentricity increases when the screen is moved backward. At a certain distance, the rays, falling on the cornea in a vertical meridian, unite, while the others still converge, the section will become horizontal, as the images of dispersion of the still converging rays form themselves collectively into a horizontal line. Beyond this *anterior focal line*, the rays, stretching in the vertical meridian, diverge again, while those passing through the horizontal meridian still converge; the image on the screen again presents a horizontal ellipse, whose eccentricity, however, decreases, if the screen is moved backward and becomes reduced to nothing at a certain point, so that the image acquires the form of a circle. This is exactly the place where the rays undergo, proportionally, the greatest concentration; hence it may with some propriety be called the "middle focus," or the "middle converging point." Beyond this point, the image again becomes an ellipse, whose long axis is, however, vertical, and whose eccentricity increases when the screen moves backward, till, finally, the rays, striking on the horizontal meridian, unite, and the vertical section of the bundle of rays presents a vertical line, *the posterior focal line*, on account of the mutual covering of the sectors refracted in the vertical and oblique meridians. Beyond this line, however, the image will have the form of an ellipse, with the long axis perpendicular. (*Knapp, Donders.*)

A more direct examination into the condition of refraction of the dioptric apparatus shows that only the foci of these rays, which are refracted in the two chief meridians, fall in the optic axis; that, on the contrary, the foci of the remaining rays fall in an irregular plain, which joins the two focal lines. It further teaches that the length of the anterior focal line is to that of the posterior focal line as the focal distance of the more strongly-curved diameter is to that of the lesser curved; that is, the anterior is shorter that the posterior. Finally, it results from this, that the cross-shaped section (i. e. the point of greatest concentration of the bundle of homocentric rays broken up in the dioptric apparatus) lies nearer the anterior focal line, and is the nearer, the greater the difference of the two focal lines. (*Knapp, Donders.*)

To be exact, we should not speak of the *focal distance* of the dioptric apparatus, but of the *focal tract*, whose length is equal to the difference of the focal distances of the two chief sections; hence it increases and diminishes in proportion to the difference of curvature.

At most, we may recognize as focal distance some spot within the focal tract, where the rays are most concentrated, and which lies nearer to the anterior limit of the focal tract than to the posterior. (*Knapp.*) Ordinarily, however, the differences of the focal distances of the two chief meridians is very slight; hence, in representing the conditions of refraction, they may be neglected, and a common focal distance taken for homocentric light.

The deviation of the rays broken up in the different meridian planes of the eye is ordinarily too slight to interfere with distinct vision; careful experiments even are necessary to show it clearly. In accordance with the above, we find that most persons distinctly see vertical lines or a point of light through a horizontal stenopäic slit, at a greater, but horizontal lines and a bright point through a vertical stenopäic slit at a shorter distance. Moreover, if the adjustment of the dioptric apparatus remains the same, they see the bright point distorted horizontally or vertically, according as it is actually, or by the use of glasses apparently, brought nearer or removed.

7. The irregularities of curvature of the different sectors of the lens, together with the frequent want of correspondence between the centers of the different surfaces, cause monochromatic aberrations, which are very complicated, and affect not only rays that are refracted in different meridians, but even those that enter the cornea through the same meridian. These deviations (irregular astigmatism) from

the slightness of the malformations and the relatively weak refraction of the crystaline, are, under normal circumstances, less disturbing than those caused by the asymmetrical formation of the cornea; but, under some circumstances, they are very marked. The stellated figures of dispersion, in which brightly-illuminated points—as the stars, or even distant small flames—are seen, as well as the doubling or multiplication of the images (*diplopia and polyopia monocularis, H. Meyer*), depend on this, as is proved by the fact that these appearances do not occur in eyes deprived of the lens (*Donders*), but do not disappear when the refraction of the cornea is overcome by dipping the eye in water. (*Young.*)

Normal irregular astigmatism is most evident, when a bright or dark spot, with a contrasting background, is regarded from a distance, for which the eye can not be adjusted, especially if the pupil is dilated. A bright spot then appears as a distorted, radiated star, whose greatest diameter approaches the vertical or horizontal meridian, according as the object is beyond or within the point of distinct vision. Where the points are less bright, or are dark, only the more decided parts of the figure of dispersion are perceived; hence this is divided into a number of distinct figures. The same reasons explain the doubling and multiplication of lines, of the horns of the moon, &c. (*Helmholtz, Donders.*)

8. The layer of the retina, sensitive to light, consists of a great number of simple elements, cones, and rods. These are pressed against each other, like mosaic work, with their bases toward the inner surface of the retina. Their walls are reflecting surfaces, and throw back all rays of light falling into the element, thus preventing the rays passing from one element to another. (*Brücke.*)

Each rod and cone, on account of its elementary simplicity, can only bring to perception the combined total impression of the rays of light falling on it at any time. A separation of the different simultaneous impressions is scarcely possible in one simple element. Even the rods, although several of them are united to the brain by a single nerve-filament, most probably can not separate their individual impressions, but carry to the brain a total impression, composed of the combined individual impressions.

Inasmuch as each sensitive element of the retina has, under normal circumstances, an unchangeable relation to the optical center of the eye, if the refractive media are properly adjusted, it can only be reached by direct rays, which diverge from a certain section of the visual field. For it is nearly the same with the eye as with a simple spherical lens; certain points on the object and the corresponding points of its image, lie on a straight line which passes through the center of the lens. That which, in a simple lens, we call the *axis* and *chief ray*, in the eye is called *visual line* and *line of direction*, or ray of direction.

Strictly speaking, the position of the retinal image is determined by two lines, of which one passes from the object to the anterior nodal point [Donders on Accom. and Refrac. New Sydenham Society's translation, p. 50], the other, parallel to the first, from the posterior nodal point to the retina. (*Listing.*) But as the two nodal points lie near each other, we can, without great error, consider the two as coinciding. This nodal point, which we consider as simple, is then the optical center of the eye and the crossing-point of the lines of direction.

Lines of direction (*Richtungslinien*) and visual lines (*Sehrichtungen*) are very different. The former relate to the course of the objective rays of light, and may be called light lines (*Lichtlinien*). By their direction in relation to the axis of vision, they determine the relative position of the object and of the image in the *monocular* field of vision and on the retina. The axis of vision, on the other hand, indicates the position in absolute space, toward which the retina refers the impression of its sensitive elements. The lines of direction and the visual axis can never coincide, but must always be separated to some extent. (See section on *Muscles.*)

As the cones and groups of rods present surfaces rather than points exteriorly, it is evident that to each element, or series of elements, there belongs not a point but a certain aliquot part of the visual field, in proportion to its surface, and that hence the visual field is divided into as many parts as in the retina there are groups of rods and cones.

The relative size of these parts or the sections of the visual fields, is proportionate to the surface of the elements belonging to it. In the center of the visual field they are smaller, as the basis of the cones is there smaller, and the rods are absent. The absolute extent of the sections, however, is in proportion to the extent of the entire visual field, therefore, also, to the length of the lines of direction drawn to its limits. As an immediate consequence of this, there is great difference between the optical qualities of the objective retinal images, and the subjective perception of optical peculiarities of corresponding objects; that is to say, while the retinal image gives the surface of the object down to its finest details, since a point of the former corresponds to each point of the later, each point of the retinal image is not perceived by itself and separate, but will be made up of only so many perceptions as there are cones and groups of rods covered by the retinal images, and no more. Consequently, the fineness of the perceived details of a certain object depends, on the one hand, on the relative size of the retinal images, or the visual angle at which the object is seen, so that the object must be brought nearer to the eye the finer the details.

On the other hand, the place on which the retinal image falls is of the greatest importance. The power of separating impressions exists, to the greatest extent, in the center of the retina, where only cones receive the outward impressions; hence, objects that are to be examined carefully must be turned toward the center of the retina, where the "point of direct vision" lies. In proportion to the lessening of the cones, and the increase of the bases of the different groups of rods, this power of the retina evidently diminishes toward the periphery. This occurs sooner in a vertical than in a horizontal direction (*Aubert, Förster*); still, the distinctness of "indirect vision" can be increased by practice, while it sinks by neglect (*Möser*). In the region of the entrance of the optic nerve the *light-perceiving* elements are entirely absent, and hence a portion of the field of vision proportionate in size appears defective, but on account of the subordinate rôle which the spot in question plays in the visual field, is unheeded (*Woinow*).

Doubts have been raised against the supposition that the cones are visual units, as their bases have been found too great to allow of explaining the empirical exactness in the separation of individual impressions (*Volkmann*).

However, the diameter of the base, as it has recently been found in the cones of the fovea centralis (*M. Schultze, H. Müller, Welker*), is entirely sufficient to render possible the separate perception of objects, the distance between which amounts nearly to 60 seconds (*Helmholtz, Bergmann*), particularly if it is confirmed, that the visual field of the macula lutea is deficient (*Hensen*).

The sharpness of vision, or the measure of the power of separately perceiving individual impressions, is not always the same. The visual angle, necessary for the separation, varies even in normal eyes, and in disease the difference is often very great.

These differences are of great practical interest, and means have long been sought for easily measuring the angle in question, in each case, so as to express in figures the relation of the existing central sharpness of vision to the supposed normal amount.

Practically, test-types answer this purpose. Since these only form small angles, the height of the letters, divided by the greatest distance at which they can be distinctly seen, gives the tangent of the angle sought, exactly enough. Generally speaking, five minutes is the smallest visual angle at which print can be fluently read. Hence, five minutes is usually considered as the normal angle, and the sharpness of vision is expressed by the proportion of the greatest distance at which type of a certain height can be clearly seen, to the distance at which the same type is seen with the normal visual angle of five minutes. (*Snellen.*) To avoid the calculations that would be necessary if all kinds of type were used, and also to give the most evident value to the sharpness of vision, certain test-types have been prepared. The smallest of these is 0.209''' Paris measure high h, and at a distance of one Paris foot (one hundred and forty-four lines) d, gives an angle of five minutes. Each subsequent number is a multiple of this. The coefficient precedes each set of types as its *number*, and it of course gives at once the number of Paris feet to which the object must be removed from the eye, in order to be seen at the normal visual angle of five minutes. Hence, an eye with normal vision should see the types 1, 2, 3, n at a distance of 1, 2, 3, n Paris feet, for $\frac{h}{d}, \frac{2h}{2d}, \frac{3h}{3d}, \frac{nh}{nd}$ = tang. five minutes. If, on trial, an eye can not distinctly see 2h, but only 4h at 2d, and at 4d can only see 8h, of course $\frac{4h}{2d}, \frac{8h}{4d} = 2$ tang. five minutes. The requisite visual angle is double the normal; hence the sharpness of vision is diminished one-half. (*Snellen.*)

This method is evidently very convenient, but it does not give perfectly accurate results; for five minutes is rather too great a visual angle for persons under twenty-five years. (*Vroesom.*) By diminishing this and proportionately dividing the shadows and clear portions (*Giraud Teulon*), the measurement is made more exact, but still not perfectly so, for the illumination of the visual field has a decided influence on the results of the examination; so that, under different circumstances, the same eye may show great differences in sharpness of vision. The greater or less practice in reading also makes a difference, for it enables many to recognize letters from their shadows, while they are very indistinctly seen. Finally the numerical values found for the sharpness of vision do not permit calculations without losing their value. For example, a sharpness of $\frac{10}{20}$, $\frac{4}{8}$, or $\frac{3}{6}$ is not the same as $\frac{1}{2}$; for eyes that see No. 10 type distinctly, at twenty feet, do not necessarily see No. 2 at one foot, No. 4 at two feet, etc. Hence the values of the sharpness of vision, laid down in some books, do not give an idea of the actually existing state of the case, even apart from the fact that the illumination of the field of vision, and other important circumstances, are entirely left out of consideration. To give an idea of the sharpness that is to be at all correct, all reduction of the fraction must be avoided.

To the possessors of Jaeger's test-type it may be of use to know that No. I appears under an angle of 5 minutes at a distance of 14,'' II at 19,'' III at 28,'' IV at 33,'' V at 35,'' VI at 38,'' VII at 4,' VIII at 4.5,' IX and X at about 5,' XI at 5.5, XII at 6.75,' XIII at 7.5,' XIV at 10,' XV at 13.5,' XVI at 17.5,' XVII at 24,' XVIII at 30,' XIX at 37,' and XX at 44' (*Zehender*).

Tests for vision with numerous grouped points as well as with parallel lines (*Burchardt*) are less suitable for ascertaining the acuteness of vision, as they are easily recognized under a much smaller visual angle than 5 minutes by reason of the simplicity of the objects.

The measurement of the acuteness of vision is always to be undertaken with the

ked eye. If the eye to be examined is provided with a concave or convex glass, e magnifying coefficient and relatively the diminishing coefficient must be taken to account. The latter is for convex glasses $\frac{V}{V-C}$, for concave glasses $\frac{V}{V+C}$, 1 which V signifies the focal distance as regards the glass and C its distance from he optical center of the eye. This coefficient in strong glasses is, as the formula ives, of great significance for the size of the retinal image, and therefore is also of reat importance in ascertaining the acuteness of vision. (*Woinow.*)

9. It is evident that quite sharp images must be thrown on the anterior surface of he bacillar layer of the retina to give distinct perceptions. For if circles of dispersion, of some size, fall on the surface, the light arriving at the eye from each egment of the visual field is divided up among a number of cones and rods, and inversely each cone and rod is met by light from different parts of the visual field; hence the perception of the details of the object is indistinct. This occurs in proportion to the size of the circles of dispersion; that is, in proportion to the size of he pupil, and the distance of the images from the anterior surface of the bacillar membrane, or to the "difference of the posterior focal distance."

Hence the circles of dispersion must acquire a certain diameter, before the image becomes indistinct. Very small circles of dispersion influence the clearness of the perceptions in a very light, almost imperceptible, degree; as they throw too little light from single sections of the visual field on the sections in the neighborhood of their corresponding retinal elements, for the quality of the perceptions received from single cones and groups of rods to be perceptibly changed. Hence it follows, if the dioptric apparatus is adjusted, and remains so for a certain distance, the object can change its distance within certain bounds, without the perceptions losing much in clearness; that hence the eye is never adjusted for a single distance, but for *a difference of distances*, which is called the line of accommodation, and whose length increases and diminishes in inverse proportion to the varying focus of the dioptric apparatus, and to the diameter of the pupil. (*Czermak.*) Hence it is also shown that the ellipsoidal form of the chief dioptric surfaces, as a rule, does not disturb sharp vision; that astigmatism only appears to a disturbing degree, when the difference of the refractive circumstances of the two surfaces, or the size of the pupil, is much increased.

Under otherwise normal circumstances, this indistinctness can never become absolute, as the size of the circles of dispersion only varies within certain relatively narrow limits; for, if the object be brought into the anterior focus of the cornea—that is, within a few lines of the eye—so that the rays pass parallel into the aqueous, they will still be brought to a focus something over an inch behind the retina.

The diameter of the circles of dispersion scarcely ever reaches that of the pupil. Hence, in spite of totally abnormal adjustment of the refractive apparatus, the outlines of dark objects may still be recognized, and their boundaries only appear more or less indistinct.

As may be readily understood, these errors are, to some extent, improved by contraction of the pupil or partial closure of the eye-lids, or by using a shade with a narrow slit in it. There is also a possibility of suppressing the circles of dispersion; that is, of estimating the true forms of objects from their indistinct images. This power varies in different eyes, and may be increased by exercise. (*Graefe.*) It is, however, never anything more than an aid, and does not always give distinct perceptions of small objects, or fine details of larger ones.

10. The power of the eye to see clearly and distinctly at different distances presupposes the power of voluntarily shortening, and again increasing, the focal distance of the dioptric apparatus, so as to correspond to the differences in the posterior point of convergence, which are caused by the variation of the distance of the object. This power of the eye to adjust its dioptric apparatus for different distances is called the power of *accommodation* or *adaptation.*

The distance for which the eye is accommodated in complete relaxation of the

muscle of accommodation is called the far-point, and its reciprocal value determines the natural or minimum condition of refraction. On the contrary, the distance for which the light-refracting apparatus is accommodated by the maximum of the possible attempts at accommodation, is the near-point. The far-point and the near-point are themselves points of the prolonged visual line and form the limits of the range of distinct vision. The difference of the reciprocal values of the far-point and near-point is called the range or equivalent of accommodation. (*Donders.*) We can more readily understand these conditions by a diagram. Let *HH* be a spherical surface, with the radius *rr* (Fig. 103) and the axis *AA* the dividing surface of two

Fig. 103.

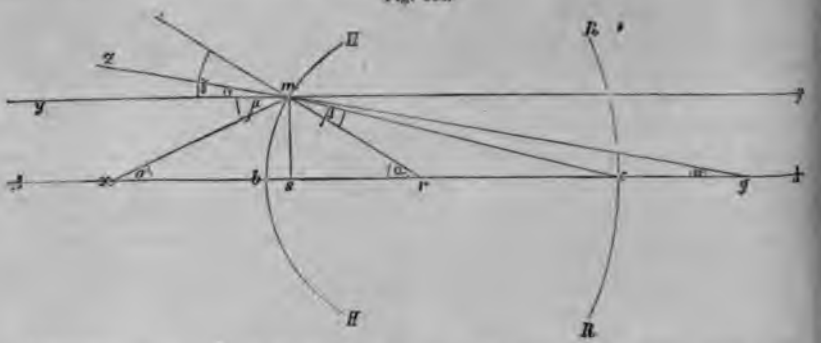

refracting media, the first of which is the air, but the second possesses an exponent of refraction, which makes the deviation of the rays of light falling upon that spherical surface the same as that in the whole dioptric apparatus. The general law of refraction $\sin. \alpha = n. \sin. \beta$, where α signifies the angle of incidence and β the angle of refraction, holds good for every incident ray *xm*, *ym*, *zm*. Since for distinct vision of external objects the union of every individual homocentric bundle of light upon the retina *RR* is necessary, and since the length of the axis of the globe *bc*, and therefore the size of the angle β also, is for every eye a fixed one; it is evident that in the above equation n must rise and diminish in proportion to the size of the sine of the angle of incidence, that this sine, therefore, furnishes a measure for the condition of refraction $N = n. \sin. \beta$, which is necessary for the union of homocentric bundles of light upon the retina. If we proceed from the angle of incidence $\gamma = \rho$ of parallel rays *ym* as the normal and place $\gamma = \theta$, hence $\sin \gamma = \theta$, then it also appears in the above equation that $n = \theta$. If then divergent rays *xm* fall upon the spherical surface, if therefore the angle of incidence *xmr* becomes greater than θ, then the sine of this angle and the n of that equation must naturally be also greater than θ, the necessary condition of refraction N appears positive and so much the greater, the nearer the source of light *x* advances to the eye. If, on the contrary, convergent rays *zm* meet at the spherical surface, if therefore the angle of incidence *zmr* is less than θ, then its sine and with this the n of the equation also becomes smaller than θ, the necessary condition of refraction N becomes negative, and reaches a more considerable negative value, the more the rays converge, the nearer therefore their point of union *g* approaches the optical center of the system.

We see plainly from the preceding, that the necessary condition of refraction N, as well as n, is really determined by the two angles μ and ν, and that N, when we

make $\gamma = \theta$, may also be expressed by *sin.* μ and *sin.* ν. Now, on account of the parallelism of yy and AA, the angle $\mu = o$ and $\nu = \omega$. The condition of refraction F finds, therefore, its expression under the same hypotheses in the sine of the central angle which the ray in question incloses with the optical axis AA. As we always have to do with very small central angles, we must make $xm = xs$ and $gm = gs$, without any essential error being brought into the estimate.

If we assume in the schematic eye ms as the measure of the unit of length in the value of a line, an inch, a centimeter, etc., the sine of the angle of difference, and consequently, also N, appear equal to the reciprocal value of the positive or negative distance of the source of light. By the power of the accommodation the condition of refraction N of the eye is increased, since by reason of the increase of convexity of the lens the refractive value of the entire system is increased. This referred to the diagrammatic eye shows an increase of n, and consequently of the *sin.* a also. In so far as the power of accommodation is a limited one, the *sin.* a also will only vary inside certain limits. The difference between the sine of the smallest and largest angle of incidence, or, what is the same thing, the difference between the minimum and maximum condition of refraction, or between the reciprocal values of the distance of the far and near points is therefore what we call the range of accommodation.

The range of accommodation amounts in the eyes of young persons with normal functions frequently to $\frac{1}{3}$, almost to $\frac{1}{4}$ and even more, in early manhood about $\frac{1}{5}$, and sinks in old age far below this value. If the distance of the far-point F is determined in a case, the distance of the near-point P may then be estimated with the help of the range of accommodation and vice versâ. The minimum condition of refraction *plus* the range of accommodation gives the maximum condition of refraction, and this *minus* the range of accommodation gives the minimum condition of refraction. A varying length and position of the range of distinct vision naturally corresponds to the same range of accommodation. The former becomes so much the longer, the more the minimum condition of refraction approaches zero in a positive or negative direction, and the greater the range of accommodation itself is.

In the following table the conditions of minimum refraction are collected together, increasing from left to right, and under each one the corresponding value of maximum refraction is placed, which is given under the hypothesis of a range of accommodation of $\frac{1}{3}$. The denominator of the fraction in the upper row gives the position of the far-point, the denominator of the fraction standing under it gives the corresponding position of the near-point.

$$\frac{1}{2},\ \frac{1}{3},\ \frac{1}{4},\ \frac{1}{5},\ \frac{1}{10},\ \frac{1}{20},\ \frac{1}{40},\ \frac{1}{\infty},\ -\frac{1}{40},\ -\frac{1}{20},\ -\frac{1}{10},\ -\frac{1}{5},\ -\frac{1}{4},\ -\frac{1}{3},\ -\frac{1}{2}$$

$$\frac{1}{1.42},\ \frac{1}{1.87},\ \frac{1}{2.5},\ \frac{1}{2.5},\ \frac{1}{3.3},\ \frac{1}{4},\ \frac{1}{4.4},\ \frac{1}{5},\ \frac{1}{5.7},\ \frac{1}{6.66},\ \frac{1}{10},\ \frac{1}{\infty},\ -\frac{1}{20},\ -\frac{1}{7.5},\ -\frac{1}{3.3}$$

For every point lying within the range of distinct vision the eye may be accommodated, and the reciprocal value of the positive or negative position of this point gives the necessary condition of refraction or the absolute value of accommodation. The accommodation or the relative accommodation will naturally be different in different eyes, according to the extent of the state of minimum refraction, and may be expressed by the difference of the latter and of the absolute accommodation.

The following table gives in the first line a row of conditions of minimum

refraction R; in the second and third lines the corresponding relative accommodations $\frac{1}{e}$ for distances D = 20 and D = 10 units of measure.

$$R \ldots\ldots\ldots\ldots -\tfrac{1}{5}, -\tfrac{1}{10}, -\tfrac{1}{20}, -\tfrac{1}{40}, -\tfrac{1}{60}, -\tfrac{1}{80}, +\tfrac{1}{60}, +\tfrac{1}{40}, +\tfrac{1}{20}, +\tfrac{1}{10}, +\tfrac{1}{5}$$

$$\tfrac{1}{e} \text{ for } D = 20 \quad \tfrac{1}{4}\ \tfrac{1}{6.66}\ \tfrac{1}{10}\ \tfrac{1}{13.33}\ \tfrac{1}{15}\ \tfrac{1}{20}\ \tfrac{1}{30}\ \tfrac{1}{40}\ \theta\ \text{“}\ \text{“}$$

$$\tfrac{1}{e} \text{ for } D = 10 \quad \tfrac{1}{3.33}\ \tfrac{1}{5}\ \tfrac{1}{6.66}\ \tfrac{1}{8}\ \tfrac{1}{8.58}\ \tfrac{1}{10}\ \tfrac{1}{12}\ \tfrac{1}{13.33}\ \tfrac{1}{20}\ \theta\ \text{“}$$

It is, moreover, evident, that an equal relative accommodation under otherwise similar conditions will require very different efforts at accommodation according to the extent of the range of accommodation; that therefore not so much the relative accommodation, as such, as rather the amount of accommodation necessary for a certain distance of the object, will determine the measure of the individual act. The amount of accommodation to be employed for a fixed distance of the object is, however, so much the greater, the smaller the condition of minimum refraction of the eye in question is, and the smaller the range of accommodation.

The amount of accommodation q necessary for a fixed absolute accommodation may be expressed by a fraction, the numerator of which is the relative accommodation $\frac{1}{e}$, the denominator the available range of accommodation $\frac{1}{a}$; for there is evidently the proportion $\frac{1}{e} : q = \frac{1}{a} : 1$, hence $q = \frac{a}{e}$.

From this expression it occurs directly, that the amount of accommodation necessary for a fixed absolute accommodation rises and falls in direct proportion to the denominator of the range of accommodation and in inverse proportion to the denominator of the relative accommodation. In behalf of an accommodation for a distance of 10 units of measure, eyes whose range of accommodation is $\frac{1}{3}$ or $\frac{1}{4}$, with a minimum refractive condition of $-\frac{1}{10}$, $\frac{1}{80}$, $\frac{1}{10}$, would be obliged to employ an amount of accommodation of $\frac{5}{8}$, $\frac{5}{10}$, $\frac{5}{80}$, or relatively of $\frac{3}{5}$, $\frac{3}{10}$, $\frac{3}{80}$.

11. The variation in the amount of adjustment of the dioptric apparatus is caused solely by changes of curvature of the lens. (*Cramer, Helmholtz.*) The causes of these changes are, the action of the ciliary muscle, and the great elasticity of the normal crystalline lens, while the capsule is uninjured.

If we consider the limitations of accommodation, which are usually met with in extensive posterior synechiæ of the pupillary margin and after iridectomy, we can hardly deny that the iris assists in the accommodation. This may, perhaps, be inferred from the straining action which the *ligamentum pectinatum*, connected with the ciliary body, exerts upon the anterior portion of the zonula. (*Hensen, Voelckers, Heiberg.*) It certainly, however, can act only to a very inconsiderable extent; for there are cases where the power of accommodation has been preserved after the formation of artificial pupil (*Graefe, Trautvetter*), as well as after traumatic loss of the entire iris (*Graefe*), and in congenital absence of the iris. (*Secondi.*)

The exact manner in which the ciliary muscle causes an increased convexity of the lens, proportioned to the power of its contraction, is still uncertain. The most numerous and important authorities now say that the lens, by a very evident elasticity, possesses the innate power to increase its convexity by a shortening of its diameters; but that it is kept flattened by the zonula, as long as the ciliary muscle remains inactive. As soon, then, as this muscle contracts, the choroid and retina stretch, and the ora serrata approach the equator of the lens. The zonula is relaxed in proportion to the action of the muscle, and hence the lens is enabled to follow the impulse to increase its convexity. (*Helmholtz.*)

The anatomical distribution of the greater portion of the muscular fibers is undoubtedly favorable to this mode of explanation. Besides this, the lens, by partial or complete separation from the zonula, or after death (apparently independent of the swelling), increases the convexity of its surface in a far higher degree than happens in life, even by the maximum action of accommodation. Certain subjective symptoms, which are observed in the dark during the strong contraction of the muscle, and subsequent relaxation of its action (*phosphenes of accommodation, Czermak*) show, in the same way, that in fixing the eye for the near point, there is a stretching of the anterior zone of the retina. Finally, direct experiments on living animals (*Völkers, Hensen*) have supported the correctness of this hypothesis.

There is, however, great difficulty in showing that, during rest of the muscle of accommodation, the lens is indeed flattened by the zonula. The zonula can scarcely do so much by simple elasticity. The rapid disappearance of this physical peculiarity after death, would also be difficult to explain. But contractile elements, of such number and strength as to overcome not only the opposition of the lens, but, by their action, to neutralize that of a muscle as strong as the ciliary, have not yet been found.

Another explanation given is, that the ciliary muscle and the iris press on the border of the lens, and at the same time cause relaxation of the zonula. (*H. Müller, Coccius.*) This hypothesis is supported chiefly by the retraction of the periphery of the iris during the adjustment of the eye for near objects, and by the existence of circular fibers in the ciliary muscle. Direct action of the ciliary processes on the crystalline is, however, impossible, as the two are not in contact. (*Arlt, O. Becker.*)

In the process of accommodation, changes in the shape, and consequently in the relative position, of the ciliary processes and margin of the lens, certainly do occur. But direct observations of the eyes of living albinoes have proved with certainty that these changes depend not so much on the change of accommodation as on the associated change of size of the pupil. The ciliary processes swell, and their heads approach the margin of the lens, when, in distant vision, or from the action of mydriatics, the pupil is dilated. On the other hand, they become smaller, and their anterior bulbous extremities are removed from the border of the lens, when, in accommodation for near objects, or from the action of the preparations of calabar-bean, the pupil contracts. (*O. Becker.*)

The action of the ciliary processes in changes in the state of refraction is, therefore, exactly opposed to this theory. The contradiction is still further strengthened by the fact of the contraction of the pupil not keeping pace with the accommodation for the near-point, but falling perceptibly behind it; the dilatation of the pupil, on the contrary, precedes by a little the accommodation for the far-point. (*Donders, Arlt, Jr.*)

12. The real, and very probably the only nerve of accommodation, is the oculo-motorius. (*Donders, Trautvetter.*) The oculo-pupillary branches of the sympathetic exert scarcely any direct influence upon the accommodative movements; at least, the latter have been found completely free in periodical spastic mydriasis (*Donders*) and in paralytic myosis connected with sympathetic ptosis. The trigeminus invests the iris with the power of sensation and acts upon the internal muscles scarcely in any other way than in a reflex manner, whereby the intra-ocular ganglia and the ciliary ganglion (*Adamük*) are centers. The abducens also, contrary to for-

mer assertions (*Budge, Graefe*), does not take part directly in the accommodation for the near-point.

The nerve of accommodation has probably a separate cranial origin, and only becomes united, at some distance from it, into a common trunk with the motory nerves of the sphincter pupillæ and those of the external muscles of the eye. Without regard to the results of physiological experiments (*Adamük*), this view is corroborated by several cases in which the accommodation alone seemed paralyzed, and others in which the latter was entirely unaffected, while there was complete paralysis of the muscles moving the eye and of the sphincter of the pupil. (*Ruete, Graefe.*)

Still the nerve of accommodation stands in the most intimate functional relations with the remaining branches of the third pair. Efforts at accommodation, as a rule, relieve a contraction of the pupil, and are always connected with the effort for increased convergence. On the contrary, however, increased degrees of convergence of the visual lines, for the purpose of fixation of objects which are situated in the range of distinct vision of the individual, are, as a rule, accompanied by an increase in the state of refraction and by a contraction of the pupil. By forced convergence of the visual lines, the distance of the near-point may even be made considerably less than the amount suitable for the person under examination, and consequently the amount of accommodation necessary for a fixed adaptation somewhat diminished; while voluntary (*Hering*) positions of divergence of the visual lines, or those produced by prisms (*Berlin*), displace the entire range of distinct vision a little forward and increase the amount of accommodation necessary for a fixed adaptation. The position of the visual plane is no less influential. Depressions of the latter are connected with the effort at convergence of the visual lines, and may cause a certain approximation towards the eye of the entire range of distinct vision (*Schirmer*), and as a consequence therefore may also diminish the amount of accommodation necessary for a fixed adaptation. Elevations of the visual plane, on the contrary, remove the entire region of accommodation somewhat from the eye, and render difficult the production and maintenance of the accommodation and convergence necessary for short distances. Lateral directions of the visual lines are without any considerable influence upon convergence and accommodation, when they are very great; in case, however, they deviate very much from the median line, they cause a narrowing of the region of accommodation and convergence in a very perceptible degree. The co-ordination of these muscular actions has, without doubt, an anatomical basis, and is to be referred to the existence of definite centers of co-ordination, which stand in direct connection on the one hand with the origins of the nerves under consideration, on the other hand with the origins of the impulse of the will, with manifold reflex centers, etc. These co-ordinative movements are always innervated from birth as a whole, without it being in the power of the will to cause the individual factors to act separately. Paralyses of separate co-ordinative movements also occur; that is, cases in which one or the other co-ordinative movement with all its components cannot possibly be brought into use, while other co-ordinative movements in which the same nerves and muscles are brought into action, with relatively great expenditures of force, are more easily brought into play. (See relative paralyses.) According to more recent investigations on animals, these centers of co-ordination are to be sought in the *corpora quadrigemina*, and to every individual co-ordinative movement a definite portion of this organ seems to correspond as center. (*Adamük.*)

Still, practice has an extremely important influence, and may change the pro-

portions very much in which the amounts of innervation and expenditures of force of the separate co-ordinated muscles are united for a definite purpose, and it may also adapt them to the necessities of the case. In fact these proportions are very different in different individuals, according to the amount of accommodation and convergence which the adaptation for every separate definite distance demands; it can even essentially vary in the same individual, in conformity with the increase or decrease of the state of minimum refraction and with the range of accommodation, provided that this increase or decrease follows gradually and slowly, and therefore grants time to the muscles to adapt themselves to the necessities of the case.

While a myope, for example, can converge the visual lines from the position of parallelism up to the position of his far-point, which is often very near, without calling into activity his muscle of accommodation; an emmetrope, even with a moderate approximation of the objects, must connect the corresponding convergence of the axes with attempts at accommodation, and many a hypermetrope will associate the maximum of his power of accommodation with the parallel position of his axes.

The connection, however, between the congenital relations, suited by practice to the necessities of the case, in which the amounts of innervation and hence, also, the effective expenditures of force of the muscles of accommodation and convergence co-ordinate, is not very close. Experiments with spherical glasses, as well as with abducting and adducting prisms, teach us that inside certain limits the accommodation of the dioptrical apparatus may vary with equal convergence of the axes, and vice versâ. We speak, therefore, of the range of relative accommodation, and express it by the difference of the maximum and minimum accommodation capable of being brought into play in a certain convergence of the axes. On the other hand we speak of the range of relative convergence, and by it are accustomed to describe the play which is permitted the convergence of the axes in a definite refractive state of the dioptrical apparatus. (*Donders.*) Here, also, the congenital and acquired relations of association are very evident. In general we can say that it is the more difficult to bring the co-ordination into play, and maintain it, the more the relation of the accommodation and convergence which are to be associated together, deviates from that which is firmly fixed by practice.

Fig. 104.

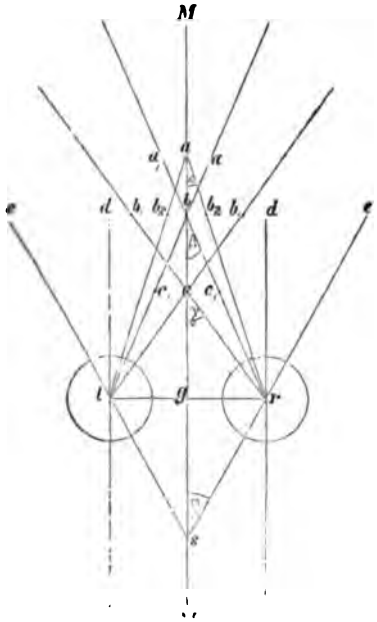

Let l and r be the centers of rotation (Fig. 104) of both eyes, lr the base line and MM the median line perpendicular to it; a, b, c, the points of binocular fixation, and ar, br, cr, the corresponding visual lines with the half angles of convergence α, β, γ. Let the parallelism of the visual lines with the angle of convergence θ be denoted by dr and dl, and by er, el, a position of divergence with the negative angle of convergence δ. The convergence of the visual lines, at the time of observation, may now be expressed by the sine of half the angle

of convergence, and this is equal to half the base line, therefore gr, divided by the distance of the center of rotation from the point of fixation, or, as it is always a question of very small angles, equal to half the base line divided by the positive or negative distance of the point of binocular fixation from the middle g of the base line.

If we now consider half the base line, about 1.25 inches, as the unit of measure, the value of convergence may also be expressed by the reciprocal value of the distance of the object. We would then have to understand by range of convergence, agreeing with the idea of range of accommodation, the difference between the sine of the angle of minimum convergence and of maximum convergence, or the difference of the reciprocal values of the smallest and greatest distance for which binocular fixation is possible. In so far as in reality it is always merely a question of positive distances of the object, and divergence of the visual lines can only be acquired by great practice or produced by prisms; we should regard the infinite distance as the most extreme limit of the range of binocular fixation, and the parallelism of the visual lines or rather the sine of the half angle of convergence θ as the value of minimum convergence. The value of relative convergence for a fixed distance would then consequently be designated by the reciprocal value of the latter, would therefore coincide with the value of absolute convergence in question. In accordance therewith the quota of convergence, which is necessary for a fixed distance, like the expression found for the quotas of accommodation, presents itself as a fraction, the numerator of which is the denominator of the range of convergence, and the denominator of which is the distance of the point of fixation at the time of observation. If for example γ were the greatest half-angle of convergence which could be employed, then the sin. $\gamma = \frac{gr}{gc} = \frac{1}{gc}$ would at the same time be the expression for the entire range of convergence. The quotas of convergence which are necessary for the binocular fixation of the points c, b, a, ∞ and s, would be represented by the expressions $\frac{cg}{cg}$, $\frac{cg}{bg}$, $\frac{cg}{ag}$, $\frac{cg}{\infty}$, $\frac{cg}{-gs}$. We see that the quota of convergence for the minimum distance c is equal to the unit, for parallelism of the visual lines θ and for positions of divergence is *negative*, and therefore smaller than θ; further, that the quota of convergence for a fixed distance is so much the smaller, the greater the latter is and the smaller cg, or the minimum binocular distance of the fixing-point is. Let b be a point in the median line, which is fixed with the corresponding quotas of the range of accommodation and convergence. By placing convex or concave glasses before both eyes the virtual images of the fixed point b are displaced towards a_1 a_1 or relatively towards c_1 c_1, and as they fall in the visual line, are seen singly in the point a or relatively in c. Under such conditions the convergence for the distance b seems to be united with the adaptation of the dioptrical apparatus for the distance a or c. If now a and c were the most extreme limits, inside which the accommodative adaptation with the half-angle of convergence β can vary, then the difference of the reciprocal values of the distance a and c would be the range of relative accommodation in regard to the point b. If instead of spherical glasses, we imagine prisms to be placed before both eyes, which refract the rays coming from the point b in such a manner, as if they came from a or c, or rather from b_2 b_2 or b_1 b_1, and if the corresponding values of convergence were the most extreme which could be brought into use by maintenance of the accommodation for the distance b, then the difference of the sines of α and γ, or, in case half the base line prevails as unit of measure, the difference of the reciprocal values of the distances c and a would be the range of relative convergence, which corresponds to the accommodative adaptation of the eye for the point b.

Nosology.—An *emmetropic* eye is defined to be one whose posterior focal distance is equal to the distance of the anterior surface of the layer of rods from the center of the dioptrical apparatus, its refractive condition placed equal to zero, and thus is considered to be a normal eye. In reality there are but very few eyes which strictly fulfill these conditions; still the difference in the great majority of cases is inconsiderable. Homocentric, parallel bundles of rays under complete relaxation of the muscle of accommodation are united so closely in front of or behind the surface of the retina, that the distinctness of the perceived images does not perceptibly suffer on account of the smallness of the circles of dispersion. Such eyes are consequently reckoned among the emmetropic, and are opposed to the ametropic

nes, in which the posterior focal distance and the distance of the layer of the rods and cones differ so essentially from each other, that distant objects, under complete relaxation of accommodation, can be seen only in indistinct circles of dispersion.

1. In many cases the posterior focus of the dioptric apparatus is relatively too short, since the axis of the eye is too long, or some of its surfaces are too much curved, or since these two causes act together. Hence, such eyes see distant objects in relatively large circles of dispersion. In order to be distinctly seen, the objects must be brought near to the eye; that is, the far point lies near the eye. The extent of distinct vision is shortened, approximated. The eye sees clearly only at short distances; it is *short-sighted*, myopic. The near point depends on the position of the far point, and particularly on the amount of accommodation. If this remains normal, or is but slightly limited, the near point is nearer than normal.

2. In other cases that occur just as frequently, the focus of the dioptric apparatus, during complete relaxation of the muscle of accommodation, lies beyond the bacillar layer of the retina. This depends either on a decrease of convexity or a total loss of certain surfaces, or on abnormal shortness of the optic axis, or on the two causes combined. When the accommodation is completely relaxed, such eyes see both far and near objects in circles of dispersion; the rays of light must fall *convergently* on the cornea, in order to be united to distinct images on the bacillar layer. In such cases, the dioptric apparatus is only adjusted for virtual images that lie behind the retina. The eye is over-sighted (*hyperpresbyopic*, *hypermetropic*, *hyperopic*).

If the posterior focus of the dioptric apparatus is only slightly beyond the retina, and if the power of adjustment is normal, not only will this difference be readily equalized, but the focal distance may be diminished to a certain amount shorter than the retinal distance; the eye possesses the power of accommodation for parallel, or even for divergent rays, and for objects at a positive distance, which may even be very short; the far point lies behind, the near point in front of the retina; on the prolonged optic axis, the line of distinct vision is *interrupted*. The distance of the near point is greater than normal, for a certain amount of the serviceable power of accommodation is required to adjust for parallel rays (*facultative hypermetropia*).

If the posterior focus of the dioptric apparatus lies *considerably* behind the retina, the maximum of the serviceable power will not suffice to adjust the eye for parallel rays, that is, for positive distances; both far and near points lie behind the retina. The whole line of distinct vision is negative, the eye is *absolutely hypermetropic*.

These relations may perhaps be made more clear and distinct in another way.

Let C E be the axis of a schematic emmetropic eye. Let ϕ be its state of refraction, the angle of incidence γ of the ray ym of homocentric light parallel to the axis AA being assumed equal to zero, and therefore $sin.\ \gamma=\phi$. If now we consider the general law of refraction: $sin.\ \alpha=n.\ sin.\ \beta$ (p. 764), we find that the state of refraction $N=n.\ sin.\ \beta$ is determined by two factors, n and $sin.\ \beta$, each of which may vary inside certain limits independently of the other. If now we regard the n of the main equation as constant, then every prolongation of CF, even the most trifling, will naturally bring with it an increase of the $sin.\ \beta$ and therefore require a proportionate growth of the $sin.\ \alpha$, the state of refraction of the eye will increase as a whole, parallel rays ym with the $sin.\ \gamma=\phi$ will no longer unite upon the retina, but rather divergent rays zm with the $sin.\ (\gamma+\mu)$: the eye has become myopic and its state of refraction finds expression in the sine of the positive differential angle $\mu=0$.

If on the contrary the axis of the globe was shortened to CH, then the $sin.\ \beta$ of the main equation would be diminished to a corresponding degree; parallel rays ym with the angle of

incidence γ would no longer unite upon the retina, but rather convergent rays with a smaller angle of incidence $\gamma - v$, the state of refraction of the eye $N = n.\ sin.\ \beta$ would seem diminished and therefore smaller than ϕ, equal to the sine of the angle of incidence $(\gamma - v)$, and as the $sin.\ \gamma = \phi$, the sine of the differential angle $-v$ would be the expression for the existing degree of hypermetropia.

Fig. 105.

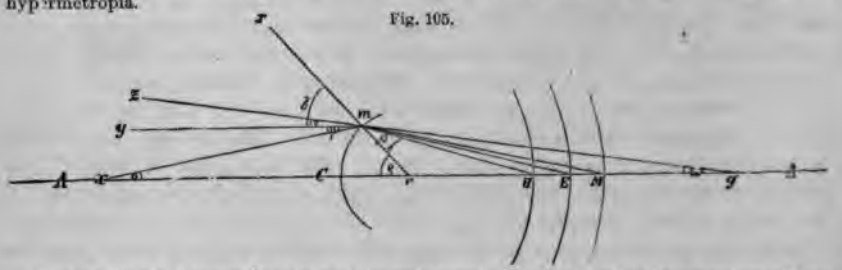

Just as the $sin.\ \beta$ so can also the n of the main equation vary, either by the curvature of one or more separating surfaces deviating from the normal, or by the opposite distances varying, or by the refractive relation of some of the internal media becoming different. If the value n rises, an increase plainly results; if on the contrary it falls, there results a diminution of the state of refraction $N = n.\ sin.\ \beta$, in other words, parallel rays with the $sin.\ \gamma = \phi$ no longer unite, but rather divergent rays zm with the angle of incidence $(\gamma + \mu)$ or convergent rays zm with the angle of incidence $(\gamma - v)$. The emmetropic eye has become short-sighted or relatively hypermetropic, and the degree of the ametropia finds its designation in the sine of the differential angle, and is therefore $sin.\ \mu$ or relatively $-sin.\ v$.

If in a hypermetropic eye with the axis of the globe CH the n of the main equation is increased by a certain amount, while $sin.\ \beta$ remains constant, or if the reverse occurred, or if both factors rose in value, then the angle of incidence $(\gamma - v)$ would evidently be forced to rise corresponding to the increase of the state of refraction $N = n.\ sin.\ \beta$, in order to do justice to the main equation. Rays would then unite upon the retina, whose angle of incidence approaches the assumed normal $\gamma = \phi$, reaches its value or even surpasses it. The state of refraction would come near to or equal ϕ, or would be even positive, the hypermetropic eye would be less hypermetropic, emmetropic or even myopic.

If the $sin.\ \beta$ or n, or both factors at the same time increased in a myopic eye with the axis of the globe CM, then the differential angle μ must also necessarily increase; while the sinking of one or both factors would bring with it a diminution of μ. In the first case an increase of the state of refraction N would occur, and therefore of the degree of myopia also; in the second case the result would be a decrease of the myopia and according to circumstances a change into emmetropia or hypermetropia. One factor may however increase in an eye, while the other decreases. It then very naturally depends upon the opposing relations, in which n and $sin.\ \beta$ change, whether the state of refraction remains as before, or whether it becomes larger or smaller.

Emmetropia, myopia and hypermetropia cannot well hold good as essentially different conditions of the eye, as in one and the same case they pass directly into one another. The very manifold conditions of refraction occurring in practice must rather be regarded as members of a single, infinitely long series, which begins with the positive unit, passes through the normal and gradually descends to the negative unit.

If we cause the separate members to fall by a fixed difference, we obtain a logarithmical series, the application of which exceedingly facilitates the solution of certain important problems in practice, particularly the correction suitable for occasional necessity. If, namely, in a dioptric system the distance of the separate dividing surfaces is neglected, their refractive values are summed up. An eye armed with a positive or negative glass has therefore a refractive condition $N \pm F$, and an eye armed with two glasses a refractive condition $N \pm F \pm P$, where F and P signify the refractive values or the reciprocal values of the focal distance of the glasses employed. Therefore every positive or negative refractive condition deviating from the normal is corrected to emmetropia or the normal by the addition of a spherical glass, whose refractive value F is equal to the refractive condition given according to the value, but bears the opposite sign $\pm$.

The proposal has recently really been made by many to establish by agreement such a logarithmic series with fixed intervals for general use in the designation of various degrees of ametropia, and to construct a scale for the refractive value of the correcting glasses exactly corresponding to it, a scale, therefore, in which the refractive values of the collected numbers are the multiples of a fixed number m, and the reciprocal value of m represents the interval between two numbers following each other. If we took $m=100$, the series would appear

$$\underbrace{100, 99, 98, \ldots 50 \ldots 3, 2, 1, \phi, -1, -2, -3, \ldots\ldots -50 \ldots\ldots -98, -99, -100}_{100}$$

Such a scale differs very favorably from that which was hitherto employed in the designation of the refractive values of the glasses, and consequently of the refractive conditions also. In this the intervals are everywhere unlike, in the weaker glasses very small, in the strong ones disproportionately great. Thus the interval for focal distances of 40″ and 36″ is equal to 1 : 360, for 22″ and 20″ equal to 1 : 220, for 13″ and 12″ equal to 1 : 156, for 6″ and 5″ equal to 1 : 30, etc.

It is unfortunately very difficult to come to an understanding concerning these fundamental sizes. There have been proposed one after the other 24 (*Donders*), 60 and 120 (*Burow*), 48 and relatively 96 (*Zehender*), and finally 216 (*Girard-Teulon*). But the supposition of the last value would render 432 numbers of glasses necessary, namely 216 for convex glasses and just as many for concave glasses. If however m is chosen smaller, *e.g.* 96, then a series of weak glasses are excluded, which can by no means be dispensed with in practice, especially when it is a question of correcting slight degrees of hypermetropia. The focal distances would then be 96, 48, 32, 24, 19$\frac{1}{5}$, 16, 13$\frac{5}{7}$, etc. But cases of hypermetropia occur every day, where focal distances of 36, 30, 28, 26, 22 inches are necessary, and of myopia, where focal distances of 22, 20, 18, 17, 15 inches, etc., are necessary, and cannot be sufficiently compensated by glasses of the series previously mentioned. The advantage which a greater assortment in the high numbers offers, is on the other hand very slight, since high degrees of myopia and hypermetropia can be but seldom entirely corrected. They are frequently accompanied by a considerable decrease in the acuity of vision. Furthermore in sharply defining glasses, the unavoidable, relatively considerable distance of the glass from the optical centre of the eye is of very great importance, and usually makes a merely partial neutralization of the defect of refraction more advantageous. Where however we can disregard this latter factor, especially in strong convex glasses, which cause an enlargement of the retinal image by their distance from the eye: here slight differences in the refractive values of the glasses may be very easily compensated by very slight changes in the distance of the glass. In addition it happens that the methods of examination applicable in practice are not sufficiently exact to ascertain surely very small differences in the refractive condition of the eye, and this would be necessary, in order that such logarithmic series could be turned to practical account throughout its entire extent. Without regard to the difficulties in the measurement of small fractions of an inch, the influence of varying degrees of illumination and of varying widths of the pupil, the ability to read in circles of diffusion, capable of being increased by practice, etc., stand very much in the way of obtaining such exact results. The grinding of glasses, however, whose refractive values are expressed by very complicated fractions, is very difficult, and very many such glasses are found in every logarithmic series.

By reduction of the values to metrical measurement (*Javal. Nagel*), the international arrangement is of course very much facilitated, and the time is not far off when the unit of measure will no longer be the inch varying in different countries, but the centimetre. In the computation of a logarithmic series the same inapproachabilities are however just as prevalent as in the establishment of the inch-measure.

On the whole we shall best answer all demands in the construction of a scale of glasses by choosing the intervals merely of the weaker numbers very small, as has hitherto been the custom, but causing them to gradually increase, the sharper the glasses become. In fact in practice a series of glasses entirely suffices, whose focal distances, as well for positive as negative glasses, differ by 4″ from 48″ to 32″, by 2″ from 32″ to 20″, by 1″ from 20″ to 10″, by ½″ from 10″ to 4″, and from here on by ¼″.

Moreover we often have occasion to cause glasses to be cut of a definite refractive value which is not contained in the scale of glasses of the optician, or to combine this refractive value with prisms, or to concentrate upon a single surface of the glass, in order to add to the other surface a colored plane glass, or to give it a cylindrical curvature for the purpose of correcting astigmatic differences.

If p is the desired focal distance, and therefore $\frac{1}{p}$ the refractive value, $n=1.5$ the exponent of refraction of the glass employed, further if f and g are the radii of the surfaces of curvature of a biconvex or biconcave lens, we would then have the formula:

$$\pm\frac{1}{p}=(n-1)\left(\pm\frac{1}{f}\pm\frac{1}{g}\right);\text{ and when } f=g,\text{ so is } \pm\frac{1}{p}\ \pm\frac{0.5}{f}\pm\frac{0.5}{g}\ \frac{1}{f}=\frac{1}{g};$$

that is, in the biconvex or biconcave lens the desired focal length gives the radius of curvature of both surfaces. If the desired refractive value upon a single surface of the glass were to be obtained, then the formula would run

$$\pm\frac{1}{p}=\pm\frac{0.5}{f}=\pm\frac{1}{2f}\text{ and } p=2f.$$

i.e., the demanded focal length gives the diameter of curvature. If a biconcave lens of 10″ focal length were to be ground upon a prism, a concavity of 10″ radius must be given to both surfaces of the latter. If, however, a spherical concavity of 10″ focal length should be given to one surface, and a cylindrical concavity of 10″ focal length to the other, the diameter of curvature of both surfaces must be 10″, and therefore the radius must be 5″.

The state of refraction may moreover change in the same individual within a short time. Without regard to the possible lengthening of the axis of the eye by the development of a staphyloma posticum, it is to be considered that the lens is by no means an absolutely elastic structure, which immediately springs back into its former shape, when the ciliary muscle is completely relaxed. By long-continued powerful efforts at accommodation the refraction is often considerably increased for hours and even for days, since the lens only flattens out again gradually. On the contrary we find in eyes, which are usually subject to powerful and continued efforts at accommodation, after several days or even weeks of continued rest of accommodation, very frequently a perceptible diminution of the former refraction. Paralysis of the ciliary muscle produces also the same effect, and even in a heightened degree, whether it be the consequence of diseased processes or of the local action of powerful mydriatics. To this attention has been already directed for a long time, and hence we insist upon the strict differentiation of the natural from the actual, most extreme situation of the far-point.

It is clear that this difference cannot easily occur in highly myopic individuals, who use their range of accommodation but little or not at all, but usually place the objects of their ordinary occupation in the position of the far-point. On the contrary the difference is often very great in hypermetropes, who employ a greater quota of accommodation not only for seeing in the near, but also for seeing in the distance, and must therefore maintain the ciliary muscle continually in a condition of great tension during their waking hours. Such persons, according to authenticated cases (*Dobrowolsky*), not uncommonly even become apparently myopic. Long-continued rest of accommodation as well as morbid or artificial paralysis of the ciliary muscle cause the state of refraction again to sink a little, and the eye may again become hypermetropic.

There is no doubt that the same causes may, under suitable conditions, produce a permanent increase of the refraction, and in so far play a not entirely unimportant part in the acquisition of shortsightedness. With long-continued efforts at accommodation the lens and the muscle finally grow into the shape forced upon them.

In fact increase of convexity of the lens has for years been demonstrated with certainty as the cause of permanent myopia (*Cramer*). Recently it has been found that the ciliary muscle also, which under normal relations appears in vertical sections like a right-angled triangle (Fig. 2, o, l,), changes considerably its form and structure in hypermetropic and highly myopic eyes. In the hypermetropic eye that portion of the circular fibres, which forms the internal and anterior surface of the belly of the muscle, is enormously enlarged, but the longitudinal fibrous portion is perceptibly thinner. The chief mass of the muscle, therefore, seems to be pulled forwards and inwards, and the short kathete of the triangle appears bulged forward in

a very convex arch towards the equator of the lens, while the posterior portion of the muscle appears much thinner. In the highly myopic eye, on the contrary, the circular fibres are almost entirely wanting at the internal and anterior surface of the belly of the muscle; the bundles running longitudinally, however, have increased in number and thickness. The inner anterior surface of the muscle, therefore, appears inclined very obliquely backwards, the inner posterior angle of the belly has receded very much and is obtuse, so that the greatest thickness of the muscle falls very far backward. It is clear that these changes cannot remain without influence upon the accommodation. Even superficial observation shows that the resulting action of the course of the muscle in hypermetropic eyes is almost perpendicular to the optical axis, and consequently has a direction very favorable to the relaxation of the zonula; in highly myopic eyes, however, it runs more from before backwards along the internal surface of the sclera (*Iwanoff*).

3. Not uncommonly there exists a relatively great difference between the refraction of various meridional planes of the dioptrical apparatus, on account of an unusually great asymmetrical formation of the refracting surfaces. If then the rays refracted in one meridian cast distinct images upon the layer of rods of the retina, the rays running in the other meridional planes unite so far in front of or behind the bacillar layer that they meet this in the form of circles of dispersion, and consequently render the whole impression very indistinct. In case, however, the middle focal length or focal distance fell in the layer of rods, the concentration of the rays there is still much too slight, the circular section of the separate homocentric rays is much too extensive, for a sufficient distinctness of the retinal image to be obtained. Such eyes lack therefore a distinct range of vision. They perceive objects at a given distance merely in circles of dispersion, they indeed see better at certain distances than at others, but in none distinctly. Such eyes we call astigmatic, and we describe the condition as abnormal, regular astigmatism, or simply as astigmatism. It only differs in degree from the normal astigmatism, which attends almost every eye.

If we imagine a regularly astigmatic eye covered by a diaphragm with two very fine slits crossed at a right angle, each of which coincide exactly with the meridian of greatest and least curvature, the astigmatic appears analyzed into two spherical, schematic eyes, each covered entirely with exception of the slit (Fig. 97). The length of the globe, and therefore also $\sin. \beta$ of the main equation $\sin. \alpha = n. \sin. \beta$ is common to both, but the n is different and hence the $\sin. \alpha$ also, which is necessary to bring the rays to a union upon the retina. The sine of the differential angle, or the reciprocal value of the positive or negative distance, from which the rays must diverge, in order to come together at the retina, now gives the state of refraction of the one and of the other schematic eye, and therefore the state of refraction of both chief meridians of the astigmatic eye also. The difference between the two is what is called the astigmatic difference. The state of refraction of every other intervening meridian is equal to that of the meridian of least curvature plus the product from the astigmatic difference, and from the sine of the angle which the meridian in question encloses with the meridian of least curvature. This product in the meridian of least curvature is ϕ, and in that of the greatest curvature is equal to the entire astigmatic difference.

Not uncommonly we meet in practice with a high degree of irregular astigmatism, in which the refraction not only of the separate meridians, but of various parts of one and the same meridian is a different one, and increases and decreases without any regularity. This error of refraction has its origin sometimes in the cornea, sometimes in the lens, sometimes in both at the same time (*Knapp*, *Donders*).

In regard to the cornea, we must especially consider: opacities and any superficial unevenness; circumscribed facets as consequences of preceding ulcers; keratectasia with keratoconus; curvatures of otherwise unchanged portions of cornea, as are found with penetrating, extensive, shrinking corneal cicatrices, with partial, cicatricial corneal staphylomata, and with partial ectatic cicatrices, as also after flap extraction in consequence of incorrect healing of the flap or subsequent stretch

ing of the scar. The lens becomes a cause of abnormal, irregular astigmatism on account of change in volume with partially retrogressive cataracts; on account of dislocation (*Dufour*), ectopia and spontaneous luxation, and sometimes perhaps also on account of not entirely homogeneous density of its structure, especially in commencing cataracts (*Knapp*). The result of these deviations is often a complete confusion of the retinal impressions, so that even larger objects are perceived only in very indistinct, distorted shadowy outlines, and we might easily suspect an amblyopia, if the power of distinguishing colors were not perfect. This condition is found particularly in extensive opacities and in considerable roughness of the centre of the cornea, in great curvatures of transparent portions of the cornea on account of shrinking or ectatic cicatrices, and especially in keratoconus.

In other cases the abnormal astigmatism manifests itself by very great distortion of the retinal images, and their form varies according to the position of the objects to the eye, and therefore according as the axis-rays in question pass through this or that part of the dioptrical apparatus. Usually all the parts of the image are not equally indistinct, since the focal surfaces of the individual portions of the dioptrical apparatus with the retina enclose very different angles. Under certain conditions the circles of dispersion which meet the retina form separate images, monocular diplopia, triplopia (*Dufour*), or polyopia, and the separate images are crossed or not, according as the refraction of the places in question is increased or diminished (*Knapp*). Generally the same changes are also perceptible in the ophthalmoscopic image of the fundus of the eye, at the entrance of the optic nerve, the retinal vessels appear distorted, vary their shape according to the position of the mirror, and appear also double and multiplied (*Graefe*, *Knapp*). If the cornea is the cause, the irregular astigmatism also appears in the reflections from its surface.

In circumscribed facets and opacities of the cornea the metamorphosia is also observed with similar appearances as in the exudative neuroretinitis, and in detachment of the retina. Straight lines, as far as they lie in definite portions of the field of vision, appear bent, curved lines appear sinuous, etc. (*Knapp*).

4. Besides the above-mentioned anomalies of refraction, we often see *limitations* of the range of accommodation. They exist in normal adjustment of the dioptric apparatus, as well as in company with myopia, hypermetropia, and astigmatism, and they alter the length and position of the distance of distinct vision, in various degrees, according to the form of the fundamental disease.

This is frequently a *mechanical* hindrance to the muscular action, or a disease of the muscle of accommodation and its nerves, a true paresis of accommodation. The distance of distinct vision then appears lessened by the increased distance of the near point; the far point is not removed at first.

True spasms of accommodation cause disease in some rare cases. Then during the spasm, the dioptric apparatus appears adjusted for the near point, or even a shorter distance; the far point is brought almost to the near point, or else both of them are brought within the previous limits of clear vision.

By far the most common cause of limitation of accommodation is the change which the lens and muscle of accommodation undergo with increasing age. For while, on the one hand, the lens constantly becomes denser and offers increasing opposition to the accommodative change of shape, on the other hand, in advanced age, the power with which the muscle acts on the lens diminishes; hence the maximum of serviceable accommodative action must necessarily be reduced. But since, with increasing density, the layers of the lens become homogeneous, and the lens itself

flattens, the refractive power suffers, and consequently the refraction of the whole dioptric apparatus, during the rest of the accommodation, is lessened; and not only the near point, but the far point, and consequently the entire distance of distinct vision, is removed from the eye.

These changes are entirely physiological, and are necessary consequences of senile involution; sooner or later, and more or less distinctly, they become evident in every eye.

The senile limitation of the accommodation is most marked in eyes which previously, at a distance and near at hand, saw well enough for ordinary occupations, and hence were considered emmetropic, although they were frequently slightly hypermetropic from youth. For these eyes now require glasses, while manifestly hypermetropic and myopic persons have been long accustomed to glasses, and with the former a shortening of the focal distance, with the latter a slight removal of the object, answers the purpose.

It was this circumstance that caused the senile diminution of accommodation, in eyes considered as emmetropic, to be regarded as a peculiar anomaly, and to be described as presbyopia or far-sightedness. We must here bear in mind that senile increase of density of the lens is not conceivable without a decrease of the refraction of the whole eye. Only eyes that were previously slightly short-sighted can become presbyopic in the strict sense of the word, that is, have an infinite far point, and even then the condition is only temporary. In old age, emmetropic eyes necessarily become hypermetropic, and the error of refraction in hypermetropic eyes increases. In eyes formerly emmetropic, the hypermetropia is not always manifest till the muscle of accommodation has been paralysed by atropia, so that the adjustment for *negative* distances may be seen. The error of refraction increases with advancing senile involution of the lens. What was formerly apparently a simple limitation of adaptation, has united with manifest hypermetropia. The presbyopia has become a *hyperpresbyopia*, with diminished range of accommodation.

Hence it seems advisable to cease to regard presbyopia as an *independent* affection of accommodation, and to consider the changes caused by senile involution in the length and position of the distance of clear vision in the sections on myopia and hypermetropia. [Donders on Acc. and Refrac. of the Eye, New Sydenham Soc. translation, p. 204, et seq.]

5. Not unfrequently functional disturbances originate in the muscles of accommodation, or in the internal recti (which cause the crossing of the visual axes) from the impossibility of long maintaining the correct adjustment or convergence of the axes, for short distances. When a considerable exercise of strength is required of them, the muscles easily tire; continued work causes a feeling of fatigue, or even of severe pain, and symptoms of congestion appear, which render impossible further employment of the eyes, and finally cause very painful hyperæsthesia of the retina and ciliary nerves. The extent of the power of accommodation (i. e. the possibility of equalizing differences of the posterior distance of convergence, by increasing the convexity of the lens) is not necessarily, but is very frequently, diminished. This condition of weakness of the muscles is called asthenopia, *kopiopia*, *hebetudo visus*, &c.

6. Micropsia and megalopsia (diminished and magnified vision) are intimately connected with the functional disorders of the muscles concerned in binocular vision. The judgment as to the size of an object, depends not only on the size of the retinal image, or of the visual angle, but very much on its estimated distance, which again

depends on the amount of contraction required of the muscle of accommodation and internal recti for the sharp and distinct perception of objects. (*Panum.*)

Of two objects, that one appears the smaller, whose real or apparent distance requires the greater contraction of the above-named muscles, the visual angle being the same. Hence concave glasses cause objects to appear smaller, while convex glasses, which induce relaxation of the muscle of accommodation, make them appear larger, and even magnify them much more than is explained by the refractive power of the glass, and its necessary distance from the eye. In binocular vision abducent and adducent prisms also impair the judgment as to the size. (*Graefe.*) Since morbid weakness of the muscle of accommodation and of the internal recti increases the necessary tension, and therefore renders requisite stronger nervous impulse, it also becomes a source of micropsia, especially when it occurs rapidly, and the patient has not learned, by experience, to correct his faulty judgment of the size of objects.

Indeed, micropsia not unfrequently accompanies insufficiency of the muscles in question, as is seen in asthenopia. But it occurs particularly in paresis of the muscle of accommodation, whether this exists alone or is accompanied by mydriasis (*Graefe*), or even with paralysis of all the parts supplied by the oculo-motor nerve. In the same way artificial weakness of the muscle of accommodation, such as is caused by weak solutions of atropine, are often accompanied by micropsia; and experiments undertaken under such circumstances to prove the above theory, have shown that the micropsia as well as the influence on the accommodation occur later than the paralysis of the sphincter; that it only occurs on examining objects which lie in the vicinity of the near point that is attained by the greatest exercise of accommodation; also that the diminution increases with increasing impulse of accommodation, but lessens as the latter decreases, and hence is removed by convex glasses. (*Förster*, *Donders.*)

7. Finally, *mydriasis* and *myosis* should be considered on account of their natural association with disease of accommodation. By the former term is meant a dilatation, by the latter a contraction, of the pupil, if they depend on paralysis or spasm of the muscle moving the iris.

Micropsia also often occurs in recurrent central retinitis, and in the circumscribed form of exudative neuro-retinitis. This is not completely explained. It is believed that it can be referred to the absence of a certain number of the rods and cones (*Graefe*).

Authorities.—*Preliminary Remarks: Helmholtz*, A. f. O. 1. 2. S. 45. et seq.—*Karsten*, Encyclopædia IX. S. 11. et seq.—*Knapp*, Verhandlungen der Heidelberger oph. Versammlung, 1857. S. 19, Die Krümmung der Hornhaut, &c. Heidelberg. 1860. S. 16. et seq. A. f. O. VI. 1. S. 1. et seq. VII. 2. S. 136, VIII. 2. S. 185. et seq.—*Donders*, A. f. O. IV. 1. S. 301, 303, VI. 1. S. 84. VII. 1. S. 176. et seq. IX. 1. S. 103, IX. 2. S. 219, 220; Astigmatism and Cylin. glasses. Berlin. 1862. P. 10, 16, 27, 30; klin. Monatbl. 1863. S. 496; Vierde Jaarl. Verslag. Utrecht. 1863. S. 99, 105; die Anomalien der Acc. u. Refrac. Wien. 1866. S. 7. et seq.—*Middleburg*, Vierde Jaarl. Verslag Utrecht. 1863. S. 148. et seq.; klin. Monatbl. 1864. S. 245. A. f. O. X. 2. S. 83. et seq.—*Mandelstamm*, A. f. O. XI. 2. S. 259, 264.—*Schuerman*, klin. Monatbl. 1864. S. 92.—*Rosow*, A. f. O. XI. 2. S. 129, 135. —*W. Krause*, die Brechungsindices, &c. Hannover, 1855.—*Senff*, nach Donders, Anomalien, &c. S. 34, 155.—*Kaiser*, A. f. O. XI. 3. S. 186.—*Young*, *Airy*, nach Donders l. c. S. 10, 34, 35, and Mackenzie, Traité, &c. II. P. 651; Karsten's Encyclopædia. IX. S. 141.—*H. Meyer*, Zeitschrift für rat. med. V. S. 369.—*Fick*, Med. Physik, Braunschweig. 1856, S. 327; A. f. O. II. 2. S. 79.—*Pagenstecher*, A. f. O. IX. 1. S. 41, 43.—*Brücke*, Archiv. f. Anat. u. Phys. 1844. S. 444, 1845. S. 337.—*Listing*, Handwörterbuch der Phys. von R. Wagner. IV. S. 451-504.—*Aubert* und *Förster*, A. f. O. III. 2. S. 1. et seq.—*Volkmann*, Physiolog. Untersuchungen, &c. 1. Leipzig. 1863. S. 65. et seq.—*Hansen*,

rchiv. 34. Bd. S. 401; kl. Monatbl. 1866. S. 197.—*M. Schultz*, Zur Anat. und Phys. Bonn. 1866. S. 49-62.—*H. Müller*, Wurzb. naturw. Zeitschrift II. S. 219. A. f. O. III. - *Welker*, Zeitschrift für rat. med. XX. S. 173, 176.—*Bergmann*, ibid. 22 Bd. S. 145; 1865. S. 189.—*Snellen*, Probebuchstaben. &c. Utrecht. 1862. S. 1-6.—*Vroesom de*, Jaarl Verslag. Utrecht. 1862. S. 229, 240, 278; kl. Monatbl. 1863. S. 327.—*Vierordt*, . S. 161, IX. 3. S. 219.—*Girard Teulon*, Congress, intern. d'ophth Paris. 1863. P. *rmak*, A. f. O. VII. 1. S. 147, Sitzgsber. der Wiener Akad. der Wissenschaft. XV. *wag*, ibid. XVI. S. 200; Ophth. II. S. 335, 508.—*Graefe*, A f. O. II. 1. S. 187. et seq. et seq. III. 2. S. 363, 434; VII. 2. S. 150. et seq.—*Cramer*, Het accommodatie verlem, 1858. S. 24. et seq.—*Secondi*, Clinica oc. di. Genova, Torino. 1865. P. 27.—*en*, Centralbl. f. med. Wiss. 1866, Nr. 46.—*Arlt*, A. f. O. III. 2. S. 111-120.—*Mann*-V. 1. S. 269, 280-285.—*Henke*, ibid. VI. 2. S. 52, 69.—*Förster*, kl. Monatbl. 1864. S. *ken*, Ontleedkundig, Onderzook, &c. Utrecht. 1855. S. 7. 46.—*Klebs*, Virchow's d. S. 175.—*Grümhagen*, ibid. 30 Bd. S. 481.—*Witter*, A. f. O. IX. 1. S. 207.—*Ed.* ellungen des diopt. Apparates Wien. 1861. S. 9. et seq.—*Leber*, Denkschr. der kad. der Wiss.; 24 Bd. S. 312. A. f. O. XI. 1. S 26.—*O. Becker*, Wien. med. Jahrb. et seq. 1864. S. 3, 10, 20.—*Trautvetter*, A. f. O. XII. 1. S. 96. et seq.—*Budye, Waller*, . Donders, Anomalien, &c. S. 488, 489.—*Ruete*, Lehrb. d. Ophth. Braunschweig. 1.—*Panum*, A. f. O. v. 1. S. 1. 35.—*Donders*, Centralblatt. 1866. S. 366; Het taan, etc. Utrecht. 1869. S. 137.—*Snellen*, A. f. O. XV. 2. S. 199, 204.—*Reuss*, hth. Studien. Wien. 1869. S. 10-15, 37, 51, 55.—*Woinow*, A. f. O. XV. 2. S. 144, 155, . Monatbl. 1869. S. 476, 482.—*Dobrowolsky*, A. f. O. XIV. 3. S. 51, 91.—*Arlt*, jun. S. 302.—*Schirmer*, kl. Monatbl. 1869. S. 405.—*Mauthner*, ibid. S. 481—*Berlin*, *Zehender*, ibid. 1868. S. 55.—*Heiberg*, ibid. 1870. S. 80.—*Adamük*, Centralbl. 1870. *hel*, Arch. f. Psychiatrie, I. S. 423.—*Möser*, Perimeter. Breslau, 1869. S. 10.—*Sussdorf*, Sitzungsber. d. Dresden. Gesellschft. f. Natur- u. Heilkde, 1867. S. 42. ansact. Amer. Ophth. Soc. 1869. S. 31.—*Burchhardt*, internationale Sehproben. . *Hering*, Lehre vom binoc. Sehen, Leipzig. 1868. S. 141.—*Coccius*, Der Mechan. eipzig. 1868. S. 15, 30, 41, 48.—*Schumann*, Ueber den Mechan. d. Accom. Dresden. imental Untersuchungen, etc. Leipzig. 1869.—*Dufour*, kl. Monatbl. 1870. S. 46. : *Knapp*, klin. Monatbl. 1864, S. 304. et seq.—*Donders*, A. f. O. IV. 1. S. 337, VI. 1. . 2. S. 210, VII. 1. S. 176-202, Anomalien, &c. S. 69. et seq.—*Stellwag*, Sitzgsber, k. Akad. der Wiss. XVI. 1855. S. 201, 232, 250; Ophth. II. S. 336, 360.—*Förster*, äge. Berlin. 1862. S. 69. et seq.—*Graefe*, A. f. O. 1. I. S. 341. VIII. 2. S. 360. IX. 3. S. *an*, kl. Monatbl. 1863. S. 369.—*Nagel*, kl. Monatbl. 1868. S. 65; Congrès ophth. —*Javal*, ibid. S. 142; A. f. O. XII. 2. S. 308.—*Hasner*, Prag. Vierteljahrschrift. ial. S. 86.—*Iwanoff*, A. f. O. XV. 3. S. 284, 286, 289.—*Burow*, Ueber die Reihenillenbrennweiten. Berlin, 1864; A. f. O. XII. 2. S. 308; kl. Monatbl. 1866. S. 203; —*Giraud Teulon*, ibid. 1864. S. 316.—*Zehender*, ibid. 1866. S. 1.—*Dobrowolsky*, Beil. S. 3, 9, 39, 87, 141.—*Cramer*, Het accommodatievermogen, etc. Haarlem. 1853. *amük*, Centralbl. 1870. S. 173.

Short-sightedness. Myopia.

Symptoms.—The disease is characterized by an increase of the normal refraction, that is to say, by the diminution of the distance of the far-point, and the consequent inability of the eye to perceive distant objects distinctly without the aid of dispersing or concave lenses.

1. The distance of the far-point may vary in all positive and finite amounts. Practically, however, we should only consider those cases as myopic, where it is less than five feet. According to the distance of the far-point, there are various grades of myopia. We may consider the myopia of a *low* grade when the far-point is beyond fourteen inches, *medium* between fourteen and six inches, and of a *high* grade when it is less than six inches. It is rarely less than two inches, unless there is some complication.

To determine the distance of the far-point *approximately*, as is generally sufficient in practice, we may measure the greatest distance at which the affected eye can read medium or small type, or distinguish objects of that size. The number of inches thus found gives the distance of the far-point. We have here only to take the precaution to choose for every distance that type which is seen from it under a visual angle of 5 minutes.

If the visual angle is smaller, sufficient details of the separate letters can no longer be perceived, in spite of a correct adaptation of the dioptrical apparatus. If, however, the visual angle is larger, moderate circles of dispersion by no means hinder the recognition of the type, particularly if the individual who is to be examined is very practised in reading.

Optometers (*Ruete*, *Hasner*, *Burow*, *Verschoor*) generally give unreliable results. This is particularly true of the tubular ones; for it is difficult to cause the patient fully to relax his muscle of accommodation during the examination. Hence, if we wish to obtain accurate results, we must use atropine, which is inconvenient. To avoid this, binocular optometers (on the plan of the opera-glass) have been made. These are said to compel a parallelism of the axes of vision, and hence, to attain perfect relaxation of the ciliary muscle. (*Graefe*). This may be sufficient in myopic and emmetropic patients, but in hypermetropes, relaxation of the muscle of accommodation does not necessarily accompany parallelism of the visual axes; hence the results are not exact.

Fig. 106.

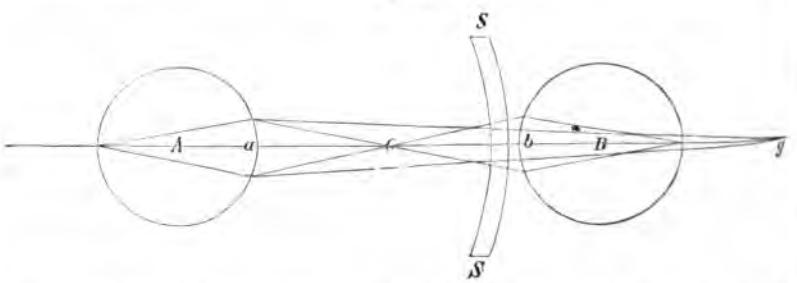

Moreover, the ophthalmoscope can be employed to determine the existing accommodation of the dioptrical apparatus, and therefore the distance of the far-point of one eye (*Helmholtz*). This latter presupposes that the eye examined is looking in the distance, and that the examiner

knows exactly the distance, for which he now adapts his eye for making the ophthalmoscopic examination, which, of course, requires great practice, and is therefore not the business of every one, and moreover does not exclude variations in the values obtained, even with the greatest skill (*Woinow*). Let $a\,o$ (Fig. 106) be the accommodation of the examined eye A, and let $b\,o$ be that of the eye B to be examined, armed with a simple illuminating mirror $S\,S$, whereby the distance of the mirror from b is made equal to zero, in order not to complicate the relations. The eye B, placed at the distance $a\,b = ao + bo$ will then evidently obtain a distinct image of the fundus of the eye A. The distance, $a\,b$, of mirrors applicable in practice cannot be much increased beyond 12 inches, without the illumination of the fundus of the eye A becoming insufficient, and the visual field of the eye B excessively contracted. In order that a simple illuminating mirror $S\,S$ may produce a distinct image of the fundus of the eye A, $a\,o$ and bo must therefore be very small, and A therefore be myopic in a high degree, and B capable of accommodation for short distances. If A were accommodated for a greater distance ag, then evidently only a hypermetropic eye B, whose accommodation bg is therefore negative, could obtain a distinct image of the fundus of the eye A, and from the distance of the mirror $a\,b$ measure the accommodation of the eye A. This would evidently be $ag = ab + bg$. If, however, in the ophthalmoscopic examination, B were not capable of accommodation for negative distances, and if ag were the accommodation of A, then the mirror $S\,S$ must be combined with a correcting lens $L\,L$ (Fig. 107), and the examination therefore be made in the upright image, which admits of a closer approximation of the two eyes to each other and offers generally many advantages. The adaptation $a\,g$ of the eye A may now easily

Fig. 107.

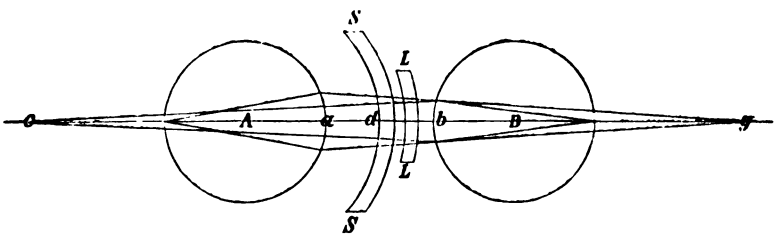

be reckoned from the focal length of the lens, which renders the distinct view of the fundus of the eye A possible, and from the known accommodation of the eye B by means of the main formula $\frac{1}{\alpha} + \frac{1}{a} = \frac{1}{p}$. Here namely α would be the accommodation of the eye B, or the focal distance obtained by the lens, a would be the accommodation of the eye A, plus or minus the distance of the mirror, and p the focal length of the adjoined lens. As a rule, the accommodation of the eye B will be positive, and therefore α will be negative in relation to the lens; whilst a in the myopic eye A must always be negative in relation to the lens. The main formula therefore appears as $-\frac{1}{\alpha} = -\frac{1}{p} + \frac{1}{a}$, that is, a concave lens is needed, whose focal length p is greater than a. If, however, B were absolutely hypermetropic, then the main formula would appear as: $\frac{1}{\alpha} = \pm\frac{1}{p} + \frac{1}{a}$, p will therefore be, as a rule, positive, and when negative, necessarily greater than a.

The ophthalmoscope, moreover, furnishes a means for judging of the refractive condition of the eye under examination in the magnifying coefficient of the virtual images perceived. Still, the exact ascertaining of this coefficient is scarcely possible, as we lack suitable measuring apparatus, and the diameter of the entrance of the optic nerve varies very much in different individuals, and moreover the existing distance of the correcting lens, relatively the magnifying-glass, from the eye examined exercises a very considerable influence upon the apparent size of the image of the fundus (*Schweigger*). Therefore we here only indicate in general, that the ophthalmoscopic examination, whether with the inverted or erect image, always gives an enlargement of the fundus of the eye; that the inverted ophthalmoscopic image of a myopic eye, compared with that of an emmetropic eye, appears diminished, and this is most so (5.3 : 4.6, *Schweigger*), when the refractive condition $N = n.\ sin.\ \beta$ has risen considerably by increase of the $sin.\ \beta$, less so (5.3 : 5.2, *Schweigger*), by growth of the n; that this increase, however, grows

with the distance of the lens from the eye; that the upright ophthalmoscopic image on the contrary causes the increase to appear very great, and particularly so when the increase of the refractive condition is principally caused by an increase of n, less so when it is caused by an increase of the *sin.* β, and therefore by a lengthening of the axis of the globe (*Mauthner, Schweigger*).

2. In myopia the near-point approaches the eye in proportion to the shortening of the distance of the far-point, when the accommodation remains normal, which is the rule.

Hence, from a marked shortening of the distance of the near-point, we may decide with great probability on the presence of myopia, and that this exists in a higher degree the nearer the near-point is to the eye; but the reverse is not true, —the lessening of the range of accommodation from many causes occurs not unfrequently in myopic cases with posterior staphyloma, and in old people.

In order to determine the near-point for practical purposes, it suffices to measure with the measuring-tape the smallest distance at which the eye is in a condition to read continuously under the visual angle of 5 minutes and relatively to recognize corresponding figures.

As a means of more accurate determination, it is well to place before the myopic eye a concave glass, whose focal length is equal to the distance of the far-point, and then to measure the distance at which the eye, with the glass, can read the text; for it is difficult to measure with a rule very small distances, such as here come in question. This distance is much increased by the concave glass, and thus the sources of error are so much diminished that even considerable differences of distance only correspond to very slight differences of converging distance—that is, of the position of the virtual image. The true distance of the near-point is then found by the ordinary formula.

3. The myope sees objects lying within his clear visual distance just as distinctly as a person with normal vision does; and at equally short distances he sees with even less exercise of the muscle of accommodation, *i.e.* with less straining. Therefore, as a rule, myopes can, without fatigue, continue in occupations which require continued vision at short distances longer than normally sighted persons. They assume such occupations from choice, and are more apt to do so because distant objects appear very indistinct, unless they use spectacles, which are troublesome.

Since the near-point is less distant, and the object can consequently be brought near the eye, myopes can undertake with ease fine work by weaker light than persons with normal eyes. For the same reason they make out finer details in objects, generally write a smaller hand, etc.

This is strictly true, however, only of the medium and low grades of myopia. Myopia over one-sixth is often, and over one-fourth is generally, accompanied by changes in the fundus of the eye, which greatly diminish central sharpness of vision, so that it becomes difficult or impossible to distinguish small objects, read fine print, etc. (*Donders*).

4. Objects placed beyond the clear visual distance are seen by myopes in circles of dispersion, their perception is, other things being equal, more indistinct, the further their distance from the extremity of the line of clear sight, and the larger the pupil. The latter factor can be diminished by drawing together the edges of the lids, at the expense of the brightness of the retinal image; and in fact myopes so frequently employ this maneuver to produce clear sight, that the functional disease in question has received its name from the Greek word μυειν, to blink.

On weak illumination of the visual field, the loss which the brightness of the retinal im-

ages suffers through a partial cutting-off of the circumferential rays is too great for the myope to obtain advantage from a decided drawing together of the eyelids. Under such circumstances, therefore, the abnormal condition of the eyes is especially felt. Even low grades of myopia become very evident in distant vision, and in high degrees it sometimes goes so far that going alone is very difficult, and those affected with it feel around like blind persons, while normal sighted persons, in the same light, find their way very well, and even perceive moderately small objects.

Causes.—Shortsightedness generally depends on abnormal increase of the long diameter of the eyeball, on account of which the natural focal length is relatively too short (*Arlt, Beer*). Other cases depend on abnormally great convexity of certain surfaces; that is, on an actual shortening of the natural focal distance.

This alternative is manifested very distinctly in the main equation $N = n.\ sin.\ \beta$, where N represents the refractive state of the eye, $sin.\ \beta$ the length of the globe, and n all those relations which exert an influence upon the refraction of the rays of light.

1. The elongation of the eye-ball often depends on faulty development. As long as the body grows, the eye continues to develop excessively in the direction of the optic axis, while the equatorial diameters remain the same. This state is called bathymorphia, or elongated eye-ball. (*Ed. Jaeger.*) It may be of any degree.

The predisposition to this is of course congenital, and is as a rule inherited. Where it exists, the myopia may be developed to high and extreme degrees, without any external circumstances having exerted any influence upon it. In fact we not uncommonly find high and extreme degrees of myopia depending upon pure elongation of the eyeball in persons who scarcely know a school even by name, and throughout their whole life have never occupied themselves with fine objects of work.

Much oftener the lengthening of the axis of the globe depends upon the development of a staphyloma posticum. This occurs especially in individuals whose business demands continuous near vision. In general it can also be said that the proportional per cent. of its appearance and the average degree of its development increases with the age, and especially with the length of time which has been spent in school instruction, or in an occupation requiring fatiguing vision for near objects. (*H. Cohn.*) Still the degree of development of the ectasia in the individual case by no means stands in direct proportion to the absolute degree of the refraction.

We really meet exceptionally with large, even ring-shaped staphylomata postica in eyes that are markedly hypermetropic, whilst on the contrary the ectasia is often entirely absent in high and extreme degrees of myopia. Only one factor of the refractive condition increases with the size of the staphyloma posticum, the others remain entirely unaffected by it. The result of the lengthening of the axis must therefore be very different according to the structure of the eye, and according to the value of the other relations which influence the refraction of light.

In order to render this perceptible, we need only give different values to N in the main equation $N = n.\ sin.\ \beta$ and then cause $sin.\ \beta$ to increase by a certain difference. If N had a higher negative value than this difference amounts to, the eye will remain hypermetropic; in the contrary case it will however be emmetropic or myopic. If N had a positive value, the myopia will by the same difference increase in a corresponding degree.

For the explanation of the data mentioned above, we may make use of the results of a statistical combination. Among 4,000 eye patients there were 350, *i.e.*, 8.75 myopes with a slightly different refractive condition of both eyes. In 220 cases the result of the ophthalmoscopic examination appears explicitly given. In 130 cases the ophthalmoscopic

with the distance of the lens from the eye; that the upright ophthalmoscopic image on the contrary causes the increase to appear very great, and particularly so when the increase of the refractive condition is principally caused by an increase of n, less so when it is caused by an increase of the *sin.* β, and therefore by a lengthening of the axis of the globe (*Manthner, Schweigger*).

2. In myopia the near-point approaches the eye in proportion to the shortening of the distance of the far-point, when the accommodation remains normal, which is the rule.

Hence, from a marked shortening of the distance of the near-point, we may decide with great probability on the presence of myopia, and that this exists in a higher degree the nearer the near-point is to the eye; but the reverse is not true —the lessening of the range of accommodation from many causes occurs not unfrequently in myopic cases with posterior staphyloma, and in old people.

In order to determine the near-point for practical purposes, it suffices to measure with the measuring-tape the smallest distance at which the eye is in a condition to read continuously under the visual angle of 5 minutes and relatively to recognize corresponding figures.

As a means of more accurate determination, it is well to place before the myopic eye a concave glass, whose focal length is equal to the distance of the far-point, and then to measure the distance at which the eye, with the glass, can read the text; for it is difficult to measure with a rule very small distances, such as here come in question. This distance is much increased by the concave glass, and thus the sources of error are so much diminished that even considerable differences of distance only correspond to very slight differences of converging distance—that is, of the position of the virtual image. The true distance of the near-point is then found by the ordinary formula.

3. The myope sees objects lying within his clear visual distance just as distinctly as a person with normal vision does; and at equally short distances he sees with even less exercise of the muscle of accommodation, *i.e.* with less straining. Therefore, as a rule, myopes can, without fatigue, continue in occupations which require continued vision at short distances longer than normally sighted persons. They assume such occupations from choice, and are more apt to do so because distant objects appear very indistinct, unless they use spectacles, which are troublesome.

Since the near-point is less distant, and the object can consequently be brought near the eye, myopes can undertake with ease fine work by weaker light than persons with normal eyes. For the same reason they make out finer details in objects, generally write a smaller hand, etc.

This is strictly true, however, only of the medium and low grades of myopia. Myopia over one-sixth is often, and over one-fourth is generally, accompanied by changes in the fundus of the eye, which greatly diminish central sharpness of vision, so that it becomes difficult or impossible to distinguish small objects, read fine print, etc. (*Donders*).

4. Objects placed beyond the clear visual distance are seen by myopes in circles of dispersion, their perception is, other things being equal, more indistinct, the further their distance from the extremity of the line of clear sight, and the larger the pupil. The latter factor can be diminished by drawing together the edges of the lids, at the expense of the brightness of the retinal image; and in fact myopes so frequently employ this maneuver to produce clear sight, that the functional disease in question has received its name from the Greek word *μυειν*, to blink.

On weak illumination of the visual field, the loss which the brightness of the retinal im-

emmetropes during the accommodation for short distances (*Cramer*). Direct observations have also proved, that continual efforts for the purpose of near vision may make even hypermetropic eyes temporarily and permanently myopic. The doubts advanced against this statement (*Donders*) do not rest upon any sufficiently positive facts. This kind of myopia has been called plesiopia, near-sightedness (*Ed. Jaeger*) It prevails only in the lower degree. The accommodation demanded by the work is the extreme limit, which it can never overstep, and even scarcely ever reach. There are but very few occupations which require an approximation of the objects inside ten inches. The lens also preserves under all circumstances a certain degree of elasticity, and can therefore always diminish its convexity when rest of the accommodation occurs.

It is in the nature of the matter, and searching investigations corroborate it (*Dobrowolsky*), that this form of myopia is only developed in individuals who occupy themselves constantly with very fine objects, and for this purpose make use of very large amounts of accommodation, and must therefore keep the ciliary muscle in a proportionately great tension, that hence persons who are almost emmetropic and hypermetropic individuals are pre-eminently exposed to it. The over-burdening of the accommodative apparatus generally soon leads to a greater reddening of the papilla, and in nervous individuals often to asthenopic troubles also. It sometimes even causes convergent squint. The error of refraction then gradually becomes evident by increasing indistinct vision for distant objects. This indistinctness of vision increases after continuous intense work, again improves, however, with a longer rest of accommodation, and even entirely disappears, in order to again appear on a new exciting cause. With prolonged, intense accommodative work the degree of the myopia and the duration of muscular relaxation necessary to the retrogression increase. Later on this retrogression is always more incomplete, the energetic employment of mydriatics becomes necessary, in order to lower the state of refraction to the former degree and make the latent hypermetropia manifest. Finally these means also become insufficient, the myopia becomes permanent, as the lens and in no less degree the ciliary muscle also permanently assume the form forced upon them.

To this form of myopia a considerable decrease in the range of accommodation is without doubt united (*Ed. Jaeger*), since a portion of it has been, so to speak, paralyzed by the loss of elasticity of the lens. If the lens follows the relaxation of the ciliary muscle only up to a certain limit, then its subsequent contraction must remain inactive up to the same limit. If the decrease of the range of accommodation is not in all cases a striking one, we should not forget that in young people by continued practice it can be raised far beyond the normal amount, and that the remaining increase in convexity of the lens generally equalizes only a trifling quota of it.

On the whole, according to what has been said, the over-burdening of the muscle of accommodation, especially in close and long-continued application in study, plays the most important part in the etiology of staphyloma posticum and of the increase in convexity of the lens. Still it is not alone the amount and kind of the occupation which is here to be taken into account; we must rather consider the conditions under which these occupations are practised, since these conditions may increase very much the demand on the accommodation. Thus the eyes are often brought excessively near the object on account of insufficient illumination or on account of an unsuitable position of the body, *e.g.* on account of sitting too low while writing. Certain it is that the percentage of myopes is not entirely the same in different

examination was neglected, partly for different reasons, partly because it furnished no result worthy of consideration. Among these 220 cases there were 117, *i.e.* 53.18% with crescentic, narrow staphyloma posticum, and in 53 of these cases the state of refraction varied between $\frac{1}{12}$ and $\frac{1}{6}$, in 50 between $\frac{1}{36}$ and $\frac{1}{12}$, in 14 between $\frac{1}{18}$ and $\frac{1}{36}$. In 67, *i.e.* 30.45% of the cases there was found a large, pointed-arch like staphyloma posticum, exceeding in its longest diameter half the breadth of the papilla, dome-shaped in 26 cases, circular in 31. The state of refraction varied here in 45 cases between $\frac{1}{12}$ and $\frac{1}{6}$, in 19 cases between $\frac{1}{36}$ and $\frac{1}{12}$, in 3 cases between $\frac{1}{18}$ and $\frac{1}{36}$. In 36, *i.e.* 16.36% of the 220 cases, the absence of a staphyloma posticum is explicitly noted. In 21 of these cases the state of refraction varied between $\frac{1}{12}$ and $\frac{1}{6}$, in 9 between $\frac{1}{36}$ and $\frac{1}{12}$, in 6 between $\frac{1}{18}$ and $\frac{1}{10}$.

The influence which the development of a staphyloma posticum exerts upon the state of refraction appears most clearly in those cases in which the myopia is merely one-sided or of very different degree in the two eyes, and in which this difference may be referred to the monolateral formation of a posterior scleral staphyloma.

Among those 4,000 cases were 20, where the state of refraction of both eyes exhibited a difference of $\frac{1}{18}$ to $\frac{1}{72}$. In 4 cases, in which the difference varied between $\frac{1}{18}$ and $\frac{1}{8}$, there was a small crescentic staphyloma in the myopic eye. In 2 other cases, where hypermetropia existed in the one eye, and a high degree of myopia in the other, and the state of refraction of the two eyes showed a difference of $\frac{1}{28}$ and $\frac{1}{24}$, there was found a large, circular staphyloma in the myopic eye. In 11 other cases a large staphyloma posticum existed on one side, with a difference in the states of refraction between $\frac{1}{8}$ and $\frac{1}{6}$.

Every greater difference in the refractive conditions of both eyes should not however be referred to the development of a staphyloma posticum. In two cases there was a difference of $\frac{1}{8}$ and $\frac{1}{4}$, and in both there was an equally large crescentic staphyloma posticum in each eye. In one case where there was no staphyloma in either eye, there was in the right a myopia of $\frac{1}{7}$, in the left a hypermetropia of $\frac{1}{40}$, therefore a difference of nearly $\frac{1}{6}$, which was evidently to be referred to monolateral bathymorphia.

An increase of the normal refraction can be caused further by a greater curvature of the cornea and of the lens, as well as by an advance of the latter towards the former. Hitherto an increase in curvature of the cornea has not been set down among the pathogenetic causes of myopia, although exact measurements have demonstrated differences of more than a millimeter in the radius of the anterior surface of the cornea (*Ed. Jaeger, Donders*). Such a marked difference, however, as a simple calculation can prove, must alter essentially the state of refraction of the eye in question; it may, other things being equal, change high degrees of hypermetropia into myopia and vice versâ.

If in highly myopic eyes the corneal curvature has been found less than in other conditions of refraction (*Donders*), a very effective correction must be here seen. In such a case n in the main equation $N = n.\ sin.\ \beta$ appears diminished, whereby the increase of $sin.\ \beta$ is necessarily partially neutralized in its effect. But what the flattening of the cornea accomplishes in pure elongation of the eye, the greater curvature of the cornea in emmetropia and hypermetropia must likewise be in a condition to produce.

Of much less importance are approximation of the lens to the cornea, its prolapse into the anterior chamber (*Ed. Meyer, Noyes*), rounding off of its form, as often occurs in stretching and rupture of the zonula, in ectopia and spontaneous luxation, sometimes in partial cataracts also. These accidents are without a doubt possible causes of increase in the state of refraction. Still, under such circumstances, the first symptom is always the irregular astigmatism on account of defective centering of the dioptrical apparatus, and frequently on account of irregular curvature of the lens also, and the result therefore is really no true myopia.

Increase in the convexity of the lens is indisputably an important pathogenetic cause of shortsightedness. Exact measurements by means of suitable instruments have in fact demonstrated, that in many myopes the mirrored images of the lens hold exactly the same relation to each other in size and mutual position as in

emmetropes during the accommodation for short distances (*Cramer*). Direct observations have also proved, that continual efforts for the purpose of near vision may make even hypermetropic eyes temporarily and permanently myopic. The doubts advanced against this statement (*Donders*) do not rest upon any sufficiently positive facts. This kind of myopia has been called plesiopia, near-sightedness (*Ed. Jaeger*) It prevails only in the lower degree. The accommodation demanded by the work is the extreme limit, which it can never overstep, and even scarcely ever reach. There are but very few occupations which require an approximation of the objects inside ten inches. The lens also preserves under all circumstances a certain degree of elasticity, and can therefore always diminish its convexity when rest of the accommodation occurs.

It is in the nature of the matter, and searching investigations corroborate it (*Dobrowolsky*), that this form of myopia is only developed in individuals who occupy themselves constantly with very fine objects, and for this purpose make use of very large amounts of accommodation, and must therefore keep the ciliary muscle in a proportionately great tension, that hence persons who are almost emmetropic and hypermetropic individuals are pre-eminently exposed to it. The over-burdening of the accommodative apparatus generally soon leads to a greater reddening of the papilla, and in nervous individuals often to asthenopic troubles also. It sometimes even causes convergent squint. The error of refraction then gradually becomes evident by increasing indistinct vision for distant objects. This indistinctness of vision increases after continuous intense work, again improves, however, with a longer rest of accommodation, and even entirely disappears, in order to again appear on a new exciting cause. With prolonged, intense accommodative work the degree of the myopia and the duration of muscular relaxation necessary to the retrogression increase. Later on this retrogression is always more incomplete, the energetic employment of mydriatics becomes necessary, in order to lower the state of refraction to the former degree and make the latent hypermetropia manifest. Finally these means also become insufficient, the myopia becomes permanent, as the lens and in no less degree the ciliary muscle also permanently assume the form forced upon them.

To this form of myopia a considerable decrease in the range of accommodation is without doubt united (*Ed. Jaeger*), since a portion of it has been, so to speak, paralyzed by the loss of elasticity of the lens. If the lens follows the relaxation of the ciliary muscle only up to a certain limit, then its subsequent contraction must remain inactive up to the same limit. If the decrease of the range of accommodation is not in all cases a striking one, we should not forget that in young people by continued practice it can be raised far beyond the normal amount, and that the remaining increase in convexity of the lens generally equalizes only a trifling quota of it.

On the whole, according to what has been said, the over-burdening of the muscle of accommodation, especially in close and long-continued application in study, plays the most important part in the etiology of staphyloma posticum and of the increase in convexity of the lens. Still it is not alone the amount and kind of the occupation which is here to be taken into account; we must rather consider the conditions under which these occupations are practised, since these conditions may increase very much the demand on the accommodation. Thus the eyes are often brought excessively near the object on account of insufficient illumination or on account of an unsuitable position of the body, *e.g.* on account of sitting too low while writing. Certain it is that the percentage of myopes is not entirely the same in different

schools, but increases considerably in those localities where sufficient daylight is wanting or where it must be replaced by artificial light during a long time, or where the arrangement of the tables and benches does not stand in any correct relation to the size of the scholars, and compels them to incline their bodies far forward (*H. Cohn*). The manner in which children sit also influences the development of the myopia. An influence is moreover exerted by a defective acuteness of vision on account of abnormal astigmatism or other causes. Opacities of the separate dioptric media are, however, of great importance in this connection, particularly of the cornea, since the disturbances of vision occasioned by them are to a certain extent diminished by close approximation of the object, by much of the lateral diffused light being thus cut off, and on the other hand by the size and brilliancy of the retinal images being increased, and therefore the intensity of illumination of the spectrum being absolutely and relatively diminished. Finally a very important cause lies in the use of improper concave glasses, inasmuch as by them virtual images are cast at too short distances from the eye, and hence a very disproportionately large amount of accommodation is rendered necessary.

Course and Results.—1. Elongation of the eyeball usually manifests itself in early childhood. When the growth of the body ceases, the lengthening of the axis of the globe depending upon it seems no longer to increase, and if a further increase of the shortsightedness is then noticed, it is always to be regarded as dependent upon a commencing staphyloma posticum. It is, moreover, possible that the elongation of the eyeball sometimes becomes stationary before the complete maturity of the individual has been reached, and that the incongruity between the separate diameters increases no further, but the increase of volume of the globe follows more uniformly in all directions up to the termination of the bodily growth.

2. The *staphyloma posticum* and the elongation of the axis of the globe caused by it may appear at every period of life. As a rule, however, the resulting myopia appears in childhood, and especially during the epoch of puberty; in the latter so commonly that we may, perhaps, assume a pathogenetic connection between them. There is, however, no doubt that it is not so much the period of puberty in itself, but rather the exertions demanded of the eye at this period, when the eyes are used a great deal in study, which give the proximate cause. Where the apparatus of accommodation is little taxed during the time of sexual maturity, here the development of a staphyloma posticum is very uncommon and is scarcely to be observed, except where there is a decided elongation of the globe.

Prolonged occupation, moreover, with small objects exercises an important influence upon the further relation of an already existing staphyloma posticum, and frequently occasions its further progress. This advancement is sometimes very gradual and imperceptible, but sometimes grows rapidly at intervals. The distance of the far-point decreases very considerably in such cases during the course of a few months, whereupon the process usually comes again to a stand-still, or the progress, at least, becomes imperceptible. Such a temporary progression is most often observed during youth, in cases in which a considerable degree of shortsightedness had been present long before the period of puberty; sometimes, however, in those cases also, where during childhood the myopia was very slightly developed, and was apparently at a stand-still, or else had undergone a scarcely perceptible increase.

The staphyloma posticum, and with it the myopia, in consequence of intense strain on the accommodation, commonly remain undeveloped till the later years of manhood. It is then frequently to be found only in one eye, and here sometimes

grows to a very considerable size, while the other eye preserves its entire integrity, and with this its former state of refraction. Thus it happens, that in many cases we find in one eye a higher degree of myopia, and sometimes strabismus divergens also, and in the other eye hypermetropia.

The staphyloma posticum and the shortsightedness occasioned by it may become stationary at any stage, particularly when the strain on the accommodation is essentially limited. In general, however, we can say, that an actual condition of "statu quo" of the affection, especially when the circumstances are not favorable, is so much the less to be expected the more pronounced the elongation of the ball is, and the greater the dimensions which the staphyloma posticum has already acquired.

Moreover, the posterior scleral staphyloma grows to extreme degrees but very rarely, without actual inflammation of the posterior internal structures of the eye having manifested itself at one time or another, and having led to real alterations of their structure. These accidents are particularly threatening with a fitful increase of the staphyloma posticum. They often announce themselves a long time before by the appearance of the spot of Mariotte in the field of vision, by the development of fixed and movable scotomata, by the incapability of the eyes to bear dazzling light, and particularly by their incapacity for continuous use, by greater injection of the ciliary and retinal vessels, by annoying feelings of pressure and weight in the globe, and later even by real manifestations of photopsia and cloudiness of the field of vision. They always lead in the end to very remarkable malformations of the choroid and retina. Intraocular extravasations of blood, also, often accompany them, as well as detachments of the retina, or at least of the vitreous humor, and sometimes also cataract.

Bathymorphia, especially when accompanied by extensive posterior staphyloma, has still other bad effects; for at short distances, binocular vision requires great convergence of the visual axes; that is, strong action of the internal recti muscles. But in bathymorphia the demand on the latter appears to be much increased by the fact that, to attain equal convergence, far greater lateral motions of the eye are requisite than in emmetropic eyes; for in myopes the axis of vision meets the long axis of the cornea at a very acute angle, or it even cuts the cornea at a point outside of its center of curvature (*Knapp, Donders, Schuermann*), and sometimes even so far to the temporal side that, on fixing near objects, the eye appears to squint inward. Moreover, in the elongation, the point of rotation of the eye is relatively moved forward (*Doyer, Donders*); hence, decided lateral motion of the anterior pole of the eye presupposes far greater motion of the posterior pole. Consequently, the opposition to be overcome increases, and the excursive power decreases. (*Schuermann.*) The internal recti are often unable to answer this double demand on them. Hence arise asthenopic difficulties, which the patient the more readily tries to avoid by turning one eye outward, because in this forced divergence he finds a way of removing the far-point beyond its natural distance, and thus facilitating vision with the fixing eye. (See *Strabismus.*) Thus we see that muscular asthenopia and external strabismus are common occurrences in myopia. (*Beer.*)

3. The myopia dependent upon an increase in the convexity of the lens is much less important in every respect. With careful use of the eyes it may entirely recede, and at any rate never attains a high degree. When the growth is completed, an increase rarely takes place, for the density of the nucleus of the lens does not then favor further change of form. This is, of course, on the supposition that a staphyloma posticum is not simultaneously developed.

4. Besides the several actual causes, the changes in the lens and muscles (which act in vision) accompanying advanced age, have great influence on the course of myopia. The increasing density of the lens leads first to a diminution of the range of accommodation. It causes a retrocession of the near-point.

Indeed, such shortenings of the visual distance in low grades of myopia often occur when, from necessity or inclination, the individual is continuously employed with small objects. The recedence of the near-point is generally first remarked about the fortieth year, and then the myope may be obliged to use *convex* glasses while at his former employment, on account of an increase in the necessary amount of accommodation, and must hold even larger objects at some distance from the eye, in order to see them distinctly.

In medium and high degrees of myopia, the removal of the near-point thus caused is much less, and hence is usually less important, because patients are rarely continuously employed about objects which, from their minuteness, must be brought near to the near-point of short-sighted eyes. But, under such circumstances, another disturbing element is frequently felt, viz., the decrease in strength of the muscle of accommodation. In high degrees of posterior staphyloma, it appears, as a rule, and most frequently quite early, during youth. It progresses occasionally to complete paralysis of accommodation. The distinct visual distance is then, of course, limited to the short line of accommodation corresponding to the distance of the far-point, and the patient is obliged to make use of different concave glasses for different distances, if he wishes to see clearly.

Subsequently, in old age, with progressive diminution of the range of accommodation, the flattening of the nucleus of the lens becomes of importance, and the fact that, with increasing density, the various layers of the lens acquire a more even density, *i.e.*, the number of the surfaces is diminished.

The result of this is a diminution of the natural refractive condition, and an increase in the distance of the far-point corresponding to it. The latter with an equal difference is naturally so much the slighter the greater the state of refraction was formerly, and hence, in high degrees of shortsightedness, as a rule, very slight; but on the contrary, in low degrees of myopia, particularly when dependent upon increase in convexity of the lens, is often sufficiently great to turn the refractive defect into hypermetropia. Since, however, the near-point simultaneously recedes, and this is more apt to occur since the muscle of accommodation at last participates in the senile changes, the entire clear range of vision appears removed from the eye.

It is self-evident that the diminution of the state of refraction which results from the senile changes of the apparatus of accommodation is far surpassed in its effect by that of a progressive staphyloma posticum; that, therefore, by its existence the myopia must continually increase in spite of the senile involution, and the latter can only be of use in the corresponding decrease in the range of accommodation.

The Treatment must first attempt to check, if possible, the development and increase of the myopia. The second indication is, by the choice of appropriate concave glasses, to compensate for the shortening of the distance of distinct vision. And finally, by prescribing appropriate conditions, we should meet the dangers which result from faulty use of spectacles, and which very often confirm the pathological state.

1. The prophylactic treatment must naturally begin in early childhood, and be especially carried out where there seems any existing predisposition. It chiefly consists in shunning continued straining of the eyes for the purpose of seeing at very short distances.

In regard to this, the choice of children's plays even is of importance. Of especial importance, however, is their mode of study. Only books with large, coarse letters should be placed before

children; they should be obliged to write a large hand, with heavy, thick strokes; drawing, and with girls the learning of fine sewing, knitting, and especially the so-called "fine work," &c., are better begun after childhood, and when myopia exists they should be avoided altogether. It is also of the greatest importance that children, in such occupations, should be accustomed to keep the object fully in front of them, so that both eyes stand at an equal distance from the point fixed; furthermore, that they do not incline the head more than necessary to the object, whose surface should be held at an angle of forty-five degrees to the plane of the face. Hence it is very important that the children should not *sit too low* compared to the object. (*Fahrner.*) Besides, it cannot be strongly enough urged, that in occupations requiring strong action of accommodation, the object be sufficiently illuminated. Nothing favors the development and increase of myopia so much as compelling children to read, write, &c., continuously in dusky places, and at a distance from the light. Children, at such employments, should use artificial light as little as possible.

Finally, the *continuance* of such employment is of importance. They should never be continued for hours, but at measured intervals interrupted and replaced by works or plays, which make no demands, or only moderate ones, on the apparatus of accommodation.

By a suitable and regularly continued treatment, we may doubtless hope, in a certain percentage of the cases, to repress the development of the short-sightedness, and to cause a retrocession of slight increase of convexity in the lens. If there is a disposition to bathymorphia, we can scarcely hope altogether to avoid the development and further increase of the short-sightedness. Nevertheless, the most rigid carrying out of the prophylactic rules appears peculiarly indicated in just such cases. For it is certain that congestive conditions of the eye exercise a most evident influence on the further progress of the elongation, as well as on the development and increase of posterior staphyloma.

The *bent position of the body*, with the consequent compression of the abdominal organs particularly, is a very important factor, as well on its own account, as because its effect increases with the progress of the bathymorphia. This does not cease to make itself felt, even when the myopia has already advanced so far that vision in the immediate vicinity no longer demands any exercise of power from the muscle of accommodation, and the optic axes do not retain their convergence, since the patient has learned to draw off one eye in viewing near objects. Hence, we may say that, in decided elongation of the eye, causes and effects move, to a certain extent, in a faulty circle; and therein lies, at least partially, the cause why high grades of bathymorphia so readily continue to progress, and finally lead to the worst results.

An immediate result of this is, that, in great predisposition to elongation, still more in already far-advanced bathymorphia, as well as when there is a posterior staphyloma, prophylaxis must be continued beyond puberty, and must be particularly important in the choice of a profession or occupation for life.

It is the duty of the physician, by all means at his command, to prevent individuals with decided bathymorphia from taking up employments which require continued vision at short distance, with stooping posture, such as watch-making, wood-engraving, lithographing, &c., and even tailoring and shoe-making. The pitiable cases caused by such mischosen employments appear only too frequently in practice, and these are the more apt to occur as, from youth up, strongly myopic individuals show an especial taste for such callings, and consider themselves as very especially fitted for them.

2. It is vain to attempt to oppose and by direct means to cure short-sightedness, or rather its causes; we must confine ourselves to neutralizing, as much as possible, the errors of refraction. This, as is well known, is done by concave glasses, which throw upright and diminished virtual images of all objects at a positive distance, *within* their negative focal distance, that is, *before* the spectacles. If they are to answer their purpose fully in the majority of cases, they must, by a correct position

before the eye, bring to a point, within the shortened clear visual distance, upright virtual images of objects beyond the far point, and the position and size of this virtual image must be such that the short-sighted eye, with glasses, brings it to clear perception under nearly the same exertion of accommodation, and with nearly the same visual angle as the normal eye, without glasses, brings the *object* itself.

In low and medium grades of short-sightedness, all these requirements may be completely satisfied practically by spectacles, whose negative focal distance, increased by the distance of the glass from the eye, is equal to the far point of the latter. To find these glasses, it is only necessary to determine the far point. Its distance, increased by the distance of the glass from the eye, gives the focal length of the glass required.

If the glass be chosen correctly, the eye before which it is placed must see distant objects under a visual angle of at least five minutes clearly and distinctly, and must be in a condition to read correspondingly large test-type with the usual fluency. As this, however, renders the choice of too strong a glass possible it will be well to make trial of somewhat weaker numbers for objects at a greater distance. The weakest glass which admits of a clear and distinct recognition of distant objects, would then be the most suitable. A large experience, moreover, makes it seem prudent to increase somewhat the size of the angle, *i. e.*, to choose objects which exceed a little the generally adopted size, since otherwise we come very frequently upon glasses which are found to be too strong, at first are at least troublesome, and may finally even become injurious by causing a demand for greater quotas of accommodation.

If the glass which corrected exactly the error of refraction could be placed in the optical center of the eye, the eye would see at any distance with the same amount of accommodation as an emmetropic eye, and the size of the images would be the same in both. But the necessary distance of the glass from the optical center of the eye changes these relations somewhat, and sometimes makes itself felt in a very unpleasant manner. Besides this, it happens that the relation of the amounts of accommodation and convergence, which has become established from practice, undergoes considerable disturbance by the correcting glass. In fact, the eye armed with the glass must employ a certain amount of accommodation for all objects situated at short distances beyond the far-point, whilst without the correcting glass it can employ the corresponding amount of convergence with complete relaxation of the muscle of accommodation. These disturbances of co-ordination are felt very much in many cases, and under certain circumstances, in difficult change of co-ordination, and in very sensitive eyes may require temporary combination of concave glasses with weak prisms, the base directed outwards, and which, therefore, demand an increased amount of convergence for any distance of the object.

In the same way the *higher* grades of myopia may best be neutralized by glasses whose focal length, increased by their distance from the eye, equals the far-point of the latter.

But in these cases a complete correction of the faulty refraction is rarely advantageous. For, with strong glasses, their distance from the eye makes a great difference, and causes a very sensible diminution of the retinal images, even if the glasses be properly chosen. Besides this we have the increasing deviation of rays that fall obliquely, and a consequent distortion of the images of objects lying to the side. These deviations are so annoying that very short-sighted persons usually prefer to wear glasses that are relatively too weak. They forego sharp perceptions of distant objects so as to obtain distinct vision for nearer points. If they occasionally wish to see distinctly at a distance, it is better for them to use opera-glasses.

We not uncommonly, however, hear very near-sighted persons complain of the inefficiency of the ordinary opera-glass. Usually such patients can assist themselves by using their correct-

ing glass with the opera-glass, and therefore make their eye likewise emmetropic. In ladies, who do not regard the wearing of glasses with favor, the evil may be remedied by adding to the eye-piece of the opera-glass a concave glass of the refractive value of the correcting glass; or, better still, by increasing the refractive value of the eye-piece itself by that of the correcting glass. If $-\frac{1}{m}$ were the refractive value of the correcting glass, and $-\frac{1}{n}$ that of the ocular of the opera-glass, then $-\frac{1}{m}-\frac{1}{n}=-\frac{1}{o}$ would be the desired refractive value of the new ocular, and o the radius of curvature of both its sides.

Much less suitable are the so-called Steinheil glass cones, which are solid cones of glass, about an inch long, with a slightly convex anterior surface and a strongly concave posterior surface, which act like the Galilean telescope. These were in use as early as the beginning of this century under the name of the Stöpsel opera-glass, but have been abandoned. Their advantage consists mainly in their small size, which admits of their being worn in the form of an eye-glass attached to a string round the neck, in the head of a cane, etc.

In many cases of short-sightedness, where we require to enlarge the retinal images somewhat, and at the same time completely correct the error of refraction, opera glasses are very valuable. These are likewise an old invention, as a small collection of them was found among some old rubbish at the Vienna optician's, *Fritsch*, and neither the latter nor his gray-haired predecessor knew anything either of the creator or inventor. These, like the glass cones, are constructed upon the principle of the Galilean telescope, have all an anterior convex surface of 9''' radius, and a posterior concave surface with very varying radius. The difference of the latter and of the thickness gives to them the most manifold positive and negative focal lengths. These can be easily computed for every arbitrary refractive value, according to the formulæ of *Stampfer* or *Gauss*. According to the latter the focal length ϕ of such a glass would be $\phi=\frac{ff^1}{f+f_1-e}$; in which $f=\frac{r}{n-1}$; $f^1=\frac{r^2}{n-1}$; $e=\frac{d}{n}$, and n represents the refraction in passing from the air to the glass, r the radius of the anterior convex surface, r^2 the radius for the posterior concave surface, and d the length of the axis or thickness of the lens. If we choose r_1 and r_2, then from the above formula the thickness necessary for a definite focal length ϕ may be computed, and in case we choose these and one radius, the other radius necessary for a definite focal distance ϕ also. The position of the two principal points E and E_1, as well as that of both foci F and F_1, are given by the following formulæ:—

$$E=\frac{e\phi}{f^1};\ E^1=\frac{e\phi}{f};\ F=\frac{f(f_1-e)}{f+f^1-e};\ F^1=\frac{f_1(f-e)}{f+f^1-e}$$

The distance of the first principal point E from the anterior surface, and that of the second principal point from the posterior surface are both to be measured forward, since E possesses a negative value. On the contrary, the distance of the anterior focus F from the anterior surface of the lens is to be estimated forwards, the distance of the posterior focus F_1 from the posterior surface of the lens backwards, and then a negative value would be given for them, where the distances are to be taken in the opposite sense. As a means of control we must make—

$$F-E=F_1-E_1=\phi;\ E-E_1=ne-\frac{e(f+f_1)}{f+f_1-e}$$

As coefficient of increase m we have $m=\frac{\phi}{\phi-p}=\frac{\phi-p^1}{\phi}$, in which p denotes the distance of the object from anterior chief point E and p^1 the distance of the virtual image from the posterior principal point E_1.

In case both eyes are myopic but are of different refraction (*Anisometropia*), we should as a rule choose for each eye that glass which changes the myopia to emmetropia and which consequently calls for an equal amount of accommodation in both eyes for an equal distance of the object. Where, however, the difference in the refraction is very great, and binocular vision is evidently present, the difference in the size of the images becomes very annoying by the use of different glasses, fully

correcting each side, and this indeed to such a degree that the patient much prefers the former condition of affairs, where the perceptions of the one eye were less clear and distinct. In consequence of this disturbance symptoms sometimes make their appearance, similar to what occurs after using too strong a glass; the condition becomes insupportable to the myope, or he learns to diverge somewhat with the eye in question and to suppress its vision in looking at a distance. We may to some extent obviate this inconvenience by only partially correcting the error of refraction of the more short-sighted eye, or at any rate of the eye which is less used in seeing at a distance, that is, by placing before it a weaker glass, and thus reducing the difference to a less disturbing amount.

Many believe that $\frac{1}{20}$ is the largest admissible difference in the refractive values of the two glasses used for binocular vision (*Donders*). In general this may be correct, still we meet with enough cases, where with indubitable binocular vision much greater differences, $\frac{1}{18}$, $\frac{1}{17}$ and even more are not only borne, but prove very advantageous and pleasant. Hence in the one case the admissibility of a certain difference cannot in advance be theoretically gainsaid, but it must always be decided by the trial.

It is not advisable to choose the middle course, that is, to give glasses whose focus is about *half* the difference of the two far points. Such glasses are too weak for one eye, and too strong for the other.

As a general rule, *binocular* spectacles should be used even when the second eye is incapable of function, or at least does not act in distant vision; for monocular spectacles are not easily retained in the right position, as they should be, if they are to fulfil their indications. Of course the frames must be carefully made.

Hence eye-glasses are less to be recommended. They are only suited for slight degrees of myopia, where the errors arising from faulty position of the glasses will be slight. They may also be used when the patient is disinclined to wear spectacles, and is satisfied with occasional clear glances at distant objects. If concave glasses are, however, used for a long time or continually, they should always be in spectacle form.

Spectacles, with spring clasps, which, throughout their length, press closely to the side of the head, and consequently hold firmly without pressing more on one point than another, are the best. Of course, these clasps should be the stronger the heavier the glasses, that is, the greater the short-sightedness to be neutralized.

This, however, has its limit, since, with the strength of the clasp, the weight of the spectacles, and the pressure which certain parts, especially the bridge of the nose, must support, increases. This circumstance proves that spectacles are generally not proper, when the individual is obliged to make very quick and extensive movements of the body. Spectacles which would remain firm, under such circumstances, soon become unbearable from their pressure. But if the spectacle is movable, the vision is greatly disturbed. Very short-sighted persons are, therefore, not suited for riding, leaping, &c.

The spectacles should stand near to the eye, in order to reduce, as much as possible, the deviation of the size of the retinal images. Especially necessary is this in high degrees of short-sightedness, where strong glasses are used. Still, the approach must never be so great as to let the cilia touch the posterior surface of the glass,

because the latter would soon become dirty and useless for sharp vision. In very prominent eyes this often becomes quite troublesome, and absolutely prevents the use of appropriate glasses.

The axes of the glasses and the optic axes should fall in the same direction, or at least only inclose a small angle, in order that chiefly central rays may reach the retina through the pupil, and the deviations produced by the prismatic form of the external parts of the spectacle may not have a chance to act. This requires that the glasses be well *centered*, that, when the spectacles are in use, their *middle* points be placed opposite the pupils, and the surfaces of the glasses stand perpendicular to the prolonged optic axis or visual line.

A glass is *centered*, when the vertical points of both curved surfaces are directly opposite each other, and sufficiently in the middle of two curves, that is, are every where at an equal distance from the margin of the lens. This centralization requires numerous and costly instruments, also dexterity and great care on the part of the maker. This centralization is most easily accomplished in *round* glasses, and is much more difficult when the glasses are to have the popular *oval* form; oval glasses are, therefore, quite frequently badly constructed, and should only be bought of trustworthy opticians; otherwise there is no objection to them, only they should be large enough to cover the pupils, even during extensive lateral movements.

If the middle points of the two lenses do not stand opposite the pupil, it may be easily seen that only such rays can arrive at the retina as have passed through a lateral portion of the glass, as all the other rays have been absorbed by the iris. A lateral portion of the glass, bounded, as it were, by the pupil lying behind it, acts on the light passing through, like a prism with curved surfaces. It deviates the rays toward its base, that is, toward the corresponding margin of the glass, and this deviation is the stronger the greater the refractive angle of the prism, that is, the stronger the glass. Hence, this error is less marked with *weak* glasses, but makes itself more felt with *strong* glasses; for the images falling on the retina appear blurred, or else deviate altogether from the visual line, and require a degree of convergence of the optic axis inharmonious with the accommodative condition of the eye. This disturbance of the developed conditions of accommodation often shows itself very quicky by the appearance of muscular asthenopia, and can not be long borne. Moreover, the difficulty is greatly increased when the surfaces of the glasses do not stand perpendicular to the visual lines, as, with the size of the angle of incident, the deviation which the rays acquire through the prismatic form of the margins of the glass, increases.

Hence arises the necessity of giving to the bridge of the spectacles a length corresponding to the average of cases, and a horizontal position. Therefore, before the choice of spectacles, it must always be decided how far the vertical points of the two cornea stand from each other, when the patient looks at the distance for which he is to wear the glasses.

In practice, however, very accurate decisions are not necessary, as the spectacles are not always used for one single distance. With the change of the distance the angle of convergence of the visual axes changes, and hence also the distance between the vertices of the two cornea. To avoid error entirely, the centers of the spectacles would have to approach and recede, according to the distance of the object, but this is not practicable. It is only necessary that this difference should not pass a certain limit. This limit is, for weak glasses, *extensive*; for *strong* glasses, slighter, but *in all* cases limited enough to render the same glasses unsuitable for great and small distances.

To reduce the prismatic deviation to a small amount, the surfaces of spectacles used for distant vision must stand in the same vertical plane before the eye. If the spectacles, however, are to serve for short distances, the glasses should incline, corresponding to the angle of convergence of the optic axes; the bridge must then describe a bow, with a posterior convexity in the horizontal plane. The spectacle-

glasses must be ground from very clean and perfectly colorless mirror or crystal glass.

Bubbles, cracks, flaws, and of course also spots of dirt, have the worst effect on the clearness of the perceived images; for the diffuse light acting on them produces turbid spectra, which lay themselves over the images. Therefore, while the spectacles are not being used, they should be kept in suitable cases. Fine linen should be used for cleaning them; chamois' skin has the advantage of softness, but where long used, it becomes fatty, and does not answer the purpose.

Spectacles are usually numbered according to the length of their focus. As a rule, the number expresses the focal length in inches, so that a glass of 40, 20, 10, 6, 5½, has so many inches' focus. Hence spectacles of the same number vary in different countries according to the long measure in use. Some opticians, however, number their glasses on wholly independent and sometimes very arbitrary principles.

Ordinarily, concave glasses are ground bi-concave, more rarely plano-concave. Formerly convex-concave or *periscopic* glasses were very popular, since their spherical form was said to cause the deviation to be less felt.

Metal, with dead polish, is the best material for spectacle frames; horn and tortoise-shell are lighter, but such frames readily turn and so alter the position of the glasses to the eye.

The use of suitable glasses is not of itself injurious; but certain precautions must be observed in their use. Unsuitable *use* of glasses, even when they altogether answer the requirements, is quite certain to increase the evil and to excite a series of injurious circumstances.

In medium and high degrees of shortsightedness, if the patient has hitherto worn no glasses or else much too weak ones, and if the relative accommodation is defective, the sudden disturbance of the deep-rooted relations of coordination is not uncommonly the source of asthenopia. In these cases it is well at first only partially to neutralize the myopia and gradually to increase to the fully-correcting glasses, according as the relations between the accommodation and convergence change.

It is an important rule never to use spectacles for distances *within* the limit of clear vision; for since, with *concave* glasses, the focal distance of divergent rays is always shorter than the distance of the object, by the use of glasses for objects lying within the far-point, the requirements of accommodation are considerably increased. The muscle of accommodation which, with the naked eye, could remain at rest, or would have to make but little exertion, must now exercise considerable force to bring and retain the lens in the curvature corresponding to the distance of the virtual image. The accompanying overburdening of the muscle of accommodation, and the consequent disturbance of the developed conditions of associations, usually quickly excite asthenopic difficulties, and by continued misuse of the spectacles, cause a true asthenopia, and one very difficult to cure. Besides this, the overburdening of the muscles of accommodation causes congestion of the eye, which gives one of the most active pathogenetic factors for progressive development of bathymorphia, also for quick development and increase of posterior staphyloma, and indirectly even for inflammatory processes in the deeper parts of the eye, which again may lead to complete loss of function of the organ. If the glasses are strong, or are improperly placed before the eye, these bad results progress more rapidly and urgently, and the spectacles become most injurious.

Therefore, in low degrees of myopia, spectacles should only be used for distant vision. The case is different when the far-point sinks to less than ten inches: then concave glasses can not always, without injury, be laid aside, even in near vision, in reading, writing and similar employments, since, for clear vision, the object must

e approached very near to the eye; which not only presupposes very great *convergence* of the optic axes, as long as binocular vision exists, but also renders necessary great *stooping* of the body when the position of the objects is not readily changed. With this in view, it is well, in far-points of less than 10 and more than 8 inches, in employments where the objects can be removed to 12 or more inches, without injuring the clear vision of the myope, to recommend glasses whose focus lies a few inches beyond the far-point. Such a rule seems particularly advisable, even absolutely necessary, where the range of accommodation is relatively very small.

Theoretically the indication is to choose glasses which made the same amount of accommodation necessary for the distances in question, as in the emmetropic eye. These, however, would be fully-correcting, and these prove as a rule too strong for eyes unaccustomed to glasses, as they disturb exceedingly the relations of coördination. If, however, we consider only the latter, and if we choose glasses which cast the virtual images of the objects in question exactly in the position of the far-point, the patients then, as a rule, find them too weak, and while using them are unsatisfied, whilst a slight demand upon the muscle of accommodation usually proves very agreeable.

The necessity of such a choice of glasses appears especially in musicians, who are obliged to hold the notes at a fixed distance, about 18-30 inches distant from the eye.

In myopia of less than 6 inches' far-point, the patient should use glasses that are too weak. Hence, he can use the proper glasses for *near* objects, and generally does so without injury, as he usually places a second glass in the form of "eye-glass" before his spectacles when regarding distant objects.

The refractive value of such an eye-glass may be easily computed from the formula $-\frac{1}{f}-\frac{1}{g}=-\frac{1}{p}$, in which f is the focal length of the glass, p that of the two glasses taken together or of the completely correcting glasses and g the desired focal length of the eye-glass. There results namely:—

$$-\frac{1}{g}=-\frac{1}{p}+\frac{1}{f}.$$

4. The periods of progressive growth of posterior staphyloma require particular attention. As long as this has not become stationary, the above-defined rules must be followed very carefully, and any overburdening or cause of congestion of the eye should be most carefully avoided. If the disease appears to be advancing rapidly, the above rules no longer suffice; then absolute rest is required, if we would arrest the process.

Above all, it is necessary to entirely give up any employment that strains the eye, as reading, writing, &c., and to protect the eye from dazzling light, and particularly from strong contrasts of illumination.

5. The *senile* changes in the eye deserve great attention on account of their influence on the length and position of the clear visual distance. They increase the expenditure of accommodation for distinct vision at short distances lying within the far point, in proportion as the near point recedes from the eye. The result of this is, that the former customary employments of the myope now overburden the muscle, and may endanger the eye. The myope then aids himself, to a certain extent, by increasing the distance of the object; but when this increase has gone as far as the nature of the employment, or the size of the necessary visual angle,

permits, the habitual employment must be given up, or spectacles used which throws virtual images of the object at the most convenient distance, nearer to the far point of the myopic eye.

In *low* grades of myopia, when the object must be brought near to the eye, it is frequently necessary to use weak convex glasses, which throw upright enlarged virtual images of the objects lying within their focus, beyond the distance of the object.

But in *high* grades of near-sightedness, in which, as above advised, concave glasses are used for *near* vision, it becomes necessary, instead of the spectacles formerly used, to choose *weaker* ones, in order, by this means, to increase the distance of the virtual image, the distance of the object remaining the same. If, later, the distance of the far point moves off, the spectacles used for greater distance must be exchanged for others, whose focus answers to that of the last far point. In the highest degree of myopia, in which, as a rule, too weak glasses are used, a change of glasses is rarely needed.

6. In cases of myopia, where, in looking at near objects, *binocular* vision exists, and the impossibility to *effect* the convergence of the optic axes necessary for certain employments, or to keep it up long, shows itself, prismatic (or so-called dissecting glasses) are indicated. (See *Treatment* of Asthenopia.)

In high degrees of short-sightedness, where the demands on the internal recti are always excessive, it is at present advised not to await the occurrence of asthenopia, but from the first to use prismatic glasses, and if these do not answer the purpose, to lay back the external rectus muscle, in order to forestall the bad effects as much as possible. It is also thought that the tenotomy has a beneficial influence on the subsequent course of the bathymorphia, and may even prevent its advance. (*Graefe.*) But on the whole it is better to postpone operating till it becomes absolutely necessary. (See *Asthenopia.*)

We cannot sufficiently caution against such an undertaking. In case we could by means of it really put a stop to the progress of the main trouble, the gain would be all too dearly bought by disturbances in the power of projection, and by the consequent unavoidable exclusion of the one eye from binocular single vision.

Authorities.—*Stellwag*, Sitzungsberichte der Wiener k. Akad. der Wiss. XVI. Bd. 1855. S. 201 et seq. Ophth. II. S. 337-360.—*Donders*, A. f. O. IV. 1. S. 301, et seq; VI. 1. S. 67, 83, 101, VI. 2. S. 219, et seq., IX. 1. S. 105, 135-154; Anomal. der Ref. u. Acc. Wien. 1866. S. 74, et seq.—*Ed. Jaeger*, Einstellungen des dioptr. Apparates Wien. 1864. S. 25, et seq.—*Hasner*, kl. Vorträge, Prag. 1860. S. 31, et seq.—*Ruete*, Lehrb. der Ophth. I. Braunschweig. 1853. S. 220, 223.—*Graefe*, A. f. O. II. 1. S. 160, III. 1. S. 308; kl. Montbl. 1863. S. 355-360, 1865. S. 392.—*Burow*, ein neues Optometer, Berlin, 1863, Ueber die Reihenfolge der Brillenbrennweiten. Berlin, 1864; A. f. O. IX. 2. S. 228, XII. 2. S. 308. kl. Monatbl. 1866. S. 293.—*Helmholtz*, Beschreibung eines Augenspiegels. Berlin. 1851. S. 38.—*Schweigger*, Vorlesungen über den Gebrauch des Augenspiegels. Berlin. 1864. S. 58.—*Schuerman*, Vijfde. Jaarl. Verslag. Utrecht. 1864. S. 1.; kl. Monatbl. 1864. S. 92, 95.—*Knapp*, A. f. O. VI. 2. S. 7.—*Doyer*, Derde Jaarlijsch Verslag. Utrecht. 1862. S. 209.—*Donder's* Anomalien, etc. S. 339.—*Virschoor*, Zesde Jaarl. Versl. Utrecht. 1865. S. 97.—*Böhm*, der Nystagmus, etc. Berlin. 1857. S. 40.—*Arlt*, die Krankheiten des Auges. III. Prag. 1856. S. 238.—*H. Cohn*, deutsche Klinik. 1866. Nr. 5, kl. Monatbl. 1866. S. 188, 195.—*Cramer*, Het. Accommodatievermogen. Haarlem. 1853. S. 141, 145, 146.—*Fahrner*, Wien. Jahrb. f. Kinderheilkunde, VI. S. 151-168; kl. Monatbl. 1866. S. 189.—*Giraud-Teulon*, kl. Monatbl. 1864. S. 316, 318; Congress intern. d'ophth. Paris. 1863. P. 102.—*Zehender*, kl. Monatbl. 1866. S. 1-17, 203.—*Javal*, nach Burow. A. f. O. XIII. 2. S. 308.—*Haase*, Pagenstecher. klin. Beobachtgn. III. Wiesbaden. 1866. S. 102.—*Beer*, Lehre v. d. Augenkrankheiten. II. S. 653, 654.—*Reute*, Schmidt's Jahrbücher. 134. Bd. S. 217.—*Graefe*, kl. Monatbl. 1869. S. 227.—*Schweigger*, Göttinger Nachrichten 1870. Nro. 9.—*H. Cohn*, kl. Monatbl. 1867. S. 357; 1868. S. 49; Untersuchung der Augen von 10.000 Schulkindern. Leip-

867; Berlin. Med. Wochenschrift. 1867. Nro. 50; 1868. Nro. 50.—*Ainsiaux*, Congrès L d'ophth. Paris. 1868. S. 180.—*Pagenstecher*, kl. Beob. III. S. 102.—*Coccius*, der anismus der Accommodation. Leipzig. 1868. S. 67-109.—*Ed. Meyer*, kl. Monatbl. 1869. l.—Dobrowolski ibid. 1968. Beil. S. 3, 93, 141, 175, 181, 201.—*Mauthner*, Lehrb. d. Ophroscopie S. 161, 190.—*Kaiser*, A. f. O. XIII. 2. S. 353.—Liebreich, ibid. VIII. 1. S. 261. *der*, kl. Monatsbl. 1868, S. 37.—*Woinow*, Centralbl. 1869, No. 56.—*Lagneur*, ibid. S. —*Schumann*, Experimentaluntersuchungen über die Baufehler, etc. Leipzig, 1869.—Noyes, iv für Augen—und Ohrenheilkde. I. S. 154.

Hypermetropia.

Symptoms.—The chief symptoms of this disease are the lowering of the refraction below what is called the normal zero, that is to say the removal of the far-point from positive infinity to a negative distance, and a consequent inability of the eye to unite convergent rays into distinct images on the retina.

Hypermetropia is that condition of the eyeball, in which its antero-posterior diameter is too short, and hence the focus of its dioptric system is situated behind the layer of rods and cones of the retina.—*Donders.*

1. The distance of the far-point may vary in all negative values. Still hypermetropia is only of significance in practice when the refraction reaches a very low degree, that is, when the far point is approached to within a few feet of the eye, or the optic axis elongated posteriorly.

For measuring the distance of the far-point, we generally content ourselves in practice with finding out the strongest convex lens, which placed immediately before the eye, renders still possible the clear and distinct vision of distant objects under a visual angle of 5 minutes. The focal length of this glass diminished by its distance from the eye, gives the desired distance of the far-point, and its reciprocal value the degree of hypermetropia.

It is evident, that by such a procedure the exact state of refraction cannot be found. The relations of co-ordination between the ciliary and converging muscles do not admit of a complete relaxation of the muscles of accommodation in a parallel position of the visual lines. The lens moreover, which in hypermetropes is maintained uninterruptedly in a certain degree of convexity, with insufficient elasticity does not always, even if ever, spring back to its natural shape, even when the ciliary muscle is completely relaxed; and therefore the refraction remains somewhat increased. In order to determine correctly the true distance of the far-point to an approximate degree, it is therefore indispensable to fully relax the muscle of accommodation for some time by repeated instillations of a strong solution of atropine.

If at this examination the pupil is widely dilated, the glass should be covered, except a part the size of the ordinary pupil; otherwise the symmetry of curvature of the cornea and lens shows itself, and impairs vision. Optometers can only be used when they are made with regard to chosen negative distances. They give even less reliable results than in emmetropia and myopia. The opthalmoscope renders good service, provided that the muscle of accommodation of the eye examined is paralyzed by mydriatics, and the examiner knows the state of his own accommodation while using the instrument. If in (Fig. 108) the eye examined A is hypermetropic and accommodated for o or g the examining eye B by means of a simple illuminating mirror S S will obtain a distinct image of the fundus of A, if its accommodation is bo or bg. The distance of the far-point of the eye A then appears as bo-ba or as bg-ba. A myopic eye B can naturally obtain by a simple illuminating mirror a distinct image of A only when this is hypermetropic in a high degree. If however B were in high degree hypermetropic, then A must be hypermetropic in a slight degree, in order that the fundus of the latter should be distinctly seen.

If, however, the illuminating mirror is combined with a correcting lens, and therefore the examination be made with the upright image, these restrictions are done away with and the

Fig. 108.

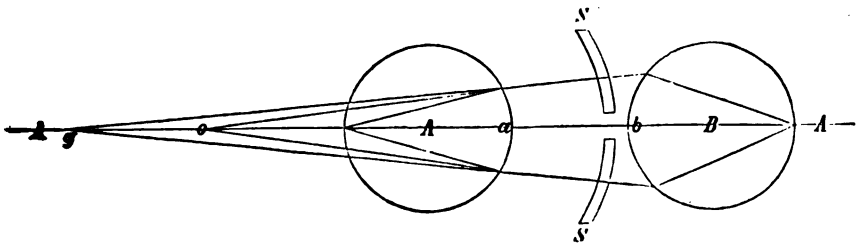

focal length of the glass necessary for distinct vision combined with the known accommodation of the eye B furnish the necessary factors for the computation of the refraction of A. The formula $\frac{1}{a}=+\frac{1}{p}-\frac{1}{a}$ here again holds good, in which a signifies the accommodation of the eye B, p the focal length of the lens, and a the accommodation of the examined eye A plus the distance of the mirror. If the eye A (Fig. 109) were accommodated for g and B for o, then would $a=gb$ and $a=ob$; a concave lens would then be necessary for distinct vision. When

Fig. 109.

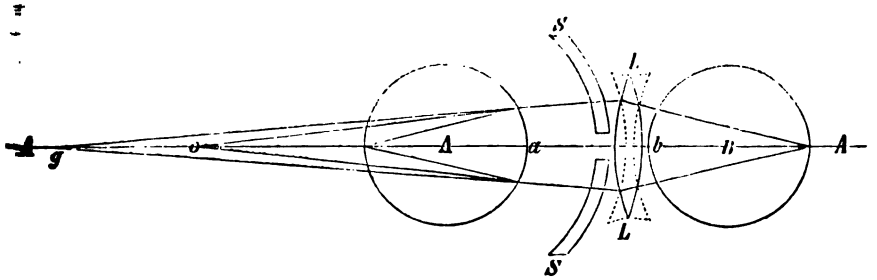

however A is accommodated for o and B for g, a convex lens must plainly be employed. In case B is absolutely hypermetropic, the formula takes the form $\frac{1}{a}=\frac{1}{p}-\frac{1}{a}$, and a convex lens is necessary under all conditions.

The magnified condition in which the fundus of a hypermetropic eye compared with that of an emmetropic eye is perceived, is also of some value. In the inverted image the relative enlargement is a considerable one, particularly (5 : 3 : : 6 : 1, *Schweigger*) when the hypermetropia depends upon a flattened construction. It moreover increases as the distance of the glass from the eye. In the upright image it is very slight, especially when in the main equation the n appears diminished (*Mauthner*, *Schweigger*).

[See Appendix, for more extended remarks on examination with the upright image].

2. The near-point may lie at either a positive or negative distance from the eye; hence the distance of distinct vision is sometimes interrupted, again it is negative throughout its entire length.

We speak in the first case of a facultative hypermetropia, in the latter of an abso-

lute hypermetropia, without there being thereby necessarily different degrees of hypermetropia designated, since the position of the near-point depends not only upon the minimum refraction but also upon the extent of the range of accommodation, and consequently a hypermetropia of equal value may be represented as facultative and absolute. This will be best rendered intelligible by placing a number of cases of negative refraction by the side of one another, and adding to each a fixed difference, $\frac{1}{5}$, $\frac{1}{10}$, etc.; that is to say, ascertaining the maximum refraction by fixed range of accommodation, and out of this the near-point.

Moreover, we then see immediately that cases of refraction of a low degree give, with normal or even increased range of accommodation, distances of the near-point, which are not very essentially distinguished from normal, and that a hypermetrope with a highly-increased range of accommodation may have a shorter distance of the near-point than an emmetrope with the normal range of accommodation.

Generally, a relative hypermetropia is also distinguished. By the latter we understand a hypermetropia, in which the near-point can only become positive when the axes of vision cross in front of the point fixed (*Donders*); in other words, when the eye gives up binocular vision and squints inward.

In order to ascertain the position of the near-point it is sufficient in facultative hypermetropia to make use of the procedure proposed for the same purpose in myopia, namely, the determining of the smallest positive distance at which the eye is in a condition to see objects under an angle of five minutes clearly and distinctly. In absolute hypermetropia a convex lens corresponding to the distance of the far-point must be placed before the eye, and then the shortest distance measured, in which clear and distinct perceptions may still be obtained with this glass. From this value and from the focal length of the glass in use, the distance of the virtual image may easily be reckoned, and by subtraction of the distance of the glass from the eye we know the position of the near-point.

3. Objects and virtual images that lie within the distance of clear vision are as sharply and clearly seen by the hypermetropic eye as by the emmetropic; still, he must bring into play much larger amounts of accommodation, and he is hence more easily fatigued, and his range of accommodation would then overstep the normal, which is frequently the case in young persons, who busy themselves for a length of time with small objects, and hence exercise their accommodation strongly. The necessary quota of accommodation for 20 and for 10 units of measure is in emmetropia with range of accommodation of $\frac{1}{5}$, $\frac{5}{20}$, and correspondingly $\frac{5}{10}$. In hypermetropia—$\frac{1}{20}$, and with a range of accommodation $\frac{1}{5}$, the quotas of accommodation for 20 and 10 units of measure would be $\frac{5}{10}$ and $\frac{5}{100}$; in hypermetropia — $\frac{1}{20}$, and with a range of accommodation $\frac{1}{3}$ they would be $\frac{3}{10}$ and $\frac{3}{100}$. In hypermetropia — $\frac{1}{10}$, and with a range of accommodation $\frac{1}{3}$ for distance of 20 and 10 units of measure, quotas of accommodation of $\frac{3}{100}$ and $\frac{3}{5}$ would be necessary. Objects and virtual images lying beyond the line of distinct vision are universally the more indistinct, the larger the circles of dispersion meeting the retina; that is, the wider the pupil and the greater the distance behind the retina at which the rays of light, passing the dioptric apparatus, come to a focus.

But inasmuch as the circles of dispersion are far less influenced by this latter factor (from causes above mentioned), than by the diameter of the pupil, especially as long as the lens exists as a condensing medium, the hypermetrope acquires tolerably clear perceptions of objects lying far within his near-point in *positive* distance, by partially *covering*, and as much as possible

contracting the pupil, and thus perceptibly increasing his clear visual distance by a considerable amount in a positive direction. He is accustomed, therefore, in examining near objects, to blink as the myope does, and, if possible, so to place himself that the object and the eye may be strongly illuminated. By the exercise of the maximum of his power of accommodation then, not only is the difference of the posterior converging point lessened, but the pupil is more contracted, and, when he can no longer change the size of the circles of dispersion, he seeks to lessen their action by bringing the object near to the eye, since, in inverse proportion to the distance of the object, the visual angle, and hence, also, the bright nucleus of the circle of dispersion increases, and hence the latter overcomes the indistinct *contours*. By continued practice, wonderful power of doing away with circles of dispersion is often acquired, so that it is not rare to find young patients with hypermetropia, who, with the naked eye, read medium, and even very fine print, sew, &c., provided they can illuminate the eye and the object sufficiently to contract the pupil. Where the illumination is weaker and the pupil more dilated, the difficulty of adjustment becomes more evident, and may even go so far that absolute hypermetropes find difficulty in going about alone, in dim twilight, or rather dark rooms.

4. It is also important to note here that, not unfrequently, in high degrees of *facultative*, and almost always in high degrees of *absolute*, hypermetropia, there is marked diminution of sharpness of vision. With increasing age, this progresses much more rapidly than it does in emmetropia. This is partly explained by the fact that, on account of the relative distance of the posterior focus, the retinal images appear *smaller*, partly by a deficient development of the sensitive parts of the eye. Another important fact is, that in high grades of hypermetropia there is almost always an asymmetry of the cornea and lens (*Donders*).

Causes.—Hypermetropia may be the result as well of a shortening of the axis of the globe, as of decrease in curvature of the separate refracting surfaces, or of a diminution in the refractive conditions of the lens.

This is seen directly from the main equation $N=n, \sin. \beta$, where the length of the axis of the globe is represented by $\sin. \beta$, and the relations of refraction and curvature are represented by the factor n.

1. Hypermetropia really often results from a defective form of the eye-ball, especially an abnormal shortening of the optic axis. This defect, the so-called "flat formation," plathymorphia, is often congenital, and frequently hereditary (*Ed. Jaeger*). Where it reaches a very high grade, it shows itself very markedly by the deep position and actual or apparent smallness of the eye.

On careful examination, the lateral portions of the eye are found to be more strongly curved. In opposition to the state in bathymorphia, the globe has grown more in width than in length; it appears pressed together from behind forward, that is, flattened antero-posteriorly; and the anterior chamber is often much contracted. This depends upon an increase of convexity occasioned by the constant effort at accommodation, or perhaps also on the advanced position of the lens, and causes the cornea generally to appear somewhat flatter. An *actual* flattening of the cornea is not, however, one of the peculiarities of hypermetropic (plathymorphic) eyes. On the contrary, in high grades of congenital hypermetropia, where the cornea is smaller, it is often more strongly curved. (*Donders.*) At the same time the optical vertex of the cornea is almost always displaced inward. The axis of vision and the long axis of the cornea inclose a far greater angle than is the case in emmetropes. Not unfrequently they even cut the cornea so far inward from its center of curvature, that when they are parallel, the eyes appear to squint divergently (*Donders*), and the motion outward of the axis of vision is much limited. (*Schuerman.*) It is uncertain whether hypermetropia is accompanied by a slighter curvature of the crystalline. (*Donders.*) It is said that decided plathymorphia is accompanied by shallow orbits, and consequently the entire countenance has a flat appearance. (*Donders.*)

The range of accommodation appears in this form of hypermetropia very often markedly increased in young individuals, far surpasses $\frac{1}{5}$ and even reaches $\frac{1}{3}$. This should not excite any surprise, as in hypermetropia the ciliary muscle is from childhood very strongly brought into play, and the circular fibers especially active in accommodation are generally excessively developed. Under such circumstances cases occur sufficiently often, in which the range of accommodation, in spite of youth and great activity of the ciliary muscle, scarcely reaches $\frac{1}{3}$, and is even considerably less. It seems that it is exactly in these cases in which a convergent strabismus is threatened. Still the diminution of the range of accommodation is, under such existing circumstances, by no means always a real one, but often in fact an apparent one, since in practice we take into account usually not the really most extreme minimum refraction, but rather the minimum refraction manifest in parallelism of the visual lines.

Another consequence of this morbid condition is, that the range of accommodation in the same individual varies according to time and circumstances. The manifest distance of the far-point is dependent as well upon range of relative accommodation as upon the occupation of the individual and upon the greater or slighter elasticity of the lens: it is one after prolonged rest, another after prolonged efforts of the ciliary muscle to obtain near vision.

A further consequence of the defective determination of the distance of the far-point is the apparent rarity of hypermetropia in youth. According to statistical investigations (*H. Cohn*) myopia appears in children and young persons four times as often as hypermetropia. These calculations were limited solely to individuals who were at school, and who, therefore, had caused the lens to assume a greater curvature by great and continuous accommodation, and who might perhaps have acquired a staphyloma posticum. With this view agrees the circumstance that the number of hypermetropes and the degree of the error of refraction can show no increase during the period of study, but increased rapidly after termination of school-life.

2. Another cause of hypermetropia, which has hitherto attracted but little attention, lies in the congenital abnormal flatness of the cornea, and perhaps of the lens also (*Donders*).

Diminutions of convexity of the different surfaces of the dioptric apparatus is sometimes also acquired. Inasmuch, however, as the curvature is then always very irregular, the result will be not so much hypermetropia, but rather irregular astigmatism with far-sightedness as the basis. Under this head come those cases of flattening of the cornea, which result from the shrinkage of cicatrices, and those of diminution in the volume of the lens, which usually arise from the retrogressive metamorphosis of partial cataracts. In hypermetropia of the latter kind the range of accommodation is always reduced to nothing.

3. A further very frequent source of hypermetropia is cataract operations, or anything that removes the lens from the optic axis. The hypermetropia thus caused is always absolute and of a high grade, the negative distance of the far-point is very short, so that convex lenses of very short focus are required. The variation between different cases depends mostly on differences in the natural forms of the eye. In very myopic eyes, the hypermetropia caused by aphakia is usually less than one-fourth; in other cases it is over that amount. Under such circumstances the power of accommodation is entirely lost. Cases may occur now and then, where eyes, that have lost their lenses, retain the power of seeing objects at *different* distances, with a suitable lens, or without one. But this depends on an unusual asymmetry of the cornea, on a very marked regular corneal astigmatism. (*Donders.*) This

may be assisted by a very narrow pupil and the cultivated power of suppressing circles of dispersion. These cases of such excellent vision are relatively very rare. As a rule, besides the loss of accommodation, there is a decided diminution of sharpness of vision, which is caused by the frequent occurrence of opacity of the posterior capsule and vitreous, after the extraction of the lens; sometimes, also, by irregular curvature of the cornea.

4. Most frequently hypermetropia is caused by the senile degeneration of the lens—that is, by the flattening of the crystaline, accompanying its increase of consistence and the consequent increase of the regularity of the density in the different layers. These very peculiar physiological circumstances always show themselves first by a decrease of the extent of accommodation, also by a removal of the near point; the simultaneous lessening of the natural refractive condition of the eye—that is, the removal of the far point—is hidden by involuntary contraction of the muscle of accommodation. It requires the powerful action of mydriatics to render it evident. In eyes that have been *normal*-sighted, it appears as if there were only a question of an anomaly of accommodation, of a lessening of the distance of clear vision from a simple increase of the distance of the near point; that is, of a condition which was formerly described as *far-sightedness* (presbyopia, in the strict sense of the word). With increasing senescence of the lens, however, the error of refraction becomes evident and increases more and more; while simultaneously, on account of increasing opposition of the lens to accommodative change of form, and finally on account of senile decrease of strength of the muscle, the extent of accommodation diminishes in more rapid progression. The apparently *pure* error of accommodation is always more prominent than the actual affection, which is a hypermetropia combined with a decided limitation of accommodation. (See *Course.*) According to the axiom: *a potiori fit denominatio*, the great frequency of cases from this cause justifies the original designation of this error of refraction as *hyperpresbyopia.*

The Course and Results vary greatly according to the cause of the affection.

1. Decided plathymorphia is rarely observed in babes. It usually begins in childhood, and increases gradually, as, with the growth of the body, the disproportion between the different diameters of the eye increases. (*Ed. Jaeger.*) On the completion of growth, however, the form of the eye-ball appears to become settled, and a further decrease of the refraction appears to depend solely on increased density of the lens, and hence to accompany limitation of the accommodation.

Still, it not uncommonly happens that the far-sightedness caused by the shortness of the eyeball suffers a diminution in degree during the period of youth, the state of refraction therefore increases or myopia may even result. In some cases with further growth of the globe the disproportion between its separate diameters may be done away with, or the shortness of the optical axis may be compensated for by increase of curvature of the cornea. As a rule the reason of the increase of the refraction is without doubt the increase of convexity of the lens caused by the prolonged efforts at accommodation, together with the greater development of the circular fibres of the ciliary muscle, but particularly the acquisition of a staphyloma posticum.

The shortness of the eyeball very often (in 61 per cent. of children manifestly hypermetropic, *H. Cohn,*) leads to convergent squint, since the amount of accommodation necessary to near vision is more easily set up and maintained under forced attempts at convergence. In many cases it merely amounts to giving up binocular single vision; one eye is, as it were, neglected with the binocular part of its field

of vision, the portion of the retina in question becomes more and more blunted to perception, and finally becomes entirely incapable of finer powers of perception.

When the body has completed its growth, such evil effects are scarcely to be feared. Later in life, hypermetropes are subject to accommodative asthenopia. This may occur early, when the hypermetropia is congenital, but, as a rule, it does not come on till about the twenty-fifth year, when the increasing density of the lens offers greater opposition to accommodation. With increasing density of the lens, accommodation is diminished, just as in normal or myopic eyes. Subsequently, from flattening and regular partition of the density in the different layers of the lens, there is a shortening of the distance of the negative far-point; the hypermetropia increases.

2. In eyes deprived of the lens, the focus of the dioptric apparatus can not vary much. Still, it is asserted by many that in excessively myopic persons who have undergone a cataract operation, there is a new increase of the refraction even up to slight degrees of myopia (*Mooren*).

But, even under the most favorable circumstances, the exercise of accommodation necessary to such employments, soon exceeds the given power of the organ in question. The muscle of accommodation, which, on account of the increased distance of the near point, must contract almost to the maximum, to bring the lens to the necessary convexity, soon tires, and at the same time very disagreeable painful feelings are developed in the ciliary region. (See *Asthenopia.*)

Finally, with progressive hardening of the lens, and increasing senile involution of the muscle of accommodation, the near-point recedes, the range of accommodation sinks far below its normal value to $\frac{1}{10}$, $\frac{1}{15}$, even to $\frac{1}{60}$ and less, and renders such employment impossible for the naked eye. The patient can only see objects which give a sufficient visual angle when at a distance of some feet.

Treatment.—We can scarcely effectually prevent the development and increase of the disease; but treatment is very serviceable in decreasing and removing the dangers that accompany hypermetropia. The second indication, partly included in the first, aims at neutralizing the abnormal adjustment of the dioptric apparatus, and at avoiding the injuries arising from the improper use of glasses.

1. In a prophylactic point of view, similar rules obtain as in decided elongation of the eye. It is necessary, above all, that children with plathymorphic eyes should not learn to read, write, &c., too soon; otherwise the above-mentioned evils, especially strabismus, occur.

Besides this, it is of the highest importance to wear suitable and correctly-made spectacles. It would be a great error to urge tender age as a ground against their use. On the contrary, if any thing besides care of the eyes can obviate the above-mentioned dangers, it is the rational use of suitable spectacles. Still, we must not overlook the fact that spectacles can not entirely replace the normal form of the eye, since faults not to be avoided cling to them, and especially that their conjugate foci increase and diminish in different *proportions; so that a plathymorphic eye* with a suitable glass, is, under all circumstances, inferior to a normal eye in power. To avoid injury, this should be well noted in the choice of a means of livelihood. As a general thing, it may be considered as certain, that plathymorphic individuals can not, without great danger, engage in an employment which requires *continued* sharp vision at near distances.

2. The object in using the glass, considered from the theoretical side, is evidently to cause the hypermetrope to see clearly and distinctly at every distance with one and the same amount of accommodation, like an emmetropic eye, and therefore not only to correct completely the error of refraction, but also the somewhat defective range of accommodation. Where the range of accommodation is normal this service will be rendered by a convex lens, whose positive refractive value is equal to the negative state of refraction, in which the necessary distance of the glass from the optical center of the eye is not regarded. In case, however, the range of accommodation were diminished or even zero, the refractive value of the convex lens in relation to the diminution of the range of accommodation would naturally be raised as soon as the question arose of obtaining a clear and distinct image of near objects. In practice, however, the glasses selected according to this principle are always very much too strong, the hypermetrope always feels extremely uncomfortable while using them, asthenopic troubles soon appear, which compel the discontinuance of the use of the glasses. Here we must again take into account that the hypermetrope was formerly compelled to work with a very large amount of accommodation, and now, provided with a glass, is called upon to perform the same occupations with a much smaller amount of accommodation. After great and continued efforts at accommodation, however, the flattening of the lens is not always proportional to the relaxation of the ciliary muscle, but frequently remains below it, so that the accommodation in question makes a proportionately greater relaxation of the ciliary muscle necessary. This great relaxation of the muscle of accommodation, however, the distance of the object being unchanged, brings with it a very great disturbance of the intimate coordinate relations, which will not be borne. The hypermetrope, therefore, always prefers to combine a greater amount of accommodation with the corresponding amount of convergence, and can do this so much the sooner, as the circular fibers of the ciliary muscle, by reason of their greater development, facilitate essentially the work of accommodation.

In determining the correcting glasses, therefore, it is not the really extreme distance of the far-point which is the standard, but rather the manifest distance; in other words, the convex lens to be chosen must, on the whole, have a somewhat smaller refractive value than would, in fact, correspond to the degree of the hypermetropia.

a. In facultative hypermetropia the use of correcting-glasses for seeing at a distance is, as might well be supposed, found very troublesome. Even when the near-point is removed very far from the eye, and therefore a high degree of accommodation becomes necessary, the patients prefer the unaided eye for seeing at a distance. Correcting-glasses are, therefore, only a necessity when the patient wishes to see distinctly at short distances, and under such circumstances have to cast upright and correspondingly enlarged virtual images of objects, determined according to their position, at a greater positive distance from the eye, and therefore to act like magnifying glasses. Where the range of accommodation is normal, that glass, as a rule, answers best whose positive refractive value raises the minimum amount of manifest refraction to zero. If, however, the range of accommodation has sunk beneath the normal standard, the refractive value of the glass must be increased by a corresponding difference. The amount of this difference cannot be easily determined theoretically, since the range of relative accommodation here plays an important part, and, as is well known, is very changeable; since further equivalent disturbances in coördination are borne very differently in different individuals, and in the

same individual under different circumstances. On the whole, great limitations of the range of accommodation require great differences, and small limitations small differences; the real value of the latter can, however, only be obtained by experiment. In order that the chosen convex lens may be regarded as suitable, it must render the images of near objects perfectly clear and sharply defined, and type, therefore, deep black, without indistinct margins, and slightly magnified; but, furthermore, must admit of a change of distance of the object within certain limits, without detriment to the sharpness and distinctness.

A slight amount of magnifying, particularly in the somewhat stronger glasses, is without significance. It depends in part upon the unavoidable distance of the glass from the eye, in part upon the unwonted relaxation of the ciliary muscle, and upon the confused estimate of size connected with it, and therefore usually disappears after a time, so far as the latter factor comes into play.

A glass which compels the wearer to remove the objects upon which he is engaged beyond the normal distance, or to approximate them to the eye, is not the correct one; in the first case it is too weak, in the latter too strong.

Very often glasses are proved to be unsuitable for use, which at the first moment seemed to fulfil these conditions, as they demand too much from relative accommodation. Hence, this examination should not be superficial, but the patient must use the glass ten minutes, a quarter of an hour, and longer, for reading and similar work, and must find it satisfactory before deciding upon its fitness. At the same time it is well to change the intensity of illumination of the room in different degrees, and also to make the examination by artificial light. It then frequently appears advantageous to choose somewhat stronger glasses for work by artificial light.

If we meet with great aversion to every disturbance, even the most trifling of the intimate relations of co-ordination, the latter must be gradually remodeled according to the necessities of the case. As a rule, it suffices to use the glass at first only for a very short time, with many interruptions, and immediately to lay it aside as soon as an uncomfortable feeling comes on. Generally, the hypermetrope accustoms himself to the glass within a few days, and can then always use them without any trouble, provided that it is correctly chosen.

Wealthy persons who can afford to purchase several pairs of glasses may commence with weak glasses, which facilitate somewhat the work for the patient, and gradually pass to the correcting-glasses.

Often, however, there remains nothing to be done but to combine the correcting-glass with prisms, the base turned inwards, in order to unite the diminution of the amount of accommodation to a corresponding decrease in the necessary amount of convergence, and thus to avoid the alternative either of leaving the correction of the hypermetropia and of the defective range of accommodation entirely insufficient, or by the choice of the correct refractive value to call out asthenopic troubles through disturbance of the co-ordinate relations. The refracting angle of the prism needs but seldom to reach three degrees on each side, and, as a rule, two degrees are sufficient. The aim of all this is by no means to disburden the converging muscles entirely, but rather to diminish somewhat the necessary amount of convergence by the unusual lessening of the amount of accommodation. Such convex lenses ground upon prisms render very excellent service in suitable cases. Moreover, it is not long before the new coördinate relations are again fully established.

and admit of a further step forwards. The hypermetrope can now dispense with the prisms and make permanent use of the simple correcting convex lenses for work.

The change of the co-ordinate relations connected with the use of the glass, brings along with it soon the incapacity of the hypermetrope to unite the convergence necessary for short distances with the corresponding amount of accommodation; when seeing with the naked eye he must remove small objects much farther away than was formerly the case, and, therefore, in reading and writing without glasses he finds much greater difficulty than formerly, or else is entirely unable to perform such work. It is then the habit of the laity to assume an increase of the evil and to attribute to the glasses an injurious influence upon the power of vision. Hence arises the tolerably widely-extended dread of commencing the use of glasses. It is the duty of the physician to destroy such doubts by an explanation of the error, and to acquaint those needing glasses, at the time of ordering them, with the consequences to be expected.

b. In absolute hypermetropia convex glasses are also necessary for seeing distinctly and clearly at great distances. Here also it is not the neutralizing glasses which correspond, but much weaker ones, which compel a union of a very considerable amount of accommodation with the parallel position of the visual axes. For near vision, on the contrary, with a normal range of accommodation, the glasses which reduce the manifest minimum refraction to zero again come into play; but where the range of accommodation is normal we use convex lenses whose refractive value somewhat exceeds in amount the manifest degree of hypermetropia. The rules above given hold good for the choice of these glasses.

Many hypermetropes of this kind prefer to use a glass for ordinary purposes. In case they then wish to see for a short time near by, they can add an eye-glass, which brings the refractive value of the glass to the degree necessary for near vision. If $\frac{1}{m}$ were the refractive value of the glass employed for distant vision and $\frac{1}{n}$ that of the glass necessary for near vision, then the refractive value $\frac{1}{o}$ of the eye-glass would be $\frac{1}{o}=\frac{1}{n}-\frac{1}{m}$.

When the range of accommodation is very small, or even zero, as *e. g.* after cataract extractions, a different glass should really be employed for every distance. In practice however, two different convex lenses as a rule suffice. What is wanting in these, is sufficiently supplied by the conditions which assist the accommodation. Moreover, the patient may still aid himself by moving the glasses away from and towards the eyes. In so far as in absolute hypermetropia glasses of only a few inches focal distance are always necessary, the distance of the glass from the eye has a very perceptible influence upon the position of the virtual images in the range of distinct vision. An increase of this distance up to ¼, ½ an inch almost always suffices to enable us to dispense with glasses with focal lengths of intervening values.

In strong glasses, which are needed by highly hypermetropic eyes, particularly in aphakia, the irregular refraction of the marginal rays makes itself felt everywhere, and even in an increased degree, when the surface of the glass is turned obliquely towards the object. The retinal images of objects lying eccentrically in the field of vision are then not only distorted, but there also results simultaneously a concentric deficiency in the visual field. This defect is in very strong glasses not uncommonly so considerable, that it renders the locomotion of the patient somewhat difficult, and its external limit advances so much the nearer to the point of fixation by otherwise similar diameter of the pupil, by similar refractive value of the glass and similar distance of the latter from the plane of the pupil, the smaller the aperture of the glass is (*Berlin*). Hence arises the necessity of giving to strong convex glasses as large an opening as possible, and of making its position perpendicular to the visual line.

Many believe that these defects may to some extent be avoided by using glasses which are ground periscopically, and by magnifying essentially the visual field. So much is certain, that opera glasses render excellent service to many strong hypermetropes, and increase very considerably the central acuteness of vision in comparison to that attained by biconvex lenses. Where it is a question of enlargement of the retinal images, they may often prove very valuable.

Just as in a high degree of myopia, so in very high degrees of hypermetropia, the commercial opera-glasses are often unsuitable for distant vision. For the necessary correction the patient must at the same time use his glasses, or else diminish the refractive value of the ocular by that of his glasses used for distant vision.

3. When both eyes are hypermetropic in a different degree, or when, with the same degree of hypermetropia, they have a different range of accommodation, each eye must be corrected by a corresponding glass. If one eye is myopic, and its range of accommodation is not very much diminished, while the other is hypermetropic and needs a correcting glass, it is often well to grind merely the suitable glass for the opening in the spectacle frame corresponding to the hypermetropic eye, but to leave the other opening free. Great differences in the refractive value of both glasses often make it impossible to correct the refraction of both eyes, on account of the unequal magnifying of the retinal images. In such a case there is nothing to do but to content ourselves with the complete correction of that eye which is used by preference for a definite distance, and to undertake the correction of the second eye only so far as the circumstances admit of it. When no binocular visual act exists, there is, of course, no necessity for different glasses.

The incompatibility of considerable differences in the size of the retinal images of both eyes does not admit of the neutralization of the error of refraction when the lens has been lost on one side, so long as the other eye can still be used for distinct vision.

4. Convex glasses also are best fastened in *spectacle-frames*. In low grades of hypermetropia, where very great focal lengths are sufficient, an eye-glass may, it is true, be used without harm, as here the distance of the glass from the eye and the prismatic deviation are unimportant. In *high* grades of hypermetropia, where *strong* glasses are used, the two difficulties above mentioned are much felt. Hence it is of the greatest importance to fix the glasses in a certain position before the eye. This can only be done by spectacles. Here also, as a general rule, the glasses should stand as near as possible to the eye, and their axes correspond with the visual axes, or at least meet them at a very small angle.

In the use of very strong convex glasses a peculiar deception of the senses is sometimes very troublesome, by means of which hollow objects appear convex, and vice versâ. This phenomenon is a consequence of the prismatic deviation, and, therefore, appears most prominently when the nose-band of the spectacle-frame is too short or too long, so that mainly those rays reach the pupils of both eyes which have passed through the inner and outer halves of both glasses. (*Zehender.*) The union of two bundles of homocentric light then follows upon separate portions of the retina, and causes the binocular image of the object in question to be removed from the center of the visual space.

5. Of course, as the hypermetropia increases (as it usually does in old age), glasses of shorter focus must be chosen from time to time. But if, in far-advanced senile involution, sharpness of vision also decreases considerably, spectacles will often be insufficient; strong "reading glasses" will be required. (*Graefe.*) Generally, they can only be used for monocular vision (*Donders.*) and in high degrees of absolute hypermetropia they must be used with proper spectacles.

Authorities.—*Janin*, Abhandlgn. u. Beobacht. Aus dem Franz. von Selle. Berlin. 1788. S. 373.—*Stellwag*, Sitzungsbericte der Wien. k. Akad. der Wiss. XVI. 1853. S. 232 et seq. Ophth. II. S. 360-379.—*Donders*, A. f. O. IV. 1. S. 319, 323-329; VI. 1. S. 73 et seq. VI. 2. S. 210, 228, 231; VII. 1. S. 155, 162, 167; IX. 1. S. 99 et seq.; Anomalien der Refr. u. Acc. Wien. 1866. S. 74 et seq.—*Ed. Jaeger*. Einstellungen des dioptr. Apparates Wien. 1861. S. 20 et seq.—*Hasner*, kl. Vorträge, Prag. 1860. S. 99-104, 226.—*Graefe*, A. f. O. II. 1. S. 160 et seq. kl. Monatbl. 1865, S. 343, 345, 392. —*Colemann*, deutsche Klinik, 1865, Nr. 23.—*E. Hering*, verbal communications.—*Schuerman*, vijfde Jaarlijhsch, Verslag, Utrecht. 1864. S. 1.; kl. Monatbl. 1864. S. 92, 100.—*Cramer*, Het accommodatie-vermogen. Haarlem. 1853, S. 118 et seq.—*Schweigger*, Vorlesgn. über den Gebrauch des Augenspiegels, Berlin. 1864, S. 58.—*Haas*, Derde Jaarlijhsch, Verslag, Utrecht. 1862, S. 137.—*Nagel*, A. f. O. XII. 1. S. 25.—*Giraud-Teulon*, Congress intern. d'ophth. 1863, P. 104.—*Gerold*, A. f. O. XII. 1. S. 31.—*O. Becker*, kl. Monatbl. 1866, S. 54-56.—*Burow*, ein neues optometer, Berlin, 1863, S. 12 et seq.—*Haase*, Pagenstecher kl. Beobacht. III. Wiesbaden, 1866. S. 109.—*Schweigger*, Göttinger Nachrichten. 1870. Nr. 9. kl. Monatbl. 1867. S. 30.—*Berlin*, ibid. 1869. S. 1, 361.—*Zehender*, kl. Monatbl. 1868. S. 137.—*Dobrowolski*, ibid. Beil. S. 94, 97, 104, 106, 114-118, 175.—*Liebreich*, A. f. O. VIII. 1. S. 269.—*Kaiser*, ibid. XIII. 2. S. 352.—*Mooren*, Ophth. Beob. S. 327.—*Coccius*, Der Mechan. d. Acc. S. 54, 64, 77.—*H. Cohn*, Untersuchungen der Augen von 10060 Schulkindern. 1867. S. 138 u. f. *Reuss*, *Winow*, Ophth. Studien. Wien. 1869. S. 1.—Mauthner, Lehrb. d. Ophthscop. Wien. 1868. S. 160, 177, 185, 190.

3. Abnormal Regular Astigmatism.

Symptoms.—*This affection is characterized by a decided difference of refraction, in the different meridional planes of the dioptric apparatus, and a consequent diminution of sharpness in vision.*

1. The disturbance of vision is a necessary symptom, for that distinguishes abnormal from normal astigmatism, which exists in almost all eyes. Much larger visual angles, than usual, are required in distant as well as in near vision, to give moderate distinctness; occasionally this even goes so far as to make us suspect the existence of amblyopia.

Moreover, with equal want of symmetry of the meridian, the diminution of sharpness of vision is not always the same; dilatation of the pupil increases, while contraction often conceals one of it. Persons who employ themselves mostly with large objects often do not notice even high grades of astigmatism; but in reading, writing, and particularly in fine work, even slight degrees are very annoying and require correction.

If the natural refractive state is at the same time myopic or hypermetropic, the sharpness of vision may be considerably increased by suitable concave or convex glasses, but it always remains much less than that of normal eyes. In such cases, the maximum of correction is not limited to one glass, but the focus may vary within certain limits, without materially increasing or diminishing the clearness; this is explained by the relative length of the focal distance (*brennstrecke*). (*Knapp, Donders.*) Some patients find from their own observation, that by placing their glasses *obliquely*, they increase their usefulness.

For, under these circumstances, only those rays enter the pupil which have passed through the axis of the glass. On account of the size of their angle of incidence, the remaining rays are partly reflected, partly so much deviated that they do not greatly impair the distinctness of the other images. Thus, in *one* meridian, the correction is great, while in the other meridians the rays are partly arrested; the obliqely placed glass to some extent answers the purpose of a stenopäic fissure.

Horizontal and vertical lines, as well as objects that lie principally in these directions, are most distinctly seen when the head is held in a certain upright or oblique position. (*Knapp, Donders.*)

Not a few astigmatics have themselves noticed this difference, and, in describing their condition, speak particularly of it. Others, without knowing it, have learned empirically to overcome the difference by placing the head or the object in a certain position. For instance, in reading or writing, they place the paper so that, instead of being horizontal, the lines are vertical or very oblique. Some persons, after much practice, are thus enabled so much to overcome high grades of regular astigmatism as to be able to do even the finest work. (*Javal.*)

In high grades of astigmatism, there is also chromatic aberration. The image of dispersion of a bright point or other object, sometimes appears surrounded by variously-colored borders, whose arrangement differs according to the distance of

bject and the refraction of the eye, and hence may be modified within certain , by placing different positive or negative glasses before the eye.

ese phenomena are most marked when, during the examination, instead of white light, we employ such as is composed of only two prismatic colors, of eatest possible difference of refraction; that is, if we pass sunlight through violet, or lamplight through dark cobalt, glasses.

hen a person with astigmatism regards a bright point through such glasses, if e is myopic the point will appear red, with a blue border; if it is hyperme-, it will seem blue, with red edges. If the patient sees the point sharply and —that is, if the *middle* of the focal line fall on the retina—the upper and lower appear blue, the sides red; the eye is relatively myopic in the vertical, hyper-pic in the horizontal, meridian. But if the point is drawn out to a *line*—that focal line fall on the retina—the ends and middle of the line are of different , and the colors change on varying the direction of the line by a modifying (*Donders.*)

Regular astigmatism may be objectively determined by ophthalmometric ements, but only so far as it affects the cornea. As in practice the total t of astigmatism always determines the mode of operation, and these mea-nts, moreover, render necessary very costly and complicated instruments *oltz*), the methods here referred to are less suited to general use. The oph-scope, however, gives us excellent aid in recognizing high grades of astig- and the direction of the chief meridians; for the optic papilla appears ed, first in one, then in the other chief meridian, according as the fundus is ed in the upright or reverse image. (*Knapp, Schweigger.*) The unequal re-n of the different meridional planes is still more evident, on examining the of the fundus; for then we only see clearly the vessels running in one direc-o distinctly see the others, especially those perpendicular to the first, the ing eye must change its accommodation. These symptoms change according ye is examined in the upright or reverse image. (*Donders.*)

differences are, as a rule, of course not very marked. Still they can be made more by removing the mirror with the correcting lens or the magnifying glass as far as pos-m the eye examined, since by such means the relative magnifying coefficients are very reased, relatively diminished. (*Mauthner.*) It is also well to dilate the pupil to its n, in order to be able at once to examine as large a part of the fundus as possible. In avoid being deceived, it is of great importance that the correcting lens of the mirror, the magnifying glass, should always be parallel to the plane of the pupil of the eye amination, in default of which, a perfectly analogous distortion of the image is artifi-duced. (*Schweigger.*) With great experience in making ophthalmoscopic examina-refraction of the two chief meridians may be obtained with some exactness, accord-es already mentioned. In some cases of very high degree, a doubling of the fundus observed. (*Graefe, Knapp.*)

grades of astigmatism sometimes betray themselves, also, by the peculiar the cornea; this appears *oval*, or the abnormal curvature of the different is may be perceived with the naked eye. More frequently, astigmatism be decided on from a peculiar distortion of the reflections, especially of a r of a circular object.

ie direction and refractive conditions of the chief meridians, hence also the the astigmatism, may be more easily and certainly determined by trials of iat is, subjectively.

sequently of the second, which, in regular astigmatism, is
Then, if, while the accommodation remains the same, the
be changed in some direction (usually decreased), the str
broader; it becomes an ellipse with decreasing excentricit
tance be continued, it becomes a round, blurred disc, agai
even a stripe again, whose axis is perpendicular to that of

Of course it does not alter the effect, if, instead of an act
rent, change of distance. If, while the object is in the sa
vertical, different glasses, positive or negative, as the case
find a lens through which the light point appears as a shar
axis is perpendicular to the former direction. (*Knapp*, *Do*

To gain as strong impressions as possible, for great distances we
a line to a line in diameter, made through the window-shutter of a d
in a metallic cylinder surrounding the flame of a lamp. The openi
by a piece of milk-glass, so that no direct rays of light may pass thr
ink-spot on a piece of paper is sufficient.

Tests of vision, with small slits cut in blackened metal
in deciding the presence and extent of astigmatism. If t
such a slit, pressed as closely as possible to the eye, by rota
a direction of the slit in which the sharpness of vision
another direction, perpendicular to this, in which the indis
mum. These two directions of the slit, if the head is erect,
of the two chief meridians; that is, of the two meridians i
the rays is greatest and least.

If the position of the two chief meridians has been dec
plicated, irregular astigmatism, easy to find for each of the
or positive spherical glass, which, brought immediately bef
directed slit, will increase the sharpness to the normal deg
distinct perceptions. (*Knapp*, *Donders*.)

The *length* of the slit is optional, but the width should not exce
slits are best which can be narrowed or widened by slides. As ob
suitable, but perpendicular and horizontal lines and bright points
any *irregular* astigmatism present, slits and spherical glasses will

Upon the other they are arranged in three rows one above the other. Each group is marked with the angle that it makes to a perpendicular when the table is placed vertically. If, while the head is held perpendicularly, the astigmatic eye regard this table from a distance of ten or fifteen feet, one or more groups usually appear more distinctly and blacker. If, however, the eye is very myopic or hypermetropic, suitable spherical lenses are required to render this difference very perceptible. In either case, if different spherical glasses be placed before the eye, as the focus increases or lessens, the distinctness and sharpness will grow greater or less, and we will, at last, find a glass through which some one group will appear perfectly black and sharply bordered; but beyond this we must not pass, or all the groups will lose in distinctness. The angle of inclination of the distinct group gives the direction of one chief meridian. If we now continue the examination and change the focus of the lens in the other direction, the formerly distinct group becomes less so, while another group, perpendicular to the first, becomes more distinct. A further increase or diminution of the focus causes all the groups to become less distinct.

The astigmatic tables of Dr. Pray are arranged according to exactly the same principle; still the lines of each direction form letters, whose hight and breadth exceed the test-types of Snellen No. 40 threefold, and which are so arranged, that every two formed by lines directed perpendicular to one another stand one above the other.

Very myopic patients, with diminished sharpness of vision, require the test-objects to be brought very near; hence the groups of test-lines should be made of smaller size.

In all these examinations, changes of accommodation are very disturbing, as they change the length and position of the focal line, and the relation of its chief parts to the sensitive layer of the retina. Where exact results are required, it is therefore necessary to paralyze the muscle of accommodation by atropine. The accompanying enlargement of the pupil is also advantageous, as it proportionately increases the diameter of the figures of dispersion, and consequently renders the symptoms of the astigmatism more marked.

If the astigmatic patient, with unweakened accommodation, views a light point with the naked eye, not unfrequently the light point appears at one time elongated in a certain direction, at another as a round disk. If the object stands exactly at such a distance that, with excessive strain of accommodation, the middle of the focal line falls on the retina, it may appear alternately elongated in two directions perpendicular to each other. Of course, these same fluctuations are also found in viewing *lines*. But this difference is particularly trying when the distances or glasses are to be decided on, which give the best vision for each of the two chief meridians.

We may readily convince ourselves of the disturbing influence of the accommodation in determining the amount of astigmatism by rendering ourselves astigmatic, by placing a cylindrical glass before the eye, and then undertaking the above experiments. Moreover, such trials are highly recommended; in fact, they are quite necessary for the proper study of this state of refraction.

If we have thus found the foci of the two spherical glasses, which cause clear perceptions of distant objects, in two chief meridians perpendicular to each other, we have the far points of the two chief meridians of the astigmatic eye; for these are equal to the focus of the glass *plus* its distance from the eye if it is a concave lens, *minus* this distance if it is convex. The reciprocal values of the distances of the far points express the refractive state of the corresponding meridional planes. The difference between these values gives the grade of the existing astigmatism. (*Knapp, Donders.*) The correctness of the value found, may be proved by trying cylindrical glasses. If the refraction of the chief meridian, nearest normal, has

This book is the property of
COOPER MEDICAL COLLEGE,
SAN FRANCISCO, CAL.
and is not to be removed from the
Library [illegible] by any person on

been equalized by a proper spherical glass, a cylindrical glass, whose refraction is the same as that of the astigmatism, and whose axis is parallel to the already-corrected chief meridian, should neutralize the error of refraction in the second principal meridian, so that the object will appear sharply defined in all directions.

Stokes' astigmatic lens answers the same purpose. This consists of two cylindrical glasses, one with a positive, the other with a negative, focus of ten inches. These glasses are fastened in metal rings, which fit on each other so that the lenses may be brought close together and rotated. If their axes are parallel, as is shown by marks on the outer edge of the framework, the refraction of the instrument will be 0. But it reaches a maximum $-\frac{1}{10}-(+\frac{1}{10})=\frac{1}{5}$ if the axes of the two lenses inclose an angle of 90°. For any other angle of the axes, α, the astigmatic deviation is $\frac{1}{5}$ sin. α. If the grade of the astigmatism and the position of the chief meridian be accurately determined in an eye, it is only necessary to adjust the instrument properly, and to place it in the right direction before the eye, to correct the error of refraction to emmetropia, or to a simple myopia or hypermetropia, and further to neutralize this by a suitable spherical glass. Inasmuch however, as the instruments correct both meridians equally, we must not, at the same time, use a spherical lens which exactly neutralizes the refraction of the meridian nearest normal, but employ one whose refraction is about the medium between that of the two principal meridians. (*Middleburg, Donders.*) Hence we see at once, that Stokes' lens is not a convenient means of originally determining the true adjustment of the two meridians; it only gives values from which the refractive states may be reckoned by a somewhat complicated calculation.

Suitably-arranged optometers may also be used to prove or determine the refractive states of the two chief meridians. The test-object used is a figure formed of delicate lines of equal length, arranged as radii of a circle. If this object be successively approached toward and withdrawn from the eye, by elongating or shortening the instrument, at one distance one line will appear distinctly, and at a second distance a line perpendicular to the first will be distinct. The two lines give the chief meridians, while their adjustment may be directly read off from the instrument. (*Burow.*) During this examination, it is difficult to avoid the action of the accommodation; if this is prevented by atropine, the rotation of the meridians accompanying the convergence of the visual axis interferes. And they are more annoying, if the same position of the visual plane be not maintained during the examination. Hence, the determination of the position of the meridians is very variable. Double optometers, on the plan of the stereoscope, have been constructed, in order to prevent the convergence of the visual axes, and thus fix the accommodation. (*Javal, Hirschberg*).

The ocular is a strong convex lens of large diameter, which admits of the virtual image of the object being brought into any distance from the eye desired, positive or negative, by slight movements of the object. A circle serves as object for every tube, in which the above described radiating figure is delineated. In order to avoid artificial illumination, which easily leads to erroneous results, the test-figure should be burned in black upon white porcelain, as by such means the experiment can be undertaken by transmitted light.

After the two figures have been blended, cylindrical glasses may be placed before the eye, and all the radii made to appear equally distinct.

From the focal length of the suitable cylindrical glass, the degree of astigmatism is then determined, and from the direction of the ray of the figure, seen clearly and distinctly without the cylindrical glass, the direction of the chief meridian is determined.

4. The distance of the near point is obtained in the same way as when the refraction is normal; but it is more difficult, and mistakes readily occur; for, in maximum accommodation, the pupil is very narrow, and the circles of dispersion are smaller. Continued examination is fatiguing. If we examine at different distances, the difference of convergence of the visual axes comes into consideration; we do not find the true, but the binocular near point (*Middleburg, Donders*), and the rotation of the meridians becomes marked. But if we use spherical glasses, while the distance of the object remains the same, other evils arise. But these points are

all useful; for they give the changes in the position of the chief meridians, and in the grade of the astigmatism that must be borne in mind while correcting the error of refraction for near vision. The cause of this is the *irregular* increase of curvature in some of the meridians of the lens. (*Middleburg, Donders, Dobrowolsky*).

5. The natural states of refraction of the two chief meridians vary excessively in different astigmatic eyes. Very often only one chief meridian is myopic or hypermetropic, while the refractive state of the other is normal. Such cases are spoken of as simple myopic or hypermetropic astigmatism. More frequently, however, both chief meridians are myopic or hypermetropic, but in different degrees; there is a *compound* myopic or hypermetropic astigmatism. Rarely one chief meridian is myopic, while the other is hypermetropic—a condition described as *mixed* astigmatism with myopia or hypermetropia predominant. (*Donders.*)

For the sake of simplicity, each of these different forms of astigmatism may be considered as composed of an ordinary normal myopia or hypermetropia, and a certain astigmatic deviation, which will be expressed by the different refractive states of the two chief meridians; in other words, it may be supposed that the eye, as a whole, is normal, myopic, or hypermetropic; but that in one chief meridian there is a certain maximal myopic or hypermetropic deviation of the refraction. On this hypothesis, we may have certain monogramatic expressions which show the special variety of the existing refractive anomaly, and are of great practical value, since, on the one hand, they render unnecessary extensive descriptions, and, on the other, show at once the refractive power of the spectacles necessary to a correction of the entire error of refraction.

In *simple* astigmatism, if the one chief meridian is normal—that is, if its refraction is $\frac{1}{\infty}$, while the other is myopic, or hypermetropic—that is, its refraction is M $\frac{1}{a}$ or H $\frac{1}{a}$, the refractive anomaly appears combined of normal vision = E = $\frac{1}{\infty}$ = 0, and an astigmatic deviation of Am or Ah, = $\frac{1}{\infty} - \frac{1}{a} = \frac{1}{a}$; the expression, therefore, would be Am (Ah) $\frac{1}{a}$.

Compound astigmatism may be divided into simple myopia or hypermetropia, and astigmatic variation; the expression then would be M $\frac{1}{m}$ + Am $\frac{1}{n}$, or H $\frac{1}{a}$ + Ah $\frac{1}{n}$. If, for example, the refractive condition in one meridian were M $\frac{1}{20}$, in the other M $\frac{1}{10}$, the expression would be M $\frac{1}{20}$ + M ($\frac{1}{10} - \frac{1}{20}$) = M $\frac{1}{20}$ + Am $\frac{1}{20}$.

Mixed astigmatism appears to be combined of a simple myopia or hypermetropia, and an astigmatic deviation of the opposite sort; the expression, then, is M $\frac{1}{a}$ + Ah $\frac{1}{n}$, or H $\frac{1}{a}$ + Am $\frac{1}{n}$. The astigmatic deviation, Ah or Am, is here reached by *adding* the refractive state, because the distance of the far point in hypermetropia, opposed to that of myopia, has a *negative* value. If, for instance, there were in one chief meridian M $\frac{1}{24}$, in the other, H $\frac{1}{12}$, the expression for the astigmatic deviation would be Ah = $\frac{1}{24} - (-\frac{1}{12}) = \frac{1}{8}$. The anomaly of refraction would then have to be designated M $\frac{1}{24}$ + Ah $\frac{1}{8}$. (*Donders.*)

Cause and Course.—Astigmatism is by no means a rare affection, but is found in about 0.2% of all children, and in 1.3% of ametropic children. (*H. Cohn.*) Astigmatism, or at least the predisposition to it, is *congenital*, but it may develop late in life as a result of various morbid processes.

1. Congenital astigmatism generally depends on asymmetry of the meridians of the cornea; but occasionally cases are met with that depend mostly on anomalies of the curvature of the crystaline, or even on flaws in its surfaces. (*Knapp.*) The asymmetry shows itself to be hereditary by occurring in several members of the same family. It appears more frequently in men than women. It is generally binocular, and then not always of the same grade in both eyes. Sometimes, however, it is confined to *one* eye, and may then attain a high development, and resemble amblyopia. It is worthy of remark that, with such differences of form of the two

eyes, there is not unfrequently a striking asymmetry in part of the face, especially of the bones of the orbit.

Like bathymorphia and plathymorphia, with whic bined, the disturbance of vision is occasionally first n childhood. As long as the accommodation is still very and in slight asymmetry of the meridians it is even overl age, the accommodation gradually decreases, even low tism are perceived in the most unpleasant manner, and to asthenopia, as the patients, for sharp vision, are oblig than suits the general adaptation of the eye. If a h present in one eye only, the result is not rarely the amblyopia from disuse or strabismus (*Javal*), just as in of vision.

In advanced age, astigmatism is readily hidden by but otherwise it is not much changed. (*Donders.*)

2. Astigmatism is *developed* by disease in the cornea very irregular, and does not come under the present hea luxation of the lens are sometimes causes of regular ast

The usual cause of acquired astigmatism is the e astigmatic difference found after such an operation vari more. It is according to its degree especially depen exact healing of the wound, and therefore is usually prolapsus iridis has accurred. With the subsequent co astigmatic difference as a rule diminishes, but without The meridian of greatest curvature is in the majority commonly oblique, only very exceptionally vertical. T fore, are reversed by the operation. Moreover, the met greatest influence upon the kind and degree of the extraction the astigmatic difference appears in general ular astigmatism more frequently occurs than after the e linear incision. Prolapse of the iris is also in both ope it induces very great irregularities in the asymmetry. (*I*

Treatment.—This depends on the same principle requires similar means, as the previously described ano

1. This is especially true of the general rules of pro carefully followed, when the astigmatism is accompani tion of the eye, which, in high grades of asymmetry, astigmatic disturbance of vision increases the danger hypermetropia, and, therefore, double care is required.

2. The chief aim is evidently to render the refractio astigmatic eye emmetropic, and to render it possible for distinctly at any distance whatever with the normal am

In order to understand this object perfectly clearly, of refraction into two parts, namely, into the astigmat matic difference. Under the astigmatic basis we may c main meridian, *i. e.*, that of the meridian nearest emm any meridian whatever may then be denoted as the sum

of the product of the astigmatic difference and of the sine of the angle which the meridian in question encloses with the main meridian. Since this astigmatic basis is a portion of the refraction of any one meridian, and therefore must be equalized in every meridian, its correction requires a spherical glass, which is positive if the astigmatic basis is negative and *vice versâ*. The same laws hold good for the choice of the refractive value of this spherical lens, which are in force in the correction of a simple myopia and hypermetropia with and without limitation of accommodation. When the correction should be complete, the refractive value of the spherical glass will be equal in amount to the astigmatic basis, but of a reverse sign; or if we take into account the necessary distance of the glass from the optical centre of the eye, the correction will require a spherical lens, whose positive or negative refractive value is equal to the reciprocal value of the distance of the far-point of the main meridian, increased or relatively diminished by the distance of the glass from the eye. Just as in simple myopia and hypermetropia however, insurmountable difficulties to full correction often appear even in their combination with astigmatism, and we must content ourselves with simply *approximating* the refraction to zero, at the same time taking into account the limitations of accommodation, and also often employing different glasses for different distances. A detailed description of these laws would merely be a repetition of what has been already said in the chapters on myopia and hypermetropia.

The correction of the astigmatic difference, which yet remains, should under all circumstances be complete. It requires naturally a glass, whose refractive value in one meridian is zero, but in the meridian perpendicular to this is the same as the astigmatic difference, but of the reverse sign. To these requisitions correspond positive and negative cylindrical glasses, whose axis is placed in the main meridian already corrected to emmetropia by the spherical glass. If we had a simple astigmatism, the necessary refractive value of the spherical lens would naturally be zero, and therefore a simple cylindrical glass would suffice, whose refractive value is the same as the astigmatic difference, but of the reverse sign.

In compound myopic or hypermetropic astigmatism, a spherical glass is needed, which corrects the astigmatic basis, so far as from the conditions it appears advantageous, and a cylindrical glass, which brings the astigmatic difference to zero.

The refractive values of both glasses are summed up by turning away from the reciprocal distance of their centres. Since two glasses reflect a good deal of light from their four surfaces and consequently limit the acuteness of vision, and moreover since they become troublesome by their weight, it is necessary to concentrate the cylindrical and spherical curvature, each to one surface of a single glass. Now the refractive value of each surface of curvature of the glass, whose refractive exponent n is assumed equal to 1·5, is $\frac{1}{r}=\frac{n-1}{r}=\frac{0.5}{r}$, therefore $r=\frac{p}{2}$, in which r signifies the necessary radius of the dividing surface in question. If therefore 10″ were the desired focal length of the spherical and cylindrical surface, then there should be given to each of them a curvature of 5″ radius or 10″ diameter.

In mixed astigmatism the combination of a spherical and a cylindrical surface in the correcting glass is only of advantage, when the refraction of one of the chief meridians is not much removed from zero, and thus the astigmatic difference is proportionally slight. When both chief meridians are in their refraction far removed from emmetropia and hence the astigmatic difference is also very considerable, the cylindrical surface in relation to the spherical and even absolutely would be forced to receive a very great positive or negative curvature, which, as in spherical glasses

is disadvantageous even in a higher degree. It therefore seems better in such cases to divide the correction of the astigmatic difference between both surfaces of the glass, and therefore correct each individual meridian by itself to emmetropia, *i.e.* to give to both surfaces of the glass a cylindrical curvature, whose refractive value is equal in degree to the refraction of the corresponding chief meridian, but of an opposite sign. The axes of both cylindrical surfaces must then naturally stand perpendicularly to each other and must be placed in such a manner before the eye, that the axis of the negative cylindrical curvature falls in the hypermetropic chief meridian and *vice versâ*.

There is considerable difficulty in correcting astigmatism in the change of the astigmatic difference, at different states of accommodation, and in the variations which the position of the chief meridians undergo in the various positions of convergence of the visual lines, and particularly in changes of situation of the visual plane. Hence it is evident, that one and the same astigmatic glass cannot always be used with equal advantage for great distances, and at the same time also for distances of ordinary occupation, especially when the asymmetry is considerable; and that we are often rather compelled to give different curvatures to the glasses for the distance and for near work, and a different position to the axis of the cylindrical surface.

Still, with all these precautions we very often fail in giving to the eye the complete normal acuteness of vision. Without regard to the imperfections of every glass, and setting aside any defects in function of the retina which may often be connected with high degrees of asymmetry, the circumstance forces itself upon us that great astigmatic differences occur but seldom without considerable irregularities in the curvature of the cornea, and particularly of the lens.

Irregular astigmatism can never be more than partially corrected, *i.e.*, in so far as it can be referred to a regular asymmetry of the meridians.

Of course, in the displacement of the pupil we have a means of diminishing very considerably the irregular portion of the astigmatism, especially in pathological faulty curvatures of the cornea, by shutting off those portions of the cornea which are most distorted, and thus the cylindrical glasses may be made to complete the correction. Still, this operation has its dangers, and its performance appears sometimes very hazardous.

The deficiencies which generally pertain to glasses, and especially the differences in the size of the retinal images which the necessary distance of the glass from the optical center naturally brings with it, and which in cylindrical glasses are plainly different in the different meridians, cause us to regard the employment of astigmatic glasses as not worthy of recommendation, when one eye is emmetropic, or at least ametropic in no disturbing degree, and only the other is abnormally astigmatic.

Where, on the contrary, both eyes are astigmatic, even if to a different extent, or where, with binocular myopia or hypermetropia, which requires correction, one eye is also astigmatic, it seems absolutely necessary to use cylindrical glasses to prevent injuries that will probably arise from the disturbance of vision. It is impossible to say, absolutely, whether in different grades of astigmatism, especially when the difference is great, the correcting glass suited to *each* eye should be used or not. Some patients cannot bear this at all, others only to a certain point; while others, again, find it very comfortable (*Javal*).

In a word, in the use of cylindrical glasses the same rules are to be followed as

in the use of spherical concave and convex lenses, and the rules given under simple myopia and hypermetropia should be the more carefully followed in astigmatism, as cylindrical glasses afford a much less complete means of correction than spherical.

Of course, the glasses should always be retained in their correct position; hence, only spectacles with spring clasps should be used. This immobility of the spectacles is also important as regards the distance of the glass from the eye, since, with concave and also with strong convex glasses, this distance greatly influences the size of the image, which, moreover, increases and diminishes in a different proportion in each meridian of the cylindrical surface, and therefore necessarily causes blurring. It is very necessary to diminish this blurring as much as possible, that is, to keep the glasses very near to the eye.

In the same connection we may mention the necessity, where both surfaces of the glass are convex or concave, of always placing the greatest curve next to the eye, that is, posteriorly; but when one surface is convex and the other concave, to turn the latter toward the eye. It is an equally important rule to keep the glasses parallel to the plane of the pupil.

Authorities.—*Gerson*, *E. G. Fischer*, kl. Monatbl. 1866. S. 58, A. f. O. XII. 1. S. 27.—*Airy*, nach Mackenzie, Traité d. mal. d. yeux. Traduit par Warlomont et Testelin. II. Paris. 1857. P. 652.—*Knapp*, A. f. O. VIII. 2. S. 185 et seq.; Congress intern. d'ophth. Paris. 1863. P. 42.—*Donders*, A. f. O. VII. 1. S. 176, 194, 200; Astigmatismus und cylind. Gläser. Berlin. 1862. S. 30. et seq. Anomalien der Refrac. und Accom. Wien. 1866. S. 379. et seq.—*Middleburg*, Vierde Jaarl. Verslag. Utrecht. 1863. S. 149, 175, 187. A. f. O. X. 2. S. 96, 105; kl. Monatbl. 1863. S. 496, 1864. S. 245.—*Schweigger*, A. f. O. IX. 1. S. 178 et seq. Ueber den Gebrauch des Augenspiegels. Berlin. 1864. S. 60.—*Javal*, kl. Monatbl. 1865. S. 336 et seq.—*Hirschmann*, ibid. S. 341.—*Graefe*, ibid. S. 342; A. f. O. I. 1. S. 341.—*Burow*, A. f. O. IX. 2. S. 228, 230; ein neues Optometer. Berlin. 1863. S. 34.—*Kugel*, A. f. O. X. 1. S. 89. XI. 1. S. 106.—*Tetzer*, Wien. med. Jahrb. 1868. 6. S. 145.—*Haase*, Pagenstecher, kl. Beobachtgn. III. Wiesbaden. 1866. S. 113.—*Javal*, kl. Monatbl. 1868. S. 372; Ann. d'oc. 53. Bd. S. 50.—*Snellen*, A. f. O. XV. 2. S. 199, 206.—*Dobrowolsky*, ibid. XIV. 3. S. 51. u. f.; kl. Monatbl. 1868. Beil. S. 146, 153, 157.—*Reuss*, *Woinow*, Ophth. Studien. Wien. 1869. S. 4—6, 12—15, 20.—*Pray*, Archiv. f. Augen- u. Ohrenhlkde. I. S. 147; Astigmatismustafeln. Herausgeg. von Heymann. Leipzig. 1870.—*Mauthner*, Lehrb. d. Ophthscop. 1868. S. 199.—*H. Cohn*, Untersuchung. v. 10,060 Schulkindern. Leipzig. 1867. S. 151.

4. Asthenopia.

Symptoms.—*By asthenopia we understand the inability of maintaining the adjustment of the dioptric apparatus for short distances for a length of time, and the hyperæsthesia of the retina and ciliary nerves accompanying this inability.*

1. The cause of the disease is sometimes an absolute or a relative deficiency of energy in the muscle of accommodation.

When we speak of deficiency of energy, it is well to distinguish between the *actual* energy, which the muscle requires to enable it to contract to a certain extent, and the *potential* energy required to maintain this state of contraction. For, in proportion as the elastic expansion of the fatigued muscle gives way, its contractions must gradually increase so as to overcome the mechanical elongation. And thus the muscle must be completely exhausted. (*Donders.*)

This disease is characterized by the rapid exhaustion of the muscle of accommodation, when sharp images on the retina are required of objects which, on account of their smallness, must be approached to the eye. While the fatigued muscle gives out and gradually relaxes, of course the convexity of the lens correspondingly diminishes. Although its position is unchanged, the object is seen in increasing circles of dispersion, and with increased exertion, it is often also smaller. The patient is consequently obliged to remove the object more and more from the eye; consequently the size of the retinal images is diminished, and the clearness of perception injured, and thus the work of the retina is increased; hence the desire for enlarged retinal images is soon felt, and the patient feels obliged to bring the object nearer the eye. But the improvement does not last long, the accommodation soon tires again, the object must again be removed from the eye, and so it goes on, the intervals between the changes of distance constantly becoming shorter, till finally the retina becomes fatigued by the steady contest with indistinct and small images, and, like the muscle, does not do its work, and thenceforth objects seem to swim before the eyes. The eyes then require long rest before they are in condition to resume their activity for short distances. Furthermore, the functional stamina has much decreased; in a very short time the above-mentioned symptoms recur, while simultaneously symptoms of vascular and nervous irritation appear, which constantly increase with continued forcible straining. These first announce themselves by a feeling of pressure and fullness in the eye, with a peculiar tension in the forehead. If the work is continued these feelings soon increase to actual pain in and over the eyes, and are soon accompanied by a very painful feeling of dazzling; finally headache, dizziness, universal *malaise*, and even nausea, occur. Besides these there is almost always strong contraction of the pupil, marked injection of the conjunctiva and episclera, as well as excessive lachrymation.

This hyperæmia is not uncommonly a very prominent symptom, and later in the disease is combined very commonly with more or less abundant secretion of muco-purulent matter, simulating a simple catarrh. This condition frequently resists all remedies, if the overburdening of the apparatus of accommodation is not done away with by relinquishing the work or by correcting-glasses. In consideration of

this fact, therefore, we should always examine for defects of refraction or accommodation in cases where a conjunctival catarrh has appeared without any existing external cause, and has lasted for some time. We shall thus avoid many errors in diagnosis, and also frequently a disagreeable failure in treatment.

Causes.—The immediate cause is always overburdening of the muscle of accommodation, or of the internal recti, as the case may be. But the trouble does not commence equally soon in all persons, even under the same circumstances. The power of the muscles in question varies greatly in different persons, and in some it is far below the normal amount. (*Graefe.*) Frequently, such insufficiencies are congenital, or even hereditary; hence, under otherwise similar circumstances, asthenopia affects an unproportionately large number of the members of some families, while it never occurs in others (*Graefe*); but just as often they are acquired, and then they result from exhausting diseases, anæmia, &c. Indeed, under such circumstances, asthenopia almost always occurs, if the patient strains his eyes too soon. But the disease soon passes off, as the muscles grow stronger during convalescence. Finally, one very important cause is, that the amount of work which the same employment requires of these muscles varies in different cases, as the refractive state of the eye, and the opposition to the shortening of the muscles, have great influence.

Of course, in hypermetropic eyes, the muscle of accommodation must be strained to adjust for short distances. Hence, hypermetropes furnish by far the greater number of the cases of accommodative asthenopia. Indeed, some assert that, when it occurs *pure*, it is always associated with hypermetropia. (*Donders.*) This affection is most frequently developed after the twenty-fifth year, because, as the density of the lens increases, its resistance to the accommodative changes of form increases also. Where the difficulty of refraction is greater, the asthenopia occurs much sooner, even before puberty.

In general, we may say that the asthenopia comes on earlier, the higher the grade of the hypermetropia. We can not, however, accept the rule that has been given, that the year of life in which the asthenopia appears, nearly corresponds to the denominator of the fraction that expresses the hypermetropia. (*Donders.*) The exceptions to this rule are so numerous and striking, that it must be accepted with reservation. Indeed, we not unfrequently meet cases where hypermetropes of $\frac{1}{14}$, $\frac{1}{20}$, $\frac{1}{18}$, and in one case of $\frac{1}{8}$, did not use spectacles till the fiftieth year, or later, on account of commencing weariness of the eyes; although they had previously read, written, &c. Various circumstances coöperate in causing asthenopia; or, perhaps, the hypermetropia developed late in life from increased density of the lens, has relatively increased in such cases.

In emmetropes and myopes, accommodative asthenopia rarely occurs, for few occupations require such an approach of the object to the eye as to overburden the muscle of adaptation. But such eyes are not perfectly safe when there is muscular insufficiency; it only requires unfavorable circumstances to excite the affection. In this respect, wearing *too strong* concave glasses in myopia, and the use of spectacles for distances where they are not required, is a frequent cause.

Where there is deficient energy of the muscle of accommodation, among the circumstances that lead to asthenopia are: working with small objects, fine embroidery, sewing, painting, reading small or bad printing or writing, especially when, to make out the true meaning, it is necessary distinctly to see fine lines, by which the different letters are distinguished, and the habit of read-

ing in circles of dispersion, becomes insufficient. Indistinct contours, dull colors, slight contrasts with the background, deficient illumination, and any thing else that affects the distinctness of the retinal images, and renders a nearer approach of the object necessary (hence, particularly, abnormal astigmatism) (*Pagenstecher*, *Dobrowolsky*,) of course increases the strain on these muscles, and hastens their fatigue, and consequently favors the occurrence of asthenopia. Continuous rapid changes of the distance for which the eye must adjust, as in comparing different copies of long rows of figures, &c., is also a frequent cause. And here the *actual* energy of the ciliary muscle comes into play.

It is not, however, always an over-amount of work which calls forth asthenopic troubles, for sudden and powerful disturbances in the inherent coördinal relations are frequently the chief or only cause. Such a disturbance occurs when during the ordinary occupations the glasses hitherto employed are suddenly laid aside, or when the eye, hitherto unprovided with glasses, is furnished with a glass which corrects the error of refraction and the limitation of accommodation completely, or even over-corrects them.

In other cases the asthenopia is caused: by changing the glasses ordinarily employed for much stronger or weaker ones, no matter whether the former or the latter are suitable for the special case; by an incorrect position of the glasses in relation to the eye; by faulty employment of the glasses, etc. At least it only needs under such circumstances the occurrence of external unfavorable conditions to turn occupations, which require a continuous vision at short distances, into a source of asthenopia.

Course and Results.—At first, all the symptoms of the disease only appear when the affected muscles are subjected to unaccustomed or excessive straining. Then the intensity of the symptoms is in proportion to the extent and duration of the work that the muscles have to perform. With continued forced work, however, the nervous symptoms soon become permanent, the patient constantly suffers from the sensation of dazzling, and even slight use of the eye, as in distant vision, suffices to excite severe pain in and around the eye. The asthenopia acquires more and more the character of *retino-ciliary hyperæsthesia.*

Asthenopia can be cured. This we may expect with the greatest certainty in those cases, in which it is not so much a real lack of energy that is the cause of the affection, as rather an absolute or relative over-amount of service demanded. The prognosis is equally unfavorable in those cases in which diseases which weaken the general system have lessened the power of work of the muscles under consideration, and in connection with over-burdening have laid the foundation for asthenopia. With sufficient care, the parts usually soon recover sufficiently for the eye to do a moderate amount of work. It not unfrequently happens, however, that subsequently a certain degree of insufficiency remains, and later, every indiscretion is accompanied by a return of the asthenopic difficulties. Where a certain deficiency of energy is the cause of the development of the asthenopia, the eye *never returns* to normal duration of function; throughout life it requires certain helps, which, in ordinary occupations, diminish the amount of its work to the existing power.

Treatment.—The first and most important indication is to arrest the progress of the disease. If the immediate causes of the overburdening of the muscles are correctly understood, this is not very difficult in the majority of cases, provided that the patient presents himself to the surgeon as soon as the symptoms of diminished

duration of function begin to evince themselves, and that he is in condition to leave off the occupations causing the affection.

Frequently, improving the circumstances under which work is conducted suffices to increase the functional duration to the normal amount. Thus it will often be necessary to arrange the position of the patient in regard to the source of light—the window, for instance; where the illumination is insufficient, to increase it to the proper amount by strengthening the artificial source of light, or by the choice of a more suitable location.

In other cases, the object is improperly placed as regards the eye; it is too high, too low, or lateral, as occurs in reading in bed, &c., and hence must be altered, &c., &c.

But if the cause of the overburdening (as is the rule) depends on inadequate power of the muscle of accommodation, in its incapability to produce and maintain the requisite amount of accommodation, whether the fault lies in a real weakness of the muscle, or in the resistance which the muscle meets with, or, finally, in the refraction of the eye, it is very necessary to order *suitable glasses.*

The rules for their choice have already been mentioned in the previous sections. When disturbances of the natural co-ordinate relations are the proximate cause for asthenopia, it will more frequently be necessary to combine the correcting glasses with prisms according to necessity, so much the more as in the hyperæsthesia of the parts already developed, every confusion of the co-ordinate relations, even the most trifling, is usually absolutely unbearable.

Where the asthenopia is accompanied by great ciliary or retinal hyperæsthesia, it has been advised to give a blue tint to the correcting spherical glasses or prisms. (*Böhm, Graefe.*) But it is doubtful whether this is of any use. At first every attempt to employ the eyes for continuous near vision only for a time is generally interdicted, and is each time followed by unbearable increase of the extremely painful affection; even under the most favorable circumstances the patient is absolutely incapable of doing anything requiring *near* vision. The chief indication, then, is to first remove the state of nervous active excitability. This is to be done by taking great care of the eye, and avoiding all exercise of it. Great benefit is ascribed to the methodical use of atropine, and the complete relaxation of the muscle of accommodation that it causes. (*Donders.*) When the sensitiveness of the retina and ciliary nerves has been diminished, it is time to commence attempts at vision, with completely correcting glasses. At first these attempts must only last a short time, and be resumed after long intervals. But in proportion as the power of the eye increases, so should the frequency and duration of the trials increase, till we attain our end.

[Under the belief that in asthenopia there was often a discrepancy between the power of the ciliary muscles and the angle of convergence, it was concluded that there was—

"1*st.* Some disturbance of the relative accommodation.

"2*d.* There seemed to be a want of tone or power of the ciliary muscle for continued action.

"3*d.* Want of mental energy, the patient having lost confidence in his power to use his eyes."

The first difficulty is overcome by giving glasses, to change the relation of the accommodation to the angle of convergence of the optic axes.

Secondly, the tone of the muscle is increased by a regular course of gymnastic exercises.

The patient is to commence using the eyes with the chosen glasses; he is to read for from three to fifteen minutes, three times daily, from a book, with good clear type. The duration of this exercise is to be daily increased, by additions of one minute to each period—taking care, however, not to cause fatigue.

Thirdly, the above "course of treatment serves to distract the mind of the patient, and restores his confidence in his ability to use his eyes." (*E. Dyer.*)

It would be superfluous to enter into detail in regard to a method which has been so fully laid down by its originator, but agreeing, to a great extent, with Dr. Dyer, both as to the nature and the seat of the disease, and having become thoroughly convinced, in many cases, of the efficacy of the treatment proposed, I have been led to look into the matter for the purpose of explaining, if possible, the manner in which this benefit is effected. In order to do this, we must first take into consideration the nature of the part to which the remedy is to be applied, and as this is in the present case what is known as the relative accommodation, it is to this that our attention will be chiefly confined.

In emmetropic or normal eyes, there is a certain relation between the accommodation and convergence of the visual axes, so that a certain amount of the former corresponds to a given amount of the latter. Now, although this amount of accommodation is definite, it is by no means absolute, as is proved by the fact, that, with a fixed degree of convergence, the accommodation can be modified and yet distinct vision remain undisturbed. To prove this, let a small object (fine print) be placed at the distance of twelve inches from the eye. This particular degree of convergence is here chosen on account of simplicity, and because with it we obtain a greater amount of relative accommodation than with any other, while, at the same time, it is the average distance at which the object is held for near work. As the visual axes are converged upon the object, and as the accommodation is adjusted for the above distance, vision is acute. Now, the strongest *convex* glass, through which the object still remains distinct, will show the amount which the accommodation can be relaxed. This is known as the negative portion of the relative accommodation, and represents the amount of relaxation of which the ciliary muscle is capable, with this definite amount of convergence. On the other hand, the strongest *concave* glass through which the object still remains distinct, will show the amount of accommodation which can be brought forth by increased tension, or muscular effort, on the part of the ciliary muscle. This is known as the positive portion. The negative portion represents, then, the amount of muscular force actually used with a given convergence, in order to render vision distinct; the positive, that which is held in reserve. The positive ought to predominate over the negative in the proportion of 3 to 2.

"*The distinction here made,*" says Donders, "*already acquires practical importance, from the fact that accommodation can only be maintained at a distance, at which, in reference to the negative, the positive part of the relative range of accommodation is tolerably great.*" This is a most important law, and its practical effect is admirably shown in hypermetropia. The reason why the accommodation can not be maintained in hypermetropic eyes is, not because the relative accommodation for a given convergence is not sufficient, for it is usually greater than in normal eyes, but because the positive part is too small in proportion to the negative, or, in extreme cases, does not exist at all. In other words, the amount of muscular force expended

is much greater than that held in reserve. But this may also occur, under certain conditions, in the normal eye.

No muscle can long maintain its maximum tension without giving rise to fatigue and pain, and these follow in the case of the ciliary muscle, just as they would in any other muscle which was overtasked; and there is no reason why that which takes place in the hypermetropic eye, from abnormal structure, should not also occur in an emmetropic eye, from weakness—that, just as the ciliary muscle, in one case, is overtasked, from having an abnormally heavy burden to carry, so it might, in the emmetropic eye, be too weak to perform its normal amount of duty. If the weakened muscle is using a force disproportionate to its strength, in order to adjust the accommodation for a given convergence, it must be at the expense of that amount of power usually held in reserve by the normal eye, and represented, as we have seen, by the positive part of the relative A. I have seen many cases of this type of asthenopia, where the deficiency of the positive, or want of reserved force, was very apparent. The amount has varied between what would be represented by a convex glass of $\frac{1}{20}$ to $\frac{1}{40}$.

Now, in regard to the treatment of these cases. As it has been proved that accommodation can only be maintained, for any length of time, where the positive is tolerably great in reference to the negative, and as it has been shown that the positive, in the above cases, is disproportionately small, the indication would appear to be to restore the positive to its normal dimensions, and it would follow that the asthenopia would then be relieved. The question then is, how can this be done? The answer is, by convex glasses.

As a convex lens represents so much muscular force, we have, by adding this lens, added just so much power, restoring the proportion between the positive and negative parts of the relative accommodation.

It would seem to follow then, that, as soon as the want in the positive was supplied by the glasses, the asthenopic symptoms would rapidly disappear. This is often the case, and would be so nearly always if a new factor of the disease did not come into play, and this is want of energy. It is one thing for a muscle to contract and quite another for it to maintain its contraction; and the fatigue which arises in this case, is not so much that which proceeds from actual energy, as of lifting a load, as that which results rather from the simple extension of an elastic muscle when in the condition of contraction. The power to maintain a certain amount of contraction is, to a very great extent, dependent on the will—the patient "having lost confidence in his ability to use his eyes" being a very prominent feature in this form of asthenopia. Having restored, as it were, by the glasses, the actual muscular force, we must seek to cultivate the ability to maintain the required muscular tension; in other words, to restore the tone and vigor of the weakened ciliary muscle; and the best way of doing this appears to us that proposed by Dr. Dyer, viz. gradually increasing exercise at stated intervals, with light convex glasses] (*E. G. Loring.*)

Authorities.—*Stellwag*, Sitzungsberichte der Wien. k. Akad. der Wiss. XVI. S. 245, 264, 265. —*Graefe*, A. f. O. II. 1. S. 169 et seq.; III. 1. S. 308–326; VIII. 2. S. 314 et seq.; X. 1. S. 156, 165, 169; Congress intern. d'ophth. Paris, 1863. P. 93.—*Donders*, A. f. O. IV. 1. S. 329, 332, 334, VI. 2. S. 78 et seq.; Anomal. der Refr. u. Acc. Wien. 1866. S. 217 et seq.—*Schuerman*, Vijfde Jaarl. Verslag. Utrecht, 1864. S. 1; kl. Monatbl. 1864. S. 92, 95.—*Hering*, Verbal communications.—*Kugel*, A. f. O. XII. 1. S. 66–75.—*Knapp*, Congress int. d'ophth. Paris, 1863. P. 96; kl. Monatbl. 1863. S. 478, 480.—*Pagenstecher* und *Sämisch*, kl. Beobachtungen. Wiesbaden. I. 1861. S. 63; II S. 36.—*Liebreich*, Canstatts Jahresber. 1864. S. 164.—*Brücke*, A. f. O. V. 2. S. 180.—*Landsberg* ibid.

XI. 1. S. 69 et seq.—*Böhm*, der Nystagmus, etc. Berlin, 1857, S. 63. 111; die Therapie des Auges mittelst des farbigen Lichtes. Berlin, 1862. S. 203–236.—[*Dyer*, N. Y. Med. Jour. Oct. 1865.—*E. G. Loring*, N. Y. Med. Journal, Feb. and May, 1867.]—*Pagenstecher*, kl. Beob. II. S. 36; III. S. 90.—*Dobrowolsky*, A. f. O. XIV. 3. S. 53, 61, 75, 80; kl. Monatbl. Beil. 1868. S. 114–118.—*Manuhardt*, ibid. XV. 1. S. 288.—*Tetzer*, Wien. Augenklinik. Ber. S. 157.—*Böhm*, Die Therapie d. Auges mittelst farbigen Lichtes. Berlin. 1862. S. 203–236.—*Schirmer*, kl. Monatbl. 1867. S. 114.

5. Paralysis of Accommodation.

Symptoms.—*This affection is characterized by the removal of the near point, and its approach to the far point; or, in other words, by the diminution or entire loss of the range of accommodation.*

Even in low grades of the paresis, the difficulty of exciting or maintaining sufficient accommodation shows itself very decidedly. On such attempts, the eye soon tires, its accommodation begins to waver, and the muscle soon gives out. Mikropsia is often observed at the same time. In the higher grades of the paresis, the power of adjustment is almost, or wholly, lost. The extent of distinct vision is limited to the longest line of accommodation, whose length and position, of course, vary with the natural refractive state of the eye. The latter does not appear to change much in slight paresis; but in complete paralysis it is often much diminished. Many eyes become hypermetropic that were not so before, and their natural refraction returns again after the cure of the paralysis. (*Jacobson*, *Höring*, *Pagenstecher*, *Donders.*)

Sometimes the paresis of accommodation is *simple*, the pupil retains its normal size, and reacts very freely to reflected irritation, but in the accommodative changes of the eye it does not move. Myopes who in their ordinary occupations use their accommodation little, if any, and do not use any correcting glasses, usually have their sight little disturbed. On the other hand, emmetropes, and still more hypermetropes, are much affected by the loss of accommodation during near vision. Their sharpness of vision is greatly decreased for short distances, and sometimes, also, for far distances, and the attempt to cover the defect by straining the accommodation soon causes asthenopia.

As a rule, the reflected movements of the iris are also arrested, the pupil reacts slightly, if at all, to light, &c., it remains fixed and moderately dilated, the paresis of accommodation is accompanied by mydriasis (see under this head). The disturbance of vision is then always marked, very often there is also paralysis of the *external* muscles supplied by the oculo motor. Indeed, not unfrequently the paralysis extends to several cerebral and spinal nerves, and is very complicated.

Causes.—We divide paralysis of accommodation into two forms, viz. true paresis dependent on functional disturbances of the nerves, and others that are caused by pathological changes in the muscle or their sheaths.

1. Where true paralysis of accommodation occurs alone, or combined only with mydriasis, cerebral origin of the disease is not impossible, it is true, but is very rare. It almost always depends on an affection of the short root, or of the lenticular ganglion. Where, however, the paresis of accommodation and the mydriasis are only partial symptoms of an affection, extending to several muscles, there must be disease in the trunks or sheaths of one or more nerves, or, as more frequently occurs, in the central organs. Among the affections of the latter are not only perceptible organic changes in certain portions of the brain or spinal medulla, but also less manifest alterations, such as those that occur in alcoholism, late in diabetes mellitus

(*Graefe, Nagel*), in uræmia, lead-poisoning, trichiniasis (*Höring*), and malarial fever (*Mannhardt*).

Epidemic diphtheria is an important cause. In some epidemics the disease is very often accompanied by paralysis of accommodation. (*Donders, Pagenstecher, Benedikt, Nagel, Stammeshaus*).

The symptoms of paralysis usually appear after the croup has nearly or quite disappeared, usually between the third and sixth week. They do not occur in cases that run their course rapidly, or in the slower ones, where death results from kidney-disease. (*Pagenstecher.*) The muscles of accommodation and of the palate are most frequently affected. Some think that the nerves passing through ganglia are most attacked. (*H. Jackson.*) In some epidemics the paresis of accommodation is accompanied by great decrease of the natural refraction (*Jacobson, Pagenstecher*); but the nerves of the iris are usually unaffected, so that the reflex movements of the iris generally continue. Paralysis of the soft palate prevents the separation of the nasal cavities from the throat, and so hinders speaking, swallowing, &c., and this is more apt to occur, as there is often also anæsthesia of these parts. (*Pagenstecher.*) Besides the paralysis of accommodation, the muscles supplied by the oculo-motor are also often paralyzed. More rarely the extremities, especially the extensors, are affected with palsy, sometimes also with anæsthesia. Exceptionally, there is also paresis of the nerves governing forced expiration. (*Pagenstecher.*) Diphtheritic paralysis has always terminated in recovery, if the disease itself did not cause death. Still, the paresis of accommodation often causes asthenopia for a long while.

Strabismus divergens has also sometimes been seen as a consequence of paralysis of accommodation. (*Donders, Pagenstecher.*)

It is thought that a constitutional disease may be considered as the cause of the local affection, and that the paralysis results from the influence of the changed character of the blood on the central organs. (*Donders.*) Possibly the diphtheritic deposit causes a blood-poisoning. This view is favored by the fact that severe cauterization diminishes the mortality of the disease, and renders the paralyses rarer. (*Bretonneau.*)

Still paralysis of accommodation has been also observed without any diphtheritic affection in acute swelling of the submaxillary and cervical glands, even in deep cervical cicatrices after ulcerations of scrofulous glandular tumors. (*Graefe, Remak.*) We are, therefore, very much inclined to refer the paresis of the different nervous regions just as in Basedow's disease, also in diphtheritis faucium, to diseases of the cervical sympathetic nerve, and to the circumscribed paralytic dilatations of the vessels of the central parts of the brain, particularly of the medulla oblongata. (*Steffan.*) This would be corroborated by the circumstance that in diphtheria swellings usually appear at both the angles of the lower jaw, which seem to be infiltrations of the connective tissue, and can, without doubt, react upon the superior cervical ganglia (*Remak*) The frequently demonstrable sensibility of the cervical cord (*Grenstein*), and the healing action of electric currents passed through the latter, may also be here turned to account. (*Remak, Benedikt.*)

In several cases a very remarkable limitation of accommodation was also observed in affections of the teeth, and explained by the reflex action of the trigeminus upon the vasomotor nerves of the brain. The degree of pain for the slighter or greater amount of the paresis is said here to be of less significance, and the affection to be found especially in individuals between the 10th and 15th years of life; very exceptionally, however, or even not at all, after the 30th year. (*H. Schmidt.*) The question may here be asked, whether these limitations of accommodation may not often be explained by the fact that energetic and continuous muscular efforts are usually rendered very difficult by pain in any part of the body.

2. The muscle of accommodation itself may become incapable of reacting proportionately, or at all, to the nerve-impulse; from inflammation and its results in outgrowths or atrophy; from senile changes, and as a result of continued inactivity from neglect of the eye, as occurs in strabismus or marked functional disturbance of

one eye. Besides these, practically, debility of the muscle of accommodation approaching paresis, is frequently witnessed as a result of diseases affecting the nutritive functions.

Treatment.—Where the cause is within reach, of course its removal must be attempted, and meantime the eyes should be carefully used. If the diseased process is eradicated, and yet the muscle remains to some extent weakened, electricity promises, without a doubt, the best success. (*Benedikt, Coccius.*) The copper pole should be placed upon the closed lid, and the zinc pole should be moved round the orbital margin. In diphtheritic paralysis, galvanization of the cervical sympathetic is to be preferred. (*Benedikt, Remak.*) In addition, carefully-conducted exercise of the apparatus of accommodation, never carried to fatigue, may effect a favorable result.

Convex glasses, that do not fully correct, furnish a means for this exercise, as they do not free the muscle of adaptation from exertion. But if asthenopia be caused by their use, we should rather employ fully-neutralizing spectacles. (*Donders.*) At the same time, cold-water treatment, sea-baths, cold douches, life in the open air, and anything that increases the muscular strength, is beneficial. Besides invigorating diet, quinine, sulphuric acid, and the preparations of iron internally, are recommended in diphtheritic paralysis. (*Donders.*) Ergot (*Willebrand*) is of no use, and extract of calabar-bean is of but little service in paralysis of accommodation.

Authorities.—*Stellwag*, Sitzungsbericht der Wien. k. Akad. d. Wiss. XVI. S. 244, 266; Oph. II. S. 325, 674.—*Donders*, Anomalien der Refrac. u. Acc. Wien. 1866. S. 500 et seq.—*Graefe*, A. f. O. II. 1. S. 173, 191, 192; II. 2. S. 299 et seq.; III. 2. S. 363; IV. 2. S. 230, 234.—*Nagel*, ibid. VI. 1. S. 231.—*Höring*, kl. Monatbl. 1864. S. 235.—*Hughlings Jackson*, ibid. S. 143, 145–147.—*Mannhardt*, ibid. 1865. S. 18.—*Pagenstecher*, aus Elberfeld, ibid. S. 358.—*Jacobson*, A. f. O. X. 2. S. 47.—*Bretonneau*, nach Donders, l. c. S. 513.—*H. Gerold*, Zur ther. Würdigung farbiger Diopter. Bonn. 1867. S. 36, 42.—*Willebrand*, A. f. O. IV. 1. S. 341, 344.—*Donders*, Centralbl. 1867. S. 526.—*Graefe*, Deutsche klinik. 1865. S. 115.—*Remak*, ibid. S. 115.—*Coccius*, Der Mechanismus der Accommodation. S. 61, 99.—*Benedikt*, Elektrotherapie. Wien. 1868, S. 457, 461.—*Schmidt*, A. f. O. XIV. 1. S. 107.—*Steffan*, kl. Erfahrungen. und Studien. Erlangen. 1869. S. 47, 54.—*Stammeshaus*, Diss. Bonn. 1870.

6. Mydriasis.

Symptoms.—*This affection is characterized by a widely-dilated or only slightly-movable pupil, which does not depend on any material change in the eye.*

The dilatation of the pupil is always marked, but seldom reaches such an extent that the iris appears in the form of a small border behind the limbus conjunctivalis. Sometimes it is irregular, when certain arcs of the pupil are more dilated than others, and it sometimes appears as a perpendicular or horizontal oval, or a polygon with rounded angles, &c. At the same time the dilated pupil is fixed, it varies little, if any, from the action of light, convergence of the optic axes, or exertion of the accommodation. Since, with enlargement of the pupil, the intensity of illumination of the fundus and the quantity of reflected light is increased, the pupil loses its blackness, and appears more gray, with a tendency to blue or green, and, when the light falls at a favorable angle, may even appear brilliant.

The power of accommodation is almost always limited, and often entirely removed. Still, no constant proportion exists between the pupillary dilatation and the loss of accommodation; this may be reduced to nothing in a slightly-dilated pupil, and, conversely, may remain in marked mydriasis.

This diminution of accommodation, occurring with mydriasis, manifests itself very disagreeably, since the diameter and apparent brilliance of the circles of dispersion, falling on the retina, increase with the size of the pupil. Moreover, the mydriatic eye does not see with perfect distinctness at any distance, as the asymmetric curvature of the cornea and lens greatly affects vision, on account of the amount of blurring. Besides this, there is the very unpleasant feeling of dazzling, which often accompanies mydriasis, and frequently renders it impossible to use the eye in bright light.

Mydriasis is usually confined to one eye; it is rarely binocular. Nevertheless, it disturbs binocular vision very much, till the patient has learned to suppress the indistinct perceptions of the affected eye.

Causes.—Mydriasis must not be considered as an entire paralysis of the iris. This is characterized, not by dilatation of the pupil, but by inaction and tremulousness in quick movements of the eye. In mydriasis, the iris is always tense, even when reaction to light and the power of accommodation are absent. Moreover, by powerful irritation of the twigs of the fifth pair of nerves about the eye, temporary contraction may almost always be induced; on the other hand, the use of atropia will produce maximum dilatation. (*Ruete.*)

We generally distinguish a spastic and a paralytic form. The first depends upon an irritated state of the oculo-pupillary branches of the sympathetic nerve, and is therefore caused by a spasmodic contraction of the dilatator pupillæ and of the muscular portions of the vessels of the iris, and in *pure* cases is not attended by any limitation of the range of accommodation.

To this class belongs the mydriasis, which sometimes during attacks of hemicrania (*Du Bois-Reymond*) affects the eye corresponding to the side of the head affected, but in most cases seems quickly to pass away, as the spasm soon changes to paralysis of the muscular walls

of the vessels. Furthermore, there may here be reckoned the ephemeral mydriasis (*Graefe*), which develops itself only temporarily at certain hours of the day, without any especial cause or under the most varying external causes. In one case mydriasis and myosis alternated periodically with each other, without there being demonstrable any limitation of accommodation (*Donders*). The dilatation is probably also to be reckoned here which is sometimes observed in Helminthiasis (Worms) and in certain abdominal affections, although the abdominal sympathetic can exercise no direct influence upon the oculo-pupillary nervous branches (*Budge*). An important cause are irritating injuries acting directly upon the cervical sympathetic (*cervicalstrang*). In fact a high degree of mydriasis has been observed in consequence of an aortic aneurism, of carcinoma of a cervical gland (*Ogle*), during the passage of a phlegmonous inflammation of the neck into suppuration (*Kidd*), and in connection with great elevation of the upper lid, even repeatedly in ordinary goitre (*Demme*). Unfortunately the state of accommodation has not in these cases been sufficiently estimated, and hence many of them might possibly be confounded with those which have been seen in diphtheria of the throat and affections of the teeth. Finally in the category of spastic mydriasis are to be reckoned those cases of dilatation of the pupil, which constantly occur in very slow respiration, or where the latter has entirely ceased, in concussion of the brain, in obstruction of the respiratory passages, and generally in death by suffocation, and which, according to physiological experiments (*Thiry*, *Ludwig*, *Bezold*), are to be explained by the irritating action of blood rich in carbonic acid and poor in oxygen, upon the central organs of the sympathetic nerve.

The mydriasis is usually a symptom of paralysis and to be explained by obstruction to the conducting power of the oculo-pupillary branches of the third pair of cranial nerves. The paralysis is but rarely limited to the motor nerves of the sphincter pupillæ and can then always be referred to a central cause. In the great majority of cases it is accompanied by paralysis of accommodation, and its cause may then be found as well in pathological changes of certain portions of the brain situated beyond the centre of origin of the trunk of the oculo-motorius, as in obstructions in the conducting power of the ciliary ganglion and of its short root, or even merely of the intraocular ganglia. Mydriasis and paralysis of accommodation are frequently merely two of the symptoms of a paralysis which extends over larger parts or over the entire region or ramification of the third and even of several cranial nerves. The cause of the obstruction in conducting power is then often an affection of the sheath of the nervous trunk, and as a rule is referred to a rheumatic origin. Just as often, however, the morbid deposit lies deeper, in the envelopes of the brain or even in the latter itself.

Mydriasis is also a symptom of certain brain-diseases, chronic hydrocephalus, basilar meningitis, and apoplectic effusions at the base of the brain. It occurs frequently in diseases of the cerebellum (*Duchek*) and in chorea (*J. Meyr*), poisoning with coal-gas, lead, certain narcotics, &c.

The dilatation of the pupil, occasioned by mydriatics and accompanied by paralysis of accommodation, manifests also a spastic contraction of the muscles of the iris supplied by the sympathetic, as well as a paralysis of the sphincter pupillæ and of the ciliary muscle, and is to be explained by an action of those poisons upon the intraocular ganglia.

Course and Results.—Where the original disease can be cured, or subsides spontaneously, the mydriasis and its attributes also often disappear. Still, not unfrequently, dilatation and sluggishness of the pupil, with or without limitation of the accommodation, remains; sometimes only the latter. Once chronic, mydriasis usually defies all attempts at cure, and becomes permanent, probably because the muscles or nerves involved become atrophied.

Treatment.—This should always be directed to the original disease, where this is discoverable. Hence it will be purely antiphlogistic, antirheumatic, anthelmintic, &c., according to circumstances. If the original disease has been removed, or if the treatment for it has done its utmost, and the mydriasis continues as an independent disease, or if it was so from the first, without perceptible cause, we should try to excite contractions of the sphincter pupillæ.

The hopes of doing this by the calabar preparations have not been fulfilled. The effects of this remedy are evanescent. Where the causes are ephemeral, however, calabar may hasten, or even excite, recovery. The hopes from it are the better, the greater and more permanent its effect on the pupil and the accommodation, at each application. (*Graefe.*)

In some cases, after the fruitless use of other remedies, *electricity* has proved beneficial. (*Benedikt, Fieber.*) The copper pole should be placed over the closed lids, the zinc pole to the zygoma.

In the spastic form, however, the galvanic current is better conducted to the cervical sympathetic.

Not very unfrequently, irritation of the ophthalmic branches of the fifth pair of nerves is beneficial by the reflections to the sphincter. For this purpose tincture of opium may be applied once, or at most twice, daily, to the conjunctiva. If, in consequence of this treatment, there is so much vascular irritation as to require treatment, we may apply cold compresses, without diminishing the effect of the first remedy, as cold also stimulates the sphincter pupillæ.

Frequent contractions of the orbicularis muscle are considered beneficial, as they sympathetically excite contractions of the sphincter pupillæ. (*Graefe.*) The patient should be advised to close the lids frequently. Methodical use of the muscle of accommodation should also be tried.

We may soon judge from the extent and duration of the pupillary reaction, whether this remedy promises any thing. Where the diameter of the pupil changes little, or quickly returns to its former size after all these attempts, there is little hope.

Instead of applying laudanum to the conjunctiva, we may, of course, use any other irritants. Thus, the conjunctiva or edge of the cornea have been cauterized with nitrate of silver; the patient has been ordered to take snuff, smell ammonia, &c. Greatly irritating the retina, in order to affect the pupil, is dangerous, and of little benefit. The same is true of repeated paracentesis of the cornea. The use of strychnia and veratria salve to the frontal regions, as well as the internal use of ergot, are of little or no advantage. (*Arlt.*)

Authorities.—*Stellwag*, Ophth. II. S. 329, 331; Wien. med. Wochenschrift, 1864. Nro. 10-12. *Ruete*, Lehrb. der Ophth. I. Braunschweig, 1853. S. 101, 328, II. S. 568. — *Donders*, Anom. der Refr. u. Acc. Wien, 1866. S. 493, 504, 505, 506, 524. — *Graefe*, A. f. O. I. 1. S. 315, II. 1. S. —*Stellwag*, Wien. Med. Jahrb. 1869. 2. S. 50; Der intraoculare Druck. Wien. 1868. S. 74 u. f. —*Thiry*, *Ludwig*, *Bezold*, ibid. S. 76 u. f.—*Donders*, Het tinjarig bestaan v. h. nederl. gasthuis etc. Utrecht. 1869. S. 137.—*Benedikt*, Electrotherapie. S. 291, 303.—*Budge*, Die Bewegung der Iris. Braunschweig. 1855. S. 176.—*Ogle*, *Kidd*, Nach Eulenburg und Guttman Arch. f. Psych. I. S. 422.—*Demme*, Würzburg. Med. Zeitschrift. III. S. 269, 273, 297.—*Du Bois-Reymond*, Arch. f. Anat. u. Phys. 1860. S. 461 u. f.

7. Spasm of Accommodation.

Symptoms and Causes.—*This affection is characterized by a sudden increase of refraction, with a diminution or loss of the power of voluntary change of accommodation.*

This is one of the darkest chapters in ophthalmology, because a sufficient number of carefully-studied cases has not yet been observed. It is thought that it may be reflected, or sympathetically excited, through the muscles, producing convergence of the optic axes.

1. Reflected spasm of the ciliary muscle occurs from severe irritations of the sensitive ciliary nerves, especially in inflammations. Then it is accompanied by great retinal hyperæsthesia, and usually by spasm of the sphincter of the pupil and of the orbicularis palpebrarum.

In other cases these reflex spasms seem to originate in a sort of hyperæsthesia of the retina and optic nerve, which shows itself especially by intolerance of small circles of dispersion; for cases are observed where, at the moment such circles of dispersion fall on the retina, the muscle of accommodation contracts strongly, increases the refraction of the eye, and hence the indistinctness of perception, and so, instead of a favorable condition of adaptation, induces the opposite. Hitherto this peculiar disturbance of function has only been noticed in myopia of low or medium grades. It is noticed by the patient, that, when removing an object under examination from the eye, beyond the far point, it does not become *gradually* indistinct, but *suddenly*, and with the sensation of an alteration of accommodation. While, for instance, such a person sees sharply at one, one and a half, or two feet distance, objects at three to five feet appear to him much more indistinct than they would to others of an equal or higher grade of short-sightedness. More careful examination then easily discovers that this sudden increase of indistinctness is caused by an excessive strain of accommodation, which is associated with an increased convergence of the optic axes. Strong concave glasses held before the eye correct not only the dioptric anomalies, but also the false axis-convergence. This rare state is called "myopia in distance." It requires the correction of the existing anomaly of refraction; that is, the use of suitable concave glasses for distant vision.

Exactly in opposition to these cases, others appear where the spasm of accommodation occurs when the object is brought within the line of clear vision, so as to require a certain increase of accommodation. Then too great an amount is supplied, the muscle of accommodation contracts much more strongly than the distance of the object requires, while simultaneously the axis-convergence increases disproportionately, and a squint is developed in one eye. In many cases the tension of the muscle of accommodation and the internal recti increase and diminish in proportion to the approach or removal of the object; still, however, only to such an extent that, within certain bounds, it always exceeds the requirements. In other cases, however, at the moment an object approaches within a certain point, the maximum of accommodation and axis-convergence is excited, and remains for a time unchanged, even if the distance is again decreased. The spasm, once excited, sometimes does not relax for a length of time, even when the cause is entirely removed. Such cases easily pass for high degrees of myopia; still, the fact that, under ordinary circumstances, at least occasionally, the patients see sharply at a distance, as well as their inability to wear strong concave glasses, shows that only a temporary increase of refraction exists. In fact, careful examination shows the natural adjustment of the eye to be sometimes a proportionately slight myopic, normal, or moderately hypermetropic one.

The therapeutic indications are evidently to render unnecessary the amount of strain of

accommodation that causes spasm. Of course, this may best be done by shunning employments requiring near vision. However, where this can not be done, the use of weak glasses for near vision may be advisable, as the objects thus appear removed, and the amount of accommodation required is diminished. In a short-sighted person whose far point is at fourteen inches, spasm was kept off for years by using twenty-six-inch convex glasses. While previously the patient, in reading or writing, approached objects to within three or four inches and turned the left eye strongly inward, he now continued the same occupation for hours, with a normal fixation and distance of the object. The disuse of the glasses always resulted in a return of spasm. (*Graefe.*) In other cases continued use of atropia seems to have removed the affection.

2. It is said that, in spasm of accommodation excited sympathetically from the internal recti when the object is approached to a certain distance, a strong contraction of the muscle of accommodation and internal recti results, so that, even while the distance of the far point is great, the patient can only see to read, write, &c., at three or four inches. It is said that the use of abducent prismatic glasses of two or three degrees has entirely removed the functional disturbance. (*Liebreich.*)

In a word, the forms of disease described under 1 and 2 are very unclear and doubtful.

3. The elevations and variations of the state of refraction, which frequently occur after continuous and strong efforts at accommodation and can be made manifest by the forced application of mydriatics, are, apart from reasons previously mentioned, by reason of the slowness of their growth and recession scarcely to be referred to spastic contractions (*Dobrowolsky*), but rather to hypertrophic development of Müller's circular fibres and to loss of elasticity of the lens.

Authorities.—*Graefe*, A. f. O. II. 1. S. 158 et seq.; II. 2. S. 307, 313, 316.—*Liebreich*, ibid. VIII. 1. S. 259, 265, 266.—*Donders*, Anomalien der Refrac. u. Acc. Wien. 1866. S. 536.—*Dobrowolsky*, kl. Monatbl. 1868. Beil. S. 3, 141, 175, 179, 180, 244.—*Berlin*, ibid. 1869. S. 1.

8. Myosis.

Symptoms.—*This disease is marked by an excessive and permanent contraction of the pupil, which is also fixed, or but slightly movable. It is independent of any structural change in the eye.*

The pupil is contracted to the size of a pin-head, or even the point of a needle, perfectly circular and very black. It reacts slightly, or not at all, to changes of light, or even to the action of atropia. Its small diameter limits perceptibly the visual field, so that, sometimes, the patient can only see parts of large objects, even when they are at some distance. Moreover, the apparent brilliancy of retinal images is decreased, and hence clear vision, with moderate or slight illumination, becomes more difficult, or even impossible.

The accommodation is, in the majority of cases, very little or not at all limited. In old people there is found almost constantly a very remarkable narrowness of the pupil, together with incomplete and slow reaction to atropine. Here it seems to be not so much an obstruction to the conducting power in the nerves under consideration, as rather the resistance which the rigid, or perhaps atheromatous walls of the vessels of the iris oppose to the organic muscles supplied by the sympathetic.

Causes.—We divide myosis into two forms, spastic and paralytic. The first is to be referred to direct conditions of irritation or to those communicated from the opticus and trigeminus to the oculo-pupillary branches of the third cranial nerve. It is very perceptible in inflammations accompanied by great irritation of the ciliary nerves, and usually renders the energetic use of strong solutions of atropine completely useless.

The continuous activity of the sphincter pupillæ, for the sake of distinct vision at very short distances, may possibly give to this a certain over-balance. At least myosis is found in watch-makers, jewelers, engravers, etc., in a much larger proportion (*Arlt*).

The paralytic form occurs not very uncommonly with slight ptosis of the upper lid (*Horner*), and depends upon obstructions to the conducting power of the sympathetic nerve branches going to the eye and the organic muscles of the upper lid. This form has hitherto been observed solely in adults. The affection of the sympathetic here often manifests itself by periodical semi-lateral redness and development of heat in the face and head (*Horner*). Sensibility of the corresponding cervical region was also observed in one case. At the same time, so far as experience thus far teaches, the myosis is not usually very great, and still admits of slight variations of the diameter of the pupil in reflex and accommodative impulses. The paralytic condition of the vessels of the iris and of the dilatator pupillæ, moreover, manifests itself very distinctly by the extremely rapid and complete narrowing of the pupil through the action of the calabar-bean, as well as by the very vacillating and incomplete dilatation of the pupil on the employment of atropine. The spontaneous movements of the upper lid are not at all impeded, with the slight exception of the upward movement, and act very powerfully against an external mechanical resis-

tance, so that there can be no doubt that the seat of the functional disturbance lies not so much in the levator palpebræ as in the organic muscle of the upper lid. In the majority of cases the affection seems to have been developed without any considerable external cause. It may often be explained by the pressure of a tumor upon the cervical filament (*Grenzstrang*, *Willebrand*, *Gairdner*, *Ogle*, *Heinke*, *Mitchel*, *Morehouse*, *Keen*). In one case a tumor of the parotid gland seemed to be the cause (*Verneuil*).

In addition, myosis often occurs in tabes dorsalis and other forms of paralysis of the spinal cord (*Robertson*), in obstinate constipation, in consequence of torpidity of the intestines, etc. The pathogenesis of these forms of myosis is as little known as of those which occur as symptoms of many affections of the brain, especially in diseases of the pons Varolii (*Duchek*), as symptoms of apoplexy in the stage of reaction, in the commencement of meningitis, together with the appearance of tetanus, hydrophobia, etc.; or which appear as accompaniments of hysterical spasmodic attacks; or which are observed in cases of intoxication by certain narcotic substances, like opium, morphine, etc.

The Treatment of myosis requires, first, the removal of the cause. If this can be removed, the myosis usually disappears spontaneously. In other cases, where the myosis apparently exists independently, direct treatment is usually without result. Mydriatics have been tried without effect.

In some cases (*Benedikt*), particularly when paralysis of the cervical sympathetic plays a part, electricity may render good service. When this has been employed in vain, and the myosis limits the power of vision very much, nothing remains but the formation of an artificial pupil.

Authorities.—*Ruete*, Lehrb. der Ophth. I. Braunschweig. 1853. S. 328, II. S. 568.—*Stellwag*, Ophth. II. S. 327.—*Willebrand*, A. f. O. I. 1. S. 319.—*Simrock*, kl. Montbl. 1863. S. 122.—*Duchek*, Wien. med. Jahrb. 1864. 4. Jahresbericht. S. 54.—*Arlt*, Krankheiten des Auges. II. Prag. 1853. S. 181.—*Donders*, Anomalien der Refr. u. Acc. Wien. 1866. S. 610.—*Gairdner*, ibid.—*Stellwag*, Der intraoculare Druck. S. 76.—*Ogle*, *Heineke*, *Verneuil*, *Mitchel*, *Morehouse*, *Keen*, nach Eulenburg und Guttman. Arch. f. Psych. 1. S. 420.—*Horner*, Klin. Monatbl. 1869. S. 193.—*Robertson*, Edinburgh med. journal. 1869. Febr.—*Benedikt*, Electrotherapie, S. 291, 304.

SECOND SECTION.

ENTOPTIC APPEARANCES—SCOTOMATA.

Symptoms and Causes.—*The characteristic symptom is the perception, by the patient, of circumscribed shadows of opaque particles in the dioptric media.*

The shape and general appearance of these shadows or scotomata vary greatly, in accordance with the great variety of the "entoptic bodies" which cast shadows. Several varieties are distinguished.

1. The most important of these scotomata are known as *muscæ volitantes.* They are seen in the visual field as more or less dark spots, having a roundish or irregular outline, and a straight or curved tail-like appendage. They vary in size between a millet-seed and a pea or bean, being rarely larger than the latter.

The color depends on the thickness of the entoptic body, and on the kind and amount of the incident light, varying from dirty gray to a brown or black. The color is also different in different parts of the shadows.

These entoptic appearances are most distinctly seen when the eyes are directed toward a distant, strongly-illuminated, bright surface, such as the clear sky, a field of snow, or a white wall, on which the sun shines. They are especially noticed when the eye is adjusted for a near point.

We may get a distinct image of these shadows, by looking upon the sky through a small perforation in an eye-shade, or through a strong convex glass upon the flame of a lamp, in a dark room, at the same time having a diaphragm with a small opening between the glass and the eye. (*Zehender.*) We then see, just as in looking through a small hole in a screen, that they are composed of small shadowy figures, each one of which has a border of darker or lighter color, while the center generally appears very light. We may often distinguish an irregular granular nucleus.

At the center of the scotoma these parts pile up on each other into a mass, whose shade is dark. At the periphery the shadowy forms only partially cover each other, so that the outlines are more distinctly perceived. In the tail-like attachments, the independent lines and filaments, they appear laid on each other, and thus form chains, rings, &c.

At the same time, we generally observe numerous little circles very much alike, isolated and scattered, arranged, in part, like a string of pearls, connected together in the most different manner. Ribbon-like or broad opacities also rise up, which generally pass in a vertical direction, and, by their changing shadows, present an appearance of folds. They are especially observed when the visual axis is moved laterally, or deviates vertically, and the movements are quickly interrupted. (*Donders.*) With less illumination of the visual field, these scotomata disappear, or at least decrease in number. Those which remain then generally appear as indistinctly bordered, small, dirty-brown spots. They follow the patient almost constantly. They are even perceived when moderately bright light falls on the closed lids, and are only lost when the visual field is very slightly illuminated. Yet there are cases

where the scotomata only appear when the eye is directed on some bright object, as a book, with artificial illumination. Sometimes they are only seen when the view is directed to a certain side.

The muscæ are, as a rule, only apparently a few inches off. They are exceedingly movable, and follow the changes in the optic axis, whether these latter are caused by contraction of the muscles of the eye, or by movements of the head. If these motions be made quickly, and the head then held still, the flying muscæ shoot on a short distance and then stop.

If the eye then remains quiet, they begin to sink. Some disappear at the lower border of the field of vision, others stop sooner, and remain at a certain point in the visual field, until a new motion occurs. The entoptic corpuscles giving origin to these scotomata are situated entirely in the vitreous, and have been seen there by the aid of the microscope. (*Donders, Doncan.*)

Pale cells and remains of cells, in a state of mucous metamorphosis, were found there; these answer to the scattered small circles. There were also filaments with granules, answering to the strings of pearls and chains, groups of granules, with granular fibers hanging on them; these explain the larger muscæ. Finally, there are membranes without number that lie chiefly to one side, close behind the lens, in the vitreous of old persons, causing the ribbon and flat scotomata which appear as folds.

Myodesopsia is a normal condition. Indeed, scarcely any eye is without muscæ. In individual cases, it only requires favorable external conditions to cause them to be perceived. Morbid conditions always have a great influence on the symptoms.

It is a fact, that irritations in the vascular parts of the globe increase very considerably the number, size, and density of the *muscæ volitantes*. Myodesopsia may thus become an extremely painful affection, probably by leading immediately to proliferation and increase in size of the cells of the vitreous humor. Muscæ are often very annoying after excessive straining of the eyes, but chiefly as a premonitory indication of asthenopia. They are almost always found as an extremely disturbing symptom in the rapid enlargement of a posterior staphyloma.

The entoptic bodies are most frequently found in the vicinity of the optic papilla, and are often connected to this. They are rarely so large as to be recognized with the ophthalmoscope as turbid, moving flocculi. Inflammations of various sorts may also cause them to appear. The appearance of a painful myodesopsia often dates from the termination of a severe conjunctivitis, keratitis, or iritis. Syphilitic iritis is particularly suspected as a cause of muscæ, especially of those produced by cell-proliferation in the vitreous, based on an inflammation of the part, influenced or produced by the dyscrasia.

As is evident, retinitis and choroiditis would be permanent causes, but they disturb the functions of vision too much, to allow the extremely delicate shadows from the proliferating vitreous to be recognized.

2. The so-called constant scotomata are very different. When these have once arisen, they generally exist unchanged for years, and maintain a fixed position in the visual field, independently of the movements of the eye, as long as the light is conducted in a certain direction through the dioptric media. Under ordinary circumstances they are rarely seen, but when they are, they disturb the vision very much, because they seem to lie in front of the objects, and to partially cover them. Generally, light that is perfectly homocentric is required—that is, that which passes

through a very minute hole in a shade—in order that they may be seen on looking at a brightly-illuminated surface.

Then the visual field appears as a bright disc, whose contours show any irregularities in the pupil, and whose surface is a delicate cloudy gauze or net-work, with fine molecules or larger points rarely striated, radiated, or wavy, like mohair. On this surface, the individual scotomata arise more or less sharply. They are much varied in form. They are often dentated figures whose teeth are mostly crooked, and are arranged around some middle point. They are generally very bright, with their edges blurred, or with sharp, black borders. Sometimes it appears as if these figures were formed from the shadows of nucleated cells. Less frequently, small, dark, straight lines appear, which either radiate from a common center, forming a star, or else approach (without reaching) the center from the periphery. Sometimes they stand alone in the visual field; again, a large number are scattered around or collected in groups. Their size varies from that of a poppy-seed upward, rarely surpassing that of a pea, when the scotomata cover a large portion of the visual field. It is sometimes a dark, roundish, or irregularly-shaped spot, with sharp and often bright boundaries. Sometimes they are more ring-shaped, and a bright or dark, granular, roundish or square nucleus appears, surrounded by a dark girdle, beyond this by a bright zone. It is remarkable that very similar scotomata appear in the visual field of both eyes. They are similar not only in shape, but in number and arrangement. (*Listing.*)

The entoptic bodies causing these scotomata are chiefly situated in the lens, and on close examination are proved to depend on the not quite perfect optical regularity of the crystalline substance, and on the deposition of certain morbid products.

The serrated figures, and the delicate marking of the whole spectrum, are to be ascribed to the peculiar structure of the lens, its fibrous composition, and their arrangement about the so-called nucleus. They lie chiefly near the surface, and excentrically. They may arise within a few days, and then exist for a long time, but again disappearing, while others appear. Their number increases with years. The irregular dark spots are recognized as shadows of superficial, white, granular, opaque corpuscles, which are almost always situated on the borders of the sectors of the lens, and do not seem to be caused by fatty degeneration. (*Donders, Doncan.*)

Some of the dark spots, with irregular contours, are to be explained by irregularities and opaque deposits in the corneal tissue and the lenticular fossa. They are also caused by turbid, and perhaps partially loosened epithelial cells, on the two surfaces of the cornea. (*Listing.*)

When a small hole in a screen is moved in front of the pupil, it is clearly seen that the entoptic corpuscles in question are situated, sometimes in one of these positions, and sometimes in another. On observing their peculiar appearance, the direction of the homocentric light, falling on the entoptic bodies, is changed by the movements of the aperture in the screen. The shadows also are seen on parts of the retina which are constantly changing. If we successfully look at different points of the field, the shadows of all bodies which are not in the plane of the pupil change their position in reference to the circular boundary to the field of vision. This movement of the shadows in the entoptic field of vision, Listing calls the relative entoptic parallax; it is positive for objects behind the pupil, and negative for objects in front of the pupil. (*Helmholtz.*) Furthermore, the amount of the deviation, in the same movement of the hole in the screen, must be the greater, the farther the entoptic bodies are from the plane of the pupil. (*Listing.*)

The position of the entoptic bodies, at various distances from the plane of the pupil, may be estimated or even measured with great exactness by the method, *a double vue.* (*Donders.*) In this method we look through a screen, having two apertures about a line apart, so that two spectra are thrown upon the retina, which half cover each other anteriorly. In these the scotomata appear double, at a distance from each other, which is equal to the distance between the centers of the two entoptic circles. If the entoptic bodies are in the plane of the pupil, these spectra are

nearer each other, if behind it, further from each other, if in front. The distance of the shadow seen is proportionate to the distance from the plane of the pupil. (*Donders.*)

3. Scotomata of the third variety are of a very ephemeral nature, if we regard them individually. They are also only seen under peculiar circumstances, for instance, when a patient uses the microscope, but particularly when looking upon a bright surface, through a hole in a card. They are not otherwise perceived, and hence do not interfere with vision. They appear chiefly as round cells without nuclei, about as large as a poppy-seed, with dark, not well-defined edges. They somewhat resemble delicate vesicles; at times they are alone in a gray field, again they are in groups; but they are frequently arranged in chains, which look like strings of pearls.

In any movements of the eyes, all these scotomata, like the *muscæ volitantes*, move in a corresponding direction. If the movement has been rapid, they continue for a moment after the globe is at rest. When the eye is quiet, they begin to fall with increasing velocity, often forming arcs as they fall to one side or the other. They finally disappear at the lower limit of the visual field, while others appear at the upper. By the closure of the lids, and, still more, by gently rubbing the closed lids, the position of the scotomata in the visual field is changed; other groups and chains immediately appear, which again sink rapidly downward. The ephemeral scotomata are certainly caused by optical irregularities of the stratum of fluid, constantly covering the anterior surface of the cornea. Apart from the peculiarities in their movements, this is seen from the influence which the movements of the lids, or delicately rubbing the closed lids, has upon their relative arrangement in the visual field. The darker spots, like scotomata, may be referred to thrown-off epithelial cells, meibomian secretion, &c. The bright, ring-shaped ones, are to be ascribed to air-vesicles, which are mingled with the tears.

The union of these ring-shaped scotomata in strings may be explained by the meniscoid shape of the lachrymal stream. The specific lighter air-vesicles ascend to the lachrymal meniscus, and collect in a row in its upper angle, which is drawn over the cornea by shutting the lid, and they again sink down with the tears.

Treatment.—According to what has been said, scotomata are, for the greater part, only symptoms of the incompleteness of development in the structure of individual dioptric media, and have, therefore, no very great significance.

Even the muscæ volitantes, which may, with great probability, be referred to proliferation of cells in the vitreous humor, are of themselves symptoms which need cause no apprehension. They exist in many eyes during the whole period of life, without injuring them in the slightest degree. But where the eye is impaired, it is not so much on account of the cell-proliferation of the vitreous humor as from the original disease, which has involved the vitreous. In accordance with this no treatment is indicated, except in cases where we have reason to believe that such a primary disease exists. The treatment will then be regulated by the form of this morbid condition.

If myodesopsia appears primarily, so as to materially annoy and disturb the patient, protection and rest of the eyes are to be enjoined. Under their influence the muscæ seem to actually diminish.

Authorities.—*Listing*, Beitrag zur phys. Optik. Göttingen, 1845. S. 7, 26, et seq.—*Helmholtz*, Karsten's Encyclopädie, IX. S. 148–164.—*Donders*, Anomal. der Refr. u. Acc. Wien. 1866. S. 167–172, 331.—*Duncan*, ibid. S. 168.—*Zehender*, Seitz Handbuch der ges. Augenheilkunde, Erlangen, 1855. S. 538, 542–547.—*Stellwag*, Ophth. II. S. 387–398.—*Graefe*, A. f. O. I. 1. S. 351, 358, II. 2. S. 293.—*Coccius*, über Glaucom, Entzündung, etc. Leipzig, 1859. S. 6, 7.

[*James Jago*, Entoptics, with its uses in Physiology and Medicine. London, Churchill, 1864.]

THIRD SECTION.

FUNCTIONAL DISEASES OF THE OPTIC NERVE AND RETINA.

Nosology.—These functional disturbances are exceedingly varied, and are still very insufficiently investigated. We divide them into qualitative discordances (*verstimmungen*) and quantitative deviations from the normal condition—the former class comprising the idiosyncrasies, the latter hyperæsthesia, anæsthesia, and amaurosis.

1. Micropsia, megalopsia, metamorphopsia, color-blindness, and colored vision, are counted with the idiosyncrasies. This classification, however, is only partly correct.

The first two conditions generally have their origin in altered conditions of accommodation and convergence. Here and there, however, they appear after injuries of the brain (*H. Gerold*), with inflammation in the retina or optic nerve. When misplacements of the cones, by exudation, are not the proximate cause (*M. Tetzer*), they may possibly be referred to an affection of the nerves which may cause them to act discordantly. Metamorphopsia depends in part on an oblique position of single groups of rods and cones, as in exudative retinitis, in detachment of the retina, in progressive posterior staphyloma. It is in part, also, a consequence of a very unsymmetrical formation of the dioptric media.

Color-blindness is rarely complete. The lack of sensitiveness to impressions of color, which is a normal state of the periphery of the retina (*Aubert*), appears to be extended over the yellow spot (*achromatopsia*, *achrupsia*). The patient distinguishes between light and shade very well—even between the finest grades of the apparent brightness of the retinal images; but he recognizes none of the colors. In fact, he has no idea of color. (*Wartmann.*) But generally the perception of certain colors is very much limited, and thus confusion of colors and tints arises (*chromatodysopsia*).

It is believed by some, but is again denied on weighty authority (*Rose*), that the eye is sensitive to the undulations of three different waves, and that the sensation of each one of these is a peculiar process, or, if we choose so to regard it, the result of the irritation of a particular kind of nerve. Of these, the first is greatly excited by red, the second by green, the third by violet rays, but only slightly so by the other kinds of rays. (*Young.*) White is then induced by an equally powerful irritation of all three varieties of nerve-fibers, black by different irritation of these. The sensation of red appears, if the nerves sensitive to red are *greatly* irritated, the green not so powerfully, and the violet still weaker. Yellow is perceived when nerves sensitive to red and yellow are moderately irritated, but violet is very little excited. Green is seen when there is greater irritation of the nerves sensitive to green, with a weaker irritation of the red and violet. Blue results from a moderately severe irritation of the nerves sensitive to green and violet, and a not so powerful irritation of the red. Violet occurs from a powerful irritation of the nerves sensitive to the slightest undulations, and from a weaker one of the two other kinds of nerves. From red, yellow, green, blue, violet, with white and black, all possible colors may mingle, and the result be an equalization of the colors. (*Helmholtz.*)

More recent investigations have proven, that the sensibility for change of tints is greatest in yellow, next in cyanide blue and blue-green, and least in red, and that tints of color are

generally distinguished with the greatest difficulty, the nearer they lie to a prime color. (*Mendelstamm.*) It has been thought that the power of distinguishing colors might be connected with a division of the cone fibers into three parts, and that the sensibility for one of the three prime colors might be ascribed to each of the three fibers resulting from this division. (*Henle, Hasse.*) But this hypothesis fails with the demonstration of a multiform division, of a brush-like separation of the cone fibers. (*M. Schultze.*) Others think that the physical conditions for the separate perception of different tints of color may be sought in the leaf-like structures of the external members of the cones, and that here may be seen an analogue of those contrivances which in the cochlea of the organ of hearing render the distinguishing of pitches of sound possible.

In chromatodysopsia the sensitiveness to undulations of light is wanting to one of the three undulation or wave-lengths (*Wellen länge*); that is, one of the three fundamental colors is absent; and corresponding to this, all the colors perceived by the patient may be made up upon Maxwell's circle with white and black, by two, instead of three, fundamental colors. Without doubt, the colors then appear differently to the patient than to a normal-sighted person. The kind of impression is changed. But different colors appear to be the same, and are, therefore, confounded with each other. Three variations are distinguished. (*Seebeck.*) In one variety, all the trouble is due to the absence or imperfect perception of green (*green-blindness.*) In the second, it is red that is wanting (*red-blindness, anerythropsia, Daltonism*), and in the third the blue is excluded (*blue-blindness*).

Red-blindness occurs rather frequently; it is, as a rule, congenital and often hereditary. It occurs more frequently in men than in women, and is mainly observed in persons of Germanic race. In England the number of patients affected with red-blindness is very large. (*Wilson.*) Anerythropsia is sometimes acquired by straining of the eyes, and in consequence of severe injuries of the head. (*Wilson, Tyndall.*) It is most frequently developed in connection with progressive atrophy of the optic nerve.

In red-blindness, the objective red light, which only slightly excites the nerves sensitive to green, and still less the violet, does not appear red, but greenish, and, with less intensity, grayish. The objective yellow light irritates the nerves sensitive to green very much, the violet less; hence it produces the sensation of a decided green. The objective green, especially when it approaches the blue of the spectrum, greatly irritates the nerves sensitive to green and like, and must, therefore, appear whitish. Blue is perceived very correctly, since here, in a normal state, the influence of the nerves sensitive to red is almost nothing. The anerythropes see only two colors in the solar speculum, which are called yellow and blue. They consider all the red, orange, yellow, and green, as yellow. They call the greenish blue tints gray, the others blue. The outermost red ones they do not see at all, unless they are very intense. The boundary of their spectrum is, therefore, at a point where normal eyes still plainly perceive an indistinct red. Among the fundamental colors, they confound the red with brown and green, and see their shades darker than persons with normal vision. They do not distinguish golden-yellow from yellow, nor rose-color from blue. A certain mingling of yellow and black appears to them on Maxwell's circle, the same as red—a certain mixture of yellow and blue the same as green, another gray; but they make all other colors from red, yellow, green, and blue, with the assistance of white and black. The person affected with red-blindness distinguishes violet, but calls it blue. (*Helmholtz, Schelske.*)

Patients afflicted with green-blindness distinguish in the sun's spectrum only two colors, which they call, probably with tolerable correctness, red and blue, or when white light is mixed with them, yellow and blue. These two colors are separated by a stripe of an indefinite, grayish tint, and this stripe occupies exactly that place in the spectrum which, in the normal eye, gives the purest sensation of green, and therefore excites the green-perceiving nerve-fibres most. At the same time the sensitiveness for blue is very much increased; so that the spec-

trum appears considerably lengthened at the violet end. The sensitiveness for red is also somewhat increased. (*Preyer.*) Persons affected by green-blindness recognize transitions between violet and red easily and surely, which appear to anerythropes uniformly as blue. On the contrary, they also make mistakes between green, yellow, blue, and red, but in case they confound the same tint with green, they choose a more yellowish green than those affected with red-blindness. (*Seebeck, Helmholtz.*)

In persons affected with blue-blindness, blue and green, or blue and yellow, are regarded as the same, but red and green are not confounded. The violet end of the spectrum is said not to be shortened (*Preyer*), since probably violet is perceived as red.

Violet-blindness also occurs. This is explained by abnormally great concentration of the yellow pigment, running into greenish, which distinguishes the region of the macula lutea, and it is believed that this pigment weakens considerably the transmitted blue and violet light, but affects the red only in a slight degree. (*M. Schultze.*) In accordance with this, we refer the very varying sensibility of different eyes for blue and violet light, the occurrence of persons affected by ultra-violet or lavender-blue blindness (*Masoart*), and the occurrence of violet-blindness (*Rose*) to a varying intensity of the color of the yellow-spot. We have even gone still farther and thought that the red-blindness might be accounted for by a greater development of the greenish tint of the pigment in the yellow-spot (*M. Schultze*), but have failed by reason of contradiction from many sides. (*Dor.*)

Colored vision is, on the whole, a disease which has been very slightly investigated. It is characterized by the saturation of the visual field with a certain color, yellow, red, blue, green, &c., the real color of the objects looked upon being changed.

Colored vision is in the great majority of cases dependent upon the coloring and opacities of the dioptric media and of the anterior layers of the retina. The yellow vision in icterus (*Rose*) is without doubt generally to be referred to the circulation of the coloring matter of the bile in the dioptric media and retina. The simultaneous occurrence of violet-blindness is explained very simply by the non-transmissibility of the yellow-colored media for blue light. The yellow vision in poisoning by santonine is probably the symptom for a stronger irritation of the blue and red-perceptive nerve-fibers, which, however, is soon exhausted in bright light, so that yellow-vision remains, and therefore violet blindness appears, but in shadow is soon re-established and causes violet-vision. At any rate, yellow-vision in poisoning by santonine cannot depend upon a greater amount of yellow pigment collected in the macula lutea (*M. Schultze*) or find its origin in a yellow coloring of the serum of the blood (*Nagel*), since Haidinger's luminous tufts are perceived very distinctly in poisoning by santonine, and therefore the blue light finds no impediment in its passage to the bacillar layer. Violet-vision also should not be referred to complementary-colored after-images (*M. Schultze*), since it is perceived before the yellow-vision. (*Hüfner.*)

Whether the colored vision, occurring after local application of digitaline, &c., has an analogous cause, is still unsettled. The colored-vision after intraocular hemorrhages, in many cases of retinitis and of glaucoma, is certainly to be explained by opacities of the dioptric media and retina. The blue-vision after cataract extractions (*Guepin*) depends upon the presence of some fragments of cortical substance, since it is relieved by an artificial prolapse of the vitreous. (*Hasner.*) The colored borders, which appear around the images of objects in astigmatism, are to be referred to the diffusion of light in the dioptric apparatus and to insufficient accommodation. If we disregard these cases and the complementary colored-vision, which appears exceptionally after the use of deeply colored glasses (*Böhm*), there only remain a few cases, in which the affection seems to be entirely independent of material causes, and may be regarded as a true impairment of the light-refracting apparatus. Such conditions have been observed under various external conditions. Sometimes the subjective coloring of the field of vision varied, remitted, or even intermitted. (*Skokalski.*) It cannot be neutralized by placing complementary-colored glasses before the eyes, but requires often very singular combinations of color, which cannot be explained by any physical laws. (*H. Gerold.*)

2. Hyperæsthesia optica is characterized, on one hand, by abnormally increased sensibility—that is, by excessive intensity and duration of the sensations which may

be caused by irritation of the optic nerve and retina—but on the other hand, also, by a condition of abnormally high excitement, which is indicated by sensations which do not depend on external influences.

a. The most common symptom is an exceedingly painful sensation of dazzling. This occurs from the action of even a comparatively small amount of light, or even when there is no objective light at all. This dazzling sensation is generally combined with ciliary hyperæsthesia; that is, with a more or less severe pain in the eye-ball, extending to one or the other branch of the fifth pair of nerves. There is profuse secretion of tears, reflex spasms of the orbicularis muscle, &c. In this combination of symptoms, that condition is seen which is called photophobia. Photophobia is, indeed, a very complicated phenomenon. It is the reflection of hyperæsthetic affections in different nerve-tracts, that stand in intimate connection with each other, however, so that excitations of first one, and then the other, may be induced.

In very rare cases there is found, accompanied by intense photophobia, nyctalopia, *i. e.*, the power of seeing, reading, &c., tolerably distinctly under very slight illumination. In one case nyctalopia appeared with considerable concentric limitation of the field of vision and intense photophobia, after an injury to the head. Later, nystagmus and epilepsy were added to it. The result was a cure. (*Mooren.*)

b. Another manifestation of hyperæsthesia optica is the appearance of the so-called phosphenes. They occur not only with, but also without, the dazzling sensations, and true photophobia; and, like these symptoms, they are not necessarily connected with the action of objective light, but are even characteristically seen in complete darkness, in perfect amaurosis.

They are usually only the symptoms of a morbid excitation of individual nerve-elements. They are, however, much increased in number, size, and intensity, or even produced, by absolute and relative external irritations.

They depend on slight and temporary hyperæmia, or congestion of the blood. Even the normal circulation and pulsation of the vessels, slight pressure on the eye-ball, concussions, quick lateral movements of the globes, simultaneous sudden contraction of the four recti muscles, an electric current, &c., may cause them.

These subjective symptoms often present themselves as brightly-illuminated white, or colored clouds, rings, &c., which cover a large part of the visual field, and move about in it with various changes in shape. Occasionally, the whole visual field appears filled with a wavy or vibrating mist, whose color is generally bluish-white, but not unfrequently yellow, green, red, &c. Objects are then seen indistinctly through a mist, and are occasionally surrounded by the colors of the rainbow. This phenomenon is described under the name of chromopsia, chrupsia, colored vision.

Generally these phosphenes are seen as bright white or colored flashes, sparks, flames, wheels, spheres, &c., which rise up in various portions of the visual field, and quickly cross over it in very different directions. They more rarely seem to stay in one place, and gradually fade away, without having changed their position. Sometimes they are collected in such a way that they nearly fill the visual field; then it seems to the patient as if he were looking in a thick rain of waving, golden, silver, or fiery drops, or as if there danced before his eyes a sea of flame or melted metal. The usual name for this kind of subjective appearances is photopsia or spintherism.

c. Very recently a very peculiar symptom of hyperæsthesia of the optic nerve and retina, described long since (*Reinicke*, *Ruete*), the so-called flitting scotoma has again attracted attention. (*Förster.*) This seems to occur not uncommonly, appears paroxysmally with or without external cause, at longer or shorter, very irregular intervals, is sometimes announced by attacks of headache, sometimes followed by them, and is, with few exceptions, monolateral. (*Schirmer.*) It is characterized by the sudden appearance of a blind spot in the field of vision, which rapidly increases in size and is bounded by a remarkably bright zone, which either simply glistens or shines in dazzling colored zig-zag lines. As far as the scotoma extends, the perception of objects of the field of vision is completely annulled. The defect in the field of vision appears sometimes as an enlargement of the blind spot (*Ruete*); sometimes it represents a nearly central interruption, which rapidly extends over large parts of the field of vision (*Förster*); sometimes it extends to a whole quadrant of the visual field (*Mannhardt*); and sometimes the half of the visual field is blind, and the affection takes on the form of a hemiopia (*Wollaston*, *Airy*, *Brewster*, *Listing*, *Testelin*). The attacks last, as a rule, only a few minutes, may, however, extend over an hour and more, after which the former power of vision is restored. Hence the name, "amaurosis partialis fugax," has been proposed (*Förster*). The pathogenic factor is probably vaso-motor disturbances in certain central portions of the optic nerve and retina.

d. The morbid increase of the excitability often increases the duration of the reaction to objective irritation. Impressions left on the retina, or after-images, appear more readily, reach very great intensity of illumination, and do not so easily disappear, as in the normal condition.

In suddenly changing the direction of the eyes, it easily occurs that, while another object has come under observation, the impression of the former one is still present, and consequently the after-images are mingled with the impression of the objects still in sight; the perceptions become confused, and, since the after-images change their position with the movements of the eyes, an apparent motion is imparted to the objects which are really at rest. This moving and dancing about of the objects makes the patient dizzy, if the object changes its position a little suddenly. (*Ruete.*)

Very strong and permanent impressions plant themselves firmly in the retina, as it were, so that their after-images remain for days and weeks in the visual field, or they at least appear as soon as the patient thinks of them.

If these impressions were of very varied and varying form, it amounts to an actual chase after subjective visual appearances, each of which seeks to displace the other, and which sometimes simply reproduce the object seen, sometimes combine several impressions with one another under the form of after-images, and sometimes represent to the sensorium very irregular, parti-colored figures, and thus cause the most fantastic visions. (*Ruete.*)

Optical hyperæsthesia is occasionally seen as a symptom of congestion or inflammation of the brain, of drunkenness, poisoning with certain narcotics, &c. (*Mackensie*, *Ruete*), together with neuralgic attacks of the trigeminus (*Alexander*), &c. Sometimes it accompanies the more acute forms of neuro-retinitis, and is one of the premonitions of retinal detachment. It is generally caused and kept up by irritation of the ciliary system. It is then commonly referred to inflammation, and sometimes is a sympathetic affection. It is in the latter case generally associated with concentric limitation of the field of vision, with intense photophobia and limitation of accommodation. But this connection is often wanting, the hyperæsthesia is an immediate result of severe irritation acting on the ciliary system. Straining of the accommodation and of the muscles of convergence exerts a great influence in this respect. In other cases the affection is primarily developed in the retina, and is propagated upon the ciliary system. The most common cause is straining the eye, with intense illumination of the visual field, by direct sunlight, or flickering gaslight, working upon very shiny or light-colored objects, or upon those

which are small and not sufficiently illuminated, especially when these latter move very rapidly. Besides all this, when there is a frequent change in the light, the impairment of vision thus occasioned has a great similarity to asthenopia. Hence the condition has been described as asthenopia of the retina. (*Graefe.*)

This condition is characterized negatively by the absence of any loss of accommodation, or want of power of the muscles of the eye; positively, by the inability to use the eyes in any way, on account of an extremely painful sensation of dazzling, and, with this, an indistinctness of the object viewed, no matter what may be its distance, or the required tension of the muscle of accommodation, and of the recti. Retinal asthenopia, when once developed to a high degree, is generally very obstinate in spite of all care, and the employment of blue glasses, which is so highly esteemed by some. (*Böhm.*) It often lasts for months, and renders the patient unable to pursue any occupation requiring the use of the eyes.

3. Anæsthesia optica is a lessening of the excitability of the retina, independent of any recognizable organic changes. Its principal symptom is the very great weakening of the impression which low degrees of illumination exert upon the eye. This anæsthesia optica is seen under various forms, according to the cause.

a. In the greatest number of cases, it is excessive irritation of the optic nerve and retina which leads to anæsthesia. It seems as if there were a kind of exhaustion or blunting caused, which renders the affected nerve-elements incapable of reacting to moderate light.

Light is one of the chief irritants which come into consideration here. Indeed, misty vision at night, which is so frequent and often even endemic (*hemeralopia*), is nothing more than anæsthesia optica, which has its origin in the long-continued action of strong light upon the eye, but remotely in deficient nutrition and weakness in the functions of the entire nervous system. Snow and moon blindness are intimately connected with it.

Snow-blindness is a very common occurrence in men as well as in domestic animals, who run over the snow and fields of ice among the mountains, in bright sunlight, without having any protection to the eyes from the dazzling reflection. It is characterized sometimes by a rapid, and again by a gradual, darkening of the visual field, which lasts as long as the person affected remains in such inhospitable regions without protection to his eyes, but disappears as he descends where there is no snow, or if the eyes be protected by some material, e. g. black crape or dark glasses. (*Tschudi, Förster.*)

Moon-blindness often appears among sailors, when in the tropics, if they sleep on the deck, under the full light of the moon. It sometimes becomes so intense that the patients on awakening can scarcely recognize daylight and must be led about (*Robinson*).

Intense direct or reflected sunlight, which suddenly meets the eye, or acts on the retina for some time, occasionally causes partial anæsthesia, especially on the center of the retina, which is the part most exposed. This condition is evinced by the dark cloud in the middle of the visual field, which is impermeable, or which, when not so dense, allows the objects to appear through with more or less distinct boundaries and colorings.

The cloud is generally darker the less brightly illuminated is the visual field. When the latter is very light, it often appears colored. It does not disappear entirely when the eyes are closed, but, in some cases, is brighter than the normal surrounding part. It is often ephemeral, only lasting a few hours, disappearing after the night's sleep; but, under other circumstances, it is an extremely troublesome symptom, which affects the patient for weeks and months, until, with proper care of the eyes, it becomes gradually thinner, objects appear clearer and clearer, it breaks up and disappears from the field of vision. Occasionally weakness of the center of the retina remains, which is particularly noticed on going from a light room to a dark one. (*Ed. Jaeger, Schirmer, Mackenzie.*)

b. A stroke of lightning, or mechanical concussion of the eye or brain, may be a cause of optic anæsthesia. It is also believed that severe irritations, in one or other branches of the fifth pair, may lead to similar results.

Unfortunately, only a small portion of these cases have been sufficiently examined, and it is quite probable that very different kinds of affections are classed together, that correspond in the chief symptom, which is the sudden or very rapid diminution, or complete destruction, of the sensitiveness to light. The fact that the impairment of vision often exists for a long time, without any organic changes being recognized with the ophthalmoscope, and also that, after some time, the function of the retina and nerve may be restored, shows that they belong in some degree to the forms of anæsthesia. In such cases, only a concentric narrowing of the visual field remains, without any objective appearances.

The proximal pathogenetic factor of this anæsthesia is still unclear. In the majority of cases, however, it may certainly be referred to vasomotor influences. These are frequently powerful enough to bring about, sooner or later, material changes in the light-perceptive apparatus, which then appear in the form of actual inflammation or of progressive atrophy of the optic nerve, and render it necessary to include the case in question in the category of real amaurosis.

It is certain that the kind of direct injury may be very different in different cases. As to lightning, there are cases known where the disturbance in vision could be referred to the direct influence of the electric current upon the nervous system (*Petrequin*, *Schirmer*). There are others, where the stroke fell at some distance (*Lawrence*), and the anæsthesia optica was due to some other cause, perhaps to excessive dazzling, or a combination of disposing causes; the severe emotion excited (*Graefe*) might be recognized as a cause.

The second variety, the so-called traumatic amaurosis, without any objective appearances, is sometimes caused by a moderately slight blow or fall upon the eye (*Testelin*), sometimes by pressure exerted upon the globe (*Beer*), sometimes by a foreign body springing against the eye and becoming imbedded in the cornea (*Schröter*, *Falko*), sometimes by a fall upon the forehead or by a jump from some height (*Secondi*). In very many cases material changes in the deeper parts of the eye, extravasations of blood in the cavity of the skull, in the choroid, etc., may have given rise to the pathogenetic cause of the disturbance in vision and have reduced the case to an amaurosis in the narrow sense of the word. In the third variety, which is generally described as amaurosis trifacialis, the pathogenic factor is sometimes a neuralgia of the trigeminus in the usual sense of the word (*Hippel*, *Alexander*), more rarely an extensive shrinking cicatrix, or a tumor in the region of the forehead, etc., by which a single branch of the fifth pair, particularly of the frontal nerve, is put upon the stretch. In the latter case very violent reflex spasms in the region of the circular muscle of the lids are usually present (*Beer*, *Mackenzie*). The irritating cause very often seems to proceed from carious teeth, which cause more or less pain (*Beer*, *Hutchinson*, *Hays*, *Wecker*, *Delgado*, *Delestre*, *Witt*, *Geissler*). Without doubt many cases are to be excluded from this amaurosis trifacialis also, as not strictly belonging here, and a portion of these are to be referred by preference to mydriasis (*Mackenzie*, *H. Schmidt*). As a rule, however, we have really to do with a true anæsthesia optica, whose occurrence happens very probably in a reflex manner, since a cure of the disturbance in vision is obtained after removal of the neuralgia of the trigeminus, as well by division of the trunk of the frontal nerve or by removal of the injurious tooth.

c. Anæsthesia optica exceptionally forms a link in a long chain of very changeable and different symptoms, which indicate constitutional disturbance of the nervous system. It is then generally partial, confined to the periphery of the retina. It shows itself by a considerable irregular or concentric narrowing of the visual field, while, as a rule, the central acuteness of vision appears only a little diminished. It is less frequently markedly affected, and all sensitiveness to light is lost. There is seen at the same time a great sensitiveness to objective light, showing that the

affection has a very marked erethitic character. This great excitability causes the central acuteness of vision to increase in the dark, rather than diminish, and especially on placing very dark-colored glasses before the eyes. Such eyes often see quite well where the illumination is not sufficient for normal eyes. Further evidence lies in the fact that both eyes are almost always affected; in the sudden appearance, or in the very rapid development, of the impairment of vision (within a few hours or days); in the evident continuance of the conducting power of that part of the retina which has become anæsthetic, and in the frequent simultaneous appearance of different nerve-symptoms. Thus we often meet with want of cutaneous sensibility, convulsions, hysteria, chorea, and even headache, &c. In some cases, spasm of the accommodation seems to accompany the symptoms. (*Mandelstamm.*) Finally, the diagnosis is assisted by the fact that the disease occurs almost always in women and children, very rarely in men, and then only in those who approach the female or infantile type in temperament and constitution. Besides, the children thus attacked are usually very irritable and nervous. The females are frequently exceedingly hysterical, and the exciting cause is generally some agitation, fright, &c. Children between six and fourteen years old are said to suffer from it most frequently, and in them the retinal hyperæsthesia is often very slight, while it is very prominent in hysterical females. The prognosis is very favorable; the anæsthesia nearly always completely disappears, and it is only rarely that limitations of the periphery of the field of vision remain, even when the disease was characterized by complete blindness. (*Graefe, Haase.*)

The treatment consists in remaining in a dark room for some days, and subsequently wearing blue glasses, with complete avoidance of use of the accommodation. The lactate of zinc, used internally, is said to do good service, and when the eyes have begun to improve, a more vigorous treatment, with abundant exercise in the open air, may be employed, but we are warned from blood-letting. (*Graefe.*)

d. Those cases of amblyopia also deserve special mention, which occur exceptionally in "diphtheritis faucium," with or without limitation of accommodation. (*Benedikt.*) We may here also call attention to those not very uncommon cases of intermittent amaurosis (*Zehender*), which, like the ophthalmia intermittens, seem to be connected with malarial infection.

e. It is undeniable that anæsthesia optica is most frequently caused by exclusion of an eye from binocular vision. It often appears combined with paralysis of the accommodation, which is then indicated by the mikropsia. It has been described under the name *amblyopia exanopsia*, or amplyopia from disuse of the eye.

They are distinguished from the other pathogenetic forms of anæsthesia essentially by the functional integrity of the peripherical zone of the retina, which may generally be demonstrated, and, therefore, by the limitation of the defect to a more or less circumscribed portion of that part of the retinal centre belonging to the common visual field (see strabismus convergens). Moreover, the functional disturbance usually shows itself more by the necessity of large visual angles for distinct vision, less by the necessity for great intensity of illumination. It, therefore, bears more the character of a simple blunted condition.

It is, of course, only monocular, and occurs especially where the indistinct perceptions of one eye render the more distinct ones of the other turbid in binocular vision, so that a formal suppression of the perception of the first eye, in order to get distinct vision, is an absolute necessity. It is, therefore, very frequently observed in

monocular strabismus, as well as in eyes which are affected with opacities of the cornea, or lens, with mydriasis, a want of accommodative power, &c., the other eye being normal, or in much better condition than the one thus affected.

Anæsthesia exanopsia is not apt to reach so high a grade, and yields more readily when no distinct images at all are perceived on the retina, and there is no impairment of the function of the other eye; for example, in fully developed cataract, complete closure of the pupil, or when there are dense and large opacities of the cornea. Childhood is the most common period for the occurrence of such an anæsthesia, the perception of images being then much more easily and quickly suppressed. In more advanced life, the same causes do not so readily lead to impairment of the function of the retina.

Finally, we should speak of the lessening of the acuteness of vision in advanced life. The acuteness of vision becomes markedly less after the twenty-fifth year, and, according to recent investigations (*Vroesom de Haan*), in very old persons it has decreased one half. We do not know how much of this is to be ascribed to actual weakness of the functions or torpor of the nerve-elements; at any rate, the organic changes which the dioptric media, as well as the retina and choroid, undergo from senile alterations in structure, play quite a large part in the loss of vision. These changes must exert an externally unfavorable influence upon the brilliancy and distinctness of the images.

4. Amaurosis and amblyopia, which are by many confounded with anæsthesia, do not depend so much on a lessened excitability of the nerve and retina, for this may be even increased, but they are rather the symptoms of an impairment of function of an organic variety, which is either observed objectively in the beginning, or is seen in the further course of the disease, by the gradual appearance of atrophy of the optic nerve.

Treatment.—The treatment of the functional disturbances described in the preceding pages is naturally to be first of all directed to the main affection. When this is eradicated, or at least brought to a stand-still, the anæsthesia which may have remained, so far as it is independent of any material changes, frequently disappears of itself. Whether the wearing of colored glasses (*Böhm, H. Gerold*) can aid in what is here required, must be proved by further experience. Methodical exercise, as has been recently recommended (*Fronmüller*), is only of use in torpidity of the light-perceptive apparatus resulting from non-use of one eye.

In this sort of exercise, printed types are best suited as visual objects, since in them there is a change from letter to letter, and, therefore, the attention must be directed uninterruptedly to the object, and mistakes, which have slipped into the estimate of what is perceived, appear immediately by the context, and, therefore, invite correction. These printed types must, of course, be well illuminated, and must, moreover, be projected upon the retina under a large visual angle, in default whereof they appear, even in slight torpor of the light-perceptive apparatus, as images which cannot be deciphered. They must, therefore, be chosen large, and be brought near the eye. But in order to see as clearly as possible at short distances, convex glasses are usually needed, as the amblyopia exanopsia is, as a rule, accompanied by weakness of the apparatus of accommodation. Convex glasses are, moreover, under all circumstances very useful, as, by an apparent magnifying of the objects, and by an increase of the apparent brightness of the retinal images, they increase the distinctness of the perceptions and facilitate the choice of test-types. It is, therefore, the custom to employ them in all cases, at least at first, and to distinguish the exercise in general with the name of treatment by convex glasses. The weakest convex glass must here be first ascertained, which enables the affected eye, the other one being closed, to decipher larger printed types (*Jaeger*, No. 12-20) at a distance of from 8-12 inches. With this glass the patient must now undertake, two or three times a day,

exercise in reading, at first for five minutes, but gradually increasing the time, but should never push the attempt so far as to excite symptoms of fatigue, pain, congestion, or inflammation. On the whole this method of treatment, particularly in the higher degrees of amblyopia, demands in many cases great patience and perseverance, as it is often very long before any perceptible effects make their appearance. Finally, however, the power of vision often increases in favorable cases in very rapid progression. It is then time to pass to weaker glasses, and by lengthening the periods of exercise to rise to smaller and smaller test-types. Sometimes the progress is all at once arrested, and the power of vision does not improve, in spite of all that can be done. We should not then lose courage; for all at once it again advances, and we finally are able to employ glasses which are weaker by many numbers, or we may even reach a point where glasses are found to be superfluous. If the eye has become so far cured, that ordinary printed type may be read fluently with weak convex glasses or without any, the reading exercise must still be continued for a time, in order to confirm the cure, and prevent relapses. (*Fronmüller.*)

Authorities.—*Helmholtz*, Karsten's Encyklopädie. IX. S. 200. et seq.—*Young*, ibid. S. 29[illegible] —*Wilson*, *Tyndal*, S. 209, 300.—*Seebeck*, ibid. 294, 299.—*E. Rose*, Virchow's Archiv 16. Bd. S. 233; 18. Bd. S. 15, et seq.; 19. Bd. S. 522, et seq.; 20. Bd. S. 245–290; 28. Bd. S. 30, et seq.; [illegible] Bd. S. 442, A. f. O. VII. 2. S. 72, et seq.; *Poggendorf's* Annalen. 126. Bd. S. 68–86.—*Aubert*, A. f. O. III. 2. S. 38, 42, et seq.—*Schelske*, ibid. IX. 3. S. 39, 49, XI. 1. S. 171.—*Setschenow*, ibid. V. 2. S. 205, 207.—*M. Schultze*, über den gelben Fleck etc. Bonn. 1866. S. 3–16.—*Mackenzie*, Traite d. mal. d. yeux. Traduit p. Warlomont et Testelin. I. Paris, 1856. P. 160–165; II. 56, et seq.—*Ruete*, Lehrb. der Ophth. I. Braunschweig 1853. S. 156, et seq.—*Wartmann*, ibid. S. 184.—*Stellwag*, Ophth. II. S. 629, 649.—*Benedikt*, A. f. O. X. 2. S. 185.—*H. Gerold*, zur Würdigung farbiger Diopter. Giessen 1867. S. 10, et seq.—*M. Tetzer*, Wien. Med. Jahrb. 1864. 5. S. 177, 180.—*Skokalski*, Ann. d'oc. III. S. 201.—*Guepin*, ibid. VI. S. 12.—*A. Weber*, kl. Montbl. 1863. S. 377.—*Hasner*, kl. Vorträge. Prag. 1860. S. 305, 306.—*Böhm*, die Therapie des Auges mittelst farbigen Lichtes. Berlin 1862. S. 18.—*Liersch*, der Symptomen-complex Photophobie. Leipzig, 1860. S. 87.—*Graefe*, A. f. O. I. 1. S. 329, 440; VIII. 2. S. 336; kl. Montbl. 1865. S. 261, 365.—*Tschudi*, Thierleben in der Alpenwelt. Leipzig, 1854. S. 591.—*Förster*, über Hemeralopie etc. Breslau 1857. S. 34.—*Boussingault*, Humboldt's kleinere Schriften. Stuttgart 1853. S. 174, 190, 192.—*Robinson*, Ausland 1858. S. 1080.—*Ed. Jaeger*, Staar und Staaroperationen. Wien. 1854. S. 73.—*Schirmer*, kl. Montbl. 1866. S. 261.—*Sämisch*, ibid. 1864. S. 21.—*Testelin*, ibid. 1865. S. 358, 364.—*Beer*, Lehre von den Krankheiten des Auges. I. Wien. S. 176, et seq.—*Secondi*, Clinica oc. di Genova. Torino 1865. S. 138.—*Himly*, Krankheiten u. Mißbildungen. I. Berlin 1843. S. 85.—*Schneller*, A. f. O. VII. 1. S. 72.—*Petrequin*, *Henrotay*, nach Mackenzie. l. c. II. S. 857, 858.—*Lawrence*, nach Himly. l. c. S. 427.—*Hutchinson*, *Wecker*, *Delgado*, kl. Montbl. 1866. S. 269.—*Hays*, nach Mackenzie. l. c. II. S. 846.—*Haase*, kl. Monatbl. 1866. S. 251, 254.—*Mandelstamm*, Pagenstecher's kl. Beobachtungen. III. Wiesbaden 1866. S. 84.—*Donders*, Anom. der Refr. u. Acc. Wien, 1866. S. 159, 162.—*Vroesom de Haan*, Derde Jaarl. Verslag. Utrecht, 1862. S. 229, 277; kl. Monatbl. 1863. S. 327, 331.—*Functional Diseases of the Optic Nerve and Retina: Page* 654.—*Schelske*, Deutsche klinik. 1865. S. 115.—*Böhm*, Ueber die Anwendung des blauen Doppellichtes. Berlin. 1858.—*Graefe*, Congrès ophth. 1868. S. 60.—*Förster*, kl. Monatbl. 1869. S. 422.—*Wolfe*, Lancet, 1869. I. Nro. 7.—*Preyer*, Pflüger's Arch. f. Phys. I. S. 229.—*Masoart*, Centralbl. 1869. S. 382.—*Alexander*, kl. Monatbl. 1868. S. 42, 43.—*Wollaston*, *Airy*, *Brewster*, *Listing*, ibid. 1867. S. 331.—*Mannhardt*, *Heinicke*, ibid. 1869. S. 427, 428.—*Talko*, ibid. 1868. S. 79.—*Zehender*, ibid. 1867. S. 233, 331.—*Niemetschek*, Prag. Vierteljahrschft. 1868. IV. S. 224.—*Dor*, Zeitschrift f. rat. Med. 32. Bd. S. 599.—*Henle*, *Hasse*, ibid. 29. Bd. S. 250, 272.—*Nagel*, Sammlung gemeinverständlicher wiss. Vorträge. Berlin. IV. 73. Heft.—*Remak*, Deutsche klinik. 1865. S. 116.—*Hüfner*, A. f. O. XIII. 2. S. 309.—*J. J. Müller*, ibid. XV. 2. S. 208.—*H. Schmidt*, ibid. XIV. 1. S. 107.—*Hippel*, ibid. XIII. 1. S. 49, 55 u. f.—*Leber*, ibid. XV. 3. S. 57.—*Mooren*, Ophth. Beob. S. 270, 272, 291; Ueber symp. Ophth. S. 119.—*Geissler*, Schmidt's Jahrbücher. 138. Bd. S. 354.—*Delestre*, Gaz. med. d. Paris. 1869. S. 105.—*Witt*, Centralbl. 1868. S. 447.—*Fronmüller*, Die Convexgläserent. Nürnberg. 1857.—*Berlin*, A. f. O. XIII. 2. S. 305, 306.—*Knapp*, Arch. f. Angen. u. Ohrenheilk. I. S. 7.

1. Night-Blindness—Hemeralopia.

Symptoms—*This disease is characterized by the following symptoms: an abnormally great amount of light is required by the person affected, in order to see distinctly, and there is a decrease in the visual power when the visual field is not illuminated up to a certain amount, which is not proportionate to the want of illumination.* (*Förster.*)

In cases of hemeralopia that are not very severe, the full light of a bright and even of a cloudy day is sufficient, with a proper adjustment of the dioptric apparatus, to allow the affected person to plainly distinguish objects seen under a small visual angle: for example, there is enough light to allow the patient to read small print easily and even continuously. In high degrees of night-blindness, however, it requires the whole light of a very bright day to obtain normal perceptions of light on the eye. The light of a cloudy day, an unfavorable position of the objects to the light, a slight shadow falling upon them, markedly increase the size of the required visual angle, perceptibly weaken the power of distinguishing colors, and diminish the time during which the eyes may be used.

Lateral limitations or interruptions in the visual field are also frequently noticed under such circumstances. In the highest degrees of hemeralopia, which approximate amblyopia, the most favorable conditions of illumination are insufficient for the distinct recognition of objects seen at a small visual angle. A large visual angle and great illumination are then required. Perception of color is usually very much diminished, and interruptions or lateral limitations of the visual field are often observed. (*Förster.*)

If the illumination necessary for clear vision is suddenly diminished to a considerable extent, the decrease of visual power is much more marked than in healthy eyes; hence the hemeralope requires time to accustom himself to the lessened illumination, and even then the clearness of perception is less than in a normal eye. If the intensity of illumination sinks very gradually from this grade, the clearness of perceptions diminishes at first slowly, but this progression is the more rapid, the higher the degree of the hemeralopia. If the brightness be weakened to a certain point, the further decrease of visual power does not occur gradually, but rather with a *bound*, so that often even a scarcely-marked further lessening of the intensity of illumination suffices instantly to render the recognition of objects impossible, or even to remove the sensitiveness to light. (*Förster.*)

The amount of brightness, at which the recognition of objects ceases, varies exceedingly in different individuals, but is usually greater the higher the grade of the hemeralopia, and the longer its duration. In recent and less developed cases, quite dark places or far-advanced twilight are required to render the patient unable to see. In chronic and high degrees of hemeralopia, on the contrary, the visual field is often darkened when there is sufficient light to enable sound eyes to read even small print, or it even occurs that hemeralopes are sometimes obliged to be led, late in the afternoon.

This latter condition is the reason that hemeralopia was long considered as a disease confined to certain hours of the day—a sort of disguised intermittent. This is certainly an incorrect view, for direct observations clearly show, that, in the existence of hemeralopia, a lessening of the amount of illumination at any time of day is sufficient to produce an impairment of vision, except that in the morning, after several hours' sleep, the amount of light required is usually somewhat less, the susceptibility of the retina being increased by the rest. The impairment of vision seems to the patient as a regular, rarely *spotted*, dark-gray to black (exceptionally, colored, purple, red, green, &c.), mist or smoke, which covers the whole visual field and envelops the object. Brilliant, shining objects, and those which contrast with their surroundings, like the moon, the flame of a candle, &c., a white wall, glimmer indistinctly through this mist, and often appear abnormally colored. The moon, for example, may appear purple red.

It is worthy of remark that, in this, as in true amblyopia, pure white, as well as yellow and green light, excite the retina much more easily than blue, violet, and red. (*Förster.*) In severe cases of hemeralopia, the obtuseness of the retina and nerve may be so great that even the moon, and still more the flame of a lamp, is not seen.

The pupil is generally normal, when there is sufficient illumination for distinct vision, not only in diameter, but also in mobility. But if the illumination decreases, the pupil enlarges very much, and it reacts very little, or not at all, to changes in the light. In very severe and old cases of night-blindness, however, we find the pupil always enlarged and torpid. It requires very strong light—direct sun or concentrated lamp light—to excite the pupil to great contraction. (*Förster, Alf. Graefe.*)

The accommodation is then generally considerably limited, and, according to recent investigations, there is a slight insufficiency of the internal recti muscles, that is, an inability to converge strongly. (*Alf. Graefe.*) How much this is influenced by the need of a large visual angle for distinct vision, has not, as yet, been demonstrated. The ophthalmoscope does not generally show any changes in the fundus of the eye, although we often find a considerable injection of the retinal vessels. But this may be properly referred to the coincidental action of the irritation from light, caused by the night-blindness. This is also true of the hyperæmia of the ophthalmic ganglion observed in one case (*Guemar*), and the conjunctival congestion, which quite often accompanies hemeralopia. Some claim to have also observed dryness of the conjunctiva, with fatty degeneration of the epithelial cells. (*Huebbenet.*) If this be a proper explanation for some cases or epidemics, it may also explain the appearance of silver-like, shining spots on the scleral conjunctiva, to which a particular diagnostic importance has been ascribed. (*Bitot.*) Still, it is only an extremely rare appearance. (*Netter.*)

It is yet to be mentioned, that night-blindness often, but by no means always, is developed to the same extent in both eyes. In certain illuminations, one eye often has still, to some extent, distinct perceptions, while the other seems completely clouded over, or some parts of the visual field appear clear, and permit an indirect vision, while in the other eye the whole visual field is enveloped in an impenetrable, dark cloud. (*Förster.*)

Causes.—The immediate cause of hemeralopia is always over-dazzling of the eyes; generally, the effect of intense direct or reflected light. Such an over-dazzling will especially cause the disease when it is unusual, and repeated often, and on each occasion remains a longer time. If a large number of persons are at the same time exposed to the same injurious influences, the hemeralopia often acquires an epidemic or endemic type.

Hence, in many places, numbers of people become night-blind when harvest calls them from their dusky rooms to the field, where they are exposed all day long to the unaccustomed sunlight. In the same way, soldiers are especially affected when in spring or summer they exercise much in the sunlight, or bivouac for days in bright weather; also sailors who are exposed in the tropics for many hours of the day to direct sunlight, or that reflected from the vessel and water. Moreover, hemeralopia is often seen in prisons, poor-houses, &c., where the inhabitants work in the open air without protection from direct sunlight, or are lodged in bright, sunny places.

The influence of very bright light alone, however, scarcely suffices for the development of hemeralopia; for, as a rule, only a certain portion of individuals exposed to the same influences will be affected. On the other hand, the intensity of illumination which acts as a cause of hemeralopia, is not necessarily excessive, but is often too slight to affect a normal eye injuriously in the slightest degree. In order that night-blindness may occur, a certain predisposition is necessary, and this may be sought for in a weakness of the nervous system, or, in other cases, in faulty nutrition of the whole body.

In fact, diseases accompanied by marked depression of the nervous system, but especially scurvy (*Guemar*), malarious cachexia, and liver-complaints, markedly favor the occurrence of hemeralopia. Apart from this, it is chiefly poor, badly-nourished, weak individuals who become night-blind under the action of these causes. Officers, officials, clergymen, and persons in the better walks of life subjected to the same influences, are rarely if ever affected. In flourishing places, where the people are in good circumstances, night-blindness is a very rare disease, even among the common people; but, on the contrary, in very poor, unhealthy fever-districts, especially among the members of the *orthodox* Christian Church, after the forty days' fast, it is a very frequent occurrence. Here it is seen under the form of an annual spring plague. (*Huebbenet*, *Mackenzie*.)

Course.—Hemeralopia usually occurs suddenly, either in the spring or summer, after one or more days spent in the bright sunlight. In the beginning, the center of the retina, which is exposed to the strongest light, is the only part blinded. Then, as twilight comes on, the patient sees a more or less sharply-defined cloud in the middle of the visual field, which compels him to look beyond the objects in order to see them at all distinctly.

More frequently the whole of the visual field is clouded, or all except a circumscribed peripheral portion, which allows indirect vision. If the eye remains exposed to the injurious influences, the characteristic darkening of the visual field continues every evening, and even increases; the density and darkness of the cloud become greater, as well as the amount of illumination necessary for distinct vision, so that the blindness shows itself earlier in the day. This increase of the disease is particularly marked when we have a long period of very clear weather, and the patient is continuously exposed to an excessive amount of light; while, under contrary circumstances, a marked improvement occurs. Continued cloudy weather causes the disease to disappear entirely, and breaks up extensive epidemics. A strong tendency to relapse, however, remains. If the circumstances are continuously unfavorable, the disease lasts for weeks or months, ceasing or lessening only with the approach of autumn or winter. Then it usually appears again, with greater intensity and obstinacy, as spring advances.

Treatment.—This depends on the cause. Protection of the eyes from the action of bright light by shades and dark glasses, but still more by shunning brightly illuminated places, by living in dark chambers, shady court-yards, gardens, woods, &c., and suitable treatment for existing constitutional diseases, with good nourishment, suffice to bring about a cure in a temporarily short time, especially when the case is not very chronic or very severe.

But we attain our end much sooner and more certainly, by keeping the eyes in perfect darkness for a time, by applying a protective bandage, and by taking care that it is not lifted during the day. If there is no guaranty for proper conduct of the patient, we may confine him in a perfectly dark chamber, and feed with nourishing, easily-digested food, wine, &c. Under the continuous use of these means, twenty-four to forty-eight hours, or at most five or six days, suffice for the disappearance of the night-blindness. (*Förster*, *Eitner*.)

It is understood, of course, that, by the above means, the hemeralopia is removed, but not the tendency to relapse. To attain a lasting cure, it is absolutely necessary to protect the patient from dazzling light for a long time after the treatment; hence, we must urge the shunning of brightly-illuminated, particularly sunny, places, and by shades or dark glasses weaken the action of any unavoidable, injurious influences. At the same time, the nutritive condition of the patient is to be raised by good food and suitable regimen. Internal remedies are only successful where actual diseases exist requiring them—as in intermittent fever, scurvy, &c.

The vapor from cooked liver has been for a long time famed as a specific for hemeralopia. (*D'Entrecolle*.) This vapor is to be conducted from the vessel in which the liver is being cooked to the eye through a paper cone. This is done once or twice a day, when the meat is to be eaten by the patient.

Recently cod-liver oil (*Desponts*, *Spengler*, *Lacerda*) and electricity (*Poncet*) have been recommended, as well as the cauterization of the limbus conjunctivalis with the pointed end of a stick of nitrate of silver (*Coindet*).

Authorities.—*Mackenzie*, Traité d. mal. d. yeux. Trad. p. Warlomont et Testelin. II. Paris. 1857. P. 733.—*Stellwag*, Ophth. II. S. 644.—*Förster*, Ueber Hemeralopie. Breslau. 1857. S. 16. et seq.—*Alf. Graefe*, A. f. O. V. 1. S. 112-127.—*Guemar*, Canstatt's Jahresbericht. 1857. III. S. 103. —*Huebbenet*, Prag. Vierteljahrschrift. 76. Bd. Misc. S. 20.—*Bitot*, *Netter*, Gaz. méd. de Paris. 1863. Nr. 31.—*Eitner*, Deutsche Klinik. 1863. Nr. 25.—*D'Entrecolle*, according to Wecker's Etudes ophth. II. Paris. 1867. P. 429.—*Desmorets*, Schmidt's Jahrbücher. 121. Bd. S. 218.—*Desponts*, *Spengler*, kl. Montbl. 1863. S. 136.—*Lacerda*, kl. Monatbl. 1867, S. 232, 238.—*Poncet*, *Coindet*, Schmidt's Jahrbücher, 145. Bd. S. 190.

FOURTH SECTION.

DISEASES OF THE MUSCLES OF THE EYE.

Anatomy and Preliminary Remarks.—The eyeball is moved by six muscles, the four recti and two oblique. The seventh muscle, extending deeply into the orbit, has no effect on the movement of the globe, but acts, by lifting the upper lid, as an antagonist to the orbicularis. The four straight muscles have a tendinous origin from the margin of the optic foramen. The elongated and smooth bellies of the muscles separate from each other in their passage outward, so that if four planes were passed through their breadth, by intersecting each other they would form a somewhat oblique and not quite equilateral pyramid. For a distance the internal rectus muscle runs forward in a direction nearly parallel with the plane of the line bisecting the skull; the external rectus diverges at a greater angle, and the superior and inferior at a smaller.

These muscles, in their course anteriorly, strike the globe just behind its equator, when the visual line is directed exactly forward. They grasp the eyeball at this point, and are inserted by tendons on the anterior half of the sclerotica. The tendons are flat, ribbon-like, from three to four lines wide, and are inserted in a line, curved like an arch, toward the cornea. The centre of this convex line of attachment is about three lines distant from the corneal margin at the insertion the superior and inferior recti, at that of the internal recti at the most two and half lines, but at the external rectus generally more than three lines.

The recti muscles are enveloped in a tendinous sheath throughout their course. This is in fact only a thickening of the fatty orbital connective tissue, and is connected to the *periorbita* by several dense bands. At the point where the muscles meet the globe, the sheath of the muscles unites with the ocular or Tenon's capsule, *tunica vaginalis bulbi.* The muscles then run forward in the ocular capsule, as it were, and perforate this in an oblique direction, just behind the point of insertion, and finally unite with the sclerotica.

The margins of the broad tendons are not united to each other, although there is an indirect union by means of Tenon's capsule, with which the sheaths of the muscles and their tendons are continuous. It is this connection of the muscles and their tendons with the anterior part of the ocular sheath, that keeps a muscle against the globe after division of its tendon, and prevents its complete retraction, and still allows it some influence upon the movements of the globe.

Moreover a firm, moderately thick cord runs from the point of attachment of the tendon of the rectus internus to the connective tissue surrounding the caruncle and unites the latter to the capsule of Tenon, as well as to the tendon of the muscle, from which moreover some tendinous fibers pass over into this cord. This anatomical relation explains the great sinking-in of the caruncle in excursive displacement backwards of the internal rectus (*Luschka*, *Liebreich*).

The superior oblique muscle also originates by a tendon at the margin of the optic foramen. Its thin belly runs between the rectus superior and internus, reaching the trochlea (pulley) at the upper portion of the inner side of the eye. Before

reaching this it passes into a long and thin tendon, which runs over the pulley, is then immediately turned backward and outward, becomes gradually broader, and, running under the superior rectus, spreads out like a fan, and is attached to the sclerotica, after having passed through the capsule at an arch of about three lines long, running backward and outward. The inner end of this arch is about three to four lines from the optic nerve.

The pulley of the superior oblique is a tendino-cartilaginous ring, which is attached to the *spina* or *fovea trochlearis* of the frontal bone by two short bands, and lies close under the outer and inner angle of the orbital border.

The belly of the muscle is surrounded by a delicate sheath. At the point where the muscle becomes tendinous, the structure about it thickens, enveloping the tendon like a tube. It is connected on one side with the trochlea, on the other with the *tunica vaginalis bulbi*, and the muscular sheath of the superior rectus muscle, and thus forms a kind of supensory ligament for the globe.

The inferior oblique arises from the inner and lower portion of the bony orbital border. It first runs outward and backward, and passes between the globe and the inferior rectus, where its sheath is connected to this latter by cellular fibrous tissue. Just here it changes its direction by curving strongly upward and backward. It then reaches the posterior and upper part of the globe on the temporal side, close to its capsule between this and the external rectus. It is inserted here, after having become much broader, and having penetrated the capsule. The line of insertion is convex, upward and anteriorly, and is at least five lines long. Its anterior end is about seven lines, its posterior from two to three lines from the optic nerve.

The arteries of these muscles are all branches of the ophthalmic artery. The veins unite in part with branches of both ophthalmic veins, and in part with branches of the facial.

The nerves which connect the six ocular muscles with the brain are the third, fourth, and sixth cerebral nerves, with branches of the fifth (trifacial) and the sympathetic. The center of the motory power of the eye is to be found in the *pons varolii* and the *medulla oblongata*. As is known, the third pair, *oculomotorius*, supplies the superior, internal, and inferior recti muscles, the levator and the inferior oblique, while the fourth pair supplies the superior oblique, and the sixth (*abducens*), the external rectus.

The third nerve or oculomotorius arises from remarkably large nerve-cells (oculomotorius nucleus) at the bottom of the aqueduct of Sylvius, and the nuclei of both sides lie in the median line very near one another. The bundles of fibers, 9 to 12 in number, proceeding from each nucleus pass downwards and intersect the longitudinal fibers of the crus cerebri. After having joined the motor nerves of the muscle of accommodation and of the sphincter pupillæ, each of which must possess a different nucleus of origin, though perhaps situated very near. The fourth nerve or trochlearis arises behind the corpora quadrigemina from the "valvula cerebelli," the sixth nerve or abducens at the posterior border of the pons Varolii (*Stilling*, *Rüdinger*). The seventh or facialis, which supplies the orbicular muscle of the lids, arises at the external periphery of the medulla oblongata from the ganglia of the formatio reticularis. From here the fibers of origin run in the interior of the medulla oblongata towards the middle of the bottom of the rhomboid fissure (*Rautengrube*), where they form an elevation, which was formerly regarded as the nucleus of origin (*Deuters*, *Rüdinger*).

In a normal condition, all the movements of the eyeball, by the muscles, are revolutions about a point which lies upon the optic axis, that is, upon the straight line uniting the vertex of the corneal ellipsoid to the posterior scleral pole. This

point does not, however, lie exactly in the middle of the line, as was formerly believed, but considerably back of this (*Doyer, Donders, Volkmann*).

The relative position of the center of motion varies within certain limits, according to the conformation of the eye. In emmetropic eyes, the center of motion is found 1.77 millimeters behind the middle of the visual axis. In myopes, it lies somewhat more behind the vertex of the corneal ellipsoid, but at the same time farther from the posterior pole of the sclerotica, so that the relation of the anterior and posterior parts of the optic axis remains nearly the same as in the emmetropic eye. In the shorter, hypermetropic globes, the center of motion is actually not so far back, but, in spite of this, is very much nearer the posterior wall of the eyeball (*Doyer, Donders*).

The pole moreover appears to change its position inside certain limits, according to circumstances. The fixation of the globe is brought about on the one side by the fat-bolster of the orbit, on the other however partially by the tension of the two oblique muscles also, which in their action are opposed in a certain relation to the action of the four straight muscles, but are not able to maintain the equilibrium against these, in so far as, without regard to their slighter size, the direction in which both groups act encloses an angle; hence then the action of the combined six muscles is inwards and backwards. In accordance therewith, we not uncommonly see during operations on restless patients, that the globe recedes somewhat in consequence of spasmodic muscular contractions, and the conjunctiva is pushed forward in the form of a roll from the side of the yielding bolster of fat, especially in the region of the internal angle. It is also claimed that more recent investigations by means of more suitable instruments have established the fact that the globe of the eye projects from the orbit about a millimeter in forced innervation of the levator muscle of the lid, generally when the visual lines stand horizontal and parallel to one another; that this change of position of the eye is however absent, when the elevation of the lid is caused by an external force. It is further believed that the pole remains tolerably fixed only in horizontal movements of the visual lines, that it recedes somewhat however in elevation of the visual plane, and approaches the summit of curvature of the cornea when the visual plane is lowered (*J. J. Müller*). Many have claimed to have found displacements of the pole even during near and distant vision, as well as in conditions of irritation and paralysis of the third pair of nerves (*Coccius*).

It is evident that changes in the position of the center of rotation in connection with the change of the angle, which the axis of the eye encloses with the visual line in different states of accommodation, must influence the position of the individual parts of the retina to the objects inspected. Still this influence upon the act of the retina in adapting itself to surrounding objects is, under ordinary circumstances, so slight and so easily corrected, that it is only under certain conditions that it proves of consequence and must be attended to.

By means of its six muscles the eyeball may be rotated about any axis intersecting the center of motion. There is not the same rotary power in all directions, however. In a horizontal direction it is about 87° on the average, in a perpendicular it varies between 86° and 100°. It is greater inward than outward, and greater downward than upward. It varies with the age, but chiefly according to the formation of the globe, and the position of the center of motion. The greatest amount of motion occurs in emmetropic eyes, a little less in hypermetropic, and the least in very myopic eyes (*Schuerman*). The age of the individual, and particularly the habit, is of essential influence.

In a child, whose pupil was completely covered by dense, extensive spots upon the cornea, the eyes were always so much depressed in behalf of the fixation of external objects, that a segment, scarcely d''' in width, of the superior periphery of the cornea, which had remained transparent, appeared above the edge of the lower lid. In cases of convergent strabismus the eyes are so much turned inwards that the cornea disappears entirely, or in great part, behind the caruncle.

On the whole the excursive capacity of the eyeball is only in small part brought

into play, since greater rotations of the eyes are generally lessened by corresponding movements of the head.

Each movement of the eye results from the combined action of certain muscles, and in an individual case by means of a fixed expenditure of force. This depends in part on the position of the point of rotation, the amount of resistance, etc. It may vary, however, within certain limits.

Still one and the same rotation of the visual line is by no means to be regarded always as the equal movement of the eyes, for it is set in motion by the combined action of various muscles, and determines a very different process of the retina in obtaining a view of things, accordingly as it aims at a change in the visual direction of the parallel visual lines, or at a position of convergence of the latter. In view of this, the direction of the glance in parallel visual lines and the movements of convergence are to be strictly differentiated in the analysis of the separate movements of the eyes.

We must further consider that there is never any period at which one or the other of the six muscles is entirely inactive, but that by its living and elastic tension it aids in guiding a definite movement, even if it does not take direct part in it. The paralysis of a single muscle really renders all excursive movements of the globe less sure, and causes very many of them to be accomplished only under irregular movements, that is to say, not in the right direction. Moreover, in the movements of the eyes, it is not only the power with which a muscle acts, but also the angle at which its line of insertion stands to the axis of its belly, which is of importance. If this angle is not a right angle, the muscle in question, when innervated, will roll it into a position, so far as the hindrances admit, in which all its fibers maintain a uniform tension.

If in total paralysis of the oculomotorius a lowering of the visual line is innervated, the centre of the cornea turns downwards and outwards under the sole action of the superior oblique; with the cessation of this innervation, however, the eye rolls back into the former position, since on the one side the elastic tension of the paralyzed muscles and of the different sheaths comes into account, and on the other side the external rectus strives to equalize the dissimilar tension of its fibers.

From all this it is evident that the position, from which the eye should pass over into another, is the standard in regard to the necessary relative expenditures of force, as well of those muscles which take an active part in the movement as of those which merely regulate it; hence it is necessary to come to an understanding concerning a certain primary position. The horizontal direction of the visual lines parallel to the median plane, with the vertical axis of the head situated perpendicularly, is now almost universally recognized as the primary position.

The median plane of the eye is that which is considered as passing through the vertical axis of the head, and through the center of the base line. The base line is the straight one connecting the point of rotation of both eyes. A plane laid through the base line and the binocular point of fixation, that is, through the two visual lines, is called the *visual plane*, and its line of intersection with the median plane is called the median line.

If the eye, the visual lines being always parallel, be turned directly from the primary position into any other, which will be a "secondary" position, it is done by a rotation upon a single axis, which stands perpendicular to the first and second positions of the visual lines; that is, perpendicular to a line supposed to be drawn

backward from their extremities. In other words, the retina changes in its position in a single direction, and hence does not undergo at the same time, or along with this, a so-called rotary motion; that is, a rotary motion around the visual lines.

The same thing occurs if the eye be turned directly from a secondary position into the primary, or into any other secondary one lying in a straight line passing through the primary; if, for example, the gaze be turned from outward and upward, to inward and downward. It is different, however, if the eye exchanges a secondary position for another which does not lie in a straight line in the direction of the primary position; if, for example, the eye is turned from outward and upward to a direction outward and downward. Such a motion does not take place around a single axis, but on a great number of axes following quickly one upon the other. The retina does not incline in a single direction to the new point of fixation, but undergoes a rotary motion, that is, a rotation about the visual line, in order to finally take the same position again, which it would have had if it had changed from the primary position into the one which would have then been secondary (*Listing*).

In order to avoid errors, it is imperatively necessary to strictly distinguish from each other the positions of the retina, and the conditions of projection of objective images, or after-images (*nachbilder*) artificially excited. If we imagine the eyes in the primary position directed upon a wall, perpendicular to the visual line, and a small star to be drawn on the former, through whose center the visual line passes, every radius of the star will be formed on a particular meridian of the retina. If we now excite an after-image from this star, and if the eye be moved from its primary position into any secondary position, the ray in the course of the gaze, and the one of the after-image standing perpendicular to it, will preserve their original relations. All other rays appear in different positions, and at relatively different angles. In order that the star may present itself as exactly as in the primary position of the eye, the plane of the projection must again be placed in a normal direction to the visual line. In accordance with this, the after-image induced in the primary position of the eye of a line perpendicular to the horizon, can only appear perpendicular to a perpendicular plane wall, when the gaze is turned upward or downward, or horizontally to one side. In all oblique directions it must appear oblique, without any indication of a rotation of the retina about the visual line, but simply because of the changed conditions of projection. But that which is true of after-images, is also true of those which are objective.

The contraction of one of the lateral straight muscles suffices to produce a turning of both visual lines, remaining parallel in an unchanged manner, from the primary position straight inwards or outwards, and the reverse, as the course of these muscles remains during this movement in the horizontal plane.

If we wish to move the eye from its primary position exactly upward or downward and back again, it requires the contraction of a rectus muscle, and of the oblique one lying opposite. Thus the rectus superior, and obliquus inferior, or rectus inferior and obliquus superior, must be used together. The course of the superior and inferior recti deviates from the vertical meridian plane of the eye, which is in the primary position toward the nose, at an angle which opens backward. Hence its traction is directed away from the perpendicular plane, toward the inside, and involves, beside, a rotary motion, that is, a rotation around the visual line. This motion inward, as well as the rotary, can only be neutralized by the traction of an oblique muscle being united with that of the rectus, and is so in reality with a small excess, in so far as the vertical meridians of the eyes diverge upwards when the eye is directed upwards, but converge upwards when the eye is turned downwards. If the eye be turned from the primary position into an oblique secondary position, two recti (lying near each other) and one oblique must act.

But if the visual line be turned outward from this vertical plane, the rotary action of the two recti must be lessened, and that of the oblique increased; the elevating action of the former, on the contrary, must be diminished, and that of the oblique be enlarged, because the visual line approaches the course of the upper and lower rectus, and is removed from the course of the oblique. If then the power be the same with which the superior rectus, and the oblique associated with it, regulate each other in the primary position, and in the perpendicular and horizontal secondary position, and if the visual line also passes from a secondary position into another which does not lie in the direction of the primary, rotary motions must occur. On the other hand, this is again a proof of the unchangeableness of the regulating action; that is, of the identity of the innervation, and with this, of the great simplicity of the combination of impulse acting on the movements of the eye. (*Hering.*)

It is important to observe that most of the movements of the eyes in parallel visual lines are to be regarded as a change between secondary positions, and therefore as rotations, and consequently make the continuance of the oblique muscles in action necessary. In fact the four straight muscles sufficed completely to direct the visual lines of both eyes to any point whatever of the visual space, but by no means to give to both retinæ a definite legitimate knowledge with their surroundings in any position whatever of the eyes.

In positions of convergence the knowledge of the retinæ of surrounding objects is different from what it is in the same visual direction with parallel visual lines; these require therefore the united action of partly different muscles. In general the vertical meridians of the globe undergo, in symmetrical positions of convergence of the visual lines, a rotation in the course of the inferior oblique, so that their upper ends diverge more when the visual plane is elevated, and converge less when the visual plane is lowered, than is the case with parallel visual lines and similar position of the visual plane. The differential angle resulting from this increases with the deviation of the visual plane from the horizontal position and with the deviation of the glance from the median plane (*Hering*).

That this non-acquaintance of surrounding objects manifested by the retinæ does not lead to disturbances of binocular single vision, is explained by the fact that elevations and depressions of the visual plane and changes in the visual direction are only accomplished by the muscles which move the eyes within very narrow limits, but generally are made superfluous by movements of the head, and that slight deviations in the knowledge of the retina for surrounding objects may be easily neutralized by spontaneous corrective movements of rotation.

The innervation which incites the separate movements of the eye is always and unchangeably bilateral, every impulse which is exerted upon the motor apparatus of one eye as a rule compensates corresponding muscular activity in the other eye, and this in such a way, that both retinæ may work together in a certain sense in the binocular visual act. To this extent also both globes may be regarded as a single organ in the sense of a double-eye.

In conformity therewith the twelve muscles of the eyes may be divided into those which rotate the eyes to the right and left, those which lift and lower the eyes, into abductors and adductors, in which every individual muscle in the different groups is naturally called upon to play a part. The internal rectus muscle of one eye acts with the external rectus muscle of the other eye, as rotators to the right or left. In the lowering of the visual plane both inferior recti concur, as well as both superior oblique, the latter with a slight preponderance. In connection with this there always occurs an inclination to convergence of the visual lines, and in those who are not short-sighted probably an accommodative increase of the refraction also. At the same time the upper lid sinks in a corresponding degree, under

the action of the superior half of the orbicularis palpebrarum. The rectus superior and obliquus inferior act as elevators of the visual plane, with which the levator palpebræ superioris is coördinated, whilst at the same time any attempts at convergence and accommodation are lessened. Both interni work together in behalf of attempts at convergence, and at the same time the inferior oblique muscles come into play and the muscle of accommodation together with the sphincter pupillæ are rendered active. In the diverging movements, *i.e.*, in the movements of the eyes which aim at the change of direction of the visual lines from convergence to parallelism, both externi are coördinated and perhaps the superior oblique muscles also, while the muscle of accommodation and the sphincter of the pupil are relaxed.

Each of these coördinated movements is occasioned by a particular individual nerve-impulse, and succeeds under all circumstances in the same regular manner, without, however, voluntary changes in the relative expenditure of force of the separate muscles taking part being excluded. By continual exercise the limits for such corrections may be considerably extended (range of relative accommodation and convergence); it is even possible to produce small degrees of divergence of the visual lines and even rotations (*Hering*, *Nagel*, *Williams*), without the aid of prisms, while otherwise the entire activity of the apparatus which moves the eye is directed to positions of convergence and parallelism of the visual lines, and the isolated innervation of both oblique muscles is excluded. In agreement with the laws of rotation above-mentioned, the number of movement-impulses is markedly limited, they are directed to a turning right or left, to elevation and sinking of the visual plane, as well as to abduction and adduction of the visual lines. By combinations of two or at most of three such impulses, which may possibly affect in part one and the same muscle, every visual direction, visual height and position of convergence may be obtained. Thus if an object lying at a short distance downwards and laterally from the eye were regarded, the innervation of the depressor of the visual plane would be required, the right or left rotator and the muscles of convergence.

On the whole, combined coördinate movements are accomplished with more difficulty, and are confined within certain limits. Thus the visual space is much smaller for binocular single vision, than the scope of the movements of separate visual lines; in other words, the visual lines of every individual eye may be conducted to a point to which the other visual line cannot follow, and hence diplopia results on account of faulty acquaintance of both retinæ with surrounding objects. The limits of the binocular visual space become still narrower, when it is a question, at the same time, of seeing near objects singly, and, therefore, of positions of convergence. In fact a non-acquaintance of the retina with surrounding objects rapidly comes on, if, in fixing near objects, the visual plane should be raised somewhat higher, or the glance should be directed more towards the side, or even if an elevation or lateral turning of the visual line should be combined with positions of convergence. It is these relations which make themselves everywhere felt in the symptomatology of disturbances of mobility, and must be accounted for in the estimate of the latter.

The converging movements are wanting in the new-born child, and the activity of the muscles of the eye is here limited to an active change in the direction of the visual lines. The fixing of objects is a very complex act, in which, besides the convergence, the accommodation and direction of the visual lines concur. It only occurs in the interest of a conscious purpose, namely, in order to obtain the clearest and most distinct perceptions possible of the objects attracting attention,

and with these the premises for further conclusions concerning the relations of the objects to the subject. It, therefore, presupposes on the one hand a certain interest in the object, but, on the other hand, a judgment concerning the "quale" of the impressions previously obtained from the object; for that which is wanting can be supplied by corresponding voluntary muscular activity, only upon the condition that what is unsatisfactory in the impression by false fixation is recognized and correctly estimated. The correcting measure for the direction of the visual lines and for the convergence lies in the acuteness of vision increasing from the periphery towards the centre of the retina, and in the relative position of the double images, which must necessarily appear in false fixation. But the correcting measure for the accommodation coördinated with this lies in the defective sharpness of the images perceived. This requires a much more delicate estimate than the other, as defective sharpness interferes much less with the distinctness of the images than their doubling. The coördinated movements tending to a change in direction of the visual lines proceed symmetrically and legitimately in the new-born child, and even in those born blind. This conformity also lasts during life, even when blindness persists. It is maintained to a certain degree even in nystagmus, since the characteristic movements of the latter are always effected in the course of the rotators to the left and right, or alternately in the course of the two upper and lower oblique muscles.

As consequence of this, the directions of the visual lines and, if analogous conclusions are allowed, the remaining coördinated movements of the eyes also cannot be something assumed, but must be rooted in the relations of the brain-organization. Hence we are compelled to assume certain centres of coördination, which, being irritated in some part of their extent, transmit their state of irritation to a certain number of nerve origins and excite muscular contractions in the radiating region of the motor nerves proceeding from them, whose sum total furnishes a definite single movement. This movement is then naturally the resultant of the relative expenditures of force of the individual muscles, and the absolute power with which it succeeds is dependent upon the intensity of the state of irritation, in which the centre of coördination has been replaced by the nerve-irritation in question.

The necessity for the existence of such centres of coördination is manifested with particular clearness by the wonderful readiness with which the newly-born of certain classes of animals accomplish certain movements, often very complex, indispensable in the struggle for existence, without any previous practice, and in every species of animal according to a definite type. We need but recall the surprising activity which the young of the invertebrate animals, and of the cold-blooded vertebrates, left to themselves, show at the moment when they leave the egg. We should recall further the facility of the nest-builders among birds, of the ruminants, of the solipeds, &c., among the mammals, of rising, walking, running, swimming, &c., soon after birth.

We have further proof of the existence of definite centers of coördination in the occurrence of relative paralyses, in which separate spontaneous or reflex coördinated movements have become completely impracticable in their totality, whilst other coordinated movements, in which the same muscles, and hence the same motor nerves also are in part concerned, proceed with perfectly normal absolute energy, and, therefore, with normal relative expenditures of force of the separate muscles also.

According to the results of physiological experiments, these centres of coördination for the movements of the eyes lie especially in the corpora quadrigemina of the brain, and those for the iris and apparatus of accommodation of the eyes in the

ciliary and intraocular ganglia. The irritation of the first always produces symmetrical movements of both eyes, and in general the right half of the corpora quadrigemina controls the movements of both eyes to the left, and the left half the movements of both eyes to the right. By the irritation of different points of each half we can produce many movements, but always with both eyes at the same time and the same direction. If the irritation lasts longer, the head also turns towards the same side as the eyes. If we divide both halves of the corpora quadrigemina in the median line by a deep incision, the motion is limited to the side of the irritation. (*Adamük.*)

If before the irritation the eyes diverge somewhat downward, as is usual in animals in a state of rest, and if the middle of the anterior portion of the corpora quadrigemina, *i.e.*, in the posterior commissure, be irritated, the axes of the eyes immediately become parallel. If the irritation in the centre, between the anterior corpora, take place more posteriorly, a movement of both eyes upwards with dilatation of the pupil occurs. This upward motion becomes so much the more convergent, the more posteriorly the source of irritation is found. If we irritate the posterior inferior part of the anterior corpora, or if the irritation extend to the floor of the aqueductus sylvii, we get a greater convergence with inclination downwards and contraction of the pupil. The irritation of the free surface of each anterior corpus causes a movement of both eyes towards the opposite side, and besides, whether the irritation take place on the left or right, so much the more upwards, the nearer to the median line the cause of irritation acts, but, on the contrary, downwards, the more the cause of irritation acts externally to the median line. In all these movements the pupil remains unchanged. The sinking of the line of vision with parallel axes has its centre probably at the base of the corpora quadrigemina. The simultaneous irritation of both anterior corpora calls forth movements, such as are observed in nystagmus. A divergence of the axes of the eyes, or an isolated movement of a single eye by irritation of the uninjured corpora can only be produced after division of the corpora by a deep incision in the direction of the median line, or after division of one of the motor nerves of the eye. After division of the oculomotorius great mydriasis always appears, which can be reduced neither by irritation of the corpora quadrigemina nor of the trigeminus. The irritation of the posterior corpora, particularly in the middle, causes very powerful movements of the narcotized animal, with great dilatation of the pupil and a horrible expression to the physiognomy. (*Adamük.*) Practical experience at the sick-bed teaches us that centres of coördination for lateral direction of the visual lines *may also be found in the* corpora striata.

These centres of coördination are in part of a reflex character, and are excited by the optic nerve or by the sensitive fibres of the trigeminus, with which they are connected by central fibres. These innervations, and the movements brought about by them, occur involuntarily, without consciousness, and, therefore, afford no premises for the estimate of the occasional position of the eyes. Such reflex centres have been demonstrated in the inner half of the anterior part of the corpora quadrigemina (*Flourens, Budge*). In addition to these, the ciliary and intraocular ganglia belong to this category.

The centres of the voluntary coördinated movements are, without doubt, connected with the periphery of the brain, as the seat of mental activity, and the point of origin of the impulse of the will, by central nerve-fibres. Their irritation is spontaneous, conscious, and this consciousness involves that of the consequent movement, and, therefore, that of the relative position of the eyes to the body, and indirectly to the external world occasioned by it. There is no need here of a chain of operations of the understanding, but the consciousness of the movement produced by a spontaneous act attaches itself to the idea of free will itself, which is a general attribute of the animal body, and must correspondingly be considered as a

mental act of the most primitive kind. The consciousness has nothing to do with the individual muscles and their peculiar effects, but concerns solely the kind and degree of the voluntarily expended innervation. The estimate of the movement produced by a definite spontaneous innervation and the consequent new position can, in accordance therewith, only be correct, when the conducting power of the muscles in question corresponds in kind and degree to the spontaneous innervation; on the contrary, it becomes false, the conscious position deviates from the real in the same degree by which the conducting power of the muscles differs qualitatively and quantitatively from the effect intended by voluntary innervation.

This consciousness of the occasional, voluntarily expended innervations is one of the primary conditions of the localizing sense of the double eye, in so far as there is included in it the consciousness of the general position of the retinæ and of the accommodation. The other main condition lies in the relations of organization of the retina, and in the relative power of localization of the light-perceiving elements. The latter propagate their impressions by means of an inherent functional energy always in one direction, which is given by the prolongation of their own axis, passes through the point of intersection of the lines of direction, under normal conditions, *i.e.*, in the natural position of the rods and cones, and is, moreover, determined by the situation and angular value of the curve, which unites the element in question with the centre of the retina. The relative power of localization of the retinal elements, therefore, refers solely to points in the eye itself, and is usually shown by the lines of direction. The correct projection of these impressions outwards into absolute space presupposes the consciousness of the occasional position of these points, and of the relative position of the separate elements of the retina to its centre, and, therefore, the consciousness of the visual direction and of the meridian situation of the retina, and further the consciousness of the position of convergence and state of accommodation.

The conscious direction of the common glance, or the visual direction, is the direction in which the object fixed is seen. It is, therefore, also called the direct or main visual direction. It is represented by a line, which we may imagine to be drawn from the apex of the angle of convergence, or from the object of fixation to the centre of the main line. It is this line which comes immediately to consciousness in voluntary visual directions, not the direction of the visual line of each individual line for itself, as the innervation of the motory apparatus of both eyes proceeds from one and the same centre of coördination.

Fig. 110.

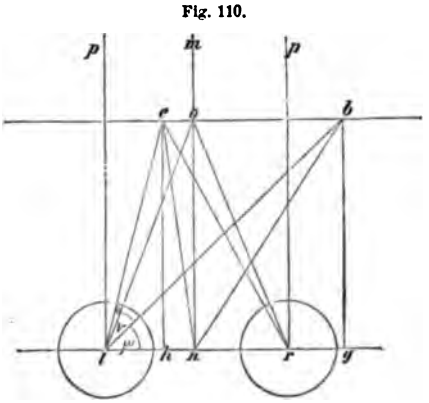

If *l r* (Fig. 110) were the main line, *m n* the median line, and *o*, *e*, *b*, points in space, then *on*, *en*, *bn* would be the visual lines. For an object situated at an indefinite distance in the prolongation of *pp*, the visual line would evidently be *mn*. We see that the visual line bisects the angle of convergence only when the object fixed lies in the median plane.

The consciousness of the position of the meridian of the retina in connection with the relative power of localization of the light-perceptive elements determines the direction in which the eccentric impressions are projected outwards; in other words, the direction in which the images of objects lying eccentrically seem to be arranged around the point of fixation.

Every image that is formed upon the vertical lines of division, or the longitudinal median sections of both retinæ, appears in a plane perpendicular to the visual plane, and situated in the line of vision; and every image that is formed upon the horizontal lines of division, or the transverse median sections of both retinæ, appears in the visual plane itself. The images of any other two meridians lie in a plane of the visual space, passing through this dividing line, whose inclination to the visual plane depends upon the angle which the retinal meridians in question make with the accompanying horizontal line of separation.

We may therefore say, that every intersecting plane of the subjective visual space drawn through the line dividing the angle of convergence into halves, corresponds to a certain pair of "identical meridians." What is true of the individual pairs of meridians, is also true of every two corresponding or identical points of the same; the so-called congruous or identical spots (*deckstellen*) of the retina.

There is added to this a line of common or secondary visual direction. The position of these, with reference to the principal line of vision, is decided in an analogous manner by the segment at which the two identical points deviate from the middle of the retina. We may then make a formula of the law of the "identical visual direction," by saying, that everything which is formed on corresponding positions of the two retinæ, is seen in the same direction. (*Hering.*)

The vertical and horizontal meridians or separating lines of the two retinæ are generally nearly the same, with imaginary perpendicular and horizontal sections through the middle of the retina, in the primary position of the eye. Yet even this is not quite exact, since slight deviations almost always exist. (*Recklinghausen, Hering, Volkmann.*) We therefore do well to invert the definition, as it were, and to designate those meridians as horizontal or oblique which have their common visual direction in the visual plane, or, as the case may be, a plane perpendicular to this.

We must generally consider that these projections, in so far as they are connected with the consciousness of innervation and do not proceed from the relative power of localization of the elements of the retina, are really merely facultative, and express the consciousness of the meridional position of the retina, which is variable under ordinary conditions only within narrow limits; that under certain conditions eccentric points of the retina and meridians deviating considerably from the longitudinal median sections may project their impressions in the chief visual direction and relatively in the meridian plane, provided the position of these points and meridians is a conscious one. The proofs of this are furnished by the power of localization of the deviated eye in pure convergent strabismus (see this article). Still under such relations the binocular visual act and the direct perception of depth are lost.

If one is deceived as to the position of objects in space, or as to the reciprocal position of the visual lines, the impressions of two corresponding points of the two retinæ will be displaced externally, in the same course, although they arise from entirely different objects. If then, in the same direction, both images of the two identical points in question are not seen at the same time, the reason lies in the competition between the retinæ, and also between each of the corresponding parts of the retina, whence it happens that the brain is conscious of that image only which is more prominent on account of its color, sharp outlines, bright contrast with the surroundings, &c., or on account of more attention being given to it. But where

these influences are about equal, both retinal images, sometimes one and sometimes the other, may appear in the common visual line, or a mixed image be recognized. (*Hering.*)

Fig. 111.

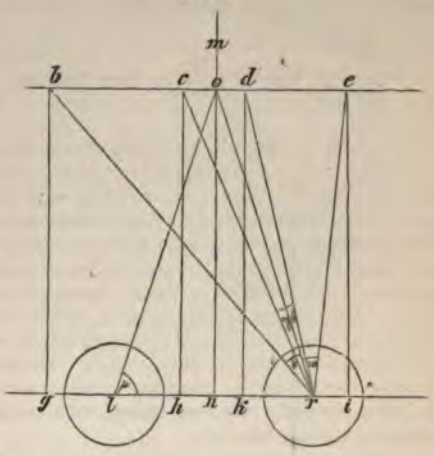

A special example will facilitate the comprehension. Let one eye fix an object o lying in the median plane $m\,n$, the head being in the upright position and the visual line horizontal. Let the visual line of the right eye from any reason whatsoever be deviated in the horizontal direction to the left, to the amount of the angle α or o, and hence directed to the objects c or b. The images of both retinal centers, differing among themselves, will then be displaced in the known common visual direction on, although only the object o fixed in consciousness is usually seen there. The entire monocular field of vision of the deviated eye is herewith naturally turned towards the right around the angle α or o. If now the image of o, which is now thrown upon an eccentric spot of the right retina, is perceived under the form of a phantom image, by overpowering the visual impression of the corresponding spot of the other retina, it must appear in the point d, when $\alpha=\beta$, and relatively in the point e, when $o=\omega$. If the right visual line during conscious fixation were turned from o towards the right to an amount equal to the angle β or ω, and hence directed to d, relatively to e, then the monocular field of vision of the right eye must be turned to the left for a degree equal to the same angle α or o, and the phantom image of o must appear in c, respectively in b.

Now, what holds good for the horizontal deviations of one visual line also holds good for deviations in any other direction, and also for deviations of single meridians, *e. g.*, in consequence of pathological rotations. For example, let the right eye A in the primary position be directed towards a very distant object. Let the vertical line of division $a\,b$ of the retina therefore stand perpendicular to the main line. In the left eye B let the vertical line of division be turned to the left and outwards in the course of the inferior oblique for a distance equal to the angle α, and therefore it would stand in the direction $c\,d$. The longitudinal median section of the left retina will now evidently be met by a line, or better by the image of a line in the visual space, parallel to $c\,d$, which we obtain by drawing a plane through $c\,d$. This oblique line is now in the double eye C, in common with the perpendicular object-line fixed by the left eye, removed into the median plane $m\,n$, and the phantom image of the really vertical object-line seems turned to the right from the median line towards $g\,h$ for a distance equal to the angle $\beta=\alpha$. The respective position of the double images, which come from a point correctly fixed by only one eye, affords a valuable means of determining the deviation of the other visual line, as long as no very considerable rotations of the meridian come into play. The horizontal position of the visual line of the healthy eye and a vertical field of vision being supposed, we obtain the deviation in height by dividing the difference in height of the double images by the distance of the object from the prolongation of the main line. The quotient is the tangent of the angle sought for. In order to find the deviation in width of the line of vision, we must first determine the angle which the line of vision in correct accommodation would enclose with the main line, and then the

Fig. 112.

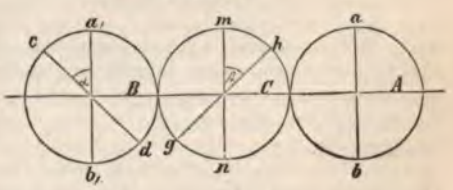

angle which it actually forms with the latter. The difference of both is the angle sought for. For the purpose of ascertaining the tangent of the main angle in correct fixation, the distance of the object is to be divided by the sum, or relatively by the difference of half the main line and of the horizontal distance of the middle point of the object from the median plane. For example, the tangents of the main angles μ, $\mu+\nu$, $\mu+\nu+o$ (Fig. 111), would be as follows:

$$\text{tang. } \mu=\frac{bg}{ln+ob}; \text{ tang. } (\mu+\nu)=\frac{on}{ln}; \text{ tang. } (\mu+\nu+o)=\frac{eh}{ln-eo}.$$

In order to find the tangents of the main angle of the deviated visual line, the same formulæ naturally hold good; yet instead of the horizontal distance of the object from the median plane, that of the phantom image is to be taken, and therefore the perpendiculars from b, c, d, e must be dropped upon the prolongation of the main line towards g, h, k, i. (Fig. 112).

We may lessen very much the labor of the measurement of the horizontal distance apart of double images, if we employ a round black spot, about as large as a copper coin, upon a large sheet of stiff white pasteboard, which is marked on its center with a horizontal scale in inches and lines. The patients generally see the double image on the paper also, and know how to localize it, or at least to indicate it, when a vertical thread fastened upon the cord, and which may be moved from side to side, strikes it. We then have only to read off the distance from the object. If we wish the difference in hight, we only need to turn the card at a right angle to its former position. We may reckon every oblique deviation of the visual line from the ascertained hight and breadth.

Any considerable meridian deviations should, as has been said, be also estimated. It is not difficult to determine these, if we have a horizontal adjustment of the visual line and a vertical visual field. We then only require a vertical line as an object, which is placed in the median plane. The obliquely appearing double image is projected upon the card, and elongated until it intersects the object-line, and gives the angle of deviation by a very simple operation. If, from a point in the double image, a vertical line be drawn upon the line of the object, its length divided by the hight of the right-angled triangle thus enclosed will be the tangent.

The apparatus of Hering renders excellent service in enabling us to read off directly distances of hight and width of the double images, as well as any inclination of them. This apparatus is a black tablet measuring about 6 feet square, which is hung vertically upon a wall by means of rings. At its upper and lower border two rods divided into centimeters or half-inches are fastened firmly in a horizontal direction. On these two rods run other perpendicular rods, likewise divided into centimeters or half-inches, which can be easily moved from side to side. Each of these two perpendicular rods bears a sheath movable in a vertical direction, on the anterior side of which a line about 6″ long and 0.5″ wide is fastened as visual object, the center of which expands into a disk of 1″ diameter. One of these objects is white, the other red, and both may be rotated round the center of their disk. A second disk, firmly united to the sheath, divided into degrees, blackened and immovable, which has a somewhat larger diameter and is only partially covered by the colored one, enables us to read off the angle of rotation of the latter directly. In using it, we have only to see that the visual plane and the median line of the patient distant from six to twelve feet stand exactly perpendicularly to the plane of the blackboard, whilst the patient fixes the central point of the disk of one object. The phantom image of this object belonging to the other eye will now appear at some other point of the board. Towards this point the second object must now be pushed, and be so placed that it is exactly covered in all directions by the phantom image. The difference in hight, width and inclination, which appears in the position of this second object, opposed to that of the fixed object, now gives exactly the deviation of the diverted eye in hight, breadth, and inclination of the meridian, but in the reverse sense.

In all these experiments, turning of the head around the horizontal and vertical axes, which with the naked eye are very difficult to control, become very disturbing, so that the repetition of one and the same experiment furnishes always different and very important results. In order to check this, the apparatus, invented by Helmholtz, would, of course, render the best service. Still in practice this instrument cannot well be applied, as, without regard to anything else, we cannot easily expect the patient to bite into the mouth-piece. We must, there-

fore, content ourselves with a less suitable instrument, though one which renders perfectly satisfactory service for coarser examinations. This is a species of head-band (Fig. 113) of delicate brass plating, which can be fastened to the head posteriorly by means of a buckle, and is well padded. In the middle it runs downwards into a small point, which is placed exactly upon the middle of the root of the nose. Exactly over this is fastened a vertical bar, which carries a horizontal sheath running in the sagittal direction, in which a stiff, straight rod is movable. At the anterior end of the sheath a thread is fastened as plumb-line, which bears a small weight hanging down on a level with the end of the nose. This plumb-line, by its position to the face, enables us to recognize and immediately correct every inclination of the head. The rod, however, serves to confirm the position of the median plane to the black-board and to regulate it according to necessity. For this purpose one of the examiners must place himself behind the patient, and with one eye glance along the rod towards the object of fixation.

Fig. 113.

The third main condition for the localization of the retinal images is the consciousness of the convergence employed for fixation. The actual place of appearance of the point of fixation is not yet determined by the visual direction, but there is still necessary the correct estimate of the distance, and for this the premises are given by the consciousness of the voluntary innervation to convergence necessary for fixation and of the accommodation united with it. Still this consciousness of the innervation to convergence and accommodation is a less exact measure of value, admits more easily of slight deceptions, probably because so much greater differences in the distances of the objects correspond to equal differences in the main angles of the visual lines, and in the conditions of refraction produced by the accommodation, the greater the absolute distance of the object is from the eye. Therefore, for the exact estimate of the distance of the object, certain external aids can with difficulty be dispensed with. To this category belong the relation of the known actual size of the object to the perceived, apparent size, the air-and-light-perspective, &c.

If the position of the object "fixed" be decided, that of all other objects lying in the common visual space of both retinæ, and formed upon them, is also determined. The former then becomes, as it were, the middle point, around which the remaining positions group themselves, in accordance with unchanging laws. Corresponding positions of the two retinæ have not only a common visual direction, that is, a common hight and breadth, but also a fixed depth. If we call the position of the fixation-point the *nuclear-point* of the visual space, and a nominal plane falling through this upon the principal visual direction, the *nuclear surface* of the visual space, we may say that all points of both retinæ, lying to the nasal side of the median line, have a positive perception of depth, all to the temporal side have a negative one; since the former place their impressions beyond the nucleus, the latter, on this side, at a distance which is proportionate to the distance of the images apart, reckoned from the vertical line of separation, and the estimated distance of the nuclear point. The hight of a retinal image is without influence upon the perception of depth. (*Hering.*)

This law shows itself absolutely in the apparent position of false images, that is,

of double images, which, on simultaneous vision of both eyes, proceed from one retina only. Then crossed false images always appear in front, while homonymous ones appear behind the nuclear surface of the visual space.

In binocular retinal images, seen singly, the apparent distance from the nuclear surface is proportionate to their lateral distance apart. In accordance with this, everything appears in the nuclear surface of the visual space, which is formed and seen singly on corresponding portions of the two retinæ, or upon parts at an unequal hight, but, at the same distance, on the same side of the median line. On the contrary, everything appears without the nuclear surface of the visual space, which is formed upon both retinæ at an irregular distance, or upon opposite sides of the median line, and is perceived as a single object. The apparent distance of the binocular image, seen singly, from the nuclear surface, is the greater, the greater its estimated distance, and the greater the difference in breadth of the horizontal line, upon which the two retinal images lie. The image appears in front of the nuclear surface, if the breadth of the temporal meridian of one retina be greater, behind the nuclear surface when the contrary is the case. That which is formed upon pairs of horizontal sections, that is, on nasal or temporal retinal halves of the same breadth, and which is seen singly, appears in the same distance from the nuclear surface of the visual space; in front of the latter, if equal horizontal meridians of the two outer retinal halves are met, and behind it, if equal horizontal meridians of the two inner retinal halves are encountered. (*Hering.*)

We need only a momentary impression upon both retinæ, in order to perceive the value of the depth of the object under consideration. Therefore the correct estimate of depth of momentary impressions, in which all other aids to the estimate of depth are excluded by the rapidity of its passage, furnishes an excellent premise for the estimate of the presence or absence of the binocular visual act. The means to this is the falling experiment. (*Hering.*)

For this purpose the patient looks through a tube, from 1–1½ feet long, one end of which is applied to the face, and is wide enough to include both eyes in its caliber, towards a bare wall, and fixes a fine dark thread, suspended vertically at a slight distance from the other end of the tube. Whilst this is being done, small balls of different size, are allowed to fall one after the other from a height somewhat on the side of the thread, sometimes in front of it, sometimes behind it, so that they pass over the field of vision of the patient included by the tube. Where a common visual act exists, a mistake concerning the position of the direction of the fall to the thread never occurs. In the reverse case, the patients err frequently in repeated attempts, they place the course of the fall sometimes in front of, sometimes behind the thread, when it actually was in front of it. They do not err every time, because the probability of the guess is as 1 : 2. Many of them are even deceived concerning the position of the thread itself, they think it oblique, when it is perpendicular, and perpendicular when it is inclined to the horizon from before backwards. Still this may hold good as confirmation of the extinction of the common visual act, but we can by no means conversely conclude from a correct estimate of the position of the thread the existence of the common visual act. For many persons the consciousness of the altered accommodation, when the glance runs up and down the thread, suffices to confirm the real position of the thread. In the fall-experiment it is of the very greatest importance to exclude the patient entirely from all external aids to the estimate of the depth, he should see no other object but the thread and the falling ball, since this furnishes points of departure for the estimate of the relative position of the course of fall. Therefore, for the same reason, the wall, which cuts off the field of vision behind, must not be figured, spotted nor striped, and must offer no prominent points. For the same reason, the falling balls must be different sizes, because if they are of the same size, the change in the diameter of the retinal image connected with the distance of the course of the fall from the eye can be turned to account in the estimate of the depth. Undertaken with such precautions the

fall-experiment fails but very rarely, and the objections raised against it, as well as those raised against the direct perception of depth (*Donders*), are not tenable (*Hering*).

The physiological laws, according to which the impressions received on the different parts of the retina localize themselves around the nuclear point of the visual space, are approximately in consonance with the purely physical laws according to which the homocentric rays of light proceeding from objects are projected in the form of an image upon the retinas. The consonance is almost complete, in respect to distant objects. Yet the subjective or apparent and actual position of objects close at hand, correspond quite exactly. This is especially true of objects seen in the middle portion of the common visual space, to which the attention is almost exclusively called. But the further an object is removed towards the periphery, the greater is the disproportion, but the less also the distinctness of the perception, and consequently, the impairment of vision caused by the want of consonance in the apparent and actual position. Strictly speaking, the fixation-point only can be seen in its true position. (*Hering.*)

For example, the head being erect, and the visual plane perpendicular, let the middle point o of a sheet of paper xy, suspended very near and lying perpendicular to the horizon, be "fixed" or looked upon by the patient. The paper, presupposing a proper estimation of its distance, evidently lies in the nuclear surface of the subjective visual space. A second point g on the sheet, to the left, in an horizontal direction from the point of fixation, will project its image in both the retinæ, at a point deviating to any point to the right from the middle point c, viz., in f and d, and these points will not be in consonance, inasmuch as the breadth of the right is less than that on the left, because $lo=ro$ and hence sin. ν . sin. μ=sin. o : sin. ($\nu+o$). In accordance with this, the point indirectly seen cannot appear in the nuclear surface of the visual space, that is, in its true position, but must be the farther removed from the visual surface, the farther it stands in reality from the fixation-point, since with it the disparity, that is, the difference in breadth of the two retinal images, increases. But what is true of one point is also true of all the points in a horizontal row made on a sheet of paper. Such a row must be presented as a curve ss, passing through the fixation-point, which turns its convexity toward the eyes. But the individual points of such a curve are formed upon identical portions only of the two retinæ, and appear entirely in the nuclear surface of the subjective visual space, that is, as horizontal lines on the sheet of paper. The results of carefully-conducted physiological experiments correspond to this. (*Hering.*)

Fig. 114.

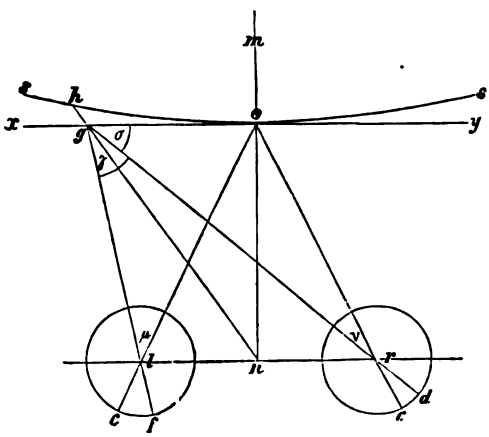

The physical laws, according to which the images of objects lying excentrically, are projected upon both retinas, necessarily involve the fact, that binocular single vision can not be connected with identical impressions on corresponding points of both retinas. If this were the case, only those points in the visual field could be

seen singly, which lie in certain lines and sufaces through the point of fixation. But this contradicts common experience and the results of more exact physiological investigations, and it is especially disproved by the optical effect of the stereoscope. We can only say that binocular single vision of corresponding portions of the two retinas actually occurs, that it is to some extent obligatory, since no kind of practice, or artificial assistance, renders it possible to see the two simultaneous irritations of such points, at the same time, separated, near or behind each other. We may also say that the power of the single sensation extends to different part of both retinas, and may be here called *facultative*, since practice and all kinds of artificial assistances cause an object originally seen single, to appear separated into two false images. Still more, single vision with disconsonant retinal positions is one of the requirements for the solid vision of objects. (*Hering.*)

A line or surface drawn through the point of fixation, all of whose points are formed upon corresponding parts of the two retinæ, is called a *horopter*. All objects seen at the same glance with both eyes appear to be in the plane of the horopter. [The horopter, from ὅρος, *boundary*, and ὄπτομαι, *I see*, is defined to be a line drawn from the point of intersection of the optic axes, and parallel to the line joining the centres of the two pupils; the plane of the horopter to be a plane passing through this line at right angles to that of the optic axes. (*Mackenzie*, after *Aguilonius.*)] A surface passing through the point of fixation, all of whose points are formed upon corresponding horizontal meridians of the two retinæ, is called the horizontal horopter. It is, for objects at a short distance, always a surface of the second degree. If, for example, the vertical line of separation lies vertical to the plane of vision, the horizontal horopter is a cylindrical surface passing through Müller's horopter-circle, and perpendicular to the visual plane. If the vertical lines of separation converge above the horizontal horopter, it becomes a conical surface, with its apex pointing upward, if there be a symmetrical convergent position of the visual lines. In the same way, the sum of the outer points, which project their images upon corresponding oblique sections of the two retinæ, but in general upon disconsonant horizontal meridians, is designated as an oblique horopter. This always forms, for objects at a short distance, a surface of the second degree, which, in the simplest case, passes into two planes, intersecting each other. There are, besides, in the outer space numerous rectilineal surfaces of the second degree, which are so drawn that each straight line contained in them is formed upon correspoding points of both retinæ. These are the so-called partial horopters. By a total horopter we understand the meridian between a horizontal and oblique horopter. For short distances, the visual line being strongly converged, it is always a line whose form and position vary according to circumstances. On looking at objects at a greater distance, the difference in breadth and hight of the portions of the two retinæ met by homocentric rays, disappears more and more; the visual field, as a whole, becomes an horopter, that is, everything appears in the nuclear surface of the visual space, and the transposition of the individual objects at various depths, is the result of an estimation which is induced by the perspective, and which is also the determining measure in monocular perceptions of depth. (*Hering.*)

It remains still to be remarked, that we are only conscious of *voluntary* movements of the eyes. This is not the case in passive and involuntary movements, therefore objects seen under their influence appear to be moving, whether they actually move or are at rest. This is the cause of the dizziness that is apt to occur after rapid turnings and unusual passive movements of the body, e. g. on a ship, in a swing, etc.

Since the involuntary and passive movements of the eyes are not directly perceived, the judgment as to the position of the visual field, as to the rest and movement of the objects, is confused; all the objects in the visual field, and the field itself, appear in motion, and this is vertigo. In the same manner the vertigo is ex-

plained, which occurs in paralysis, spasmodic contraction, or after division of single muscles of the eye.

Since, under such circumstances, the effect of the straining of certain muscles becomes entirely different from what it may have been formerly, the estimation of the relative position of the visual field, and of the rest and movement of objects, is considerably impaired.

Still it should be remarked, that under such relations the vertigo, as a rule, only appears when a greater number of muscles or nerves are not in a condition to answer voluntary innervations with the corresponding amount of force, or relatively to conduct these innervations unweakened to the muscles. Therefore the vertigo also occurs generally in paralysis of the oculomotorius, whose region of radiation is proportionately very considerable. Still it should not be concealed, that complete paralysis of the oculomotorius of the one side by no means always leads to vertigo, even when the eye in question is the only one which can be used. In fact cases occur in which with complete blindness of the one eye, paralysis of the motor nerves of the other eye, paralysis of both of the third pair of cranial nerves, even of all the motor nerves of the eyes, have never led to vertigo, even when they have occurred suddenly. Of course the dimensions of depth are wanting to such patients, and most of them also project the visual line falsely; still there is rapidly developed in them the power of estimating tolerably correctly the difference between the voluntarily innervated and actually resulting movements of the eye and therefore also of guiding themselves and of pursuing their business. It appears that the constraint in exclusive functional ability of the paralyzed eye hastens and sharpens this capacity for estimation, since in functional ability of both eyes, the disturbance of the common visual act by double images and vertigo usually lasts very long, and disappears very gradually only by suppression of the phantom images, and by the development of a new power in the peripherical parts of the deviated retina belonging to the monocular visual field, to acquaint themselves with surrounding objects.

Nosology.—The functional defects of the muscles of the eyes are sometimes the symptoms of disturbed co-ordinate relations, and sometimes are to be regarded as spasms in the narrower sense of the word, or as actual paralyses.

1. Among the disturbances of co-ordination, squint stands at the head as regards practical importance. Under this name are included two conditions essentially different from one another. In the one the range of convergence is as a rule increased, and the affection is characterized by an over-amount of convergence, which is spontaneously and consciously co-ordinated to the purpose by the innervation of a definite amount or of every amount of accommodation, in order the more easily to introduce them and maintain them (strabismus convergens). In the other form the range of convergence appears very much diminished or reduced to zero, the introduction and maintenance of definite amounts of convergence are rendered very difficult, easily lead to asthenopic troubles (asthenopia muscularis), and finally to deviation of one visual line in the horizontal or diagonal direction outwards. The movements of convergence are moreover, in both varieties of squint, less regular inside certain limits; the visual direction, on the contrary, seems in no wise confused, as long as no secondary changes have appeared in the muscles moving the eyes, and as long as the muscles do not have to contend with increased resistance.

2. The complete freedem of the visual movements distinguishes strabismus from luscitas or from the oblique position of the eyes. In this latter defect the excursive capacity of the globe in one or in several directions is more or less limited, whereby it is immaterial whether the innervation aims at changes in the visual direction or in the convergence. In the highest degrees the globe stands entirely motionless. The diseased eye does not therefore follow the excursions of the other

in a corresponding manner, but remains behind in certain or in all directions of the axis of the latter. The luscitas is according to circumstances a symptom expressive of very manifold conditions. Here belong: abnormal diminution and staphylomatous distention of the globe, deposits upon the external wall of the globe, formation of tumors in the orbit, narrowing of the latter, various affections of the muscles, particularly spasm and paralysis.

3. It should not here be overlooked, that the form of the eyes may under certain conditions bring with it an apparent oblique position of the axes or an apparent strabismus. If the angle, which the visual lines inclose with the axes of the corneæ, is to some extent more considerable, then in the fixation of distant objects, that is, in the parallel position of the visual lines, the centers of the corneæ evidently deviate on both sides outwards or inwards, according as the angle α itself is positive or negative.

4. In another series of cases the visual direction as well as the convergence is completely free, but the quiet fixation of objects is impossible in most or all of the relative positions of the latter; the patient cannot fix the visual lines upon one point of the field of vision; both eyes oscillate during fixation and in a thoughtless look in an entirely symmetrical manner alternately in the course of the external or internal rectus muscle, or in the course of the two superior and inferior oblique muscles, or in a course combined from both, by means of involuntary, extremely rapid, and almost rhythmical, alternating innervations of the muscles in question (Nystagmus).

5. Finally, we meet with cases in which definite co-ordinated movements are partially or entirely impracticable, while the other co-ordinated movements, even those in which the same nerves and muscles take an active part, are accomplished with completely normal power and continuance (relative paralyses). Their pathogenetic factor cannot possibly be sought in functional impediments to the nerves in question, and their central nuclei of origin, but must lie in morbid conditions of certain centers of co-ordination subject to the will or of a reflex nature, as in fact more recent physiological experiments have demonstrated.

If the trunk or the nucleus of origin of the nerves in question were hindered in the conducting power, then the effect of the corresponding muscles must remain behind the innervated measure under all circumstances, in every kind of innervation, which is only the case in absolute paralysis.

Such relative paralyses of the most manifold kind occur in Basedow's disease, and are here referred to circumscribed paralytic dilatations of the vessels in the central organs. Many of the disturbances in motility occurring in diphtheritis faucium also seem to belong to this category. Paralyzed states of the levator and converging muscles are moreover exceptionally observed as apparently primary. Strictly speaking, the disturbance in motility of the iris occasioned by local applications of mydriatics is also to be reckoned here, since the internal muscles presided over by the oculo-pupillary branches of the third pair of cranial nerves seem paralyzed to all innervations coming from the brain, but react very powerfully and continuously to reflex impulses, which are brought to bear upon them by means of the ciliary and intra-ocular ganglia.

6. True spasm rarely occurs in all the six muscles of the eye at one time.

Clonic spasms are sometimes observed under the form of excursive movements, as symptoms of lead-poisoning; in cerebral and meningeal disease, and particularly in children, as an accompaniment of basilar meningitis; in chorea, &c.

Tonic spasm of the muscles of the eye occurs as a symptom of tetanus, of epilepsy, of

eclampsia, in extremely exceptional cases as a purely local disease, in consequence of injuries in the region of the eye, or of the eye itself. All the ocular muscles then generally appear spasmodically contracted, or at least the most of them (*ophthalmospasmus, tetanus oculi*). The globe, in the latter case, looks fixedly forward, or somewhat obliquely. It has generally receded into the orbit, and at times so much so, that the conjunctiva lies over the cornea in folds (*enophthalmos spasticus*). The lids are then generally wide open, more rarely spasmodically closed, but in all cases immovable. The spasmodic affection of the palpebral muscles is seen by this latter symptom; at times there is spasm of the levator, at others of the orbicularis.

Spasm of the orbicularis muscle of the lid is very common. It appears both in a clonic and tonic form.

Clonic spasm in the orbicularis is often confined to individual bundles, and causes a peculiar tremulousness connected with a drawing sensation of individual parts of the lids. In other cases the whole muscle is affected with clonic spasm. The result is then the so-called *nictitation*, spasmodic winking, a rapid variation between opening and closing the lids, but in which the latter action always predominates, because it is accomplished with more power, and is done very quickly, while opening the lids is done slowly and imperfectly. It is frequently only the result of habit.

Tonic spasm of the orbicularis (*blepharo-spasm*) is sometimes continuous, lasting for days and weeks, and even months, during the waking hours of the patient. At times it appears in spontaneous attacks. It is frequently excited by certain external influences, and may be interrupted by others. It is generally so severe that it requires great force to open the lids, and this induces severe pain. Not unfrequently it must be ascribed to intracranial disease; it generally has a peripheral origin.

It is then to be referred to abnormal reflex action on the part of one of the branches of the fifth pair. The point of origin is often a diseased center in some part of the ramification of the trifacial, and its continuance is connected with this, since it disappears when the main affection is cured, or at least when the excited condition of the sensory nerve is removed. Occasionally, however, the spasm continues after the primary morbid process has been subdued. It perhaps even increases or extends upon the other nerve-tracts, and finally crops out in epileptiform attacks. (*Graefe*).

Not unfrequently blepharo-spasm arises without having any evident diseased center. It has, from the beginning, the characteristics of an independent disease (*idiopathic blepharo-spasm. Arlt.*) In cases of the latter kind, it appears as if the proximate cause were to be looked for in a kind of muscular hyperæsthesia; that is, in a morbidly excited condition of those delicate nerve-twigs which run backward from the branches of the fifth pair to the orbicularis palpebrarum, and ramify in it. (*Graefe.*) We very frequently find places in the branches of the trifacial on the forehead, cheeks, etc., which only need to be pressed upon in order to excite spasm, which lasts as long as the pressure is exerted. But where we can not find such a point of pressure, the supposition is not entirely unjustified that the seat of the disease is at a less accessible point, and therefore cannot be located with certainty. It is remarkable that the employment of certain muscles will sometimes break up blepharo-spasm; for instance, the action of whistling (*Arlt.*), inspiration. (*Benedikt.*)

The sensory nerves of the cornea and conjunctiva most frequently reflect their pathological conditions of excitation to the orbicularis; hence blepharo-spasm is almost always a symptom in a keratitis accompanied by great ciliary irritation. If the cornea be injured, or a foreign

body remains in the conjunctival sac, it is then accompanied by photophobia, and not unfrequently causes entropion. It usually subsides with the removal of the irritation, and rarely leaves a very obstinate muscular hyperæsthesia behind. In other cases the spasmodic irritation, or the muscular hyperæsthesia caused by the blepharo-spasm, proceeds from the frontal nerve. This is very sensitive to pressure (*Secondi*), or a true supraorbital neuralgia exists, each of whose attacks ends with spasm of the lids, and in the subsequent course of the disease is less and less painful, while the spasms increase in severity and duration. In one case the affection originated in the lingual nerve. There was an extensive ulcer; on pressing this, spasm was immediately excited. In another case the lingual and inferior maxillary nerves were the points of origin of the blepharo-spasm. (*Graefe.*)

The treatment is evidently to be directed toward the subjugation of the main disease, and lessening the nervous irritability. Hypodermic injections of morphia, in the vicinity of the frontal nerve, or at any point of pressure, are particularly to be recommended. (*Graefe.*) Their use is only palliative, simply acting as far as the lessening of the nervous irritation may favor resolution of the morbid conditions. It accomplishes the most, however, when the spasm depends on simple muscular hyperæsthesia, when it has arisen spontaneously, or remains after the subsidence of some other disease. The result is then not unfrequently a true cure. The remedy often proves efficacious in the existence of supraorbital neuralgia and of blepharo-spasm depending upon it. When it fails, in many cases, we may expect favorable results from the constant current of electricity, especially in cases that are connected with neuralgia. (*Remak.*) On the whole, however, electricity seems to promise little in blepharospasm. (*Benedikt.*) As a last resort in cases of the latter kind, the division of the affected branch of the fifth pair may be tried. It often is of real assistance without causing the permanent loss of sensibility in the part. Unfortunately, however, it is not entirely reliable, since with the return of sensation the spasm often returns. Excision of a part of the nerve does not render the cure any more certain than its division. (*Graefe.*)

Spasms confined to the *levator palpebræ superioris*, are only very rarely observed. They appear as spastic lagophthalmos (spasmodic hare's-eye), that is, there is a drawing upward of the upper lid, and a very wide opening of the palpebral fissure produced by this. The great resistance which the lid offers to any external force acting upon it, is then very characteristic.

6. In contrast with spasms, real and absolute paralysis of the muscles of the eyes are tolerably frequently observed. It is here not only the force with which the muscle contracts, which appears limited, but also the amount of retraction, and, therefore, the excursive capacity of the globe in the course of the muscle or group of muscles in question seems diminished. The disturbance manifests itself without exception in all innervations, no matter whence they come, and hence the pathogenetic factor of the hindrance to conduction must be sought in the trunk or in the branches, or finally in the nucleus of origin of the nerves.

We distinguish from the so-called cases of insufficiency, by which we understand a species of weakness, a minor amount of capability of performance, by means of which separate muscles or groups of muscles are not in a condition to satisfy greater demands upon their power, particularly to maintain fixed positions of the visual lines. It is, however, here solely a question of disturbance of innervation, and not of disease of the muscles. There is a great deal said of insufficiency of the internal straight muscles (see strabismus divergens), but insufficiency of the external straight muscles of the eyes has also been observed, in connection with asthenopic troubles (*Knapp*, *Loring*), and even a simultaneous insufficiency of the internal and external straight muscles. (*Kugel.*)

The degree of the paralysis is of course exceedingly variable. The extent of the paralyzed portion also varies greatly. Undoubtedly, parts of a single muscle may fall into a state of paralysis. Again, we frequently find groups of muscles, and

occasionally even all the muscles of the eye, more or less completely paralyzed. Not very unfrequently the paralyzed region extends far beyond the orbit.

Paralysis of the muscles of the eye is most frequently found combined with paralysis of the elevator of the upper lid. The result is then the so-called ptosis, falling down of the upper eye-lid, an inability to elevate it sufficiently and thus to widely open the palpebral fissure. This affection also appears sometimes as an independent disease, and then can not always be referred to hindrance of conduction in the nerve-trunks belonging to it, but occasionally it depends upon congenital deficiency or variously-caused disturbances of nutrition in the muscle itself.

Paralytic ptosis should be, besides, well distinguished from sinking of the lid as a result of increased resistance. Such fallings of the lids are constant symptoms in inflammatory or hypertrophic swelling of the conjunctiva, of the integument of the lid, and of the accompanying subcutaneous or submucous loose connective tissue. It is also always found in epicanthus and epiblepharon, that is, in congenital excessive development of the integument in the inner angle of the lid, which at times goes so far that the canthus, and even a part of the inner half of the palpebral fissure, is actually covered. (*Ammon*, *Graefe*.)

The ptosis which accompanies myosis is also to be remembered here, which has its origin in the obstructions to the conducting power of the sympathetic branches belonging to the organic muscle of the upper lid and to the muscles of the iris, and which may, therefore, be described as ptosis sympathetica.

Complications with paralysis of the orbicularis, supplied by the seventh pair, are more rare. But a paralysis of this muscle often occurs as an independent muscular affection, as well as in consequence of hindrances in conduction to the facial nerve. Lower grades of paresis often betray themselves only by the inability to close the lids powerfully, or to throw the integument into numerous folds, as well as by marked impairment in the conduction of the tears, which may be often removed by slitting up the lachrymal canaliculi. In severe grades the closure of the lids is impossible. When the levator is not in action, for example during sleep, the palpebral fissure remains half open, the upper eye-lid lies loosely on the globe, while the lower lid generally stands off from the globe, or is even everted. Therefore a greater portion of the surface of the eyeball remains exposed (paralytic or atonic lagophthalmos).

This denudation of the globe is frequently borne for a very considerable length of time, without any great amount of irritation being experienced in the globe or its surroundings. Sometimes, however, violent inflammation of the conjunctiva and cornea soon occur (*O. Weber*), and even ulceration of the latter, and here it is often difficult to decide, whether the lagophthalmus in itself or combined obstructions to the conducting power of the nerves regulating the nutrient relations of the eye must be regarded as the actual source.

The cause of paralysis of the facial nerve is doubtless most frequently a rheumatic affection of the sheaths of the nerves. In other cases an otitis media or parotitis, a morbid deposit in the region of the Fallopian canal, a tumor at the base of the skull, a morbid deposit in the pons Varolii or in the central ganglia, even in the cortical part of the brain, but rarely hysteria has been proved to be the actual cause (*Benedikt*). It is an important fact, that in central affections, the paralysis of the orbicular muscle and that of the respiratory muscles of the face frequently occur isolated, which is explained by the anatomically demonstrated existence of two distinct nuclei of origin, and from the later union of the fibres springing from them into a common trunk. No less worthy of mention is the occurrence of relative paralysis in this region. The voluntary and the forced contractions of the muscles dependent upon the facial nerve often appear in very different degrees, or may even be alone paralyzed. (*Benedikt*.)

A paralysis of both lids, blepharoplegia, is always a symptom of a widely-spread pathological process in the brain, and is on the whole rare.

Authorities.—*Anatomy* and preliminary remarks; *Listing*, Ruete's Lehrbuch der Ophth. I. Braunschweig 1853. S. 37.—*Hering*, Beiträge zur Physiologie. I.—V. Leipzig 1861-1864; Archiv. f. Anat. u. Physiol. 1864. S. 27-51, 278-285, 303-319, 1865. S. 79-97, 152-165; Verbal communications.—*Helmholtz*, A. f. O. IX. 2. S. 1853-214, X. 1. S. 160; Karsten's Encyklopädie. IX. S. 457-856.—*Ruete*, Lehrb. d. Ophth. I. S. 25-49; Einnenes Ophthalmotrop. Leipzig 1857; Festrede ad memor. E. G. Bosii. Leipzig 1857; kl. Monatbl. 1864. S. 386; Congress intern. de Paris. 1863. P. 74.—*Donders*, Holländ. Beiträge zu den anat. u. phys. Wiss. I. 1848, nach Graefe A. f. O. I. 1. S. 26, 34-41; Derde Jaarl. Verslag. Utrecht. 1862. S. 209; Anom. der Acc. u. Refr. Wien. 1866. S. 152; A. f. O. IX. 1. S. 103-110. [Anomalies of Accommodation and Refraction. New Sydenham Soc., London, p. 182.] *Fick*, Zeitschr. f. rat. Medicin. IV. S. 101, V. S. 331.—*G. Meissner*, Beitr. z. Phys. d. Sehorganes. Leipzig 1854; A. f. O. II. 1. S. 1-123.—*H. Meyer*, A. f. O. II. 2. S. 77-94.—*Panum*, Ueber das Sehen mit zwei Augen. Kiel 1858.—*Hasner*, Ueber das Binocularsehen. Prag. 1859.—*Wundt*, Zeitschr. f. rat. Medicin. VII. S. 321-396, A. f. O. VIII. 2. S. 11-14; Beiträge z. Theorie d. Sinneswahrnehmung. Leipzig u. Heidelberg 1862.—*Fechner*, Ueber einige Verhältnisse des Binocularsehlns. Leipzig. 1860.—*Cornelius*, Zur Theorie des Sehens. Halle 1864.—*Nagel*, Das Sehen mit zwei Augen. Leipzig u. Heidelberg 1861; kl. Monatbl. 1864. S. 388.—*Volkmann*, Phys, Untersuchgn. im Gebiete d. Optik. Leipzig. I. 1863. II. 1864.—*Recklinghausen*, A. f. O. V. 2. S. 127-179.—*Graefe*, A. f. O. I. 1. S. 1, 4, 7, 10, 19, 23, 32-35, 38, 41, I. 2. S. 290.—*Bahr*, ibid. VIII. 2. S. 179-184.—*Henke*, ibid. X. 2. S. 181.—*Böttcker*, ibid. XII. 2. S. 23-99.—*Doyer*, Derde Jaarl. Versl. Utrecht. 1862. S. 209, 217, 219, 221, 223, 227.—*Schuerman*, Vijfde Jaarl. Versl. Utrecht 1864. S. 1, 13, 27, 31, 50; kl. Monatbl. 1864. S. 92, 95, 100.—*Knapp*, Dritt. Jahresber. Heidelberg 1865. S. 17.—*Diseases of the Ocular Muscles: Page* 699. *Anatomy and Preliminary Remarks: Listing*, kl. Monatbl. 1870. S. 29.—*Hering*, Die Lehre vom binocularen Sehen. Leipzig. 1868; A. f. O. XIV. 1. S. 1; XV. 1. S. 1.—*Donders*, A. f. O. XIII. 1. S. 1; Het tienjarig bestaan etc. Utrecht. 1869. S. 111.—*Nagel*, A. f. O. XIV. 2. S. 228.—*Volkmann*, Verhandlungen der Leipziger Ges. d. Wiss. 1869. S. 28.—*Stilling*, *Deiters*, nach *Rüdinger*, Die anat. d. menschl. Gehirnnerven. München. 1868. S. 12, 15, 17, 39.—*Luschka*, nach Nagel, A. f. O. XIII. 2. S. 408.—*J. J. Müller*, ibid. XIV. 3. S. 183; Centralbl. 1868. S. 803.—*Liebreich*, Arch. f. Augen u. Ohrenkeilkde. I. S. 63.—*Coccius*, Der Mechan. d. acc. Leipzig. 1868. S. 26, 53, 54, 85.—*Flourens*, *Budge*, Ueber die Bewegung d. Iris. Braunschweiz. 1854. S. 130.—*Stellwag*, Der intraoc. Druck. 1868. S. 88.—*Magni*, Rivista clinica. 1868.—*Schweigger*, kl. Monatbl. 1867. S. 28.—*Alf. Graefe*, A. f. O. XI. 2. S. 1. u. f.—*Williams*, Schmidt's Jahrb. 134. Bd. S. 216.—*Nosology: Schiess-Gemusens*, kl. Monatbl. 1867. S. 79.—*Schirmer*, ibid. 1869. S. 409.—*Stilling*, A. f. O. XIV. 1. S. 97.—*O. Weber*, Deutsche *Klinik*, 1867. Nr. 25.—*Stellwag*, Wiener Med. Jahrb. 1869. 2. S. 25-46.—*Knapp*, Klin. Monatbl. 1863. S. 478.—*Nagel*, A. f. O. XII. 1. S. 66.—*Benedikt*, Elektrotherapie. Wien. 1868. S. 138, 274, 279, 414.—*Nosology: Graefe*, A. f. O. I. 1. S. 82, 95, 97, 105, 107, 109, 113, 116, 435, 440, 445, 447, 449, I. 2. S. 294, IV. 2. S. 184, 190, 192, 194, 197, 199, IX. 2. S. 57, 73; Deutsche Klinik. 1865. Nr. 22. S. 216, 217.—*Remak*, Deutsche Klinik. ibid.—*Alf. Graefe*, Klin. Analyse d. Motillitätsstörungen des Auges. Berlin 1858. S. 228.—*Donders*, Anomalien etc. S. 210.—*Arlt*, Krankhtn. d. Auges. III. Prag. 1856. S. 333, 334; Zeitschr. der Wien. Aerzte 1861. Wochenbl. Nr. 25. S. 202.—*Secondi*, Clinica oc. di Genova. Torino 1865. P. 127.—*Rydel*, Wien. med. Jahrb. 1866. 4. S. 74.—*Ammon*, Der Epicanthus und das Epiblepharon. Erlangen 1860.—[*Mackenzie*, Physiology of Vision, p. 254.]

Convergent Squint.

Symptoms.—*The affection is characterized by the excessive convergence of the visual lines [but only in the binocular visual act; when the healthy eye is covered, the squinting eye may be made to move freely in every direction].*

1. The faulty position of one visual line, directed to the object of fixation, shows itself in many cases constantly in one eye, and the strabismus is then monocular. In other cases sometimes one eye deviates, sometimes the other, whilst the other fixes, and the strabismus is then binocular, or alternating.

The squint in pure cases, and especially in those which have not existed long, cannot be observed after death, during deep sleep or deep narcosis. When the patient is awake it becomes generally perceptible either under all conditions or only in concentrated fixation of an object, when an amount of accommodation rather above a definite quantity is to be employed; the strabismus is therefore sometimes constant, continual, sometimes intercurrent and periodic.

In alternating strabismus it often happens that during the fixation of near objects the one eye always squints, and during the fixation of distant objects the other eye always squints; or that in observing objects situated in a certain direction laterally in the visual field, a certain eye is always turned in.

2. The angle of squint varies very much in size in different cases, and also in one and the same case, according to the prevailing relations within tolerably wide limits, as more exact investigations have demonstrated as opposed to the views hitherto held.

By the squint angle we do not understand, as many believe, the angle which the two visual lines enclose with one another, or in other words the ever-variable angle of convergence; but rather the difference of the two main angles, *i.e.*, that angle which the visual line of the fixing and deviated eye incloses with the main line, in fixing an object situated in the median plane.

The size of the squint-angle is dependent as well upon the amount of convergence necessary to the fixation of an object, as upon the visual direction.

If a suitable object within the median plane is gradually brought near the eyes of the patient, we in fact observe very frequently, that only the healthy eye makes proportionate movements of adduction within the normal range of convergence, but the squinting eye does not; its movements soon become very irregular, and finally entirely cease, so that the two visual lines come into an entirely different opposing position.

In a lower degree of strabismus, the squinting eye, it is true, follows the fixing eye up to a certain limit, so that the angle of squint does not seem essentially changed. If, however, the object is brought still nearer, the squinting eye falls into irregular, jerking movements, turns inwards spasmodically, springs back however to a certain extent, until it becomes fixed in a definite position, and therefore repeats exactly the behavior of normal eyes, when the object of fixation is brought inside the limit of the natural range of convergence. The examination then always shows a considerable lessening of the deviation. This is frequently even zero,

and in very short distances has even become negative, and the visual line of the squinting eye falls behind the point of fixation. In other cases, the squinting eye follows immediately the object advancing in the median plane inwards in very irregular, jerking adduction, and then remains fixed in a certain position. Not uncommonly, and even as a rule in high degrees of strabismus, the capacity for convergence of the squinting eye is almost entirely gone, it remains immovably in its position, while the other eye follows with corresponding rapidity and regularity the object advancing in the median plane. If then the deviation is not too considerable, the patient appears to squint only when he regards distant objects. In the same measure, however, as the object shortens its distance, the angle of squint diminishes in size, and finally becomes zero or even negative, and in some cases the eye even deviates suddenly with a jerk considerably outwards, at a certain distance of the object.

In the same way the visual direction at the time of examination exerts an influence upon the size of the angle of squint. In general, we may say that lowering the visual plane, as well as direction of the glance towards the side of the squinting eye increase the angle of squint, while on the contrary elevation of the visual plane, and lateral direction of the glance in the course of the squinting muscle diminish the squint-angle. By the employment of more exact means, a considerable irregularity in the movements of the squinting eye as a rule makes its appearance, a disproportionate variation of the deviated visual line, especially in its excursive movements. The direction of the glance towards the side of the fixing eye sometimes suffices in smaller squint-angles to completely mask the cosmetic defect. At the same time, as will be subsequently shown, the more correct position of the squinting eye to the object of fixation facilitates the determining the position and nature of objects. The patients also as a rule soon become conscious of this advantage, and finally accustom themselves by continued practice to a very peculiar position of the head, corresponding to the direction and degree of the squint, which often produces the impression of a diminution of the strabismus. They turn the face towards the side of the squinting eye, so that the fixing eye deviates forwards, the squinting one, on the contrary, somewhat backward. The muscles of the neck then enter into new associated relations with the muscles of the eyes, which often become so firmly rooted, that even after operative removal of the squint, the normal position of the head does not return. *(Graefe.)*

On the whole, the variability of the squint angle only becomes very evident, when the object to be fixed by means of its position, requires great degrees of convergence and excursive rotations of the line of vision. Doubtless this is only a little in excess of what occurs normally, in so far as in functional integrity of the muscular system of the eye the angle of convergence of the visual lines cannot go beyond a certain size and seems to be confined within so much narrower limits, the farther the direction of vision is removed from the center of the binocular visual space. Just as under normal conditions the more excursive directions of vision, which limit and render difficult the easy fixation of an object, are rendered superfluous by corresponding movements of the head, so does the person squinting make use of but a small portion of the motive power of his eyes, he maintains under a suitable position of the head a certain visual direction, which is useful for the best possible co-ordination of his squinting eye, and by practice may also easily be maintained. Thus there is formed to a certain extent a new visual space, within which the squint-angle varies but little. Hence, if, when an object of fixation is determined upon in this new visual space, the healthy eye be covered and the squinting one forced to direct its visual line to the object, the first immediately deviates

and this secondary deviation is as a rule equal to that which the squinting eye shows, when the object is fixed by the sound eye.

It is believed, that this is particularly the case in monolateral strabismus, and hence this form has received the special name of "concomitant;" still similar conditions are also found in the alternating or binocular strabismus.

The peculiar relations between the two visual axes furnish important aids in deciding the existence of a strabismic deviation, its affection of one or both eyes, the constancy and periodicity of the squint, as well as the influence which the distance of the objects fixed, and their relative position, have upon the occurrence of the strabismus.

For this purpose, the surgeon places himself directly opposite the squinting patient, and causes him to "fix" some small object, which is alternately brought toward and removed from him, in his median plane of vision, or is moved in a circle perpendicular to this. The deviation of one eye then appears quite plainly. We, however, succeed much more certainly, if, with first one and then another position of the object, one eye and then the other is covered by the hand or a shade. If the squinting eye be covered, it will keep its position unchanged, as well as the healthy eye. But if the fixing one be covered, the circumstances are generally reversed, and remain so, so long as the eye which, under the existing circumstances, does not squint, is hindered in its fixation; but, at the moment the hand is removed, the squinting eye springs back into its false position, while the other again assumes the fixation of the object.

Exceptions to this, however, occur. In concomitant strabismus it sometimes happens that when the squinting eye has become the one engaged in fixation, on account of covering the healthy one—that is, after the latter has been uncovered—it retains its position, at least for a time. In alternating strabismus this occurs quite frequently. The squinting eye is in many cases mechanically hindered by degeneration of the squinting muscle, or weakness of its opponent, from fixing objects, or is unable to do so on account of great amblyopia.

The above-described condition of both eyes is a valuable aid in distinguishing an actual strabismus from an apparent one. In the latter the deviation of both eyes is generally the same; in other words, it is symmetrical. The position of the globe to the object of fixation does not change, whether one or the other be covered, since both eyes "fix," and finally, in consequence of this, binocular vision results, with proper estimation of the solidity of objects.

The probable size of the angle of squint may be measured from the magnitude of the excursion which the eye makes in the experiment mentioned. This is practically of great importance, since the amount of the deviation has very much to do with the prognosis and treatment.

On the other hand, the reciprocal position of the vertices of the two corneæ affords no trustworthy means of such an estimation, unless the position of the optical centers, that is, the angle which the visual lines make with the long corneal axis, has been accurately determined.

This circumstance makes the hodometer or strabometer recommended for a measurement of the degree of strabismus of very little practical value (*Ed. Meyer*), even if the method of ascertaining the vertex of both corneæ, without exact and complicated instruments, were more trustworthy than it is.

3. The mobility of the eyes is but slightly impaired in pure and not very old strabismus, either in the course of the affected muscle and its antagonist, or in any

other direction. This law is without exception in alternating strabismus. In monocular squint, especially in cases of a high degree, the rule has some limitations, inasmuch as the sum of the mobility in the course of the squinting muscle, and its antagonist, nearly or quite approaches the normal, but the whole field of the motion is a little displaced toward the side of the deviated muscle, so that on this side the mobility is a little increased, but on the opposite side is diminished to about the same extent. The reason of this lies in the excess in power of the squinting muscle, which is seen, not only as opposed to its partner of the opposite side, but also to the antagonist of the same side. (*Graefe.*)

The reason for this lies in the increased innervation of the converging muscles.

4. A necessary consequence of the squint is the representation of the object of fixation upon points of the retinæ which do not correspond, and which are very different generally in the estimate of their width. Nevertheless binocular diplopia appears spontaneously only very exceptionally in pure strabismus convergens, and then during the stage of development, since the patients notice a certain shifting at the moment of deviation, and immediately afterwards a separation of the images. This appearance is moreover always very transitory, and can be very rarely demonstrated on account of the tender age at which convergent squint usually commences. When the strabismus has already become firmly established, even if only in a periodic form, spontaneous diplopia is never observed, and artificial manœuvers are necessary to produce it. Sometimes it is sufficient to concentrate the attention upon an object situated in the direction of the deviating line of vision, in order to cause the squinting eye to perceive the corresponding phantom image of the object of fixation. Generally the fixing eye must be covered with colored glasses, and the best are dark-red, in order that the binocular diplopia may manifest itself. These manœuvers, however, avail only in a certain class of cases, where a constant monocular strabismus has already existed for a long time, especially when the functional energy of the central parts of the diverging retina has already suffered considerably, without, however, having become incapable of perceiving qualitative impressions. When the energy of the central zones of the retina has remained almost normal, double images, in a constant monolateral squint, cannot be gained by these means, and we succeed still less in the periodic and alternating forms of strabismus. (*Alf. Graefe.*)

The relative position of the double images is, under such circumstances, homonymous, corresponding to the excessive convergence of both visual lines; when the left eye is covered, the left phantom image disappears; and when the right eye is covered, the right disappears.

With insufficient foresight, deceptions may easily creep in in this connection, even on the part of intelligent patients. If, during the fixation of a suitable object, the fixing eye be quickly covered, the squinting eye immediately directs itself to the object, and the patient thinks that the phantom image of the latter has disappeared. In order to obviate these errors, the squinting eye must be covered, therefore, very slowly by a screen rising gradually from below upwards, and only to half its extent, so that the image of the object, a vertical stripe is the best, remains half in sight of the eye. Then the deviated eye and its phantom image do not leave their position, and errors are impossible.

The lateral distance of the double images never corresponds to the degree of deviation and distance of the object, but is smaller, not only in regard to these conditions, but under all circumstances. (*Alf. Graefe, Schweigger.*) Its explanation offers, as a rule, many difficulties, particularly in unpracticed patients, on account

of the very great variations, which, without regard to any errors of observation, may be occasioned, on the one hand, by the change in position of the object, on the the other by voluntary spontaneous changes in innervation.

Very extensive errors of observation proceed from an incorrect and perhaps even varying position of the head to the object. They must be overcome by perfect control of the latter, in default whereof every experiment with the same individual and the same position of the object, yields different results.

In the variations of the lateral distances of the double images dependent upon the position of the object, the variability of the squint-angle is faithfully reflected. If the object is brought gradually near in the median line, the phantom images approach each other more and more, begin frequently to oscillate irregularly, and then suddenly spring together with a jerk, long before they have approached near enough for the edges to touch. By a further lessening of the distance of the object it not uncommonly happens that they again separate from one another and appear crossed.

Similar variations occur in excursive changes of the direction of vision. The lateral distance of the double images and often their inclination to each other, also become different, when the visual line deviates in a vertical, horizontal or oblique direction from the median line. The double images approach each other, when the glance is turned upwards, or turned away horizontally from the median line towards the side of the fixing eye. In the latter, we often see them suddenly spring together, and, when the visual direction is changed still farther towards the same side, sometimes a new separation, in which, however, it is generally extremely difficult to convince one's self, whether the double images are crossed or not. The double images, on the contrary, separate from one another, when the visual plane is turned downwards, or the visual line is turned towards the side of the squinting eye. It is very probable that these changes in the lateral distance of the phantom image depend upon normal conditions, namely, upon the difficulty, increasing with the deviation of the visual line from the median line, of producing great degrees of convergence.

The third category of variations is the most remarkable. These are apparently not subject to any rule, and thwart every series of experiments in the most disturbing manner. They appear particularly in individuals who are examined for the first time for double images, or who have gained but little practice in diplopia. These variations manifest themselves in some cases by a very tenacious maintenance in a certain lateral distance, when the object changes its distance and relative position to the median plane. If, however, a certain limit in this or that direction is overstepped, it not uncommonly happens, that the phantom image suddenly and by jerks, makes a disproportionately great change of position. A similar condition of things appears in the use of prisms. It sometimes appears as if the latter had lost all influence upon the lateral distance of the double images, since the latter does not change when we place gradually stronger and stronger prisms with the base inwards or outwards before the eye. If, however, the angle of refraction exceeds a certain degree, then the phantom image either disappears, or else appears suddenly considerably displaced, and has possibly, from being homonymous, become crossed, and vice versâ. In most cases, however, we find in such experiments a very irregular movement to and fro of the phantom image. Its lateral distance often varies during the same experiment, sometimes for a time increases proportionally with a gradual change of the position of the object, then suddenly falls in order again to rise, &c. There is no doubt that changes in the position of the head often exert a very considerable influence in careless experimentation. The chief sources, however, are certainly the voluntary corrective innervations, which can be carried out up to a certain limit. In fact, by prolonged practice in diplopia, these variations become gradually slighter and less irregular, and the patients even obtain finally a certain power over the lateral distance, so that they can approximate the but little distant double images at will, or let them even cover each other. There has, however, been founded upon this observation a peculiar method for the cure of squint without operation (*Javal*), which consists in presenting to each of the two eyes an object, whose double images may gradually by practice be made to blend. But it has been proven that this blending, wherever it really occurs, is only apparent, and that the double images do not fall together, but simply cover one another, and that this usually takes place, in spite of a still very considerable deviation of the squinting eye. (*Alf. Graefe, Schweigger.*)

5. If the lateral distance of the double images does not correspond to the degree of deviation, this cannot be as such the proximate cause of the diplopia. Everything, indeed, points to the fact that the non-adaptation of the squinting eye, which appears in simple shutting off of the fixing eye, is caused solely by the anatomically demonstrated changes, which the squinting muscle and its antagonist usually undergo in old cases of strabismus convergens, and is, therefore, based upon the disproportion, which is developed between the conscious amount of innervation and the actual power of the hypertrophied or degenerated squinting muscle, as well as of its antagonist, which has gradually become atrophic. Every essential difference between the deviations of projection, which are called forth by strabismus, paralysis, spasms, mechanical impediments to motion, etc., is consequently also wanting, and every one of these cases of diplopia must be grouped in one and the same category, according to their nature.

This defective consciousness of the position of the squinting eye in cases where diplopia may easily be produced by simply shutting off the fixing eye, is constantly manifested very distinctly in monocular vision, as the patients, when the usually fixing eye is covered, as a rule miss an object held before them, and they pass by it towards the side of the antagonistic muscle, when they attempt to touch it by a rapid movement with the finger.

6. The main proof of the dependence of the non-adaptation of the deviated retina upon the incongruity between the conscious innervation and the effective action of the muscles under consideration, lies in the circumstance that in strabismus entirely similar deviations of projection are caused as well by morbid changes, as artificially by a tenotomy of the muscles. As an actual fact, the lateral distance of the double images, which usually appear after operations for strabismus so frequently, sometimes temporarily, sometimes persisting with the greatest obstinacy for a long time, manifests itself without any relation to the actual position of the squinting eye obtained by the operation. Under all circumstances, it rather corresponds merely to the amount of displacement backward itself, and in cases in which there already existed before the operation a diplopia, based upon the mechanical preponderance of the squinting muscle, it is proportioned to the difference which results from the former *plus* and the present *minus* of the mechanical ability of the tenotomized muscle to perform its work.

If we examine patients after a tenotomy, we find that the double images, even when there is no spontaneous diplopia, become manifest, by covering the fixing eye, much easier than before the operation, and may even be often perceived at will without any external assistance. They at first show the same variations as before the operation, yet the variations become more and more limited with constant exercise, while at the same time the will gains a very remarkable influence upon the position of the phantom image. The lateral distance of the double images is always entirely changed by the tenotomy, the phantom image of the squinting eye advances from its former position in the course of the muscle displaced backwards by the tenotomy, it has approached the image of the fixing eye, or what is usually the case, it has passed considerably beyond the latter, so that the double images, from being homonymous, have become crossed. A mere lessening of the former deviation in projection, by which the double images remain homonymous, is only met with when their lateral distance was proportionally greater before the operation, and when the backward displacement of the muscle proved much too slight, and, therefore, particularly in old cases of strabismus of a high degree, when the operative correction proved much less than was required. In all other cases the double images reverse their relative position to one another, and their lateral distance appears so much the greater after the operation, the smaller it was before the tenotomy and the greater the curve was around which the insertion of the muscle was displaced backward. The new actual posi-

tion of the squinting eye is, therefore, without any marked influence. In fact we often find crossed double images after the tenotomy, in spite of a very considerable deviation inwards still existing. But the binocular diplopia, with relatively reversed position, and considerable lateral distance of the double images, makes its appearance so much the more certainly, when the amount of displacement backward was equal to the need, or when even an over-correction had taken place, whilst previously either no diplopia at all or else one with very slight distance of the double images existed.

7. If now the deviation in projection of the squinting eye can be laid solely to the account of a disproportion between the degree of conscious innervation employed and the actual capacity of the muscles in question, the deviated eye must be thoroughly aware of its position, so long as a pure strabismus exists. *And so it is.* To explain this we may again adduce the fact that double images can never be obtained by simply covering the fixing eye with dark glasses in more recent cases of continuous squint, but particularly in cases of periodic and alternating squint, though they may be sometimes by excursive turning of the glance and by prisms, especially with the base held vertically; but that then the changes resulting in the distance and position of the phantom image agree with those which appear in the functional integrity of the muscles of the eyes, when the object maintains the same position, or when prisms of equal refractive value and similar position are employed. (*Alf. Graefe.*)

On the contrary, the continual success of the attempt to grasp at an object with the finger, the fixing eye being covered, furnishes but weak proof. It is also of but very little account that the deviated retina of the squinting eye does not remain inactive in the visual act, but the visual field of the patient increases considerably towards the side of the squinting eye, since it enables a perception at least of objects situated in the corresponding monocular portion of the field of vision, and projects these also in the corresponding direction outwards, when no material changes in the muscle can be assumed. But we should place the very least reliance on the circumstance, that by the erection of a vertical screen between both open eyes, and, therefore, by complete separation of the two fields of vision, the deviated retina can be forced in its totality into participation of the visual act, and then manifest a correct appreciation with surrounding objects throughout its entire extent, since it admits of perception of all objects situated in its field, and projects these exactly outwards, so far as it is a question of direction. We meet with a similar power in cases in which the power of adaptation of the deviated retina has, without any doubt, suffered in a high degree, in strabismus divergens, after tenotomies, even in paralysis existing for a long time. It always appears more evident that practice enables the patients to correct false projections by their own judgment. This is very evident after a double tenotomy, and in cases in which a muscular paralysis exists in the only eye capable of vision.

8. Binocular vision does not occur in strabismus; the impressions of the deviated eye, as far as they come from objects which lie within the visual field of both eyes, are not perceived by reason of the incongruity of both retinas, but are suppressed, and this so much the more surely and completely, the less the energy of the deviated retina has suffered. The proof of the merely monocular vision of those who squint lies in the universal defect of a correct estimate of perspective in the falling experiment conducted with care. The squinting individual estimates the perspective, in which the central impression of the fixing eye appears, solely in accordance with the amount of accommodation employed, and according to relatively external fac-

tors, according to the perspective, to the relation of the size of the image perceived to the known size of the object, &c. When these aids are at hand in sufficient amount, the estimate of the distance of the object is approximately correct, so that persons who squint can occupy themselves with the finest work. When, however, such means are not at hand, as in the falling experiment, the estimate of the perspective space is very variable, the patient is only acquainted with the absolute and relative direction of the object in the field of vision.

In contradiction to this, it has been recently often asserted that the impressions of the squinting eye increase in intensity those of the fixing eye, and even that stereoscopic vision may exist in persons affected with strabismus. Hence we were induced to suppose that a new condition of identity of both retinas was formed, by means of which the patient is enabled to see simply binocularly, and to project correctly the objects of the common field of vision in direction, distance, and respective position, according to the geometrical proportions. (*Alf. Graefe, Schweigger.*) It is, however, evident that in the variability of the squinting angle, a new relation of identity cannot possibly satisfy these demands, rather that a different relation of identity would be necessary for every position of the eyes, which is absurd. No relation of identity can be constructed upon the basis of binocular single vision; the binocular single vision, with separate retinal images, has been long since demonstrated, and with each individual point of one retina a great number of points of the other retina must thus be identified, as if reversed.

In addition, we conclude that those observations of an increase of the central impressions of the fixing eye by the squinting eye, as well as the observations of stereoscopic vision, certainly depend upon a self-deception. In fact intelligent patients, so far as we can examine such, find no difference in the distinctness of perceptions gained from a fixed object, when we place, unknown to them, a screen before the deviated eye. The same holds good also in experiments with stereoscopes. It cannot be denied that persons who squint, by great attention, see the objects of the field of vision in perspective. Still, patients with one eye do not even refer all their simultaneous visual impressions to one and the same surface, but are able to estimate the perspective distances very well within certain limits from the division of light and shadow from the perspective, &c., and no less to form a well-drawn stereoscopic surface-figure solidly by means of mental appreciation. It appears, however, here also that covering the ocular of the stereoscope corresponding to the deviated eye by no means alters the perception of solidity, which is certainly proved by the fact that here only monocular vision furnishes the substratum.

9. The ability to suppress an image is limited to the central parts of the deviated retina, and that is to that region which furnishes the most powerful impressions and pre-eminently chains the attention. In alternating strabismus it falls sometimes upon one, sometimes upon the other side, according as this or that eye is employed for fixation.

This region of suppression can be distinctly demonstrated by placing prisms before the squinting eye. Double images then appear only when the retinal image of the object fixed is displaced by the prism beyond a certain limit. Usually we only need weak prisms, when the base is turned upwards or downwards, but if the base be turned inwards or outwards, we need very strong ones.

Hitherto it has not been possible to define the region of suppression in position and size, not to form laws for its extension in individual cases. At any rate, it does not extend beyond the common visual field of both eyes, which, by reason of the deviation, has naturally become very different from the normal.

10. Perhaps the region of suppression coincides with the region of central anæsthesia, which can very generally be demonstrated in old cases of strabismus, and which, without doubt, is to be referred to anopsia, *i.e.*, to a torpidity of the retina

elements caused by a permanent functional incapacity, since the material changes are, as a rule, wanting, and systematic exercise in vision of the squinting eye may again increase considerably the functional energy of the anoptic elements, or even bring it back to the normal standard. This anæsthetic region varies exceedingly in extent and form in different individuals. Its limits are often very indistinct, but sometimes we meet with cases in which it is sharply defined, and a stellate figure is seen as a wreath of radiating lines, because the central portion remains invisible. The acuteness of vision increases within the anoptic region tolerably uniformly from the centre towards the periphery.

Exceptionally cases of real amblyopia are found, as also central interruptions, which compel the patients to fix excentrically in monocular vision.

The supposition that the central anæsthesia of squinting eyes precedes, as a rule, the development of the squint is refuted most positively by the circumstance that anoptic regions are a regular occurrence only in cases of old squint, and are almost constantly wanting in the first stages of the affection, particularly in periodic and alternating squint.

11. The correct adaptation of the squinting eye necessarily presupposes the complete consciousness of the position of the deviated retina in space. Consequently the deviation can only be the result of a voluntary spontaneous innervation.

This assertion will at first appear strange; still we should not lose sight of the fact that, so long as there are no material changes in the muscular system, the deviation disappears in death, in deep sleep, and in complete narcosis. Moreover, the influence of voluntary innervation upon the convergence of persons affected with squint may be demonstrated with as complete certainty as upon the direction of the visual axis. At the commencement of the affection it generally suffices to call the attention of the patient to his squint, in order that he may immediately correct the deviation. If we subject cases of periodic strabismus to examination, we find, as a rule, in every individual case a fixed distance, up to which an object situated in the median plane can be brought near to the eyes, without any deviation occurring. Up to this distance the convergence is perfectly proportioned, and binocular simple vision with direct perception of perspective takes place, and hence no errors occur in the falling experiment. If, however, this distance is further diminished, the squint immediately appears, as one eye suddenly, with a jerk, turns inward a certain distance. There is now an end to binocular vision, and the estimate of perspective solidity is only based more upon the consciousness of the amount of accommodation employed and upon external aids. Moreover, the convergence, with further approximation, of the fixed object remains the same as in permanent convergent strabismus. Up to a certain limit the main angle, *i.e.*, the angle which the visual line of the deviated and of the fixing eye encloses with the main line, is proportional to the shortening of the distance. If, however, the object passes beyond the limit, the deviation begins to become irregular, and the squint-angle gradually to decrease, as the action of the squinting muscle becomes insufficient.

The deviation which, in cases of periodic squint, makes its appearance by approximation of the object to the main line, is, without doubt, connected with the amount of accommodation necessary to fixation of the object. If the increasing necessity for convergence were the cause, then prisms must exercise a perceptible influence upon the squint, which is not the case, in so far as by their use the distance of the object of fixation, which does away with the deviation, remains entirely the same, *i.e.*, is not removed by prisms with the base inwards, and is not

brought near by prisms with the base outwards. On the contrary, however, a very considerable influencing of this limit of binocular vision appears by the use of spherical glasses, which increase or diminish the necessity for accommodation. Concave glasses, which, by unchanged distance of the object, increases the amount of accommodation necessary for distinct vision, remove the limits of binocular vision in relation to its refractive value, and, under some circumstances, cause the deviation to appear even when looking at very distinct objects. Convex glasses, on the contrary, which lessen the necessity for accommodation, and even annul it, approximate the limit of binocular vision, or allow it to coincide with the normal limit, so that binocular simple vision takes place everywhere, so far as this is possible in the normal condition.

This service rendered by convex glasses which lessen the necessity for accommodation, moreover, is not limited solely to cases of periodic squint, but extends in general to cases of convergent strabismus which have become permanent, in support of the fact that in these also the deviation is maintained solely by the uninterrupted necessity of certain amounts of accommodation. So far, of course, as material changes in the muscular system do not exist, in other words, when the deviation depends solely upon the innervation for the squint, such cases of permanent strabismus may be in fact almost always corrected by convex glasses of definite refractive value, and, to a certain extent, changed in the periodic form. If, from among several convex glasses which correct the strabismus, we chose the weakest, we find, as a rule, that correct binocular fixation, with direct perception of solidity, is only possible up to a certain limit, but that this limit approaches the eye with the increase of the refractive value, and finally coincides with the normal one.

On the whole, we can say that the amount of accommodation, which does away with the deviation of the squinting eye, is in different patients very variable, sometimes very high, sometimes very slight, even almost zero, so that the patients, during their waking hours, must continually squint. In the special case, however, it is sometimes tolerably fixed, in so far as the deviation only appears and remains when the latter oversteps a certain limit.

In so far now as the introduction of a certain amount of accommodation is a voluntary act, the deviation also appears as the result of a voluntary act. In order to avoid confusion, we must well distinguish between spontaneous and perfectly voluntary movements. It is only the collective coordinated movement comprehending the deviation, *i.e.*, the innervation of the muscle of accommodation necessary for distinct vision of the object and of the muscles of convergence combined with one another, which is voluntary, but not each of these varieties of innervation for itself; if an impulse of the will of definite strength is brought to bear upon the muscle of accommodation, an innervation of definite amount affects uninterruptedly the muscles of convergence, without, however, spontaneous corrections within certain limits being excluded, as the range of relative accommodation and convergence in the normal condition attest, but in persons who squint the variations which, in the first experiments, give the lateral distance of the double images.

In persons who squint, degrees of accommodation of a definite amount are coordinated, not with corresponding but with excessive degrees of convergence; and this is explained by the fact that forced amounts of convergence with a surrender of the binocular visual act bring with them a considerable increase of the maximum refraction, and consequently a diminution of the amount of accommodation necessary for a definite distance.

We always regard the near-point as the shortest distance at which clear and distinct binocular vision is possible, up to which the refraction and the angle of convergence increase proportionately. Still, the convergence and refraction have here by no means reached the maximum, for a forced innervation rather admits of a still stronger inclination of the visual lines towards one another and a further increase of the refraction. But the increase of the angle of convergence, and that of the accommodation inside the near-point coordinated to it, is no longer proportional, but the latter drops perceptibly behind the former, and a disproportionately large increase of convergence is needed to increase the refraction to a certain point. The distinct vision of an object situated within the binocular near-point presupposes, therefore, the surrender of the binocular visual act. If, under such circumstances, the near-point is brought near the eye, and thus the range of accommodation increased, a diminution of the amount of accommodation evidently results, which is necessary for the vision of any object situated within the distinct visual range; the excessive convergence, *i.e.*, the deviation, appears as a means to facilitate the work of accommodation by a surrender of the binocular visual act.

An example will explain this. A certain occupation requires a distance of the object of 10 inches. An emmetrope with the range of accommodation $\frac{1}{a}=\frac{1}{8}$ will need in addition an amount of accommodation $q=\frac{a}{e}=\frac{5}{10}$, since the relative accommodation $\frac{1}{e}=\frac{1}{10}-\frac{1}{\infty}$ for that distance. With hypermetropia $\frac{1}{10}$ and a range of accommodation $\frac{1}{3}$, $q=\frac{5}{3}$, since here $\frac{1}{e}=\frac{1}{10}-(-\frac{1}{10})=\frac{1}{5}$. If this hypermetrope were able by excessive convergence to bring his near-point from 10″ to 6.66″, his range of accommodation would appear $\frac{1}{a}=\frac{1}{4}$, and consequently a quota of accommodation $q=\frac{4}{3}$ would suffice to accommodate for 10″.

Causes and Course.—The most frequent cause for convergent squint are occupations which require the employment and maintenance of a great amount of accommodation. Hence convergent squint is frequently developed at a very early age in children, whose attention is often and continually attracted to small objects, situated near the eyes, to whom picture-books and similar playthings are offered for amusement, which demand clear and distinct vision at short distances. As a rule, however, convergent squint first makes its appearance at the commencement period when children go to school, when the children are compelled for hours to read, write, and perform similar occupations. In accordance with this fact, therefore, strabismus convergens appears in a much higher percentage of cases in city children than in the offspring of villagers, especially of those countries that attach little or no importance to school education.

Everything that increases the necessity for accommodation, also increases the tendency to squint. In so far, insufficient illumination, dark rooms, bad care of the child during the occupation, etc., may favor an occurrence of the strabismus. Not very uncommonly the wearing of too-strong concave glasses, or the employment for near vision of concave glasses suitable for the distance, becomes from the same reason the cause of strabismus convergens in myopes. The same holds good of opacities of the dioptric media, particularly of the corneæ of both eyes, in so far as they diminish the acuity of vision considerably and force the patients to bring the objects nearer to the eyes, in order to a certain extent to gain distinct perceptions.

Direct observations have no less established the fact, that a paralysis in the region of ramification of the oculo-pupillary portion of the third pair of cranial nerves, as occurs partly independently, partly united with paralysis of the motor

muscles of the eyes, and as sometimes appears in consequence of diphtheritis faucium (*Donders*), not very uncommonly lead to convergent squint. Under such existing circumstances the strabismus always develops itself during the existence of the paralysis. When, however, the innervation to squint is once acquired and deep-rooted in practice, it never disappears, even when the original paralysis has been cured, and there is no longer any necessity for the employment of large amounts of accommodation.

It is moreover an old observation that convergent squint is easily developed in children after severe constitutional disorders, which diminish the range of accommodation very considerably, even though merely temporarily. (*Arlt.*)

At the head of these conditions which increase the necessity for accommodation, and which therefore dispose to convergent squint, stands naturally hypermetropia. In fact, the largest number of those persons affected with convergent squint are hypermetropic. It is very probable that it is not so much the hypermetropia alone, as rather the hypermetropia in connection with a relatively slighter range of accommodation, which is the actual standard. Whilst in young, non-squinting hypermetropes the range of accommodation appears very frequently very much increased, so that even the finest work can be accomplished without any particular effort; in squinting hypermetropes, even when the error of refraction is very moderate in degree, we meet very frequently with the inability to decipher the finest numbers of Jaeger's types, the range of accommodation is but little or not at all increased, and sometimes is even below the medium amount.

Among 4,000 patients strabismus internus was found in somewhat more than 2% and among all the hypermetropes in somewhat more than 16%. Among 84 persons with convergent squint there were 80.24% of hypermetropes, and 4.94% of myopes, 2.47% of emmetropes, and 4.94% of opacities of the dioptric media. The refraction was not examined in 7.40%. Among 64 hypermetropes there were 49, or more than $\frac{3}{4}$ of the individuals, whose refraction varied between $-\frac{1}{25}$ and $-\frac{1}{12}$, in 9 the refraction was $-\frac{1}{29}$ and under, in 6 it was $-\frac{1}{11}$ and over. The highest degree was $-\frac{1}{6}$. Among those cases of strabismus united with myopia there was one, whose refraction amounted to $\frac{1}{11}$, another with circular staphyloma posticum and maculae corneae, where the refraction was $\frac{1}{7}$. According to another account there were among 239 hypermetropic children 158, or more than 56%, who squinted, and among these there were 9.5% with hypermetropia $\frac{1}{60}-\frac{1}{40}$; 80% with hypermetropia $\frac{1}{39}-\frac{1}{20}$; 10.5% with hypermetropia $\frac{1}{19}-\frac{1}{7}$. An increase of the percentage according to the age and the years hitherto spent in school was observed only in the elementary and village schools, but not in the middle-schools, girls' schools, art-schools and colleges.

In general it is the medium degrees of hypermetropia which furnish the largest contingent of cases of squint. It might therefore appear in high degrees of hypermetropia, in which the necessity for accommodation is still relatively increased, as if the inclination to squint, in direct contradiction to what has been asserted, were slighter. We should not here however overlook the fact, that high degrees of hypermetropia do not frequently occur in childhood, where the senile involution does not yet concur with the shortened condition of the ball, and therefore can only furnish a small percentage. If we would bring more prominently forward the relation per cent. of the squinting and non-squinting high degrees of hypermetropia, the result would probably appear very different. We should moreover recollect, that in determining the degree of the hypermetropia, it is generally the manifest distance of the far-point, and not the actual most extreme distance, which is measured, and that during school-time, when the children must accommodate a great deal and continually, very considerable differences in the refraction are concealed by the increase in convexity of the lens. We may therefore unconcernedly assume, that many cases of a medium degree of hypermetropia combined with strabismus may really be reckoned among the high degrees, and as such have caused the early appearance of convergent squint. Since the squinting deviation frequently appears long before,

and as a rule at the commencement of, the school-life, an additional increase in the refraction, and even a considerable increase in the range of accommodation, can no longer prevail on account of practice and the consequent hypertrophy of the circular fibres of the ciliary muscle.

It can never be denied that a large number of cases of a high degree of hypermetropia maintain the binocular act of vision in spite of intense accommodation, and that, vice versâ, convergent squint is developed often enough in individuals who under the most favorable conditions are occupied with small objects, which require to be brought near the eye. Hence, still other circumstances must take part in the pathogenesis of convergent squint, and thus account for the fact that in different individuals very different amount of accommodation produces the innervation to squint.

In this respect certain abnormal conditions are first to be considered, which render the common visual act less valuable or even destroy it, since they merely allow indistinct, distorted or cloudy images to appear upon the retina. To this category belong great differences in the refraction of both eyes, monocular abnormal astigmatism, and particularly opacities of one cornea. The influence which such conditions exert upon the development of squint, appears in fact not only in their relative frequency, but also in the circumstance, that as a rule the eye, which is of the least use for distinct vision, is the one which is subject to squint.

The greater or lesser facilty with which different individuals, even under normal conditions, bring about the innervation for excessive convergence and suppress the incongruous images of one retina, is of very great importance. It is evident that a great development of this ability must favor very much the appearance of strabismus, but that its absence must render the development of a squint very difficult, or even make it impossible. Besides this, this facility may be gradually increased by continuous exercise, and consequently the conditions for the squint take on a more and more favorable form. In agreement therewith the strabismus is at first always periodic, intercurrent, and only appears when greater amounts of accommodation are called for. Gradually however the patient squints more frequently, the deviation follows more and more easily, until finally it becomes permanent, since even very small amounts of accommodation are only brought forward and maintained by the aid of the squinting innervation.

It is not improbable that a frequent, forced convergence, as is not uncommonly practised designedly by children, prepares the way for strabismus by the gradual increase of the ability to converge, and where other conditions are favorable for its development, actually calls it into existence. In fact convergent squint has been seen to prevail in schools where such games are practised. (*H. Cohn*).

It may also be very easily imagined that small children, who are often kept for a long time in one position, which forces them to fix near objects with lines of vision directed strongly to one side, acquire strabismus more easily (*Arlt*), since when the glance is directed very much to one side accommodation and convergence are difficult, and therefore the amounts necessary for clear and distinct vision of near objects are increased, and hence the development of a stronger innervation of the muscles of the eyes is rendered necessary.

Finally, experience forces us to assume that the high degrees of convergence which myopes have to bring to play in occupations with small objects, cause a convergent squint in consequence of the continual exercise of the muscles in question.

We sometimes find in myopes a convergent squint, which cannot, as usual, be brought into pathogenetic connection with the necessity for greater amounts of accommodation. It differs essentially in certain respects from the general rule, and might possibly represent a form of deviation, pathogenetically entirely different. This form occurs chiefly in medium degrees of myopia, generally with but one eye. The time of development is generally from the ages of seventeen to twenty, often even in ripe manhood. It is generally avoided by the timely use of concave glasses, which allow the objects upon which the eyes are usually engaged, to be brought to a greater distance from them. Hence, this form of strabismus is especially observed among women, who are apt to avoid wearing spectacles.

At first the squint is only observed on looking at distant objects, and it then may be often corrected by proper concave lenses. Subsequently the deviation becomes greater, and can only be somewhat lessened by appropriate glasses. The deviation is then apt to be very excursive, although the patients "fix" near objects which lie within their distance of distinct vision very well with both eyes. They neutralize the excess in power of the internal rectus by a corresponding innervation for abduction. (*Graefe.*) If in the further course, the resistance against which the internal recti have to struggle is increased by the rapid growth of a posterior staphyloma; or, if their energy decreases from any cause whatever, it may occur that one visual axis deviates outward, on looking at near objects, and inward in distant vision. In other words, convergent strabismus is connected with divergent (*Donders*).

Results.—The strabismus may completely disappear, *i.e.*, with restoration of true binocular vision. More frequently, however, the squint merely disappears, or diminishes so far that it may be concealed by slight lateral movements of the face, while binocular vision is wanting. Since this change generally comes on very gradually and imperceptibly during the growth of the body, it is usual to say that the patient has outgrown the squint.

In some cases the strabismus recedes without any assistance on the part of the patient, by regulating his mode of life or by giving up entirely his previous occupation, even in spite of the patient having busied himself uninterruptedly with studies or objects which require a continual and strong accommodation for the near-point.

Here and there, according to individual observations, the explanation for this may be sought in a diminution of the necessary amounts of accommodation on account of a decrease of the hypermetropia, or its transformation into myopia; oftener, however, the hypermetropia persists, and other circumstances, hitherto not ascertained, must have caused the favorable change.

The strabismus develops much more easily when the frequent and continuous employment of large amounts of accommodation has been rendered superfluous by a change in the occupation or by the corresponding correction of an error of refraction, as the patient then again unlearns the tendency to squint, and accustoms himself to combine with greater and greater amounts of accommodation the corresponding amounts of convergence.

As a rule, however, the strabismus takes deeper and deeper root, if a complete removal of the causes has not been undertaken in time and maintained with extreme consistency, without, however, any further change of the angle of squint in a direction upwards or downwards being excluded. The functional energy of those parts of the retina belonging to the new binocular field of vision then diminishes more and more, and finally this central anæsthesia may assume the form of complete and incurable partial amaurosis, since the retinal elements probably undergo atrophy.

Sooner or later the muscles concerned in the strabismus also usually undergo material changes. Consequently the power of coördination of the retina of the deviated eye is necessarily injured, which is shown by the possibility of producing double images. Later in the disease we meet with limitation in the excursive ability of the globe, sometimes to such a degree that the strabismus becomes gradually modified to a *luscitas.*

At first, only the squinting muscle is changed. Its excessive action sometimes leads to hyperæmia and capillary hemorrhage in its tissue, or even to actual inflammation, which finally cause different changes, but most frequently tendinous degeneration, with shrinkage. But much more frequently, and even as a rule, the muscle suffers from over-nutrition; it hypertrophies, increases in thickness and breadth, and thus actually attains an excess in power over its partner, which becomes gradually distended, elongated, but at the same time loses in thickness and breadth, and finally actually atrophies. The same fate finally overtakes the hypertrophying, squinting muscle. This gradually degenerates and shrinks to a thin, small, extremely rigid and bloodless tendinous string, that is, of course, entirely incapable of muscular contraction, and which, by means of its gradual shortening at times, occasionally brings about deviations, such as were not previously possible under the maximal exertion of its strength. At last, the partner of the squinting muscle on the other eye takes part in the degeneration, becomes also hypertrophied, and subsequently, like its distended antagonist, falls into degenerative atrophy. The mobility of the fixing eye is apt, therefore, to be restricted, and the patient is compelled to bring his eyes into the proper position to the objects, *by turning his head.* (*Graefe.*)

Treatment.—*This aims to prevent the development and organization of the squint, to remove an already existing strabismus by restoring binocular vision, and where this is not possible, to diminish the angle of squint to such an extent that the disfigurement of the patient may be very slight.*

1. The prophylactic rules spring immediately from the cause of the squint. They must, of course, be adopted very early—as a rule, in early childhood—in order to be successful.

Where the conditions necessitate greater amounts of accommodation to be suspected or admits of their demonstration, the prophylaxis aims chiefly at the avoidance of any great efforts of straining in behalf of clear and distinct vision, particularly at short distances, in order by these means to avoid as far as possible the causes for the squint. Hence in such cases the choice of the playthings must be made in a suitable manner, and the child must undertake the acquiring of reading, writing, female occupations, &c., at a much later period than would otherwise be the custom.

After the first years of childhood are passed, the kind and degree of the pathogenetic factors may be more easily determined, and thus the way be often found for lessening or removing the difficulties in binocular vision. This most easily succeeds where hypermetropia threatens to cause strabismus. In this case, the partial or complete neutralization of the error of refraction, by the proper convex glasses, is urgently required.

In every case, anything that tends to the development of squint must be avoided as far as possible by sparing the eyes most carefully, by using discretion in the choice of aids to learning, by limiting the time devoted to unavoidable efforts, by frequent change of the objects and their distances, &c.

2. If the strabismus already exists in a periodic or permanent form, the task then devolves upon us again to disaccustom the patient from the incentive to squint. Hence our efforts must be directed with redoubled exactness to the consistent performance of means of prevention. In small children, to whom the use of glasses cannot be recommended without danger of injury, &c., there can be but little accomplished in a direct way, since we must content ourselves with removing all playthings which require a great amount of accommodation. If, however, the child has reached such an age as admits of the employment of glasses, and if we can no longer postpone the commencement of instruction, we must then proceed to the correction of the error of refraction, so far as it is concerned in the causation of the squint. The refractive value of the glass to be employed is determined here not so much by the degree of the error of refraction, as rather by the amount of accommodation which is usually coördinated with the squint. Glasses often suffice, whose refractive value is less than the existing degree of hypermetropia, since the tendency to squint, especially in the commencement of the affection, is frequently connected merely with great amounts of accommodation. In other cases the existing error of refraction must be over-corrected, and sometimes a convex glass be employed, where emmetropia or even a slight degree of myopia exists, since the amount of accommodation which does away with the squint is very small. The choice of glasses is determined in the special case by experiment. In general we succeed best with that glass which corrects the existing hypermetropia to emmetropia. When, however, this glass does not relieve the tendency to squint, we must employ a stronger one, and it is then best to choose the weakest among those which are able to restrain the squint under the given circumstances.

In periodic squint the correcting glass is naturally only needed for near vision. If, however, the strabismus has become permanent, that is, if the squinting innervation coördinates very small amounts of accommodation, correcting glasses must be employed uninterruptedly during the waking hours of the patient. So long as the patient is not occupied with near objects, weak glasses may, as a rule, be employed: but for reading, writing, &c., stronger ones must be worn, in order to avoid the tendency to squint. By so doing we are not unfrequently placed in a difficult situation, since the simple correction of the error of refraction to emmetropia or the reduction of the amount of accommodation necessary for a certain occupation to the normal amount proves insufficient, and over-correcting glasses are not borne, because they give rise to asthenopia. In such cases we sometimes gain something by employing weak glasses at first and gradually increasing their strength to the desired amount.

At the same time careful use of the eyes and limitation of the accommodative work to the minimum amount are urgently indicated. Separate exercise of the squinting eye must also never be neglected, in order to avoid the development of a central anæsthesia, in case the squint is not soon cured. For this purpose it is necessary to exclude from the visual act the eye usually employed for fixation, several times daily for a quarter of an hour by a bandage.

The attempt to cure the squint orthopædically, by presenting a second object to the deviated eye and approximating it more and more to the point of fixation of the healthy eye, in order to blend the double images gradually, rests upon a false hypothesis. The employment of so-called squint-glasses, that is, covering both eyes by centrally perforated diaphragms, nut-shells, etc., are of still less use; on the contrary, the increased difficulty in the production of the binocular visual act thus caused is rather a means of causing the squint to become permanent.

Sooner or later the muscles concerned in the strabismus also usually undergo material changes. Consequently the power of coördination of the retina of the deviated eye is necessarily injured, which is shown by the possibility of producing double images. Later in the disease we meet with limitation in the excursive ability of the globe, sometimes to such a degree that the strabismus becomes gradually modified to a *luscitas*.

At first, only the squinting muscle is changed. Its excessive action sometimes leads to hyperæmia and capillary hemorrhage in its tissue, or even to actual inflammation, which finally cause different changes, but most frequently tendinous degeneration, with shrinkage. But much more frequently, and even as a rule, the muscle suffers from over-nutrition; it hypertrophies, increases in thickness and breadth, and thus actually attains an excess in power over its partner, which becomes gradually distended, elongated, but at the same time loses in thickness and breadth, and finally actually atrophies. The same fate finally overtakes the hypertrophying, squinting muscle. This gradually degenerates and shrinks to a thin, small, extremely rigid and bloodless tendinous string, that is, of course, entirely incapable of muscular contraction, and which, by means of its gradual shortening at times, occasionally brings about deviations, such as were not previously possible under the maximal exertion of its strength. At last, the partner of the squinting muscle on the other eye takes part in the degeneration, becomes also hypertrophied, and subsequently, like its distended antagonist, falls into degenerative atrophy. The mobility of the fixing eye is apt, therefore, to be restricted, and the patient is compelled to bring his eyes into the proper position to the objects, *by turning his head.* (*Graefe.*)

Treatment.—*This aims to prevent the development and organization of the squint, to remove an already existing strabismus by restoring binocular vision, and where this is not possible, to diminish the angle of squint to such an extent that the disfigurement of the patient may be very slight.*

1. The prophylactic rules spring immediately from the cause of the squint. They must, of course, be adopted very early—as a rule, in early childhood—in order to be successful.

Where the conditions necessitate greater amounts of accommodation to be suspected or admits of their demonstration, the prophylaxis aims chiefly at the avoidance of any great efforts of straining in behalf of clear and distinct vision, particularly at short distances, in order by these means to avoid as far as possible the causes for the squint. Hence in such cases the choice of the playthings must be made in a suitable manner, and the child must undertake the acquiring of reading, writing, female occupations, &c., at a much later period than would otherwise be the custom.

After the first years of childhood are passed, the kind and degree of the pathogenetic factors may be more easily determined, and thus the way be often found for lessening or removing the difficulties in binocular vision. This most easily succeeds where hypermetropia threatens to cause strabismus. In this case, the partial or complete neutralization of the error of refraction, by the proper convex glasses, is urgently required.

In every case, anything that tends to the development of squint must be avoided as far as possible by sparing the eyes most carefully, by using discretion in the choice of aids to learning, by limiting the time devoted to unavoidable efforts, by frequent change of the objects and their distances, &c.

under some circumstances even fully removed. In order to obviate the evils connected with this, it is therefore imperatively necessary, in strabismus of any considerable degree, to set back not only the deviating muscle, but also its partner of the other eye, the former somewhat more than the latter, and both together, so much that the sum of the two arcs of the part of the muscle set back shall be the same in degree with that of the angle of deviation. The field of motion of the two eye-balls is then evenly divided on each side of the median plane, and turning of the face to one side is only required for objects lying far to one side.

4. The chief disadvantage of strabotomy lies, however, in the fundamental disturbance in the power of co-ordination, and in the incurable destruction of the binocular visual act necessarily connected with it, and consequently in the loss of direct perception of perspective. According to what has been said, the squinting eye as well as the fixing eye, in relation to its *own* position, is correctly co-ordinated before the operation. After the tenotomy the consciousness of this situation persists together with the tendency to squint, and complies with the conditions of projection, while the serviceability of the divided muscle has diminished in proportion to the arc of displacement backwards of the line of insertion; hence the consciousness of the position of the retina, proceeding from the voluntary innervation, cannot possibly correspond to the actual condition of affairs. This disturbance of co-ordination frequently manifests itself, particularly immediately after the operation, in a very troublesome manner by spontaneous double vision, and then is much more marked, when the squint angle has been almost annulled by the strabotomy, that is, when the deviated visual line can again be correctly directed for ordinary objects. The respective position of the double images, as well before as after the operation, does not correspond to the actual position of the two eyes in reference to the object, but after the tenotomy is determined by the degree of the permanent tendency to squint, by any existing material changes in the muscles, and by the arc of the backward displacement of the line of insertion of the muscles.

In Fig. 114 let $m\,n$ be the median line, $l\,r$ the main line, and a a fixed point, which is cut by the visual line $l\,a$ of the left eye, while the right visual line $b\,r$ deviates about the angle $\nu+\mu$, that is, is directed to b. If the deviation depends solely upon the tendency to squint, b and a will be projected from both eyes in the suitable direction, that is, outwards in the lines $b\,n$ and $a\,n$. If, however, the squinting muscle had a mechanical preponderance, the point b would be displaced outwards by the squinting eye about in the direction $f\,n$ and the point a in the direction $h\,n$, that is, an homonymous phantom image would be perceived. Let the visual line $b\,r$ be now turned by a tenotomy round the angle ν towards $c\,r$. Evidently c will now appear in the direction $b\,n$, eventually in $f\,n$, but a in the direction $c\,n$, respectively in the direction $g\,n$, whence we assume the equation $\mu=\nu$. Crossed double images are now present. If the squint-angle is thus made equal to zero, so that by displacement backward of the left internus the visual line $l\,a$ is displaced to $l\,c$, then c must be perceived by the left

Fig. 115.

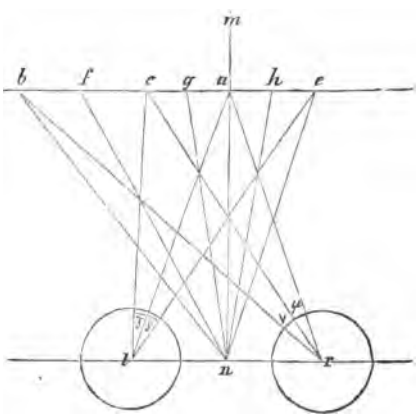

eye in the direction of $a\,u$ and a in the direction of $e\,n$ whence γ is supposed equal to δ. The directions in which c now appears in double images would therefore be, in pure strabismus, in $a\,n$ and $b\,n$, in material changes in the squint muscle however in $a\,n$ and $f\,n$, while a must necessarily be seen in $e\,n$ and $c\,n$, respectively in $g\,n$. The double images would, therefore, be again crossed, but their lateral distance from one another increased.

5. This non-coördination diminishes considerably in time, without, however, being ever entirely gotten rid of. At first the false projection of the sound eye diminishes after a double tenotomy, as the power of estimation is gradually corrected by experience; the fixing eye no longer displaces its central impressions in the innervated visual direction as formerly, but in a line which falls between this and the new actual visual direction, and gradually approximates the latter more and more. The deviations of the finger from the object in the "thrusting experiment" actually become smaller, and finally the experiment succeeds just as well as in the normal condition and relatively before the operation. In addition to this, the lateral distance of the phantom image belonging to the squinting eye diminishes, since the direct success of the operation is diminished by the subsequent contraction of the cicatricial tissue in the field of operation.

The object c (Fig. 114) is now no longer seen in the direction $a\,n$, but almost in the direction $c\,n$, since the consciousness of the innervation of the muscles of the eyes, neck, &c., employed in fixation, and the experience thus obtained, enter into the estimate and consequently eliminate mistakes. As the visual line of the squinting eye at the same time no longer lies in $e\,r$, but in $f\,r$, the object c will also no longer appear in $b\,n$, but perhaps in $f\,n$, and if b, on account of a mechanical preponderance of the muscle, was formerly seen in $f\,n$, f may now appear in $e\,n$, or even near to $g\,n$, so that in case of incomplete correction, homonymous double images again appear.

The non-recognition of the basis of squint, and perhaps also the frequent occurrence of cases in which an apparent squint has been regarded as real and has been operated upon, in connection with the apparently inexplicable positions of the phantom image after operations, has led to the assumption of congenital incongruity founded upon organic conditions of the retina, or to the assumption of a peculiar aversion to binocular single vision. This idea has for a long time been firmly adhered to, until it has been recognized as preposterous by the rapidly increasing number of opposing observations. If we take the trouble to examine very many cases for diplopia before and after tenotomy, we soon see in fact that this apparently strange relation forms the rule.

6. Hence strabotomy is purely a cosmetic operation whose performance is only urgent, when the disfigurement connected with the squint threatens to exert an unfavorable influence upon the better growth of the patient, and when the establishment of binocular single vision by another method, as well as an outgrowing of the strabismus, is no longer to be expected. Hence the period of puberty seems in general the most suitable for the performance of the operation. Moreover, the performance of the tenotomy is still less advisable in childhood, since the tendency to squint is not by its means done away with, and since by continued employment of larger amounts of accommodation the squint-angle still frequently increases, so that the correction is insufficient and a further tenotomy is necessary. This may cause finally a limitation of motility very injurious to the cosmetic interests, and even great depression of the caruncle, an ugly protrusion of the eyeball, &c. In order effectively to avoid all these dangers, there naturally remain no other means than to diminish the amounts of accommodation necessary for work in a corresponding manner by suitable glasses. It is, however, evidently wiser to bring about this correction before the operation, and by a subsequent performance of the latter to

bring about the possibility of the restoration of binocular single vision, than to impose the same trouble upon the patient, *after* having destroyed by the tenotomy all hope of binocular vision. The performance of the operation in childhood, which is urged by many, can only be excused by the obstinate erroneous view that by the tenotomy an actual blending of the binocular impressions to single perceptions, increased in intensity, could be obtained. This idea has been favored by the occasional vertical position of the double images to one another, and in many cases perhaps also by the apparent stereoscopic vision. But whoever does not grudge the trouble of examining a large number of operated cases with suitable precaution for binocular vision and direct perception of perspective, will soon be convinced, that separated double images can almost always be demonstrated, and the direct perception of perspective, as well as binocular single vision, are constantly wanting. The time is certainly not far off when, setting aside a few exceptional cases, it will be generally recognized as to the interest of the patient to postpone the operation till the age of puberty.

It is, however, not wise to hesitate long after the period of puberty has been reached. If experience does not deceive, an unlearning of the tendency to squint cannot be easily expected after this period. Besides this, a further diminution of the amounts of accommodation which do away with the tendency to squint, and a further increase of the squint-angle seem to be less threatening, and therefore the correction obtained by an operation can be more easily maintained in a sufficient degree. At least we gain this much, that the patient may dispense with the correcting glasses for the distance, etc., without danger of a return of the squint. If the glasses for the near-point must still be worn, the patient does not lose much, since the error of refraction must be neutralized for work, without regard to the squint, because the range of accommodation, which is frequently increased in youth, sinks upon or even under the normal amount, and consequently the amounts of accommodation necessary for ordinary occupations increase pretty rapidly.

7. If the operation is undertaken during or after the period of puberty, it is wise to remove the squint entirely by tenotomy of the line of insertion of the muscle. If the amount of the squint-angle dependent upon a mechanical preponderance of the squinting muscle were merely corrected, and that portion depending on the tendency to squint left uncorrected, then the necessity would still remain, in the great majority of cases, of correcting the existing error of refraction, even for the distance, etc. The patient would gain only a slight alleviation by the operation, in spite of his binocular single vision having been already sacrificed. On the whole it is well to cause a little over-correction, since the subsequent contraction of the cicatrix leads us to expect a diminution of the immediate operative effect.

8. A correct measurement is only possible when the tendency to squint still exists at the time of operation. In so far deep anæsthesia seems to be in a high degree disturbing at the time of operation. The position of the eyes only rarely completely corresponds after tenotomy of the line of insertion of the muscle; corrections must generally be undertaken by corresponding division of the sheath, and the measure for this is wanting when the tendency to squint remains. We are, therefore, forced repeatedly to weaken the patient from his anæsthesia and again anæsthetize him in order to a desired result.

With very nervous patients, anæsthesia, in spite of its disadvantages, can with difficulty be dispensed with. Such patients frequently contract the muscles so much that the conjunctiva

is caused to bulge forward; the lifting up of the tendon is in such cases very painful and increases the opposition; while in quiet patients, who oppose but little resistance, the separate movements can be performed with the greatest facility and rapidity, and with comparatively slight pain.

9. The operation requires no preparation, and is generally undertaken on patients who are going about as usual.

The instruments required for the performance of the operation are a medium-sized forceps, a pair of small scissors, curved on the flat, and some small sponges [or bits of fine soft muslin] to take up the blood.

The patient should be on his back, and in case an anæsthetic be not used, the other eye should be closed by a bandage, in order that the patient may have more power over the one to be operated upon, and be able to turn it as may be required. The assistant should open the lids as widely as possible, and hold them, while at the same time he prevents any movements of the head. Another assistant removes the blood. The eye is now turned toward the antagonist of the squinting muscle, or held there by the fixation forceps, while the surgeon seizes the conjunctiva directly over the line of insertion of the tendon to be divided, three lines from the corneal border, lifts up a fold, and cuts through it vertically with the scissors. Then the wound is enlarged above and below to the distance of about four lines. When this has been done, the forceps are placed in the wound perpendicular to the surface of the globe, and its points hugging the sclerotica are pushed a little backward, so that the muscle comes between the branches, and after the closure of the forceps, it may be drawn in an acute angle out of the wound. At the same time the scissors are placed in the wound with the other hand, one blade placed under the muscle (see fig. 115), and the tendon divided close to the sclerotica.

Fig. 116.

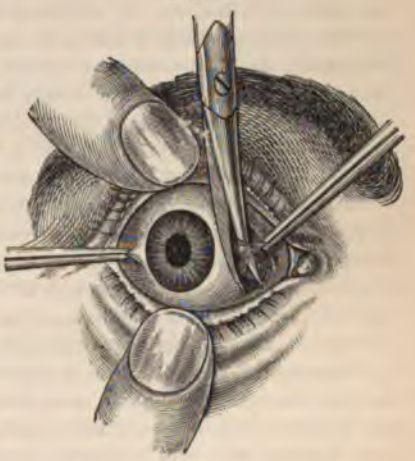

After the operation it is well to determine the relative position of the two globes, in fixation for distant and near vision, as exactly as possible.

If the deviation of the squinting eye be only a little, or not at all, lessened, we have reason to suspect that the whole breadth of the tendon is not cut through. We may say this with certainty, when, on turning the eye toward the antagonist, the wound does not gape at all, and the sclerotica does not show in its center. We should then introduce a hook into the wound, and attempt to place it under the undivided part of the muscle by pressing its blunt point close to the sclerotica, and sliding it up and down. If we have seized the undivided filaments they are cut through, as above described, when the globe will immediately turn to the other side. [In North Germany, the United States, and we believe in England, a blunt hook, called Graefe's hook, is used instead of the forceps to take up the muscle, and from experience with both methods we regard the use of the hook as preferable.]

If the deviation appear to be reduced to a very small amount, we may then be

content with the result, when the case is one of converging strabismus, because the divided muscle very often contracts very much immediately after the operation; and when this contraction subsequently ceases, the correction becomes greater. But if we have a *strabismus externus*, or if considerable strabotic deviation still remains, the tendon of the partner of the other eye should be divided in the same way. If this still does not suffice, Tenon's capsule in the squinting eye, or in both eyes, may be divided upward and downward from the wound, to lessen the opposition to the contraction of the anterior end of the muscle, which is connected to the loosened parts of the sheath, and thus increase the amount of the contraction. Yet we should be very careful in this splitting of the capsule, and be particularly guarded, when there is still considerable deviation, from attempting to force its removal by continued division of the sheath. The patient will gain nothing by this, but on the contrary he is threatened with a greater disfigurement. In consequence of this external division, great prominence of the eye-ball is added to the limitation in mobility, and it acquires a staring appearance. This is more marked and offensive, because the adjacent portion of the conjunctiva and the adnexæ are drawn back with the excessively retracted muscle. An open space remains in the field of the operation, extending far back, which is distinguished from the surrounding parts by the depth of its shadow. If we have gone too far with the division, and the muscle has been dissected from its sheath for some extent, the eye turns to the other side, a secondary strabismus has been excited, or the anterior end of the divided muscle draws itself entirely out of the sheath, and is only connected to the latter by its surrounding tissue. It can then undergo no new union to the surface of the globe, and loses its influence on the latter, which is drawn toward the opposite side by the antagonist, and remains fixed in this oblique position.

Hitherto the attempt has been made to escape these dangers by being content, in difficult cases, with a partial correction at first, and by endeavoring to overcome the remaining deficiency by two or more subsequent operations. The favorable results from this method speak well for it. Yet it cannot be denied that what may be finally attained by a repetition of the operation, may also be at first gained without injury, in a properly regulated setting-back of the muscles of each side. After each operation quite extensive cicatricial adhesions occur, the subsequent separation of which requires much more dissection, and finally, in spite of it, gives a smaller effect than a less extensive separation at the first tenotomy. Very recently, also, methods have been conceived, which allow the greatest possible enlargement in the arc of the portion that is set back, with an avoidance of the dangers above indicated.

Thus it is recommended, in case of need, after an extensive strabotomy, to keep the globe deviated by means of a thread in the course of its antagonist from one to two days, in order that the divided muscle may be compelled to unite as far back as possible. For this purpose, in *strabismus internus*, a thread is introduced through the conjunctiva in a vertical direction, near the outer margin of the cornea, and then drawn through the outer palpebral commissure, and fastened after the globe has been brought into the proper direction by traction. In strabismus externus, where greater power is required for *adduction*, the thread, in order to prevent tearing through, should be armed with two needles, which should be passed through at the corneal margin, one, one-and-a half lines above, the other, one and-a-half below the horizontal meridian, in order that both needles may be passed through the integument separately, but close to each other, passing just above the caruncle through the inner commissure, so that the entrance of the needle is close to the caruncle, and the exit about five lines on the side of the nose; then both threads are gently drawn till the cornea approaches the caruncle as nearly as the operator may desire, when they are tied. (*Knapp.*) The result is very well spoken of.

Others advise, in operating for convergent strabismus, to first carefully separate the conjunctiva up to the semi-lunar fold from Tenon's capsule, and to separate the fold with the caruncle from the parts lying behind. For this purpose the conjunctiva is lifted up in a fold on the lower end of the insertion of the muscle incised, and the scissors introduced through the wound between the conjunctiva and Tenon's capsule, dissecting as it goes. If then the separation has been accomplished in the manner indicated, and the whole capsular portion, so important for the setting-back of the muscle, be completely independent of the conjunctiva, the tendon should be divided in the usual way, and the vertical opening of the capsule made at the same time with the tenotomy, be enlarged above and below, according to the amount of setting-back required, when the conjunctival wound should be closed by a suture. The same method is practiced for the external rectus. Here the separation of the conjunctiva should be extended to that portion of the outer angle which draws backward very much on turning the eye outward. The following are claimed as advantages of this method.

1. A greater freedom and space for the regulation of the effect of the operation.

2. Avoidance of the sinking-in of the caruncle, and every trace of a cicatrix, which the operations heretofore employed occasionally left.

3. There is no necessity for more than two operations on the same person, nor more than one on the same eye. (*Liebreich.*)

Attempts at control have not resulted entirely in favor of this innovation, since there have been observed great depression of the caruncle (*Javal*), suppuration on account of extensive denudation of the muscle (*Knapp*), and large hemorrhage into the capsule of Tenon, with protrusion of the eyeball (*Habertsma*).

Many consider it better to open the conjunctiva in a longitudinal direction instead of the transverse, that is, along the belly of the muscle, so as to reduce the gaping of the wound to a minimum; then to dissect up the conjunctiva from the capsule for some distance above and below the edges of the wound, and also to detach the caruncle from the subjacent tissue, in order to then divide the muscle and split the sheath as needed (*Snellen*).

Where the squint-angle is very great, the operative removal of the squint, in spite of all these modifications, cannot very easily be performed without a very perceptible limitation of motility of the globe, great depression of the caruncle and a considerable protrusion of the eyeball. Hence it is recommended in such case to be content with a moderate tenotomy of both interni, and then to supply what is wanting in the desired effect by advancing the tendon of the antagonist. (*Graefe.*) We may even frequently succeed in obtaining a complete correction by the advancement of one muscle, which is of course a very great advantage, and consoling for the patient, who has depended upon the fixing eye alone on account of amblyopia of the squinting eye. (*Schweigger.*) If a considerable secondary deviation appears immediately after the operation, in consequence of too wide an opening of the capsule or too extensive a separation of the muscle from its adjacent parts, it is well to correct the error immediately by the conjunctival suture. Very small secondary deviations never need this, but are rather advantageous and therefore to be desired, since they soon disappear by gradual contraction of the cicatrix and thus avert an insufficiency in the result. In greater secondary deviations this also occurs not very uncommonly, and in children pretty often, and sometimes the strabismus convergens even returns, since by continuance of the tendency to squint the over-corrected angle of deviation suddenly increases considerably. We should not, however, count upon this, especially when the tenotomy has been done at the period of puberty or upon adults. In order to be assured against any remainder of a secondary squint, and to avoid the complicated advancement of the muscle, the effect of which is much more difficult to measure, there remains, therefore, nothing but to lessen the surplus of the correction by approximating the edges of the wound of the sheath and conjunctiva by a delicate suture. In order to increase the effect we may

also take a semi-lunar piece from the portion of conjunctiva and sheath near the retro-tarsal fold, and then unite the edges by a suture.

Where, however, the secondary deviation is considerable, this method will not be sufficient. We must bring forward the end of the muscle and unite it to the globe, or attempt its setting forward by the so-called thread operation.

We cannot believe that the performance of a strabotomy is rendered easier by opening the conjunctiva and capsule at a greater distance from the corneal margin. We then meet with that part of the muscle which reaches within, or even beyond, the unsheathing membrane, and which is connected to this by numerous filaments of connective tissue. The muscle cannot then, of course, be drawn clearly out of its bed; the forceps are more apt to bring with them the sheath of the muscle and conjunctiva. In consequence of this, it is often difficult to tell just what is and what is not muscular structure. Single filaments of tendon often remain undivided, or too much is separated from the sheath, and the result of the operation is unfavorable.

We are in a similar danger when we divide the muscle at a great distance from the line of insertion. Then the amount of setting-back is much greater than in the regular method, since the muscle is shortened to the length of the stump remaining, and a portion of the resistance to retraction is removed which the adhesion of the muscle to its envelopes offers. Added to this, the tendinous stump does not always simply shrivel, but often granulates excessively, and thus causes much difficulty in the treatment, and at any rate delays the recovery very much.

12. Immediately after the division, the muscle retracts as far as the still-existing adhesion permits. This contraction is often spasmodic, hence the effect of the operation appears less at the time than after the lapse of a few hours. In a short time, inflammation comes on, neoplastic connective tissue develops. This soon becomes thickened, and at last forms rigid, tendinous fibres. These proceed, in part, from the inner surface, partly from the cut edges of the end of the muscle to the surface of the sclerotica. By this means the original adhesions remaining are considerably strengthened, and a new direct connection, a new insertion, induced.

Since the neoplastic adhesions become shorter in their higher development, and are less distensible than the former means of connection—the envelopes of the muscle—the effect of the operation undergoes a slight diminution, which, after the course of a few weeks, usually disappears again, probably on account of increasing activity in the antagonists (*Graefe*).

If the obstacles that the divided tendon found in its retraction were not equal throughout the extent of the divided edge—if, for instance, the sheath was divided to a greater extent above or below—the retraction of the individual bundles of fibers is not at all equal. The new line of insertion is oblique to the former. Therefore, the course in which the affected muscle rotates the eye is moved toward the anterior point of insertion, *i.e.*, the optic axis is deviated somewhat upward or downward, if the internal or external rectus be divided. This experience has been made available for slight corrections in cases in which the strabismic deviation did not lie entirely in the course of one muscle.

The interval between the two cut ends of the tendon often remains vacant, and is filled by loose connective tissue. Sometimes, however, a rather large neoplastic cord is formed, which unites the separated edges of the divided muscle. But it is only exceptionally that such an intervening piece exerts an influence upon the mobility of the globe in the course of the affected muscle, since its whole length is apt to adhere to the sclerotica, and only the most posterior point of insertion is to be regarded as the actual point at which the muscle was seized (*Graefe*).

If the muscle retracts entirely from its sheath, tendinous, connecting filaments are also developed from the end of the muscle, but these run in the orbital tissue; the muscle remains separated from the sclerotica.

13. These methods are scarcely ever attended by any great irritation. The adhesion of the edges of the wound occurs, with rare exceptions, by first intention.

The injury done by the operation itself scarcely ever requires any direct treatment.

Still it is urgently advised to keep the eye and eyelids immovable during the first few days after the operation by a bandage. If conjunctival sutures had to be introduced on account of an over-correction, we should not neglect to examine the eye repeatedly after several hours, since the state of tension of the muscles has usually become very different from what it was immediately after the operation, and a loosening or tightening of the sutures is often necessary in order to make the correction complete.

If the operation be rather more difficult than is usual, and if the surgeon was compelled to divide the sheath, or to use the hook more than usual, we may apply cold applications for a time, in order to avoid an excessive reaction.

Where considerable hemorrhage has occurred, it is advisable, the second day after the operation, to begin to apply linen cloths dipped in a weak solution of brandy, in order to somewhat favor absorption. Granulations are kept down by the application of the tincture of opium, or if they are large, are cut off with the scissors. Yet it is well to delay their extirpation until the edges of the wound of the conjunctiva have contracted to a small size, and they appear somewhat pedunculated.

14. The management of the measures which aim at the correction of the main affection is of very great importance after the operation; that is especially the avoidance of great strain of the accommodation, since by the employment of large amounts of accommodation the tendency to squint might increase, and with this a new squint. In children a complete correction of the error of refraction is especially desirable; while in adults it generally suffices to advise the employment of the glasses merely for close straining in near vision; and frequently large amounts of accommodation may even be here disposable.

15. In some cases, after the operation, an extremely troublesome double vision arises, with or without vertigo, the abnormal relation of the two retinæ, to which the patient is accustomed, being removed. This diplopia often disappears within a few days. Not unfrequently, however, it continues for weeks, and occasionally for months. But frequently the distance apart of the false images is so small, that it only requires a slight movement of adduction or abduction to bring them together. But if this does not occur, if the innervation is diverted to a new strabotic deviation, the squint returns, if the patient does not learn to suppress the retinal images of the squinting eye. In such cases, we may seek to favor the union of double images by prisms, while, at the same time, an attempt is made to remove the cause. Whether favorable results are to be expected from this, further experience must say. Where these means have been found insufficient, the treatment should be directed toward exclusion of the squinting eye, in order to restore the cosmetic result. This is done by placing a dark glass before the eye, or allowing the patient to cover it with a bandage until the purpose is attained.

16. In secondary strabismus, when the angle of squint is moderately large, and the limitation of motion in the course of the muscle, which has been set back, does not exceed two to two and a half lines, stitching the insertion of the muscle forward is indicated. This operation is also to be recommended in certain paralytic impairments of motion of a slight degree, as well as in great primary strabismus, especially in divergent squint, if mobility in the course of the antagonist of the squinting muscle has been somewhat impaired. In the first case, secondary squint, of course the tendon of the shortened muscle, but in paresis, or in excessive primary strabismus, the elongated muscle, should be sewed forward. The division of the antago-

nist should always be combined with the bringing forward, in order to increase the effect and to diminish the great tension on the thread.

It is better to undertake the advancement during anæsthesia, or at any rate with the globe well fixed. The conjunctiva must be first cut with a fine pair of scissors with rounded points exactly over the insertion of the muscle to be advanced and throughout the whole extent of the latter, then be loosened towards the periphery, but especially towards the cornea, and as far as the corneal border for a distance corresponding to the breadth of the tendinous insertion (10—12 mm.) during which, however, the conjunctiva should not be torn. The capsule of Tenon must now be opened by a small incision at one end of the muscular tendon, in order to admit of the passage of a blunt hook, curved on the flat, between the muscle and the sclera, and then the capsule of Tenon at the other end of the insertion is so far cut through upon the hook, until the latter comes out free. Two fine waxed silk sutures are now passed through the muscle. Each of these is provided with two needles, which are introduced along the hook from the scleral surface of the muscle through its belly, so that each of the two loops of silk embraces a portion of muscle from 2—3 millm. wide. Next the insertion in front of the hook is detached close to the sclerotic. This being done, the needles are passed through the conjunctival flap from its scleral margin close to the border of the cornea and tied. One end of each suture is cut off short, but the other is left sufficiently long, in order to facilitate the removal of the sutures on the 2d—3d day. The conjunctival wound is now closed by a fine suture, and finally the muscle causing the squint is cut through in accordance with the rules previously mentioned (*Schweigger*).

As a matter of experience it is well to produce a small over-correction, since the immediate effect of the operation is afterwards always somewhat lessened. The suture must remain from 2—3 days, during which time the adhesion has always reached a sufficient degree of firmness. In order to prevent the rubbing of the suture-knot and limit the extension of the extravasated blood, the compressing bandage is very much to be recommended, but cold applications only where great inflammatory irritation is present.

It is less advantageous to introduce the sutures into the muscle after its division, as was formerly the custom (*Critchett*, *Graefe*), since the muscle retracts very much and we must then penetrate with the forceps into a dark space in order to bring it to light again, whereby we commonly bring to light no more than the bundle of fibres which is grasped by the forceps, and this difficult and injurious maneuver must be repeated for each suture.

[Another method is as follows. The patient having been placed upon his back, and under the full influence of an anæsthetic, and the eye to be operated upon exposed by the wire speculum, an assistant draws the cornea as much as possible toward the outer canthus by catching the tissues over the tendon of the external rectus muscle in the blades of a pair of fixation forceps. The operator then makes a horizontal opening over the internal rectus muscle, midway between its borders, and extending from a point one line distant from the cornea down to the semi-lunar fold. This opening should be made by lifting a vertical fold of the conjunctiva and subconjunctival tissues with forceps, and cutting it with scissors in a horizontal direction. If care is exercised, the internal rectus muscle will be exposed without any difficulty or the occurrence of much bleeding. The next step is to secure the entire tendon of the muscle which is to be brought forward. This is especially essential in those cases in which the divergent squint has been the result of the operation for

convergent squint; for in such cases the tendon and theca, having been much haggled in the original tenotomy, fall back irregularly, and, being split more or less, form false insertions, which are zigzag or interrupted.

After the apparent insertion of the muscle has been brought into view, a strabismus-hook, having an eye drilled in its free extremity, and armed with a waxed silk, is made to sweep beneath it, from below upward, care being taken to keep the instrument in close contact with the sclerotic, and carried so far back as to include every straggling band of muscle or theca which is to be advanced.

The uplifted mass should then be tied close to its sclerotic implantation. The next step is to divide the external rectus muscle freely through a horizontal wound in the conjunctiva, and thus complete the preliminary steps for the advancement of the internal rectus. The latter step is effected as follows: the operator, holding the ligature firmly in one hand, should cut with scissors the insertion of the muscle and gently break up any bands of connective tissue which may attach it to the sclerotic. As he does this, he should draw upon the ligature and sway it from side to side until it becomes evident that any adhesions which might obstruct the advancement of the muscle have been overcome. He should now estimate the amount of adduction which may be necessary to cure the divergence. This he can do by catching with forceps the sclerotic edge of the cut tendon of the external rectus and drawing the cornea toward the inner canthus, while he holds up upon the stretch the muscle to be advanced. The retentive sutures are now to be placed. For this purpose two delicate, short, and sharply-curved needles are to be armed with fine, well waxed silk, and adapted to a needle-holder. (The needle-holder of Dr. H. B. Sands, of New York, is decidedly the best for this purpose.)

Having measured the extent to which the eye-ball must be adducted in order to correct the divergence, the sutures should be passed through the muscle and its theca as far from its cut end as may be necessary. The muscle should be drawn well out and kept upon the stretch, so that the sutures may be passed through it as deeply as possible behind the caruncle, to secure a firm hold, and to leave a somewhat longer mass between the perforations made by the sutures and the ligature upon its cut end than the original divergence measured. The course of the sutures should be perpendicular to the plane of the muscle, one passing through near its upper margin, and the other near its lower. After the sutures have been placed in the muscle, the end included in the ligature should be cut off, care being taken to leave enough to prevent their tearing out. The amount cut should nearly equal the degree of divergence to be corrected, allowance being made for shrinkage which has followed the detachment of the muscle from the sclerotic. The next step is to carry the sutures beneath the conjunctiva above and below the cornea. It is better to place the upper suture first. This also requires the curved needle. The point aimed at in carrying the needle along the sclerotic, beneath the conjunctiva, should be about a line above the cornea and over the center of the line of implantation of the superior rectus muscle, and there the suture should emerge. Before tying the upper the lower suture should be brought out at a corresponding point over the inferior rectus insertion. While the operator is cautiously tying the sutures his assistant should, catching hold of the insertion of the external rectus, carry the cornea toward the internal canthus as much as possible, and thus effect what may be considered the real intention of the operation, namely, to adduct the eye strongly, and thus place the end of the *shortened* internal rectus in co-aptation with the sclerotic at the natural line of sclerotic implantation. The exercise of a little care will cause the muscle to

spread out and be hidden behind the horizontal pillars of the wound through which the retentive sutures have been carried; and thus insuring a consolidation of the wounded parts, obtain the aid of the subsequent cicatricial contraction of the soft parts intervening between the cornea and the caruncle in the ultimate result. This method has been employed upon two eyes which had been rendered divergent by operations for convergent squint. In one of these eyes the divergence was more than five lines, in the other about four. In the first eye a small amount of convergent squint was induced, which was cured by applying the glass, which neutralized existing hypermetropia. In the second case a very slight degree of convergence was caused, not exceeding a line, which was also removed by the use of the proper glasses. And in both these cases the existence of hypermetropia would have rendered glasses necessary, aside from any convergence.

The operation has also been satisfactorily performed in two cases in which slight paresis of the internal rectus, the result of injury, had led to divergent squint.

No inflammation of an annoying character has followed the procedure. It is believed that the chance of success is greatly increased by dividing the external rectus of the fellow-eye, even though it is proposed to advance the internal rectus of one eye only. (*Agnew.*)]

Others prefer to split the conjunctiva in the region of the new muscular insertion by a vertical incision, and then to dissect it up from the subjacent capsule of Tenon as well towards the cornea as towards the retro-tarsal fold, then to separate the muscle from the sclera immediately, and to incise the capsule so far upwards and downwards, that the muscle and portion of capsule lying upon it become perfectly movable, and hence can be drawn easily beneath the conjunctiva as far as the border of the cornea. Here the anterior end of the muscle is to be fastened in the following manner: Two fine needles at both ends of the same suture are first drawn through the capsule and end of the muscle and then through the conjunctiva from behind forwards, over which the loop is tied. Such a suture or loop is introduced in the region of the superior border of the muscle, and a second in the region of the inferior border of the muscle. After the muscle, and with it the capsule, are in this way fixed close to the corneal border under the conjunctiva, the conjunctival wound is carefully closed by several sutures. If necessary, a piece of the anterior end of the muscle and also of the capsule of Tenon can of course be excised, in order to increase the effect. (*Liebreich.*)

17. In cases of secondary squint, where the mobility in the course of the retracted muscle is completely or almost completely removed, especially where the muscle has drawn itself completely back, and has no connection with the globe, and in all cases where the angle of squint is very large, even if the limitation of motion in the course of the muscle which has been laid back was only to a moderate degree, the stitching forward is no longer sufficient. Then a greater bringing forward of the end of the muscle is necessary, and this may be attained by the so-called thread operation. This method is also to be recommended in all cases of great paralysis of the muscle as well as in primary strabismus, with a large angle of squint, and great limitation of motion in the course of the squinting muscle. (*Graefe.*)

To bring forward the insertion of the muscle, after properly fixing the globe, the conjunctiva in front of the affected muscle is to be divided vertically and then separated from the sclera toward the cornea and toward the reflection to a proper distance. Then the end of the muscle is to be dissected up from the sclera, and the antagonistic muscle divided, not close to its line of insertion, but about one line further back, so that a stump may remain. Through this stump a loop of thread is to be passed by means of a curved needle, the globe turned toward the side of the

muscle to be brought forward, and retained in this position for two or three days by properly fastening the thread. At the same time, the proper application of a pressure-bandage is of marked service, as it fixes the globe to some extent, and somewhat prevents traction of the parts united to the thread, and removes one cause of great pain and intense irritation. (*Guerin, Graefe.*)

Unfortunately, in this method we can not easily regulate the effect, since the eye must be turned as far as possible to the side of the muscle to be brought forward, in order that the thread may not pass over the cornea and rub upon it, which generally causes unbearable pain, and often severe inflammation and even suppuration of the cornea. (*Steffan.*) There then generally remains in the most cases a great deviation of the globe in the course of the muscle again brought forward, which then must be covered by a setting-back of the partner of the opposite side, in case this has been already divided. (*Graefe.*)

12. In order to remove the great deformity caused by a great sinking-in of the conjunctiva and caruncle after excessive division of the ocular sheath on the inner side of the globe, the ocular conjunctiva is opened in the same way as in strabotomy, some lines in front of the caruncle, in a vertical direction. The submucous tissue is then dissected with care as far back as the outer surface of the muscle, which has been set back, and forward to a point near the corneal margin. The edges of the wound are then united by suture, taking care to draw the caruncle well forward and somewhat upward. The surface of the posterior conjunctival flap, which has been dissected up, is then united to the sclerotica. (*Graefe.*)

In order to conceal great protrusion of the globe, or to remove excessive gaping of the palpebral fissure, tarsoraphy is performed with advantage. (*Graefe.*)

Authorities.—*Graefe*, A. f. O. I. 1. S. 10, 13, 82–120, 435, I. 2. S. 294, II. 1. S. 289-308, III. 1. S. 177–386, IV. 2. S. 261, V. 2. S. 211, VIII. 2. S. 339, 348, 365. IX. 2. S. 48–56, X. 1. S. 156–175; klinische Monatbl. 1863. S. 484. 1864. S. 1–22.—*Donders*, A. f. O. VI. 1. S. 92, IX. 1. S. 99–154; Anomal der Acc. u. Refr. Wien. 1866. S. 243, et seq. [Accommodation and Refraction of the Eye. London, 1864, p. 244, 291, 403, et seq.]; Verhandlgn. d. ophth. Versammlg. zu Heidelberg. Berlin 1860. S. 31–34; Vierde Jaarl. Verslag. Utrecht 1863. S. 1–52, 84; Congress ophth. de Paris 1863. P. 148.—*Ritterich*, Zur Lehre vom Schielen. Leipzig 1856.—*Ruete*, Lehrb. d. Ophth. II. Braunschweig 1854. S. 495–568.—*E. Hering*, Archiv. f. Anat. u. Phys. 1865. S. 153.—*Ed. Meyer*, A. f. O. IX. 3. S. 215; kl. Monatbl. 1864. S. 55, 58.—*Haas*, Derde Jaarl. Verslag. Utrecht 1862. S. 137, 190–298.—*Alf. Graefe*, Klin. Analyse d. Motilitätsstörungen d. Auges. Berlin 1858. S. 56–96, 214–279; kl. Monatbl. 1863. S. 126–136, 312, 521–528; A. f. O. XI. 2. S. 1–46.—*Pagenstecher* u. *Sämisch*, kl. Beobachtungen. I. Wiesbaden 1861. S. 63–69, II. S. 36.—*Hirschmann*, ibid. III. S. 89, 92.—*Colsmann*, Deutsche Klinik. 1865. Nr. 23.—*Secondi*, Clinica oc. di Genova. Torinol 865. P. 111.—*Mooren*, Kl. Monatbl. 1863. S. 37, 417–423, 1864, S. 64.—*Knapp*, A. f. O. VIII. 2. S. 227; kl. Monatbl. 1863. S. 471–484, 1865, S. 346, 351, 3. Jahresber. Heidelberg 1864–5. S. 20.—*Schweigger*, Kl. Monatbl. 1867. S. 1–31.—*Javal*, ibid. 1864. S. 404, 437.—*Liebreich*, A. f. O. XII. 2. S. 298–307.—*Critchet*, nach Niemetschek, Prag. Vierteljahrschr. 78. Bd. S. 96.—*Guerin*, Congress intern. d'opth. Paris 1863. P. 195; nach Graefe A. f. O. III. 1. S. 372. [*Agnew*.—N. Y. Med. Journal. Vol. 5, 1866. Trans. Am. Oph. Society, 3d year.] *Agnew*, kl. Monatbl. 1869. S. 139.—*Zagorski*, ibid. 1867. S. 317.—*Steffan*, ibid. S. 73.—*Dobrowolsky*, ibid. 1868. Beil. S. 185; A. f. O. XIV. 3. S. 53.—*Habertsma*, *Snellen*, ibid. 1870. S. 24.—*Liebreich*, Congrès Ophth. 1868. S. 104; Canstatt's Jahresber. 1864. S. 164; Arch. f. Augen- u. Ohrenheilkd. I. S. 63; kl. Monatbl. 1868. S. 323.—*Arlt*, Lehrb. III. S. 316.—*H. Cohn*, Untersuchungen von 10.060 Schulkindern. Berlin. 1867. S. 145, 164, 167.—*Stellwag*, Wien. Med. Wochenschrift. 1867. Nro. 82–84.—*Critchett*, nach Niemetschek. Prag. Vierteljahrschrift. 78. Bd. S. 96.

2. Divergent Squint.

Symptoms.—*The affection is characterized by a diminished convergence of the visual lines, while the visual movements in any direction but that of convergence are unimpaired.*

1. The squint according to the rule follows solely in the course of the external recti muscles, so that the visual line of the squinting eye passes behind the object of fixation and usually diverges with the other visual line. The visual line of the squinting eye deviates, however, exceptionally upwards and outwards, or downwards and outwards.

2. Strabismus divergens, like the convergent form, is especially in the beginning frequently periodic, intercurrent, *i.e.*, it appears only under certain conditions, while in other respects both eyes fix correctly, and even binocular simple vision with direct perception of perspective takes place when other morbid conditions do not hinder it. In the course of time, however, the divergent squint is wont to become permanent.

In a number of cases, sometimes the one eye, sometimes the other deviates outwards, while the other eye fixes, and this depends sometimes upon the will of the patient, and sometimes the choice of the fixing eye is determined by the position of the object in space, so that at certain distances and in certain lateral directions of the visual lines the one eye is accommodated for the point of fixation, and in others the other eye, and the strabismus divergens appears of the alternating form. Generally, however, one eye is constantly turned out, the strabismus is monocular, and concomitant in so far as by covering the fixing eye, it turns outwards, while the squinting eye becomes the fixing one.

3. The squinting angle is of very different size in different individuals. It varies however in the same individual within very wide limits, according to time and circumstances. In general we can say, that the deviation in old cases is usually wont to be greater than it has been in the same individual at the beginning of the disease. Doubtless a degeneration of the participating muscles, namely a hypertrophy of the squinting muscle and atrophy of its antagonist, are here partly to be taken into account.

Moreover the existing necessary amounts of convergence and the direction of the visual lines have a proportional influence upon the angle of squint in the same individual and at the same time. In this respect, however, very considerable differences make their appearance and justify the supposition, that we may not always have to do with conditions, pathogenetically of the same value, but that there is embraced in one category much that in the future will be considered as distinct.

a. The greatest differences appear in the relation of the squinting eye, when an object is gradually approximated in the median plane, the horizontal visual plane remaining unchanged, and therefore the amount of convergence necessary for fixation is increased. In many cases, especially in old permanent ones of a very high degree of strabismus divergens, the squinting eye remains completely immovable in

its pathological position, or at most it makes very irregular and insufficient movements of adduction, more by jerks and less excursive, while the other eye moves inwards proportionally to the shortening of the distance.

In other cases of permanent strabismus divergens, generally of a less high degree, the squinting eye turns outwards in the same degree, or somewhat more and more rapidly than the fixing eye turns inwards.

In low degrees of strabismus divergens the ability of the squinting eye to converge is usually, and in the periodic form of squint as a rule, not entirely absent, but only the potential or even the actual energy of convergence has sunk more or less below the normal amount.

So we meet with such cases, where the patient, when his attention is called to it, by the employment of a powerful impulse of the will is enabled to produce every amount of convergence situated within normal limits and even to maintain it for some time, but becomes fatigued sooner, and then from a feeling of tension and fatigue allows the squinting eye again to turn outwards. Usually, however, the patient is actually capable of producing much smaller degrees of convergence than in the normal state. If an object is brought near in the median line, both eyes converge regularly only up to a certain distance; if the object oversteps this limit, the squinting remains unmoved or undergoes slight, irregular oscillations; finally, with a further shortening of the distance it suddenly turns with a jerk considerably outwards, the visual lines diverge or converge in a much slighter degree than that which the patient, with a corresponding position of the object, is still in a condition easily to produce and to maintain with the binocular visual act. The patient feels very distinctly this sudden deviation and knows exactly how to designate the moment when it comes on. The limit of the shortening of the distance at which the squinting eye remains immovable, and that at which excursive deviation comes on, are very different in different individuals. By prolonged experiments and the consequent fatigue of the muscles in question, they usually recede somewhat from the eye. On the contrary, a moderate increase or decrease in the amount of accommodation by concave or convex glasses have no considerable influence. Just as little can these limits be perceptibly displaced by moderate diminutions in the amount of convergence with unchanged distance of the object, *i.e.*, by placing before both eyes prisms of 2°–4°, with the base inwards. The limits are, however, caused to recede somewhat by adducting prisms, base outwards, and by everything that is in a condition to confuse the common visual act in a high degree, especially by prisms placed vertically before the eyes, by very strong, over-correcting concave or convex glasses, even by excluding one eye from the act of vision by holding a screen before it.

There are finally to be mentioned cases of moderate strabismus divergens, which frequently occur, where the deviation manifests itself chiefly during distant vision and without fixation, while during distinct fixation of near objects within certain limits the correct convergence of both eyes with the binocular visual act can be produced and maintained. Here either merely the potential energy has sunk, and the patient converges up to 4 inches but soon tires; or the actual energy is also diminished, the limit of binocular vision and that of the actual squint have more or less receded.

b. No less remarkable is the change of the size of the angle of squint with changes in the direction of the visual lines; the deviation would then be permanent and very excessive, in which case the influence of the visual direction is very little

manifested. As a rule, the deviation increases considerably or assumes the form of periodic squint, when the look is directed upwards, or is turned from the median plane towards the side of the usually fixing eye; the angle of squint on the contrary decreases or becomes zero, when the look is lowered or directed towards the side of the squinting eye. The patients willingly make use of the latter visual direction, in order to give a better coördination to the retina of the deviated eye, and to conceal the cosmetic defect. They also soon accustom themselves to maintain the surface of the face in a certain oblique position, by which the squinting eye comes somewhat forward, while the fixing eye recedes to a corresponding degree.

4. The mobility of the eyes is not perceptibly diminished, as long as the strabismus remains pure. With a longer continuance of the affection, and particularly with a large angle of squint, the mobility on the contrary diminishes perceptibly, doubtless in consequence of material changes in the muscular structure, so that the squinting and even the fixing eye also cannot be turned so much towards the side of the latter, and the excursive region appears somewhat displaced towards the squinting side.

5. The deviation manifests itself at the commencement of the affection, and especially in the periodic form, by spontaneous binocular diplopia. In the further course of the disease, however, the phantom image of the squinting eye recedes under the contention of both retinæ, and the patient needs the concentrated attention or the covering of the fixing eye by dark glasses, in order to bring about its perception. In old cases and especially in very high degrees of strabismus divergens, on the contrary, a diplopia cannot usually be obtained, even when the retina of the deviated eye has not yet become in a high degree functionally incapacitated.

The double images, corresponding to the position of the visual lines, are always crossed. The relation of their lateral distance to the angle of squint varies in many points, and is not yet sufficiently explained in every direction, to be formulated into any general law.

In periodic strabismus divergens the lateral distance of the double images generally corresponds to the degree of deviation. If the object of fixation is gradually approximated in the median plane beyond the limit of the region of convergence, its image becomes indistinct at the moment when one visual line remains immovable; later it becomes split and the double images diverge from one another in proportion as the distance of the object becomes shortened. If then an excursive squinting deviation appears, the double images also become suddenly very distant, and here again proportionally to the existing size of the angle of squint.

In permanent strabismus divergens, which is not too excursive, the double images are likewise very distant and their lateral distance sometimes harmonizes with the size of the deviation, though sometimes such an agreement cannot be found. The latter appears to form the rule in old cases. There also appears quite often in old cases of strabismus divergens a remarkable disproportion in the localization of objects in the raising of a vertical screen between both eyes, by which a division of the two fields of vision is produced.

Doubtless many circumstances here act together in a disturbing manner. On the one side the material changes in the muscular structure are to be taken into account, which have increased differently in different cases and must essentially confuse the co-ordination of the deviated eye. Then we not uncommonly meet with an impediment in the circumstance that it is often very difficult for the patient to maintain the mutual position of both eyes, when he directs the attention to the double images or to both objects separated by the screen, in order

to estimate their lateral distance. The eyes here very easily become subject to a very irregular, jerking motion, by which the retinal images are naturally displaced also. Finally, a further disturbance proceeds from the indistinct perception of the phantom image belonging to the squinting eye or of the object situated on this side of the screen. In consequence of this indistinct perception the struggle between the two retinæ is as a rule decided in favor of the fixing eye, so that the impressions of the squinting eye are but momentarily perceived.

By reason of these disturbing influences, even very intelligent patients, who are already practiced in experimenting, often find it entirely out of their power to estimate even in an approximatively correct manner the existing lateral distance of the double images of a fixed object. If a screen is erected between both eyes, the patient sees the two objects each on its respective side, perceives also their gradual approximation, but is uncertain in his estimate of their mutual distance to such a degree that he is not in a position to decide at once whether the distance is great or small. It is here of considerable moment, that the patients are not usually able to perceive the screen on the side of the squinting eye, and that the object here situated soon disappears, when by unaltered position of the squinting eye the screen is brought near.

Equally indistinct to the patient in old cases is usually the perspective of the phantom image belonging to the squinting eye, and when a vertical screen is placed before it, also the distance of the object in question. Still an approximation and diminution of these images was repeatedly estimated, which is connected with their position upon more eccentric portions of the external halves of the retina, and is explained by the direct perception of perspective founded in the conditions of organization of the retina.

If we combine everything hitherto mentioned, we cannot for a moment doubt that the deviation of divergent squint, unlike the convergent form, in binocular vision brings along with it an absence of co-ordination of the squinting eye in and for itself, and that this absence of co-ordination later in the disease is very much influenced by the material changes in the muscular structure, as well as by many other circumstances.

This change of the false co-ordination in old cases of divergent strabismus manifests itself also as a rule in monocular vision with the squinting eye. When the sound eye is covered, the patient as a rule in pointing at an object situated in the median plane, misses it. Generally he fails towards the side of the healthy eye. Still it also happens, that the finger, when rapidly thrust forward, passes by the object towards the side of the squinting eye. In one case of the latter kind the tenotomy of the squinting muscle was performed with an unsatisfactory result.

In monocular vision, the squinting eye in recent cases of permanent divergent squint and of periodic strabismus divergens is just as well co-ordinated as under normal conditions, the patient fails but seldom in thrusting at an object, and can accomplish his work without intermission, provided the functional energy of the retina be normal, as a proof that the absence of co-ordination of the squinting eye is connected with its deviation, *i.e.*, disappears when the squinting eye is directed correctly towards an object.

7. The deviation of squint and the absence of co-ordination of the squinting eye occasioned by it exclude binocular vision; the images belonging to the squinting eye, of objects situated in the common field of vision, are completely suppressed under the action of both retinæ, the retina therefore of the deviated eye performs its functions merely with a more or less wide zone of its inner periphery. Still even here the absence of co-ordination is from the commencement strongly marked under all circumstances. Where double images of a monocularly fixed object appear, either spontaneously or by the aid of certain manœuvers, this is of course the case. Where, however binocular, diplopia does not make itself felt, this follows from a

simple experiment. In fact such patients cannot give any definite information concerning the position of objects, which are moved round in the monocular visual field of the squinting eye, while the other eye fixes an object, even when they are still to some extent able to see the object of the squinting eye distinctly.

8. The region of suppression of the retina of the deviated eye is generally very extensive in divergent squint. Within its range, a very considerable torpidity of the retinal elements, and therefore a central anæsthesia usually manifests itself much earlier than in convergent squint. The limits of the latter can then be sometimes very exactly determined, and appears sometimes distinct, sometimes diffused.

Not uncommonly, however, we also meet with cases, in which the functional disturbance extends over the entire retina and becomes a true amblyopia.

9. If there is absence of co-ordination in the divergent squinting eye, the deviation cannot, as in convergent squint, be occasioned by a voluntary, and therefore conscious innervation, even if in the normal condition there existed the power to produce and maintain considerable differences of the visual lines voluntarily, and not merely forcibly by abducting prisms. The divergent squint must consequently be placed to the account of an involuntary, and therefore unconscious process, which however as little excludes the feeling of deviation as in spasms.

It has been hitherto almost universally believed that the cause must be sought in an insufficiency of the internal recti muscles, *i. e.*, in a diminution of the actual or potential functional energy of the muscles of convergence. Against the basis of a muscular weakness, however, overpowering objections can be raised.

First, such a condition could be employed as explanation for those gradual deviations, which the squinting eye often undergoes by approximation of an object situated in the median plane within the limit of binocular fixation. But if an insufficiency of the muscles themselves were manifested in this deviation, then a relatively increased innervation to convergence would have to be introduced for every object situated beyond that limit, and consequently a confusion in the estimate of the perspective must result; the object in question must be seen at all distances smaller and nearer, which is not the case. In the same manner the insufficiency in changing the direction of vision in the course of the one or the other internal rectus muscle must be made manifest by excursive limitation of the eye and by a false estimate of the direction of the point of fixation, whether a monocular or binocular visual act takes place. Such an absence of co-ordination, however, is only met with as a matter of experience in old cases, especially where material changes in the muscular structure are to be assumed or demonstrated.

Still less can the excursive squinting deviations be made to agree with a muscular insufficiency. One visual line deviates as a rule far beyond the measure of convergence, which is still easily produced and maintained by the patient in question, with a corresponding distance of the object, and frequently the reciprocal position of the visual lines becomes a divergent one, while the range of convergence is still very considerable. How finally are the excursive squinting deviations to be explained, which appear when the eye is not fixed and during distant vision, while the patient fixes binocularly nearer objects easily and continuously.

If an insufficiency is at the bottom of the divergent squint, it cannot affect the muscular structure, at least so long as the strabismus remains pure, but only its conditions of innervation. For the excursive squinting deviations, an abducting innervation must moreover be assumed as cause, for they cannot be explained merely by the yielding of an internal rectus muscle, but must be regarded as active effects of the abducting muscles.

Till further fundamental investigations admit of a definite opinion concerning the character of strabismus divergens, we must assume, in accordance with all that has been stated, that in the divergent deviation of the squinting eye, there is mani-

fested a disturbance of those co-ordinate conditions which, in the normal state, connect fixed amounts of accommodation and convergence with each other.

This disturbance of co-ordination in fact manifests itself very distinctly by the considerable overbalance of the abducting ability of the eyes as opposed to the amount of adduction disposable at a fixed distance of the object.

In the normal state, in observing distant objects, and therefore with parallelism of the optical axes, only very weak prisms with the base inwards are overcome; the voluntary turning outwards of the eye seems under such circumstances very limited; but it increases, and so much the stronger prisms are borne without diplopia by voluntary tension of the external recti muscles in question, the nearer the object approaches the eyes in the median line. The voluntary adduction always overbalances under all circumstances, and with the same distance of the object much stronger prisms with the base outwards are always overcome by voluntary turning-in of the eye, than prisms with the base inwards by voluntary abduction; only in the neighborhood of the accommodative near-point are the adduction and abduction which can be produced by prisms, usually equivalent. In the cases in which the way has been prepared for strabismus divergens, or in which it has already appeared in the periodic form, this relation is reversed in favor of abducting ability; at the distance of the usual occupations prisms with the base inwards are overcome, which have a far greater, often double and treble as large a refracting angle, than those prisms which are borne with the base outwards without causing diplopia; even for great distances the abduction still often overbalances, so that tolerably strong prisms with the base inwards are still overcome, while very weak prisms with the base outwards produce incurable diplopia. These appearances are manifested in an especially distinct manner, when the visual plane is horizontal or even inclines upwards (*Graefe*).

Causes.—Strabismus divergens is accompanied by myopia in more than half the cases. This error of refraction has hence for a long time been connected etiologically with divergent squint, and ophthalmologists have sought to explain the deviation in part directly from the need of extreme convergence (*Beer*), but in part from the resistance to the action of the internal straight muscles, which, in elongation of the eyeball and especially when a large staphyloma posticum is present, proceeds so much the more from a displacement of the centre of rotation, as the angle, which the visual line makes with the axis of the cornea, is under such conditions often very small, and sometimes even negative, and therefore the necessity for work of the muscles of convergence is perceptibly increased (*Donders, Schuerman, Graefe*).

Experience shows that strabismus divergens may be referred to the increased resistance to convergence, since this form of squint is found in a very small percentage of numbers in school-children, where large posterior scleral staphylomata only exceptionally occur (*H. Cohn*), but is usually developed much oftener during the period of youth or even in mature manhood, particularly in individuals whose occupation requires close application for near objects, and since in many cases the development of divergent strabismus coincides very closely with the appearance or with the rapid increase of a staphyloma posticum. On the contrary, however, the fact is of great importance, that the same resistance, which renders a great degree of convergence difficult, is also opposed to excursive divergent squint; the cases of myopia accompanied by strabismus externus can only in about half the cases be reckoned as of a high degree, and only a small part of them seem to be combined with posterior scleral staphylomata of a width of more than half the breadth of the papilla. In addition comes the fact, that among the myopes with divergent squint there are not a few, whose eyes are in a morbid condition, which in and for themselves, without combination with myopia, may originate or at least favor divergent

squint. Moreover it should not be overlooked that among the cases of divergent squint we also meet with hypermetropes and emmetropes with perfectly healthy eyes.

Among 4,000 eye-patients of all ages there were 350 myopes, 399 hypermetropes and 42 cases of divergent squint. Of the 350 myopes 27 squinted outwards, or about 7·7%. On the other hand, the proportion of the myopes to the entire number of cases of divergent squint was somewhat more than 64%. Among these there were only 14 in which the refraction rose above $\frac{1}{5}$, and 4 in which a staphyloma posticum exceeding in diameter half the width of the papilla could be demonstrated. In two cases only the squinting eye was myopic, on account of the development of a staphyloma posticum, and the other eye was emmetropic. In 2 cases there were maculæ corneæ on both sides, in one case it existed on one side, and in 3 cases there was cataract of the squinting eye. The number of pure cases of binocular myopia was therefore reduced to 19, *i.e.*, to more than 45%.

Of the 399 hypermetropes 7 squinted outwards, *i.e.*, 1.75%. On the contrary, the proportion per cent. of hypermetropes among the cases of divergent squint was 16.6%. The degree of hypermetropia here varied between $\frac{1}{24}$ and $\frac{1}{10}$, but rose above $\frac{1}{14}$ in negative direction only in 3 cases. Morbid conditions of the eye were here entirely wanting.

In 8 cases, *i.e.*, in about 19% of the cases of divergent squint, there was emmetropia, yet the eyes were healthy in only two cases, in 3 cases there were found maculæ corneæ on both sides, and one case each of phthisis corneæ, macula corneæ with cataracta centralis, and retrogressive total cataract of the squinting eye.

If we connect all this together, we are again forced to the conclusion, that the original cause for strabismus externus cannot be so well sought in anomalous conditions of the eyes and their muscles, *i.e.*, not in any existing errors of refraction, opacities of the dioptric media, etc., but must lie much deeper, in morbid conditions of innervation of the muscles of convergence. This is in accordance with the experience that divergent squint not very uncommonly appears suddenly after severe diseases, particularly after affections of the brain, meningitis, etc. In agreement therewith stands also the result of a number of investigations (*Graefe*), according to which there is reason for believing that the power of abduction of the eyes is in very many cases considerably superior to the power of adduction not only in myopia but otherwise, and that this incongruity is not uncommonly inherited; further, it is exactly such cases which furnish the greatest contingent to the category of divergent squint, since the disposition to strabismus externus increases in the same measure as in a special case the adduction is surpassed by the abduction.

If this is correct, then the myopia, the binocular opacities of the dioptric media and in a certain sense also a higher degree of astigmatism (*Pagenstecher*, *Dobrowolsky*), as well as hypermetropia, may be considered as being in pathogenetic connection with the strabismus divergens, in so far as these conditions increase the necessity for convergence either directly or in behalf of enlargement of the retinal images, and thus permitting the disturbance of innervation already typified which is independent of it to become more easily and therefore more frequently manifest. The proportionally frequent appearance of strabismus externus is then very naturally explained in morbid conditions, which make the binocular visual act impossible or less valuable, even if not disturbing, particularly in very different states of refraction of both eyes, in monolateral opacities of the dioptric media, in transient paralysis of separate muscles (*Graefe*), after severe operative interference on one eye, in monocular blindness, etc.

Having premised this much, the fact does not seem wonderful that conditions of the eyes, apparently perfectly similar, occasion sometimes divergent squint, sometimes convergent squint, and sometimes neither. It is then of considerable moment,

how in a given case the power of adduction and abduction of the patient is determined.

Course.—a. Strabismus divergens is usually developed very gradually, particularly when myopia has any part in causing it. The insufficiency of the power of convergence first manifests itself merely in more rapid fatigue of the eyes, particularly when the occupation of the patient requires continuous fixation of near objects. Hyperæmic conditions then soon appear, accompanied by the feeling of tension, fulness and real pain, which force the patient to rest the eyes for some time. If the work is continued, the affection becomes very similar to accommodative asthenopia; still the retinæ in muscular asthenopia do not have to contend with circles of dispersion and too small images, but with the latter and double images. The patients are therefore accustomed to complain not so much of an increase in the width and indistinctness of the borders of the neighboring letters, but rather of a convergence and running into one another of these letters, corresponding to the immovable condition of the squinting eye under greater demands for convergence. In individual cases the patient may aid himself for some time by removing the object further from the eye. As a rule, however, this means succeeds much less in muscular asthenopia than in the accommodative form. Many patients therefore prefer, from the first, or as soon as symptoms of indistinctness appear, to close the weaker eye or cover it with the hand. Many move the object also towards the affected side and consequently fix with corresponding lengthening of the internal rectus in question, and thus diminish its necessity for work (*Graefe*). But still by these means only a very transient alleviation is wont to be obtained; as a matter of experience a lengthy interruption of work and even the nightly rest does not suffice in muscular asthenopia to establish a considerable continuance of the functional energy; the energy of the converging movements, once sunken, rises again much more slowly and with more difficulty than that of the muscle of accommodation.

Gradually one eye moves more outwards, an excursive squint appears, which at first is wont to be connected with diplopia, and generally immediately disappears when the patient looks away from the object of his occupation, and hence it remains for a long time unnoticed by those surrounding the patient. With continued work this excursive deviation becomes more frequent, while the phantom image of the squinting eye is suppressed more and more easily, and thus renounces its disturbing influence. If asthenopic troubles had existed they disappear, and for the patient there has arisen from this squint an essential alleviation of the visual act. Finally the squinting eye, even during the non-working hours, moves into the pathological position from every slight cause, and at last the strabismus becomes permanent.

b. In another series of cases, especially where confusion in binocular vision takes place, strabismus divergens is developed more or less quickly or even suddenly, without asthenopia having preceded it. It appears here also at first periodically as a rule, but with excursive deviation, generally without the patient having been specially annoyed by diplopia, since the suppression of the phantom image under such circumstances usually succeeds easily. At first the person squinting has still very often a tolerable amount of power over the muscles, and can still correct the false position of the eye without difficulty and for a considerable length of time. Sooner or later, however, this influence grows constantly less and the strabismus becomes permanent.

Results.—It is not definitely settled whether strabismus divergens, when it has already appeared in the form of excursive deviations, can spontaneously recede, that is to say, whether it can be outgrown. At any rate, the firm establishment and gradual increase of the squinting deviation forms the rule. Experience shows that degeneration of the muscles concerned, central anæsthesia of the retina, and finally real amblyopia occur much more easily and quickly in strabismus divergens than in convergent squint.

Treatment.—We aim from the first at prevention of the affection, and in cases where the actual conditions cause us to suspect the development of a strabismus divergens, or where the symptoms of muscular asthenopia already manifest themselves, our efforts should be especially directed to a lessening of the necessity for convergence and to the doing away with all that may confuse or hinder in any manner single binocular vision.

To this end all occupations which make great demands on the muscles of convergence must be limited as much as possible, or at least the circumstances be made to assume a more favorable form. In so far it is sometimes necessary to regulate the illumination and improve any bad posture which the patient may be subject to, etc. In the majority of cases, however, we shall be compelled to neutralize existing errors of refraction, or at least to correct them so far that the patient is enabled to remove the objects of his work somewhat farther from the eye. According to the nature of the special case, cylindrical, convex, and, in higher degrees of myopia, concave glasses are naturally to be used. In fact we sometimes in this way succeed in banishing the asthenopic troubles of the patient and preventing the development of the strabismus. Generally, however, the glasses prove insufficient, since the occupation does not admit of the removal of the object to the necessary extent, or it may be that the shortness of the arms or the diminution of the retinal images acts as a hindrance.

In such cases we may try to lessen the necessary amounts of convergence by abducting prisms with the base inwards. These prisms, in case they disturb in a troublesome manner the co-ordinate relations of the muscular apparatus of convergence and accommodation, are naturally to be combined with spherical glasses, which lower the amounts of accommodation to the corresponding degree. The rules for these corrections have already been mentioned sufficiently in the chapter on the errors of refraction. There remains therefore only to point out that for continuous work in general only those prisms are applicable whose refracting angle is not greater than 3° or at most 4°, since in stronger prisms the chromatic aberration, the distortion of objects situated laterally and the reflexion of light, become very perceptible, without any reference to their troublesome weight. Therefore it is advisable under all circumstances to place prisms before both eyes, and thus divide the necessary refractive value between two prisms. As a rule, we shall succeed with prisms of 2°—3° placed before each eye. The choice is determined by direct experiment.

It is hardly necessary to mention, that the combination of a prism with a convex or concave lens must be made only for the experiment in the narrow sense of the word. For use the necessary lenticular curvatures must be ground upon the surfaces of the prisms. Such glasses were first introduced into science under the name of dissecting glasses (*Bracke*), and gave the first impulse to the more exact investigation of muscular asthenopia and of the means applicable to its cure.

On the whole, we should expect but slight success even from prismatic glasses, as they exert no influence upon the actual original affection, and, as has already been mentioned, alter the range of convergence of the individual in question but little or not at all. The prospect of a re-establishment of the normal condition becomes so much the less probable, when even at work, excursive deviations have perhaps already become manifest. Here we but rarely succeed in re-establishing permanently the single binocular vision. In such cases therefore it becomes extremely necessary to oppose the development of central anæsthesia by systematic exercise in vision of the squinting eye, and to hinder its passing into actual amblyopia, in order on the one hand to maintain the visual field of the patient as wide as possible, but on the other hand to keep a reserve for the patient in case the healthy eye should be injured.

In one case of a 9 years old child, whose right eye had become affected by divergent strabismus in the second year of life in consequence of hydrocephalus, the power of vision was by such exercise not merely so far increased that the patient could read fine print easily and continuously, but the squint also disappeared. After several months of apparent cure there occurred a large extravasation of blood into the vitreous humor, which stopped up the pupillary region completely and the divergent squint immediately reappeared.

In consequence of the insufficiency of the means before mentioned, it was found necessary to bring about the correction of divergent strabismus by operative interference, and to extend the indication for the tenotomy to muscular asthenopia. Recently encouraged by apparent success, the tenotomy of the external rectus is recommended as a means of hindering the increase of myopia, and even of diminishing the degree of myopia already existing. Still we must well consider before undertaking such a procedure, that the co-ordination of the eye in question is by the tenotomy essentially changed, and every prospect of a re-establishment of single binocular vision act is destroyed for ever. The operation leads not very uncommonly to extremely troublesome binocular diplopia which lasts for a long time, and resists all means for its relief. That this does not always occur is explained by the fact, that in strabismus divergens the ability to suppress the impressions of the squinting eye is commonly early developed to a great extent, and that the region of suppression is generally very extensive, and thus not only the physician, but also the patient, is very easily deceived concerning the service rendered by the operation.

The tenotomy is nothing but a pure cosmetic operation which may conceal the squint, but can never cure it. Therefore it appears justified only where we are dealing with a disfiguring and permanent strabismus, and every prospect of restoring single binocular vision has disappeared.

The same rules hold good for the operation, as in convergent squint. Still the final effect of equally graduated tenotomies of the external recti muscles, particularly in old cases where material changes in the muscular structure already have occurred, is much less evident to the eyes than in tenotomies of the interni; hence the advice, in every excursive divergent squint, to combine the advancement of the antagonist with the tenotomy of the squinting muscle, is of great weight (*Schweigger*).

If double images make their appearance after such an operative procedure, which trouble the patient very much, there remains nothing to be done but by the means already mentioned, to bring about the method of cure attempted by nature, the exclusion of the squinting eye from the act of vision, but to exercise the squinting eye separately, in order to prevent its falling into an amblyopic condition.

Authorities.—*Javal*, Congrès Ophth. 1868. S. 107.—*Knapp*, ibid. S. 112; 1863. S. 96.—*Mooren*, Ophth. Beiträge. S. III., 3 30 u. f.—*Graefe*, Congrès Ophth. 1868. S. 109; Congrès int. d'ophth. Paris. 1853. S. 93; kl. Monatbl. 1869. S. 225-281.—*Donders*, Centralbl. 1867. S. 526.—*Beer*, Lehre v. d. Augenkrankheiten. 1817. II. S. 653.—*Schuermann*, Vijfde Jaarl. Verslag. Utrecht. 1864. S. 1; kl. Monatbl. 1864. S. 92, 95.—*Hering*, Das binoc. Sehen. Leipzig. 1866. S. 144.—*Alf. Graefe*, kl. Monatbl. 1867. S. 1 u. f.—*Schweigger*, Göttinger nachrichten. 1870. S. 262, 266.—*Pagenstecher*, kl. Beob. III. S. 89, 102, 120.—*Schiess-Gemuseus*, kl. Monatbl. 1867, S. 79.—*Zehender*, ibid. 1868. S. 136.—*Mannhardt*, ibid. XV. 1. S. 288.—*Brücke*, A. f. O. V. 2. S. 180.—*Laudsberg*, ibid. XI. 1. S. 69, u. f. *Boehm*, der Nystagmus, &c. Berlin. S. 63, 111.

2. Nystagmus.

Symptoms.—*This affection is characterized by tremulous movements of eyes whose mobility is not otherwise impaired. These movements are involuntary, exceedingly rapid, almost rhythmical, and affect both eyes at the same time.*

The oscillations occur, with very rare exceptions (*Mooren*), in both eyes simultaneously and in the same direction. Their course lies generally in the plane of rotation of the external and internal recti muscles; more rarely it is oblique or varies in different directions. The oscillations are often excursively rotatory and occur alternately in the course of the muscles of both eyes. Cases also occur, in which the tremulous movements take place in the course of certain recti muscles and of the oblique muscles (*Nagel*). Hence we distinguish an oscillatory, rotatory and mixed nystagmus (*Böhm*).

The peculiar phenomenon is at times only seen periodically, under very especial circumstances. Nystagmus is more frequently permanent, continuing almost without interruption during the waking hours. It may vary in severity, and in some positions of the eye be changed to a quiet glance.

For example, in many cases of continuous nystagmus the eye becomes quiet, when it is turned laterally very much, in a horizontal or oblique direction, and is directed upon a more or less distant point. In other cases this occurs if objects in the median plane and at a certain distance are looked upon. Some patients have several such points of rest, others only one, and others none at all. In the latter cases the oscillations continue in every direction of the optic axes, and at most lose somewhat of their intensity and extent. (*Böhm.*)

On the other hand, the periodical nystagmus is usually excited, and the continuous, greatly increased if the patient is excited, and if exact vision of near objects requires great straining of the muscles of accommodation and convergence, or if the recognition of objects is rendered difficult by a poor illumination. The relative position and distance of the object also have an influence. It is said to have been observed, that the tremulousness increases in proportion as the eyes are turned from the point where a quiet gaze is obtained, to one side or to different distances, and frequent change in the position of an object is particularly a cause, which is apt to increase the nystagmus decidedly, and for a long time. Sometimes the lateral motion of the eyes, which is necessary in following lines in reading, is sufficient to excite the nystagmus; hence the patients, in order to avoid the tremulousness, move the head rather than the eyes, or push the book to one side in order to have the words at the point of quiet vision, or they hold the book so that they run over the lines perpendicularly with the assistance of the upper and lower recti muscles. Nystagmus is particularly excited by looking at objects or men moving among each other; hence patients in crowded streets, where their gaze must be constantly turned from side to side, now at objects that are near and again at those which are far off, are immediately attacked by very great tremulousness of the eyes, which then remains even after their return to their room, where they are alone, and prevents them from taking up any employment which requires a quick fixation of the objects for some time. (*Böhm.*)

2. Nystagmus of itself does not in any way impair the simultaneous action of the two eyes. Yet it is very frequently complicated with, or rather etiologically connected to, conditions which render binocular vision impossible, with impairments of functions of one or both eyes, with strabismus, &c.

3. The patient does not generally perceive the tremulousness of his eyes. He

sees all objects just as they are, either in a state of rest or motion. But nystagmus always impairs the sight. The movements of the retinal images, here and there, renders the vision confused in proportion to the severity and extent of the tremulous movements. This impairment of vision is, however, only very marked when the patient is looking at very fine objects, in motion or at rest, or when he wishes to find out quickly the relative position and distance of objects. Reading very fine writing or type, working upon embroidery, fine sewing, &c., are generally very troublesome, if the nystagmus becomes greater while thus employed; walking in crowded streets, walking in rooms filled with people, is very uncertain; the patient stumbles all the time.

There is a method of correction of the trouble which many patients make use of at first voluntarily, but which they subsequently unconsciously attain by means of long practice and habit. They move the head in a contrary direction from the movements of the eyes, by a perfectly coincident action of the cervical muscles, by which they are enabled to keep the visual axes immovably on the fixed point. These movements of the head are in some cases quite remarkable; they increase and decrease with the nystagmus, but may often be suppressed and again called up at will. They often appear only when the patient desires to "fix" some object sharply, and can not bring the eye to rest.

Causes.—Nystagmus develops itself almost always in infancy. It is doubtful if it is, as many suppose, sometimes brought into the world fully developed, and is thus a hereditary disease. However, the oscillation of the eyes is first remarked, in by far the greater number of cases, when great requirements are made on the activity of the muscles of the eye, that is, at the beginning of school-life. It appears also, as if exactly this strain provoked the formation of the disease; as if the nystagmus from an etiological stand-point, concealed itself similarly to the strabismus that so often accompanies it. Such a view is certainly supported by the fact that nystagmus, with rare exceptions, is developed only in cases in which, during childhood, the attainment of sharp or even moderately clear perceptions was difficult, and required a decided approach of the object to the eyes, and thus great opportunity was given for overburdening them. In fact, nystagmus is by far most frequently found with corneal opacities, especially, on both sides, which occur in the early years of life; with congenital short-sightedness; with central capsular cataract, and other partial cataracts, which date from childhood; with faulty development of the eyes; with functional disturbance of the optic nerve and retina.

The primal cause of the affection, as in squint, lies doubtless in disturbances of innervation, and the recent discovery that certain centers exist in the region of the corpora quadrigemina of the brain, the irritation of which gives rise to oscillatory movements of the eyes very similar to nystagmus, is in so far of importance (*Adamük*).

Exceptionally, nystagmus occurs in older children, or grown persons, even with complete integrity of the function of vision. In this view, of course, we do not consider the visual loss caused by the nystagmus itself.

But then we may almost suspect that in such cases impairment of sight existed in the first years of life, which increased the work of the muscles, but which was in time relieved. On the other hand, we not unfrequently meet with nystagmus in cases in which the condition of the eyes—extensive degeneration of the cornea, cataract, want of development of the eye-balls, &c.—makes any distinct perceptions absolutely impossible. Overburdening of the muscles is also not entirely excluded in such cases; but we frequently see such children bringing every thing which

they take in their hands close to the eyes, and often in a very peculiar position, in order to amuse themselves with the changing shadows, which occur on a fanning motion of the objects.

Course.—Nystagmus once developed, generally exists unchanged through life; yet, according to recent observations, a spontaneous improvement, and even cure, is not impossible; especially when the impairments of sight are neutralized or removed, and thus the demands on the ocular muscles lessened.

Treatment.—Prophylactic means are to be adopted, just as in strabismus. Their principal aim is to avoid all excessive strainings of the ocular muscles, together with the removal of neutralization of the impairments of vision.

But if nystagmus is once fully developed, there is not much to be done. After improving the vision, however, we may attempt to secure an improvement or cure by appropriate exercise of the muscles. In doing this, we gradually change the direction and distance of the objects, and increase the duration of the exercises, proceeding from the point of quiet vision.

Setting back the insertions of the affected muscles has been well spoken of. (*Böhm.*) Doubts are, however, already raised on many sides as to the effectiveness of this method. (*Ruete, Nakonz.*)

Perhaps it is a question of deception, as in squint, in so far as by a tenotomy of the muscle in question, the extent of motion in the oscillations must evidently diminish.

The choice of an occupation is important. In order to render nystagmus as painless and harmless as possible, those employments only should be chosen which require only a moderate degree of looking hither and thither, and permit the compensation of the effects of the nystagmus, by slight movements of the head. In short-sighted persons fine work is not impossible, provided the object can be kept perfectly quiet. Where corneal opacities, &c., render sharp vision impossible, those occupations suit best where perfect vision is not required, and the sense of touch can aid the patient somewhat, such as baking, basket-making, gardening, etc.

Authorities.—*Böhm*, Der Nystagmus und dessen Heilung. Berlin, 1857.—*Ruete*, Lehrb. d. Ophth. II. Braunschweig. 1854. S. 492, 495.—*Graefe*, A. f. O. I. 1. S. 10.—*Nakonz*, ibid. V. 1. S. 37.—*Mooren*, Ophth. Beob. S. 339.—*H. Cohn*, Untersuchung. von 10,060 Schulkindern. 1867. S. 167.—*Adamück*, Centralbl. 1870. S. 65.—*Nagel*, A. f. O. XIV. 2. S. 240.—*Kugel*, ibid. XIII. 2. S. 413.—*Fano*, Virchow's Jahresber. 1868. II. S. 488.

3. Paralysis of the Muscles of the Eye.

Symptoms.—*The characteristic symptom of paralysis of the muscles of the eye is lessening of the mobility of the organ, in the course of individual muscles, or groups of muscles, and a consequent and exceedingly variable deviation of one of the optic axes, in binocular vision.*

1. In order to determine with accuracy the chief symptom, that is, the difficulty of directing the eye in certain directions, we may adopt a similar proceeding with that for the determination of insufficiency. If we first wish to assure ourselves merely as to the actual existence of a paresis, we proceed as in an examination of the angle of squint.

We cause the patient to look steadily at a finger placed at the distance of most distinct vision, and parallel to the perpendicular axis of the head, while we carry it out of the middle line, in various directions on the borders of the visual field. We at the same time note the deviations which the affected eye undergoes in binocular vision, and again when the sound eye is covered.

In paresis of the lowest degree, the impairment of the mobility of the eye is not very marked. It generally first declares itself by a feeling of tension in the eye, when the patient wishes to look at objects in a certain direction, and to maintain the position of the eye at this point. The affected muscles then become tired very easily. They can only do their work spasmodically, or at intervals. The eye acquires a tremulous movement, and finally yields very much to the side of the antagonistic muscle. (*Graefe.*)

In partial paralysis, the false position of the affected eye is, as a rule, very marked, if the object be turned from the median position into the course of the paralytic muscle. Sooner or later the affected eye remains behind the object, so that its visual line shoots by it, in the course of the antagonist. The sound eye is deviated in the same direction, e. g. to the right or left, if the affected one alone be employed in fixation, that is, the former being covered. The angle of deviation is then larger, however. This is in proportion to the greatness of the demands made upon the paralytic muscle. It is the larger the more the object in the course of the affected muscle is turned from the median line, the longer the examination lasts, the greater the paralysis. There is an important diagnostic assistance in this, which should never be neglected.

In complete paralysis, the deviation of the affected eye is noticed in the median position of the object, since the great relative preponderance of the muscle not affected is then seen, and the field of binocular fixation is pushed entirely to the side of the sound eye, and limited to a small amount. The affected muscles are, at the most, only capable of weak contractions with a small excursion, and movements of the globe in their course can only be accomplished spasmodically, through the combined action of other muscles.

2. The deviation of a visual line necessarily leads to binocular double vision.

This plays a very important part in the symptoms of paralysis of the muscles, and, in the greater number of cases, is the symptom most complained of by the patient. It is usually the most marked and painful symptom, especially where the deviation, on account of its smallness, is not very prominent, and the distance, therefore, of the double images from each other is also slight. Under ordinary circumstances, the double image of the affected eye is not perceived in any position of the object. The sound eye requires to be covered by a deeply-colored glass, or a prism must be used, in order to cause the diplopia to appear. These are almost always old cases, with great strabismic deviation, where the marked eccentricity of the retinal image, in connection with the disturbances of accommodation, very much diminishes the clearness of the perceptions of the affected eye, and greatly favors their suppression.

The amount of deviation of the double images stands, of course, in proportion to the size of the angle of deviation. It becomes nothing; the double images unite, when the object takes a position for which a certain adjustment of the optic axes is still possible. The field of the binocular single vision is not always, then, in proportion to the magnitude of the limitation in motion. Cases frequently occur, where the limitation is slight, but the double vision extends over the greater part of the whole course of the paralytic muscle, and others, where, in spite of great limitation in motion, diplopia only appears within narrow bounds. Still more, the excursive power in the course of paralyzed muscles may, according to experience, increase and decrease, without any enlargement and diminution of the field of binocular single vision. (*Benedikt.*)

The power of voluntary abduction and adduction comes into consideration here. In different persons this is very different, and may be considerably influenced by a number of circumstances. Thus it is clear that the innervation directed toward correction of the position of the eyes, may easily disappear, or prove insufficient, if the urgency for single vision be slight, if the patient easily suppresses the perceptions of the deviated retina, and if, at the same time, this suppression is favored by diminished acuteness of vision, insufficient accommodation of the eye, very eccentric position of the images, and so on.

The natural conditions of association between the muscle of accommodation and the two lateral recti, make themselves known in a very marked way. A corrective adduction must succeed much more readily, when the distance of the object, and the state of the refraction of the eye, render a very great straining of the accommodation necessary. On the contrary, a corrective abduction, together with maximal relaxation of the accommodation, finds the most favorable conditions. In other words, the field of binocular vision will be much larger in hypermetropes, in the course of a paralytic internal rectus, if near objects are observed. But a myope with partial paralysis of the external rectus will see far objects in a much greater proportionate lateral distance from each other, than near ones.

Here, also, is to be considered, not only the facility or difficulty with which an innervation tending toward correction is induced, but also the increased resistance which the lateral recti offer to the diametrically opposite movements of the eye, with a state of tension or relaxation of the ciliary muscle. For example, a hypermetrope, in looking at near objects, will only, with the greatest difficulty, make a corrective movement of abduction, on account of the unavoidable tension of the internal recti. Yet, under normal circumstances, it is seen that the excursive power of the globes in the course of the external recti, is greater, in a parallel position of the two visual

lines; that is, in distant vision, when the internel recti are less tense, than when convergent. (*Hering.*)

If the voluntary correction of the paralytic deviation can not, from any cause, be made, the innervation directed to secure this end soon ceases, and the affected globe takes a position which corresponds to the impaired muscular equilibrium; that is, it deviates the more from the normal, the farther the paralysis has advanced, the greater demands are made on the paralyzed muscle, and the greater resistances this has to contend against. We may see this deviation very distinctly, if a voluntarily-induced correction be suddenly removed by placing a prism before the eye, which can not be overcome.

In correspondence with the laws of the identical visual direction, the relation of the visual lines and the position of certain meridians to each other, may be measured from the situation of the double images, which are cast upon the retina from an object properly fixed with one eye. But, if we wish to avoid the troublesome calculations which changed conditions of projection induce, it is necessary to see to it, that the surface of the object always remains *normal* to the ideal visual plane, that is, to a plane which would pass through the properly-adjusted visual axes, and the base-line. We must first fix the object with the sound eye, having the visual axis horizontal, and directed exactly forward, and then note the symptoms. Then, for the purpose of employing single muscles, and groups of muscles, instead of lifting and sinking the visual plane, the head should be inclined forward or backward, while the visual plane remains unchanged in a horizontal position. In order to still further diminish the influence which convergence of the visual axes exerts upon the inclinations of the meridians, it is advisable to place the object at a distance of several steps off.

This moreover is necessary, because the binocular visual space in positions of convergence is limited even under normal conditions, and causes double images when the glance is directed very laterally and at the same time upwards or downwards towards near objects.

If, in this way, the deviation of the visual axes and of the vertical line of separation of the affected eye, for the given directions of vision, be made out with certainty, the premises are furnished, to come to a conclusion as to the seat and extent of the paralysis. Yet we cannot be too careful here, especially when we are dealing with false inclinations of the meridians, since there are many circumstances which render the solution of the problem very difficult. Thus the normal meridian inclinations, which accompany certain directions of the vision, must be considered. Nor should we overlook the fact that abnormal resistances and positions of the points of rotation, as well as displacements of the resulting course, with an irregular paralysis of single bundles of one muscle or of a group of muscles, may be of importance. We should also remember that it is often very difficult to secure exact horizontal or perpendicular movements of the fixating eye without movements of the head at the same time; and the statements of the patients as to the situation of the double images is very untrustworthy.

a. If a lateral rectus alone be paralyzed, the visual axis of the eye to which it belongs, with a primary position of the other, deviates horizontally from the object of fixation, in the course of the antagonist. If the gaze in the course of the paralyzed muscle be turned horizontally to one side, the affected globe follows the healthy one, for a certain distance, but always remains behind the latter, and if there be a complete paralysis of the muscle, does not pass beyond the median posi-

tion. The rotation is, then, on both sides around a vertical axis, and only a little less on the affected side. The two retinal images are therefore of the same height, but thrown upon different horizontal meridians, and appear about parallel to each other, and equally high, but crossed or homonymous, according as the internal or external rectus may be paralyzed. If now, while the ideal visual plane maintains the horizontal position, the head be moved greatly forward or backward, so that the former appears relatively raised or sunken, the visual axis will again remain behind, if the gaze be turned laterally in the course of the paralyzed muscle.

Consequently, the vertical meridians of the two retinas will not be parallel, since this is possible only with parallel visual axes, but in accordance with Listing's law, the one retina, in comparison to the other, will be distorted. In unison with this, the double images of a line vertical to a horizontal ideal visual plane will seem inclined to each other, always providing that all the fibers of the affected muscle are equally paralyzed, and that its resulting direction of action has undergone no great change.

If an external rectus muscle is paralyzed, and if a distant object situated in the median plane is to be fixed when the eyes are innervated for the primary position of the eyes, the visual line of the diseased eye turns away from the point of fixation towards the side of the healthy eye on account of the overbalance of the internus, and hence homonymous and parallel double images of the same height are perceived. The overbalance of the internal rectus, and therefore the lateral distance of both double images, also decreases or disappears when the glance is turned vertically upwards or towards the side of the healthy eye. On the contrary, the overbalance of the internus and with it the distance of the double images increases, when the glance is turned vertically downwards, or in any direction out of the median plane towards the side of the affected eye. In diagonal directions of the glance towards the side of the paralyzed muscle, a false inclination of the meridian then occurs. If the glance is turned out from the primary position of the eyes diagonally upwards and towards the diseased side, the axis of rotation of the paralyzed eye approximates the horizontal direction more than that of the healthy eye, the longitudinal median sections of both retinæ converge upwards, hence the double images diverge upwards on account of their being homonymous. If, on the contrary, the glance is turned downwards and towards the side of the paralyzed muscle, the axis of rotation of the affected eye again lies more horizontally than that of the healthy eye; while the vertical, longitudinal median section of the latter inclines very far outwards, the longitudinal median section of the paralytic eye is inclined but a little inwards, and the double images must correspondingly converge upwards, on account of their being homonymous. If an internal rectus is paralyzed, the visual line of the corresponding eye with innervated primary position turns away from the point of fixation towards the side of the latter, on account of overbalance of the externus, and hence diverges from the visual line of the other eye; consequently we get crossed double images, of the same height and parallel. The overbalance of the externus and therefore the lateral distance of the double images diminish, when the glance is turned vertically downwards or towards the side of the affected eye; on the contrary, the overbalance of the externus and the lateral distance of the double images increase, when the glance is turned vertically upwards or in any direction out of the median plane towards the side of the healthy eye. In diagonal directions of the glance towards the side of the healthy eye, false inclinations of the meridian again prevail, since the axis of rotation of the diseased eye is less distant from the horizontal than that of the healthy eye. If the glance is turned diagonally upwards and towards the sound side, the vertical lines of division of both retinæ diverge upwards; the two double images should converge upwards, but seem again divergent because they are crossed. In a diagonal direction of the glance downwards and towards the sound side, the vertical lines of division of the two retinæ on the contrary converge upwards, just as the crossed double images also do.

b. If a superior or inferior rectus is alone paralyzed, the visual line of the affected eye in the primary position of the healthy eye turns upwards or down-

wards, accordingly as the rectus inferior or superior suffers; at the same time this eye usually experiences a small deviation outwards, owing to the overbalance of the coördinated oblique muscle, while a false inclination of the meridian simultaneously appears, since the axis of rotation of the affected eye is different from that of the sound eye. In innervation of the primary position therefore double images of dissimilar height appear, which at a slight lateral distance are crossed and stand a little oblique to one another. These deviations increase, when the glance is turned out of the primary position into a direction which calls upon the active participation of the paralyzed muscle; they decrease when the direction of the glance changes in the opposite sense.

If a superior rectus is paralyzed, then in the innervated primary position of the eyes a crossed phantom-image standing higher appears, of a slight lateral distance, which is somewhat inclined to the image of the fixing eye, and diverges slightly with the upper end. If the glance is turned horizontally towards the healthy side or in any direction downwards, the difference in height and width, like the inclination of the double images, diminishes rapidly, and soon entirely disappears. On the contrary, these differences increase when the glance is turned horizontally towards the side of the affected eye or in any direction upwards. The difference in height of the double images reaches, in an innervated lifting of the visual plane, the maximum, when the glance is directed towards the side of the affected eye; on the contrary, the obliquity appears most evident when the glance is turned towards the sound side.

If an inferior rectus is paralyzed, then in the innervated primary position of the eyes the crossed phantom image of the affected eye, with slight lateral distance, stands somewhat lower, and converges slightly upwards with the image of the sound eye. These deviations diminish and soon disappear, when the glance is turned towards the sound side or in any direction upwards; on the contrary, they increase when the glance is turned towards the affected side or in any direction downwards. The difference in height reaches a maximum, when the glance, with depressed visual plane, is turned towards the side of the affected eye; on the contrary, the obliquity appears greatest when the glance, with depressed visual plane, is turned towards the sound side.

c. **If an oblique muscle alone be paralyzed, the circumstances are to a certain extent changed from those in paralysis of the associated recti. For example, we** will suppose that a superior oblique is paralytic. The visual axis of the affected eye (there being a primary position of the sound one) will deviate a very little upward and inward (*Graefe*), and the retina will undergo a slight rolling outward. The double images will then be on the same side—homonymus—that belonging to the affected eye will be somewhat lower down, and will converge upward with the other. Moreover, the image of the healthy eye seems to stand somewhat nearer and to be so inclined towards the body of the patient, that its upper end seems to be farther away. These differences decrease, when the object is turned towards the side of the affected eye or in any direction upwards; they increase, on the contrary, when the glance is turned towards the healthy side or in any direction downwards. The vertical distance, with diminution of the lateral distance and of the obliquity of the phantom image, reaches its maximum, when the glance is directed very much downwards and towards the healthy side. On the contrary, the obliquity becomes the greatest with decrease in the vertical and lateral distance, when the glance is turned strongly downwards and towards the side of the affected eye (*Graefe, Schuft*).

If an inferior oblique muscle is paralyzed, the relations are reversed, in so far as the phantom image of the affected eye stands higher and diverges, and moreover the differences are more strongly manifested by elevation of the visual plane, but disappear when the glance is lowered.

d. If several muscles of the same eye are paralyzed at once, the sound eye being in the primary position, and the direction of the gaze in the course of the paralytic group of muscles, the deviation of the visual axes and the rotation always occurs in the resultant of the antagonistic muscles. It varies according as the course of the intended rotation approaches the direction of action of one or the other paralytic muscles, and according as the paralysis is distributed evenly or unevenly over the group in question. On the whole, then, the conditions appear somewhat involved. Yet the laws governing the movements of the eyes, and of identical vision, furnish the means of determining the deviations of the visual axes, and of the position of the meridians in the various directions of the vision, from the reciprocal situation of the double images, as well as the extent of the paralysis, provided always that the examination be made with a horizontal ideal plane (in order to keep the extremely complicated conditions of projection out of the estimation); and besides this, the directions of the vision are only horizontal and vertical.

If all the muscles of the eye, supplied by the *oculo-motorius*—third pair—are paralyzed (and this is a very frequent occurrence), the opening of the palpebral fissure becomes very difficult or impossible. The lower border of the upper lid is much lower than that of the healthy eye, and it can only be lifted up to a certain hight, when the affected eye alone is used. It can be better done than when we attempt to open both eyes at the same time. Opening the lids can often be accomplished only with the aid of the muscles of the forehead. The globe of the eye seems somewhat prominent, and turned outward on account of the preponderance of the rectus externus. Its mobility is limited or removed in all directions, except outward and downward.

If the gaze be turned from the median position, horizontally, toward the sound eye, this deviation outward is always more distinct; but if the gaze be directed upward, in complete paralysis, the visual axis of the affected eye does not follow at all. On the contrary, if it be turned downward, the affected eye only follows slightly, and immediately deviates somewhat outward. In consonance with this, the double images appear crossed, in the primary position of the sound eye, and the lateral distance from each other increases with the amount of the deviation, which the view toward the side of the healthy eye undergoes.

The pupil of the affected eye is, with very rare exceptions, considerably enlarged, fixed, and immovable. By means of mydriatics, however, it may be fully dilated. The accommodative power is generally removed, although not necessarily so.

e. When all the muscles of the eye are paralyzed (*ophthalmo-plegia paralytica*), which is almost always coincident with paralysis of other cerebral and spinal nerves, we find the globe somewhat pushed forward, completely immovable, and covered by the paralyzed upper lid. Its optic axis is exactly forward or a little to the outer side. The pupil and accommodation are in the same condition as in complete paralysis of the third pair. (*Graefe.*)

3. A necessary result of the paralysis is an inability of the affected eye to find out where objects lie. If objects are to be "fixed," which lie in the course of the paralytic muscle, the patient, on account of the need of greater innervation, projects the whole visual field too far away, and consequently grasps beyond the object which he wishes to seize.

This impairment of function is often evinced by dizziness, especially when the muscles supplied by the third pair are paralyzed, but less in paralysis of the external rectus. The symptom is particularly prominent if the sound eye be covered, and is

then occasionally so troublesome, that the patient is scarcely able to maintain his footing.

4. In order to avoid the extremely annoying diplopia and dizziness, when he can not suppress the impression on the affected eye, the patient generally closes it, and uses the healthy one alone in fixation. But where he can, he endeavors to bring the object at which he wishes to look in such a relative position, by turning the head around a perpendicular, horizontal, or oblique axis, that the proper adjustment of the two visual lines requires very little or no expenditure of power on the part of the paretic muscle. (*Graefe.*)

If, for example, the eye be less movable toward the right, the patient turns the face, by means of the muscle of the neck, to the right, and thus lessens the work of the paralyzed muscle. But if excessive contraction of the antagonist has already appeared, the patient holds the head in the opposite way, because the suppression of the double image is thus most easily accomplished (*Graefe.*)

If a superior rectus muscle is paralyzed, the head is bent backwards; if on the contrary an inferior rectus muscle is paralyzed, the head is inclined downwards. In paralysis of a superior oblique muscle, the patient bends the head forward and turns it towards the sound side. (*Graefe, Schuft*).

Causes.—Paralysis of the muscles of the eye is never any thing but a symptom. It is a mark of extremely different morbid conditions, which affect the muscular tissue itself, and prevent it from giving any results from nervous impulses, or render the conduction of nerve-force in any point of the nerve-tracts, either difficult or impossible.

1. On the basis of this difference, paralysis is divided into spurious and true. The latter is again divided, according to the situation of the hindrances to conduction, into peripheral and central.

Atrophy of the muscular tissue should be particularly mentioned among the causes of spurious paralysis. This is congenital in exceptional cases. But it is usually a result of excessive tension after exophthalmos. It may also occur from the tension and permanent inactivity of the antagonist of the squinting muscle in old strabismus.

The other causes of spurious paralysis are: tendinous degeneration of the squinting muscle; cicatrices on muscles resulting from lacerated wounds; inflammation of the muscle with or without suppuration; destruction of the muscular tissue occurring in orbital tumors.

Perhaps *lagophthalmos cholericus* is to be classed here, since it is by no means ascertained, whether the impairment of sensibility in the cerebrum, or the diminution of the excitation from the fifth pair, or the loss of fluids depending on the peripheral muscular affection, together with the resistances offered by the dryness of the conjunctiva, is the actual cause of this form of spurious paralysis. (*Graefe.*)

2. Orbital abscesses, which injure one or more nervous branches or growths, penetrating wounds, &c., are causes of peripheral true paralysis. More frequently, however, such a paralysis is caused by rheumatic affections of the nerve-sheaths. These rheumatic paralyses are often accompanied by similar affections of the orbit and its surroundings. These most usually develop very quickly from great change of temperature, especially a draught of air. They are generally confined to one side, and even to single twigs of a nerve-branch, that is, to single muscles. The paralysis may appear, however, on both sides, and upon all the muscles of the globe, and, at

the same time, extend to other cerebral and spinal nerves. In cases of this kind of long standing, the remains of perineuritic disease, with atrophy of the nerve, have been seen. (*Graefe.*) In some cases, peripheral paralysis may have been caused by syphilitic affections of the orbit, and by participation of the nerve-sheath in the disease. In other cases, where syphilis is the cause, the paralysis is central.

3. Cerebro-spinal paralysis is at times binocular, and not always of the same severity or extent on both sides, or it is often combined with paralysis in the branches of other cerebral or spinal nerves. It then sometimes affects the whole section of a nerve, and is again confined to single bundles. The causes of this variety of paralysis are about the same with those which have been given in speaking of amaurosis, and we may refer the reader to them. In some cases, pure mechanical hindrances to conduction may be the cause, such as disturbances of circulation, morbid substances, or foreign matters in the blood. Yet these are rare exceptions. As a rule, we certainly have proliferative processes, which bear the character of a true inflammation, or gray atrophy, and are originally seated in the intracranial branches of the nerves, or in the actual point of origin and central connecting filaments.

a. Proliferation in the intracranial portions of the trunks of the nerves occasionally occurs independently, from very different causes. In the beginning, they are often confined to small portions of the nerves, but they are generally rapidly carried along the bundles of fibers, and cause the entire trunk to appear changed. Occasionally several intracranial nerves are affected at the same time, or within a short time of each other, without any common central focus being discovered. We must then suppose that there have been a number of foci. (*Türck.*)

The process seems more frequently to be secondary, especially as a consequence of basilar meningitis. The paralysis of the muscles of the eyes then appears often very early, even before any symptoms of the main affection have distinctly shown themselves, and is usually distinguished by great variability in the symptoms. At the same time the meningitis can be primary, or be occasioned by other morbid processes, *e. g.*, thrombosis of the sinus cavernosus (*Knapp*), or by fractures of the orbit (*Mans*), by periostitis and syphilis (*Leidesdorf*), etc. In other cases tumors make their appearance at the base of the skull, *e. g.*, a gliosarcomatous mass in the region of the sella turcica (*Leber*), the atheromatous degeneration and expansion of the portion of the carotid artery running in the sinus cavernosus (*Magni*), etc., as exciting cause of the paralysis. The interference in the conducting power is explained, under such circumstances, sometimes by direct passage of the growth to the neurilemma, sometimes by mechanical constriction of the main trunk in the neighborhood of the mass (*Türck*).

b. Actual brain affections sometimes lead to functional disturbances of the motor nerves of the eye, since separate nuclei of origin or central connecting fibres fall in the morbid mass itself or in the reactionary girdle surrounding it. The same holds good for the diseases of the spinal cord. Among the latter, tabes dorsalis is to be first mentioned, since in this disease paralysis of individual muscles frequently makes its appearance very early, or even appears as the first symptom.

The occurrence of lancinating pains in the extremities is said to be characteristic of this connection. It is also believed that such lancinating pains in the head, when they precede the paralysis of the muscles of the eye, and diminish in intensity with their appearance, point to a central origin (*Benedikt*).

b. True cerebral disease occasionally leads immediately to impairments of the functions of the motory ocular nerves, since the origins of the nerves or connecting filaments are involved in these diseases. Paralysis of the third cerebral nerve generally occurs in disease of the *crus cerebri*, and is then usually combined with paralysis of the opposite extremities. (*Duchek.*) On the other hand, paralysis of the facial nerve is generally a result of disease of the *pons varolii*, and is generally accompanied by paralysis of the extremities. (*Duchek.*)

Besides, paralysis of each of the motory ocular nerves is met with in the most diverse varieties and localizations of cerebral disease, and under conditions which cause us to look for the origin of the paralysis only in the primary situation of the disease.

In old persons, where such paralyses more frequently occur, true diseases of the encephalon, especially cerebral softening, are the causes of the impairment of the motion of the eye in a much larger proportion of cases than in young persons. It is imperatively necessary to consider this fact, even if the paralysis be at first confined to a single muscle only. Indeed, it often happens that such processes are first indicated by a narrowly circumscribed disease. Such a paralysis may even disappear, and several weeks or months afterward it may suddenly occur in a greater number of muscles, which will leave no doubt as to the existence of serious cerebral disease.

In other cases, diseases of the encephalon are only to be regarded as remote causes. The true source of the paralysis is either a secondary basilar meningitis, or an increased cerebral pressure. The pressure occasionally proceeds from tumors, which lie on the *pons varolii*, on the *crus cerebri* or its immediate vicinity, and on the surface of the cerebrum. In other cases, these parts of the brain themselves swell, on account of after-growths, apoplectic clots, &c., in their tissue, or in their surroundings, and press the nerves against the bones, or they cause the larger vascular twigs, which interlace with the nerve-trunks, to actually ligate the nerve (*Tarch*), or the filaments of connective tissue, which surround the vessels and nerves, and are attached to the base of the brain, compress the nerves. Cerebral pressure is often to be ascribed to a primary or secondary hydrocephalus.

4. In exceptional cases paralysis of individual muscles seems to depend merely on muscular anæsthesia, that is, is a result of the removal of muscular sensation. Such a paralysis is found in connection with anæsthesia of sensitive nerve-twigs. It may generally be quickly overcome by peripheral irritation of the anæsthetic twigs. (*Graefe.*)

5. We may, finally, merely mention the impairments of motion in the ocular muscles, which sometimes occur as a result of diphtheritis of the fauces.

Course and Results.—These vary exceedingly in individual cases, according to the varieties of the primary affections. Rheumatic paralysis usually occurs very quickly, often in a few hours, or in one night; while central paralysis, especially that depending on compression or primary inflammation of intracranial trunks, usually appears gradually, and perhaps increases. It is not necessary to state that very great deviations from this rule are not rare; this is understood, of course, from the peculiarity of the individual causes. It is, however, worthy of remark, that the progress of the paralysis is often variously interrupted. The symptoms of paralysis for a time vary in intensity and extent—increase, decrease, disappear, again appear, &c., till finally the condition becomes more stable. Occasionally, also, spasms appear while the paralysis exists or precede it, especially where it is of inflammatory origin, when they appear to announce the irritative state preceding the inflammation. (*Graefe.*)

Recent, or at least cases of paralysis of the muscles of the eye which are not old, in case they are not combined with strabismic deviations, are frequently relieved. This occurs spontaneously, or with the assistance of appropriate treatment. The rheumatic form of paralysis is the most favorable in this respect. In the majority of cases this disappears when the circumstances are only moderately favorable. The paralysis depending upon primary inflammation of the intracranial portions of the nerve-trunks, is not very unfrequently entirely relieved by a complete removal of the inflammation and of the organic changes caused by it.

Secondary neuritis and compression of the nerve-trunks, on the contrary, give very little hope of the complete removal of a paralysis caused by them, unless the disease may be subdued within a short time, which not unfrequently occurs, where syphilis is the original cause.

The prognosis is the worst, when the symptoms indicate an affection of the cerebral or spinal portion of the nerves, because this generally threatens an increase in the extent of the paralysis, if not worse results.

Still the paralysis of the muscles of the eye occurring in the course of tabes dorsalis is often entirely healed, without the main affection ever taking on a similarly favorable course.

If the paralysis have already existed for some time, or if it be ancient, hope of relief, and even of an improvement in the condition, is very slight or none at all. On the one hand, the long time which has elapsed shows that the disease has little inclination to recede of itself. On the other hand, the paralysis itself is a very fruitful source of secondary affections, which, in their nature, are incurable. To these belong atrophy of the nerve itself, with atrophy of the paralyzed muscle, fatty degeneration, relaxation; development of amblyopia from non-use of the eye, but especially the strabismic deviation of the eye toward the antagonist, or of the other eye toward the muscle, corresponding to the antagonist. This strabismic deviation is a very frequent result, and appears as a rule to affect the eye having the least visual power. (*Graefe.*) Its proximate cause is the extremely troublesome diplopia and vertigo, which the patient seeks to remove in every possible way.

Treatment.—We must first attempt to reach the original disease. Direct treatment of the paralysis is not justified until the cause is subdued, or at least deprived of its influence on the conduction in the course of the affected nerves. If, then, this treatment fails to restore the normal function to the paralyzed muscle, in appropriate cases the attempt may be made to increase the relative power of the muscle mechanically, that is, by lessening the resistances to its action.

1. The principles on which the main disease should be treated, are given in the text-books for special therapeutics.

Where rheumatism is the cause, in very recent cases, the use of dry, warm cloths, or bags filled with aromatic herbs, and flying blisters, with the internal use of the iodide of potassium, have been recommended. At the same time, the indications springing from the cause are to be carefully fulfilled. These cloths and bags should cover the eyebrow and temple, and be worn for some time. The blisters should be about as large as a copper coin, and be applied daily on some part of the forehead or temple.

The sprinkling of powdered strychnine or veratrine $\frac{1}{16}$, to $\frac{1}{2}$ grain, mixed with 1 to 2 grains of sugar or starch, or smearing ointments of these substances, on parts deprived of their epidermis by vesicants, is scarcely ever of any use. The so-called "sweating treatment," and the use of tartar emetic in small doses, are also superfluous.

2. After the treatment of the main disease, in cases which are probably rheumatic, the electric current should be employed. In some cases it does admirably, even in the undoubted existence of incurable intracranial disease which can not in other respects be improved. It is in this case an important rule to begin with the current from the fifth nerve. A direct excitation of the motory nerves of the eye is not only superfluous (*B. Schulz, Szokalski*), but also less effectual than one induced by reflection from the trifacial.

The current employed should be just strong enough to cause a slight sensation on the affected portion of integument, and always act only for a short time, say about half a minute. The strength of the current and the duration of the sitting will vary according to the irritability of the patient and of the trifacial nerve. If too great an irritation is made, or for too long a time, there will be no result. The improvement generally appears in a moment, and disappears just as quickly if the application be not properly made. It is therefore well to first use the current for a few seconds only, and to see if there be any improvement. If any progress is noticed, the employment of the electric stream should be continued. But when there is no further increase in mobility, or if after the first few seconds no improvement is seen, the operator should stop, and subsequently renew the treatment.

It is quite certain, that, in the cases where this method of using the electric current does not avail, greater irritation does no good, and that it even makes the condition worse. It not unfrequently occurs that no improvement is seen until after a number of sittings, and then it rapidly advances. We should, therefore, not lose our courage too soon. But if there is no benefit in two weeks, there is scarcely any thing to be hoped from it. The improvement is sometimes seen in an increase of the contractile power of the muscle, and of the parts in which there is binocular single vision. Again, the power of the muscle increases while the binocular visual field does not increase at all. (*Benedikt.*)

It is believed that experience has taught, that irritations of certain branches of the fifth pair are particularly adapted for paralysis of certain parts. Thus, in paralysis of the sixth pair (*abducens*), the result is said to be best, if the copper pole be placed on the forehead, while the region of the malar bone is irritated. In paralytic ptosis, the copper pole should be placed on the forehead, or applied to the mucous membrane of the cheek by means of a catheter-like electrode, and the closed lids stroked with the zinc pole. In paralysis of the superior rectus, rectus internus, and the two oblique, the zinc pole should be placed on the side of the nose, near the inner canthus. In paralysis of the inferior rectus, it should be moved here-and-there on the lower orbital border, while the copper pole is applied to the forehead. (*Benedikt.*) [It is claimed that, besides the universally conceded value of electricity in paralysis of the ocular muscles, partial electrization with the Faradaic current, the hands of the patient being placed on the negative pole, and the positive applied over the eye with the hand of the operator, the current passing through his body, has a positive beneficial effect in conjunctivitis and inflammations of the lachrymal passages. (*Beard and Rockwell.*)]

Proper exercise of the paralytic muscle at the same time is of importance. For this purpose it is well to bandage the healthy eye for some time, often during the day, and cause the patient to use the affected one only. At the same time the patient should be instructed to "fix" or look at objects which lie in the course of the affected muscle and outside of the meridian position. In order to increase the innervation of the muscle as much as possible, it is very important to choose near objects for corrections in motions of adduction, and far objects for abduction, and where it is necessary to lessen or increase the refraction by the proper convex or concave glasses.

For the same purpose, some advise the use of two lines, one of which is fixed by the healthy eye, while the other, which is movable, is approached so near the visual line of the affected eye, that the double images unite. Then the second line is gradually pushed away in the course of the paralytic muscle, and the latter thus excited to corrective contractions. (*Javal.*)

Others, having the head immovable, bring the object of fixation into a position in which binocular single vision is still possible, and then gradually remove it in the course of the paralyzed muscle so far, that the images begin to separate, and the effort for single vision causes a corrective innervation. (*Seokalski.*)

If we wish to correct slight paralytic deviations, the trial of prismatic plane glasses is recommended, since, if chosen and used properly, they allow binocular vision, and perhaps accustom the eyes to work together. If they are to accomplish what we desire of them, their angle of refraction should be, of course, that one which requires a slight tension of the paralytic muscle, and one which can be kept up, in order to unite the double images. If the power of the muscle gradually increases, weaker prisms should be chosen, until finally they can be dispensed with. (*Graefe.*)

3. If contraction of the antagonist has already commenced, and it is desired to restore the functional activity of the affected muscle, or if a slight degree of paresis in one or other rectus muscle withstands all attempts to remove it, in slight limitation of the mobility, we may attempt the stitching forward of the end of the muscle, but in greater limitations the bringing forward by the thread operation. In this way, with the aid of proper after-treatment, the attainment of correct adjustment of both optic axes, with binocular vision, has often been accomplished, or at least a less annoying position of the muscularly affected eye, with suppression of the double images secured. (*Graefe.*)

In general, the hopes of the patient should be very slightly raised, even as to any improvement in the appearance. The regulation of the amount of effect from an operation is very difficult, and even in theory it is not easy, unless we disregard important factors, such as the changed resistance in various states of the accommodation, &c. We should not overlook the fact that these mechanical influences of the action of the muscles vary exceedingly after, as well as before, the operation, and that any correction attained can only be sufficient for certain conditions.

4. To remove the ptosis of the upper lid,—which often remains after paralysis of the ocular motor-nerve, but often, also, occurs alone,—the following proceeding has been lately recommended. First, at the distance of a few millimeters from the edge of the upper lid, a transverse incision is made through the integument of the lid, down to the orbicular muscle, and the integument of the lid is separated from the latter toward the edge of the orbit, throughout its entire width. When the orbicularis has been exposed to a sufficient width, four to five lines of it, corresponding to the gaping wound, is to be excised with curved scissors, after it has been drawn out with toothed forceps. Then three stitches, at a suitable distance from each other, are so to be passed through the remaining muscular bundle and the edges of the wound, that the armed needle is entered near the free edge of the lid, under the ciliary portion of the muscle and out at the wound, then under the muscle at the upper part of the wound, and through the skin near the edge, and tied. Thus a subcutaneous shortening of the upper lid will be attained, the action of the orbicularis weakened, and the action of the levator seconded by the retraction of the lid. If this be not enough, if the upper lid be markedly elongated, it will be well to cut out

a crescentic piece of the integument having the first transverse incision as its base, and then apply the sutures. A pressure-bandage is then applied for from twelve to twenty-four hours to favor union by the first intention. (*Graefe.*)

Authorities.—*Graefe*, A. f. O. I. 1. S. 7, 9-23, 52-81, 433, I. 2. S. 312, et seq.; II. 1. S. 282, 284, II. 2. S. 299, III. 1. S. 182-189, 326-386, III. 2. S. 409, VII. 2. S. 24-35, IX. 2. S. 57-62, XII. 2. S. 198, 202, 265-277; klin. Monatbl. 1863. S. 3, 4, 1864. S. 2-22; Verhandlgn. der Heidelberg. ophth. Versammlung. 1859. S. 22.—*Türck*, Zeitschr. d. Wien. Aerzte. 1865. S. 522-532.—*Stellwag*, ibid. 1854. II. S. 491-504, Ophth. II. S. 1194-1200.—*Schuft*, [now Waldau] Zur Lehre v. d. Wirkung u. Lähmung der Augenmuskeln. Berlin.—*Alf. Graefe*, A. f. O. VII. 2. S. 109; kl. Analyse Motilitätsstörgn. etc. Berlin 1858. S. 17-37, 97-191.—*Nagel*, A. f. O. VIII. 2. S. 368-387.—*Donders*, Anom. d. Acc. u. Refr. Wien 1866. S. 502. [Accommodation and Refraction of the Eye. London, p. 599]. *Leidesdorf*, Wien. med. Jahrb. 1864. 4. Text, S. 112-118.—*Duchek*, ibid. Jahresb. S. 28-42.—*Benedikt*, Wochenbl. d. Wien. Aerzte. 1863. S. 351, A. f. O. X. 1. S. 97-103, et seq.—*B. Schulz*, Wien. med. Wochenschrift. 1862. S. 243.—*Javal*, kl. Monatbl. 1864, S. 404.—*Pagenstecher u. Sämisch*, kl. Beobachtungen. II. Wiesbaden 1862. S. 38.—*Hirschmann*, ibid. III. S. 89, 98.—*Hering*, verbal communication.—[*Beard and Rockwell*, Medical use of Electricity, New York, 1867, p. 50.] *Graefe*, Klin. Monatbl. 1867. S. 381; Symptomenlehre d. Augenmuskellähmungen. Berlin.—*Hering*, Das binoculäre Sehen. Leipzig. 1868. S. 115, 144.—*Coccius*, Der Mechan. d. Acc. Leipzig. 1868. S. 62.—*Manz*, A. f. O. XII. 1. S. 1.—*Knapp*, ibid. XIV. 1. S. 220, 234.—*Leber*, ibid. XIV. 2. S. 346.—*Magni*, Rivista clin. 1868.—*Power*, Virchow's Jahresber. 1868. S. 478.—*Steffan*, Klin. Monatbl. 1867. S. 73.

DESCRIPTION OF THE CHROMO-LITHOGRAPHS.

A. Congenital excavation of the Optic Nerve, and crescentic Posterior Scleral Staphyloma.

The entrance of the optic nerve is reddened, and surrounded by a ring of connective tissue. The excavated central portion of the papilla is seen as a bright white disc, on whose margin the central vessels slightly curve over, and press the principal trunks toward the center. The surface of the posterior scleral staphyloma is slightly reddened; its convex border has a fringe of pigment. The fundus is in other respects normal.

The region of the macula-lutea is deeply stained with pigment, and in this brownish-gray, somewhat undefined spot, there is an irregular, bright hole or space, the fovea centralis.

B. Apoplectic Neuro-Retinitis.

The margin of the optic nerve, especially toward the inner side, is very indistinct, and the adjacent parts of the retina finely striated in a radiate manner. The veins are very tortuous, and of an unevenly dark-red color. There are numerous blood extravasations, with their long diameter generally in a radiate course.

In the region of the macula-lutea a bluish-gray circular spot, surrounded by a narrow, sharply defined, bright zone.

C. Diffuse Neuro-Retinitis.

The densely-infiltrated retina gives the fundus of the eye a dirty, yellowish-red color. The optic-nerve entrance is only to be distinguished on the *porus opticus*, and by the radiated reddish striation of the parts about; its margin being completely obscured. The retinal vessels are very tortuous, in some spots darker colored, at others completely lost, or very much covered. There are numerous blood extravasations. Besides these there are several roundish, dirty-yellow spots, partly fringed with pigment, which are to be explained by exudations on the posterior surface of the retina, and the changes in the tapetum connected with them.

D. Exudative Neuro-Retinitis.

Recent and old morbid collections already advanced in atrophy. The entrance of the optic nerve slightly reddened, and the connective-tissue ring plainly visible. The inner portion of the optic papilla covered by an irregularly-bounded, recent inflammatory mass, which extends up to near the borders of the picture. On the outer margin of the picture are two similar roundish patches, which are recent. Above and below the papilla, is a large and irregular patch, and in the immediate vicinity of the outer border of the optic-nerve entrance, are several small masses, which are older, where the tendinous white sclerotica shines through the atrophied choroid and retina. There are only slight remains of the choroidal tapetum in

these masses, in the form of dirty-yellowish spots, but a few vascular twigs, appearing as if covered by gauze, remain. Here and there are scattered collections of dark pigment from proliferating tapetum cells. The remainder of the fundus appears of a dirty-brown color, from the pigment of the tunica vasculosa.

E. Circumscribed atrophy of the Retina and Choroid after exudative Neuro-Retinitis. Posterior Staphyloma.

In the vicinity of the macula-lutea there is seen an extensive, irregular, sharply-defined, tendinous white spot, on which the sclerotica seems to lie exposed. Its border is surrounded by neoplastic pigment, which is collected in lumps, as it were, and the surface is strewn with analogous large and small groups of pigment. The reddish color of the fundus indicates the partial existence of the choroidal vessels. The retinal vessels are unchanged, and extend over the surface, and thus indicate the existence of the remains of the anterior retinal layers. The fundus of the eye, between the inner boundary of the white spot and the optic-nerve entrance, as well as below the latter, is lighter-colored, owing to partial destruction of the tapetum, and a less amount of atrophy of the choroid. It has somewhat of an inlaid appearance, and, at intervals, is slightly clouded by the vasa vorticosæ of the tunica vasculosa. Below, and to the inner side, are seen collections of tapetum pigment, resembling bone-corpuscles. An exudation has here occurred on the outer retinal surface, and atrophy has begun. The outer half of the papilla, which is of a pale-red color, and which glimmers out of the depths as a bluish white disc, is surrounded by an irregular posterior scleral staphyloma, whose surface is delicately tesselated with the remains of pigment of the tunica vasculosa. Such a tesselated appearance is also seen on the upper periphery of the fundus.

F. Atrophy of the Retina and Choroid after exudative Neuro-Retinitis. Posterior Staphyloma.

The whole fundus has a striking tesselated appearance, and is strewn with irregular large and small collections of dark neoplastic tapetum pigment. The entrance of the optic nerve is very pale, with a marked tendency to a bluish-gray color. Connective tissue well developed. Retinal vessels normal.

G. Partial atrophy of the Retina and Choroid, after exudative Neuro Retinitis aveolaris (Retino-Choroiditis). Large Posterior Staphyloma.

The optic-nerve entrance is slightly reddened, and seen in an oblique projection, that is, as an oval disc, on account of the staphylomatous distention of the posterior scleral zone. The staphyloma is shaped like a shell, tendinous in appearance, of a striking bluish color, and graded almost like a miniature terrace. The border contains a great deal of pigment. Above and below, touching the staphyloma, there is a small roundish, pale-red mass of exudation. To the outer side of the scleral staphyloma, are two groups, connected to each other, of ancient inflammatory centers, roundish in shape, and already advanced in atrophy, through which the sclerotica glimmers, and which appear mostly surrounded by a ridge of dark pigment. On the inner half of the fundus are numerous scattered small atrophying spots, surrounded by pigment, as well as some recent ones of a yellow color. The whole fundus has a tesselated appearance.

H. Atrophy of the Retina and Choroid in consequence of exudative Neuro-Retinitis.

The optic disc is pale, and has somewhat of a veiled appearance. The connective-tissue ring is very indistinct. The whole fundus is covered with bright yellowish white spots, the smaller of which have a roundish shape, and the larger ones show that they have been formed by the running together of small round ones. In the spots toward the periphery, we distinctly recognize the vorticose vessels of the choroid, while they are entirely destroyed in the spots which are more central.

On every hand, a fine gray stippling is seen, which seems to depend on remains of the pigment of the tunica vasculosa. The tapetum on the surface of these spots is almost entirely destroyed, but on the edges it has collected in irregular heaps. In the spaces between the spots, the fundus appears quite normal in color, slightly stippled, and at intervals strewn with neoplastic collections of tapetum pigment.

I. Nephritic Neuro-Retinitis.

The optic-nerve entrance is very much veiled, especially in its outer half, and contains delicate radiate striations. Close to it is an extensive mass of retinal infiltration, which varies greatly in density, and thus has an appearance as if made up of a number of smaller masses. These are in part distributed along the principal vascular trunks, and are combined with a delicate gauze-like opacity, in which the slightly stippled red of the choroid shows through more or less markedly. The branches of the central artery passing over are veiled, at intervals dark-colored, again lighter, or even completely concealed. A number of large and small blood-extravasations appear near them, whose long axes radiate from the optic papilla. The outer border of the exudation runs into the characteristic stellate figure. This arises from a retinal exudation occurring in the vicinity of the macula-lutea, and ending in atrophy of the choroid and retina. The remainder of the fundus is normally colored and slightly stippled.

K. Nephritic Neuro-Retinitis.

Optic-nerve entrance very indistinct, discolored a yellowish-red. The central portions of the retinal vessels completely concealed from view. The retinal zone bordering on the papilla infiltrated with a dirty, grayish-white exudation, somewhat bulged forward, particularly at the inner margin of the papilla, where the vessels run in curves over the swelling. The infiltration extends outwards far beyond the macula-lutea. In the latter region a group of small, whitish-gray spots, and farther towards the equator numerous whitish-yellow masses of exudation, sometimes isolated, sometimes coalesced into irregular masses, which seem to be raised slightly above the surface of the retina. The retinal vessels greatly engorged, and in the neighborhood of the papilla indistinct. Numerous large and small hemorrhages, sometimes following the vessels, sometimes situated between the masses of exudation. The fundus markedly pale on account of the infiltration of the retina.

L. Atrophy of the Optic Nerve and Retina.

The optic papilla is of a bluish-white color, surrounded by a distinct ring of

connective tissue, and the whole fundus is of a dirty, grayish-white color, dull, and as if veiled over. There are scattered quite dark, irregularly bounded collections of neoplastic pigment, which have a gauzy covering, and some of which are very indistinct, and are plainly distinguished from the reddish choroid which shows through. The central vessels are very thin, and soon disappear, having but few branches.

M. Typical Pigment-degeneration of the Retina, pellucid Atrophy of the Optic Papilla.

The fundus is pale, delicately tesselated, and finely stippled. Around its periphery are the characteristic collections of pigment, resembling bone-corpuscles. Entrance of the optic nerve is of a bright white color, tendinous, surrounded by the ring of connective tissue. The central vessels very thin, with few branches.

N. Detachment of the Retina, congenital, flask-like (ampullar), Excavation of the Optic Nerve.

Lower and outer part of the retina bulged forward in the form of an opaque, dirty, grayish-yellow vesicle. The base of this vesicle is elevated very slightly, and hence the shadow is wanting, and the bending of the vessels passing over it is much less marked. The excavation has a somewhat irregular border, is of a bright white color, and has a delicate gray stippling from the interstices of the lamina cerebrosa. The vessels bend sharply over the border, and appear, in part, on the floor of the excavation, and are again lost sight of.

O. Detachment of the Retina.

The retina, with the exception of the upper quadrant, is detached from the choroid, and this detached portion forms a pouch which projects into the vitreous in the form of four points, which converge towards the papilla, encroach in part upon it, and between them narrow portions of the fundus may be seen. The detached portion of the retina is greatly infiltrated and thrown into irregular folds, and hence results the yellowish-white color with the bluish shadowing. The folding of the points is also manifested in the marked tortuousness and partial bending of the abnormally dark vessels running over them. These vessels begin apparently like a beak at the everted edges of the points, for the central portions of the trunks of the vessels are covered by the overhanging base of the sack.

P. Incipient Glaucoma.

The trunks of the central vessels are very much bent on the edge of the pale optic papilla, and have a beak-like curvature. The central portions of the larger branches are very pale as far as seen. The macula-lutea is very distinctly seen.

Q. Absolute Glaucoma.

The entrance of the optic nerve is clear white in color, tendinous, and has bluish-gray shadowed borders. The ring of connective tissue greatly developed, with irregular edges. All the retinal vessels are beak-shaped on the edge of the papilla. Only a few very tortuous and gauzy remains of its central portions are seen, which do not reach to the *porus opticus*, but which are probably to be referred

to distended collateral vessels. The principal veins are very full. The fundus is also tesselated on the periphery.

R. Posterior Staphyloma, partial Atrophy of the Choroid, Blood extravasation in the vicinity of the Macula-Lutea.

Optic-nerve entrance slightly reddened. The bright surface of the staphyloma delicately inlaid with the remains of the pigment of the tunica vasculosa. The upper and outer portion of the fundus is coarsely tesselated, as a result of advanced atrophy of the tapetum and of the choroid, and the sclerotica appears at intervals through the pigment. The vorticose vessels of the choroid are plainly visible on the remainder of the fundus.

S. Posterior Staphyloma, partial Atrophy of the Choroid and Retina.

The margin of staphyloma surrounding the optic-nerve entrance is sinuated bright, tendinous white in color, spotted with gray from the remains of pigment of the tunica vasculosa. The optic papilla is oval on account of oblique projection. Fundus is everywhere greatly tesselated, and at intervals covered by proliferating tapetum. It is of a lighter color in the vicinity of the macula-lutea from advanced atrophy.

TRANSLATORS' APPENDIX.

TRANSLATORS' APPENDIX.

LATERAL ILLUMINATION AND THE OPHTHALMOSCOPE.

Introduction.—Professor Stellwag has assumed, in his Treatise, that the reader has already made himself familiar with the employment of lateral or oblique illumination and the use of the ophthalmoscope. This assumption is quite proper for Germany, where the practice of ophthalmology is, to a very great extent, limited to specialists. It is, however, hardly right for a work prepared to meet the wants of general as well as special practitioners in the United States, to leave the matter in this way. Inasmuch as it is hoped that our translation will prove to be a complete text-book for diseases of the eye, we have deemed it necessary to compile the following addendum to the preceding pages, comprising a very brief description of the above-named diagnostic aids. We have also added a set of Professor Jaeger's Test-Types.

Fig. 117.

Lateral Illumination.

This should be conducted in a darkened room, although a little experience will enable the surgeon to use the method quite well, in one that is partially illuminated. A lighted lamp is placed on one side and at a level with the patient's eye; then, by means of a two-inch convex lens, a cone of light is directed upon the eye to be observed, as is seen in the wood-cut given on the preceding page.

By holding a second convex lens in front of the eye, a magnified image of the cornea, iris, anterior chamber, and crystalline lens is obtained. This method is especially valuable in cases of iritis and cataract. Indeed, it is almost indispensable in the doubtful cases of the former disease.

The Ophthalmoscope.

History of its Discovery.—The glittering of the eyes, observed especially in the eyes of the domestic animals, dogs and cats, was formerly ascribed to a spontaneous development of light under the influence of the nervous system. The first to controvert this opinion were *Prevost*, *Rudolphi*, and *Gruithuisen*, in 1810, the first of whom discovered that this glitter could not be seen in a dark room, and that the appearance was therefore only to be considered as a reflection of incident rays.

Gruithuisen traced the effect to the operation of the tapetum, combined with a great refraction by the crystalline lens. Rudolphi first noticed that the observer must look into the eye in a certain direction in order to see the glitter.

The exact conditions of the luminosity, without any explanation of it, were determined by *Behr* in 1839, who, in describing a case of complete absence of the iris in a girl, stated that in order to see the reflection the eye of the observer must look in a direction parallel to that of the rays incident upon the eye of the child. At a later period, *Cumming*, *Brücke*, and *Coccius* completely exhausted the subject of the apparently spontaneous luminosity of the human eye.

The first problem, as to why the eyes of men and animals sometimes shine with a reddish lustre, being solved, the second remained, that is, why the interior of the eye usually appears dark.

This second one was first fully answered by *Heinrich Helmholtz*, in the year 1851 (now Professor of Physics in the University of Heidelberg, but then in Königsberg) although *De la Hire* in 1709, and *Kussmaul* in 1845, had already taken some steps in the way of the discovery. Seventeen years have thus elapsed since this discovery of the ophthalmoscope. It is not too much to say, and it has been said very often, that it has completely revolutionized practice in certain departments of ophthalmology, or rather, created new fields of labor in them.

Helmholtz predicted of its use as follows: "I do not doubt, judging from what can be seen of the state of the healthy retina, that it will be possible to discern all its diseased conditions, as far as these, if seated in other transparent parts, such as the cornea, would admit of diagnosis by the sense of sight. I believe also, that the turbidity of the vitreous body will be determined with greatly increased facility and certainty. I do not consider it an overstrained expectation that all the morbid changes of the retina or vitreous body, found on the dead subject, will admit of recognition in the living eye." How much more than these expectations have been fulfilled, is readily answered.

PRINCIPLES ON WHICH THE USE OF THE OPHTHALMOSCOPE DEPENDS.

In looking into the eye of another person, the pupil usually appears black, and the interior of the organ does not return a single reflected ray to the observer. This is an apparent exception to the well-known law, that the passage of light from one medium to another is never complete, and that some of the rays that fall upon the new medium are in all cases reflected.

The incident light is to some extent reflected, part being absorbed by the pigment of the choroid, and by the sclerotica. The reflected portion, however, in consequence of the action of the cornea and crystalline lens, returns to exactly the point whence it came; the incident and emergent cones exactly coincide. The object and its retinal image are in the position of conjugate foci, and the rays proceeding from either focus are reunited in the other. In order to perceive the returning rays, it is evident that the eye of the observer must be placed between the source of light and the eye that is illuminated, which can not be done without cutting off the illumination from the latter.

It is also impossible to perceive light from the eye of another person, when the latter is exactly accommodated for the pupil of the examiner. Under these circumstances, a perfectly dark image will be formed on the retina of the eye that is observed. The dioptric media will return an image of this dark portion of the retina to the former, and the observer will, therefore, see nothing but the reflection of his own dark pupil.

Professor Helmholtz, after it had been shown, by *Von Erlach*, that the rays could be intercepted by means of a plate of glass, and reflected so as to illuminate the eye, found the reason that the retina could not be distinctly seen, and also means for making it visible. There were three things to be done:

1. The eye must be sufficiently illuminated.
2. The eye of the observer must be placed in the direction of the emergent rays.
3. These emergent rays must be changed from their convergence, and rendered divergent or parallel.

In a well-darkened chamber, the light of a lamp was allowed to fall on a polished plate of glass in such a manner, that the rays of light entered the eye to be examined.

The observer placed himself on the other side of the glass plate, and made the convergent rays divergent by a concave lens.

This instrument was the first ophthalmoscope.

The use of the ophthalmoscope, as thus described, is not now very general; silvered or metallic mirrors, having greater illuminating power, have been generally substituted for the plate of glass.

The first instrument of Helmholtz, however, solved the problems which rendered possible all the suggestions of the subsequent ophthalmoscopes, such as those of Reute, Coccius, Jaeger, Stellwag, etc., which are minutely described in Zander's work on the ophthalmoscope.

There are two methods of examining the fundus of the eye with the ophthalmoscope, which are called the *direct* and the *indirect*. The latter is more commonly employed than the former, and is much the easier of application; but the *direct* method is of far greater value in making a correct diagnosis.

Indirect Method.

The ordinary instrument in common use, or what is known as Liebreich's ophthalmoscope, answers very well for the indirect method of investigation. It consists of a round, metallic, concave mirror, of about one-and-a-half inches in diameter, and six inches focal length. It has a central aperture of about one-tenth of an inch in diameter, and is mounted on a light handle of about six inches in length. Behind the mirror is a hinged clip, by which lenses may be held. The lenses held in this clip are concave, varying in focus from six inches to twelve inches, with convex ones of ten and twelve inch focus.

In using this instrument, the patient and surgeon sit face to face in a darkened

Fig. 118.

room, and a lamp or gas-burner is placed at the side of, and a little behind, the patient's head, the flame being on a level with his ear. The surgeon takes the mirror and reflects the light upon the patient's eye, just as the rays of the sun may be reflected on any given surface by means of a reflector.

The object-glass is then to be employed as in the figure. This is nothing more than a bi-convex lens of from two and one-half to three and one-half inches' focal length, which the surgeon holds in his left hand about an inch or so from the eye to be examined, and the mirror, as before, immediately before his own, and about a foot from the eye to be examined. The rays of light reflected from the fundus of the eye strike the object-glass, and form an inverted real image.

If the eye of the observer be normal or hypermetropic, the inverted image is made more distinct, by the use of a convex eye-piece in the hinged clip. In thus examining with one eye, the proper estimation of the different planes in which the parts lie either normally, or in a morbid condition, is somewhat difficult, at first. A little experience, however, enables the observer to tell from the bending of the vessels, and the change in focus necessary for the clear study of each part, whether the

optic-nerve entrance be excavated, or the retina pushed forward by effusion. It is well to remark, that it is better for the examiner to accustom himself to keep both eyes open in the use of the monocular ophthalmoscope, as being less wearisome, and perhaps better enabling the surgeon to properly adjust his accommodative powers.

The accompanying wood-cut, which originally appeared in Zander's work on the ophthalmoscope, will give an idea of the relation and appearance of the veins and arteries of the optic papilla. For a true representation of the coloring of the fundus oculi, as illuminated by the ophthalmoscope, the reader is referred to the chromo-lithographic plates accompanying this work. In order that the observer may see the optic-nerve entrance, the patient should be directed to turn his eye inward. He may look at the right ear of the surgeon, if it is the right eye that is being examined, and *vice versâ*.

Fig. 119.

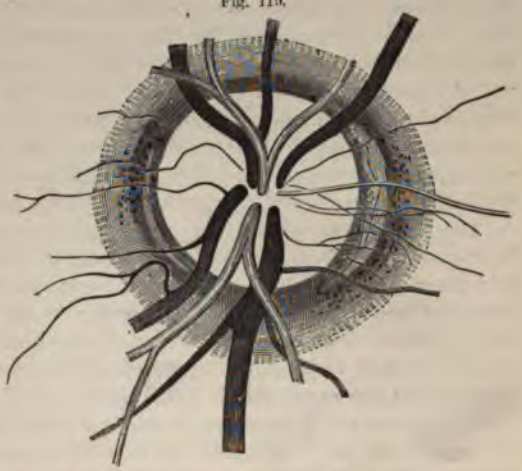

Direct Method.

The best explanation that can be offered of the direct method of examination is that given by Dr. Loring in an article published in the *American Journal of the Medical Sciences* for April, 1870, from which the following description is taken:—The most of the description is a verbatim quotation from Dr. Loring's article, although many omissions have been made.

The one great advantage which this method possesses over all others is, that by it we are enabled to determine the optical condition of the eye, independent of its visual power and the statements of the person examined. Any ophthalmoscope may be used for making the examination, which is provided with an apparatus at the back for holding the necessary glasses. The mirror may be of plane glass, or a plane silvered one, or finally a concave silvered one, the latter being most useful for determining errors of refraction. Whenever there is any dread of light on the part of the patient, we must always employ a weak illumination.

The light should be placed on the side of the patient and on a plane somewhat posterior to him, and the intensity of the illumination may always be modified by having the chimney colored blue of various tints. The observer should sit well to the side of the patient, and on the side of the eye to be examined. The patient should be directed to look slightly to the opposite side of the eye to be examined, so as to bring the optic-nerve entrance opposite the pupil. When the region of the macula is to be examined, the patient should be directed to look straight forward, in the horizontal plane. Perfect relaxation of the accommodation in the observed

eye may be obtained by atropia, and for the beginner it will be better always to employ it. For the practised observer, sufficient relaxation can usually be obtained in emmetropia by causing the patient to look into the distance, and as much as possible into vacancy. When the patient is a myope, he need only look at some object which is at a greater distance than his far-point, in order to relax his accommodation. When the patient is hypermetropic, it is on the whole better to employ atropine. The more completely the observer can relax his accommodation, the more correct will be his diagnosis. The ability to relax the accommodation varies with different people, and is of course increased by practice. As a rule, the weakest concave glass through which the fundus of an emmetropic eye can be distinctly seen should be taken as the criterion on which the emmetropic observer, who cannot entirely relax his accommodation, should base his estimates of refraction. If the observer is ametropic, he must first correct his ametropia by the suitable glass.

The optic papilla, which is the most conspicuous object in the fundus, should never be chosen as an object on which to found our observations, as it frequently projects very much above the plane of the retina, as do also the main trunks of the central artery and vein. There are, however, some very fine vessels which always leave the edge of the nerve, and run out horizontally on either side, and these are very good objects by which to judge of the refraction of an eye. But the best of all objects for the practised observer is the choroidal epithelium near the macula.

If the observer is emmetropic and can entirely relax his accommodation, he knows that his eye is adjusted for parallel rays; and if he sees distinctly the fundus of an eye, while his accommodation is relaxed, he knows that the patient's eye is emmetropic, as this is the only kind of eye from which rays emerge parallel. If in a given case the observer does not distinctly see the fundus of the eye examined, when his own examination is relaxed, but does see clearly by using his accommodation, he knows that the eye in question is hypermetropic; for his own eye is now adjusted for divergent rays, and there is no eye but a hypermetropic one from which divergent rays can come.

Finally, if the observer can obtain no clear view of the fundus either by relaxing or calling forth his accommodation, he knows that the rays coming from the observed eye are neither parallel nor divergent; hence they must be convergent, and the eye is therefore myopic. Thus we see that the advantages offered by the direct method of examination are two-fold:

(1.) The ability to tell the optical condition of the eye examined independent of the statements of the patient, or amount of vision of the eye.

(2.) The ability to measure the amount of elevation or depression of given parts of the fundus. We are thus enabled to measure numerically the amount of excavation of the optic nerve or its projection above the level of the retina; the projection of the choroid or retina from underlying effusion; the height of tumors and their rate of increase; the amount of swelling in the retina; the situation of membranes in the vitreous, etc.

In attempting to determine the existence of astigmatism by the ophthalmoscope, we must look at the vessels in the fundus. If we consider the optic disk as the centre of a circle, and all the vessels, large and small, radiating from it as so many straight lines, we have a representation of Dr. Green's test for astigmatism, in which the principal branches of the central artery and vein represent the vertical lines, and the small vessels leaving the edge of the disk, the horizontal and oblique. The existence of astigmatism is at once recognized, and the direction of one of the princi-

pal meridians is given by the fact that those vessels are most distinctly seen which are situated in the meridian of greatest ametropia, and we know that the direction of the other principal meridian must be at right angles to it. We then determine the refraction of each meridian separately, and the difference between the two will be the amount of astigmatism.

One of the principal causes which have retarded the more general use of the upright image in ophthalmoscopy is the necessity for a constant change of the glass behind the mirror, and consequent loss of time and inconvenience. To avoid this, and to expedite the determination of errors of refraction, Dr. Loring suggested the following modification of the ophthalmoscope, the principal feature of which is the substitution of detachable cylinders for the fixed Rekoss disk, now common to a number of ophthalmoscopes. In the present case but three cylinders are employed, though these might be multiplied indefinitely were there any occasion for so doing. Each cylinder is pierced for eight glasses, forming in the aggregate the following series:—

$$\text{Convex.....}0,\ \frac{1}{48'}\ \frac{1}{24'}\ \frac{1}{16'}\ \frac{1}{12'}\ \frac{1}{10'}\ \frac{1}{8'}\ \frac{1}{7'}\ \frac{1}{6'}\ \frac{1}{5'}\ \frac{1}{4'}\ \frac{1}{3'}$$

$$\text{Concave.....}\ \frac{1}{48'}\ \frac{1}{24'}\ \frac{1}{16'}\ \frac{1}{12'}\ \frac{1}{10'}\ \frac{1}{8'}\ \frac{1}{7'}\ \frac{1}{6'}\ \frac{1}{5'}\ \frac{1}{4'}\ \frac{1}{3'}\ \frac{1}{2'}$$

Thus we have a series of glasses extending, with but comparatively slight differences in focal value, from convex $\frac{1}{48}$ to $\frac{1}{3}$ and from concave $\frac{1}{48}$ to $\frac{1}{2}$.

The manner in which the glasses are divided among the cylinders will be readily understood from the accompanying figures. The first cylinder is made up entirely of convex glasses, by means of which all ordinary degrees of hypermetropia can with sufficient exactness be determined. One hole (0) is left vacant to represent emmetropia, without the necessity of removing the cylinder, and for examination by the inverted image without an eye-piece; should, however, the latter be desired, the observer has a large selection at his command. The second cylinder contains the concaves of moderate focal power, and the third is composed of the high numbers, both positive and negative. These strong numbers are designed for the determination of the highest degrees of errors of refraction and for the measurement of the inequalities of the fundus, such as excavations and elevations of the optic nerve, projections of tumors, retinal detachments, membranes in the vitreous, etc. With the stronger convex, such as $\frac{1}{3}$, opacities of the cornea and lens can be viewed under considerable enlargement.

The cylinders fit into a cell at the back of the instrument and are held firmly in their place by means of the two small springs shown in the engraving, which projecting into a groove in the side of the cylinders, prevent these from falling out, yet do not interfere with their rotation. In turning, the centre of the glass comes opposite the centre of the hole in the mirror.

Great care was taken to have the mirror, which is concave, seven inches focal distance, ground exceedingly thin—as thin almost as a metal mirror—while the surrounding brass work is so bevelled away that as little impediment as possible is offered to the passage of the rays, thus rendering the image perfectly distinct, and unusually brilliant.

The mirror being contained in a separate case of its own is made detachable from the rest of the instrument, which can then be used as an optometer, the pa-

Fig. 120.



EXPLANATION OF FIGURES.—Fig. 1. Back of instrument with cylinder in position. Fig. 2. Front view of instrument. Figs. 3 and 4. Remaining cylinders detached. Fig. 5. Astigmatic optometer and mirror.

tient himself revolving the cylinder till the suitable glass is obtained. As the perforation through which the patient looks when the mirror is removed is equal to the diameter of the glass (three lines), and is much larger than the normal pupil, the peripheral rays are not cut off, which is usually the source of error when smaller diaphragms are used.

The handle of the instrument has purposely been made unusually long, so that the observer's hand shall not interfere with an easy and close proximity to the observed eye, which is a great advantage in examination by the upright image.

The instrument, the three cylinders, and a convex two and one-half inches less for examination by the inverted image, are all contained in a small pocket-case, measuring four and three-quarter inches by two and one-half square by three-quarters thick.

Besides the common concave mirror which comes with the instrument, Dr. Loring had two others constructed. The first is intended for examination by the "weak illumination," and is precisely similar to the common concave 7″ mirror silvered on the back, only it is made from London smoke instead of colorless glass.

As it is the property of London smoke glass to simply reduce the quantity of the transmitted light without sensibly altering its color, it occurred to me that any degree of illumination might be obtained by using various shades of the glass, without sensibly changing the appearance of the fundus. Many experiments were made with these mirrors, and two were finally fixed upon as the most serviceable. One is even weaker than the three plates of plane glass—so weak indeed that the patient is hardly aware that any light is thrown into his eye. The other is made from a much lighter shade, and gives a reflection intermediate in brilliancy between the ordinary weak and strong reflectors. By its means a much more brilliant picture is obtained than with the plane glass mirror, while at the same time with much less glare to the patient than with the ordinary silvered one. The advantages of these mirrors are that the quantity of light can be varied and that they can be so easily kept clean.

The common weak mirror, consisting of three plates of plane glass, could however be easily fitted to the instrument should it be desired.

The remaining mirror mentioned above was originally designed for a stenopæic slit to be used with the instrument when employed as an optometer for the determination of astigmatism. It consisted of a thin plate with a slit in it, whose length was equal to the diameter of the perforations in the cylinder. This was mounted like the mirror, and made to fit in the mirror cell in which it revolved, so as to allow the slit to correspond with any given meridian of the cornea. The meridian once determined, the patient turned the cylinder till the suitable glass was obtained. This plate was subsequently made with a polished surface in front, and then was made to serve also as a mirror for determining, by means of the ophthalmoscope, the amount of astigmatism in the principal meridians of the eye.

Those who are desirous of obtaining this instrument can procure it of the manufacturer, H. W. Hunter, Optician, 1132 Broadway, N. Y. City.

JAEGER'S TEST-TYPES.

No. 1.

We again turn from the siege of Boston, to the invasion of Canada, which at that time shared the anxious thoughts of Washington. His last accounts of the movements of Arnold, left him at Point Levi, opposite to Quebec. Something brilliant from that daring officer was anticipated. It was his intention to cross the river immediately. Had he done so, he might have carried the town by a *coup de main*; for terror as well as disaffection prevailed among the inhabitants. At Point Levi, however, he was brought to a stand; not a boat was to be found there. Letters which he had despatched some days previously, by two Indians, to Generals Schuyler and Montgomery, had been carried by his faithless messengers, to Caramhe, the lieutenant-governor, who, thus apprised of the impending danger, had caused all the boats of Point Levi to be either removed or destroyed. Arnold was not a man to be disheartened by difficulties. With great exertions he procured about forty birch canoes from the Canadians and Indians, with forty of the latter to navigate them; but stormy winds arose, and for some days the river was too boisterous for such frail craft. In the mean time the garrison at Quebec was gaining strength. Recruits arrived from Nova Scotia. The veteran Maclean, too, who had been driven from the mouth of the Sorel by the detachment under Brown and Livingston, arrived down the river with his corps of Royal Highland Emigrants, and threw himself into the place. The Lizard frigate, the Hornet sloop-of-war, and two armed schooners were stationed in the river, and guard-boats patrolled at night. The prospect of a successful attack upon the place was growing desperate. On the 12th of November, Arnold received intelligence that Montgomery had captured St. Johns. He was instantly roused to emulation. His men, too, were inspirited by the news. The wind had abated; he determined to cross the river that very night. At a late hour in the

No. 2.

We again turn from the siege of Boston, to the invasion of Canada, which at that time shared the anxious thoughts of Washington. His last accounts of the movements of Arnold, left him at Point Levi, opposite to Quebec. Something brilliant from that daring officer was anticipated. It was his intention to cross the river immediately. Had he done so, he might have carried the town by a *coup de main*; for terror as well as disaffection prevailed among the inhabitants. At Point Levi, however, he was brought to a stand; not a boat was to be found there. Letters which he had despatched some days previously, by two Indians, to Generals Schuyler and Montgomery, had been carried by his faithless messengers, to Caramhe, the lieutenant-governor, who, thus apprised of the impending danger, had caused all the boats of Point Levi to be either removed or destroyed. Arnold was not a man to be disheartened by difficulties. With great exertions he procured about forty birch canoes from the Canadians and Indians, with forty of the latter to navigate them; but stormy winds arose, and for some days the river was too boisterous for such frail craft. In the mean time the garrison at Quebec was gaining strength. Recruits arrived from Nova Scotia. The veteran Maclean, too, who had been driven from the mouth of the Sorel by the detachment under Brown and Livingston, arrived down the river with his corps of Royal Highland Emigrants, and threw himself into the place. The Lizard frigate, the Hornet sloop-

No. 3.

of-war, and two armed schooners were stationed in the river, and guard-boats patrolled at night. The prospect of a successful attack upon the place was growing desperate. On the 12th of November, Arnold received intelligence that Montgomery had captured St. Johns. He was instantly roused to emulation. His men, too, were inspirited by the news. The wind had abated; he determined to cross the river that very night. At a late hour in the evening he embarked with the first division, principally riflemen. The river was wide; the current rapid; the birch canoes, easy to be upset, required skillful management. By four o'clock in the morning, a large part of his force had crossed without being perceived, and landed about a mile and a half above Cape Diamond, at Wolf's Cove, so called from being the landing-place of that gallant commander. Just then a guard-boat, belonging to the Lizard, came slowly alongshore and discovered them. They hailed it, and ordered it to land. Not complying, it was fired into, and three men were killed. The boat instantly pulled for the frigate, giving vociferous alarm. Without waiting the arrival of the residue of his men, for whom the canoes had been despatched, Arnold led those who had landed to the foot of the cragged defile, once scaled by the intrepid Wolfe, and scrambled up it in all haste. By daylight he had planted his daring flag on the far-famed Heights of Abraham. Here the main

No. 4.

difficulty stared him in the face. A strong line of walls and bastions traversed the promontory from one of its precipitous sides to the other; inclosing the upper and lower towns. On the right, the great bastion of Cape Diamond crowned the rocky hight of that name. On the left was the bastion of La Potasse, close by the gate of St. Johns, opening upon the barracks; the gate where Wolfe's antagonist, the gallant Montcalm, received his death-wound. A council of war was now held. Arnold, who had some knowledge of the place, was for dashing forward at once and storming the gate of St. Johns. Had they done so, they might have been successful. The gate was open and unguarded. Through some blunder and delay, a message from the commander of the Lizard to the lieutenant-governor had not yet been delivered, and no alarm had reached the fortress. The formidable aspect of the place, however

No. 5.

awed Arnold's associates in council. They considered that their whole force was but between seven and eight hundred men; that nearly one third of their fire-arms had been rendered useless, and much of their ammunition damaged in their march through the wilderness; they had no artillery, and the fortress looked too strong to be carried by a *coup de main*. Cautious counsel is often fatal to a daring enterprise. While the council of war deliberated, the favorable moment passed away. The lieutenant-governor received the tardy message. He hastily assembled the merchants, officers of militia, and captains of merchant vessels. All promised to stand by him; he had strong distrust, however, of the French part of the population and the Canadian militia;

No. 6.

his main reliance was on Colonel Maclean and his Royal Highland Emigrants. The din of arms now resounded through the streets. The cry was up—"The enemy are on the Heights of Abraham! The gate of St. Johns is open!" There was an attempt to shut it. The keys were not to be found. It was hastily secured by ropes and handspikes, and the walls looking upon the heights were soon manned by the military, and thronged by the populace. Arnold paraded his men within a hundred yards of the walls, and caused them to give three hearty cheers; hoping to excite a revolt in the place, or to provoke the scanty garrison to a sally. There were a few scattered cheerings in return; but the taunting bravado failed to produce a

No. 7.

sortie; the governor dared not venture beyond the walls with part of his garrison, having too little confidence in the loyalty of those who would remain behind. There was some firing on the part of the Americans, but merely as an additional taunt; they were too far off for their musketry to have effect. A large cannon on the ramparts was brought to bear on them, and matches were procured from the Lizard, with which to fire it off. A few shots obliged the Americans to retire and encamp. In the evening Arnold sent a flag, demanding in the name of the United

No. 8.

Colonies the surrender of the place. Some of the disaffected and faint-hearted were inclined to open the gates, but were held in check by the mastiff loyalty of Maclean. The veteran guarded the gate with his Highlanders; forbade all communication with the besiegers, and fired upon their flag as an ensign of rebellion. Several days elapsed. Arnold's flags of truce were repeatedly insulted, but he saw the futility of resenting it, and attacking the place with his present means. The inhabitants gradually recovered

No. 9.

from their alarm, and armed themselves to defend their property. The sailors and marines proved a valuable addition to the garrison, which now really meditated a sortie. Arnold received information of all this from friends within the walls; he heard about the same time of the capture of Montreal, and that General Carleton, having escaped from that place, was on his way down to Quebec. He thought at present, therefore, to draw off on the 19th to *Point aux Trembles* (Aspen-tree Point), twenty miles above Quebec, there to await the

No. 10.

arrival of General Montgomery with troops and artillery. As his little army wended its way along the high bank of the river toward its destined encampment, a vessel passed below, which had just touched at Point aux Trembles. On board of it was General Carleton, hurrying on to Quebec. It was not long before the distant booming of artillery told of his arrival at his post, where he resumed a stern command. He was unpopular among the inhabitants; even the British merchants

No. 11.

and other men of business, were offended by the coldness of his manners, and his confining his intimacy to the military and the Canadian noblesse. He was aware of his unpopularity, and looked round him with distrust; his first measure was to turn out of the place all suspected persons, and all who refused to aid in its defence. This caused a great "trooping out of town," but what was lost in numbers was gained in strength.

No. 12.

With the loyally disposed who remained, he busied himself in improving the defences. Of the constant anxiety, yet enduring hope, with which Washington watched this hazardous enterprise, we have evidence in his various letters. To Arnold, when at Point

No. 13.

Levi, baffled in the expectation of finding the means of making a dash upon Quebec, he writes: "It is not in the power of any man to command success, but you have done more, you have deserved it; and

No. 14.

before this time (Dec. 5th), I hope you have met with the laurels which are due to your toils, in the possession of Quebec. I have

No. 15.

no doubt but a junction of your detachment with the army under General Montgomery, has been effected before this. If so, you will put yourself under his com-

No. 16.

mand, and will, I am persuaded, give him all the assistance in your power to finish the glorious work you have begun." In the month

No. 17.

of December a vessel had been captured, bearing supplies from Lord

No. 18.

Dunmore, to the army at Boston. A letter on board, from his lordship

No. 19.

to Gen.
Howe, in-
vited him
to transfer
the war to
the southern

No. 20.

colo-
nies, or
at all
events,
to send

INDEX OF AUTHORS.

Abernethy, 561.
Adams, 120, 483.
Adamük, 5, 6, 12, 13, 311, 317, 687, 688, 784.
Alison, 10.
Althof, H., 54, 117, 139, 254, 283, 286, 287, 402, 456, 457, 481, 486, 539, 540, 545, 558, 601, 797.
Arit, F., 70, 77, 78, 110, 218, 224, 230, 274, 294, 317, 318, 364, 365, 409, 420, 429, 460, 474, 485, 489, 499, 503, 514, 540, 580, 581, 600, 610, 624, 627, 636, 637, 643, 662, 687, 702, 752, 755, 795, 810, 811.
Agnew, C. R., 645, 826.
Acrel, 542.
Achilli, 541.
Ammon, 118, 152, 354, 561, 592.
Arit, jr., 9, 687.
Arnold, 133.
Aran, 523.
Arcoleo, 226, 285, 557.
Aubert, 19, 681, 761.
Autenreith, 113.
Athill, Lombe, 32.
Airy, 678, 765.
Alexander, 765, 767.
Andreä, 217, 563.
Appia, 563.

Bärensprung, 11, 61.
Babuchin, 154, 274.
Bader, C., 413, 540, 547.
Barkan, 154.
Bainbridge, 228.
Bartisch, 468.
Baillie, 543.
Basedow, 77, 520.
Bauer, 223.
Balfour, 552.
Barns, 561.
Berlin, R., 137, 138, 141, 164, 198, 263, 284, 322, 331, 494, 512, 572, 688.
Becker, O., 3, 13, 134, 138, 139, 157, 168, 178, 229, 254, 259, 274, 312, 491, 517, 541, 561, 590, 591, 601, 602, 687.
Bell, 37, 562.
Beer, 109, 217, 218, 219, 220, 226, 262, 492, 508, 540, 600, 703, 707, 767.
Benjamin, 37.
Bernard, Cl., 5, 8, 9, 10, 12.
Bernatzik, 31.
Benedikt, 8, 11, 177, 209, 216, 218, 234, 536, 743, 749, 752, 756, 768, 795, 797, 849, 852.
Bernstein, 33, 34.
Bezold, 7, 35, 751.
Berthold, 3–7, 213, 553, 554, 555, 558.
Beronius, 299.
Bertrandi, 96.
Beard and Rockwell, 852.
Bergmann, 637, 681.
Beck, 217.
Betke, 220.
Beger, 612.
Biffi, 34.
Billroth, Theodor, 360, 366, 550, 551, 561.
Bitot, 426.
Biermer, 229, 523.
Blasius, 494, 538.
Blessig, 176, 177, 178, 220, 221, 226, 229, 294, 426.
Bloebaum, 7, 35.
Blumberg, 358, 363.
Bonafont, 474.
Bowman, William, 37, 50, 51, 52, 54, 61, 62, 102, 121, 138, 133, 193, 201, 269, 274, 322, 474, 481, 504, 505, 506, 508, 510, 560, 563, 631, 645, 665.
Bochdalek, 488, 489.
Bonnet, 514, 580.
Böck, 77.
Bouchut, 2, 177, 190.
Boissonneau, 327.
Boyer, 229.
Böhm, 763, 766, 769.
Boettcher, 561.
Bourguet, 562.
Bouillaud, 219.
Bretonneau, 748.
Brücke, 274, 276, 680.
Brainard, 562.
Braun, 32, 155.
Bright, 229.
Brewster, 765.
Brassant, 543.
Brodowski, 547.
Burow, 693, 700, 734.
Buttles, 37.
Budge, 8, 9, 10, 12, 13, 34, 228, 688, 751, 784.
Büttner, 10, 11.
Buys, 411.
Busch, 286, 475, 542.
Burns, 32, 552.
Buzer, 225.
Businelli, 557.
Burchardt, 682.

Coccius, 13, 35, 55, 95, 139, 150, 157, 158, 161, 185, 207, 253, 286, 313, 317, 318, 319, 564, 687, 749, 777.
Canton, 564.
Carius, 611.
Canstatt, 77.
Carter, 120.
Camper, 347.
Carron du Villards, 527.
Cappelletti, 116.

Caratheodori, 538.
Charcot, 11.
Chelius, 61, 484, 494, 540, 542, 545, 552, 557.
Chisholm, 77, 209.
Christison, 37.
Chassaignac, 217.
Classen, 49, 52, 88, 89, 185, 197, 558.
Clifford, 177.
Collin, 229.
Cohn, H., 16, 254, 354, 426, 516, 703, 706, 722, 723, 735, 811.
Cohnheim, 49, 50, 51, 285, 286.
Courserant, 120, 648.
Coindet, 229, 774.
Colberg, 244.
Cotard, 11, 61, 552.
Cooper, 366.
Combette, 229.
Cowell, 553.
Colsmann, 218.
Collard, 562.
Cramer, 13, 34, 686, 694, 705.
Cunnier, 543.
Cusco, 310.
Czermak, 683, 687.
Critchett, 130, 131, 268, 269, 297, 301, 302, 318, 508, 509, 631, 635, 665, 670, 824.
Cruveilhier, 226.
Crusell, 109.
Cruise, 523.
Cunier, 105, 218, 327.
Cyr, 46, 411.
Czerny, 104, 123, 136, 281, 296, 550, 561.

Davis, 615.
Danielson, 61, 77.
Davidson, 610.
Danielssen, 11.
Dale, 229.
Daviel, 89.
Danjoy, 219.
Dantone, 641, 639.
Dalrymple, 562.
Descemet, 50, 51, 55, 68, 78, 80, 224.
Demour, 50.
Decês, 524.
Derby, 35, 311.
Deiters, 9.
Demme, 229, 522, 751.
Debrou, 432, 480.
Deval, 218, 524.
Desmarres, 140, 219, 432, 433, 464, 492, 493, 503, 643, 648.
Demarquay, 541, 553, 562.
Delgado, 767.
Deuters, 776.
Du Bois-Raymond, 750.
Desponts, 774.
Desormeaux, 562.
Delpech, 538.
Delestre, 767.
Desbois, 219.
Dieffenbach, 483, 485.
Dixon, 553.
Dobrowolsky, 37, 302, 354, 524, 678, 694, 705, 735, 742, 754.
Donders, 3, 4, 5, 7, 9, 12, 34, 37, 54, 55, 111, 120, 136, 149, 150, 185, 205, 253, 278, 297, 319, 335, 352, 430, 608, 616, 631, 677, 678, 680, 683, 687, 689, 693, 694, 695, 697, 698, 702, 704, 705, 707, 712, 719, 720, 721, 722, 728, 730, 731, 732, 733, 734, 735, 736, 740, 741, 742, 743, 747, 748, 749, 751, 757, 758, 761, 777, 791, 810, 812.
Doncan, 758.
Doyer, 707, 777.
Durand, 552.
Dyer, E., 744.
Donnell, M., 523.
Doneau, 133.
Don, 288, 763.
Dönitz, 157.
Duchek, 226, 227, 228, 230, 751, 756, 850.
Dusch, 524, 525.
Dupuytren, 509.
Dufour, 228, 696.
Duval, 517.

Eimer, 358.
Ebert, 220.
Eiselt, 381.
Ellinger, 443.
Emmert, 516, 520.
Engelmann, 49, 50.
D'Entrecolle, 774.
Erismann, 218, 219, 220, 234.
Esmarck, 11, 61.
Estlander, 294, 295.
Estlin, 563.
Eulenberg, 8, 9, 12, 250.
Eisner, 774.
Eger, 624.

Fikentscher, 218.
Follin, 19, 41, 219
Foucher, 563.
Foltz, 510.
Freck, 678.
Freeman, 562.
Froebelius, 610.
Fardel, 552.
Falko, 757.
Fano, 22, 538, 565.
Fränkel, 286.
Frontmüller, 224, 769, 770.
Faye, 624.
Fieber, 752.
Fernari, 98.
Fari, 125.
Ferrul, O., 517, 580.
Finkbeiner, 134, 135.
Fischer, K., 25, 77, 226; H., 228, 262, 518, 527, 541.
Fiedler, 229.
Flarer, 467.
Flourens, 13, 228, 784.
Fried, 99, 467, 509.
Fournier, 524.
Ford, 347.
Förster, 13, 138, 166, 184, 185, 209, 212, 270, 308, 493, 592, 610, 681, 698, 765, 766, 771, 772, 774.
Fricke, 484, 485.
Fraser, 34, 37.
Fries, 358.
Fraas, 32.
Frank, 77, 287, 381, 543.
Friedberg, 519.
Friedrich, 523.

Gairdner, 756.
Gendrin, 562.
Gerold, H., 761, 763, 769.
Gescheidt, 614.
Geissler, 10, 11, 526, 562, 767.
Gemuseus, Scheiss, 123, 545, 546.
Geisler, 458.
Giraud-Teulon, 682, 693.
Gioppi, 642.
Grenzstrang, 756.
Grünhagen, 311.
Guepin, 763.
Greeve, 548.
Guemar, 772, 773.
Graves, 77.
Graefe, A. von, 2, 4, 5, 10, 11, 13, 15, 26, 31, 32, 33, 35, 37, 38, 41, 42, 71, 72, 77, 88, 89, 90, 98, 99, 112, 118, 119, 120, 136, 138, 142, 150, 168, 169, 174, 177, 178, 186, 190, 194, 196, 197, 198, 200, 201, 202, 203, 206, 209, 213, 216, 217, 218, 220, 222, 224, 225, 226, 229, 230, 232, 237, 245, 253, 262, 263, 268, 271, 283, 285, 286, 287, 292, 293, 294, 296, 297, 300, 302, 303, 305, 308, 309, 311, 312, 313, 314, 316, 317, 319, 322, 323, 324, 326, 327, 328, 329, 331, 333, 247, 355, 356, 384, 385, 386, 395, 396, 397, 398, 413, 414, 426, 433, 465, 473, 475, 481, 483, 488, 492, 493, 494, 510, 511, 521, 522, 525, 526, 528, 531, 538, 539, 540, 541, 542, 543, 548, 552, 553, 554, 556, 558, 560, 561, 563, 564, 565, 568, 569, 571, 572, 574, 576, 577, 578, 580, 601, 602, 609, 610, 614, 616, 621, 622, 624, 625, 626, 630, 631, 365, 636, 637, 638, 639, 640, 641, 643, 644, 647, 648, 649, 652, 665, 668, 683, 686, 688, 696, 698, 700, 716, 728, 741, 748, 751, 752, 754, 766, 767, 768, 772, 795, 796, 797, 800, 802, 813, 821, 824, 827, 849, 850, 851, 853, 854.
Graefe, Alf., 198, 269, 381, 492, 507, 509, 553, 556, 564, 578, 802, 803, 805, 806.
Green, 508.
Grünhagen, 2, 3, 5, 6, 12, 13, 33, 35, 38.
Griesinger, 8.
Gouvea, 54, 142, 458.
Götz, 7.
Gutman, 12.
Guthman, 9.
Guttmann, 524.
Guthrie, 563.
Gulz, 110.
Guerin, 827.
Galezowski, 176, 177, 178, 190, 209, 238.
Gaillard, 473.
Gad, L., 262.
Gama-Lobo, 426.
Geigel, 523, 524.
Gensoul, 508.
Giraudet, 226, 563.
Gluge, 492.

Habershon, 229.
Habertoma, 821.
Haase, 154, 287.
Hasse, 155, 156, 547, 553, 762.
Hasner, 55, 61, 67, 68, 69, 71, 72, 107, 108, 179, 200, 237, 245, 259, 288, 419, 420, 421, 425, 489, 493, 497, 502, 503, 516, 538, 540, 571, 598, 600, 610, 615, 636, 642, 643, 644, 763, 768.
Harder, 26.
Hannover, 128, 133, 134.
Hanmann, 12.
Hancock, 128, 271.
Hackley, 538, 644.
Harpin, 562.
Harpeck, 49.
Hartmann, 49.
Hart, 563.
Harley, G., 37.
Harling, 430, 515.
Hasket Derby, 35, 311.
Hyrtl, 515.
Hesse, 38.
Helfreich, 360.
Henle, 49, 50, 133, 134, 135, 154, 155, 156, 160, 224, 241, 273, 274, 334, 335, 357, 431, 488, 499, 515, 590, 632, 762, 763.
Henoch, 228.
Heurteloupe, 26, 191.
Heiberg, 135, 547, 548, 686.
Heymann, 10, 45, 46, 152, 164, 176, 209, 234, 335, 336, 492, 522, 524, 548, 616.
Heineke, 756, 765.
Helmholtz, 677, 678, 680, 681, 686, 700, 731, 759, 761, 762, 763.
Hedäus, 222, 543.
Herzenstein, 464, 491, 509.
Herrison, 228.
Hensen, 13, 155, 586, 687.
Hebra, 61.
Himly, 8, 113, 217, 218, 220, 251, 261, 269, 396, 432, 442, 459, 460, 475, 493, 517, 537, 539, 540, 563, 580, 600, 619, 624, 660, 662.
His, 147, 175.
Hippel, 2, 3, 5, 6, 10, 11, 12, 13, 35, 244, 311, 317, 557, 767.
Hirschberg, 77. 282, 287, 147, 153, 178, 198, 432, 544, 545, 546, 547, 848, 550, 553, 544, 556, 561, 578, 734.
Hirschler, 219, 287, 564.
Hirschmann, 220, 610.
Hering, 688, 780, 781, 782, 786, 787, 789, 790, 791, 792.
Hays, 767.
Huebbenet, 772, 773.
Hoffmann, 229.
Hofmann, 51.
Howship, 543.
Horner, 61, 120, 190, 191, 225, 250, 265, 271, 297, 313, 354, 396, 430, 492, 531, 544, 554, 580, 610, 628, 640, 755.
Homberger, 37.
Hoyer, 50.
Horper, 5.
Höring, 191, 268, 563, 616, 639, 640, 747, 748.
Hunter, J., 228.
Hulke, 155, 178, 526, 539, 546, 553, 558, 562.
Hutchinson, 61, 62, 68, 69, 70, 185, 218, 219, 252, 311, 553, 767.
Hjort, 226, 228, 547, 548.

Iwanoff, 49, 52, 53, 54, 61, 62, 95, 133, 134, 135, 140, 141, 142, 162, 164, 165, 166, 169, 170, 178, 189, 190, 193, 194, 205, 222, 224, 275, 279, 282, 283, 296, 351, 354, 543, 544, 554, 557, 592, 593, 611, 695.

Janin, 494.
Javal, 693, 730, 734, 736, 738, 803, 853.
Jaeger, 99, 116, 135, 145, 146, 147. 149, 158, 168, 169, 176, 184, 190, 206, 207, 215, 216, 218, 221, 231, 280, 285, 286, 306, 326, 334, 348, 351, 354, 355, 467, 509,

510, 543, 563, 564, 589, 601, 619, 633, 639, 643, 662, 703, 704, 705, 721, 723, 766, 769.
Jackson, H., 219, 223, 226, 228, 229, 748.
Jacobs, 218.
Jacobi, 137, 177, 328.
Jaesche, 509, 510.
Jäsche, 464, 506, 508.
Jacobson, 287, 305, 398, 542, 564, 578, 634, 637, 638, 640, 648, 747, 748.
Javal, 214, 677.
Javas, 821.
Jansen, 19.
Javalle, 66.
Jeffries, 62.
Jobert, 562.
Jobert de Lamballe, 228.
Joiyet, 9.
Jobst, 38.
Jüngken, 225, 541.
Junge, 165.
Just, 221.
Jeffries, B. Joy, 211, 545.
Junge, 10.
Jüngken, 118.

Koeben, 523.
Keate, 563.
Keyser, 254.
Kempf, 561.
Kersten, 501.
Kerst, 538.
Keen, 756.
Kitt, 50.
Kittle, 137.
Klebs, 54, 77, 133, 145, 154, 164, 299, 300, 554.
Kleeman, 501.
Knapp, 11, 117, 131, 139, 141, 147, 153, 168, 176, 178, 185, 197, 220, 221, 222, 223, 264, 282, 284, 287, 288, 423, 460, 542, 543, 544, 545, 546, 547, 548, 552, 553, 554, 556, 559, 570, 575, 576, 579, 624, 626, 630, 637, 639, 640, 644, 669, 670, 677, 678, 695, 696, 707, 730, 731, 732, 733, 735, 796, 820.
Kölliker, 50, 134, 154, 155, 175, 241, 360.
Korn, 254, 492.
Koster, 225, 226, 230, 561.
Kreitmair, 328.
Krause, C., 9, 358, 360.
Krause, W., 155, 156, 218.
Kuchler, 98, 127, 483, 633, 648, 660, 670.
Kussmaul, 3, 167.
Kidd, 751.
Kugel, 796.

Labarraque, 66.
Laiblin, 3.
Lacerda, 234, 774.
Ladame, 226, 227, 228, 229.
Landesberg, 200, 308.
Laforest, 508.
Landois, 8.
Lancereaux, 227, 228, 229.
Lallement, 229.
Laurence, 302, 442, 512, 541, 548, 553, 562, 563, 649, 767.
Lawson, 35, 217, 218, 279, 458, 491, 570, 572.
Larrey, 110.
Laquenr, 308, 310, 313.
Landray, 624.
Langenbeck, H., 557, 634.
Lainati, 541.
Langier, 630.
Landesberg, 221, 553, 554.
Langhans, 558.
Lancereaux, 219.
Lebert, 226, 227, 228, 229, 492.
Lebrun, 542, 553.
Lerche, 548.
Leidesdorf, 849.
Lecorché, 219, 611.
Lenoir, 562.
Leber, 146, 209, 219, 275, 276, 285, 286, 309, 553, 849, 153, 156, 168, 175, 176, 177, 178, 185, 229, 230, 239, 241, 242, 334, 335, 359.
Lesshaft, 488.
Letenneur, 492.
Leven, 229.
Leyden, 228, 527.
Lisfranc, 543.
Lincke, 547, 557.
Listing, 680, 759, 765, 779.
Liebreich, 66, 134, 147, 157, 158, 173, 189, 191, 193, 196, 199, 206, 207, 221, 223, 238, 264, 277, 278, 283, 297, 322, 323, 352, 577; O., 646, 754, 755, 821, 826.
Loewegren, 213, 593.
Logan, 564.
Loring, 651, 745, 796.
Loureiro, 219.
Loven, 12.
Lubinski, 318.
Ludwig, 7, 751.
Luer, 31.
Luys, 218.
Luschka, 357, 775.

Maats, 297.
Mackenzie, 8, 70, 117, 118, 217, 218, 219, 294, 295, 318, 391, 432, 433, 469, 493, 502, 523, 526, 527, 538, 539, 540, 542, 543, 545, 548, 551, 561, 562, 563, 564, 570, 613, 616, 765, 766, 767, 773, 792.
Magendie, 10.
Magni, 514, 570, 849.
Maitre-Jean, 553.
Mannhardt, 8, 238, 336, 420, 465, 474, 580, 627, 765.
Manz, 152, 155, 170, 177, 178, 228, 285, 615, 849.
Mauvezin, 432, 480.
Marcé, 229.
Maier, R., 488.
Marston, 381.
Mariotte, 198.
Mauchle, 360.
Mauthner, 3, 157, 158, 162, 168, 169, 172, 178, 183, 203, 215, 216, 223, 277, 286, 287, 322, 323, 348, 565, 601, 677, 702, 719.
Masson, 208.
Mayrhofer, 1.
Manfredi, 544.
Mandelstamm, 677, 762, 768.
Maisonneure, 542.
Masoart, 763.
Melchoir, 624.
Mead, 110.
Mende, 564.
Memorski, 3, 5, 6, 150.
Meissner, G., 10, 134.
Merkel, 241.

Meuriot, 34, 35.
Meyer, Ed., 120, 167, 219, 302, 302, 616, 668.
Meyer, L., 224.
Meyer, H., 589, 669.
Meyer, J., 220, 611, 794, 781.
Meyer, Ig., 153, 751.
Middleburg, 734, 735.
Mitchel, 756.
Michel, 228, 229.
Middleburg, 678.
Middlemore, 116.
Moll, 430.
Moeser, 209, 593, 594, 661.
Morehouse, 756.
Mooren, 11, 35, 89, 99, 119, 134, 170, 178, 217, 218, 267, 288, 297, 301, 302, 322, 336, 433, 446, 532, 541, 553, 554, 555, 581, 610, 611, 631, 636, 637, 734.
Morton, 562.
Moster, 229.
Mohr, 228.
Monnik, Dor., 2.
Müller, H., 9, 54, 55, 133, 135, 139, 146, 154, 156, 163, 203, 204, 205, 276, 277, 278, 350, 515, 591, 595, 597.
Müller, E., 541.
Müller, D. E., 21, 36, 226, 601, 616, 631, 687.
Müller, J. J., 777.
Müller, C. F., 49, 50.
Muralt, 118, 120.
Myelinkugeln, 591.

Nagel, 5, 164, 167, 168, 173, 184, 190, 218, 317, 323, 632, 696, 748, 763, 782.
Narkiewicz, 498.
Naumann, 12, 546.
Neumann, 244.
Nelaton, 552, 562.
Netter, 772.
Niemetschek, His., 53.
Niemetschek, 62.
Noyes, 176, 190, 704.
Nordmann, 614.
Nunneley, 562.
Nussbaum, 32, 113.

Ogle, 9, 751, 756.
Olliver, 229, 524.

Pagenstecher, 41, 173, 174, 175, 176, 178, 187, 190, 196, 199, 200, 213, 224, 251, 268, 269, 298, 300, 423, 464, 478, 555, 600, 622, 625, 626, 637, 644, 645, 742, 747, 748.
Paul, 534.
Panum, 698.
Passavant, 259, 268, 481, 563.
Pamard, 557.
Parish, 563.
Paget, 552.
Pauli, 561.
Palucci, 630.
Peringer, 372, 380, 381, 413.
Pedraglia, 238.
Petit, 9, 284.
Petermöller, 50.
Petriquin, 767.
Piringer, 99, 100, 110, 364, 600.
Picard, 237.
Pilz, 601; O., 570.
Pope, 3, 163, 165, 205, 476, 678.
Power, 10.
Poland, 562.
Pokela, 544.
Polak, J. E., 551.
Poncet, 774.
Praag, L. V., 32.
Prava, 31.
Prevost, 9, 238.
Prosoroff, 41.
Pray, 733.
Preyer, 763.

Quadri, 446, 565, 644.
Quaglino, 209, 220, 221, 238.

Raleigh, 5.
Ran, 41, 219, 455, 473, 503, 506, 509.
Rautengrube, 776.
Ritter, C., 133, 135, 155, 156, 176, 274, 284, 590.
Riegler, 77.
Rivaud, 624.
Ritterich, 584, 638.
Riberi, 358.
Rittmann, 218.
Remak, 9, 209, 748, 749.
Reith, 523.
Reisel, 532.
Resal, 612, 613.
Recklinghausen, 49, 51, 155, 168, 230, 422, 522, 533, 547, 550, 786.
Reuss, 642. 677, 736.
Rindfleisch, 554.
Ruiter, 33, 34.
Richter, 507, 510, 635.
Ringland, 218.
Robertson, A., 37.
Rogow, 33, 34, 37, 38.
Rothmund, 10, 109, 138, 267, 492, 542, 558, 611, 631.
Rokitansky, 190, 202, 560, 561.
Rollet, 224, 241, 275.
Rosenberg, 524.
Rosow, 11, 175, 274, 279, 677.
Roosa, 8.
Roser, 43, 73, 245.
Rosenstein, 219.
Rosenthal, 229.
Roosbroeck, 72, 563.
Roosa, D. B. St. John, 313.
Rose, 761, 763.
Robinson, 766.
Robin, 544, 546, 570.
Robertson, 756.
Rudnew, 165, 194, 205.
Rudmaier, 488.
Ruete 8, 33, 118, 136, 484; B., 502, 668, 760, 750, 765.
Rädinger, 776.
Rydl, 310, 317, 517, 612.
Ryba, 541, 616.

Saemisch, 89.
Salter, 225.
Salkowski, 8, 9.
Sämisch, 9, 134, 165, 166, 168, 184, 212 or 213, 220, 226, 286, 287, 295, 434, 645.
Samuel, 8, 11.
Samson, 483.
Sands, H. B., 825.
Sappy, 589.

Saunders, 553.
Sanson, 98.
Sandifort, 538.
Sappey, 430.
Seebeck, 762, 763.
Serres d'Uzes, 209.
Scarpa, 98.
Schalygen, 49, 52.
Schelske, 158, 208, 762.
Schiff, 8, 9, 10, 11, 12.
Schirmer, 77, 157, 158, 177, 327, 328, 372, 551, 561, 688, 765, 766, 767.
Schweigger, 9, 137, 158, 163, 167, 170, 173, 190, 193, 205, 214, 222, 237, 276, 281, 284, 287, 307, 317, 340, 341, 508, 525, 542, 564, 597, 637, 701, 702, 719, 731, 802, 803, 806, 821, 824.
Schiess, 284, 340, 341.
Schiess-Gemuseus, 54, 253, 282, 284, 296, 340, 434, 443, 546, 562, 572, 620.
Schneller, 35, 164, 221, 223.
Schön, 561, 610.
Schuft, 270, 631.
Schreder, 218.
Schroff, 36.
Schwalbe, 147, 273, 514.
Schmidt H., 147, 178, 190, 492, 501, 503, 507 ad 539; A., 600; H., 563 ad 767, 748.
Schön, Haynes-Walton, 492, 628.
Schultze, M., 154, 155, 156, 158, 159, 160, 357.
Schultze, F. E., 275, 358; M., 681, 762, 763.
Schulz, 852.
Seamann, 234.
Secondi, 70, 72, 126, 175, 190, 191, 200, 221, 222, 223, 238, 249, 26c, 302, 317, 357, 507, 508, 624, 686, 767, 796.
Sichel, 36, 117, 120, 200, 218, 219, 228, 302, 344, 346, 517, 544, 546, 548, 558, 563, 570, 572, 581, 629, 630, 637, 643, 648.
Seidel, 218.
Seitz, 402, 540.
Sesemann, 146, 178, 515, 516.
Seegen, 77.
Shearer,
Simon, 168.
Simrock, 77.
Singer, 61, 552, 600.
Schuh, 540, 541, 542, 559, 560.
Sous, 563.
Spengler, 218, 774.
Spöring, 543.
Snellen, 11, 270, 385, 474, 677, 682.
Stör, 134.
Streatfield, 36, 259, 267, 287.
Stricker, 51.
Stengel, 552.
Stelling, 776.
Stevenson, 217.
Schelske, 209, 305.
Schmucker, 538.
Schröter, 767.
Schrœter, 665.
Solly, 229.
Solomon, 271.
Soelberg, Welz, 137, 564.
Späth, 234.
Spurgin, 226.
Stanley, 10, 543.
Staub, 8, 250.
Stavenhagen, 16, 88, 99, 137, 175, 194, 287, 446, 570, 571.
Steffan, 10, 11, 61, 62, 217, 221, 222, 228, 268, 286, 442, 488, 552, 558, 600, 625, 631, 637, 748
Stieda, 358, 430.
Stilling, 133, 134, 190, 193, 226, 317, 510, 665.
Stemlin, 155.
Schott, 564.
Schuerman, 677, 707, 721, 777.
Sellheim, 218.
Sen. Scultet, 563.
Sippell, 616.
Skokalski, 563, 763, 852, 853.
Soler, 561.
Stöber, 557.
Stammeshaus, 748.

Thielesen, 219.
Talko, 234, 287, 334.
Tamanschef, 50.
Tanquerel, 219.
Tardieu, 218.
Teslelin, 8.
Testelin, 302, 765, 767.
Teichmann, 50.
Teulon, 681, 682.
Tetzer, 71, 332, 528; M., 761.
Thomas, 109.
Théry, 7.
Thiry, 751.
Tomsa, 360.
Traube, 190, 219, 523.
Trautvetter, 3, 9, 12, 686, 687.
Trousseau, 520, 523, 524, 525.
Türck, 226, 230, 849, 850.
Tavignot, 624.
Travero, 540, 561.
Toussaint, 134.
Todd, 274.
Travers, 111, 543.
Tschudi, 766.
Tyndall, 762.
Tyrrel, 120.

Ullersperger, 218.

Villards, Caren du, 540, 563.
Visconti, 541.
Virchow, 77, 133, 155, 164, 167, 168, 190, 244, 328, 4
503, 521, 523, 537, 538, 539, 540, 542, 543, 544, 5
548, 549, 550, 552, 553, 554, 556, 558, 570, 600.
Vierordt, 3.
Vée, 38.
Verschoor, 700.
Vidal, 462, 474.
Völckers, 13, 686, 687, 777.
Volkmann, 681, 786.
Vroesom de Haan, 769.
Vroesom, 682.
Verneuil, 756.
Velpeau, 562.
Vernon, 285.

Waldau, 270.
Walton, H., 455, 543, 562.
Walker, H., 99, 116.
Walther, 494.
Wagner, R., 9, 10, 228.

Wagner, E., 366, 600, 613.
Wardrop, 110, 118, 120, 561, 562.
Warlomont, 43, 98, 411, 492, 508, 510.
Waldhauer, 539, 563.
Wartmann, 761.
Warren, 553.
Weber, A., 3, 6, 13, 80, 89, 228, 229, 259, 267, 478, 488, 494, 503, 508, 509, 510, 564, 646, 666, 668, 681.
Weber, C. O., 133, 136, 229, 306, 593.
Wedl, 51, 52, 55, 95, 102, 135, 136, 162, 163, 164, 167, 204, 243, 277, 278, 279, 282, 284, 298, 300, 340, 341, 350, 425, 432, 488, 549, 551, 591, 593, 594, 595, 597, 600.
Wegner, 5, 6, 9, 12, 311.
Wecker, 134, 153, 178, 201, 221, 262, 269, 317, 366, 492, 507, 509, 517, 539, 541, 562, 563, 613, 626, 637, 767.
Weickert, 229.
Weller, 110, 538, 545.
Welz, 214.
Wenzel, 635.
Weinlechner, 540.
White, 366.
Williams, 493, 506, 510, 562, 580, 638, 782.
Williams, H., 664.
Willebrand, 191, 749, 756.
Wilson, 287, 762.
Wittich, 211, 274.
Windsor, 109.
Winther, 10, 276, 421.
Witt, 767.
Wolfring, 357, 358, 359, 363, 364, 365, 429, 431.
Worlitschek, 268.
Woinow, 642, 677, 678, 681, 683, 701, 736.
Wollaston, 765.
Wunderlich, 234.
Wutzer, 113.

Young, 677, 678, 680, 761.

Zander, 526.
Zeisal, 501.
Zehender, 134, 218, 222, 486, 493, 516, 540, 562, 570, 572, 648, 660, 682, 693, 725, 757, 768.
Zeis, 497.
Zenker, 167.
Zernoff, 590.
Zülzer, 12.

INDEX.

Abduction, 833.
Aberration, chromatic, 730, 678.
Ablation of staphyloma, 129.
Abnormal astigmatism, 695.
Abscess of antrum a cause of amaurosis, 225.
brain, 227.
cornea, 53.
conjunctiva, 366.
iris, 244.
lids, 431, 437, 438.
orbit, 198, 526, 529.
vitreous, 135.
Absolute hypermetropia, 691.
Absorption of cataract, 619, 621.
Accidents in peripherical linear extraction, 669.
Accommodation, 683.
in aphakia, 722.
paralysis of, 747.
range of, 685, 722.
spasm of, 33, 753.
Accommodative asthenopia, 740.
Acetate of lead, 41; in pannus, 98.
Achromatopsia, 209, 761.
Achrupsia, 761.
Acid nitrate of mercury in pannus, 98.
Acne, 538.
ciliaris, 429.
indurata, 440.
of caruncle, 538.
of lids, 433.
pustulosa, 434.
Acquired astigmatism, 736.
Action of ciliary muscle a cause of staphyloma posticum, 354.
Action of mydriatics, 34.
ocular muscles, 780, 785.
Acuity of vision, 682.
Adaptation, 683.
of artificial eyes, 583.
Adduction, 833.
Adenoid growths, 550.
Adhesion of the edges of the lids, 454.
iris to lens-capsule, 291, 293.
lids to globe, 457.
Advance of vitreous with lens, 663.
Advancement of external rectus, 821.
internal rectus, 824.
Adjustment, 683.
Ægilops, 437, 494.
After-images, 765, 779.
After-treatment of cataract, 641.
Age at which squint should be operated upon, 817.
Agnew's operation for opaque capsule, 445.
Alcohol to be avoided in amaurosis, 234.
Alum, 41.
Amaurosis, 769.
from alcohol and tobacco, 219.
basilar periostitis, 224.
tumors, 225.
atrophy of nerve and retina, 207.
anæmic, 218.
with cataract, 609.
partialis fugax, 765.
spinalis, 230.
trifacialis, 767.
uræmic, 191.
Amaurotic cat's-eye, 339.
Amblyopia, 208, 769.
exanopsia, 108, 763.
in squint, 832.
potatorum, 219.
Ametropia, 691.
Amorphous yellow oxide of mercury, 40.
Amotio ratinæ, 193.
Amount of blood in the eye, 1.
Anæmia a cause of amaurosis, 218.
Anæmic atrophy, 218.
Anæsthesia optica, 166.
exanopsia, 769.
in squint operations, 818.
of cornea, 305.
of retina, 724.
trigeminus in exophthalmic goitre, 523.
Anæsthetics in cataract extractions, 630, 646.
Anatomy of the choroid, 273.
conjunctiva, 357.
cornea, 48.
eyelids, 427.
crystalline lens, 590.
iris, 240.
lachrymal apparatus, 488.
ocular muscles, 775.
orbit, 513.
retina, 154.
sclera, 334.
vitreous, 133.
Anchyloblepharon, 452, 454.
Anchylops, 437, 494.
Anerythropsia, 762.
Aneurysma anastomoticum, 562.
Angioma, 559.
cavernosum, 560.
Anisometropia, 711.
Ankyloblepharon and blepharophymosis, 454.
from blepharitis, 432.
Anodynes after extraction, 649.
Anterior chamber, 240.
focal line, 679.
symblepharon, 432.
Anterior synechia, 294.

Anthrax palpebrarum, 432.
Antidote to atropine, 37.
calabar-bean, 39.
Antiphlogistic medicines, 27.
regimen, 26.
Aphakia, 722.
Application of mydriatics, 33.
Aqua chlori, 385.
Aqueous humor, 240.
Arcus senilis of cornea, 50.
lens, 595, 602.
Arcus tarsus, 431.
Arteria centralis retinæ, 146.
hyloidea, 134, 139.
Artificial eye, 583.
for entropion, 476.
leech, 26.
pupil, 261.
in iritis, 259.
myosis, 756.
opacity of the cornea, 113.
sclero-choroidal staphyloma, 345.
Asthenopia, 697, 724.
accommodative, 740.
Astigmatism, 678, 731.
abnormal, 695, 730.
irregular, 696.
normal, 678.
regular, 678, 730.
after cataract extraction, 650.
Astigmatic difference, 695.
glasses after cataract extraction, 651.
Astigmometer, 734.
Astringents, 42.
in conjunctivitis, 374, 378.
blennorrhœa, 387.
Astringent caustics, 43.
injections in dachryocystitis, 506.
Atheroma, 450, 598.
of choroidal vessels, 278.
Atonic lagophthalmos, 797.
Atresia pupillæ, 255.
Atrophy of the choroid, 298.
eyeball, 298, 330.
lens, 592, 594.
ocular muscles, 848.
optic nerve, 180, 202, 209.
Atropine, 36.
antidote to, 37.
an antidote to calabar-bean, 39.
as a cause of acute glaucoma, 35.
constitutional poisoning by, 36, 37.
fungi in solutions of, 36.
gelatine, 36.
in conjunctivitis, 373.
herpes of the cornea, 66.
hypermetropia, 718.
iritis, 258.
keratitis punctata, 69.
phlyctenular conjunctivitis, 418
spasm of accommodation, 754.
suppurative keratitis, 87.
trachoma, 410.
vascular keratitis, 59.
local poisoning by, 35.
ointment, 37.
paper, 36.
poisoning, 33.
Atropine, strength of solution, 36.

Bandage, 15.
hermetical, 377, 384.
pressure, 14.
protective, 66.
retentive, 15.
after squint operations, 823.
Basedow's disease, 517, 520.
Base-line, 778.
Basilar tumors, 226.
Bathymorphia, 703.
Baths, 67.
Bdellatomy, 25.
Becker's tables, 732.
Beer's cataract-knife, 660.
needle, 655.
Binocular diplopia, 802.
vision, 805, 831.
visual space, 782.
Binoxyde de mercur hydraté, 41.
Blennorrhœa, 379.
a cause of pterygium, 421
of the lachrymal passages, 500.
Blennorrhœal secretion, 361
Blepharadenitis, 434.
Blepharitis, 431.
ciliaris, 373, 434, 441.
a cause of ankyloblepharon, 454.
hypertrophica, 434.
secretoria, 434.
tarsalis, 435, 448.
ulcerosa, 434.
Blepharophymosis, 454.
Blepharoplasty, 485, 571.
Blepharoplegia, 797.
Blepharospasm, 795.
Blind-spot, 211.
Blood, abstraction of, 24.
Blood-letting in exudative retinitis, 187.
neuro-retinitis, 181.
staphyloma posticum, 356.
Blood-supply of uveal tract, 275.
Blood-vessels of conjunctiva, 359.
choroid, 275.
iris, 241.
lids, 431.
optic nerve, 146.
retina, 146.
Blue-blindness, 762.
Bonnett's capsule, 514.
Bony degeneration of atrophied eyeball, 330.
cornea, 104.
Bowman's membrane, 49.
Brain-disease a cause of divergent squint, 824.
amaurosis, 217.
Branches of the orbital artery, 515.
Brandy-solution, 823.
Bright light a cause of ophthalmia neonatorum, 390
Brilliant reflex in atrophy of nerve, 206.
Bringing forward of internal rectus, 826.
Broad-brimmed hat in neuro-retinitis, 181.
Buphthalmus, 115.
Bursting of staphyloma posticum, 355.

Cadmium, sulphate of, 41.
Calabar-bean, 38.
antidote to, 39.

Calabar-bean, constitutional poisoning by, 39.
in iritic adhesions, 259.
mydriasis, 752.
paralysis of accommodation, 749.
ulcer of cornea, 39.
Calabar-paper, 38.
Calomel, dusting in of, 40.
in diffuse keratitis, 72.
herpes of the cornea, 65.
pannus, 97.
phlyctenular keratitis, 59.
conjunctivitis, 418.
vascular keratitis, 59.
Cancer, 543, 558.
Canaliculus, 488.
probing of, 305.
slitting of, 498.
Canal of Schlemm, 276.
Canthoplasty, 455.
in blepharophymosis, 455.
ectropion, 472.
phlyctenular keratitis, 59.
vascular keratitis, 59.
Canthus, 427.
Capsular cataract, 83.
Capsule, Bonnett's, 514.
Tenon's, 514.
of lens, 589.
Capsulitis, 245, 298, 618.
Carbuncle of lids, 432.
Carcinoma, 557.
cutaneous, 558.
Caries of the lachrymal bone, 497.
Cataplasms in suppuration after flap-extraction, 650.
Cataract, 589; adnata, 610: argentea, 599; calcarea, 599; capsular, 83, 598, 600; capsulo-lenticular, 597; chalky, 599; cholesterinic, 599; choroidalis, 255; complicated, 608; cortical, 596; cruenta, blood, 255; cystic, 598; cum bursa ichorem tenente, 600; diabetic, 611; discoid, 620; dura, hard, 595; ergotica, 611; false, 255, 256; fibroid, 599; fibroso-calcarea, 599; fluid, 598; glaucomatous, 315; grumous, 255; hyaloid, 293; inflammatory, 592; lactea, 598; lymph, 255; laminated, 606, 618; mature, ripe, 626; mixed, 595; milk, 598; myaline, 598; natans, 615; nigra, 612; nuclear, 595, 602; osseous, 600; over-ripe, 627; partial, 600; pigmented, 255; polar, 142, 293; posterior capsular, 142; purulent, 593; putrid, 600; pyramidal, 600, 607; secondary, 620; siliquata, 599, 620; spurious, 255; soft, 596, 598, 604, 630; spontaneous, 616; stellate, 604; traumatic, 614; tremulous, 615; vitreous, 293.
Cataract, absorption of, 619, 621.
after-treatment of, 641.
diagnosis of, 602.
operations for, 624.
spontaneous cure of, 618.
Catarrhal conjunctivitis, 369, 652.
secretion, 361.
Catgut bougies, 509.
Cat's-eye, amaurotic, 339.
Cauda equina, 203.
Cauda-equina-nervi optici, 145.
Caustics, 43.
in blennorrhœa, 387.
Cauterization in corneal staphyloma, 120.
after cataract extraction, 651.
Cauterization of walls of lachrymal sac, 506.
Cavernous tumors, 560.
Cavum narium, 489.
Central anæsthesia, 807.
capsular cataract, 600, 607.
Centred glasses, 718.
Centres of coördination, 784.
Cerebral amaurosis, 228.
hemorrhage a cause of amaurosis, 227.
Cerebro-spinal meningitis, 117, 328.
paralysis, 849.
Cervical limiting cord, 9.
Chalazion, 449, 450, 538.
from trachoma, 409.
Chalky cataract, 599.
deposits in vitreous, 135.
Chancre of lid, 433.
Changes in corneal opacities, 107.
ciliary muscle, 282.
Chemical causes of injury, 16.
Chemosis, 362.
Chiasma, 226.
Chloride of potassium in epithelioma, 570.
Chloroma, 552.
Choice of glasses in myopia, 710.
Choked disc, 178.
Cholesterin crystals, 196.
Choloid bodies, 278.
Chondroma, 542.
Choroid, anatomy of, 273.
detachment of, 283.
ophthalmoscopic appearance of, 276.
rupture of, 286.
senile changes in, 277.
Choroidal glioma, 545.
hemorrhages, 289.
Choroiditis, 278.
areolaris, 166.
exudative, 281.
hyperplastic or sarcomatous, 553.
metastatic, 329.
serous, 279.
suppurative, 283, 325.
Chromatic aberration, 678, 730.
Chromatodesopsia, 761.
Chromo-lithographs, description of, 855.
Chromopsia, 209.
in glaucoma, 309.
panophthalmitis, 326.
Cicatrices, corneal, 102.
with anterior synechia, 103.
Cicatricial corneal staphyloma, 122.
staphyloma, 123.
total staphyloma of the globe, 338.
Cilia, 427.
Ciliary arteries, 275.
body, 273, 274, 275.
ganglion, 242.
muscle, division of, 271.
influence of, 18.
processes, 274.
Circular muscle of the lids, 428.
Circulation in head and neck, 22.
intraocular, 1.
Circulus arteriosus iridis minor, 241.
major, 275.
Circumcision of cornea, 98.
Circumcorneal injection, 291.

Cirsophthalmus, 345.
Clavus, 104.
Cleansing the eye after extraction, 548.
in blennorrhœa, 387.
lids in blepharitis, 445.
acne ciliaris, 440.
Clonic spasms, 794.
Closure of pupil, 267, 281.
puncta, 493.
Cloudiness of media in glaucoma, 307.
Cloudy atrophy of nerves, 202.
Cold applications, 24.
after squint operations, 823.
for blepharitis, 440.
in blennorrhœa, 386.
conjunctivitis, 373, 377, 398.
suppurative keratitis, 87.
vascular keratitis, 59.
Collapse of globe, 86.
Collyria, 42.
Colloid deposits in vitreous, 135.
Color-amblyopia, 209.
Color-blindness, 761.
in neuro-retinitis, 175.
Colored glasses, 20.
in neuro-retinitis, 181.
Colored vision, 761, 763.
Color of iris, 241.
optic disc, 147.
in glaucoma, 306.
Combination of tumors, 539.
Comedones, 439, 538.
Complications of cataract, 609.
iritis, 245.
Compound astigmatism, 735.
Concave glasses, 714.
Concomitant squint, 801.
Condylomata of iris, 249.
Confluent pustule of the lid, 441.
Congenital astigmatism, 735.
cataract, 610.
excavation, apparent, 145.
true, 146, 148.
flatness of cornea and lens, 722.
Congestive atrophy, 218.
Congruous spots, 786.
Conical cornea, 115.
Conline as a myotic, 37.
Conjunctiva, 357.
blood-vessels of, 359.
lymphatics of, 359.
minute anatomy of, 358.
nerves of, 360.
ocular, 357.
palpebral, 357.
Conjunctival croup, 395.
suture in squint operations, 821.
Conjunctivitis, 357.
blennorrhœal, 379.
catarrhal, 369.
degenerative, 365.
diphtheritic, 366, 395.
gonorrhœal, 381.
membranous, 365, 376.
Consanguinity of parents a cause of retinitis pigmentosa, 237.
Consecutive glaucoma, 316.
Consequences of blepharitis, 454.
Consequences of conjunctivitis, 419.
Constant scotomata, 758.
Constitutional poisoning by atropine, 36, 37.
calabar-bean, 39.
treatment in pannus, 100.
Contagion a cause of conjunctivitis, 372.
trachoma, 404.
Contractions of the nasal duct, 509.
Contra-indications to extraction, 628.
Conus, crescent, 348.
Convergent squint, 795, 799.
Convex glasses in asthenopia, 745.
hypermetropia, 724.
spasm of accommodation, 754.
Co-ordination, 688.
Copper, sulphate of, 41.
Corelysis, 259.
Corneal causes of astigmatism, 695.
corpuscles, 49.
cicatrices, 102.
herpes, a cause of pterygium, 420.
ulcers, a cause of false pterygium, 420.
transverse section of, 89.
staphyloma, 115.
Cornea, 48.
abscess of, 73.
anatomy of, 49.
artificial, 113.
blood-vessels of, 50.
bony degeneration of, 104, 108.
chalky deposits on, 104.
conical, 115.
conjunctiva of, 49.
corpuscles of, 49.
curvature of, 677.
globosa, 115.
hernia of, 81.
herpes of, 60.
inflammation of, 45.
inflammatory changes in, 52.
inflam. neuro-paralytic, 77, 546.
in marasmus, 51.
lymphatics of, 50.
metallic incrustations on, 104.
neoplasia of, 54.
nerves of, 50.
rupture of, 82.
senile changes of, 50.
staphyloma of, 85.
Corpora quadrigemina, 228.
Corpus vitreum, 133.
Corpuscles, corneal, 49.
Correcting-glasses in squint, 814.
Correction of unequal refraction, 728.
Corrosive chloride of mercury, 41.
sublimate in eczema, 66.
Cortical cataract, 596, 608.
Couching, 642.
Counter-irritation, 30.
Crescentic ulcers, 383, 393.
Critchett's operation for staphyloma, 130.
Crossed images, 845.
Crystalline lens, 589.
senile changes of, 591.
Cupping, 26.
of disc, 305.
Cure of cataract by therapeutic measures, 634
lachrymal fistula, 510.

Curtains, 19.
Cyanometer, 209.
Cyclitis, 296.
Cylindrical glasses, 733.
in anterior staphyloma, 121.
Cylindroma, 561.
Cysticercus, 563, 577.
in lens, 614.
Cystoid cicatrix, 641.
degenerations, 546.
Cysts of the iris, 539.
Cysto-sarcoma, 549.

Dacryo-adenitis, 492.
Dacryocystitis, 496.
Dacryocystoblennorrhœa, 494.
Dacryoliths, 493, 503.
Dacryops, 492, 539.
Dalrymple's needle, 655.
Daltonism, 762.
Damp rooms, 17.
Dark-chamber in neuro-retinitis, 181.
Darkness a cure for hemeralopia, 773.
Daturine, a mydriatic, 36.
Death from enucleation, 580.
panophthalmitis, 329.
Degeneration of muscle in squint, 813.
Degenerative form of cyclitis, 296.
Demour's membrane, 50.
Depilation for blepharitis, 446.
Depression of cataract, 632.
Dermoid tumors, 541.
Descemet's membrane, 50.
Description of chromo-lithographs, 855.
Destruction of hair-follicles, 463.
lachrymal sac, 510.
gland, 512.
Detachment of ciliary body, 282.
choroid, 283.
retina, 193, 298, 355.
vitreous, 140.
Determination of far-point, 701.
hypermetropia, 719.
astigmatism, 732.
Deviation of visual line, 842.
Diabetic amaurosis, 218.
cataract, 610.
Dictyitis, 154.
Dietetic regimen, 257.
Difficulty in escape of cataract, 663.
Diffuse granulations, 363.
Digitaline as a myotic, 37.
Diffuse neuro-retinitis, 172, 179.
trachoma, 402.
Dilator muscle of iris, 241.
Dilute acetic acid in xerosis, 426.
Diminution of vision in hypermetropia, 721.
Dioptric apparatus, 677.
media incompressible, 13.
opacity of, 196.
Diphtheritic conjunctivitis, 366, 395.
paralysis, 748.
Diplopia, 830, 843.
after tenotomy, 804, 823.
from pterygium, 419.
monocularis, 680.
Direct method, 867.
Disadvantages of tenotomy, 817.
Discission, 630, 632, 655.
Discoloration of the papilla, 215, 322.
Diseases of refraction and accommodation, 677.
Disease of pons Varolii, 229.
Diseases of ocular muscles, 775.
Dislocation of lens, 293, 615.
Displacement of pupil, 268, 626.
in corneal opacities, 111.
irregular astigmatism, 738.
anterior staphyloma, 121, 122.
Dissecting glasses, 716, 836.
Distichiasis, 444.
and trichiasis, 462.
Distoma oculi humani, 614.
Disturbances of vision in glaucoma, 308.
Divergent squint, 707, 828.
Division of cataract, 630, 631.
ciliary muscle, 271.
nerves, 301.
optic nerve for photopsia, 200.
Dizziness in paralysis of ocular muscles, 847.
Double images, 782, 786, 830.
iridectomy, 323.
needle operation, 645.
Double vision, 419, 680, 804, 823, 830, 843.
Douches, 23.
Drastic purgatives, 29.
Dry capsular cataract, 643.
catarrh, 372.
Dust, 15.
Dust-spectacles, 16.

Echinococcus, 563.
Ectasia of the cornea, 115.
Ectopia lentis, 616.
Ectropion, 373, 384, 393, 477.
from blepharitis, 432.
trachoma, 409.
mechanical, 479.
paralytic, 478.
sarcomatosum, 478.
senile, 478.
Ectropium luxurians, 403.
Eczema, 66.
Effect of division of cervical limiting cord, 9.
sympathetic nerve, 10.
Elastic catheters for tear-duct, 509.
Electricity in mydriasis, 752.
myosis, 756.
opacity of the cornea, 109.
paralysis of ocular muscles, 852.
conjunctivitis, 852.
Elephantiasis of lids, 540.
Elevation of temperature in blennorrhœa, 379.
conjunctivitis, 367.
Elongation of optic axis, 349.
Embolic panophthalmitis, 371.
Embolism, 222.
Emmetropia, 579.
Emphysema of lachrymal sac, 503.
orbit, 518.
Encanthis calculosa, 538.
fungosa, 538.
Encephalitis a cause of amaurosis, 227.
Encephaloid glioma, 543.
Endothelium, 147.
Enlargement of the blind spot, 353.

Enophthalmos spasticus, 795.
Entoptic appearances, 757.
bodies, 139.
Entozoa, 563, 614.
Entropion, 373, 470.
a cause of xerosis, 426.
after flap-extraction, 664.
from trachoma, 409.
Enucleation, 580.
for staphyloma, 123, 347.
glaucoma, 323.
suppurative irido-choroiditis, 333.
sympathetic ophthalmia, 301, 302.
Ephidrosis palpebrarum, 433.
Epiblepharon, 797.
Epicanthus, 797.
Episcleritis, 336.
Epithelial cancer, 559.
opacities, 101.
Ergotism a cause of cataract, 611.
Ergot in paralysis of accommodation, 749.
Erysipelas of lids, 433.
from destruction of tear-sac, 511.
Escape of vitreous, 267.
before lens, 663.
Ethmoidal nerve, 9.
Everting the lids, 44.
Examination of visual field, 209.
Exanthemata as cause of panophthalmitis, 328.
Excavation of optic nerve in atrophy, 203.
glaucoma, 306.
congenital, 146, 148.
Excision of blood-vessels in pannus, 98.
chalazion, 452.
corneal opacities, 110.
granulations, 411, 823,
prolapsed iris, 659.
pteryglum, 422.
staphyloma, 129.
Exophthalmia fungosa, 557.
Exophthalmic goitre, 520.
Exophthalmos, 517.
cachecticus, 517.
Exophthalmus from extra-ocular tumors, 569.
Exostosis, 542.
External palpebral ligament, 473.
rectus, advancement of, 821.
Extirpation of eyeball, 573.
lachrymal gland, 512.
sac, 512.
tumors, 570.
Extraction of cataract, flap, 660.
lens and capsule entire, 636, 642.
Liebreich's corneal, 672.
linear, 657.
with iridectomy, 271.
peripherical linear, 665.
Streatfield's peripherical, 671.
Extraction of cilia, 463.
cysticercus, 578.
Extra-ocular tumors, 569.
Extravasations, 170.
in choroid, 288.
in conjunctivitis, 367.
in detachment of retina, 196.
in retinitis, 164.
in vitreous, 138.
Exudative choroiditis, 281.
neuro-retinitis, 166.
retinitis, 183.
Eye, artificial, 583.
care of, 14–21.
glasses, 712, 728.
lotions, 41.
shades, 20.
Eyeball, atrophy of, 329, 383.
enucleation of, 580.
extirpation of, 573.

Facial erysipelas, 371.
Facultative hypermetropia, 691, 720.
False cataract, 255, 256.
pterygium, 419.
Far-point, 700, 718.
Far-sightedness, 723.
Fascia tarso-orbitalis, 428, 514.
Fasting a cause of hemeralopia, 773.
Fatty degeneration, 204.
of cells of vitreous, 135.
Favus of the lids, 442.
Fibroma, 540.
Field-glasses, 711.
Field of vision, 213.
in amaurosis, 232.
Fifth nerve, 9.
Filaria, 565.
oculi humani, 614.
Fil de Florence used for suture, 481.
Filthiness a cause of ophthalmia neonatorum, 391.
Fistula of lachrymal gland, 492.
Flap extraction, 635, 637, 660.
Flat formation, 721.
Flattening of cornea, 305.
Flitting scotoma, 765.
Flocculi in atropine solutions, 36.
Fluid vitreous, 615.
Focal distance, 678, 703.
tract, 679.
line, anterior and posterior, 679.
Foci, 183, 184.
Fœtal vitreous, 133.
Follicles of cilia, 430.
Fontana's canal, 241.
Foramen opticum choroidea, 273.
Forced ripening of cataract, 627.
Foreign bodies in anterior chamber and iris, 250, 264, 265.
conjunctiva, 250, 257, 372.
cornea, 58, 76, 250, 257.
eye, 257.
lens, 613.
orbit, 529.
vitreous, 137, 139.
Form of cornea, 677.
Fovea centralis, 154.
trochlearis, 776.
Fracture of roof of orbit, 518.
Frog-spawn granules, 364.
Frontal nerve, 9.
Fulminating glaucoma, 314.
Fungi in canaliculi, 493.
hair-follicles, 442.
Fungous, hæmatodes, 559.

Galvanic current in amaurosis, 234.

Gerontoxon of cornea, 50.
lens, 592.
Glass-stud in opacity of cornea, 113.
Glasses, concave, 712.
convex, 722, 724, 745, 754.
cylindric, 733.
periscopic, 714.
prismatic, 716, 836.
dissecting, 716, 836.
Glaucoma, 304, 305.
absolutum, 315, 323.
consecutive, 316.
fulminating, 314.
simplex, 315.
in staphyloma posticum, 355.
Glaucomatous cataract, 315.
degeneration, 316.
excavation of papilla, 280, 305.
Glioma, 543, 575.
Gliosarcoma, 549, 552, 576.
Glittering of the eyes, 864.
Globe, collapse of, 86.
atrophy of, 329, 383.
Globulin, 590.
Glycerine in xerosis, 426.
Goggles, 16.
Goitre and exophthalmos, 520.
Gonorrhœal ophthalmia, 381.
Grades of myopia, 700.
Grando, 538.
Granular conjunctivitis, 401.
trachoma, 401.
Granulations of iris, 243, 249.
stump of divided tendon, 822.
Granuloma, 557.
Graves' disease, 520.
Gray atrophy, 202.
Greasing edges of lids, 375, 445.
Green-blindness, 762.
cataract, 307.
Gummy tumors, 281.
of iris, 243, 249, 255.
lids, 432.
Gymnastic exercises in asthenopia, 744.

Hæmophthalmia, 247.
Halo round the macula, 158.
Hancock's operation, 271, 317.
Hard cataract, 595.
Harder's artificial leech, 26.
Hardness of globe, 304.
Haziness of the vitreous, 292.
Heart-disease a cause of neuro-retinitis, 176.
Heat and cold, 18.
Hebetudo visus, 697.
Hemeralopia, 766, 771.
in retinitis pigmentosa, 237.
Hemiopia, 212, 225.
homonymous, 213.
nasal, 213.
Hemorrhage in iridectomy, 266.
into eye, 346.
vitreous, 138.
from iris, 249.
in irido-choroiditis, 303.
in staphyloma posticum, 355.
into retina and papilla, 170.
Hemorrhagic onyx, 55.
Hermetical bandage, 384.
Hernia of the cornea, 81.
lachrymal sac, 503.
Herpes of the conjunctiva, 366, 416.
cornea, 60, 63, 64, 65.
ophthalmicus, 62.
Herpetic bridge, 61.
pannus, 418.
Heurteloupe's artificial leech, 26.
Histoid tumors, 539.
Historical notice of exophthalmic goitre, 520.
Hodometer, 801.
Homonymous images, 845.
Hordeolum externum, internum, 435, 448.
Horner's muscle, 428.
Horopter, 792.
Humor morgagni, 591.
Hyalitis, 133, 137, 138, 139, 142.
hypertrophic, 136.
suppurative, 135.
tuberculous, 135.
Hyaloid artery, 134, 139.
Hydatids, 227, 564.
Hydrarg. præcip. albus, 40.
ruber, 40.
Hydrocephalus a cause of amaurosis, 230.
Hydromeningitis, 55, 68, 293.
Hydrophthalmos anterior, 115.
Hydrops nervi optici, 152.
sacci lachrymalis, 503, 539.
subretinalis, 193, 298, 569.
Hyoscyamine, 36.
Hyperæmia of the iris, 247.
Hyperæsthesia optica, 763.
Hypermetropia, 608, 691, 718, 843.
a cause of neuro-retinitis, 175.
squint, 810, 834.
changed to myopia, 352.
Hyperopia, 691.
Hyperpresbyopia, 691, 697, 723.
Hypodermic injections, 31.
morphine, in atropine poisoning, 37.
suppurative keratitis, 87.
vascular keratitis, 59.
Hypohæma, 247.
Hypopyon, 73, 244, 249, 256, 281.
Hypopyum keratitis, 73.

Iced compresses in abscess of the lid, 438.
diphtheritic conjunctivitis, 398.
Identical meridians, 786.
Idiopathic blepharospasm, 795.
Immediate consequences of tenotomy, 822.
Immobility of the pupil, 213.
Impairment of vision in atrophy of nerve, 208.
irido-cyclitis, 292.
iritis, 248.
trachoma, 404.
a cause of nystagmus, 840.
Impetigo faciei, 65.
Incapsulation of foreign bodies, 138, 139.
Incision of abscess of the lid, 438.
orbit, 529.
hordeolum, 451.
staphyloma, 129.
skin of lid for blepharitis, 446.
walls of tear duct, 510.
Incomplete correction in astigmatism, 738.

Incomplete evacuation of cataract, 663.
Incorrect apposition of flap, 664.
Increase of convexity of cornea, 704.
lens, 704.
refraction in staphyloma posticum, 352.
Indications for discission, 655.
the use of mydriatics, 35.
Indirect method, 866.
vision, 681.
Inferior palpebral muscle, 430.
Inflammation of the canaliculi, 493.
conjunctiva, 357.
cornea, 48.
lachrymal gland, 492.
lids, 427.
mouths of the puncta, 492.
ocular capsule, 517.
retina, 154.
sclera, 334.
tissues of the orbit, 517.
vitreous, 183.
Inflammatory reaction after iridectomy, 267
Infra-trochlear nerve, 9.
Inherited staphyloma posticum, 354.
syphilis, 76.
Injecting lachrymal duct, 508.
Injections, hypodermic, 31.
Injuries of the ciliary region, 293.
Innervation, disturbances of, 7.
Inoculation a cause of blennorrhœa, 380.
ophthalmia neonatorum, 391.
for the cure of pannus, 99.
Insufficiency of the muscles, 796.
Integument of the lids, 430.
Interfibrillary passages, 590.
Intermittent amaurosis, 768.
ophthalmia, 8.
Internal lachrymal fistula, 497.
ophthalmia, 279.
remedies in diphtheritic conjunctivitis, 398.
Interruptions of visual field, 211, 232.
Intra-cranial pressure, 178.
Intraocular circulation, 1.
ganglionic system, 33.
hemorrhage, 318.
myotomy, 271, 317.
pressure, 1, 35, 150, 280, 291, 304, 338.
effect of removal of, 130.
tumors, 575.
Inunction treatment, 28.
in hyalitis, 142.
irido-choroiditis, 300.
iritis, 258.
Inversion of lids, 373.
Iodide of potassium, 41.
in ocular paralysis, 851.
neuro-retinitis, 181.
Iodine salve in corneal opacity, 109.
Iridectomy, 261.
for removal of foreign body from anterior chamber, 264.
in blennorrhœa, 386.
flap-extraction, 635.
glaucoma, 317, 321.
irido-choroiditis, 301.
iritis, 257.
kerato-globus, 120.
pterygium, 424.
Iridectomy in sclero-choroidal staphyloma, 345.
staphyloma anticum, 119, 122.
staphyloma posticum, 356.
suppurative keratitis, 89, 91.
with extraction in irido-choroiditis, 301.
Iridenkleisis, 269, 318.
Irido-capsulitis, 245.
Irido-choroiditis, 245, 281, 291.
a result of peripherical extraction, 641.
sympathetic, 298.
Irido-cyclitis, 245, 281, 291.
a result of peripherical extractions, 641.
Iridodesis, 268.
Iridodonesis, 603.
Iridotomy, 271.
Iris, anatomy of, 240.
atrophy of, 246, 253.
granulations of, 243.
gummy tumors of, 243.
hemorrhages from, 249.
stroma of, 241.
papillary excrescences of, 243.
prolapse of, 93, 664.
purulent infiltration of, 244.
staphyloma of, 85.
Iritis, 240.
causes of, 250.
complications of, 245.
secondary, 250.
serous, 243.
malarial, 250.
suppurative, 256, 258.
sympathetic, 250.
syphilitic, 251.
Iron and nutrients in diphtheritic conjunctivitis, 400.
Irregular astigmatism, 679.
Irritants, 39.
in blennorrhœa, 387.
corneal opacities, 109.
chronic ulcers, 90.
Irritating ointments, 40.
powders, 40.
vapors, 17.
Ischæmic amaurosis, 220.
Isinglass plaster for closing lids, 265.
Issues, 30.

Jaeger's test-types, 682, 875.
Janin's ointment, 445.

Kakochymia, 548.
Keloid, 551.
Keratectasia, 81, 118.
Keratectomy, 120.
Keratitis, 48.
cicatricial, 107.
neuro-paralytic, 78, 546.
diffuse or parenchymatous, 70.
pannosa, 463.
phlyctenular, 60.
postica, 55.
punctata, 55, 68, 293.
suppurative, 73, 87.
vascular, 53, 57.
Keratocele, 81.
Keratoconus, 115.
Keratoglobus, 115.

Kerato-iritis, 245.
Keratonyxis, 656.
Knapp's operation for staphyloma, 131.
Kopiopia, 697.

Laborraque's solution, 66.
Lachrymal abscess, 497.
calculi, 503.
caruncle, 357.
duct, 488.
fistula, 497.
gland, 488.
muscle, 428.
nerve, 9.
puncta, 488.
sac, 489.
destruction of, 510.
Lactate of zinc in anæsthesia optica, 768.
Lacus lachrymalis, 491.
Lagophthalmos a cause of xerosis, 426.
cholericus, 848.
paralyticus, 478.
spasticus, 796.
Lamina cribrosa, 1, 145.
fusca, 242, 273.
Laminaria digitata probes, 509.
Laminated cataract, 610, 618.
Lamp-shades, 19.
Lapis divinus, 41.
infernalis, 43.
mitigatus, 43.
Lateral illumination, 864.
Laudanum in corneal opacity, 109.
diffuse keratitis, 72.
pannus, 97.
Laws of motion of the eye, 780.
Lead-deposit on cornea, 90.
poisoning a cause of paresis, 748.
probe of Scarpa, 508.
water-compresses, 393, 652.
Leeches, 25.
artificial, 26.
after cataract extraction, 649.
in abscess of the lid, 438.
orbit, 529.
diphtheritic conjunctivitis, 398.
membranous conjunctivitis, 377.
nephritic retinitis, 191.
vascular keratitis, 59.
Lens, crystalline, 589; capsule of, 589; curvature and refractive conditions, 677; dislocation, 616; ectopia, 616; escape of, through ruptured cornea, 85; entozoa, 614; foreign bodies in, 613; inflammation of, 618; injuries, 612; luxation, 616; senescence, 610.
Lenticular causes of astigmatism, 696.
Leontiasis, 542.
Lesions of ciliary processes, 614.
Leucæmic retinitis, 168.
Leucoma, 101.
Levator palpebræ, 428, 429.
Lice a cause of blepharitis ciliaris, 442.
Lids, abscess of, 431, 437; acne, 433, 439; anatomy of, 427; chancre of, 433; erysipelas of, 432; eversion of, 477; inflammation of, 427; inversion of, 470; œdema of, 431; lupus of, 432; syphilitic ulcer of, 432; eruptions, 433.
Liebreich's corneal extraction, 672.
Ligamentum pectinatum, 240.
palpebrarum, 428.
Ligation of carotid for cure of tumors, 570.
pterygium, 422.
Light, 18.
Limbus conjunctivalis, 357, 359, 360.
Limitation of mobility, 816.
range of accommodation, 696.
visual field, 207, 232, 308, 321.
Linear extraction, 630, 642, 657.
Line of direction, 680.
Lipoma, 541.
Liquefaction of vitreous, 135, 140.
Listing's law, 779.
Lithiasis, 538.
Local depletion in blennorrhœa, 386.
suppurative keratitis, 87.
Localization of images, 831.
London-smoke glasses, 20.
Long ciliary nerves, 242.
Loring's cataract glasses, 655.
ophthalmoscope, 870.
Loss of vision in amaurosis, 231.
corneal opacity, 105.
exudative retinitis, 185.
Lupus of the conjunctiva, 365.
lids, 432.
Luscitas, 793.
Luxatio lentis, 616.
Lymph cataract, 255.
corpuscles, 49.
Lymphatics of optic nerve, 146.
conjunctiva, 359.

Macula cornea, 101.
lutea, 154, 157.
Madarosis, 409.
partial, complete, 444.
Malarial fever a cause of paresis, 748.
Malignant pustule of lids, 432.
Manometer, 6.
Marrotte's blind-spot, 681, 211.
Marsh mallow, 445.
Maxwell's circle, 762.
Mechanical ectropion, 479.
injuries of eye, 14.
Median plane, 778.
Medullary carcinoma, 558.
fungus, 543.
sarcoma, 548, 550, 553
Megalopsia, 175, 697, 761.
Meibomian glands, 428.
Melanoma, 543.
Melanotic carcinoma, 558.
sarcoma, 552.
Meliceris, 538.
Membrana-capsulo-pupillaris, 591.
chorio-capillaris, or Ruischiana, 273.
Membrane of Descemet, 50, 73, 102, 104, 124.
Membrane of Bowman, 49, 50, 102.
Demour, 50.
Membranous conjunctivitis, 365, 376.
nasal canal, 489.
Meningitis, 177.
epidemic cerebro-spinal, 177.
Mental diseases in amaurosis, 233.
Mercury, 28.
Mercurial inunction in exudative retinitis, 187.

Mercurial inunction detachment of retina, 200.
irido-choroiditis, 300.
iritis, 258.
nephritic retinitis, 192.
neuro-retinitis, 181.
staphyloma posticum, 356.
Merits of different cataract operations, 641.
Metallic incrustations on cornea, 104.
Metamorphopsia, 175, 197, 353, 696, 761.
Metastatic deposits in sarcoma, 556.
panophthalmitis, 328, 371.
Methodic exercise of eyes, 769.
Method of holding open the eyelids, 646.
recording visual field, 209.
detecting simulated amaurosis, 213.
Mikropsia, 175, 697, 747, 761, 768.
Middle converging point, 679.
focus, 679.
Milk in xerosis, 426.
Milium, miliary nodules, 538.
Mitigated stick, 98, 411.
Mixed astigmatism, 735.
cataract, 595.
nystagmus, 839.
trachoma, 402.
Mobility of the eyes in squint, 830.
Modifications of squint-operation, 820.
Modified linear extraction, 639.
Modus operandi of mydriatics, 83.
Molecular opacities of lens, 591.
Molluscum, 540.
Monochromatic aberration, 678.
Monocular diplopia, triplopia, polyopia, 680, 696.
vision, 831.
Monostoma lentis, 614.
Moon-blindness, 766.
Morbid tumors, 535.
Morphia, 30.
an antidote to atropia, 37.
as a myotic, 37.
Mosaic layers of retina, 154.
Movements of eyeball, 777.
Moxas, 30.
Mucous polypi, 539.
Müller's supporting fibres, 156.
Muscæ volitantes, 757.
premonitory of asthenopia, 758.
Muscles of the eye, 775; of the lids, 428; lachrymal apparatus, 491; bringing forward of, 825; Horner's, 429; motions of, 778; orbicularis, 428; paralysis of, 842; spasm of, 839.
Muscular insufficiency, 832.
Mydriasis, 250, 698.
Mydriatics, 32, 35, 625.
in myosis, 756.
Mycloplaxi, 554.
Myocephalon, 104.
Myodesopsia, 758.
Myoma, 543.
Myopia, 691, 700.
a cause of squint, 812, 833.
apparent, 753.
in distance, 753.
from opacity of cornea, 108.
posterior staphyloma, 353.
Myopic presbyopia, 708.
Myosis, 38, 698, 755.
Myotics, 37.
Myotomy, intraocular, 317.
Myxoma, 541.
Myxosarcoma, 549, 552.

Nævi venosi, 561.
Narcotics, 30.
Narrowing of aqueous chamber, 305.
Nasal catarrh a cause of lachrymal blennorrhœa, 501.
Naso-ciliaris, 9.
Natural and extreme far-point, 694.
Near-point, 702.
sightedness, 705.
Necessary properties of glasses, 714.
Necrosis of lachrymal bone, 497.
Negative accommodation, 744.
Negro fundus, 277.
Neoplasia of cornea, 54.
Nephritic retinitis, 167, 189.
Nerve of accommodation, 687.
Nerves of conjunctiva, 360.
iris and ciliary muscle, 242.
lids, 431.
the ocular muscles, 776.
Nervous elements of the retina, 154.
Nervus opticus, 144.
Neuritis optici, neuro-retinitis, 153; apoplectic, 173; circumscripta, 166, 184, 186; descendens, 153, 177; diffuse, 172; embolic, 176; exudative, 166, 183; from heart and lung disease, 176; hydrops, 152; leucæmic, 168; nephritic, 167, 189; pigmentosa, 237; purulent, 167; suppurative, 167; syphilitic, 176; tuberculous, 167.
Neuro-paralytic ophthalmia, 11.
ulcerations, 546.
Nictitation, 795.
Night-blindness, 771.
Nitras argenti mitigatus, 43.
Nitrate of silver, 41.
for healing up lachrymal fistula, 510.
in amaurosis, 234.
blennorrhœa, 387.
blepharitis ciliaris, 446.
conjunctivitis, 374.
corneal opacity, 109.
corneal ulcers, 90.
corneal staphyloma, 120.
diphtheritic conjunctivitis, 399.
eczema, 66.
hordeolum, 452.
ophthalmia neonatorum, 393.
pannus, 97.
symblepharon, 458.
trachoma, 411.
Nodal point, 680.
Normal astigmatism, 695.
Nourishment of patient after cataract extraction, 648.
Nuclear cataract, 595, 602, 617.
point, 789.
surface, 789.
Nutrition of lens, 591.
Nyctalopia, 763.
Nystagmus, 794, 839.
from corneal opacity, 108.

Obliteration of lachrymal sac, 510.
nasal duct, 509.
Ocular conjunctiva, 357.
Œdema of lids, malignant, 432.

Œdema of retina, 169.
Ointment for chalazion, 452.
of iodide of potassium in acne ciliaris, 440.
of yellow oxide of mercury in blepharitis ciliaris, 445.
of yellow oxide of mercury in phlyctenular conjunctivitis, 418.
of yellow oxide of mercury in trachoma, 414.
Onyx, 75.
hemorrhagic, 55.
Opacities of the cornea, 101.
after iridectomy, 267.
epithelial, 101.
from keratonyxis, 656.
parenchymatous, 101.
tendinous, 101.
Opacities of the vitreous, 139.
Opaque nerve-fibres, 157.
Opening of lachrymal sac, 507.
Opera-glasses, 711.
Operation for chalazion, 453.
cicatricial staphyloma, 127.
diminishing wall of lachrymal sac, 508.
ectropion, 480.
entropion, 473, 475.
extraction of floating cataract, 644.
membranes in the vitreous, 142.
nystagmus, 841.
ptosis, 853.
removal of membraniform obstructions, 645.
strabismus, 819.
symblepharon, 460.
trichiasis, 464.
passing thread through sclera and vitreous, 347.
splitting a staphyloma, 128.
Operations for staphyloma, incision, excision, 129; Critchett's, 130; Knapp's, 131; splitting, 128; ablation, 129.
Ophthalmia, anterior, 279; general, 279; granular, 401; impetiginosa, 62; intermittent, 8; internal, 279; morbillosa, 371; neonatorum, 390; neuroparalytic, 11, 76, 546; post-febrilis, 294; psoriaca, 62; scarlatinosa, 371; scrofulosa, 63; serpiginosa, 62; sympathetic, 297; variolosa, 371.
Ophthalmoblennorrhœa, 361, 379.
infantum, 390.
Ophthalmocenthese, 200.
Ophthalmoplegia paralytica, 847.
Ophthalmoscope, 865.
Ophthalmoscopical appearances in astigmatism, 731; in atrophy of optic nerve and retina, 205; in cataract, 602; in cysticerci in the vitreous, 577; in detachment of the retina, 195; in diffuse neuroretinitis, 173; in exudative retinitis, 183; in glaucoma, 305; in glioma of the retina, 575; in hyalitis, 139; in hypermetropia, 718; in intra-ocular tumors, 575; in myopia, 700; in nephritic retinitis, 189; in posterior staphyloma, 351; in retinitis, 183; in retinitis pigmentosa, 237; in rupture of the choroid, 286; in sclero-choroidal staphyloma, 341; in tubercles in the choroid, 285; in typical pigment degeneration, 237; of choroid, 276; of optic nerve, 147; of retina, 157.
Ophthalmospasmus, 795.
Ophthalmostat, 262.
Ophthalmotonometer, 1.
Opium as a myotic, 37.
Optical hyperæsthesia, 765.
Optic nerve, anatomy of, 144.
excavation of, 146, 203, 306.
atrophy of, 202.
functional diseases of, 761.
inflammation of, 152.
ophthalmoscopical appearances of, 147.
Optic thalamus, 228.
Optometers, 700.
Ora serrata, 273.
Orbicularis palpebrarum, 428; paralysis of, 797; spasm of, 795.
Orbit, anatomy of, 513; abscess of, 511, 526, 848; caries of, 531; emphysema of, 518; extravasations into, 518; inflammation of, 517; periostitis of, 517, 531; tumors of, 569.
Orbito-palpebralis, 429.
Orgagoid growths, 539.
Oscillatory nystagmus, 839.
Ossification, 299.
Osteoma, 542.
Osteosarcoma, 542, 549.
Osteo-steatoma, 542.
Ostitis of orbit, 518.
Oval appearance of disc, 352.
glasses, 713.
Over-ripe cataract, 627, 642.
Oxide of zinc, 41.
Ozœna a cause of amaurosis, 225.

Pachyblepharosis, 443.
Pagenstecher's ointment, 41.
Pain in blennorrhœa, 379.
irido-cyclitis, 292.
iritis, 247.
panophthalmitis, 326.
Palpebral conjunctiva, 357.
ligament, 428.
Pannus, 53, 95; causes of, 96; crassus, 95; herpeticus, 417; results of, 96; siccus, 97; tenuis, 95; treatment of, 97; from blennorrhœa, 382; from trachoma, 409.
Panophthalmitis, 325.
Papilla, discolorations of, 322.
in cloudy atrophy, 207.
Papillary excrescences, 243, 248, 254.
trachoma, 401.
Papilloma, 557.
Paracentesis corneæ, 94.
in blennorrhœa, 386.
diffuse keratitis, 72.
glaucoma, 317.
iritis, 258.
keratitis punctata, 69.
panophthalmitis, 332.
sclero-choroidal staphyloma, 345.
staphyloma of the cornea, 120.
staphyloma posticum, 356.
suppurative keratitis, 88, 91.
ulcer of the cornea, 93.
Parenchymatous opacities, 101.
Parry's disease, 520.
Pars ciliaris retinæ, 154.
Partial sclero-choroidal staphyloma, 340.
Paralysis of accommodation, 747.
the muscles of the eyeball, 842, 849.

Paralysis of the lateral recti, 844.
oblique muscles, 846.
superior or inferior recti, 845.
third pair of nerves, 847.
Paralytic ectropion, 478.
lagophthalmia, 478.
lagophthalmos, 797.
mydriasis, 751.
Patches of exudation, 377.
Pearl-tumors, 538.
Pemphigus conjunctivæ a cause of xerosis, 426.
Perception of colors, 209.
Perforation of cornea a cause of cataract, 614.
Perimeter for measuring visual field, 209.
Periostitis of orbit, 225, 517, 531.
Peripherical linear extraction, 665.
Periscopic glasses, 714.
Phakitis, 593, 618.
Phakohymenitis, 592.
Phakohydropsie, 598.
Phacomalacia, 596.
Phacoscleroma, 595.
Phlebectasia, 561.
Phlegmonous inflammation of lachrymal duct, 495, 497.
Phlyctenular conjunctivitis, 416.
keratitis, 60.
Phosphenes, 209, 763.
Photophobia, 62, 63, 417.
Photopsia, 209, 292, 764.
in atrophied eyes, 300.
in glaucoma, 309.
Phthisis bulbi, 86, 298, 330.
Physaliphores, 133.
Physiological whiteness of disc, 232.
excavation, 146.
Physostigmine, 37.
Pigmentation of fundus, 277.
Pigment collections as seen in detachment of retina, 196.
layer of the iris, 240.
on the optic disc, 147.
Pinguecula, 540.
Pituitary gland, 228.
Plaques, 169.
Plaster, 15.
Plathymorphia, 721.
Plesiopia, 705.
Plexiform tumors, 560.
Plica semilunaris, 357.
Point of direct vision, 681.
middle converging, 679.
Poisoning by atropine, 33; local, 35.
Polar cataract, 139, 142, 293.
in retinitis pigmentosa, 237.
Polyopia, 116, 696.
monocularis, 680.
Polypus, fibrous, 548.
mucous, 539.
of lachrymal sac, 494.
Porus opticus, 148.
Position of patient after extraction, 647.
Positions of convergence, 781.
Positive accommodation, 744.
Posterior capsular cataract, 142, 602.
chamber, 240.
focal line, 679.
polar cataract, 351.
Posterior staphyloma of the sclera, 348.
symblepharon, 377.
synechia, 293.
Potassium, iodide of, 41.
Power of squinting eye, 805.
Pray's tables, 733.
Presbyopia, 697, 723.
Pressure-bandage in diphtheritic conjunctivitis, 399.
Pressure, intra-ocular, 1, 15, 304, 328.
intra-vascular, 150.
Prevention of symblepharon, 378, 458.
Primary and secondary positions, 778.
Prismatic glasses, 716.
after squint operations, 823.
in divergent squint, 836.
in spasm of accommodation, 754.
in paralytic deviations, 853.
Probing canaliculus, 504.
lachrymal duct, 504.
through nose, 508.
Prodromal appearances of sympathetic ophthalmia, 297.
Prognosis of amblyopia, 232.
atrophy of optic nerve, 232.
Progressive development of posterior staphyloma, 707.
Projection of images, 792.
Prolapse of the iris in flap extraction, 664; in ulcer of the cornea, 93.
uvea, 344.
vitreous in linear extraction, 659; in flap extraction, 663; in peripherical linear extraction, 669.
Protective bandage, 15; after cataract extraction, 647; in detachment of the retina, 200; in herpes of the cornea, 65; in herpetic pannus, 418; after iridectomy, 265; in irido-choroiditis, 300; in neuro-retinitis, 180; in rupture of the sclera, 345; in suppurative keratitis, 87, 91; in vascular keratitis, 59.
Prothesis ocularis, 583.
Protuberantia sclerotica, 354.
Pseudo-membranes to be removed from conjunctival sac, 400.
Pseudoplasms, 538.
Pseudo-paralysis, 748.
Pterygium, carnosum, crassum, sarcomatosum, tenue, vasculosum, 419.
Ptosis, 384, 796.
Pulsating tumors, 562.
Pulsation of retinal vessels, 149; in glaucoma, 304.
Puncta lachrymalia, 491.
Punctum lachrymalis, 488.
Puncture in corneal staphyloma, 120.
of retina, 200.
of sclera, 200.
Pupil, artificial, 113, 261; displacement of, 111; movements of, 245; in sclerotic, 113.
Purgatives, 29.
Purulent retinitis, 167.
Pustules of conjunctiva, 366.
Pyorrhœa, 379.

Quinine used locally after cataract extraction, 652.
as a cause of amaurosis, 220.
Quota of accommodation, 685.

Radiating fibres of the iris, 240.
Range of accommodation, 685.

Range of accommodation in hypermetropia, 722.
Raphania, 611.
Reclination of cataract, 632.
Recurrent gliomatous orbital tumors, 547.
retinitis, 168.
Red-blindness, 762.
Reddening of the papilla, 705.
Reflex relations of sympathetic, 12.
Reflex, white, 342.
Refractive media, 677.
power of lens, 678.
values of glasses, 693.
Refraction, anomalies of, 677.
Register of field of vision, 210.
Regular astigmatism, 678.
Relation of squint to amount of accommodation, 808.
Relations of co-ordination, 688.
Relative accommodation, 744.
Relative cure of cataract, 619, 622.
hypermetropia, 720.
Remaining behind of pigment layer in iridectomy, 266.
Remote causes of amaurosis, 224.
Removal of sclero-choroidal staphyloma, 346.
Replacement of prolapsed uvea, 345.
Resorption of soft lens matter, 619, 621.
Restrictions in the use of mydriatics, 35.
Results of amaurosis, 231.
Retaining-suture in squint, 820.
Retina, anatomy of, 154; atrophy of, 201; corresponding points of, 791; detachment of, 193, 298; functional disorders of, 761; inflammation of, 154; ophthalmoscopical appearances of, 157; pigment degeneration of, 237; puncture of, 200; senile changes of, 162.
Retinal anæsthesia, 724.
glioma, 575.
hyperæsthesia, 743.
vessels as seen in detachment, 196.
hemorrhages, 7.
Retinitis, 154; circumscripta, 166; exudative, 183; nephritic, 189; pigmentosa, 237.
Retino-ciliary hyperæsthesia, 742.
Retino-choroiditis, 166.
Retrogressive fluid total cataract, 642.
Retro-tarsal fold, 358.
Retention tumors, 538.
Ruischiana membrana, 273.
Rheumatic paralyses, 848.
Ring around optic disc, 147.
Ripe cataract, 626.
Rods and cones, 680.
Rotatory nystagmus, 839.
Round glasses, 713.
Rules for choosing glasses, 715.
using glasses, 739.
Rupture of the choroid, 286.
choroidal vessels, 288.
cornea, 82.
retina, 199.
sclera, 344.
zonula, 622.
Sarcoma, 548, 576.
telangiectodes, 549.
Saturnine amaurosis, 219.
Scarification of the conjunctiva, 98, 386, 398.
Scalping of lid, 446.
Scarpa's ointment for blepharitis ciliaris, 445.
Schematic eye, 684.
Schlemm's canal, 334.
School-education a cause of myopia, 354.
Schwann's membrane, 282.
Sclera, sclerotic, 334; senile changes of, 335; regulative influence of, 4; staphyloma of, 338.
Scleral incision, 639.
staphyloma, 338.
Scleritis, sclerotitis, 334.
Sclerochoroidal staphyloma, 298, 338; anticum, annulare, 342; partial, 340; posticum, 348; total, 338; traumatic, 344.
Sclero-choroiditis, 336.
Scleronyxis, 644.
Sclerosis of the sclera, 336.
Scleroticonyxis, 655.
Sclerotitis, scleritis, 334.
Scotoma, 608, 757.
in staphyloma posticum, 353.
Scrofulous ophthalmia, 63, 67.
Sebaceous tumors, 538.
Seborrhœa ciliaris, 434.
Sebum palpebræ, 428.
Secondary gliomatous foci, 547.
Secretions in blennorrhœa, 379.
of conjunctiva, 360.
Senile changes in choroid, 277.
retina, 162.
vitreous, 135.
ectropion, 478.
involution of the lens, 723.
Separation of the retina, 193.
Sequelæ of iritis, 252.
Serous choroiditis, 279.
iritis, 243.
Setons, 30.
Shades, 19.
Sharply bounded defects in visual field, 232.
Shortening of conjunctival sac, 377.
Short-sightedness, 700.
Shrinkage of the vitreous, 141.
Siliculose cataract, 657.
Simple astigmatism, 735.
cerate for acne ciliaris, 440.
glaucoma, 315.
Simulated amaurosis, 214.
Slitting external canthus in blennorrhœa, 386.
Sluggishness of pupil, 245, 305.
Smoke-gray glasses, 20.
Smoky pupil in old persons, 592.
Snellen's test-type, 682.
Snowden's speculum, 665.
Snow-blindness, 766.
Snuff-taking, 17; a cause of blennorrhœa of the lachrymal passages, 501.
Softening of the brain a cause of amaurosis, 227.
Soft cataract, 596, 617.
Solitary pustule of the border of the lid, 439.
Solution of salt in xerosis, 426.
Spasmodic hare's eye, 796.
Spasm of accommodation, 33, 753.
ciliary muscle, 753.
orbicularis palpebrarum, 753, 795.
levator palpebræ superioris, 796.
sphincter pupillæ, 753.
Spastic lagophthalmus, 796.
Spawn-like trachoma, 364.

Spectacles, 712; binocular, 712; colored, 20; concave, 712; convex, 725–728; cylindrical, 737–739; dust, 16; glass, 16; mica, 16; periscopic, 714; prismatic, 716, 754, 823, 836, 853; protective, 20; stenopäic, 112, 121; strabismus, 814; wire, 16; in asthenopia, 744; in divergent squint, 836; in hypermetropia, 724.
Spectrum, muco-lachrymal, 371.
Sphincter muscle of the iris, 241.
Spintherism, 764.
Spontaneous dislocation of lens, 616.
free motion of lens, 616.
luxation, 616.
Spoon-operation, 631.
Spotted retina, 237.
Squint, 793.
Squint-angle, 829.
Stair-like ulcers of cornea, 76.
Staphyloma, 115, 129; ablation of, 129; annulare, 342; anticum, 342; excision of, 129; incision of, 129; iridis racemosum, 87.
Staphyloma of cornea, 85; scleral, 338; sclero-choroidal, 298, 338.
Staphyloma posticum, 703, 706.
a cause of detachment of the retina, 197.
a cause of divergent squint, 833.
in hypermetropia, 354.
Scarpæ, 338.
Steinheil glass cones, 711.
Steatoma, 540.
Stenopäic spectacles in opacity of cornea, 111.
staphyloma anticum, 121.
Stokes' astigmatic lens, 734.
Strabismus, 799; angle of, 799, 800, 801; alternating, 801, 802, 806; apparent, binocular, concomitant, 801; constant, continual, convergent, 799; divergent, 829; hypermetropic, 810, 834; incongruous, 804; intercurrent, 811; monolateral, 801; myopic, 811, 834; paralytic, 809; periodic, 807, 811, 814; secondary, 826.
Strabometer, 801.
Strabotomy a purely cosmetic operation, 817.
Straining of the accommodation, 354.
the eyes, 22.
Stratum pigmenti, 273.
Streatfield's peripherical extraction, 671.
Stroma of the iris, 240.
Strychnine injections in amaurosis, 234.
Stye, 435, 448.
Style for blennorrhœa of lachrymal passages, 508.
Subretinal effusion, 193.
extravasations of blood, 194.
Substitutes for iridectomy, 267.
Subtarsal muscle, 429, 471.
Suction method of extraction, 636.
Sudden changes of temperature, 18.
Sugar of lead in trachoma, 411.
Sulphate of cadmium, 41.
copper, 41.
in trachoma, 412.
blepharitis ciliaris, 446.
conjunctivitis, 374.
corneal opacity, 109.
diffuse keratitis, 72.
ointment, 374, 412.
solution, 412.
Sulphate of zinc, 41, 66.
Superior palpebral muscle, 429.
Suppression of perceptions, 806.
Suppuration of cornea after extraction, 637.
the globe, 347.
Suppurative choroiditis, 283, 325.
induced by transplantation, 227.
keratitis, 76, 78.
retinitis, 167.
Supra-trochlear nerve, 9.
Suture in flap-extraction, 664.
Sutures in squint operations, 820.
Swelling of the conjunctiva, 362.
papilla in retinitis, 165.
Symblepharon, 398, 457.
a result of trachoma, 408.
Sympathetic nerve, 8.
ophthalmia, 122, 297, 555.
Symptomatic ectropion, 479.
Syncanthus externus and internus, 458.
Synchisis, 135, 140.
scintillans, 140.
Syndesmitis, 357.
Synechia anterior, 294; operation for, 113.
Synechia posterior, 248.
Syphilis, constitutional, 70.
a cause of retinitis pigmentosa, 238.
Syphilitic iritis, 251.
neuro-retinitis, 176.
ulcers of lids, 432.

Tabes dorsalis a cause of amaurosis, 230.
Tannin, 41.
in glycerine, 45.
ophthalmia neonatorum, 393.
Tapetum, 154, 273.
of the iris, 240.
Tapping subretinal fluid, 201.
the vitreous, 636.
the anterior chamber, 94.
Tarsal cartilages, 427.
glands, 428.
ligament, 428.
Tarsoraphy, 481, 483, 827.
Tearing detached retina, 201.
iris from ciliary ligament, 266.
Tears, tear-streams, tear-sac, 491.
Telangiectasiæ, 561.
Tendinous-looking opacities, 101.
Tenon's capsule, 514, 575.
Tenotomy, 837.
Tension measurer, 304.
Tensor choroidea, 275.
Teratoid tumors, 539.
Testing the vision after extraction, 648.
Test-types, 682, 872.
Tetanus oculi, 795.
Theory of accommodation, 687.
Thrusting experiment, 817.
Time of development of nystagmus, 840.
Tincture of opium, 41.
for keeping down granulations, 823.
in mydriasis, 752.
phlyctenular conjunctivitis, 418.
Tobacco-smoke, 17.
a cause of amaurosis, 219, 234.
conjunctivitis, 372.

Tonics in paralysis of accommodation, 749.
Tonometers, 1.
Total staphyloma, 123.
Trabeculæ, 241.
Trachoma, granular, papillary, 401; mixed, diffuse, 402; a result of blennorrhœa, 384; with granulations, 364.
Trachomatous bodies, 363.
Translators' appendix, 863.
Transparency of retina, 154.
Transparent total staphyloma of the globe, 338
Transplantation of pterygium, 423.
cornea, 113.
Transverse section in cataract extraction, 633.
Traumatic amaurosis, 767.
cataract, 643.
causes of conjunctivitis, 372.
Trichiasis, 444, 462; a cause of xerosis, 426; from trachoma, 409.
Trichiniasis a cause of paresis, 748.
Trichosis bulbi, 541.
Trifacial zoster, 62.
Triplopia, 696.
Trochlea, 775.
Tubercles in choroid, 285.
brain a cause of amaurosis, 227.
Tuberculous retinitis, 167.
Tuberculous panophthalmitis, 328.
Tumors, 535.
extraocular, 569.
intraocular, 575.
of orbit causing detachment of retina, 198.
base of brain, 225.
cerebellum, 229.
cerebrum, 229.
Tunica vaginalis bulbi, 775.
vasculosa, 273.
elastica, 273.
Tylosis, 443.
Typical pigment degeneration of retina, 237.

Ulceration of lachrymal duct, 497.
Ulcerative perforations of the cornea, 327.
Ulcer of conjunctiva, 366.
cornea, 75, 392.
from blennorrhœa, 383
diphtheritic conjunctivitis, 398.
perforating, 83, 84.
Uncleanliness a cause of trachoma, 404.
Unguis, 75.
Uræmia a cause of paresis, 748.

Vapor of cooked liver for hemeralopia, 773.
Variation in refraction, 694.
Variola a cause of lachrymal blennorrhœa, 501.
Vasa vorticosæ, 242, 276.
Vascular keratitis, 53, 57, 58, 382.
Veils, 20.
Veins of the orbit, 515.
Venous ciliary plexus, 276.
Venous pulsation, 149.
thrombosis, 421.
Vertigo, 792.
Vesicants, 17.
Vesica pinguis, 551.
Vesicles on conjunctiva, 366.
Vessels in optic nerve, 148.
Violet-blindness, 763.
Visual axis, 677.
field, hemiopic contractions of, 213.
interruptions of, 213, 232, 233.
limitations of, 213, 237, 238, 321.
mapping out, 208.
register of, 211.
line, 680.
plane, 778.
Vitreous cataract, 293.
anatomy of, 133.
blood in, 138.
detachment of, 141.
escape of, 267.
foreign bodies in, 137.
inflammation of, 133.
nutrition, 133.
opacities of, 139.
Vitrina, 134.
Voluntary co-ordination, 783.
squint, 807.
Vortex purulentus, 74.

Warm applications in pannus, 98.
panophthalmitis, 332.
suppurative keratitis, 87, 90.
Warts, 551.
Washing out anterior chamber, 643.
Water-closets, 17.
Wax bougies for tear-duct, 509.
Wearing metallic tube in tear-duct, 509.
White precipitate ointment for blepharitis, 445.
reflex from fundus, 342.
Wind, 18.
Window-curtains, 19.
Wounds of iris in flap extraction, 662.
lens, 612.

Xerophthalmia, 365, 398, 425.
Xerosis, 425.
from trachoma, 409.
in exophthalmic goitre, 522.

Yellow ointment in corneal opacity, 109.
diffuse keratitis, 72.
herpes of the cornea, 65.
pannus, 97.
vascular keratitis, 59.

Zinc, oxide of, 41.
sulphate of, 41.
Zonula, 134.
Zoster, 62.

We desire to express our acknowledgments to Dr. David Webster, clinical assistant to the Manhattan Eye and Ear Hospital, for the preparation of this index.—TRANSLATORS.

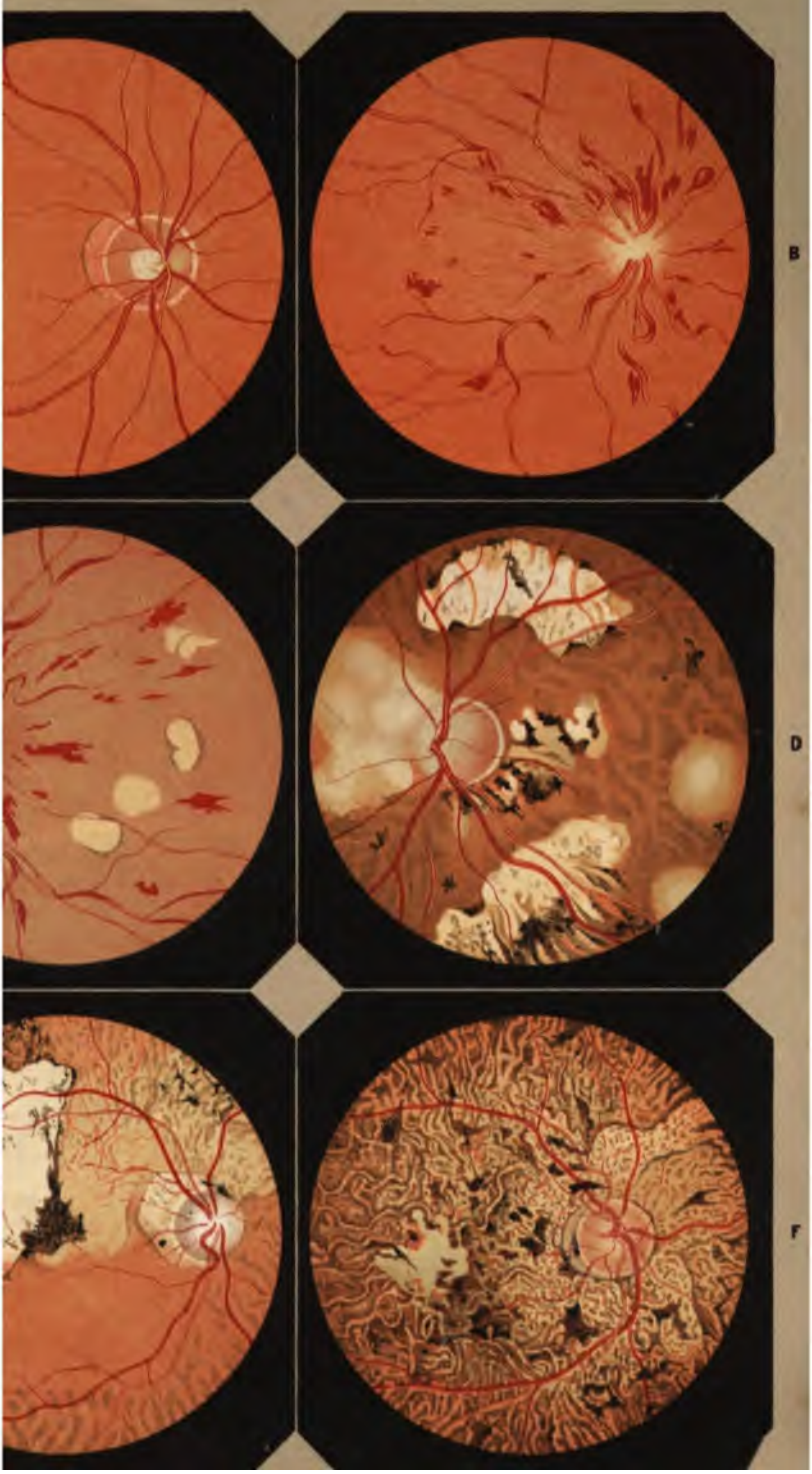
B
D
F

H

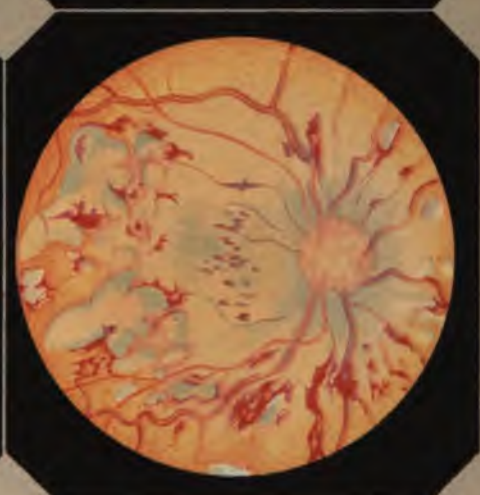

K

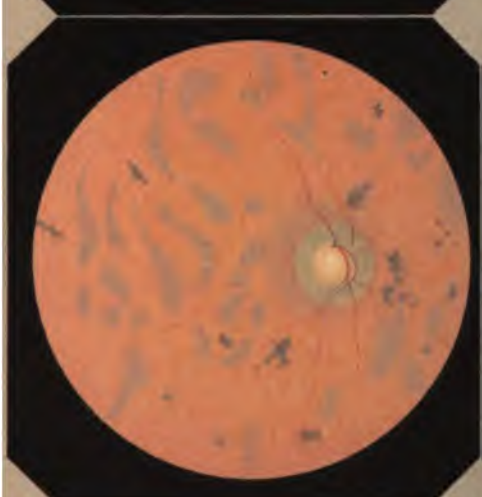

M

Lith. Anst. v. F. Köke in Wien.

F H K O S 3

U Y A C E G L 2

LANE MEDICAL LIBRARY

To avoid fine, this book should be returned on or before the date last stamped below.

MAR -3 1937		

Q46 Stellwag, v.C. K.
S82h Treatise on the dis-
1873 eases of the eye.
4th ed. 483

NAME DATE DUE

MAR 16 1937

This book i
COOPER ME
SAN FRA
and is not t
Library
under an